

Use of CO₂ Laser Vaporization for the Treatment of High-Grade Vaginal Intraepithelial Neoplasia

Myriam Perrotta, MD, Claudia E. Marchitelli, MD, Andrea F. Velazco, MD, Patricia Tauscher, MD, Graciela Lopez, MD, and Maria S. Peremateu, MD
Department of Gynecology, Hospital Italiano of Buenos Aires, Buenos Aires, Argentina

■ Abstract

Objective. In a series of cases of high-grade vaginal intraepithelial neoplasia (VaIN) at our institution, to analyze its clinicopathologic characteristics, diagnostic methodology, and therapeutic results obtained with the use of CO₂ laser vaporization.

Materials and Methods. Between January 2003 and December 2009, 28 patients with a diagnosis of high-grade VaIN were treated in our department using CO₂ laser vaporization. Of the 28 patients, 7 were lost to follow-up; 21 patients were followed up with cytological examination and colposcopy for therapeutic response. Median follow-up was 25 months (range = 12–78 months). The setting is an urban referral center, a private hospital with a high-grade complexity.

Results. Of the 21 patients evaluated, 18 are currently disease free after having undergone a single application of CO₂ laser vaporization with a cure rate of 86% (95% CI = 63.7%–97%). Three patients (14%) presented with persistence/recurrence and required a second application. Of these 3 patients, 2 are currently disease free, whereas 1 patient progressed to invasive carcinoma 11 months after a second procedure and was managed with partial colectomy and pelvic lymphadenectomy.

Conclusions. CO₂ laser vaporization was effective for the initial treatment of high-grade VaIN. However, a long-term follow-up is required due to the recurrent character of this disease. ■

Key Words: vaginal intraepithelial neoplasia, CO₂ laser, vagina

Reprint requests to: Maria S. Peremateu, MD, 3 De Febrero 3643 Floor 3° Apt "A" CP (1429) Ciudad Autonoma De Buenos Aires, Buenos Aires, Argentina. E-mail: maria.peremateu@hospitalitaliano.org.ar

The authors have no financial and conflict of interest to disclose.

© 2012, American Society for Colposcopy and Cervical Pathology
Journal of Lower Genital Tract Disease, Volume 17, Number 1, 2013, 23–27

Vaginal intraepithelial neoplasia (VaIN) is a rare premalignant condition that accounts for approximately 0.4% of intraepithelial lesions of the lower genital tract [1, 2]. The real incidence of VaIN is difficult to estimate because it represents a predominantly asymptomatic condition [3]. Risk factors are similar to those of cervical or vulvar neoplasia, with hysterectomy for cervical neoplasia a principal risk. Nevertheless, the natural history or the simultaneous presence of cervical intraepithelial neoplasia (CIN), a history of pelvic radiotherapy, and immunosuppression [4] are also included as risk factors.

Although the epidemiologic and histological correlates of CIN and VaIN are similar and both are caused by the human papillomavirus [5], recent research indicates that the cervix and the vagina may harbor different types of human papillomavirus. Human papillomavirus types with a preference for infection of vaginal tissues may be less oncogenic [6, 7]. These findings would imply that the likelihood of invasive cancer in women recently diagnosed with VaIN might be less than what was previously described in the literature because the natural history of VaIN based on a study performed, with a 3-year follow-up, in untreated patients suggests a high rate of regression (78%) compared with 13% of persistence and 9% of progression to cancer. On the other hand, unlike CIN, VaIN progression seems to require a longer period [8]. It may be possible to follow up women with low-grade VaIN, as has been recommended for CIN I [9].

Nevertheless, VaIN II/III is a true cancer precursor because invasive cancers have developed in VaIN lesions [10–12] and because excisional biopsies of high-grade VaIN have been found to contain foci of early invasive carcinoma [13]. Therefore, the risk of cancer in women with VaIN may be as high as 12% [14].

Treatment seems to interrupt oncogenesis in the vagina, but efficacy rates vary depending on the modality used [5]. High-success rates have been reported for cold-knife and loop excisions, chemotherapy, radiotherapy, immunotherapy, and laser ablation [13–19]. The available literature renders the analysis of results difficult, which can lead to erroneous conclusions. It only includes a small number of patients, because VaIN is a rare malignant lesion with different treatment modalities and because different series of cases include both of high-grade and low-grade VaIN.

The objective of this study was to present cases of high-grade VaIN managed at our institution and to analyze its clinicopathologic characteristics, diagnostic methodology, and therapeutic results obtained using CO₂ laser vaporization.

MATERIALS AND METHODS

Between January 2003 and December 2009, 28 cases of high-grade VaIN were diagnosed in the Unit of Lower Genital Tract Pathology of the Gynecology Department of Hospital Italiano of Buenos Aires. Our hospital is a private and high-complexity institution, which is considered a large referral center in our country.

Data were obtained from medical record reviews of the database of the Lower Genital Tract Unit of our institution. Consecutive cases of high-grade VaIN with a minimum 12-month follow-up were included. The diagnoses were performed through conventional cytological examination, colposcopy and colposcopically directed biopsy, as well as encompassed VaIN II and VaIN III.

All patients were treated with CO₂ laser vaporization, using Sharplan 1020 (Laser Labs Inc., Tampa, FL) and SmarXide MS (Deka M.E.L.A. S.R.L., Calenzano, Italy) laser generators. Patients underwent general anesthesia and were discharged on the same day. Estrogen therapy before the procedure was prescribed to all postmenopausal women. Application of 3% acetic acid and of Lugol iodine was carried out to define lesions for treatment. In all cases, a power density of 1,130 W/mL was used over a 1.5-mm spot diameter to a depth of 1.5 mm, with a 5 to 7 mm safety margin. The Watts setting was 25.4 W.

Postoperative assessment was performed at 15 and 30 days after laser therapy. Follow-up was carried out every 6 months during 2 years; afterward, surveillance was done annually. Both follow-up and surveillance were carried out through cytological examination and colposcopy.

Seven patients (25%) were excluded from the study because they were lost to follow-up, but they had good

tolerance to the treatment without major adverse effects at 30 days of the laser application. Only 2 of them presented vaginitis and were treated with local estrogen therapy. They had only been referred to our institution to carry out the treatment and were afterward followed up outside our institution. Therefore, they were not evaluated regarding the therapeutic response.

RESULTS

All patients, except 5, had abnormal Pap smear results. (3 atypical squamous cells of undetermined significance, 10 low squamous intraepithelial lesions, and 8 high squamous intraepithelial lesions) They all had abnormal colposcopic findings, which led to directed biopsy and diagnosed with high-grade VaIN. Twenty-one patients had at least 12-month of follow-up. Five of them (23.8%) were initially diagnosed with VaIN II, and the remaining 16 patients (76.2%) presented a diagnosis of VaIN III.

Median follow-up time was 25 months (12–78 months), and mean age at diagnosis was 51.38 years (26–85 years) (see Figure 1). Nine patients (42.85%) had a history of cervical high-grade squamous intraepithelial lesions, 8 of whom had undergone hysterectomy on this account and the remaining patient had been treated with cryotherapy. In addition, 1 patient (4.76%) had radical hysterectomy by invasive cervical cancer stage IB, and 2 patients (9.52%) had hysterectomy for benign pathological diagnosis (see Figure 2).

Four of the cases under study (19.04%) presented multiorgan involvement lesions of the lower genital tract at the moment of diagnosis. One of the patients was diagnosed with VaIN/CIN I and was treated with laser. In another patient with VaIN/vulvar intraepithelial neoplasia (VIN), the VaIN was treated with laser, and the VIN was treated with loop excision. The third patient was

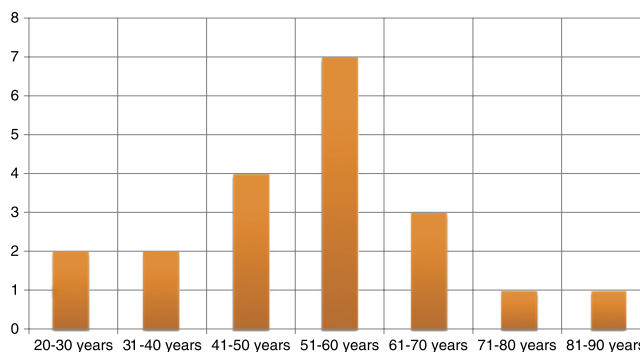


Figure 1. Mean age at diagnosis.

Risk factor for VaIN development	Number of patients
History of CIN	9
Hysterectomy for benign pathology	2
Cervical cancer	1
Immunosuppression	1

Figure 2. Risk factors.

diagnosed with VaIN/CIN III, and the 2 lesions were treated with laser. The remaining patient was diagnosed with VaIN/VIN/AIN III, who was the only immunosuppressed patient of the study because she was undergoing steroid therapy for systemic lupus erythematosus. This patient was treated with laser for VaIN and surgical resection for VIN and AIN (see Figure 3).

No major complications related to the treatment were identified in this series except for vaginitis that required local treatment.

Of the 21 patients evaluated, 18 had negative cytological examination result and normal colposcopy result and are currently disease free after a single CO₂ laser application, with a cure rate of 86% (95% CI = 64%–97%).

Three patients (14.28%), all of whom with an initial diagnosis of VaIN III, presented persistence or recurrence after 5, 6, and 14 months, respectively. All received a second CO₂ laser application. Two of them are currently disease free. The remaining patient progressed to invasive carcinoma 18 months after initial treatment and 12 months after the second treatment, diagnosed by excisional biopsy for a small lesion in the vaginal vault, International Federation of Gynecology and Obstetrics stage 1. The histopathological result showed a 0.3 × 0.5-cm invasive focus. The patient underwent partial

colpectomy and pelvic lymphadenectomy. No residual cancer was found in the surgical specimen, and lymph nodes were found to be negative. She remains disease free 12 months after surgery.

DISCUSSION

Our results confirm that high-grade VaIN is a lesion with significant potential for progression to invasive cancer. Laser ablation provides almost 90% remission, but persistence may require retreatment, and 5% of patients may progress to cancer despite careful surveillance. Owing to the scarcity of the literature published regarding VaIN so far, there is no general consensus on its optimal treatment, but our results show that CO₂ laser ablation including a 5- to 7-mm margin of colposcopically normal vagina is safe and generally effective. In published case series like ours, treatment selection depends on the operator's preference and on the experience of the referral center. However, the location and the extent of the lesion and the patient's choice should be taken into account [2].

Intervention in high-grade VaIN is indicated to reduce risk for progression to cancer and may be preferred to speed healing in high-grade lesions. Often multiple treatments are required for some women with high-grade lesions [5].

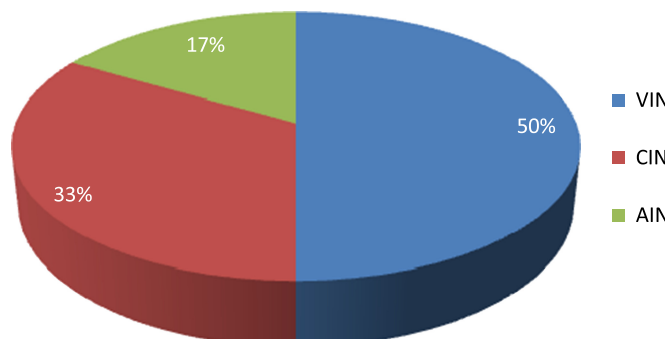


Figure 3. Multicentric lesions of the lower genital tract at diagnosis.

Interestingly, multiple modalities have been used for the treatment of this disease. Intravaginal 5-fluorouracil was once popular, but the risk of chronic vaginal ulcers suggests that it should not be used to treat VaIN [20]. High rates of viral persistence and the poor response achieved suggest limited value of intravaginal imiquimod [18]. Radiotherapy is efficacious but can lead to premature ovarian insufficiency in younger patients, and it may result in vaginal strictures or stenosis that impairs sexual function [19, 21]. Excision is an option but risks injury to the bladder, rectum, and vasculature and is optimal only for unifocal lesions [22]. Therefore, CO₂ laser in the management of VaIN has been shown to have more benefits when compared with other modalities owing to its versatility, to its precision to treat specifically the affected area, to the possibility that it provides to regulate the depth of tissue destruction, and to the early wound healing observed with its use, having no anatomic or functional sequelae. However, the cost of the equipment and the experience needed from the operator to avoid possible complications are considered to be limiting factors [23].

Some limitations of our study include limited follow-up, loss of 25% of cases to follow-up, and a relatively small number of patients owing to the rarity of the disease. However, we want to point out that this series only includes patients with high-grade lesions, which were diagnosed and treated in a single institution.

Our experience in the management of VaIN was carried out in a high-complexity center where we have all the adequate therapeutic resources to obtain results equivalent to the best reported in the literature. Nevertheless, universal access to these resources has not been achieved in our country so far. This is the reason why we believe that the management of this rare disease should be performed in large referral centers, a challenge we bear in mind at present.

We conclude that CO₂ laser vaporization is effective in the initial treatment of patients with high-grade VaIN, requiring this population a long-term follow-up, owing to the recurrent character of this disease, especially in patients with epidemiologic risks. However, additional studies with a wider number of cases are required to elucidate the most appropriate management for this rare premalignant lesion.

REFERENCES

1. Calgar H, Hertzoy RW, Hreshchyshyn MN. Topical 5-fluorouracil treatment of vaginal intraepithelial neoplasia. *Obstet Gynecol* 1981;58:580–3.
2. Graham K, Wright K, Cadwallader B, Reed N, Symonds RP. 20-year retrospective review of medium dose rate intracavitary brachytherapy in VAIN3. *Gynecol Oncol* 2007;106:105–11.
3. Boonlikit S, Noinual N. Vaginal intraepithelial neoplasia: a retrospective analysis of clinical features and colposcopy. *J Obstet Gynaecol* 2010;36:94–100.
4. Frega A, French D, Piazze J, Cerekja A, Vetrano G, Moscarini M. Prediction of persistent vaginal intraepithelial neoplasia in previously hysterectomized women by high-risk HPV DNA detection. *Cancer Lett* 2007;249:235–41.
5. Massad LS. Outcomes after diagnosis of vaginal intraepithelial neoplasia. *J Lower Gen Tract Dis* 2008;12:16–9.
6. Castle PE, Schiffman M, Glass AG, Rush BB, Scott DR, Wacholder S, et al. Human papillomavirus prevalence in women who have and have not undergone hysterectomies. *J Infect Dis* 2006;194:1702–5.
7. Sugase M, Matsukura T. Distinct manifestations of human papillomaviruses in the vagina. *Int J Cancer* 1997;72:412–5.
8. Duong TH, Flowers LC. Vulvo-vaginal cancers: risks, evaluation, prevention and early detection. *Obstet Gynecol Clin North Am* 2007;34:783–802.
9. Wright TC, Cox JT, Massad LS, Carlson J, Twigg LB, Wilkinson EJ. 2001 Consensus guidelines for the management of cervical intraepithelial neoplasia. *Am J Obstet Gynecol* 2003;189:295–304.
10. Aho M, Versterinen E, Meyer B, Purola E, Paavonen J. Natural history of vaginal intraepithelial neoplasia. *Cancer* 1991;68:195–7.
11. Sillman FH, Fruchter RG, Chen YS, Camilien L, Sedlis A, McTigue E. Vaginal intraepithelial neoplasia: risk factors for persistence, recurrence, and invasion and its management. *Am J Obstet Gynecol* 1997;176:93–9.
12. Rome RM, England PG. Management of vaginal intraepithelial neoplasia: a series of 132 cases with long-term follow-up. *Int J Gynecol Cancer* 2000;10:382–90.
13. Cheng D, Ng TY, Ngan HYS, Wong LC. Wide local excision (WLE) for vaginal intraepithelial neoplasia (VAIN). *Acta Obstet Gynecol Scand* 1999;78:648–52.
14. Indermaur MD, Martino MA, Fiorica JV, Roberts WS, Hoffman MS. Upper vaginectomy for the treatment of vaginal intraepithelial neoplasia. *Am J Obstet Gynecol* 2005;193:577–80.
15. Fanning J, Manahan KJ, McLean SA. Loop electro-surgical excision procedure for partial upper vaginectomy. *Am J Obstet Gynecol* 1999;181:1382–5.
16. Curtin JP, Twigg LB, Julian TM. Treatment of vaginal intraepithelial neoplasia with the CO₂ laser. *J Reprod Med* 1985;30:942–4.
17. Krebs HB. Treatment of vaginal intraepithelial neoplasia with laser and topical 5-fluorouracil. *Obstet Gynecol* 1989;73:657–60.

18. Haidopoulos D, Diakomanolis E, Rodolakis A, Voulgaris Z, Vlachos G, Intsaklis A. Can local application of imiquimod cream be an alternative mode of therapy for patients with high-grade intraepithelial lesions of the vagina? *Int J Gynecol Cancer* 2005;15:898–902.
19. Woodman CB, Mould JJ, Jordan JA. Radiotherapy in the management of vaginal intraepithelial neoplasia after hysterectomy. *Br J Obstet Gynaecol* 1988;95:976–9.
20. Krebs HB, Helmkamp BF. Chronic ulcerations following topical therapy with 5-fluorouracil for vaginal human papillomavirus-associated lesions. *Obstet Gynecol* 1991;78:205–8.
21. Teruya Y, Sakumoto K, Moromizato H, Toita T, Ogawa K, Murayama S, et al. High dose-rate intracavitary brachytherapy for carcinoma in situ of the vagina occurring after hysterectomy: a rational prescription of radiation dose. *Am J Obstet Gynecol* 2002;187:360–4.
22. Terzakis E, Androutsopoulos G, Zygouris D, Grigoriadis C, Derdelis G, Arniogiannaki N. Loop electrosurgical excision procedure in Greek patients with vaginal intraepithelial neoplasia. *Eur J Gynaecol Oncol* 2010;31:392–4.
23. Hruza GJ. Laser treatment of epidermal and dermal lesions. *Dermatol Clin* 1997;15:487–506