

Vulvar Procedures

Biopsy, Bartholin Abscess Treatment, and Condyloma Treatment

Edward J. Mayeaux Jr, MD^a, Danielle Cooper, MD^{b,*}

KEYWORDS

- Vulvar biopsy • Punch biopsy • Shave biopsy • Shave excision
- Bartholin fistulization • Marsupialization • Skin LEEP • CO₂ laser

KEY POINTS

- Several benign, premalignant, and malignant lesions may arise on the vulva, and multiple types of procedures may be used to diagnose and treat these conditions.
- Punch and shave biopsies may be used to diagnose most vulvar conditions, but lesions suspected of being melanomas may best be diagnosed with narrow-margin excisional biopsies.
- Bartholin gland cysts and abscesses may be treated with several different treatment modalities, the most common of which are fistulization and marsupialization.
- Genital warts may be treated with several medical and surgical modalities to relieve symptoms.

INTRODUCTION

A variety of skin lesions from benign to premalignant and malignant can present on the vulva, and examination and biopsy are often necessary to diagnose these conditions. The vulva is best examined using a good source of white light and a magnification device, which can be a simple hand-held magnifying lens or a sophisticated colposcope.¹ Biopsy is indicated for unidentified lesions, areas suspicious for malignancy, atypical pigmented lesions, suspicious ulcerations, or lesions that do not resolve after standard therapy. The vulvar examination sometimes can be aided by application of 3% to 5% acetic acid. Acetic acid has the same effect on the vulva as it does on the nonkeratinized cells of the cervix and vagina. However, because of the keratinized

Disclosure: The authors have no relationships with a commercial company that has a direct financial interest in the subject matter or materials discussed.

^a Department of Family and Preventive Medicine, University of South Carolina School of Medicine, 3209 Colonial Drive, Columbia, SC 29203, USA; ^b Department of Obstetrics and Gynecology, Louisiana State University Health Sciences Center, 1501 Kings Highway, Shreveport, LA 71130, USA

* Corresponding author.

E-mail address: dbaker1@lsuhsc.edu

Obstet Gynecol Clin N Am 40 (2013) 759–772

<http://dx.doi.org/10.1016/j.ogc.2013.08.009>

obgyn.theclinics.com

0889-8545/13/\$ – see front matter © 2013 Elsevier Inc. All rights reserved.

nature of the more external vulvar tissue, it is important to soak gauze with acetic acid and allow it to sit on the area, allowing examination for at least 5 minutes to highlight areas of acetowhitening or hyperkeratosis.¹

ANATOMY

The vulva encompasses an area between the genitocrural folds laterally, the mons pubis anteriorly, and the perianal area posteriorly. This area includes the mons pubis, the labia minora and majora, clitoris, vestibule, Skene glands and ducts, hymen, Bartholin glands and ducts, urethral meatus, and vestibulovaginal bulbs. Some vulvologists also include the anus and distal anal tract in this description because this area is also at risk for human papillomavirus (HPV) infection and transformation. The majority of the vulva is covered by keratinized hair-bearing skin; the exception is the vestibule, which is partially covered by a nonkeratinized surface without skin appendages, and is contiguous with the vagina. The presence of skin appendages may influence the type of treatments used for specified conditions and their relative success rates. The vestibule has numerous gland openings: Skene ducts, Bartholin glands and ducts, and minor vestibular glands. The vulva is subject to numerous epithelial diseases, and this article expands on 3 common issues for providers who encounter patients with vulvar problems.

VULVAR BIOPSY

Vulvar biopsy is performed to diagnose epithelial abnormalities. The biopsy may be performed using a Keyes punch instrument, blade, or scissors. The choice of tool is generally determined by provider preference and equipment availability. Punch biopsy is especially useful for flat or slightly raised lesions, and scissors or cervical biopsy forceps are good for raised or pedunculated lesions. Scalpels or skin blades may be used to perform shave biopsies and/or excisions for any type of lesion.

Epithelial punch biopsy obtains a full-thickness skin specimen for diagnostic assessment. The technique has the advantages of being rapid and simple, and generally results in an acceptable final cosmetic appearance. Vulvar biopsy is typically performed using a 3- to 6-mm punch (Keyes punch). With small lesions, a punch that is slightly larger than the lesion can remove the entire visible lesion with the biopsy.² The diagnostic yield may be increased if the most suspicious or abnormal-appearing area (darkest, most raised, or most irregular contour) is biopsied. The exception to this is sclerotic or ulcerative lesions whereby the edge of the lesion, including a small amount of normal skin, should be sampled.^{1,2}

Indications for vulvar biopsy

- Evaluation of lesions of uncertain origin
- Confirmation/exclusion of the presence of dysplasia or malignancy, including melanoma
- Evaluation of skin tumors such as basal cell carcinoma or Kaposi sarcoma
- Diagnosis of bullous skin disorders such as pemphigus vulgaris
- Diagnosis of inflammatory skin disorders such as discoid lupus
- Removal of small skin lesions such as intradermal nevi
- Diagnosis of atypical-appearing lesions
- Evaluation of lesions that do not response to therapy as expected

To perform a punch biopsy, prepare the area with povidone-iodine or chlorhexidine. Lidocaine solution (1%–2%) with epinephrine can be used to anesthetize the area of biopsy, although epinephrine should not be used in the clitoral region. A tuberculin syringe with a 30-gauge needle is appropriate for this area; however, particularly sensitive areas may require the additional use of a topical anesthetic. If the topical anesthetic creams are applied on a mucous membrane, anesthesia occurs much more quickly than the typical 30 to 60 minutes' recommended time for application on keratinized skin; however, this is an off-label use of the products. Inject local anesthetic into the dermis to raise a bleb in the skin (**Fig. 1**) under the lesion and beyond its edges.³

A circular defect is not easily closed, but an oval or ellipse may be created by stretching the skin perpendicular to the lines of least skin tension with the nondominant hand during the procedure (**Fig. 2**). Rotate the punch biopsy instrument with mild downward force around its center axis in a clockwise and counterclockwise back-and-forth motion until it traverses the full thickness of the skin. After the punch biopsy is performed, relax the nondominant hand; the circular defect becomes more oval, allowing for easier closure.² Stop the downward pressure as soon as the instrument completely penetrates the subcutaneous fat (**Fig. 3**). Do not insert the instrument to the hub in thin-skinned areas because this can damage underlying structures. However, if the blade does not transect the dermis completely around the circle, the specimen may be transected through the dermis, potentially producing a specimen with inadequate depth of biopsy. In this instance, place the blade in exactly the same cut and extend it deeper. Gently lift the specimen with a needle or pick-ups and then cut it free at the base (beneath the dermis) using scissors if necessary.

After the biopsy, apply moderate pressure and, possibly, a hemostatic agent to stem bleeding, such as aluminum chloride, silver nitrate, or Monsel solution. Keep in mind that the latter 2 agents may cause tissue tattooing.³ Monsel solution may produce tissue artifacts that can be troublesome to the pathologist if rebiopsy or further excision of a lesion becomes necessary.⁴ Electrocautery can also be used to stop bleeding. Consider closing the biopsy site with a cyanoacrylate tissue adhesive, Steri-Strips, or an interrupted suture (**Fig. 4**), especially with larger biopsies (>4 mm), to decrease postprocedure pain and improve cosmesis. Suturing with absorbable sutures may eliminate the need for removal, but stiff sutures often irritate the vulva, making silk sutures preferable, especially on mucous membranes.

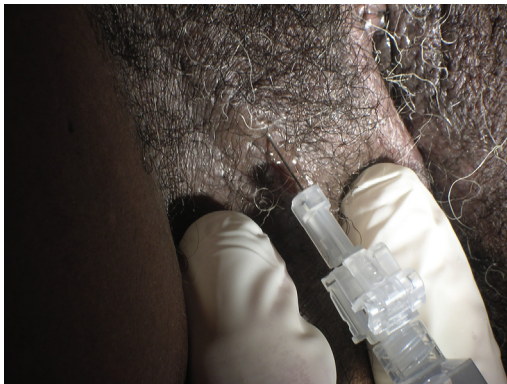

Fig. 1. To anesthetize the skin for a punch biopsy, inject lidocaine solution (1%–2%) with epinephrine into the dermis to raise a bleb in the skin under the lesion and beyond its edges.

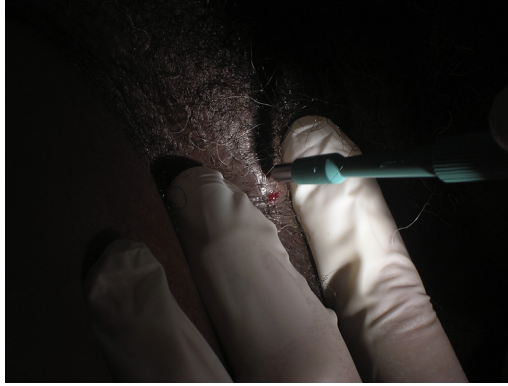

Fig. 2. Create an oval or elliptical defect by stretching the skin perpendicular to the lines of least skin tension with the nondominant hand during the procedure.

Pigmented lesions present a special problem because they may represent vulvar intraepithelial neoplasia (VIN), squamous cell carcinoma (SCC), or melanoma. One potential issue with punch or incisional biopsy that is raised historically is whether establishing a defect in the middle of a tumor allows for seeding or spread of the tumor. This theory has largely been disproven and is not considered clinically relevant.⁵⁻⁷ Clinical examination is widely used for evaluation of melanoma risk in pigmented lesions. The ABCDE rule (Asymmetry, Border, Color, Diameter, and Evolution) is commonly used to assess risk.⁸ Evolution is especially important in patients who are elderly, as a changing lesion in an elderly patient is more likely to be melanoma.⁹ Biopsy also is recommended for a lesion that is distinct from other lesions on the patient's body ("ugly duckling" sign).¹⁰ The American Academy of Dermatology (AAD) has recently issued a position statement on the management of melanomas. The AAD recommends a narrow excisional biopsy with 1- to 3-mm margins to clear the subclinical component in pigmented lesions considered at risk for melanoma. This biopsy can be accomplished in several ways, including elliptical excision with sutures or a deep shave removal to a depth below the anticipated plane of the lesion. If the suspicion for melanoma is high, most melanoma experts recommend performing deep shave (saucerization biopsy) or excisional biopsy so as to have the entire lesion available for evaluation.¹¹

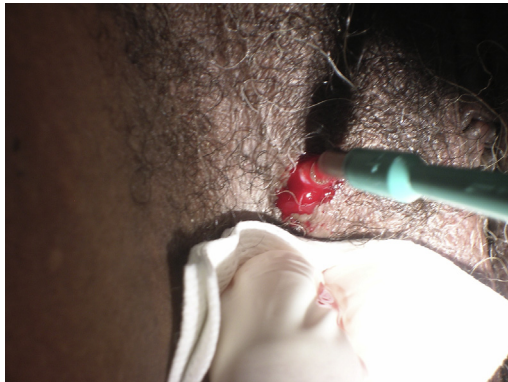

Fig. 3. Stop the downward pressure and remove the instrument as soon as the instrument completely penetrates the subcutaneous fat.

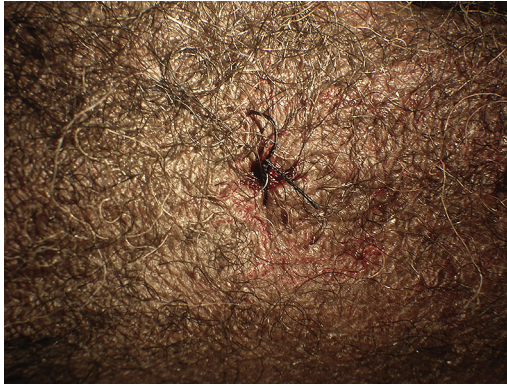

Fig. 4. Consider closing the biopsy site with an interrupted suture, especially with larger biopsies (>4 mm), to decrease the postprocedure pain and improve cosmesis. Stiff sutures often irritate the vulva, making silk sutures preferable, especially on mucous membranes.

To perform a shave biopsy, inject local anesthetic into the dermis under the lesion and beyond its edges. The wheal created expands the dermis, making the lesion easier to shave to an appropriate depth without penetrating to the fat layer, which makes scarring more likely. Squeeze skin between the thumb and forefinger of the nondominant hand to further elevate the lesion. For macular or raised nonsuspicious lesions, a simple shave biopsy is appropriate. Hold a blade parallel to the skin and shallowly remove a thin disk below the level of pigmentation. In a saucerization biopsy, a thick disk of tissue is removed with a scalpel, Dermablade, or curved razor blade, yielding a specimen that extends to at least the mid-dermis (1–4 mm deep).^{3,12} Hold the blade at a 45° angle to the skin, bend or bow the blade (depending on the width of lesion) to achieve adequate depth of cut, and remove a disk of tissue deep into the dermis with 1 to 2 mm of surrounding normal skin laterally.¹² The base of the shave should be in the dermis with multiple bleeding points before hemostasis, have no subcutaneous fat apparent, and not have any apparent lesion remaining (Fig. 5). If an area of pigment remains after saucerization, perform a punch or excisional biopsy and submit both specimens in the same pathology container. Use a hemostatic agent or electrocautery for hemostasis. Dress the site with an ointment. Instruct the patient to keep the area moist with ointment or petrolatum and to keep covered for at least 1 week.³

BARTHOLIN CYST/ABSCESS

The Bartholin glands (greater vestibular glands) are a pair of pea-sized mucus-secreting vestibular glands located at the 5 o'clock and 7 o'clock positions at the vaginal introitus. These glands are normally not palpable or visible. Cysts of these glands develop because of blockage of the duct, often caused by infection or trauma. Symptomatic Bartholin abscesses and cysts account for about 2% of all gynecologic visits per year.¹³ The affected patient typically reports vulvar pain, dyspareunia, and/or pain with walking or sitting. If the cyst develops into an abscess, the symptoms tend to be severe or even incapacitating. In addition to local symptoms, the patient may report subjective fevers, nausea, and influenza-like symptoms.

There are many treatment options for symptomatic Bartholin cysts or abscesses, including simple drainage, fistulization, marsupialization, and excision of the gland.¹⁴ Destruction of the cyst or abscess base after drainage with silver nitrate or alcohol

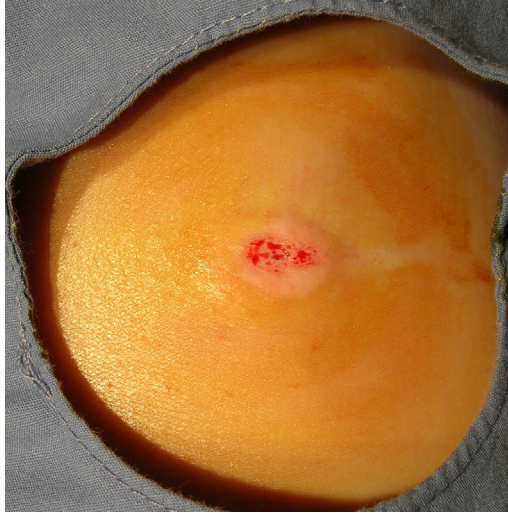

Fig. 5. After a shave, the base should be in the dermis with multiple bleeding points before hemostasis, have no subcutaneous fat apparent, and not have any apparent lesion remaining.

has been reported. The carbon dioxide (CO₂) laser may be used to ablate fenestration or excise the gland. If a patient's Bartholin gland cyst ruptures spontaneously, only hot sitz baths during resolution are needed.¹⁵ Antibiotics are only necessary when secondary infection develops or sexually transmitted infections are identified.¹⁵ Regardless of the method used, the provider and any assistants should take personal-protection precautions and wear gloves and eye equipment during these procedures.

Simple incision and drainage of the abscess under local anesthesia will provide prompt symptom relief, but recurrence after this procedure is common.¹⁵ Following a 1- to 2-cm incision in the cyst, the wall may be ablated with a stick of crystalloid silver nitrate inserted into the cavity. The coagulum may be removed or allowed to spontaneously drain.^{16,17} The most common adverse effects are vulvar burning on postoperative day 1 and labial edema. Healing usually occurs within 10 days.¹⁴ Hemorrhage is reported in 4% to 5% of these patients.^{18,19} Simple needle aspiration, sometimes with ethyl chloride spray for anesthesia, has also been studied.^{20–23} However, compared with alcohol sclerotherapy, needle aspiration has been associated with more than twice the frequency of recurrence, with no statistical analysis reported.²⁰ Needle aspiration and irrigation with 70% alcohol for 5 minutes followed by reevacuation has been studied.²⁰ Transient hyperemia and hematoma has been reported in many patients.²⁰ Seventeen percent of patients in one study experienced tissue necrosis and scarring, so the method is not widely used.²⁴

Bartholin cyst or abscess fistulization involves creating a new, epithelialized outflow tract for an obstructed Bartholin lesion by placing a Word catheter (Rusch Corp, Duluth, GA), a 14F Foley catheter, or a Jacobi ring.^{25–27} Prep the area with povidone-iodine or chlorhexidine. Local anesthesia is achieved by injecting the area around and under the lesion (Fig. 6) with lidocaine with epinephrine. This field block may take up to 10 minutes to work. Be careful not to inject the anesthetic into the cyst or abscess itself, as this often produces inadequate anesthesia and may result in explosive decompression of the lesion when incised. Next, insert a Word catheter through a 3- to 5-mm stab incision on the inner labium minus (just external to the



Fig. 6. Local anesthesia for a Bartholin cyst or abscess fistulization is achieved by injecting the area around and under the lesion with lidocaine with epinephrine. This field block may take up to 10 minutes to work.

hymenal ring) into the Bartholin gland lesion (**Fig. 7**). Hemostats or a probe should be used to break up any loculations present. The bulb of the catheter is inflated (**Fig. 8**) with 3 mL of sterile saline or gel (not air), and the catheter is tucked into the vagina and left in place for up to 4 weeks.²⁸

The Jacobi ring is made from an 8F flexible catheter threaded over a 2-0 silk suture, fashioned into a ring that enters and leaves the cyst or abscess through 2 separate incisions.²⁷ Recurrent Bartholin-gland pathology is noted in 4% to 17% of patients after fistulization.¹⁴ In a randomized trial comparing the Word catheter with the Jacobi ring for symptomatic Bartholin duct abscesses, healing was accomplished by 3 weeks and patients were highly satisfied in both groups.²⁹

Marsupialization (window operation) of the cyst or abscess is another treatment option and is often preferred if the patient has previously failed Word catheter placement. This procedure involves excising an elliptical portion of vestibular skin and cyst wall, breaking up any loculations within the cyst and suturing the cyst-wall edges with interrupted absorbable 3-0 suture to the surrounding vestibular and introital tissue.²⁸ For

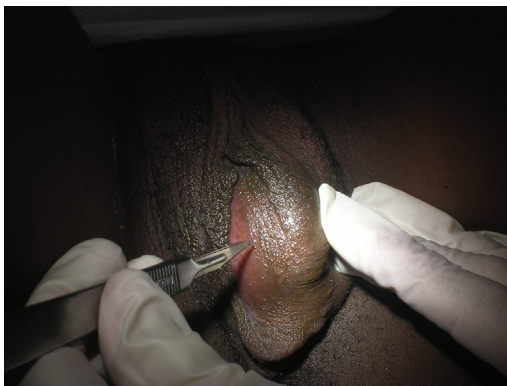


Fig. 7. A Word catheter is inserted through a 3- to 5-mm stab incision on the inner labium minus (just external to the hymenal ring) into the Bartholin gland lesion, and inflated with saline or gel.

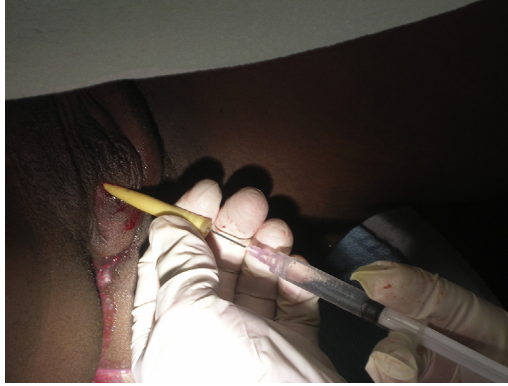

Fig. 8. The bulb of the catheter is inflated through the stem with 3 mL of sterile saline or gel, as air may prematurely deflate the catheter.

best results, it is ideal to perform this procedure on uninfected tissue. Typically this procedure is performed in an outpatient surgical suite, although it is possible in an office setting if the patient can tolerate the local/regional anesthetic for the procedure.¹⁴ Median healing occurred in less than 2 weeks but with bleeding being reported in 11% of patients in one study.³⁰ Recurrence after marsupialization is 10% to 15%. Keep in mind that if the cyst develops in a postmenopausal patient, a biopsy should be taken from the cyst wall to be evaluated by the pathologist for malignancy.³¹

The CO₂ laser may be used under local anesthesia to create an opening in the vulvar skin in the area of the duct orifice, and the lesion contents evacuated.^{32–35} The remaining wall may be left intact, ablated, or excised.³² Healing generally occurs in an average of 2.2 weeks. Unfortunately, reported recurrences are common,^{30,36} and sometimes prolonged healing may interfere with daily activities and intercourse.¹⁴ Major bleeding occurs in 2% to 8% of patients after laser ablation.^{33,34} Bartholin gland excision can be considered in cases of recurrence or suspected malignancy. Bleeding or hematoma was reported in 2% to 8%, fever in 24%, and persistent dyspareunia in 8% to 16% of patients.^{32,37,38}

TREATMENT OF VULVAR CONDYLOMA

Genital warts (condyloma acuminata) affect approximately 1% of the population.³⁹ Low-oncogenic-risk HPV viral types 6 and 11 cause more than 90% of anogenital warts. More than two-thirds of individuals infected with HPV have a transient infection that is subsequently cleared by the host immune response.⁴⁰ The average HPV infection in adolescent females lasts a median of 5.6 months.⁴¹ Diagnosis of genital warts is usually made by visual inspection.⁴² A biopsy should be taken of any lesion that has an atypical appearance, is pigmented, or is resistant to therapy.⁴³ The quadrivalent HPV vaccine can prevent infection with HPV-6 and HPV-11, but does not treat existing lesions.⁴⁴

The primary goal of the treatment of vulvar condyloma is to remove symptomatic warts. Because many warts will regress over time, treatments that do not have a significant risk of scarring should be considered first. All treatment modalities have high recurrence rates and variable success rates. No definitive evidence suggests that any of the available treatments are superior to any other, and no single treatment is ideal for all patients or all warts. Practitioners should be familiar with

at least 1 patient-applied treatment (eg, imiquimod, podofilox, or sinecatechins) and 1 provider-applied therapy (eg, surgical excision, cryotherapy, trichloroacetic acid [TCA]).⁴³ Choosing an appropriate treatment modality for condyloma depends on the size, number, and location of the lesions, as well as provider training. The use of tailored therapies to the specific needs and situation of the patient can produce good outcomes for the majority.

Imiquimod cream (Aldara and Zyclara; Medicis Pharmaceuticals, Scottsdale, AZ) is indicated only for external HPV infections (**Table 1**), and is contraindicated for use on occluded mucous membranes or on the cervix.⁴² The cream should be rubbed into the lesion to promote absorption. Patients are advised to wash the affected area with soap and water 6 to 10 hours after application.⁴⁵ Side effects include erythema, erosion, itching, skin flaking, and edema. In 3 randomized placebo-controlled trials of 5% cream, 37% to 54% of treated patients showed clearance within 16 weeks.⁴⁶

A biologically active extract of podophyllin, podofilox (Condylox; Watson Pharma, San Antonio, TX) 0.5% gel, solution, or cream, is indicated for patient application to genital lesions (see **Table 1**). It is contraindicated for use in the vagina, urethra, perianal area, cervix, and in pregnancy. There have been reported deaths from application of podophyllin to occluded membranes, so this type of use is strictly contraindicated.⁴³ Follow-up is usually within 4 weeks, and thereafter until healing. Placebo-controlled trials have shown 45% to 77% clearance rates within 4 to 6 weeks. Side effects include local inflammation, irritation, erosion, burning, pain, and itching.⁴⁶

Sinecatechins ointment, a green-tea extract, may be used for external warts.^{47–49} The medication should not be washed off after use. The most common side effects of sinecatechins are erythema, pruritus/burning, pain, ulceration, edema, induration, and vesicular rash. It also may weaken condoms and diaphragms. The safety and efficacy of the medication is not established for persons infected by human immunodeficiency virus, immunocompromised persons, persons with clinical genital herpes, or pregnant females.

Provider-administered therapies to treat genital warts involve excisions, ablations, and application of topical agents. Excisional procedures may be done in an outpatient setting for milder disease, or in an operating-room setting for more extensive disease. Provider administration has the advantage of eliminating most or all warts at a single visit. Vulvar condyloma must be resected down to normal skin, after which the base is cauterized. A #15 blade or scissors can be used to resect the condyloma using a shave technique as described earlier, after which a cautery tool or chemical applied to the area is used to control bleeding. Suture is usually unnecessary.

The skin loop electrosurgical excisional procedure (LEEP) is an excellent modality for the treatment of perineal condylomata in both males and females, and the basic equipment needed is already present in many providers' offices. HPV DNA has been found in laser and electrocoagulation smoke, although it is not known if viable HPV is present.⁵⁰ Theoretically HPV could also be present in LEEP smoke, so operators should wear a virus-filtering mask when removing condyloma in this fashion.⁵¹ Loops for the removal of external lesions are typically smaller and shorter than standard cervical loops, and are selected to allow easy removal of the lesion. The loops for the removal of condyloma typically are smaller and shorter than the typical cervical loop, allowing for easier control with resection. Local anesthesia is injected intradermally. The loop is introduced into normal skin near the base of the lesion and is pulled completely under the lesion through the dermis. Any remaining lesion is then carefully

Table 1 Therapies for condyloma acuminata				
Drug	Applied by	Pregnancy	Treatment Areas	Notes
Imiquimod 5% cream	Patient	No	Vulva	Apply to lesions 3 times a week, every other day, for up to 16 wk. Wash with soap and water after 6–10 h
Podofilox 0.5% solution or gel	Patient	No	Vulva	Apply to lesions twice daily for 3 d, then 4 consecutive days of no therapy each week for a maximum of 4 wk
Sinecatechins 15% ointment	Patient	No	Vulva	Apply a 0.5-cm strand to each wart 3 times daily using a finger to ensure coverage with a thin layer of ointment for up to 16 wk
Cryotherapy with liquid nitrogen	Provider	Yes	Vulva, vagina, anal	Refrigerant is applied until an ice-ball forms for 2–3 mm beyond the lesion margin
Cryotherapy with a nitrous oxide or carbon dioxide cryoprobe	—	—	Vulva	Refrigerant is applied until an ice-ball forms 2–3 mm beyond the lesion margin
Podophyllin	Provider	No	Vulva	Apply to each wart and allow to air-dry to prevent spread to adjacent areas
Trichloroacetic acid 50%–90% solution	Provider	Yes	Vulva, vagina, anal	Apply a small amount only to the warts and allow to dry
Surgical removal (sharp, electrocautery, curettage)	—	Yes	Vulva, anal	—
Laser	—	Yes	Vulva, vagina	—

Data from Workowski KA, Berman S, Centers for Disease Control and Prevention (CDC). Sexually transmitted diseases treatment guidelines, 2010. MMWR Recomm Rep 2010;59(RR-12):1–110; and Mayeaux EJ Jr, Dunton C. Modern management of external genital warts. J Low Genit Tract Dis 2008;12:185–92.

shaved down to the dermis using the side of the loop and fine paint-brush style cuts (Fig. 9). Fulguration can be used for hemostasis, but is not usually necessary. Late bleeding has been reported in 4% of patients treated for vaginal lesions, and can usually be controlled with Monsel solution or fulguration. Infection is an uncommon complication. Hypopigmentation and hypertrophic scars are rarely reported.⁴³

Podophyllin resin (10%–25%) may be applied weekly.⁴² Application should be limited to less than 0.5 mL of podophyllin per session, and the treatment area should not contain any open lesions or wounds, to prevent absorption of the toxin. The

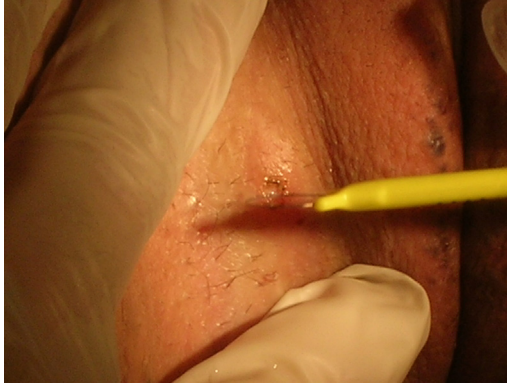

Fig. 9. During an electrosurgical shave, the loop is introduced into normal skin near the base of the lesion and pulled completely under the lesion through the dermis. Any remaining lesion is then carefully shaved down to the dermis using the side of the loop and fine paint-brush style cuts. Note that a cervical loop is used here for visualization, but shorter skin loops are easier to use.

preparation should be thoroughly washed off 1 to 4 hours after application to reduce local irritation. Podophyllin resin preparations differ in the concentration of active components and contaminants.

The CO₂ laser can be used to excise the base of a pedunculated lesion or desiccate a flat lesion just beyond the dermal layer. Appropriate personal-protective equipment including safety goggles are a necessity. Providers must remember to place moist gauze in the rectum to prevent possible ignition of colonic gas. With this procedure, healing occurs by secondary intention; there is rarely bleeding to control because of the superficial nature of the procedure. The importance of pain control and healing techniques are stressed to the patient. Sitz baths 3 times a day and lidocaine ointments for pain control will typically be adequate. HPV DNA has been found in the “plume of smoke” associated with the laser; therefore, a virus-filtering mask must be worn and a smoke evacuator used to minimize possible exposure.⁵¹

Cryotherapy is a commonly used method to remove warts, and is likely the safest modality during pregnancy. Freezing with liquid nitrogen may involve some pain and bleeding. Liquid nitrogen should be applied via a spray device or cotton-tipped applicator, or nitrous oxide or CO₂ via a cryoprobe, until an ice-ball forms 2 to 3 mm beyond the margin of the lesion. Local anesthesia can be used, although many patients will tolerate the cryotherapy without any such treatment. After several days the treated tissue will slough off; inflammation ensues and then subsides as healing occurs.⁴²

TCA is used to treat external condyloma but is not recommended for use in the vagina, cervix, or urinary meatus. TCA can be prepared in different strengths and must be compounded at a pharmacy. A thin cotton-tip applicator is used to apply the acid directly to the lesion until a white frost develops. If pain is intense, the acid can be neutralized with soap or sodium bicarbonate. Excess liquid can ulcerate surrounding tissue, and petroleum jelly can be applied to protect unaffected skin. Multiple weekly applications may be required to adequately treat the condyloma.⁴²

In general, genital warts will resolve with therapy within 1 to 6 months, regardless of the choice of treatment. Patients need to be aware of the nature of the HPV disease and the potential for latency and viral reactivation. Condom use should be encouraged, although at this time prevention is only possible with vaccination.

REFERENCES

1. Haefner H, Mayeaux EJ Jr. Vulvar abnormalities. In: Mayeaux EJ Jr, Cox T, editors. *Modern colposcopy*. 3rd edition. Philadelphia: Lippincott, Williams, Wilkins; 2011. p. 432–70.
2. Mayeaux EJ Jr. Punch biopsy of the skin. In: Mayeaux EJ Jr, editor. *The essential guide to primary care procedures*. Philadelphia: Wolters Kluwer: Lippincott, Williams, Wilkins; 2009. p. 187–94.
3. Pickett H. Shave and punch biopsy for skin lesions. *Am Fam Physician* 2011; 84(9):995–1002.
4. Olmstead PM, Lund HZ, Leonard DD. Monsel's solution: a histologic nuisance. *J Am Acad Dermatol* 1980;3(5):492–8.
5. Pflugfelder A, Weide B, Eigentler TK, et al. Incisional biopsy and melanoma prognosis: facts and controversies. *Clin Dermatol* 2010;28(3):316–8.
6. Sober AJ, Balch CM. Method of biopsy and incidence of positive margins in primary melanoma. *Ann Surg Oncol* 2007;14(2):274–5.
7. Lin SW, Kaye V, Goldfarb N, et al. Melanoma tumor seeding after punch biopsy. *Dermatol Surg* 2012;38(7 Pt 1):1083–5.
8. Thomas L, Tranchand P, Berard F, et al. Semiological value of ABCDE criteria in the diagnosis of cutaneous pigmented tumors. *Dermatology* 1998;197: 11–7.
9. Banky JP, Kelly JW, English DR, et al. Incidence of new and changed nevi and melanomas detected using baseline images and dermoscopy in patients at high risk for melanoma. *Arch Dermatol* 2005;141:998–1006.
10. Grob JJ, Bonerandi JJ. The 'ugly duckling' sign: identification of the common characteristics of nevi in an individual as a basis for melanoma screening. *Arch Dermatol* 1998;134:103–4.
11. Bichakjian CK, Halpern AC, Johnson TM, et al. Guidelines of care for the management of primary cutaneous melanoma. *J Am Acad Dermatol* 2011;65(5): 1032–47.
12. Tran KT, Wright NA, Cockerell CJ. Biopsy of the pigmented lesion—when and how. *J Am Acad Dermatol* 2008;59(5):852–71.
13. Pundir J, Auld BJ. A review of the management of diseases of the Bartholin's gland. *J Obstet Gynaecol* 2008;28(2):161–5.
14. Wechter ME, Wu JM, Marzano D, et al. Management of Bartholin duct cysts and abscesses: a systematic review. *Obstet Gynecol Surv* 2009;64(6): 395–404.
15. Omole F, Simmons BJ, Hacker Y. Management of Bartholin's duct cyst and gland abscess. *Am Fam Physician* 2003;68(1):135–40.
16. Ergeneli MH. Silver nitrate for Bartholin gland cysts. *Eur J Obstet Gynecol Reprod Biol* 1999;82:231–2.
17. Ozdegirmenci O, Kayikcioglu F, Haberal A. Prospective randomized study of marsupialization versus silver nitrate application in the management of Bartholin gland cysts and abscesses. *J Minim Invasive Gynecol* 2009;16(2): 149–52.
18. Ortac UF, Dunder I, Alatas C, et al. Management of Bartholin's cysts and abscesses with silver nitrate (AgNO₃). *Turk J Med Sci* 1991;15:116–24.
19. Turan C, Vicdan K, Gokmen O. The treatment of Bartholin's cyst and abscess with silver nitrate. *Int J Gynaecol Obstet* 1995;48:317–8.
20. Cobellis PL, Stradella L, De Lucia E, et al. Alcohol sclerotherapy: a new method for Bartholin gland cyst treatment. *Minerva Ginecol* 2006;58:245–8.

21. Cheetham DR. Bartholin's cyst: marsupialization or aspiration? *Am J Obstet Gynecol* 1985;152:569–70.
22. Poma PA. Bartholin's duct abscess: office management. *Proc Inst Med Chic* 1982;35:85–6.
23. van Bogaert LJ. Management of Bartholin's abscess. *World Health Forum* 1997; 18:200–1.
24. Kafali H, Yurtseven S, Ozardali I. Aspiration and alcohol sclerotherapy: a novel method for management of Bartholin's cyst or abscess. *Eur J Obstet Gynecol Reprod Biol* 2004;112:98–101.
25. Haider Z, Condous G, Kirk E, et al. The simple outpatient management of Bartholin's abscess using the Word catheter: a preliminary study. *Aust N Z J Obstet Gynaecol* 2007;47:137–40.
26. Yavetz H, Lessing JB, Jaffa AJ, et al. Fistulization: an effective treatment for Bartholin's abscesses and cysts. *Acta Obstet Gynecol Scand* 1987;66:63–4.
27. Gennis P, Li SF, Provataris J, et al. Jacobi ring catheter treatment of Bartholin's abscesses. *Am J Emerg Med* 2005;23:414–5.
28. Mayeaux EJ Jr. Bartholin's gland cysts and abscesses treatment. In: Mayeaux EJ Jr, editor. *The essential guide to primary care procedures*. Philadelphia: Wolters Kluwer: Lippincott, Williams, Wilkins; 2009. p. 497–503.
29. Gennis P, Li SF, Provataris J, et al. Randomized pilot study comparing a rubber ring catheter to the word catheter in the treatment of Bartholin abscesses. *Acad Emerg Med* 2004;11:527.
30. Downs MC, Randall HW Jr. The ambulatory surgical management of Bartholin duct cysts. *J Emerg Med* 1989;7:623–6.
31. Schorge JO, Schaffer JI, Halvorson LM, et al. *Williams gynecology*. 2008:675.
32. Penna C, Fambrini M, Fallani MG. CO₂ laser treatment for Bartholin's gland cyst. *Int J Gynaecol Obstet* 2002;76:79–80.
33. Heinonen PK. Carbon dioxide laser in the treatment of abscess and cyst of Bartholin's gland. *J Obstet Gynaecol* 1990;10:535–7.
34. Fambrini M, Penna C, Pieralli A, et al. Carbon-dioxide laser vaporization of the Bartholin gland cyst: a retrospective analysis on 200 cases. *J Minim Invasive Gynecol* 2008;15:327–31.
35. Benedetti Panici P, Mancini N, Bellati F, et al. CO₂ laser therapy of the Bartholin's gland cyst: surgical data and functional short- and long-term results. *J Minim Invasive Gynecol* 2007;14:348–51.
36. Goldberg JE. Simplified treatment for disease of Bartholin's gland. *Obstet Gynecol* 1970;35:109–10.
37. Mungan T, Ugur M, Yalcin H, et al. Treatment of Bartholin's cyst and abscess: excision versus silver nitrate insertion. *Eur J Obstet Gynecol Reprod Biol* 1995;63:61–3.
38. Rouzier R, Azarian M, Plantier F, et al. Unusual presentation of Bartholin's gland duct cysts: anterior expansions. *BJOG* 2005;112:1150–2.
39. Gunter J. Genital and perianal warts: new treatment opportunities for human papillomavirus infection. *Am J Obstet Gynecol* 2003;189(Suppl 3):S3–11.
40. Ho GY, Bierman R, Beardsley L, et al. Natural history of cervicovaginal papillomavirus infection in young women. *N Engl J Med* 1998;338:423–8.
41. Brown DR, Shew ML, Qadadri B, et al. A longitudinal AQ8 study of genital human papillomavirus infection in a cohort of closely followed adolescent women. *J Infect Dis* 2005;191:182–92.
42. Workowski KA, Berman S, Centers for Disease Control and Prevention (CDC). Sexually transmitted diseases treatment guidelines, 2010. *MMWR Recomm Rep* 2010;59(RR-12):1–110.

43. Mayeaux EJ Jr, Dunton C. Modern management of external genital warts. *J Low Genit Tract Dis* 2008;12:185–92.
44. FUTURE I/II Study Group, Dillner J, Kjaer SK. Four year efficacy of prophylactic human papillomavirus quadrivalent vaccine against low grade cervical, vulvar, and vaginal intraepithelial neoplasia and anogenital warts: randomised controlled trial. *BMJ* 2010;340:c3493.
45. Ferenczy A. Treatment of external genital warts. *J Low Genit Tract Dis* 2000;4:128–34.
46. Wiley DJ, Douglas JM, Beutner K, et al. External genital warts: diagnosis, treatment and prevention. *Clin Infect Dis* 2002;35(Suppl 2):S210–24.
47. Tatti S, Swinehart JM, Thielert C, et al. Sinecatechins, a defined green tea extract, in the treatment of external anogenital warts: a randomized controlled trial. *Obstet Gynecol* 2008;111:1371–9.
48. Stockfleth E, Beti H, Orasan R, et al. Topical Polyphenon E in the treatment of external genital and perianal warts: a randomized controlled trial. *Br J Dermatol* 2008;158:1329–38.
49. Gross G, Meyer KG, Pres H, et al. A randomized, double-blind, four-arm parallel-group, placebo-controlled Phase II/III study to investigate the clinical efficacy of two galenic formulations of Polyphenon E in the treatment of external genital warts. *J Eur Acad Dermatol Venereol* 2007;21:1404–12.
50. Sawchuk WS, Weber PJ, Lowy DR, et al. Infectious papillomavirus in the vapor of warts treated with carbon dioxide laser or electrocoagulation: detection and protection. *J Am Acad Dermatol* 1989;21:41–9.
51. Mayeaux EJ, Harper MB, Barksdale W, et al. Noncervical human papillomavirus genital infections. *Am Fam Physician* 1995;52(4):1137–46.