

# Synchronous Uterine Artery Embolization and Laparoscopic Myomectomy for Massive Uterine Leiomyomas

Thumuluru Kavitha Madhuri, MBBS, DRCOG, Waseem Kamran, MBBS, MRCOG, Woodruff Walker, MRCOG, FRCR, FFR (SA), Simon Butler-Manuel, MD, FRCS, FRCOG

## ABSTRACT

Uterine leiomyomas remain the commonest cause of menorrhagia and frequently cause pressure symptoms. Management of leiomyomas depends on the presenting symptoms, size, location, number of myomas, and the patient's desire to retain her uterus, fertility, or both. We present the first case of laparoscopic myomectomy for a fibroid measuring 30cm in maximum diameter.

**Key Words:** Fibroid size, Laparoscopic myomectomy, Uterine artery embolization.

## INTRODUCTION

Management of leiomyomas is factored by size, position, number of leiomyomas, and patient choice. Laparoscopic myomectomy has been reported to be suitable for leiomyomas of <10 cm in size.

We present a case of multiple very large myomas removed by laparoscopy and morcellation immediately following uterine artery embolization (UAE). To our knowledge, this is the first reported case of laparoscopic myomectomy for a fibroid >20 cm in size.

## CASE REPORT

A 42-year-old, nulliparous woman with an otherwise unremarkable medical history presented with a history of menorrhagia and intermenstrual bleeding. Abdominal and pelvic examination showed a large pelvic mass consistent with a fibroid uterus arising out of the pelvis, equivalent to a 30-week gestation uterus. An ultrasound of the pelvis showed a large multi-fibroid uterus. An MRI scan showed a conglomerate of leiomyomas extending up to the upper endplate of L4 (lumbar spine 4) (**Figure 1**). Two leiomyomas were present, one fundal subserosal with broad attachment to the body and a left posterior wall fibroid extending into the broad ligament. Also a 7.5-cm pedunculated component was found extending from the right body. The overall dimension of the uterus was 30.5x19.5x18.5 cm (**Figure 2**). The patient was very keen to have conservative management of the myomas and avoid a hysterectomy. A combined procedure of UAE immediately followed by laparoscopic myomectomy was proposed.

Following review by a radiologist, embolization of the leiomyomas was carried out through a right groin approach. The pelvic arteriogram showed a hypervascular leiomyomatous mass fed from both the right and left uterine arteries. Both the uterine arteries were catheterized and successfully embolized with 355 to 500 micron PVA particles and coils.

Later on the same day, the patient underwent a laparoscopic myomectomy. Abdominal access was gained through a Palmer's point entry. Following pneumoperito-

Department of Gynaecological Oncology, The Royal Surrey County Hospital, Guildford, Surrey, United Kingdom (all authors).

Clinical Fellow in Gynaecological Oncology, Guildford, United Kingdom (Dr Madhuri).

Specialist Registrar in Obstetrics & Gynaecology, Guildford, United Kingdom (Dr Kamran).

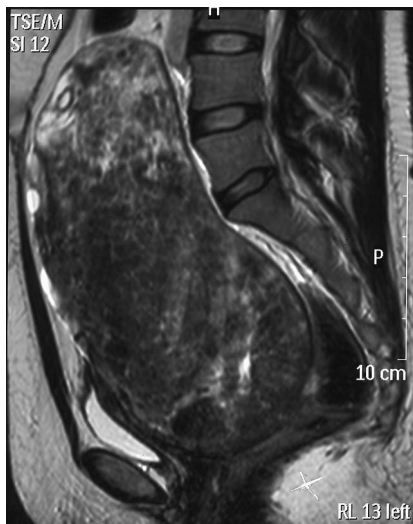
Consultant Radiologist, Guildford, United Kingdom (Dr Walker).

Consultant Gynaecological Oncologist, Guildford, United Kingdom (Dr Butler-Manuel).

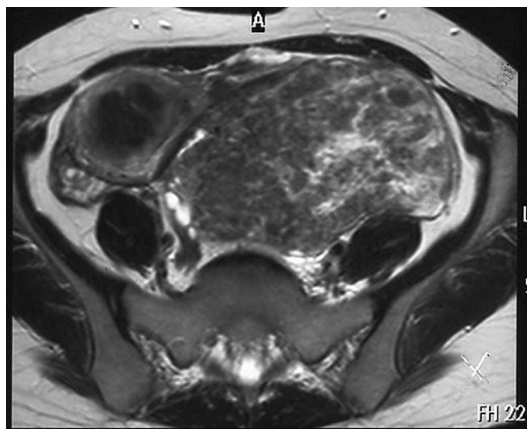
Address correspondence to: Thumuluru Kavitha Madhuri, MBBS, DRCOG, Dept. of Gynaecology, LEVEL B GOPD, Royal Surrey County Hospital, Guildford GU2 7XX, UK. E-mail: docmadhuri231@doctors.org.uk

DOI: 10.4293/108680810X12674612015021

© 2010 by JSL, *Journal of the Society of Laparoendoscopic Surgeons*. Published by the Society of Laparoendoscopic Surgeons, Inc.



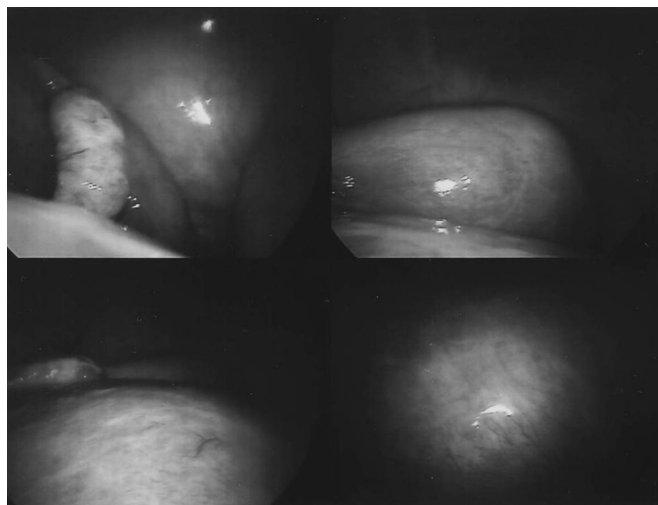
**Figure 1.** Sagittal T2 weighted MR image showing a large fibroid mass extending to upper endplate of lumbar spine (L4).



**Figure 2.** Axial T2 weighted MR image showing 2 separate fibroids.

neum, one 12-mm umbilical, one 5-mm suprapubic, and two 5-mm lateral ports were inserted under direct vision. A massive left broad ligament fibroid extending along the left pelvic side wall was noted, displacing the pelvic colon and rectum grossly to the right (**Figure 3**). A further large retroperitoneal fibroid arising from the posterior surface of the uterus down to the level of the pelvic floor was also noted.

The procedure involved identification, by using the *Harmonic ACE* (Ethicon Endo-Surgery), of both ureters followed by opening of the left retroperitoneal space and medial mobilization of the mass away from the left ureter. The second myoma was mobilized from the pelvic floor upwards and away from the rectovaginal septum. Once



**Figure 3.** Laparoscopic images showing a large fibroid displacing the pelvic colon and rectum.

the leiomyomas were mobilized and dissected free of the uterus, the tissue was extracted piecemeal by using the Gynecare X-tract (Ethicon, Inc.) tissue morcellator with some difficulty, because the leiomyomas had necrosed. The estimated blood loss was 150 mL. The procedure lasted 160 min. The myometrium was repaired in layers by using 2-0 Vicryl interrupted figure of eight sutures with intracorporeal knots. The total weight of morcellated myoma was 1.54 kg, and histology confirmed benign leiomyomas.

The patient made an uneventful recovery and was discharged home the following day. Ultrasound of the pelvis 7 weeks after the procedure showed that the uterus measured 6x4.5x5 cm.

## DISCUSSION

Uterine leiomyomas remain the commonest cause of menorrhagia and frequently cause pressure symptoms on the bladder and other abdominal viscera as in this case. Management of leiomyomas depends on the presenting symptoms, size, location, number of myomas, and the patients desire to retain her uterus, fertility, or both of these. The standard treatment offered for large myomas in postmenopausal women has been open surgery in the form of an abdominal hysterectomy rather than an open myomectomy, which was reserved for women wishing to retain fertility.<sup>1</sup> Depending on the size, position of the myoma, and incision on the uterine body, there is an increased risk of uterine rupture during labor, and elective cesarean delivery is offered to minimize these risks. Recent devel-

opments in treatment include hysteroscopic resection of submucosal leiomyomas, laparoscopic myomectomy, and UAE, especially in women wishing to retain fertility.<sup>2</sup>

Walker et al<sup>3</sup> retrospectively studied the incidence of and reported on the largest series of pregnancy outcome (53%) after UAE for symptomatic leiomyomas but did report a significant increase in preterm delivery, Caesarean delivery, and postpartum hemorrhage recommending prior prepregnancy counseling.

Though not commonly quoted, the recurrence rate following open myomectomy has been reported as being above 62% and as high as 75% in some studies.<sup>4</sup> Laparoscopic surgery has the advantages of a shorter postoperative hospital stay, less postoperative pain, and reduced risk of adhesions. Myomectomy is the preferred choice for patients wishing to conserve their uterus.<sup>5</sup>

Laparoscopic myomectomies are limited by the size of the leiomyomas. Very large myomas limit the amount of space available to manipulate the laparoscopic instruments and are associated with increased blood loss, which has been cited as a common reason for conversion from a laparoscopic approach to laparotomy. The upper limit of size of myomas for laparoscopic myomectomy has been suggested at 10 cm to avoid the complications of excessive blood loss and difficult access.<sup>6</sup>

Shrinkage of leiomyomas following UAE may continue for even up to 9 months, and myomectomy could be performed at any time during this period. Combining the 2 procedures during one hospital admission avoids ischemic pain from necrosis of the leiomyomas following embolization, reduces uterine vascularity before collateral vessel formation, and speeds patient recovery considerably with return to normal activity within 2 weeks.

Various methods have been advocated to minimize blood loss during laparoscopic myomectomy and these include preoperative treatment with Gonadotrophin (GnRH) analogues, injection of vasopressin or other vasoconstrictive agents under the capsule of the fibroid before enucleation, ligation of uterine arteries before myomectomy, and more recently preoperative embolization of leiomyomas, as described in this case.<sup>7</sup> The blood loss in our patient was only 150 mL and allowed for laparoscopic extraction without any complications.

Laparoscopic morcellation requires training and care by the surgical team to avoid potentially dangerous vascular and visceral injuries. A recent improvement in morcellators, such as Gynecare Morcellex (Ethicon, Inc.) that includes the core guard lip, makes tissue removal faster and inherently safer.

A combination of preoperative UAE and laparoscopic morcellation may be the appropriate treatment for even the largest of leiomyomas; size need not necessarily be a limiting factor for laparoscopic myomectomies.<sup>8,9</sup>

### References:

1. Agdi M, Tulandi T. Endoscopic management of uterine fibroids. *Best Pract Res Clin Obstet Gynaecol*. 2008;22(4):707–716. Epub 2008 Mar 6.
2. Lefebvre G, Vilos G, Allaire C, et al. The management of uterine leiomyomas. *J Obstet Gynaecol Can*. 2003;25(5):396–418.
3. Walker WJ, McDowell SJ. Pregnancy after uterine artery embolization for leiomyomata: a series of 56 completed pregnancies. *Am J Obstet Gynecol*. 2006;195(5):1266–1271.
4. Hanafi M. Predictors of leiomyoma recurrence after myomectomy. *Obstet Gynecol*. 2005;105(4):877–881.
5. Mukherjee SN. Role of hysterectomy and its alternatives in benign uterine diseases. *J Indian Med Assoc*. 2008;106(4):232–234.
6. Kuwatsuru R. The indications, surgical techniques, and limitations of laparoscopic myomectomy. *JLS*. 2003;7(2):89–95.
7. Kuzel D, Mára M, Masková J, et al. [Combined treatment of uterine myoma (uterine arteries embolization followed by laparoscopic myomectomy)]. *Ceska Gynecol*. 2004;69(6):497–500. Czech.
8. Walker WJ, Barton-Smith P. Long-term follow up of uterine artery embolisation—an effective alternative in the treatment of fibroids. *BJOG*. 2006;113(4):464–468.
9. Sinha R, Hegde A, Mahajan C, Dubey N, Sundaram M. Laparoscopic myomectomy: do size, number, and location of the myomas form limiting factors for laparoscopic myomectomy? *J Minim Invasive Gynecol*. 2008;15(3):292–300.