



EMAS position statement: Management of uterine fibroids



Faustino R. Pérez-López^{a,*}, Lía Ornat^a, Iuliana Ceausu^{b,c}, Herman Depypere^d,
C. Tamer Erel^e, Irene Lambrinoudaki^f, Karin Schenck-Gustafsson^g, Tommaso Simoncini^h,
Florence Tremollieresⁱ, Margaret Rees^j

^a Department of Obstetrics and Gynecology, Zaragoza University, Faculty of Medicine, Lozano Blesa University Hospital, Domingo Miral s/n, Zaragoza 50009, Spain

^b Department of Obstetrics and Gynecology, 'Carol Davila' University of Medicine and Pharmacy, Bucharest, Romania

^c Department of Obstetrics and Gynecology, 'Dr. I. Cantacuzino' Hospital, Bucharest, Romania

^d Breast Clinic and Menopause Clinic, University Hospital, De Pintelaan 185, 9000 Gent, Belgium

^e Department of Obstetrics and Gynecology, Istanbul University, Cerrahpasa School of Medicine, Valikonagi Cad. No: 93/4, Nisantasi 34365, Istanbul, Turkey

^f Second Department of Obstetrics and Gynecology, National and Capodestrian University of Athens, Greece

^g Department of Medicine, Cardiology Unit and Head Centre for Gender Medicine, Karolinska Institutet and Karolinska University Hospital, Thorax N3:06, SE 17176 Stockholm, Sweden

^h Department of Clinical and Experimental Medicine, University of Pisa, Via Roma, 67, 56100 Pisa, Italy

ⁱ Menopause and Metabolic Bone Disease Unit, Hôpital Paule de Viguier, F-31059 Toulouse Cedex 09, France

^j Women's Centre, John Radcliffe Hospital, Oxford OX3 9DU, UK

ARTICLE INFO

Keywords:

Fibroids
Gn-RH analogs
Ulipristal
Hysterectomy
Myomectomy
Uterine artery embolization
High-intensity focused ultrasound

ABSTRACT

Introduction: Uterine fibroids (also termed leiomyomas or myomas) are the most common tumors of the female reproductive tract.

Aim: The aim of this position statement is to provide and critically appraise evidence on the management of women with uterine fibroids.

Methods: Literature review and consensus of expert opinion.

Results and conclusions: Many uterine fibroids are asymptomatic and require no intervention, although it is advisable to follow up patients to document stability in size and growth. Fibroid-associated symptoms include heavy menstrual bleeding and pain or pelvic discomfort. The association between infertility and fibroids increases with age. Fibroids do not increase the risk of malignant uterine disease and leiomyosarcomas are extremely rare (less than one in 1000). It is unknown at present whether leiomyosarcoma represents de novo growth or malignant transformation from benign uterine fibroids. Treatment options for symptomatic fibroids include pharmacologic, surgical and radiologically guided interventions. The range of medical treatments allows flexible management of fibroid-related symptoms; the options include tranexamic acid, non-steroidal anti-inflammatory drugs, contraceptive steroids, gonadotropin-releasing hormone analogs, antiprogesterone, and selective progesterone receptor modulators. However, these medical options do not remove the tumors and symptoms may return when treatment is stopped. Surgical and radiologically guided procedures may be tailored to age, general health, and individual patient wishes. Hysterectomy is the most effective treatment, although in some cases myomectomy may be sufficient to control symptoms. Alternatives to surgery include uterine artery embolization, myolysis and ablation by high-intensity focused ultrasound (guided with magnetic resonance imaging or ultrasound). The choice of treatment depends on fibroid size, the underlying symptoms and their severity and the woman's desire for subsequent fertility and pregnancy, as well as efficacy and need for repeated interventions.

© 2014 Elsevier Ireland Ltd. All rights reserved.

* Corresponding author at: Facultad de Medicina, Universidad de Zaragoza, Hospital Clínico Lozano Blesa, Domingo Miral s/n, Zaragoza 50009, Spain. Tel.: +34 976 761734; fax: +34 976 761735.

E-mail addresses: faustino.perez@unizar.es, faustino.perez@hotmail.es (F.R. Pérez-López).

1. Introduction

Uterine fibroids (also termed leiomyomas or myomas) are the most common tumors of the female reproductive tract. While they may be asymptomatic they can cause abnormal bleeding, pelvic pressure symptoms and infertility. Fibroid growth and regression vary throughout life. Thus, they tend to grow during the patient's reproductive years and regress after the menopause. They affect millions of women and are the leading cause of hysterectomy.

Fibroids are benign tumors characterized by the proliferation of uterine muscle cells and the production of a collagenous matrix. They consist of smooth-muscle cells which carry the MED12 (or HMG2) mutation, suggesting that their origin is a myometrial stem cell [1–3]. The mitotic activity of fibroids is generally low, although the proliferative rate of the fibroid tissue is greater than that of the adjacent myometrium. The collagenous matrix is variable in quantity. It has been proposed that there is an inverse relationship between the percentage of tumor matrix and microvascular density which leads to interstitial ischemia and myocyte atrophy [4]. Angiogenic growth factors and glycosylated calcitonin may also be involved in fibroid development and growth, and contribute to their abnormal vasculature [5,6].

Both experimental studies and clinical observations suggest that uterine fibroids are estrogen dependent tumors. Furthermore, experimental and clinical evidence suggests that progesterone has an equally important role as estradiol in regulating fibroid growth [7,8]. Progesterone and progestins increase mitotic activity in leiomyomas and thereby their rate of growth. Other endocrine, paracrine and biochemical factors are associated with fibroid growth and development and require assessment as potential therapeutic targets [1,2].

The traditional management of symptomatic fibroids has been surgery (hysterectomy or myomectomy). However, some women do not want invasive surgery and wish to retain their uterus and fertility [9]. Fortunately in this respect, during the last few years new medical and surgical uterine-conserving alternatives have become available as technological advances have been made. Pharmacological management of symptomatic uterine fibroids has benefited from the introduction of new compounds, although the indications and treatment duration are limited by their side-effects.

The aim of this position statement is to provide recommendations to help decision-making in the management of women with fibroids.

2. Prevalence and risk factors

A large proportion of women with fibroids are unaware they have these tumors simply because they are asymptomatic and do not seek medical attention. Therefore, the reported prevalence of fibroids varies between studies, as it depends on how participants are recruited and screened. In general, the prevalence of symptomatic fibroids peaks in the perimenopausal years and declines after the menopause. Their prevalence is high, at up to 70% of women aged 50 years, and the figure is even higher among black women [10,11].

Nulliparity, early menarcheal age, older age at first term pregnancy, obesity, diabetes, hypertension and family history are associated with an increased risk of fibroids. Leiomyomas may enlarge during the first trimester of pregnancy, but with no further growth in the second and third trimesters, despite increases in circulating progesterone [12,13]. Parity is inversely related to the risk of fibroids, but only among white women [14]. Fibroids shrink postpartum. Thus one study of 171 women with one initial fibroid found that 36% had no identifiable fibroid at the time of postpartum ultrasound, and 79% of the remaining fibroids decreased in size [15].

The effect of the combined oral contraceptive pill is uncertain as the evidence is conflicting. Depot progestogens may reduce the risk of fibroids [16]. There is some evidence that caffeine intake, for instance in the form of coffee, is associated with an increased risk of fibroids but smokers are at reduced risk [17,18]. Overt hypothyroidism was found to be associated with fibroids [19]. With regard to dietary risk factors dairy products and omega-3 fatty acid intake increase risk, but high fruit intake may reduce risk in black women [20–22].

Exposure to endocrine disrupters, and intake of soybean milk, food additives and sweeteners may all increase the risk of fibroids [23,24].

3. Clinical presentation

Most fibroids are asymptomatic, and will not produce pelvic symptoms or discomfort. However, fibroids may cause heavy menstrual bleeding (HMB) or painful menstruation, abdominal discomfort or bloating, back ache, painful defecation, painful sexual intercourse, and uncomfortable pelvic pressure; they may also increase the frequency of urinary tract infections. Many of these women may nonetheless delay medical consultation for a period of years. This is often because they fear the possible consequences of such a consultation which include cancer diagnosis, surgery (and the subsequent alteration of their sexual function), and loss of self-image and/or personal control. Women with severe symptoms will take time off work and experience a reduced quality of life [9]. However, clinical symptoms tend to reduce or disappear after the menopause [4].

Co-morbid conditions that are highly prevalent among women with uterine fibroids around the time of the menopause and sometimes may be associated with similar clinical symptoms include polyps, adenomyosis, endometrial hyperplasia and ovulatory disturbances [25,26].

3.1. Bleeding problems

Bleeding problems such as HMB and inter-menstrual bleeding can lead to iron deficiency and anemia. Why fibroids cause bleeding problems is uncertain. However, abnormal bleeding tends to be associated with submucous fibroids which distort the uterine cavity and may lead to endometrial and vascular dysfunction. It has been said that submucous fibroids are associated with more severe symptoms in general than fibroids in other locations, but menorrhagia and anemia are no more likely to be reported in women with at least one submucous fibroid than in those with fibroids only in other locations [27,28].

Assessment of excessive bleeding may be carried with pictograms, weighing menstrual protection, objective measurement of menstrual blood loss with the alkaline haematin method and assessment of hemoglobin and ferritin, or a combination of these measures [29,30]. For practical purposes, a subjective definition of HMB (i.e., excessive menstrual blood loss that is not tolerated by the patient and adversely affects quality of life) rather than objective measures can be used by the clinician as the basis for further investigation.

3.2. Pelvic symptoms

Fibroids may cause pelvic pain such as dysmenorrhea, dyspareunia, pelvic pressure and pelvic heaviness or discomfort. The location and size of the fibroids may influence the pain characteristics. Some do not produce any type of pain, especially those which are small. Torsion of pedunculated subserosal fibroids may produce acute pain, and submucosal fibroids may be associated with intermittent uterine contractions. Large fibroids can cause pelvic pressure

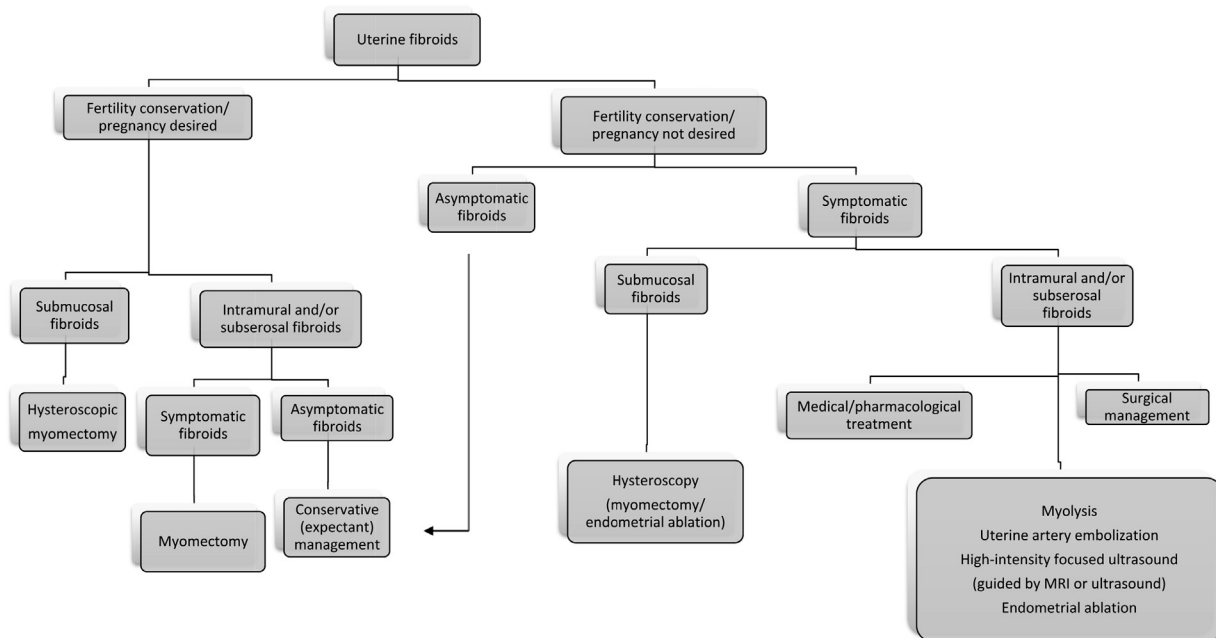


Fig. 1. Suggested flowchart for the management of uterine fibroids.

symptoms and affect bowel and bladder function although differential diagnosis should be made with other common causes such as pelvic adhesions, endometriosis and adenomyosis, and pelvic floor disorders [25,31,32].

3.3. Infertility

Fibroid location influences fertility. In patients consulting for infertility uterine morphology should be studied by magnetic resonance imaging which is a better procedure than transvaginal ultrasound and hysterosalpingography to plan clinical management. It seems that intramural, but not subserosal, fibroids may be associated with reduced fertility and increased risk of miscarriage. Submucosal or deeply infiltrating intramural fibroids may alter the endometrial cavity and interfere with implantation and pregnancy outcome [33]. The effects of multiple or different size fibroids on fertility is unclear due to the low quality of the available evidence [34]. Small fibroids not affecting the endometrial cavity do not seem to impact the *in vitro* fertility rate [35].

On the other hand, given that the prevalence of fibroids increases with age, women who delay pregnancy are more likely to have fibroids than their younger counterparts. While there is a statistical association between infertility and uterine fibroids, this is likely to be largely due to age alone, and it is not clear whether there is a direct cause–effect relationship between fibroids and infertility. Observational studies have reported inconclusive or contradictory results [36].

4. General management of uterine fibroids

Uterine fibroids may be diagnosed by pelvic clinical examination and ultrasound. Sometimes it is not possible clinically to accurately determine whether a pelvic mass involves the uterus or not, but ultrasound is a simple way to confirm this. In cases where the uncertain, magnetic resonance (MR) imaging or computed tomography may help [37]. Sonohysterography, hysterosalpingography or hysteroscopy may assist in identifying submucosal fibroids. Management depends on size, number and location as well as

whether the fibroids are causing symptoms. Fig. 1 shows the different management and therapeutic options.

4.1. Asymptomatic patients: conservative management

Asymptomatic women with small fibroids may benefit from expectant management, especially those approaching the menopause. An enlarged uterus rarely causes ureteric compression sufficient to compromise renal function. Women eligible for expectant management may be followed up to check for any change in uterine size or symptoms. While there are no standard guidelines as to frequency of follow up, annual review would appear prudent. Thus, when the woman is asymptomatic and does not want to become pregnant, there is no reason to consider treatment [38–40].

4.2. Symptomatic patients

For women with symptomatic fibroids (pain or pelvic discomfort, heavy bleeding), rapid growth or highly vascularized fibroids, treatment should be instituted after appropriate assessment. A wide variety of medical therapies are available (see Section 5). Medical treatments may shrink but will not eradicate fibroids which will tend to regrow once therapy is stopped. Surgery (myomectomy or hysterectomy) is indicated if the fibroids are large, rapidly growing or if symptoms are not responding to medical therapies. What option is used depends on a woman's desire to retain her uterus and her fertility goals.

Newer treatment options include uterine artery embolization via interventional radiologic techniques. Other new therapies such as high-intensity focused ultrasound, MR-guided laser ablation and ligation of the uterine arteries (detailed below) show promise, but need further evaluation.

5. Medical treatments and interventions

Pre-menopausal women with symptomatic uterine fibroids have different medical treatment options for the alleviation of symptoms, and may choose to delay surgery or the use of other invasive

techniques, or even to avoid them altogether. Most of the medical treatments may produce significant – though temporary – reductions in both uterine size and symptoms. These interventions may make surgery easier and in some cases may render it unnecessary, especially where, in the interim, the patient becomes menopausal. However, pharmacological treatments do not eradicate fibroids and are not devoid of side-effects.

5.1. Non-hormonal pharmacological treatment

The two commonly used non-hormonal options are tranexamic acid and non-steroidal anti-inflammatory drugs (NSAIDs). Tranexamic acid is a synthetic antifibrinolytic agent which has been used as a first-line non-hormonal therapy for HMB due to dysfunctional uterine causes or associated with fibroids [41–43].

Eder et al. [43] reported the efficacy and safety of modified-release tranexamic acid in women with HMB and fibroids. Within the tranexamic acid group, more statistically significant ($p < 0.001$) reductions in menstrual blood loss compared with placebo occurred in women with fibroids than in those without. However, further studies are needed to better define the potential benefit in women whose HMB is associated with fibroids. Tranexamic acid may increase the rate venous thromboembolism, although the rate is low; most studies have found the incidence of thrombosis in treated and untreated women [44]. In a case series of 490 women Ip et al. [45] reported that infarct-type necrosis and thrombosis of leiomyoma was more commonly observed in patients treated with tranexamic acid. However this requires further confirmation.

NSAIDs may reduce HMB and dysmenorrhea in women without fibroids [46]. However, there are no controlled trials showing the benefits of NSAIDs for HMB in women with fibroids. NSAIDs may reduce the pain associated with fibroids.

5.2. Systemic combined and progestin-only contraceptives

Epidemiologic studies suggest that both combined and progestin-only contraceptives may decrease the risk of developing clinically significant fibroids [47]. Combined oral contraceptives may control spotting or HMB associated with uterine fibroids without affecting their size [48]. A recent meta-analysis suggests that uterine fibroids should not be considered a contraindication for combined oral contraceptive use [47].

Clinical studies using progestins for the treatment of uterine fibroids have reported mixed results. While some studies with small numbers of cases reported a decrease in fibroid size during oral progestin therapy [49,50], the review by Sangkomkamhang et al. [51] concluded that oral progestins did not reduce fibroid size or fibroid-related symptoms. However, progestins may reduce endometrial hyperplasia-related HMB associated with fibroids.

5.3. Levonorgestrel intrauterine system

The levonorgestrel intrauterine system (LNG IUS) acts by inducing endometrial atrophy [51,52]. The LNG IUS is an effective treatment for HMB and irregular bleeding associated with fibroids and increases hemoglobin levels, but there are conflicting results concerning the effect on fibroid growth [53–55]. A multicentre, open, single-group, non-comparative phase 3 clinical study, 394 women between 46 and 51 years fitted with a LNG IUS found no significant change in size. Thus at study entry 83/394 (21.1%) women had one or two intramural fibroids (mean \pm SD diameter of the largest fibroid was 21 ± 9 mm). At 60 months of follow up the mean diameter was 22 ± 10 mm [55]. In cell culture, levonorgestrel inhibits proliferation and induces apoptosis of fibroid cells [56].

A systematic review concluded that progestogen-releasing intrauterine systems appear to reduce menstrual blood loss in premenopausal women with uterine fibroids [51]. However, the LNG IUS does not significantly reduce fibroid size and is more likely to be expelled [57,58]. In addition, there is some concern about the long-term cardiovascular effects of levonorgestrel, but this requires further study [59].

5.4. Gonadotropin-releasing hormone agonists

Gonadotropin-releasing hormone (GnRH) agonists have been used for the treatment of fibroids in perimenopausal women or as a preoperative treatment for 3–4 months, when they are used to reduce fibroid-related bleeding and anemia, uterine volume and fibroid size, to facilitate or enable endoscopic or transvaginal surgery [60]. In some cases a change from an abdominal procedure to vaginal surgery is possible after pre-treatment with GnRH agonists. The risk of fibroid recurrence after a course of GnRH agonists in patients who have undergone myomectomy is controversial and data are scarce on postoperative fertility [48,61].

The benefits of GnRH agonists are limited by their side-effects, which include hot flashes, sleep disturbances, vaginal dryness, depression and loss of bone mass after prolonged use. Various therapies have been studied as add-back (combined estrogen and progestin, medroxyprogesterone acetate, tibolone) to reduce these adverse effects, in order to allow longer use of GnRH agonists [62]. The improvements resulting from GnRH agonist treatment disappear soon after stopping.

A meta-analysis of the use of GnRH analogs before hysteroscopic submucous myomectomy concluded that there is insufficient evidence to support their use and that randomized trials are needed [63].

5.5. Antagonists of progesterone receptors

Progesterone receptors are present in higher concentrations in fibroids than in normal myometrium. Mifepristone (RU-486) is a progesterone receptor antagonist that has been used, at different doses, to improve fibroid-associated symptoms. Mifepristone (2.5 or 5 mg) for 3–6 months is associated with increases in health-related quality of life, which has been explained by the reduction of both pain and HMB. The effect of mifepristone on fibroid volume remains uncertain with conflicting results and there are concerns regarding endometrial hyperplasia [64–67]. Mifepristone (2.5 mg/day) for 6 months in women with at least moderate symptoms, with uterine volume of 160 ml or more, or at least one fibroid of >2.5 cm in diameter results in modest reductions in uterine size and improvements in symptoms and quality of life without endometrial hyperplasia [66].

An analysis of three randomized controlled trials of mifepristone in women with confirmed uterine fibroids showed that it may reduce HMB (compared with placebo), although it has no effect on fibroid volume. This treatment was associated with an increase of abnormal endometrial histology compared with placebo, including endometrial hyperplasia at the end of the therapy [67].

There is little information on the effect of vaginal mifepristone in women with symptomatic fibroids, although Yerushalmi et al. [68] recently reported that a course of 10 mg/day for 3 months reduced fibroid volume and the number of bleeding days, and improved quality of life.

5.6. Selective progesterone receptor modulators

Selective progesterone receptor modulators (SPRMs) act through progesterone receptors and behave as agonists or antagonists in various target organs. They include onapristone, asoprisnil

and ulipristal, all of which are under evaluation for the treatment of fibroids. The results suggest that short-term treatment can reduce fibroid-associated symptoms and anemia. Ulipristal is licensed in the USA and in the European Union for the preoperative treatment of uterine fibroids as an oral daily tablet of 5 mg.

Asoprisnil is an orally active SPRM which has been studied in a randomized double-blind, placebo-controlled trial with a small number of women scheduled for hysterectomy for fibroids. They were treated with 10 or 25 mg asoprisnil or placebo for 12 weeks before surgery. Asoprisnil moderately reduced uterine artery blood flow, decreased the frequency and intensity of bleeding in both groups of treated women, compared with the placebo group. In this short-term study no serious adverse events were reported [69].

Ulipristal acetate has been studied in premenopausal women with symptomatic fibroids. A daily dose of 10 or 20 mg for 3 months reduced total fibroid volume, compared with placebo. Treatment was associated with amenorrhea, and increased hemoglobin levels and quality of life [70]. A randomized controlled trial evaluated ulipristal treatment (5 or 10 mg/day for 13 weeks) in women with symptomatic fibroids. It effectively controlled HMB and reduced the size of fibroids compared with placebo. Rates of amenorrhea were high in women treated with ulipristal, occurring very early after initiation of treatment. Side-effects included benign histologic endometrial changes that disappeared within 6 months after treatment [71]. Both the 5 mg and the 10 mg daily doses of ulipristal acetate were non-inferior to once-monthly GnRH analog treatment in controlling uterine bleeding [72]. As ulipristal treatment does not suppress estrogen synthesis, its use is not associated with menopausal symptoms and bone loss, unlike GnRH agonists [72,73]. Ulipristal was superior to placebo as a preoperative treatment of uterine fibroids, reducing fibroid-associated bleeding and fibroid size, without the side-effects of GnRH analogs. There is also some evidence that repeated 3-month ulipristal treatment may control bleeding and shrink symptomatic fibroids [74]. Their effect on fibroid size may persist longer after cessation of treatment compared with GnRH agonist therapy [48].

5.7. Other pharmacological treatments

Danazol and gestrinone appear to be effective in treating some symptoms associated with fibroids, but they both have side-effects. In addition, there is very limited information and there are no randomized controlled trials on the risks and benefits of using these drugs for the treatment of fibroid-associated symptoms.

Currently, there is limited evidence for the use of raloxifene in premenopausal women for the treatment of fibroids and there is no evidence to support the use of tamoxifen [75].

Aromatase inhibitors (letrozole, exemestane and anastrozole) are not approved for the treatment of uterine fibroids, despite some favorable effects [76–79]. However, some studies, though with small numbers of patients, have reported a reduction in HMB and pelvic pain as well as a decrease in fibroid volume [80,81]. In addition, short-term letrozole treatment (2.5 mg/day for 12 weeks) has been reported as effective as GnRH analogs in reducing fibroid volume [77]. Further trials are required.

A systematic review concluded that current evidence does not support or refute the use of herbal preparations for treatment of uterine fibroids due to insufficient studies with large sample sizes and of high quality [82].

6. Surgical treatments and interventions

In premenopausal women with fibroids and severe symptoms which do not respond to medical treatments, surgery – either hysterectomy or myomectomy – is the conventional option. The three

common approaches are abdominal open surgery, laparoscopy or robot-assisted surgery. Classical vaginal hysterectomy or hysteroscopic myomectomy can also be performed.

6.1. Hysterectomy

Symptomatic uterine fibroids have been, and still are, one of the most common indications for hysterectomy. It eliminates the symptoms and removes the lesions. Hysterectomy should be considered when other therapeutic options have failed and the patient does not want to retain her uterus and accepts the risks of surgery [83]. The procedure can be performed via the vaginal, abdominal or laparoscopic route, taking into account uterine size, patient preference and available facilities. Vaginal hysterectomy is the most cost-effective option [84]. Laparoscopic and vaginal surgery are associated with less postoperative pain, a shorter hospital stay, better cosmetic results and quicker return to ordinary activities than abdominal hysterectomy. Some women may elect for subtotal hysterectomy. However there appear to be no significant differences in the outcome, although in some women cyclical bleeding may persist after subtotal hysterectomy [85]. It seems that subtotal hysterectomy does not lead to better sexual, urinary or bowel function when compared with total abdominal hysterectomy [86]. Furthermore women will need to continue with cervical screening. The evidence regarding robot-assisted hysterectomy for fibroids is limited and requires further evaluation [87–89].

6.2. Abdominal myomectomy

Perioperative morbidity of abdominal myomectomy and hysterectomy are similar [90]. However, myomectomy of very large fibroids may be associated with significant perioperative complications such as bleeding requiring transfusion and bowel or bladder injury. It seems that complications are more common with a uterine size equivalent to that of 20 gestational weeks or more, when 10 or more fibroids are removed and when a midline skin incision is needed [91].

6.3. Laparoscopic myomectomy

Laparoscopic myomectomy has medical, social and economic advantages over abdominal open surgery, including less postoperative pain and a shorter recovery time [92,93]. Laparoscopic myomectomy of subserous and intramural fibroids with retention of the fibroid pseudocapsule permits the preservation of myometrial and endometrial integrity, and has few complications. In addition, the fertility rate and pregnancy outcomes are more favorable with laparoscopic myomectomy than after abdominal myomectomy when there is no other cause of infertility [94]. The time to conception after laparoscopic myomectomy is shorter than after abdominal myomectomy, although the pregnancy rate is similar [95,96]. Uterine rupture during pregnancy following laparoscopic myomectomy is rare [97]. However, laparoscopic myomectomy should be considered with caution for women with fibroids of more than 5 cm in diameter, those with several fibroids and those with deep intramural myomas [98,99]. In such cases, a prospective comparative study reported better results with radiofrequency thermal ablation (see Section 8.4) than with laparoscopic myomectomy [100].

In April 2014 the US Food and Drug Administration discouraged the use of laparoscopic power morcellation during hysterectomy or myomectomy for the treatment of women with uterine fibroids because of the potential for dissemination of an unsuspected uterine sarcoma [101].

6.4. Robot-assisted myomectomy

Robot-assisted laparoscopic myomectomy is a new alternative to traditional surgery. The evidence suggests that is associated with less blood loss, lower complication rates and shorter hospital stays than abdominal myomectomy, although the cost is higher [102–104]. In a retrospective analysis of fertility, higher preterm delivery rates were associated with a greater number of myomas removed and anterior location of the largest incision [105]. Thus cost effectiveness of robot-assisted laparoscopic myomectomy requires further evaluation.

6.5. Hysteroscopic myomectomy

In women with infertility and asymptomatic submucosal fibroids, hysteroscopic myomectomy seems the only reasonable treatment option. Hysteroscopic myomectomy for submucosal fibroids greater than 2 cm and for intramural fibroids distorting the endometrial cavity may be considered in subfertile women [106]. Although the technique is widely used, there is little evidence from randomized trials to support the intervention in women whose infertility is unexplained [107,108]. Hysteroscopy-related complications include uterine perforation, hemorrhage, cervical laceration and fluid overload while long term sequelae include adhesions.

6.6. Ligation of uterine arteries

Laparoscopic ligation of the uterine arteries is better tolerated although is less efficacious than uterine artery embolization (see Section 7) [109]. It reduces the size of the fibroids as well as symptoms, but again the results obtained with uterine artery embolization are better, and there is less risk of recurrence. Laparoscopic ligation of the uterine arteries has also been used immediately before myomectomy to reduce intraoperative complications [110,111].

Transvaginal bilateral uterine artery ligation has been proposed in centers lacking high-level medical technology. Clinical and patient satisfaction has been reported to be acceptable at 3-year follow-up [112].

6.7. Endometrial ablation

Endometrial ablation can be used separately or can be combined with hysteroscopic resection in women with HMB who do not wish to preserve their fertility. Second-generation endometrial ablation (thermal ablation, radiofrequency ablation, microwave ablation) are as effective as the LNG IUS, although satisfaction is higher with hysterectomy [113–116].

7. Uterine artery embolization

Uterine artery embolization (UAE) involves the placement of an angiographic catheter into the uterine arteries via a common femoral artery approach and injection of embolic particles larger than 500 μm , in most cases polyvinyl alcohol particles or tris-acryl gelatin microspheres, until the flow becomes sluggish in both uterine arteries. The mechanism of UAE's action is the marked reduction of uterine blood flow at the arteriolar level, which produces ischemic injury to the fibroids, causing them to undergo necrosis and shrink, while the normal myometrium is able to recover. Immediately after the procedure, most patients experience moderate to severe ischemic pain for 8–12 h, but this gradually decreases during the next 12 h. Patients can usually return to normal activities within 8–14 days. A relatively common complication of UAE is vaginal expulsion of an infarcted fibroid, reported in up to 10% of cases. This

complication is more frequently seen with submucosal or intramural fibroids. The most serious complication of UAE is intrauterine infection, but this has been reported after less than 1% of procedures [117].

UAE is an option for women with symptomatic fibroids, who no longer desire fertility but who wish to avoid surgery or are poor surgical or anesthetic risks. A multicenter study carried out in the United Kingdom assessed the cost-effectiveness of UAE and hysterectomy in women with symptomatic fibroids. The women were followed from the initial procedure to the menopause. End-points were costs of interventions and complications and quality of life expressed as quality-adjusted life years (QALYs). UAE was a cheaper treatment and had more QALYs, even after accounting for repeat procedures and complications. Short-term, but not long-term, quality of life was better in patients who underwent UAE because of the need for further procedures. The authors concluded that UAE is cost-effective in women who wish to preserve their uterus [118]. The cost and QALYs of UAE have also been compared with both hysterectomy and myomectomy in Hong Kong women with symptomatic fibroids [119]. This study showed that hysterectomy is more cost-effective than the other two treatments among women with no preference for uterus-conserving interventions.

The Randomized Trial of Embolization versus Surgical Treatment for Fibroids (REST) found no differences between groups on quality-of-life measures at one year [120]. The UAE group had shorter hospital stays and recovery times than the hysterectomy group. There were no differences between the groups in the rate of major complications (15% for the UAE and 20% for the surgical group). In cost and cost-effectiveness studies, hospital costs associated with UAE were lower, largely because of shorter length of stay. However, this needs to be balanced against the need for additional interventions such as hysterectomy or repeated UAEs due to recurrent symptoms. Thus a randomized trial of 157 women found that the 5-year intervention rate for treatment failure or complications was higher for UAE (32%) than for surgery (4%) [121]. The authors concluded that the initial cost benefit of UAE over surgery at 12 months was substantially reduced because of subsequent interventions, with treatments being cost neutral at 5 years.

Gupta et al. [122] carried out a meta-analysis of the benefits and risks of UAE versus other medical or surgical interventions for symptomatic uterine fibroids. Patient satisfaction with the procedures and the rate of complications were similar for UAE and surgery at 2 and 5 years. There was some evidence that myomectomy may be associated with better fertility outcomes in the small sample of women who wished to retain their fertility. UAE was associated with reduced length of the treatment, shorter hospital stay, lower rate of blood transfusion and less time to resumption of normal activities as compared with surgical procedures. However, there were higher rates of complications after UAE, such as more unscheduled readmissions after discharge and an increased surgical reintervention rate. These surgical procedures should be included in the final costs of UAE.

In premenopausal women both hysterectomy and UAE may lead to loss of ovarian reserve [123]. Embolization particles have been found in the ovaries and blood flow is reduced [124,125]. Results from randomized trials and prospective series suggest that reduction of the ovarian reserve, after UAE, occurs mainly in women aged 45 or more [126].

The fertility rate after UAE has been studied in women with severe symptomatic fibroids and infertility. Torre et al. [127] carried out a prospective study in 66 women who had been previously treated with abdominal myomectomy but whose fibroids had recurred, and who wished to maintain their reproductive capacity. All the women underwent embolization of both uterine arteries. The procedure improved HMB, and reduced both pain and dominant fibroid size. Although the ovarian reserve was not altered by

UAE, among the 31 women who tried to conceive, there was only one pregnancy, and that ended in miscarriage. However, this low rate of fertility cannot be generalized to patients without previous surgery and extensive fibroid recurrence.

In a small sample of selected women, the long-term effects of UAE on ovarian reserve has been compared with findings in women treated with laparoscopic myomectomy. Serum anti-müllerian hormone levels and antral follicle count were significantly lower in women who had undergone UAE than in women who had undergone surgical myomectomy, although serum FSH and estradiol levels were similar in the two groups [128]. Furthermore, studies in sheep suggest that UAE could lead to intrauterine growth retardation [129].

While UAE appears to be an option for women who wish to retain their uterus, use of the procedure needs to be balanced against the need for further interventions and the loss of ovarian reserve with scarce data on pregnancy outcome.

8. Fibroid lysis

Ablation with high-intensity focused ultrasound (HIFU) is a minimally invasive treatment which is performed under the guidance of either MR or ultrasound. HIFU has been used to treat a variety of solid benign and malignant lesions. It produces focal fibroid coagulation and necrosis without alteration of surrounding normal myometrium. Myolysis is not indicated for women who want to become pregnant. Patients contemplating pregnancy should be informed that the effects of the procedure on fertility and on pregnancy are uncertain.

8.1. Magnetic resonance-guided high-intensity focused ultrasound

Magnetic resonance-guided MR-guided HIFU is an alternative to surgery and UAE. It is non-invasive, requires no general anesthetic or hospitalization, and uses high-intensity ultrasound waves to destroy fibroids, by heating, without damaging adjacent normal structures. It is an ambulatory procedure without incisions, allowing women to return to work after one or two days. Better results are achieved for intramural fibroids, so MR-guided HIFU is not recommended for pedunculated subserosal fibroids. The presence of bowel loops or abdominal wall scars in the projected pathway of the ultrasound beam may preclude use of the technique. Common symptoms during the procedure are short-term lower abdominal pain, leg pain and buttock pain. Patients are usually discharged home 1 h after the procedure. It seems that the use of GnRH agonist therapy beforehand improves the effect of the thermoablative treatment [130].

Froeling et al. [131] compared the long-term outcomes of UAE and MR-guided HIFU for symptomatic uterine fibroids. The rate of theater intervention was significantly lower after UAE (12.2%) than after MR-guided HIFU (66.7%), and both total health-related quality of life and severity of symptoms were better in women treated with UAE. The procedure is not possible when there is bowel interposition in the ultrasound beam path. Thus, a study of 783 women found that bowel interposition affected 60.4% of women and differences in technical eligibility for MR-guided HIFU (38.9%) and UAE (99.2%) were significant ($P < 0.001$) [132]. However, in some patients with bowel loops anterior to the uterus, therapeutic HIFU ablation of uterine fibroids may be possible after bowel compression with a degassed water balloon on the abdominal wall under a real-time MR guidance and control [133]. This technique needs further assessment.

MR-guided HIFU is cost-effective when compared with traditional techniques, hysterectomy, myomectomy and uterine artery

embolization. Indeed, its low overall cost may lead to the technique becoming the first therapeutic option for symptomatic fibroids. A meta-analysis of 38 studies concluded that MR-guided HIFU a safe, efficient and cost-effective technique for the treatment of symptomatic uterine fibroids that improves quality of life and fertility [134]. It has comparable results to other treatment strategies. In a recent U.S. survey in which women were informed about different treatments, 60% rated focused ultrasound as their top choice [9].

8.2. Ultrasound-guided high-intensity focused ultrasound

Ultrasound-guided HIFU ablation is a new non-invasive treatment of uterine fibroids [135]. The technique allows a check on the immediate efficacy of the procedure; then, if viable residual tissue is detected, there is the option to repeat the ablation immediately. Heterogeneous and markedly homogeneous hyperintense fibroids, as classified by MR, may be treated with ultrasound-guided HIFU [136]. Contrast-enhanced ultrasonography may also be used to monitor gradual shrinkage of the treated fibroids or later growth [137].

Large-scale clinical trials are needed to assess the role and limitations of these techniques.

8.3. Transcervical real-time intrauterine sonography with radiofrequency ablation

A device is available that combines real-time intrauterine sonography with radiofrequency ablation, which takes place under real-time visualization. A graphical interface delineates the boundaries of both ablation and thermal spread, which means that thermal injury to the serosa can be avoided, and the risk of adhesion and injury to bowel or bladder can be minimized. Overall, the procedure is well tolerated, with patients recording low pain scores; it may be carried out with the patient under local anesthetic or sedation. The procedure takes about 30 min [138]. Further studies are needed.

8.4. Laparoscopic ultrasound-guided radiofrequency ablation

Laparoscopic ultrasound-guided radiofrequency thermal ablation of fibroids seems to be safe and to have a high rate of patient satisfaction. It reduces menstrual bleeding and has a low rate of re-intervention. It has been shown to improve quality of life at one- and two-year follow-up [139–142]. Its main advantage is that it allows direct placement of the device close to the fibroid. A prospective randomized controlled trial in women who wanted to retain their uterus reported that radiofrequency thermal ablation allowed treatment of more fibroids with less blood loss and a shorter hospital stay than laparoscopic myomectomy [100].

9. Specific considerations

9.1. Fibroids and menopausal hormone therapy

Asymptomatic fibroids are not a contraindication to menopausal hormone therapy. The data are limited and show that menopausal hormone therapy does not significantly increase fibroid volume, but it can increase the risk of abnormal bleeding in women with submucosal fibroids [143,144].

9.2. Fibroid degeneration

Fibroids can undergo various types of benign degeneration. The most common is hyaline degeneration, consisting of mucopolysaccharide deposits around muscle fibers. 'Red degeneration' corresponds to vascular infarction, is associated with acute

pain and mainly occurs in pregnancy. Fat degeneration is very rare and is asymptomatic. Calcification is seen in postmenopausal women, especially those of older age [145].

9.3. Unusual fibroid complications and malignancies

In perimenopausal women rapid uterine growth may be due to an unexpected pregnancy. Unusual complications include massive hemoperitoneum resulting from spontaneous rupture or avulsion of fibroids or due to rupture of a vessel overlying an uterine fibroid, degenerative changes mimicking an ovarian cancer, or an undiagnosed uterine sarcoma. The presenting symptoms, clinical assessment, ultrasound examination and MR imaging can help to establish the differential diagnosis, and in particular to distinguish between benign and malignant causes [146,147].

It is unknown at present whether leiomyosarcoma represents de novo growth or malignant transformation from benign uterine fibroids. This rare malignant tumor (less than one in 1000) is characterized by a rapid increase of uterine size, abnormal bleeding, pain and general symptoms sometimes related to metastases. Leiomyosarcomas express a variety of genes which are related to both disease progression and metastasis formation [148].

Hereditary myomatosis and renal cell cancer is an autosomal dominant syndrome defined by uterine fibroids, piloleiomyoma and papillary type 2 renal cancer related to a germline mutation in the fumarate hydratase gene. This syndrome is very rare, affecting only some 180 families worldwide, but it is exceptionally aggressive [149].

Pseudo-Meigs' syndrome is a rare clinical condition characterized by the presence of a uterine fibroid associated with ascites, with or without hydrothorax [150].

10. Conclusions

Uterine fibroids are the most common tumors of the female reproductive tract. Fibroid-associated symptoms include HMB, pain or pelvic discomfort and infertility. Treatment options for symptomatic fibroids include pharmacologic, surgical and radiologically guided interventions. A wide range is now available and some require further evaluation. Thus women can now retain their uterus and their fertility. The choice of treatment depends on fibroid size, the underlying symptoms and their severity and the woman's desire for subsequent fertility and pregnancy, as well as efficacy and need for repeated interventions.

11. Summary recommendations

- Women with asymptomatic uterine fibroids require follow-up, with periodic assessment to document stability in size and growth.
- Women with symptomatic uterine fibroids generally complain of heavy menstrual bleeding and pelvic pain; infertility may be an associated problem.
- There is no effective non-invasive (medical) treatment that permanently removes fibroids.
- Tranexamic acid, combined and progestin-only contraceptives may be useful in the management of fibroid-associated bleeding problems.
- Progesterone receptor modulators are an important addition to the medical armamentarium, although they are advocated currently only for short-term use preoperatively.
- Hysterectomy has a high degree of satisfaction in premenopausal women who have no wish to preserve their fertility.
- Myomectomy may be indicated for infertility-associated fibroids.

- Nonsurgical treatments include uterine artery embolization and high-intensity focused ultrasound but the impact of these treatments on fertility and pregnancy success is still uncertain.

Contributors

FRPL, LO and MR prepared the initial draft, which was circulated to EMAS board members for comment and approval; production was coordinated by MR and FRPL.

Competing interests

The authors have no conflicting interests to declare.

Funding

None was sought or secured for writing this statement.

Provenance and peer review

EMAS position statement.

References

- [1] Bulun SE. Uterine fibroids. *N Engl J Med* 2013;369:1344–55.
- [2] Ono M, Yin P, Navarro A, et al. Paracrine activation of WNT/ β -catenin pathway in uterine leiomyoma stem cells promotes tumor growth. *Proc Natl Acad Sci USA* 2013;110:17053–8.
- [3] Bertsch E, Qiang W, Zhang Q, et al. MED12 and HMG2 mutations: two independent genetic events in uterine leiomyoma and leiomyosarcoma. *Mod Pathol* 2014 [in press], PMID: 24390224.
- [4] Flake GP, Moore AB, Sutton D, et al. The natural history of uterine leiomyomas: light and electron microscopic studies of fibroid phases, interstitial ischemia, inanosis, and reclamation. *Obstet Gynecol Int* 2013;2013:528376.
- [5] Nikitenko LL, Cross T, Campo L, et al. Expression of terminally glycosylated calcitonin receptor-like receptor in uterine leiomyoma: endothelial phenotype and association with microvascular density. *Clin Cancer Res* 2006;12:5648–58.
- [6] Tai R, Segars JH. The role of angiogenic factors in fibroid pathogenesis: potential implications for future therapy. *Hum Reprod Update* 2014;202:194–216.
- [7] Maruo T, Ohara N, Wang J, Matsuo H. Sex steroidal regulation of uterine leiomyoma growth and apoptosis. *Hum Reprod Update* 2004;10:207–20.
- [8] Islam MS, Protic O, Giannubilo SR, et al. Uterine leiomyoma: available medical treatments and new possible therapeutic options. *J Clin Endocrinol Metab* 2013;98:921–34.
- [9] Borah BJ, Nicholson WK, Bradley L, Stewart EA. The impact of uterine leiomyomas: a national survey of affected women. *Am J Obstet Gynecol* 2013;209:319.e1–20.
- [10] Baird DD, Dunson DB, Hill MC, Cousins D, Schectman JM. High cumulative incidence of uterine leiomyoma in black and white women: ultrasound evidence. *Am J Obstet Gynecol* 2003;188:100–7.
- [11] Wise LA, Palmer JR, Harlow BL, et al. Reproductive factors, hormonal contraception, and risk of uterine leiomyomata in African-American women: a prospective study. *Am J Epidemiol* 2004;159:113–23.
- [12] Hammoud AO, Asaad R, Berman J, Treadwell MC, Blackwell S, Diamond MP. Volume change of uterine myomas during pregnancy: do myomas really grow? *J Minim Invasive Gynecol* 2006;13:386–90.
- [13] Neiger R, Sonek JD, Croom CS, Ventolini G. Pregnancy-related changes in the size of uterine leiomyomas. *J Reprod Med* 2006;51:671–4.
- [14] Chen CR, Buck GM, Courey NG, Perez KM, Wactawski-Wende J. Risk factors for uterine fibroids among women undergoing tubal sterilization. *Am J Epidemiol* 2001;153:20–6.
- [15] Laughlin SK, Herring AH, Savitz DA, et al. Pregnancy-related fibroid reduction. *Fertil Steril* 2010;94:2421–3.
- [16] Okolo S. Incidence, aetiology and epidemiology of uterine fibroids. *Best Pract Res Clin Obstet Gynaecol* 2008;22:571–88.
- [17] Wise LA, Palmer JR, Harlow BL, et al. Risk of uterine leiomyomata in relation to tobacco, alcohol and caffeine consumption in the Black Women's Health Study. *Hum Reprod* 2004;19:1746–54.
- [18] Laughlin SK, Schroeder JC, Baird DD. New directions in the epidemiology of uterine fibroids. *Semin Reprod Med* 2010;28:204–17.
- [19] Ott J, Kurz C, Braun R, Promberger R, Seemann R, Vytiska-Binstorfer E, Walch K. Overt hypothyroidism is associated with the presence of uterine leiomyoma: a retrospective analysis. *Eur J Obstet Gynecol Reprod Biol* 2014;177:19–22.
- [20] Wise LA, Radin RG, Palmer JR, Kumanyika SK, Boggs DA, Rosenberg L. Intake of fruit, vegetables, and carotenoids in relation to risk of uterine leiomyomata. *Am J Clin Nutr* 2011;94:1620–31.

- [21] Wise LA, Palmer JR, Ruiz-Narvaez E, Reich DE, Rosenberg L. Is the observed association between dairy intake and fibroids in African Americans explained by genetic ancestry? *Am J Epidemiol* 2013;178:1114–9.
- [22] Wise LA, Radin RG, Kumanyika SK, Ruiz-Narvaez EA, Palmer JR, Rosenberg L. Prospective study of dietary fat and risk of uterine leiomyomata. *Am J Clin Nutr* 2014;99:1105–16.
- [23] Yu L, Moore AB, Castro L, et al. Estrogen regulates MAPK-related genes through genomic and nongenomic interactions between IGF-1 receptor tyrosine kinase and estrogen receptor- α signaling pathways in human uterine leiomyoma cells. *J Signal Transduct* 2012:204236.
- [24] Shen Y, Xu Q, Xu J, Ren ML, Cai YL. Environmental exposure and risk of uterine leiomyoma: an epidemiologic survey. *Eur Rev Med Pharmacol Sci* 2013;17:3249–56.
- [25] Munro MG, Critchley HO, Broder MS, Fraser IS. FIGO Working Group on Menstrual Disorders. FIGO classification system (PALM-COIN) for causes of abnormal uterine bleeding in nonpregnant women of reproductive age. *Int J Gynaecol Obstet* 2011;113:3–13.
- [26] Dreisler E, Poulsen LG, Antonsen SL, et al. EMAS clinical guide: assessment of the endometrium in peri and postmenopausal women. *Maturitas* 2013;75:181–90.
- [27] Bachmann GA, Bahouth LA, Amalraj P, Mhamunkar V, Hoes K, Ananth CV. Uterine fibroids: correlations of anemia and pain to fibroid location and uterine weight. *J Reprod Med* 2011;56:463–6.
- [28] Puri K, Famuyide AO, Erwin PJ, Stewart EA, Laughlin-Tommaso SK. Submucosal fibroids and the relation to heavy menstrual bleeding and anemia. *Am J Obstet Gynecol* 2014;210:38.e1–7.
- [29] Schumacher U, Schumacher J, Mellinger U, Gerlinger C, Wienke A, Endrikat J. Estimation of menstrual blood loss volume based on menstrual diary and laboratory data. *BMC Women's Health* 2012;12:24.
- [30] Napolitano M, Dolce A, Celenza G, et al. Iron-dependent erythropoiesis in women with excessive menstrual blood losses and women with normal menses. *Ann Hematol* 2014;93:557–63.
- [31] Kavvadias T, Baessler K, Schuessler B. Pelvic pain in urogynaecology: Part I: Evaluation, definitions and diagnoses. *Int Urogynecol J* 2011;22:385–93.
- [32] Moshesh M, Olshan AF, Saldana T, Baird D. Examining the relationship between uterine fibroids and dyspareunia among premenopausal women in the United States. *J Sex Med* 2014;11:800–8.
- [33] Kroon B, Johnson N, Chapman M, Yazdani A, Hart R. Australasian CREI Consensus Expert Panel on Trial evidence (ACCEPT) group. Fibroids in infertility – consensus statement from ACCEPT (Australasian CREI Consensus Expert Panel on Trial evidence). *Aust N Z J Obstet Gynaecol* 2011;51:289–95.
- [34] Metwally M, Farquhar CM, Li TC. Is another meta-analysis on the effects of intramural fibroids on reproductive outcomes needed? *Reprod Biomed Online* 2011;23:2–14.
- [35] Somigliana E, De Benedictis S, Vercellini P, et al. Fibroids not encroaching the endometrial cavity and IVF success rate: a prospective study. *Hum Reprod* 2011;26:834–9.
- [36] Metwally M, Cheong YC, Horne AW. Surgical treatment of fibroids for subfertility. *Cochrane Database Syst Rev* 2012;11:CD003857.
- [37] Shwayder J, Sakhel K. Imaging for uterine myomas and adenomyosis. *J Minim Invasive Gynecol* 2014;21:362–76.
- [38] Lefebvre G, Vilos G, Allaire C, et al. The management of uterine leiomyomas. *J Obstet Gynaecol Can* 2003;25:396.
- [39] Laughlin SK, Stewart EA. Uterine leiomyomas: individualizing the approach to a heterogeneous condition. *Obstet Gynecol* 2011;117:396–403.
- [40] Pritts EA, Olive DL. When should uterine fibroids be treated? *Curr Obstet Gynecol Rep* 2012;1:71–80.
- [41] Fraser IS, Porte RJ, Kouides PA, Lukes AS. A benefit-risk review of systemic haemostatic agents: Part 2: In excessive or heavy menstrual bleeding. *Drug Saf* 2008;31:275–82.
- [42] Freeman EW, Lukes A, VanDrie D, et al. A dose–response study of a novel, oral tranexamic formulation for heavy menstrual bleeding. *Am J Obstet Gynecol* 2011;205:319.e1–7.
- [43] Eder S, Baker J, Gersten J, Mabey RG, Adomako TL. Efficacy and safety of oral tranexamic acid in women with heavy menstrual bleeding and fibroids. *Women's Health (Lond, Engl)* 2013;9:397–403.
- [44] Naoulou B, Tsai MC. Efficacy of tranexamic acid in the treatment of idiopathic and non-functional heavy menstrual bleeding: a systematic review. *Acta Obstet Gynecol Scand* 2012;91:529–37.
- [45] Ip PP, Lam KW, Cheung CL, et al. Tranexamic acid-associated necrosis and intralesional thrombosis of uterine leiomyomas: a clinicopathologic study of 147 cases emphasizing the importance of drug-induced necrosis and early infarcts in leiomyomas. *Am J Surg Pathol* 2007;3:1215–24.
- [46] Lethaby A, Duckitt K, Farquhar C. Non-steroidal anti-inflammatory drugs for heavy menstrual bleeding. *Cochrane Database Syst Rev* 2013;1:CD000400.
- [47] Qin J, Yang T, Kong F, Zhou Q. Oral contraceptive use and uterine leiomyoma risk: a meta-analysis based on cohort and case–control studies. *Arch Gynecol Obstet* 2013;288:139–48.
- [48] Hoellen F, Griesinger G, Bohlmann MK. Therapeutic drugs in the treatment of symptomatic uterine fibroids. *Expert Opin Pharmacother* 2013;14:2079–85.
- [49] Venkatachalam S, Bagratee JS, Moodley J. Medical management of uterine fibroids with medroxyprogesterone acetate (Depo Provera): a pilot study. *J Obstet Gynaecol* 2004;24:798–800.
- [50] Ichigo S, Takagi H, Matsunami K, Suzuki N, Imai A. Beneficial effects of dienogest on uterine myoma volume: a retrospective controlled study comparing with gonadotropin-releasing hormone agonist. *Arch Gynecol Obstet* 2011;284:667–70.
- [51] Sangkomkarn US, Lumbiganon P, Laopaiboon M, Mol BW. Progestogens or progestogen-releasing intrauterine systems for uterine fibroids. *Cochrane Database Syst Rev* 2013;2:CD008994.
- [52] Lethaby AE, Cooke I, Rees M. Progesterone or progestogen-releasing intrauterine systems for heavy menstrual bleeding. *Cochrane Database Syst Rev* 2005;4:CD002126.
- [53] Socolov D, Blidaru I, Tamba B, Miron N, Boiculescu L, Socolov R. Levonorgestrel releasing-intrauterine system for the treatment of menorrhagia and/or frequent irregular uterine bleeding associated with uterine leiomyoma. *Eur J Contracept Reprod Health Care* 2011;16:480–7.
- [54] Kriplani A, Awasthi D, Kulshrestha V, Agarwal N. Efficacy of the levonorgestrel-releasing intrauterine system in uterine leiomyoma. *Int J Gynaecol Obstet* 2012;116:35–8.
- [55] Depypere HT, Hillard T, Erkkola R, et al. A 60-month non-comparative study on bleeding profiles with the levonorgestrel intrauterine system from the late transition period to estrogen supplemented menopause. *Eur J Obstet Gynecol Reprod Biol* 2010;153:176–80.
- [56] Xu Q, Qiu L, Zhu L, Luo L, Xu C. Levonorgestrel inhibits proliferation and induces apoptosis in uterine leiomyoma cells. *Contraception* 2010;82:301–8.
- [57] Jiang W, Shen Q, Chen M, et al. Levonorgestrel-releasing intrauterine system use in premenopausal women with symptomatic uterine leiomyoma: a systematic review. *Steroids* 2014;86C:69–78.
- [58] Youm J, Lee HJ, Kim SK, Kim H, Jee BC. Factors affecting the spontaneous expulsion of the levonorgestrel-releasing intrauterine system. *Int J Gynaecol Obstet* 2014 [in press].
- [59] Pérez-López FR. Long-term consequences of LNG-IUS vs. hysterectomy for menorrhagia. *Climacteric* 2014;14:308–9.
- [60] Muzii L, Boni T, Bellati F, et al. GnRH analogue treatment before hysteroscopic resection of submucous myomas: a prospective, randomized, multicenter study. *Fertil Steril* 2010;94:1496–9.
- [61] Lethaby A, Vollenhoven B, Sowter M. Efficacy of pre-operative gonadotrophin hormone releasing analogues for women with uterine fibroids undergoing hysterectomy or myomectomy: a systematic review. *BJOG* 2002;109(10):1097–108.
- [62] Lethaby AE, Vollenhoven BJ. An evidence-based approach to hormonal therapies for premenopausal women with fibroids. *Best Pract Res Clin Obstet Gynaecol* 2008;22:307–31.
- [63] Kamath MS, Kalampokas EE, Kalampokas TE. Use of GnRH analogues pre-operatively for hysteroscopic resection of submucous fibroids: a systematic review and meta-analysis. *Eur J Obstet Gynecol Reprod Biol* 2014;177C:11–8.
- [64] Shen Q, Hua Y, Jiang W, Zhang W, Chen M, Zhu X. Effects of mifepristone on uterine leiomyoma in premenopausal women: a meta-analysis. *Fertil Steril* 2013;100:1722–6.
- [65] Feng C, Meldrum S, Fiscella K. Improved quality of life is partly explained by fewer symptoms after treatment of fibroids with mifepristone. *Int J Gynaecol Obstet* 2010;109:121–4.
- [66] Eisinger SH, Fiscella J, Bonfiglio T, Meldrum S, Fiscella K. Open-label study of ultra low-dose mifepristone for the treatment of uterine leiomyomata. *Eur J Obstet Gynecol Reprod Biol* 2009;146:215–8.
- [67] Tristan M, Orozco LJ, Steed A, Ramírez-Morera A, Stone P. Mifepristone for uterine fibroids. *Cochrane Database Syst Rev* 2012;8:CD007687.
- [68] Yerushalmi GM, Gilboa Y, Jakobson-Setton A, et al. Vaginal mifepristone for the treatment of symptomatic uterine leiomyomata: an open-label study. *Fertil Steril* 2014;101:496–500.
- [69] Wilkens J, Chwalisz K, Han C, et al. Effects of the selective progesterone receptor modulator asoprisnil on uterine artery blood flow, ovarian activity, and clinical symptoms in patients with uterine leiomyomata scheduled for hysterectomy. *J Clin Endocrinol Metab* 2008;93:4664–71.
- [70] Nieman LK, Blocker W, Nansel T, et al. Efficacy and tolerability of CDB-2914 treatment for symptomatic uterine fibroids: a randomized, double-blind, placebo-controlled, phase IIb study. *Fertil Steril* 2011;95:767–72, e1–e2.
- [71] Donnez J, Tatarchuk TF, Bouchard P, et al. Ulipristal acetate versus placebo for fibroid treatment before surgery. *N Engl J Med* 2012;366:409–20.
- [72] Donnez J, Tomaszewski J, Vázquez F, et al. Ulipristal acetate versus leuprolide acetate for uterine fibroids. *N Engl J Med* 2012;366:421–32.
- [73] Biglia N, Carinelli S, Maiorana A, D'Alonzo M, Lo Monte G, Marci R. Ulipristal acetate: a novel pharmacological approach for the treatment of uterine fibroids. *Drug Des Dev Ther* 2014;8:285–92.
- [74] Donnez J, Vázquez F, Tomaszewski J, et al. Long-term treatment of uterine fibroids with ulipristal acetate. *Fertil Steril* 2014;101:1565–73, e18.
- [75] Deng L, Wu T, Chen XY, Xie L, Yang J. Selective estrogen receptor modulators (SERMs) for uterine leiomyomas. *Cochrane Database Syst Rev* 2012;10:CD005287.
- [76] Varelas FK, Papanicolaou AN, Vavatsi-Christaki N, Makedos GA, Vlassis GD. The effect of anastrozole on symptomatic uterine leiomyomata. *Obstet Gynecol* 2007;110:643–9.
- [77] Parsanezhad ME, Azmoon M, Alborzi S, et al. A randomized, controlled clinical trial comparing the effects of aromatase inhibitor (letrozole) and gonadotropin-releasing hormone agonist (triptorelin) on uterine leiomyoma volume and hormonal status. *Fertil Steril* 2010;93:192–8.
- [78] Brito LG, Candido-dos-Reis FJ, Magario FA, Sabino-de-Freitas MM. Effect of the aromatase inhibitor anastrozole on uterine and leiomyoma Doppler blood flow in patients scheduled for hysterectomy: a pilot study. *Ultrasound Obstet Gynecol* 2012;40:119–20.

- [79] Song H, Lu D, Navaratnam K, Shi G. Aromatase inhibitors for uterine fibroids. *Cochrane Database Syst Rev* 2013;10:CD009505.
- [80] Hilario S, Bozzini N, Borsari R, Baracat E. Action of aromatase inhibitor for treatment of uterine leiomyoma in perimenopausal patients. *Fertil Steril* 2009;91:240–3.
- [81] Duhan N, Madaan S, Sen J. Role of the aromatase inhibitor letrozole in the management of uterine leiomyomas in premenopausal women. *Eur J Obstet Gynecol Reprod Biol* 2013;171:329–32.
- [82] Liu JP, Yang H, Xia Y, Cardini F. Herbal preparations for uterine fibroids. *Cochrane Database Syst Rev* 2013;4:CD005292.
- [83] Royal College of Obstetricians and Gynaecologists. Consent advice 4: abdominal hysterectomy for benign conditions. London: RCOG Press; 2009.
- [84] Sculpher M, Manca A, Abbott J, Fountain J, Mason S, Garry R. Cost effectiveness analysis of laparoscopic hysterectomy compared with standard hysterectomy: results from a randomised trial. *Br Med J* 2004;328:134.
- [85] Nieboer TE, Johnson N, Lethaby A, et al. Surgical approach to hysterectomy for benign gynaecological disease. *Cochrane Database Syst Rev* 2009;3:CD003677.
- [86] Lethaby A, Mukhopadhyay A, Naik R. Total versus subtotal hysterectomy for benign gynaecological conditions. *Cochrane Database Syst Rev* 2012;4:CD004993.
- [87] Manoucheri E, Fuchs-Weizman N, Cohen SL, Wang KC, Einarsson JI. MAUDE – analysis of robotic-assisted gynecologic surgery. *J Minim Invasive Gynecol* 2014. pii: S1553-4650(14)00027-2.
- [88] Kannisto P, Harter P, Heitz F, Traut A, du Bois A, Kurzeder C. Implementation of robot-assisted gynecologic surgery for patients with low and high BMI in a German gynecological cancer center. *Arch Gynecol Obstet* 2014;290:143–8.
- [89] O'Neill M, Moran PS, Teljeur C, et al. Robot-assisted hysterectomy compared to open and laparoscopic approaches: systematic review and meta-analysis. *Arch Gynecol Obstet* 2013;287:907–18.
- [90] Sawin SW, Pilevsky ND, Berlin JA, Barnhart KT. Comparability of perioperative morbidity between abdominal myomectomy and hysterectomy for women with uterine leiomyomas. *Am J Obstet Gynecol* 2000;183:1448–55.
- [91] Pundir J, Krishnan N, Siozos A, et al. Peri-operative morbidity associated with abdominal myomectomy for very large fibroid uteri. *Eur J Obstet Gynecol Reprod Biol* 2013;167:219–24.
- [92] Mettler L, Schollmeyer T, Lehmann-Willenbrock E, Dowaji J, Zavala A. Treatment of myomas by laparoscopic and laparotomic myomectomy and laparoscopic hysterectomy. *Min Invas Ther Allied Technol* 2004;13:58–64.
- [93] Jin C, Hu Y, Chen XC, et al. Laparoscopic versus open myomectomy – a meta-analysis of randomized controlled trials. *Eur J Obstet Gynecol Reprod Biol* 2009;145:14–21.
- [94] Kubinova K, Mara M, Horak P, Kuzel D, Dohnalova A. Reproduction after myomectomy: comparison of patients with and without second-look laparoscopy. *Minim Invasive Ther Allied Technol* 2012;21:118–24.
- [95] Soriano D, Desolle L, Poncelet C, Beniffa JL, Madelenat P, Darai E. Pregnancy outcome after laparoscopic and laparotomized myomectomy. *Eur J Obstet Gynecol Reprod Biol* 2003;108:194–8.
- [96] Hackethal A, Westermann A, Tchartchian G, et al. Laparoscopic myomectomy in patients with uterine myomas associated with infertility. *Minim Invasive Ther Allied Technol* 2011;20:338–45.
- [97] Paul PG, Koshy AK, Thomas T. Pregnancy outcomes following laparoscopic myomectomy and single-layer myometrial closure. *Hum Reprod* 2006;21:3278–81.
- [98] Banas T, Klimek M, Fugiel A, Skotniczny K. Spontaneous uterine rupture at 35 weeks' gestation, 3 years after laparoscopic myomectomy, without signs of fetal distress. *J Obstet Gynaecol Res* 2005;31:527–30.
- [99] Parker WH, Iacampo K, Long T. Uterine rupture after laparoscopic removal of a pedunculated myoma. *J Minim Invasive Gynecol* 2007;14:362–4.
- [100] Brucker SY, Hahn M, Kraemer D, Taran FA, Isaacson KB, Krämer B. Laparoscopic radiofrequency volumetric thermal ablation of fibroids versus laparoscopic myomectomy. *Int J Gynecol Obstet* 2014;125:261–5.
- [101] US Food and Drug Administration. Laparoscopic uterine power morcellation in hysterectomy and myomectomy: FDA safety communication; 2014. <http://www.fda.gov/medicaldevices/safety/alertsandnotices/ucm393576.htm> [accessed 05.06.14].
- [102] Advincula AP, Xu X, Goudeau 4th S, Ransom SB. Robot-assisted laparoscopic myomectomy versus abdominal myomectomy: a comparison of short-term surgical outcomes and immediate costs. *J Minim Invasive Gynecol* 2007;14:698–705.
- [103] Mansour FW, Kives S, Urbach DR, Lefebvre G. Robotically assisted laparoscopic myomectomy: a Canadian experience. *J Obstet Gynaecol Can* 2012;34:353–8.
- [104] Ranisavljevic N, Mercier G, Masia F, Mares P, De Tayrac R, Triopon G. Robot-assisted laparoscopic myomectomy: comparison with abdominal myomectomy. *J Gynecol Obstet Biol Reprod (Paris)* 2012;41:439–44.
- [105] Pitter MC, Gargiulo AR, Bonaventura LM, Lehman JS, Srouji SS. Pregnancy outcomes following robot-assisted myomectomy. *Hum Reprod* 2013;28:99–108.
- [106] Brady PC, Stanic AK, Styer AK. Uterine fibroids and subfertility: an update on the role of myomectomy. *Curr Opin Obstet Gynecol* 2013;25:255–9.
- [107] Casini ML, Rossi F, Agostini R, Unfer V. Effects of the position of fibroids on fertility. *Gynecol Endocrinol* 2006;22:106–9.
- [108] Bosteels J, Kasius J, Weyers S, Broekmans FJ, Mol BW, D'Hooghe TM. Hysterectomy for treating subfertility associated with suspected major uterine cavity abnormalities. *Cochrane Database Syst Rev* 2013;1:CD009461.
- [109] Helal A, Mashaly Ael-M, Amer T. Uterine artery occlusion for treatment of symptomatic uterine myomas. *JLSLS* 2010;14:386–90.
- [110] Chang WC, Huang PS, Wang PH, et al. Comparison of laparoscopic myomectomy using in situ morcellation with and without uterine artery ligation for treatment of symptomatic myomas. *J Minim Invasive Gynecol* 2012;19:715–21.
- [111] Vercellino G, Erdemoglu E, Joe A, et al. Laparoscopic temporary clipping of uterine artery during laparoscopic myomectomy. *Arch Gynecol Obstet* 2012;286:1181–6.
- [112] Akinola OI, Fabamwo AO, Akinola RA, Ottun TA, Akinniyi A, Akpan AE. Uterine artery ligation for the treatment of fibroids. *Acta Obstet Gynecol Scand* 2009;88:59–62.
- [113] Agdi M, Tulandi T. The benefits of intrauterine balloon: an intrauterine manipulator and balloon proved useful in myomectomy. *Am J Obstet Gynecol* 2008;199:581.e1.
- [114] Bhattacharya S, Middleton LJ, Tsourapas A, et al. Hysterectomy, endometrial ablation and Mirena® for heavy menstrual bleeding: a systematic review of clinical effectiveness and cost-effectiveness analysis. *Health Technol Assess* 2011;15:iii–xvi, 1–252.
- [115] Fergusson RJ, Lethaby A, Shepperd S, Farquhar C. Endometrial resection and ablation versus hysterectomy for heavy menstrual bleeding. *Cochrane Database Syst Rev* 2013;11:CD000329.
- [116] Kroft J, Liu G. First- versus second-generation endometrial ablation devices for treatment of menorrhagia: a systematic review, meta-analysis and appraisal of economic evaluations. *J Obstet Gynaecol Can* 2013;35:1010–9.
- [117] Tropeano G, Amoroso S, Scambia G. Non-surgical management of uterine fibroids. *Hum Reprod Update* 2008;14:259–74.
- [118] Wu O, Briggs A, Dutton S, et al. Uterine artery embolisation or hysterectomy for the treatment of symptomatic uterine fibroids: a cost-utility analysis of the HOPEFUL study. *BJOG* 2007;114:1352–62.
- [119] You JH, Sahota DS, Yuen PM. Uterine artery embolization, hysterectomy, or myomectomy for symptomatic uterine fibroids: a cost-utility analysis. *Fertil Steril* 2009;91:580–8.
- [120] Edwards RD, Moss JG, Lumsden MA, et al. Committee of the randomized trial of embolization versus surgical treatment for fibroids: uterine-artery embolization versus surgery for symptomatic uterine fibroids. *N Engl J Med* 2007;356:360–70.
- [121] Moss JG, Cooper KG, Khaund A, et al. Randomised comparison of uterine artery embolisation (UAE) with surgical treatment in patients with symptomatic uterine fibroids (REST trial): 5-year results. *BJOG* 2011;118:936–44.
- [122] Gupta JK, Sinha A, Lumsden MA, Hickey M. Uterine artery embolization for symptomatic uterine fibroids. *Cochrane Database Syst Rev* 2012;5:CD005073.
- [123] Hehenkamp WJ, Volkers NA, Broekmans FJ, et al. Loss of ovarian reserve after uterine artery embolization: a randomized comparison with hysterectomy. *Hum Reprod* 2007;22:1996–2005.
- [124] Payne JF, Robboy SJ, Haney AF. Embolic microspheres within ovarian arterial vasculature after uterine artery embolization. *Obstet Gynecol* 2002;100:883–6.
- [125] Ryu RK, Chrisman HB, Omary RA, et al. The vascular impact of uterine artery embolization: prospective sonographic assessment of ovarian arterial circulation. *J Vasc Interv Radiol* 2001;12:1071–4.
- [126] Kaump GR, Spies JB. The impact of uterine artery embolization on ovarian function. *J Vasc Interv Radiol* 2013;24:459–67.
- [127] Torre A, Paillusson B, Fain V, Labauge P, Pelage JP, Fauconnier A. Uterine artery embolization for severe symptomatic fibroids: effects on fertility and symptoms. *Hum Reprod* 2014;29:490–501.
- [128] Arthur R, Kachura J, Liu G, Chan C, Shapiro H. Laparoscopic myomectomy versus uterine artery embolization: long-term impact on markers of ovarian reserve. *J Obstet Gynaecol Can* 2014;36:240–7.
- [129] Yamagami T, Yoshimatsu R, Matsumoto T, et al. Fertility after uterine artery embolization: investigation using a sheep model. *Reprod Sci* 2010;17:350–7.
- [130] Smart OC, Hindley JT, Regan L, Gedroyc WG. Gonadotrophin-releasing hormone and magnetic-resonance-guided ultrasound surgery for uterine leiomyomata. *Obstet Gynecol* 2006;108:49–54.
- [131] Froeling V, Meckelburg K, Schreiter NF, et al. Outcome of uterine artery embolization versus MR-guided high-intensity focused ultrasound treatment for uterine fibroids: long-term results. *Eur J Radiol* 2013;82:2265–9.
- [132] Fröling V, Kröncke TJ, Schreiter NF, et al. Technical eligibility for treatment of magnetic resonance-guided focused ultrasound surgery. *Cardiovasc Intervent Radiol* 2014;37:445–50.
- [133] Zhang L, Chen WZ, Liu YJ, et al. Feasibility of magnetic resonance imaging-guided high intensity focused ultrasound therapy for ablating uterine fibroids in patients with bowel lies anterior to uterus. *Eur J Radiol* 2010;73:396–403.
- [134] Gizzo S, Saccardi C, Patrelli TS, et al. Magnetic resonance-guided focused ultrasound myomectomy: safety, efficacy, subsequent fertility and quality-of-life improvements. A systematic review. *Reprod Sci* 2014;21:465–76.
- [135] Wang W, Wang Y, Wang T, Wang J, Wang L, Tang J. Safety and efficacy of US-guided high-intensity focused ultrasound for treatment of submucosal fibroids. *Eur Radiol* 2012;22:2553–8.
- [136] Zhao WP, Chen JY, Zhang L, et al. Feasibility of ultrasound-guided high intensity focused ultrasound ablating uterine fibroids with hyperintense on T2-weighted MR imaging. *Eur J Radiol* 2013;82:e43–9.
- [137] Wang Y, Wang W, Ye H. Contrast-enhanced ultrasonography assessment of therapeutic efficacy for ultrasound-guided high-intensity focused ultrasound

- ablation of uterine fibroids: comparison with contrast-enhanced magnetic resonance. *J Med Ultrasound* 2014;22:22–8.
- [138] Garza-Leal JG, Toub D, Hernández León I, et al. Transcervical, intrauterine ultrasound-guided radiofrequency ablation of uterine fibroids with the Viz-Ablate System: safety, tolerability, and ablation results in a closed abdomen setting. *Gynecol Surg* 2011;8:327–34.
- [139] Bergamini V, Ghezzi F, Cromi A, et al. Laparoscopic radiofrequency thermal ablation: a new approach to symptomatic uterine myomas. *Am J Obstet Gynecol* 2005;192:768–73.
- [140] Garza-Leal JG, Hernandez Leon I, Castillo Saenz L, Lee BB. Laparoscopic ultrasound-guided radiofrequency volumetric thermal ablation of symptomatic uterine leiomyomas: feasibility study using the Halt 2000 Ablation System. *J Minim Invasive Gynecol* 2011;18:364–71.
- [141] Robles R, Aguirre VA, Argueta AI, Guerrero MR. Laparoscopic radiofrequency volumetric thermal ablation of uterine myomas with 12 months of follow-up. *Int J Gynaecol Obstet* 2013;120:65–9.
- [142] Chudnoff SG, Berman JM, Levine DJ, Harris M, Guido RS, Banks E. Outpatient procedure for the treatment and relief of symptomatic uterine myomas. *Obstet Gynecol* 2013;121:1075–82.
- [143] Colacurci N, De Franciscis P, Cobellis L, Nazzaro G, De Placido G. Effects of hormone replacement therapy on postmenopausal uterine myoma. *Maturitas* 2000;35:167–73.
- [144] Yang CH, Lee JN, Hsu SC, Kuo CH, Tsai EM. Effect of hormone replacement therapy on uterine fibroids in postmenopausal women – a 3-year study. *Maturitas* 2002;43:35–9.
- [145] Hendrickson MR, Tavassoli FA, Kempson RL, et al. Mesenchymal tumours and related lesions. In: Tavassoli FA, Devilee P, editors. *Pathology and genetics of tumours of the breast and female genital organs*. Lyon, France: IARC Press; 2003. p. 233–44.
- [146] Namimoto T, Yamashita Y, Awai K, et al. Combined use of T2-weighted and diffusion-weighted 3-T MR imaging for differentiating uterine sarcomas from benign leiomyomas. *Eur Radiol* 2009;19:2756–64.
- [147] Thomassin-Naggara I, Dechoux S, Bonneau C, et al. How to differentiate benign from malignant myometrial tumours using MR imaging. *Eur Radiol* 2013;23:2306–14.
- [148] Davidson B, Abeler VM, Førsund M, et al. Gene expression signatures of primary and metastatic uterine leiomyosarcoma. *Hum Pathol* 2014;45:691–700.
- [149] Lehtonen HJ. Hereditary leiomyomatosis and renal cell cancer: update on clinical and molecular characteristics. *Fam Cancer* 2011;10:397–411.
- [150] Chourmouzi D, Papadopoulou E, Drevelegas A. Magnetic resonance imaging findings in pseudo-Meigs' syndrome associated with a large uterine leiomyoma: a case report. *J Med Case Rep* 2010;4:120.