

Management of borderline ovarian tumours

Pallavi Bagade MRCOG,^a Richard Edmondson MD,^{b,*} Anitha Nayar FRCPath^c

^aSpecialty Trainee, Northern Gynaecological Oncology Centre, Queen Elizabeth Hospital, Sheriff Hill, Gateshead NE9 6SX, UK

^bConsultant and Senior Lecturer in Gynaecological Oncology, Northern Gynaecological Oncology Centre, Gateshead, UK

^cConsultant Pathologist, Department of Pathology, Queen Elizabeth Hospital Woolwich, Stadium Road, London SE18 4QH, UK

*Correspondence: Richard Edmondson. Email: richard.edmondson@ncl.ac.uk

Key content

- Borderline ovarian tumours are a heterogeneous group of tumours often seen in younger women.
- Many are only diagnosed after primary surgery has already taken place for a presumed benign lesion.
- The subsequent management often causes confusion.
- Complete surgical staging is the cornerstone of management, but conservative surgery is an acceptable alternative in those keen to retain their fertility.
- The role of long-term follow-up is controversial.

Learning objectives

- To gain an overview of the pathology and biology of borderline ovarian tumours.

- To understand the principles of surgical management in young women and the importance of a multidisciplinary team approach.
- To appreciate the value of following up these women.

Ethical issues

- Can we reduce the morbidity of radical surgery in a young woman wishing to retain her fertility?
- Is a more conservative approach a safe alternative regarding cancer prognosis?

Keywords fertility-sparing surgery / invasive implants / laparoscopy / salpingo-oophorectomy / surgical staging / tumour markers

Please cite this paper as: Bagade P, Edmondson R, Nayar A. Management of borderline ovarian tumours. *The Obstetrician & Gynaecologist* 2012;14:115–120.

Introduction

Borderline ovarian tumours are a distinct pathological group of neoplasms that demonstrate higher proliferative activity when compared with benign neoplasms, but which do not show stromal invasion.¹ Also known as tumours of low malignant potential, they were first described by Taylor² and constitute 10–15% of all epithelial ovarian neoplasms.³

They are typically seen in a younger age group than their invasive counterparts and are often diagnosed at an earlier stage, resulting in an excellent prognosis. Survival rates are better than those for women with frankly malignant ovarian tumours.⁴ The 5-year survival rates for stage I borderline ovarian tumours vary from 95–97%. Even women with stage III disease have a good prognosis, with survival rates of 50–86%. The 10-year survival rates range from 70–80%, owing to late recurrence.⁵

Conversely, these figures demonstrate that some women do succumb to their disease and it is thus critical to ensure that cases are managed correctly. Factors such as the heterogeneity of tumour types, the age and fertility of the woman and the stage at presentation can render decision making regarding further treatment complex and confusing. In this article we present some of the background data and a practical management strategy.

Risk factors

Many studies of the epidemiology of ovarian cancer have combined borderline ovarian tumours and invasive carcinomas. Younger women are more likely to have borderline tumours compared with older women.⁶ Parous women have a reduced risk of developing borderline ovarian tumours compared with nulliparous women. Lactation is found to be protective. These risk factors are similar to those recognised for invasive ovarian cancer.⁷

However, unlike invasive ovarian cancer, oral contraceptive use is not protective against the development of borderline ovarian tumours. It has been suggested that this finding may support the concept that borderline tumours represent a disease that is distinct from invasive ovarian cancer.⁷ Furthermore, there is no evidence that women with mutations of the *BRCA* genes, which clearly predispose to invasive cancers, are at increased risk for the development of borderline ovarian tumours.⁸

It is now clear from molecular studies that there are at least two distinct forms of ovarian cancer. High-grade serous cancers, which are associated with very high rates of *p53* mutation, are the most common form of invasive neoplasm. Low-grade tumours, which include borderline ovarian tumours, are characterised by mutations of the

BRAF/KRAS pathway.⁹ It is thus clear that there is no progression from one type to the other and that, although borderline ovarian tumours can progress to invasive disease, this tends to be the low-grade invasive phenotype rather than the high grade.

Histological features

Serous borderline ovarian tumours are the most common histological type (50%) and are bilateral in 30% of cases (Figure 1). They can be associated with extra-ovarian lesions (also called implants), which can be invasive or non-invasive, as shown by their microscopic appearance.¹⁰

Mucinous borderline ovarian tumours (46%) are further classified into intestinal (85%) and endocervical/müllerian types (15%), depending on the nature of the lining (Figure 2). They are associated with peritoneal pseudomyxoma in 10% of cases and can be indistinguishable clinically

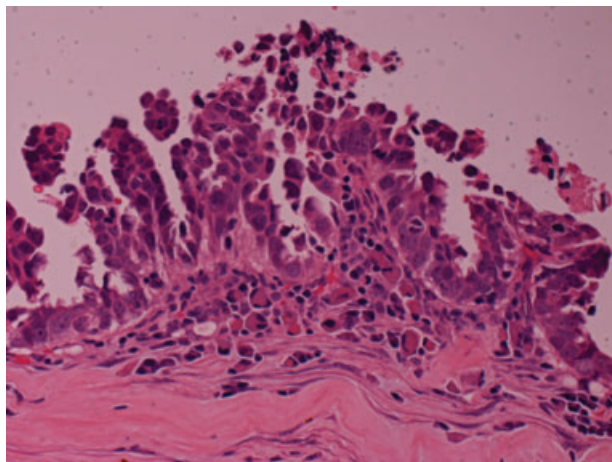


Figure 1. Serous borderline ovarian tumour

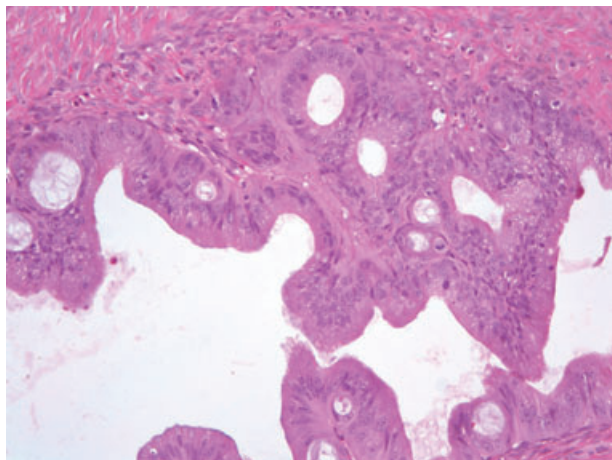


Figure 2. Mucinous borderline ovarian tumour

Box 1. Histological classification of borderline ovarian tumours

Serous	50%
• micropapillary	
• microinvasive	
Mucinous	46%
• intestinal	
• endocervical/müllerian	
Endometrioid, clear cell, Brenner and mixed	4%

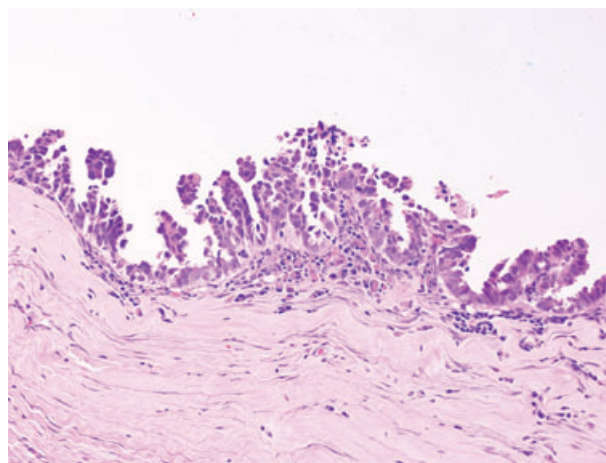


Figure 3. Histological features of borderline ovarian tumours: nuclear stratification and hyperchromasia, prominent nucleoli and the presence of mitotic figures. Stromal invasion is absent

from primary appendiceal tumours, necessitating a thorough investigation of the gastrointestinal tract with special attention to the appendix.^{10,11} These tumours are known to have a complex architecture and the presence of cytological atypia is enough to classify a mucinous tumour as a carcinoma even without evidence of destructive stromal invasion. Extensive sampling from the tumour is, therefore, recommended.

The mixed, endometrioid, clear cell and Brenner varieties of borderline ovarian tumour are relatively rare (4%) (Box 1).¹²

Histological features are defined by epithelial cellular proliferation greater than that seen in benign tumours (Figure 3). Borderline ovarian tumours have a stratified epithelium with varying degrees of nuclear atypia and increased mitotic activity; their lack of stromal invasion distinguishes them from invasive carcinomas.¹³

Diagnosis

Determining preoperatively whether a pelvic mass represents benign or malignant disease is difficult. Borderline ovarian tumours are more likely to be asymptomatic and to be diagnosed as an incidental finding or at routine examination. Among those who report symptoms, women with borderline

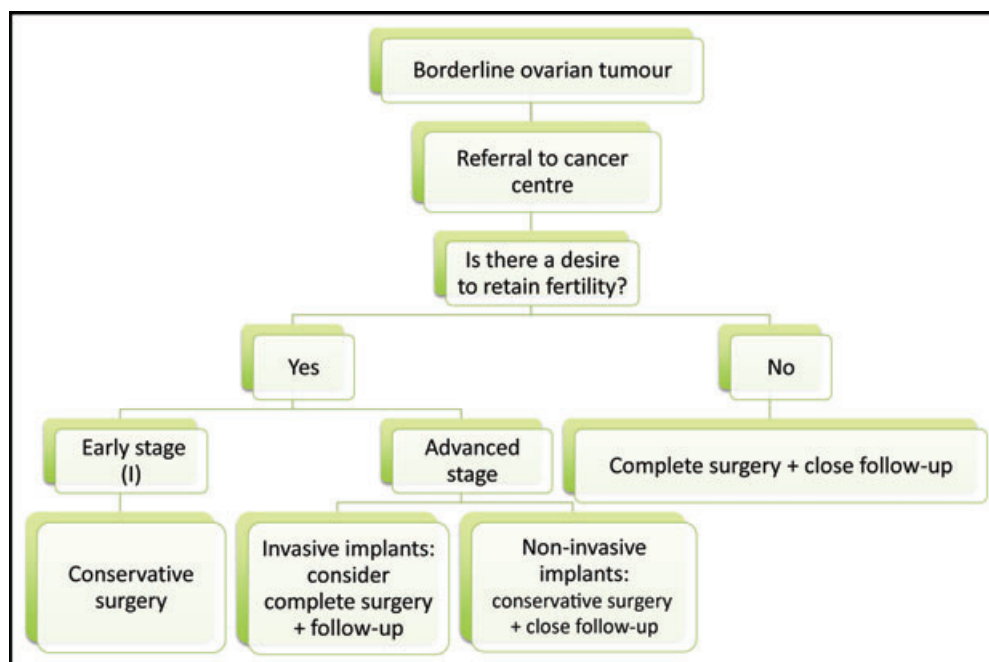


Figure 4. Management of borderline ovarian tumours

ovarian tumours have a longer duration of symptoms compared with women with invasive tumours.¹⁴ As with any other adnexal mass, there may be complaints of pelvic pain, bloating, dyspareunia, menstrual irregularities and pressure symptoms such as frequency of micturition and constipation.

Serum CA125 levels may be raised: one study¹⁵ demonstrated a high level of this tumour marker in 75% of serous and 30% of mucinous borderline ovarian tumours. Serum CA19-9 levels are frequently raised in mucinous borderline ovarian tumours. Other tumour markers such as CEA, CA15-3 and CA72-4 may help detection but are not specific and may be within normal limits or only minimally elevated in a fair proportion of cases.¹⁶ Many borderline ovarian tumours occur in younger, premenopausal women, therefore the risk of malignancy index, which uses menopausal status, is often low.¹⁷

Transvaginal ultrasound, which is commonly used to assess ovarian pathology, provides information regarding cyst diameter, thickness and regularity of cyst wall, complexity (solid areas, septa, intracystic papillary projections) and presence of ascites. Colour Doppler investigation demonstrates intracystic blood flow and is sensitive in differentiating malignancies from benign tumours.¹⁸ A wide variety of appearances, ranging from unilocular cysts, minimally septate cysts with papillary projections and markedly septate lesions with plaque-like excrescences to solid lesions with exophytic papillary projections, can be demonstrated on magnetic resonance imaging (MRI). Information acquired from MRI, including presence of peritoneal and extra-ovarian lesions, can aid management strategies and surgical

planning in those women being considered for conservative surgery.¹⁹

Management

Management of borderline ovarian tumours is individualised and depends on the age of the woman, the stage of the disease, the potential desire for pregnancy and the nature of the peritoneal implants (Figure 4). Standard management is similar to that of invasive ovarian cancer: namely, accurate staging and cytoreductive surgery where appropriate. Where possible, ovarian tumours should be subjected to frozen section analysis. The diagnosis can sometimes be difficult, however, because of the heterogeneity of appearance, particularly in large tumours and those of mucinous variety; this makes the accuracy of frozen section analysis in the diagnosis of borderline ovarian tumours relatively low.²⁰

If the frozen section is reported as borderline, for the older woman with no fertility concerns a complete staging should be undertaken, which should include:

- exploration of the entire abdominal cavity with peritoneal washings
- total abdominal hysterectomy
- bilateral salpingo-oophorectomy and infracolic omentectomy
- appendectomy in the case of mucinous tumours.

Approximately one-third of cases reported as borderline at frozen section are later reclassified as invasive tumours.

Although no survival benefit has been shown with lymphadenectomy in borderline ovarian tumours, to ensure that such cases of invasive disease are fully staged, lymphadenectomy should be considered.²⁰

When a borderline tumour is diagnosed on histology after primary surgery, a referral to the regional cancer centre followed by discussion at the local multidisciplinary team meeting may be useful; this is our practice in the North of England Cancer Network. Further management is planned according to the histology, grade, stage, DNA ploidy status, fertility preferences and completeness of primary surgery.

The role of restaging and completion surgery

There is no consensus regarding which cases need restaging or completion surgery. Overall, survival and recurrence rates do not appear to differ between women with borderline tumours who have undergone restaging compared to those who have not, but in part this may be related to the overall good prognosis of this disease — which means that demonstrating survival differences is difficult. A case-by-case approach, taking into account the adequacy of the initial surgery, must be followed.^{21,22} The decision to undertake further surgery will largely be determined by three factors: the histological subtype of borderline ovarian tumour, the completeness of the primary surgery and the fertility desires of the woman.

The risk of recurrence as invasive disease is significantly higher in borderline ovarian tumours with invasive implants compared with those with non-invasive implants (31% versus 21% over 5 years).²³ The presence of DNA aneuploidy is an independent risk factor associated with a 19-fold increase in the subsequent risk of dying when compared with diploid tumours.²⁴ Restaging may be warranted for women with micropapillary tumours, invasive implants or DNA aneuploidy and those with no fertility concerns.

There is less justification for further surgery for a woman who has undergone full laparotomy with inspection of all surfaces at primary surgery compared with a woman who has undergone only limited assessment. Hence, assessment of the contralateral ovary, omentum and peritoneal surfaces at primary surgery is helpful.

Restaging surgery should include peritoneal washings, omentectomy and complete examination of the peritoneum with/without hysterectomy and removal of the contralateral ovary (depending upon fertility desires). There appears to be no benefit to lymphadenectomy in this setting.²⁵

The role of conservative surgery and subsequent fertility

Because borderline ovarian tumours are more likely to develop in younger women, fertility is frequently an issue when discussing treatment options. Conservative surgery is an acceptable alternative for those women with early-stage disease

who are keen to retain their fertility. Careful counselling regarding the risk of recurrence and subsequent fertility is essential.

Conservative surgery is defined as surgery with complete staging but with preservation of the uterus and at least a part of one ovary to preserve fertility. The two common options are cystectomy and unilateral salpingo-oophorectomy, with/without infracolic omentectomy and peritoneal washings. Systematic biopsies of a macroscopically normal contralateral ovary are not recommended because they do not exclude recurrent disease, they yield no abnormal histological findings and they interfere with fertility further as a result of adhesions.^{25,26} Morbidity may also be reduced by less radical surgery, but clearly this must not be at the expense of safety with regard to cancer prognosis.

Relapse rates are higher after cystectomy (12–58%) and salpingo-oophorectomy (0–20%) compared with radical surgery (2.5–5.7%); there may be late recurrences, and the importance of careful, long-term follow-up needs to be stressed.¹¹ However, most recurrent disease is of the borderline type, which is easily resectable and associated with an excellent prognosis.²⁷

Several reports^{26,28,29} have been published regarding fertility outcomes after treatment of borderline ovarian tumours. They suggest no adverse effect of pregnancy on the disease or vice versa. Spontaneous fertility rates reported in literature vary between 32–65%, with nearly half of the women treated conservatively conceiving spontaneously.²⁴

Some small studies have demonstrated that the recurrence rate of borderline ovarian tumours following fertility treatment (ovulation stimulation with clomiphene citrate, in vitro fertilisation) varies from 13–29%. However, the recurrences were probably more a result of the conservative nature of surgery than of the fertility drugs. Most authors advise limitation of the number of stimulation cycles and treatment only of women with stage I disease.^{6,30,31}

The need for removal of the remaining ovary and uterus once the family is complete is debatable. Because recurrence is usually easily resectable, with borderline histology, one could recommend waiting until recurrence develops to perform any radical surgery. However, because of psychological stress, some women will choose to have definitive treatment upon completion of their family.^{11,12}

The role of laparoscopy

Increasing use of laparoscopy in oncology has led to a change in the surgical approach for borderline tumours, but there are concerns regarding the possibilities of cyst rupture, development of port-site metastases and understaging of disease; higher risk of recurrence and worsened survival have been documented.^{11,32,33} In the absence of clear evidence to the contrary, staging and treatment of borderline ovarian tumours should ideally be performed by midline laparotomy.

The role of chemotherapy

No role for adjuvant chemotherapy has been demonstrated for borderline ovarian tumours and there are no relevant clinical trials. Consideration may be given to chemotherapy in the setting of recurrent borderline ovarian tumour that is not amenable to surgical resection, particularly as undiagnosed invasive disease cannot be excluded in this situation.

Suggested follow-up

The risk of recurrence varies between 0–58%, depending upon the histological type of borderline ovarian tumour and extent of primary surgery. Published evidence^{11,12} suggests that the incidence of invasive disease at recurrence varies from 8–73%. For women treated with conservative surgery, clinical examination and vaginal ultrasound have been shown to benefit the detection of recurrent disease.³⁴ Currently, we follow up every 3 months for the first 2 years, every 6 months for the next 2 years and annually thereafter.

Conclusion

Borderline ovarian tumours are a separate entity among ovarian tumours, characterised by a degree of cellular proliferation and nuclear atypia in the absence of stromal invasion. They are commonly seen in younger women and have an excellent prognosis. The cornerstone of management is complete staging. In early-stage disease, fertility-sparing surgery can be performed without affecting overall survival. When a borderline ovarian tumour is diagnosed after primary surgery for presumed benign disease, histological review and discussion in a multidisciplinary team meeting with specialist input from a gynaecological oncologist are recommended to ensure best management.

References

- Ovarian Tumour Panel RCOG. Ovarian epithelial tumours of borderline malignancy: pathological features and current status. *Br J Obstet Gynaecol* 1983;**90**:743–50 [http://dx.doi.org/10.1111/j.1471-0528.1983.tb09305.x].
- Taylor HC. Malignant and semi-malignant tumours of the ovary. *Surg Gynecol Obstet* 1929;**48**:204–30.
- FIGO. International Federation of Gynecology and Obstetrics classification and staging of malignant tumours in the female pelvis. *Acta Obstet Gynecol Scand* 1971;**50**:1–7.
- Zanetta G, Rota S, Chiari S, Bonazzi C, Bratina G, Mangioni C. Behavior of borderline tumors with particular interest to persistence, recurrence, and progression to invasive carcinoma: a prospective study. *J Clin Oncol* 2001;**19**:2658–64.
- Barnhill DR, Kurman RJ, Brady MF, Omura GA, Yordan E, Given FT, Kucera PR, et al. Preliminary analysis of behavior of stage I ovarian serous tumors of low malignant potential: a Gynaecologic Oncology Group study. *J Clin Oncol* 1995;**13**:2752–6.
- Modugno F, Ness RB, Wheeler JE. Reproductive risk factors for epithelial ovarian cancer according to histologic type and invasiveness. *Ann Epidemiol* 2001;**11**:568–74 [http://dx.doi.org/10.1016/S1047-2797(01)00213-7].
- Riman T, Dickman PW, Nilsson S, Correia N, Nordlinder H, Magnusson CM, et al. Risk factors for epithelial borderline ovarian tumors: results of a Swedish case-control study. *Gynecol Oncol* 2001;**83**:575–85 [http://dx.doi.org/10.1006/gyno.2001.6451].
- Cass I, Baldwin RL, Varkey T, Moslehi R, Narod SA, Karlan BY. Improved survival in women with BRCA-associated ovarian carcinoma. *Cancer* 2003;**97**:2187–95 [http://dx.doi.org/10.1002/cncr.11310].
- Köbel M, Kalloger SE, Boyd N, McKinney S, Mehl E, Palmer C, et al. Ovarian carcinoma subtypes are different diseases: implications for biomarker studies. *PLoS Med* 2008;**5**:232 [http://dx.doi.org/10.1371/journal.pmed.0050232].
- Tinelli R, Tinelli A, Tinelli FG, Cicinelli E, Malvasi A. Conservative surgery for borderline ovarian tumors: a review. *Gynecol Oncol* 2006;**100**:185–91 [http://dx.doi.org/10.1016/j.ygyno.2005.09.021].
- Cadron I, Amant F, Van Gorp T, Neven P, Leunen K, Vergote I. The management of borderline tumours of the ovary. *Curr Opin Oncol* 2006;**18**:488–93 [http://dx.doi.org/10.1097/01.cco.0000239889.98289.ce].
- Cadron I, Leunen K, Van Gorp T, Amant F, Neven P, Vergote I. Management of borderline ovarian neoplasms. *J Clin Oncol* 2007;**25**:2928–37 [http://dx.doi.org/10.1200/JCO.2007.10.8076].
- Hart WR, Norris HJ. Borderline and malignant mucinous tumours of the ovary. Histologic criteria and clinical behavior. *Cancer* 1973;**31**:1031–45 [http://dx.doi.org/10.1002/1097-0142(197305)31:5<1031::AID-CNCR2820310501>3.0.CO;2-7].
- Vine MF, Ness RB, Calingaert B, Schildkraut JM, Berchuck A. Types and duration of symptoms prior to diagnosis of invasive or borderline ovarian tumor. *Gynecol Oncol* 2001;**83**:466–71 [http://dx.doi.org/10.1006/gyno.2001.6411].
- Gotlieb WH, Soriano D, Achiron R, Zalel Y, Davidson B, Kopolovic J, et al. CA125 and ultrasonography in borderline ovarian tumors of the ovary. *Am J Obstet Gynecol* 2000;**183**:541–6 [http://dx.doi.org/10.1067/mob.2000.105940].
- Schutter EM, Davelaar EM, van Kamp GJ, Verstraeten RA, Kenemans P, Verheijen RH. The differential diagnostic potential of a panel of tumour markers (CA125, CA15-3 and CA72-4 antigens) in patients with a pelvic mass. *Am J Obstet Gynecol* 2002;**187**:385–92 [http://dx.doi.org/10.1067/mob.2002.123768].
- Tingulstad S, Hagen B, Skjeldestad FE, Onsrud M, Kiserud T, Halvorsen T, et al. Evaluation of a risk of malignancy index based on serum Ca125, ultrasound findings and menopausal status in the pre-operative diagnosis of pelvic masses. *Br J Obstet Gynaecol* 1996;**103**:826–31 [http://dx.doi.org/10.1111/j.1471-0528.1996.tb09882.x].
- Zanetta G, Vergani P, Lissoni A. Colour Doppler ultrasound in the preoperative assessment of adnexal masses. *Acta Obstet Gynecol Scand* 1994;**73**:637–41 [http://dx.doi.org/10.3109/00016349409013458].
- Bent CL, Sahdev A, Rockall AG, Singh N, Sohaib SA, Reznick RH. MRI appearances of borderline ovarian tumours. *Clin Radiol* 2009;**64**:430–8 [http://dx.doi.org/10.1016/j.crad.2008.09.011].
- Naik R, Cross P, Lopes A, Godfrey K, Hatem MH. 'True' versus 'apparent' stage I epithelial ovarian cancer: value of frozen section analysis. *Int J Gynecol Cancer* 2006;**16**:41–6 [http://dx.doi.org/10.1111/j.1525-1438.2006.00312.x].
- Winter WE III, Kucera PR, Rodgers W, McBroom JW, Olsen C, Maxwell GL. Surgical staging in patients with ovarian tumors of low malignant potential. *Obstet Gynecol* 2002;**100**:671–6 [http://dx.doi.org/10.1016/S0029-7844(02)02171-3].
- Fauvet R, Boccaro J, Dufournet C, David-Montefiore E, Poncelet C, Darai E. Restaging surgery for women with borderline ovarian tumors: Results of a French multicenter study. *Cancer* 2004;**100**:1145–51 [http://dx.doi.org/10.1002/cncr.20098].
- Morice P, Camatte S, Rey A, Atallah D, Lhomme C, Pautier P, Pomel C, et al. Prognostic factors for patients with advanced stage serous borderline tumours of the ovary. *Ann Oncol* 2003;**14**:592–8 [http://dx.doi.org/10.1093/annonc/mdg173].

- 24 Kaern J, Trope C, Kristensen G. DNA ploidy: the most important prognostic factor in patients with borderline tumors of the ovary. *Int J Gynecol Cancer* 1993;**3**:349–58.
- 25 Camatte S, Morice P, Thoury A, Fourchotte V, Pautier P, Lhomme C, et al. Impact of surgical staging in patients with macroscopic 'stage I' ovarian borderline tumours: analysis of a continuous series of 101 cases. *Eur J Cancer* 2004;**40**:1842–9 [http://dx.doi.org/10.1016/j.ejca.2004.04.017].
- 26 Morice P, Camatte S, El Hassan J, Pautier P, Duvillard P, Castaigne D. Clinical outcomes and fertility after conservative treatment of ovarian borderline tumors. *Fertil Steril* 2001;**75**:92–6 [http://dx.doi.org/10.1016/S0015-0282(00)01633-2].
- 27 Morice P. Borderline tumours of the ovary and fertility. *Eur J Cancer* 2006;**42**:149–58 [http://dx.doi.org/10.1016/j.ejca.2005.07.029].
- 28 Gotlieb WH, Flikker S, Davidson B, Korach Y, Kopolovic J, Ben-Baruch G. Borderline tumors of the ovary: Fertility treatment, conservative management and pregnancy outcome. *Cancer* 1998;**82**:141–6 [http://dx.doi.org/10.1002/(SICI)1097-0142(19980101)82:1<141::AID-CNCR17>3.0.CO;2-2].
- 29 Marcickiewicz J, Brannstrom M. Fertility preserving surgical treatment of borderline ovarian tumour: long-term consequences for fertility and recurrence. *Acta Obstet Gynecol Scand* 2006;**85**:1496–500 [http://dx.doi.org/10.1080/00016340600984712].
- 30 Beiner ME, Gotlieb WH, Davidson B, Kopolovic J, Ben-Baruch G. Infertility treatment after conservative management of borderline ovarian tumors. *Cancer* 2001;**92**:320–5 [http://dx.doi.org/10.1002/1097-0142(20010715)92:2<320::AID-CNCR1325>3.0.CO;2-G].
- 31 Fortin A, Morice P, Thoury A, Camatte S, Dhainaut C, Madelenat P. Impact of infertility drugs after treatment of borderline ovarian tumors: results of a retrospective multicenter study. *Fertil Steril* 2007;**87**:591–6 [http://dx.doi.org/10.1016/j.fertnstert.2006.07.1503].
- 32 Camatte S, Morice P, Atallah D, Thoury A, Pautier P, Lhomme C, Duvillard P, et al. Clinical outcome after laparoscopic pure management of borderline ovarian tumors: Results of a series of 34 patients. *Ann Oncol* 2004;**15**:605–9 [http://dx.doi.org/10.1093/annonc/mdh149].
- 33 Vandenput I, Amant F, Vergote I. Peritoneal recurrences might be less common in advanced stage serous borderline ovarian tumors that were treated by laparotomy. *Gynecol Oncol* 2005;**98**:523–5 [http://dx.doi.org/10.1016/j.ygyno.2005.05.037].
- 34 Zanetta G, Rota S, Lissoni A, Meni A, Brancatelli G, Buda A. Ultrasound, physical examination, and CA125 measurement for the detection of recurrence after conservative surgery for early borderline ovarian tumors. *Gynecol Oncol* 2001;**81**:63–6 [http://dx.doi.org/10.1006/gyno.2000.6099].