

TREATMENT OF UTERINE ANOMALIES AND REPRODUCTIVE OUTCOME

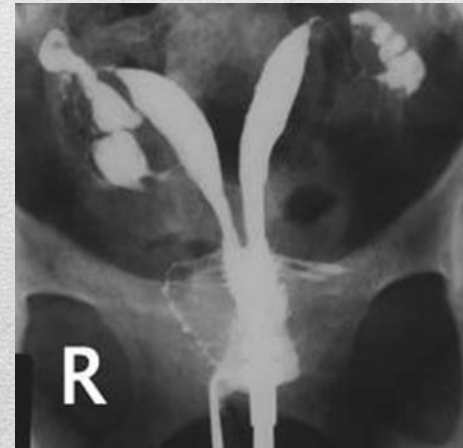Danie Botha

The Dalmeyer Fertility Unit

Port Elizabeth

SASOG 2014

- Uterine anomalies are any abnormality of the uterus that may result from defective formation or the development of uterine pathology that may interfere with the function of the uterus.
- Uterine anomalies are associated with primary amenorrhoea, dysmenorrhoea, infertility, recurrent early pregnancy loss, premature delivery and abruptio placentae.
- The abnormalities of the uterus can be described as **congenital** or **acquired**.



Introduction

Acquired
anomalies



Congenital
anomalies

Conclusion

Presentation

Should these anomalies be treated?

When should it be treated?

By whom should it be treated?

Overview

Adenomyosis

Intrauterine synechiae
and Asherman syndrome

Endometrial polyps

Uterine leiomyomas

(Cervical pathology)

Acquired anomalies

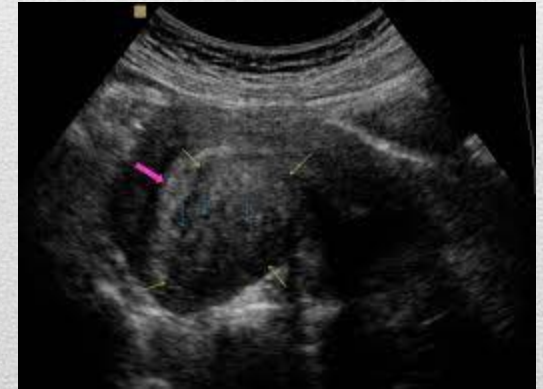
Clinical presentation

Since its diagnosis by TVUS and MRI became possible, adenomyosis is being encountered frequently during the diagnostic workup for infertility and present evidence suggests that adenomyosis has a negative impact on female fertility. The incidence of adenomyosis is believed to increase with age and patients may present with increasing dysmenorrhea and dyspareunia. ³

The association with infertility may therefore be linked to women delaying childbearing. ⁴

3. Molitor JJ.1971. Adenomyosis: A clinical and pathological appraisal . AJOG 110: 275-284

4. Devlieger et al 2003. Uterine adenomyosis in the infertility clinic .Hum Rep Update 9: 139-147



Adenomyosis

Treatment

Absence of data and RCT'S to demonstrate possible effect of surgery on miscarriage rates.

No direct data addressing RPL and adenomyosis.

Assumption of association and effect based on IVF outcome, no direct evidence.

Level of evidence: C- Recommendations are based primarily on consensus and expert opinion

Adenomyosis

Treatment

Adenomyosis may co exist with other pelvic pathology such as endometriosis or fibroids. Careful preoperative assessment should be performed before definitive treatment is offered.

- **1.Hysteroscopic resection** of adenomatous polyps (1.3% of all endometrial polyps)
- **2.Laparoscopic electrocoagulation:** Described in 1998 (Wood)⁵, involves the insertion of a monopolar needle electrode into affected myometrium at approx 1-2 cm intervals. Coagulation with a 50- W current to depth of 3-25 mm results in necrosis and shrinkage of treated myometrium.
- Not suitable for women who wants to conceive due to risk of uterine rupture as early as 12 weeks gestation due to myometrium strenght impairment following normal myometrium being replaced by scar tissue.

- 5. Wood C. Surgical and medical treatment of adenomyosis .Hum Reprod Update 1998; 4: 323-336

Adenomyosis

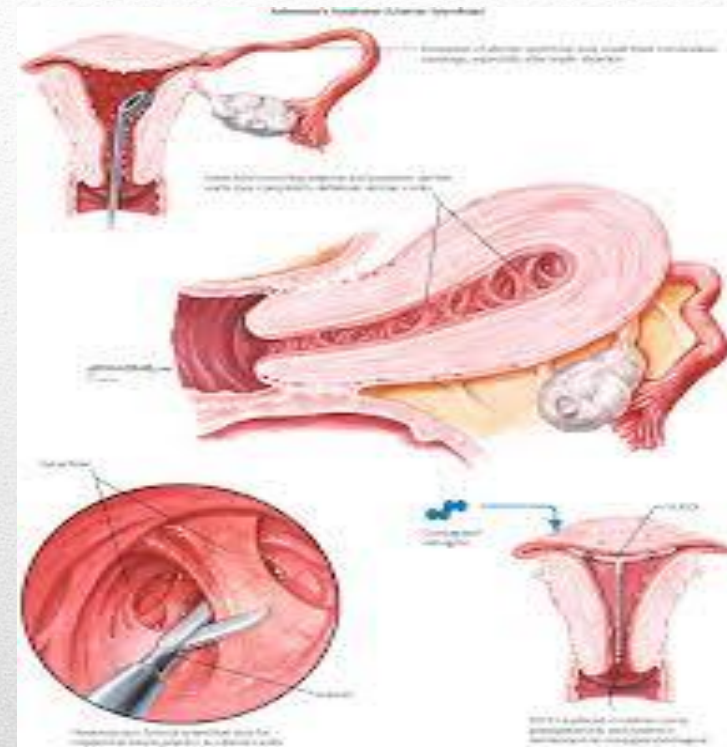
- **3.Excisional surgery:** Adenomyomectomy. Possible inadvertent removal of excess myometrial tissue due to unclear demarcation from surrounding normal myometrium.
- **Laparoscopic route** has drawbacks due to inability to palpate uterus, achieving haemostasis may be difficult. Open laparotomy remains the mainstay of extensive disease.
- **Transvers H technique:** (Fujishita et al. 2004). ⁶
- Biggest challenge with cytoreductive surgery is to avoid intraoperative complications and long term reduced uterine capacity and scarring.
- **Triple flap method** for reconstruction of uterus. Bisection of uterus with coring of tissue up to 1cm. Serosa removed and uterus closed . Good pregnancy rate (61%) with only 2 patients having had miscarriages (n=104.) Osada et al. ⁷

- 6. Fujishita A, Masuzaki H, Khan KN et al. Modified reduction surgery for adenomyosis. Gynecol Obsts Invest 2004; 57; 132–138
- 7 Osada H, Silber S, Kakinuma T, et al. Surgical procedure to conserve the uterus for future pregnancy inpatients suffering from massive adenomyosis. Reprod Biomed Online 2011; 22: 94–99

Adenomyosis

AAGL Definition:

- Synechiae: The presence of Intrauterine adhesions in the absence of symptoms (pain/menstrual disturbance/subfertility)
- Asherman syndrome: A constellation of symptoms and signs.



Intrauterine Synechiae

Clinical presentation

- Patients presents with secondary amenorrhea or decreased menstrual flow following iatrogenic surgical intervention (D&C) or post surgical/ radiological endometritis.
- Ultrasound findings are that of a thin, irregular endometrium with fluid spaces if incomplete, HSG can appear as filling defects that distorts the contour of the uterine cavity
- Diagnosis confirmed with hysteroscopy

Intra uterine synechiae

Treatment

Practice Guidelines for Management of Intrauterine Synechiae. 8 AAGL PRACTISE REPORT

- Surgery is the criterion standard in the management of Asherman syndrome and there is no role for medical management alone.
- No evidence to support the use of **blind cervical probing**. [Level C]
- No evidence to support **dilatation and curettage**. [Level C]
- **Hysteroscopic guidance** is the treatment of choice for symptomatic IUAs [Level C]
- In extensive disease, surgery should be performed by an experienced hysteroscopic surgeon. [Level C]

8.. J Minimal Inv Gynecol, Vol 17, No 1, Jan/Feb 2010



Intra uterine synechiae

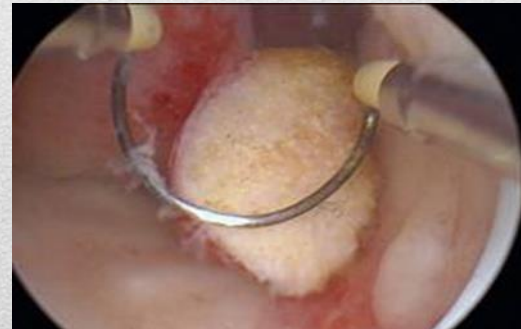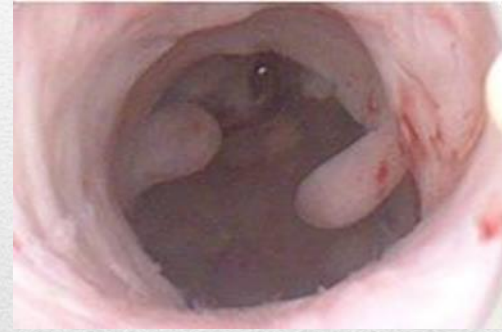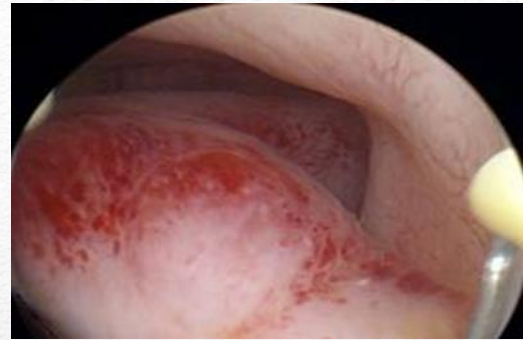
- Hysteroscopic guidance by external imaging/laparoscopy does not reduce perforations or improve outcome. [Level B]
- Laparotomy should be reserved as last resort. [Grade C]
- Because of the suppressive /inflammatory effect on the endometrium , neither LNG IUS nor Copper or T-shaped IUDs should be used after surgical division of intrauterine adhesions. [Grade C]
- There are limited data supporting a benefit for using a Foley catheter or an IUD after surgical lysis. Should not be used outside of clinical trials. [Grade C]
- Barriers such as hyaluronic acid and gel seem to reduce the risk of adhesion recurrence and may be of use. For now, post treatment pregnancy rates are unknown and should be reserved for use in Clinical trials. [Grade A]

8. J Minimal Inv Gynecol, Vol 17, No 1,Jan/Feb 2010

Intra uterine synechiaie

Clinical presentation

- Patients may present with intermenstrual bleeding or RPL or asymptomatic with co incidental finding.
- Diagnoses can be made by US, SSH , HSG or hysteroscopy.



Endometrial Polyps

Treatment

Are endometrial polyps responsible for RPL?

No evidence from RCT's that removal of endometrial polyps increase on-going pregnancy rates in patients with previous repetitive miscarriage.

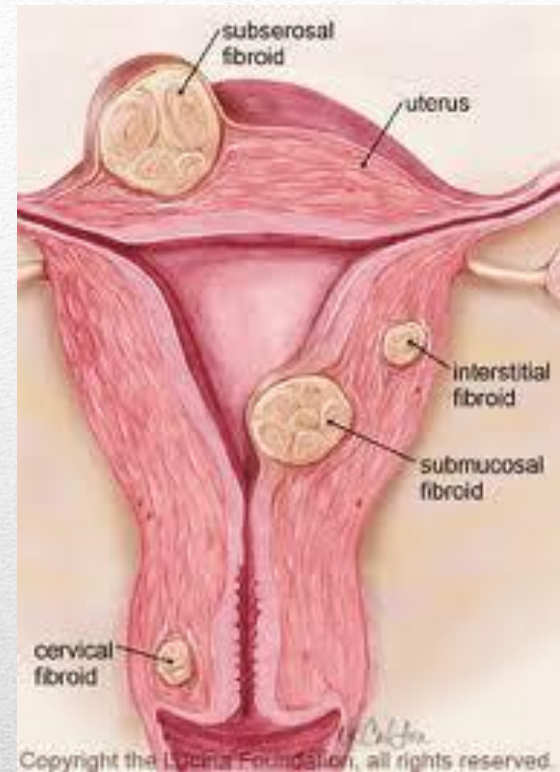
Data support removal of polyps when discovered as part of fertility evaluation and prior to IUI in subfertile women.

Bosteels J, Kasius J, Weyers S, Broekmans FJ, Mol BWJ, D'Hooghe TM. Hysteroscopy for treating subfertility associated with suspected major uterine cavity abnormalities. Cochrane Database of Systematic Reviews 2013, Issue 1. Art. No.: CD009461. DOI: 10.1002/14651858.CD009461.pub2.

Endometrial polyps

Clinical presentation

- Fibroids are the most common benign tumours of female genital tract. Occurs in 20-50% of women.
- Intermenstrual bleeding, excessive bleeding, miscarriage, implantation failure in ART
- From management perspective divided in subserosal, intramural and submucosal.
- Diagnosis by US, HSG, MRI, hysteroscopy, laparoscopy



Uterine fibroids

- The evidence regarding the effect of fibroids on fertility depends mainly on **the type** of fibroid.
- Current evidence suggests the presence of a detrimental effect for **submucous** fibroids on fertility, while **subserous** fibroids seem to have little effect.
- The evidence regarding **intramural fibroids** is less conclusive

Uterine fibroids

Treatment

1. Intramural

Metwally et al (2011).¹⁰ **Meta-analysis : Effects of intramural fibroids on reproductive outcomes:**

No effect of **fibroids** on:

- Clinical pregnancy rates
- Live birth rate
- Miscarriage rate

No effect of **myomectomy** on:

- Clinical pregnancy rate
- Miscarriage rate

Authors conclusion:

These findings highlight the current deficiency in the literature and suggest that evidence is insufficient to draw conclusions regarding the effect of intramural fibroids on reproductive outcomes

10. Metwally M, Farquhar CM, Li TC. Is another meta-analysis on the effect of intramural fibroids on reproductive outcomes needed. Repr Biomed Online(2011) 23,2-14

Uterine Fibroids

2. Submucous myomas

COCHRANE REVIEW (2012). ¹¹

Surgical treatment of fibroids for subfertility



Three parallel-design randomised controlled trials (RCTs) were included in the review. Two were single-centre studies (Casini 2006; Seracchioli 2000) and one was a multi-centre study (Palomba 2007) conducted at three university hospitals.

11. Mostafa Metwally^{1,*}, Ying C Cheong², Andrew W Horne³

Editorial Group: Cochrane Menstrual Disorders and Subfertility Group

Published Online: 14 NOV 2012

Uterine fibroids

To examine the effect of myomectomy on fertility outcomes and to compare different surgical approaches.

Randomised controlled trials examining the effect of myomectomy compared to no intervention or where different surgical approaches are compared regarding the effect on fertility outcomes in a group of infertile women suffering from uterine fibroids.

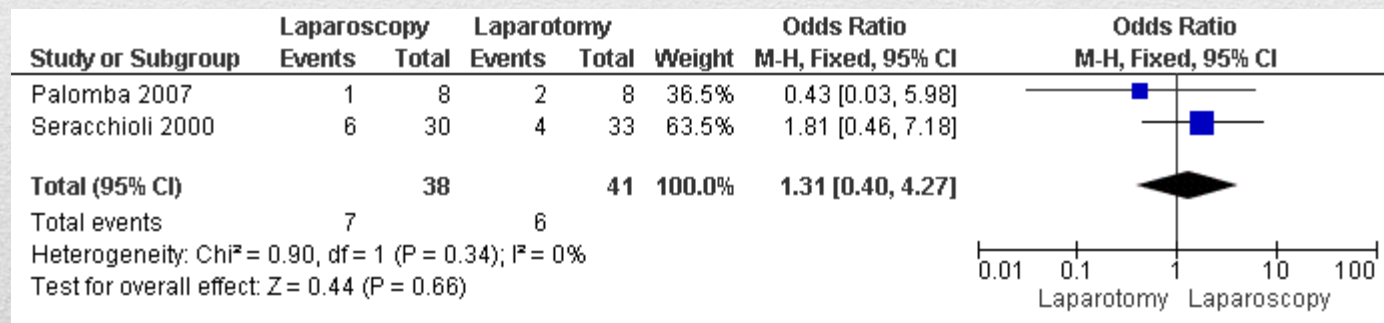
One study (Casini 2006) examined the effect of myomectomy on reproductive outcomes and showed **no evidence** for a significant effect on the **clinical pregnancy rate** for
intramural (OR 1.88, 95% CI 0.57 to 6.14),
submucous (OR 2.04, 95% CI 0.62 to 6.66),
combined intramural and subserous (OR 2.00, 95% CI 0.40 to 10.09)
combined intramural submucous fibroids (OR 3.24, 95% CI 0.72 to 14.57).

Uterine fibroids



Two studies compared **open versus laparoscopic myomectomy** and found no evidence for a significant effect on the

live birth rate (OR 0.80, 95% CI 0.42 to 1.50),
 clinical pregnancy rate (OR 0.96, 95% CI 0.52 to 1.78),
 ongoing pregnancy rate (OR 1.61, 95% CI 0.26 to 10.04),
 miscarriage rate (OR 1.31, 95% CI 0.40 to 4.27),



Uterine fibroids

Hysteroscopy for treating subfertility associated with suspected major uterine cavity abnormalities

Jan Bosteels^{1,*}, Jenneke Kasius², Steven Weyers³, Frank J Broekmans⁴, Ben Willem J Mol⁵, Thomas M D'Hooghe⁶

Editorial Group: Cochrane Menstrual Disorders and Subfertility Group

Published Online: 31 JAN 2013

To assess the effects of the hysteroscopic removal of endometrial polyps, submucous fibroids, uterine septum or intrauterine adhesions suspected on ultrasound, hysterosalpingography, diagnostic hysteroscopy or any combination of these methods in women with otherwise unexplained subfertility or prior to intrauterine insemination (IUI), in vitro fertilisation (IVF) or intracytoplasmic sperm injection (ICSI).

Authors' conclusions

Hysteroscopic myomectomy might increase the odds of clinical pregnancy in women with unexplained subfertility and submucous fibroids, but the evidence is at present not conclusive.

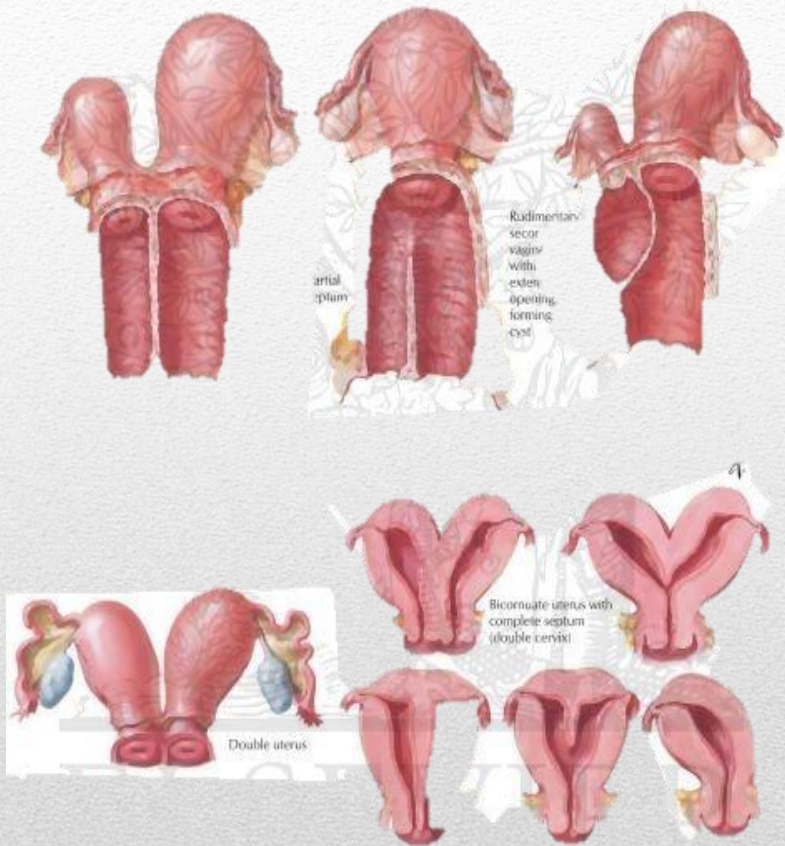
More randomised studies are needed to substantiate the effectiveness of the hysteroscopic removal of suspected endometrial polyps, submucous fibroids, uterine septum or intrauterine adhesions in women with unexplained subfertility or prior to IUI, IVF or ICSI.

Uterine fibroids

Congenital uterine anomalies

- Congenital malformations or anomalies of the female genital tract are defined as deviations from normal anatomy resulting from embryological mal-development of the Mullerian or paramesonephric ducts.
- This may be genetic (mutation of *HOXA 10* gene) or secondary to materno-fetal exposure (DES)

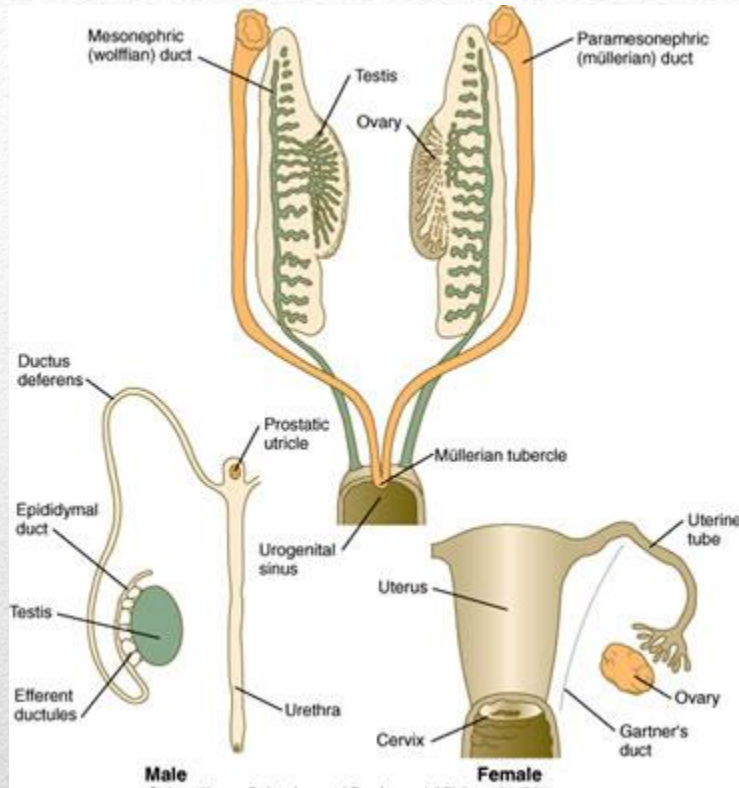
Definition and Etiology



Uterine anomalies due to defective:

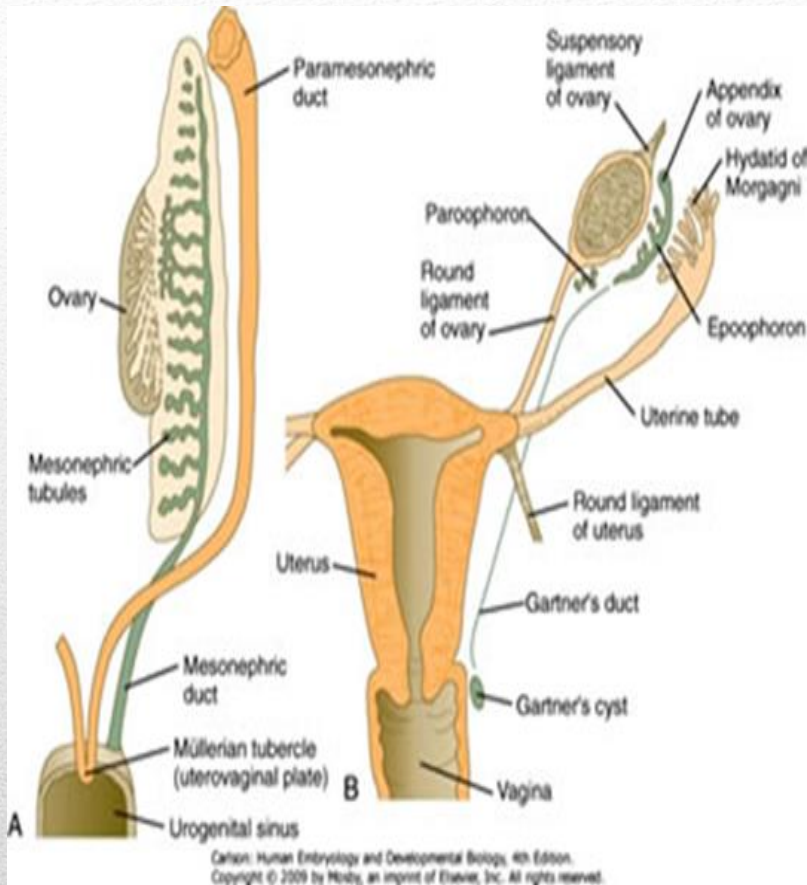
1. Formation
2. Fusion
3. Absorption

Abnormal development



- The genital ducts arise from the paired **mesonephric** and **paramesonephric** ducts
- The gonads arise from the **intermediate mesoderm** within the urogenital ridges.
- They are indifferent up to 7 weeks of development, differentiation largely by presence or absence of **SRY**

Embriology



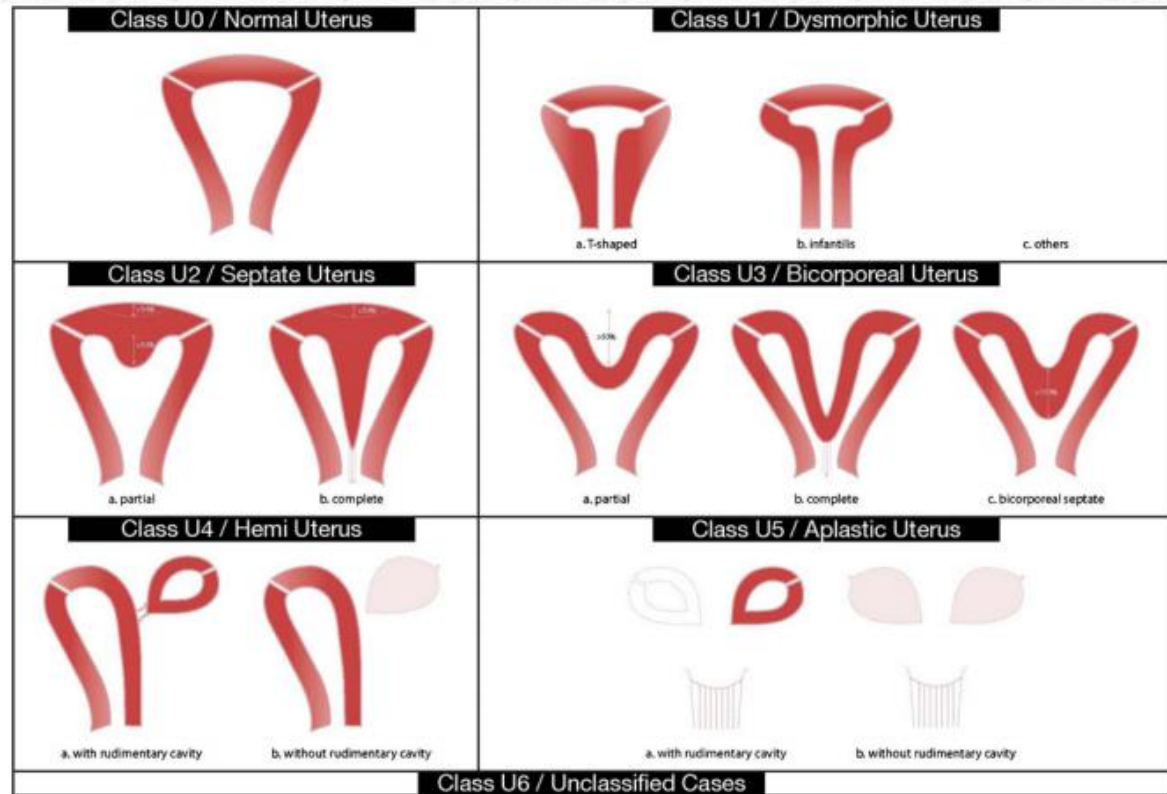
- In the absence of SRY, the gonad develops into an ovary with oogonia and stromal cells.
- Since no testosterone is produced, the mesonephric ducts regress.
- Due to absence of MIS, the paramesonephric ducts persist to give to the oviduct, uterus and upper 1/3 of vagina

- Uterine anomalies can present clinically with onset during **puberty** in young women because of severe dysmenorrhea and pelvic pain.
 - Uterine anomalies are associated with a high rate of miscarriage with normal embryonic karyotype during the **reproductive years** or may be a co-incidental finding in women with normal reproductive history.¹
 - In women with congenital anomalies of the uterus, **obstetrical outcome** is complicated by higher rates of **preterm birth <34 weeks**(OR) 7.4 (CI) 4.8-11.4; P<0.01, **preterm birth <37 weeks** (OR) 5.9 CI 4.3-8.1; P< 0.01, primary non breech **cesarean delivery** (OR) 2.6, CI 1.7-4.0; P<0.01, **breech presentation** (OR) 8.6 CI 6.2-12 P<0.01.²
-
- 1. Sugiura-Ogasawara et al. Midline uterine defects size correlated with miscarriage of euploid embryos in recurrent cases. Fertil Steril 2010; 93: 1983-1988
 - 2. Hua M et al. Congenital uterine anomalies and adverse pregnancy outcomes . Am J Obstet Gynecol 2011; 205: 558;e1-e5

Clinical presentation

- The impact of **congenital** uterine anomalies on fertility and pregnancy outcome is still controversial and a matter of debate .
- In the absence of proper controlled RCT's most meta –analyses rely on observational studies/retrospective cohort studies.
- This is further complicated by the heterogeneity of published data re patient inclusion with RPL / implantation failure in IVF or lasting infertility without pregnancy.
- From the available data, it seems that CUA are associated with poor reproductive outcome. Canalization defects appear to reduce the chance of clinical pregnancy and increase the chance of miscarriage and preterm delivery. These are more pronounced in cases with septate uteri.
- Unification defects do not reduce fertility, but some defects(bicornuate uterus), are associated with aberrant outcome .
- In up to 20% of patients with CUA , especially septate uteri, an associated renal anomaly will be found

Clinical presentation



Classification

Until recently, 3 classification systems have been proposed for the classification of female genital tract anomalies

- 1. **AFS(American Society of Reproductive Medicine)**
- 2. Embryological- clinical classification system of GU malformations
- 3. Vagina, Cervix, Uterus, Adnexae and associated Malformations System based on the TNM principle in Oncology

Classification

New classification needed to provide a more suitable system for accurate , clear, and simple (user friendly) categorization that will correlate with clinical management and improve communication and reporting to facilitate research.

ESHRE/ESGE Working Group: **CONUTA** (CONgenital UTerine Anomalies)

Grimbizis GF, Gordts S, Di Spiezio Sardo A, Brucker S, De Angelis C ET AL. The ESHRE/ESGE consensus on the classification of female genital tract congenital anomalies. *Gynecol Surg* (2013) 10: 199-212

Classification

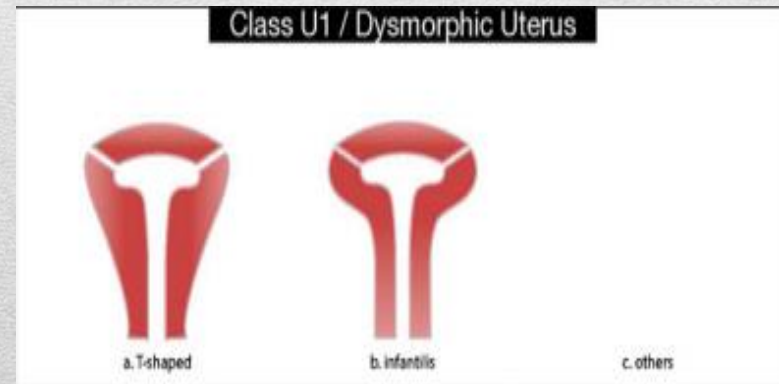
1. **Anatomy** is the basis
2. Deviations of uterine anatomy deriving from the **same embryological origin** is basis for design of main classes
3. Main subclasses based on **clinically relevance** and degree of anatomical abnormality
4. **Cervical and vaginal anomalies** are classified in independent supplementary subclasses

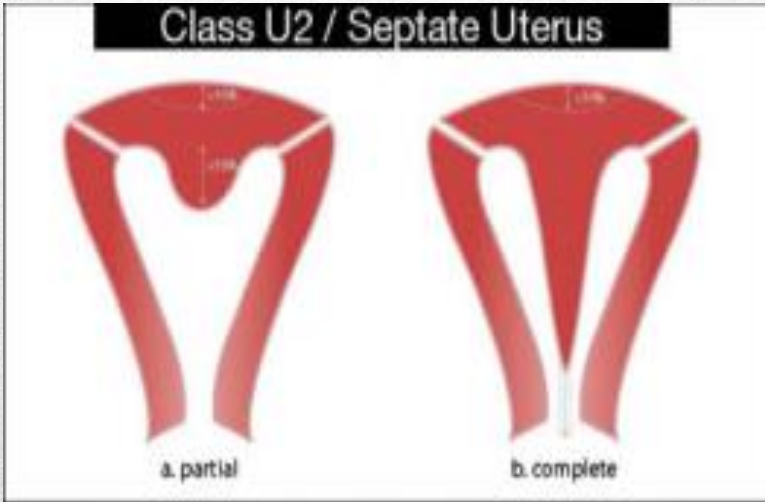
ESHRE/ESGE classification

A normal uterus is any uterus having either a straight or curved interstitial line but with an internal indentation at the fundal midline not exceeding 50% of the uterine wall thickness



Dysmorphic uteri incorporates all cases with normal uterine outline but with an **abnormal narrow shape of the uterine cavity** excluding septae. Further division in 3 subgroups according to lateral wall thickness and cervical/fundal ratio



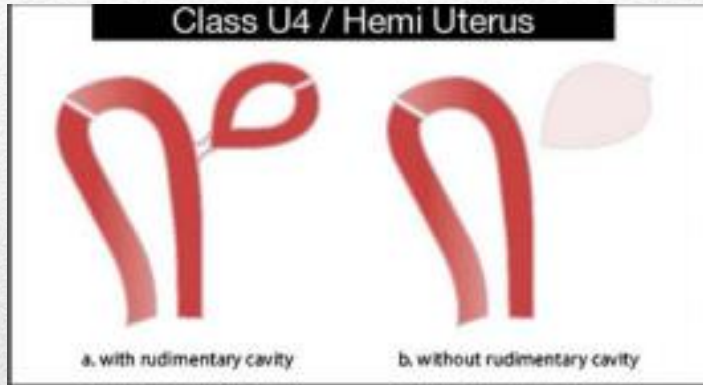


Incorporates all cases with **normal fusion and abnormal absorption** of the midline septum. The internal indentation at the fundal midline exceeding 50% of the uterine wall thickness, with normal outline.

Class U3 / Bicorporeal Uterus

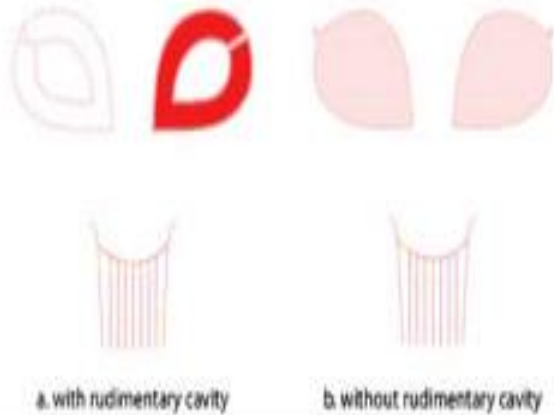


Incorporates all cases **of fusion defects**.
The uterus has an abnormal fundal outline with the presence of an external indentation at the fundal midline exceeding 50% of the uterine wall thickness



Incorporates all cases of unilateral **formation defects** of the uterus, the contralateral part could be either incompletely formed or absent. Sub division depending on the presence or not of a functional rudimentary cavity, communicating or non-communicating

Class U5 / Aplastic Uterus



Incorporates all cases of uterine aplasia. It is a **formation defect** characterized by the absence of any fully or unilaterally developed uterine cavity. Usually associated with co-existent defects (vaginal aplasia/ M-R-K-H syndrome)

Class U6 / Unclassified Cases

This category is kept for still unclassified cases.

This group was created in order to keep the other groups “clean”.

The system is designed to include all cases resulting from formation, fusion or absorption defects of normal embryological development



ESHRE/ESGE classification Female genital tract anomalies



Uterine anomaly		Cervical / Vaginal anomaly	
Main class	Sub-class	Co-existent class	
U0	Normal uterus	C0	<i>Normal cervix</i>
U1	Dysmorphic uterus	C1	<i>Septate cervix</i>
	a. T-shaped b. Infantilis c. Others	C2	<i>Double "normal" cervix</i>
U2	Septate uterus	C3	<i>Unilateral cervical aplasia</i>
	a. Partial b. Complete	C4	<i>Cervical Aplasia</i>
U3	Bicorporeal uterus		
	a. Partial b. Complete c. Bicorporeal septate	V0	<i>Normal vagina</i>
U4	Hemi-uterus	V1	<i>Longitudinal non-obstructing vaginal septum</i>
	a. With rudimentary cavity (communicating or not horn) b. Without rudimentary cavity (horn without cavity / no horn)	V2	<i>Longitudinal obstructing vaginal septum</i>
U5	Aplastic	V3	<i>Transverse vaginal septum and/or imperforate hymen</i>
	a. With rudimentary cavity (bi- or unilateral horn) b. Without rudimentary cavity (bi- or unilateral uterine remnants / Aplasia)	V4	<i>Vaginal aplasia</i>
U6	Unclassified Malformations		
U		C	V

Associated anomalies of non-Müllerian origin:

Drawing of the anomaly

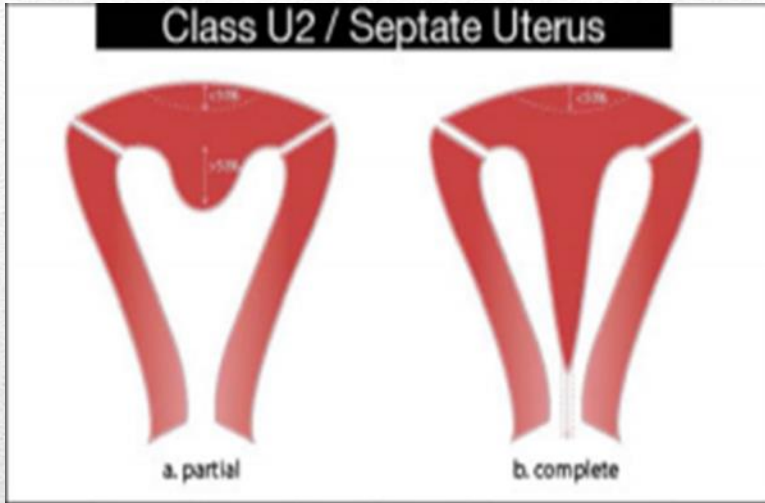
Studies based on hysteroscopy, SHG, 3D US and laparoscopy:

- General population: 2.4%
- Women with infertility: 5.6%
- Women with RPL: 7.1%

Saravelos et al. Prevalence and diagnosis of congenital uterine anomalies in women with reproductive failure. Hum Repr Update 2011; 14: 415-429

Women with primary RPL more likely to have a congenital anomaly than secondary RPL. However, no difference in acquired anomalies in the two groups

Incidence



- Surgical correction indicated:
Laparoscopy with hysteroscopy and resection septum with leaving medial aspect of cervix intact

Management

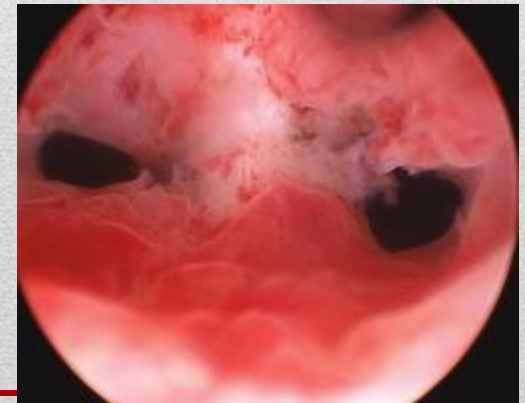
“Hysteroscopic metroplasty dramatically improves pregnancy outcome , reducing the miscarriage rate and increasing term deliveries” ¹²

Metroplasty vs expectant management for women with recurrent miscarriage and a septate uterus. Cochrane Review 2011, Issue 6 ¹³

12. Gordts S. New developments in reproductive surgery. Best Practice & Research Clinical Obstet and Gynecol. (2012), <http://dx.doi.org/10.1016/j.bpobgyn.2012.11.004>

13. Kowalik CR et al. Metroplasty vs expectant management for women with recurrent miscarriage and a septate uterus. *Cochrane Database of Systematic Reviews* 2011, Issue 6. Art. No.: CD008576

Management



Metroplasty versus expectant management for women with recurrent miscarriage and a septate uterus

C R Kowalik1,* , M Goddijn2, M H Emanuel3, M Y Bongers4, T Spinder5, J H de Kruijf6, Ben Willem J Mol7, Maas Jan Heineman8

Published Online: 15 JUN 2011

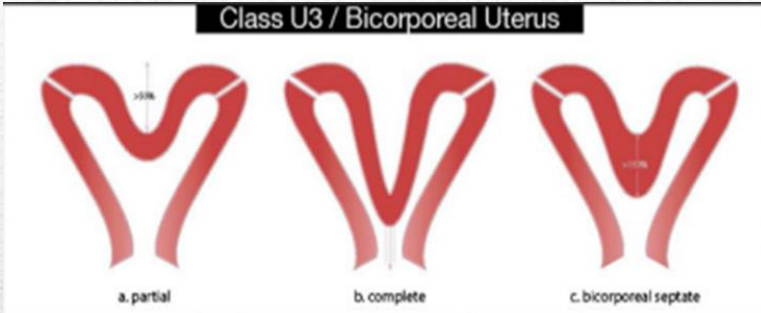


Objectives: To determine whether hysteroscopic metroplasty in women with a septate uterus and two or more preceding miscarriages improves pregnancy rates

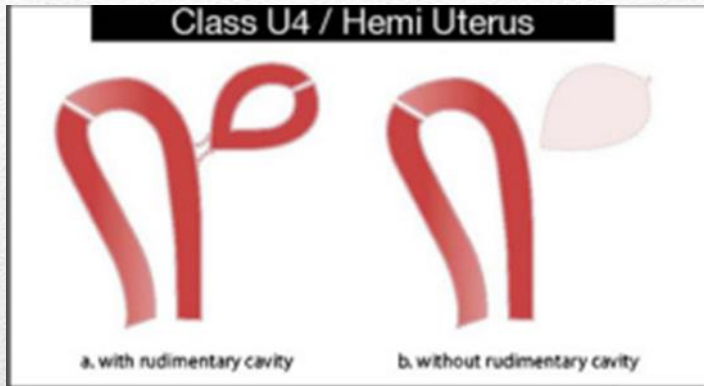
Main results: No RCT's were identified for inclusion.

Authors' conclusions: Hysteroscopic metroplasty in women with RPL and a septate uterus is being performed in many countries to improve reproductive outcomes in women. This treatment has been assessed in non-controlled studies, which suggested a positive effect on pregnancy outcomes. However, these studies are biased due to the fact that the participants with recurrent miscarriage treated by hysteroscopic metroplasty served as their own controls. Taking this into account there is insufficient evidence to support this treatment in these patients

Class U3 / Bicorporeal Uterus



- No surgery indicated, role of cervical cerclage unclear.



- Removal by laparoscopy of rudimentary horn indicated before pregnancy .
- Management of early uterine horn pregnancy ; Surgical excision and repair (MTX), ONLY 30% TERM. Fetal survival 0-13%

- Both acquired and congenital anomalies of the uterus may impair reproductive function and obstetrical outcome.
- Anatomical anomalies should be excluded in all patients with RPL/Implantation failure/ Poor obstetrical outcome.
- The new ESHRE/ESGE classification of CUA should be used in order to facilitate communication and research
- Clinical and radiological, surgical investigations will confirm the diagnosis.

Conclusion
