

CLINICAL PRACTICE GUIDELINES

Non-epithelial ovarian cancer: ESMO Clinical Practice Guidelines for diagnosis, treatment and follow-up[†]

I. Ray-Coquard¹, P. Morice², D. Lorusso³, J. Prat⁴, A. Oaknin⁵, P. Pautier² & N. Colombo⁶, on behalf of the ESMO Guidelines Committee*

¹Centre Leon Bérard, University Claude Bernard Lyon & GINECO group, Lyon; ²Gustave Roussy & GINECO group, Villejuif, France; ³Fondazione IRCCS Istituto Nazionale dei Tumori, Milan, Italy; ⁴Hospital de Sant Pau, Autonomous University of Barcelona; ⁵Vall d'Hebron University Hospital, Vall d'Hebron Institute of Oncology (VHIO), Barcelona, Spain; ⁶University of Milan-Bicocca and European Institute of Oncology, Milan, Italy

*Correspondence to: ESMO Guidelines Committee, ESMO Head Office, Via L. Taddei 4, CH-6962 Viganello-Lugano, Switzerland. E-mail: clinicalguidelines@esmo.org

[†]Approved by the ESMO Guidelines Committee: August 2008, last update December 2017. This publication supersedes the previously published version—*Ann Oncol* 2012; 23(Suppl 7): vii20–vii26.

Incidence and epidemiology

Non-epithelial ovarian tumours account for approximately 10% of all ovarian cancers. Malignant germ cell tumours (GCTs) occur mainly in young women whereas the most common type of sex cord-stromal tumours (SCSTs), i.e. granulosa cell tumour, occurs more often in middle age and in postmenopausal women [1]. Malignant GCTs represent 5% of all ovarian cancers and 80% of the preadolescent malignant ovarian tumours. SCSTs are rare neoplasms that account for approximately 3%–5% of ovarian malignancies and the majority of ovarian tumours with endocrine manifestations. The yearly-adjusted incidence rate is 3.7/1 000 000 and 2.1/1 000 000 women for GCTs and SCSTs, respectively [1]. Small cell carcinoma of the ovary (SCCO) usually affects young women and children [2] with a very low incidence (less than 1% of ovarian cancers) [1]. Unlike GCTs, SCSTs and steroid cell tumours are unilateral and occur over a wide range of age; for instance, granulosa cell tumours and thecomas are found mainly in peri- and postmenopausal women, whereas juvenile granulosa cell tumours, Sertoli cell tumours and Sertoli-Leydig cell tumours (SLCTs) usually develop in adolescents and young females in whom maintenance of fertility is important [3].

Diagnosis and pathology/molecular biology

The initial symptoms and signs of non-epithelial ovarian cancers are usually a subacute pelvic pain, feeling of pelvic pressure because of a pelvic mass and menstrual irregularities. Diagnostic work-up should include pelvic ultrasound, abdomino-pelvic computed tomography (CT) scan, chest X-ray and positron emission tomography (PET) scan in selected cases (GCTs) [III, B]. In young

patients, serum human chorionic gonadotropin (hCG), alpha-fetoprotein (α -FP) and lactate dehydrogenase (LDH) levels, full blood count and liver and renal function tests should be carried out. Inhibin B is secreted by granulosa cell tumours and could be a useful marker for the disease. Serum anti-Müllerian hormone (AMH) may be a marker of ovarian reserve and granulosa cell tumours in postmenopausal or post-oophorectomy women [4]. While these markers are nonspecific, they can provide prognostic information, so quantitative hCG, α -FP, LDH and cancer antigen 125 (CA 125) should be measured preoperatively [5]. If gonadoblastoma is suspected, a preoperative karyotype should be obtained on all premenarche girls because of the propensity of these tumours to arise in dysgenetic gonads.

Most non-epithelial ovarian tumours arise from cells specific to the ovary (germ cells, granulosa cells, theca cells, stromal fibroblasts and steroid cells); other less common gonadal tumours arise from non-specific ovarian cells (mesenchymal cells). The World Health Organization (WHO) classification of GCTs is presented in Table 1 [6, 7]. GCTs recapitulate steps of development, from undifferentiated germ cells to adult tissues. Primitive GCTs composed of undifferentiated germ cells and GCTs with extraembryonic differentiation are all malignant. Teratomas are the most common GCTs; most are composed of mature tissues and are benign (dermoid cysts). In immature teratomas, embryonic tissues indicate the malignant potential and grading is prognostically relevant [7]. Grade 1 tumours show rare foci of immature neuroepithelial tissue that occupy < 1 low power field (40 \times) in any slide (low grade); grade 2 tumours show similar elements, occupying 1–3 low power fields (40 \times) in any slide (high grade); grade 3 tumours exhibit large amounts of immature neuroepithelial tissue occupying > 3 low power fields (40 \times) in any slide (high

Table 1. WHO 2014 classification of GCTs [6]

- Dysgerminoma
- Yolk sac tumour
- Embryonal carcinoma
- Non-gestational choriocarcinoma
- Mature teratoma
- Immature teratoma
- Mixed germ cell tumour

GCT, germ cell tumour; WHO, World Health Organization.

Table 2. Immunohistochemistry of primitive GCTs

	SALL4	OCT3/4	SOX2
Dys	+	+	-
YST	+	-	-
EC	+	+	+

Dys, dysgerminoma; EC, embryonal carcinoma; GCT, germ cell tumour; YST, yolk sac tumour.

grade). A two-tiered (low and high grades) system is now more commonly used [8]. Other rare malignant GCTs constitute a heterogeneous group including somatic cancers arising in dermoids and monodermal teratomas [7]. In the elderly, non-dysgerminoma GCTs arise from epithelial ovarian cancer, usually endometrioid and clear cell carcinomas. Primitive GCTs and immature teratomas are chemosensitive and susceptible to fertility-sparing surgery. Because of their chemosensitivity and the increasing adoption of fertility-sparing surgery, correct pathological diagnosis is essential and these cases should be examined by gynaecological pathologists [V, B]. Diagnosis can be made on conventional histological material; given the multiplicity of morphological features, immunohistochemical markers (Table 2) and chromosome 12p fluorescent *in situ* hybridisation (FISH) can be used to confirm the diagnosis in difficult cases. SALL4 and OCT4 are widely used; more recently, it has been recognised that SOX2 is expressed in embryonal carcinoma and primitive neuroectodermal tumours of teratomatous origin.

SCSTs and steroid cell tumours constitute a heterogeneous group of tumours (Table 3) and vary in their capacity to produce clinically significant amounts of steroid hormones. Granulosa cell tumours are typically oestrogenic and may be associated with various clinical syndromes, depending upon the age of the patient. SLCTs typically produce androgens, and clinical virilisation is observed in 70%–85% of patients. Those with sex cord elements may be malignant, with granulosa cell tumours being the most frequent histological type. Neoplasms of pure ovarian stroma are mostly benign, with > 50% of them being fibromas. In morphologically ambiguous cases, an immunopanel of inhibin alpha, calretinin and FOXL2, together with FOXL2 (402C-G) mutational analysis, is useful to confirm the diagnosis of adult granulosa cell tumours (AGCTs) [V, B] [9]. Chang et al. demonstrated that another molecule involved in the tumourigenesis of

Table 3. WHO 2014 classification of SCSTs and steroid cell tumours [7]

- Pure stromal tumours**
- Fibroma
- Cellular fibroma
- Thecoma
- Luteinized thecoma associated with sclerosing peritonitis
- Fibrosarcoma
- Sclerosing stromal tumour
- Signet-ring stromal tumour
- Microcystic stromal tumour
- Leydig cell tumour
- Steroid cell tumour
- Steroid cell tumour, malignant
- Pure sex cord tumours**
- Adult granulosa cell tumour
- Juvenile granulosa cell tumour
- Sertoli cell tumours
- Sex cord tumour with annular tubules
- Mixed sex cord-stromal tumours**
- Sertoli–Leydig cell tumours
 - Well differentiated
 - Moderately differentiated
 - With heterologous elements
 - Poorly differentiated
 - With heterologous elements
 - Retiform
 - With heterologous elements
- Sex cord-stromal tumours, NOS

NOS, not otherwise specified; SCST, sex cord-stromal tumour; WHO, World Health Organization.

AGCTs is activin A [10]. A subset of SCSTs is typically negative for FOXL2 on immunostaining (retiform or poorly differentiated SLCT), but these tumours usually express inhibin alpha and/or calretinin. Another recent finding has been the occurrence of *DICER1* mutations in SCST [V, C].

Small cell carcinomas of the ovary hypercalcaemic type (SCCOHTs) are the most common form of ovarian undifferentiated carcinomas in women < 40 years old and the most common ovarian tumour associated with hypercalcaemia (70%). This tumour is typically unilateral and should be distinguished from primitive GCTs and granulosa cell tumours (mainly juvenile). Although its histogenesis is unknown, recent reports suggest that it may represent an ovarian malignant rhabdoid tumour [11]. Recent studies have identified mutations in the SWItch/Sucrose Non-Fermentable (SWI/SNF) chromatin-remodelling gene, *SMARCA4* encoding BRG1. These mutations represent a frequent event occurring in 76%–100% of SCCOHTs [12–14]. Germline mutations in *SMARCA4* or *SMARCB1* were already known to predispose to the development of paediatric tumours, namely atypical teratoid/rhabdoid tumours [15, 16]. *SMARCA4* immunohistochemistry is highly sensitive and specific for a diagnosis of SCCOHT [loss of *SMARCA4* (BRG1) protein expression] and is now useful in the differential diagnosis of poorly differentiated ovarian tumours [17]. SCCOHTs usually react diffusely for WT1, making the interpretation difficult. Differential diagnosis includes

juvenile or adult granulosa tumours, metastatic melanoma, dysgerminoma, Ewing tumour and undifferentiated carcinoma.

Staging and risk assessment

Prognostic factors

The staging system for non-epithelial ovarian cancers is generally adopted from the one for epithelial ovarian cancer originally defined by the International Federation of Gynecology and Obstetrics (FIGO) (Table 4) [18]. Outcomes appear to be superior when patients are treated in a large cancer centre, likely due to the rare nature and infrequent presentation of these cancers [19].

Outcomes may depend on the age at diagnosis. Premenarche girls and women > 45 years who develop GCTs may have different tumour biology and a worse prognosis than postadolescent females in the reproductive years. Patients with testicular cancer are stratified as having good, intermediate or high risk for

recurrence based on clinical, pathological and serological markers. Compared with testicular cancer, clinical prognostic factors are less well defined for ovarian GCTs. Adverse factors include age > 45 years, stage > I, incomplete surgical resection and yolk sac tumour (YST) histology [20, 21].

Stage is also an important prognostic factor for SCSTs, although advanced-stage diseases can also have a good prognosis because of their sensitivity to chemotherapy (ChT). The FIGO stage [18] and the intraperitoneal tumour rupture are the most often reported prognostic factors. Patient age (> 50 years) and the size of the tumour (> 5 cm) have a less certain prognostic value [5]. The majority of these tumours can be cured, but around 20% relapse or give rise to metastases that can be fatal [III, A].

Prognosis of SCCOHT is poor with only 30%–40% long-term survivors with standard treatment [2]. Potential favourable prognostic factors, in addition to disease stage (stage IA versus others) are: age > 30 years; normal pre-operative calcium level; a tumour size < 10 cm; the absence of large cells; and complete surgical resection including bilateral oophorectomy [22, 23].

Table 4. 2014 FIGO ovarian cancer staging system and corresponding TNM

TNM staging	FIGO staging	Description
T1a-N0-M0	Stage IA	Tumour limited to one ovary (capsule intact), no tumour on ovarian surface; no malignant cells in ascites or peritoneal washings; no regional lymph node metastasis; no distant metastasis
T1b-N0-M0	Stage IB	Tumour limited to both ovaries (capsules intact), no tumour on ovarian surface; no malignant cells in ascites or peritoneal washings; no regional lymph node metastasis; no distant metastasis
T1c-N0-M0	Stage IC1	Tumour limited to one or both ovaries with capsule ruptured (surgical spill); no regional lymph node metastasis; no distant metastasis
T1c-N0-M0	Stage IC2	Tumour limited to one or both ovaries with capsule ruptured before surgery or tumour on ovarian surface; no regional lymph node metastasis; no distant metastasis
T1c-N0-M0	Stage IC3	Tumour limited to one or both ovaries with malignant cells in ascites or peritoneal washings; no regional lymph node metastasis; no distant metastasis
T2a-N0-M0	Stage IIA	Extension and/or implants on the uterus and/or tube(s); no malignant cells in ascites or peritoneal washings; no regional lymph node metastasis; no distant metastasis
T2b-N0-M0	Stage IIB	Extension to and/or implants in other pelvic tissues; no malignant cells in ascites or peritoneal washings; no regional lymph node metastasis; no distant metastasis
T1/T2-N1-M0	Stage IIIA1	Tumour limited to the ovaries (one or both) (T1) or tumour involves one or both ovaries with pelvic extension (T2); regional lymph node metastasis; no distant metastasis
	Stage IIIA1 (i)	Metastasis up to 10 mm in greatest dimension
	Stage IIIA1 (ii)	Metastasis more than 10 mm in greatest dimension
T3a-N0/N1-M0	Stage IIIA2	Microscopic peritoneal metastasis beyond the pelvis (no macroscopic tumour); no regional lymph node metastasis (N0) or regional lymph node metastasis (N1); no distant metastasis
T3b-N0/N1-M0	Stage IIIB	Macroscopic peritoneal metastasis beyond the pelvis up to 2 cm in greatest dimension; no regional lymph node metastasis (N0) or regional lymph node metastasis (N1); no distant metastasis
T3c-N0/N1-M0	Stage IIIC	Macroscopic peritoneal metastasis beyond the pelvis > 2 cm in greatest dimension and/or regional lymph node metastasis; no regional lymph node metastasis (N0) or regional lymph node metastasis (N1); no distant metastasis
any T-any N-M1	Stage IVA	Pleural effusion with positive cytology
any T-any N-M1	Stage IVB	Parenchymal metastases and metastases to extra-abdominal organs (including inguinal lymph nodes and lymph nodes outside of the abdominal cavity)

FIGO, International Federation of Gynecology and Obstetrics; TNM, tumour, node, metastasis.

Modified from [22] and [57].

Staging

A surgical approach can be carried out through open route or, in selected cases, by minimally invasive approaches—laparoscopy and robotics—to avoid tumour rupture during surgery. A careful examination of the abdominal cavity is required. The staging procedure includes infracolic omentectomy, biopsy of the diaphragmatic peritoneum, paracolic gutters, pelvic peritoneum and peritoneal washings in macroscopic stage I disease.

Germ cell tumours. There is no consensus about the role of systematic lymphadenectomy, but the omission of staging peritoneal procedures seems to increase the recurrence rate [24], though without impact on overall survival [25]. GCTs, particularly dysgerminoma, have a high risk of nodal spread. On the other hand, given the very high chemosensitivity of such tumours, potential nodal metastasis should be cured by adjuvant ChT in these patients [III, A].

Thus, nodal debulking surgery is only required in rare cases of residual disease after ChT. In early-stage disease that does not require adjuvant ChT because of favourable prognostic factors, nodal dissection should be carried out only where there is evidence of nodal abnormalities during surgical exploration and/or initial CT scan (lymphadenopathy) [III, A]. Patients not undergoing initial nodal staging surgery can be safely cured with ChT at the time of the potential nodal recurrence [26].

Unilateral salpingo-oophorectomy with preservation of the contralateral ovary and the uterus is now considered as the standard surgical treatment for young patients with GCTs [III, A].

This conservative management should be considered even in the case of advanced disease because of the sensitivity of the tumour to ChT [IV, B] [27]. Systematic ovarian biopsy is not necessary when the contralateral ovary is macroscopically normal [III, A]. In case of macroscopic bilateral ovarian diseases (particularly dysgerminoma or immature teratoma), preservation of at least a healthy part of one ovary (unilateral salpingo-oophorectomy and contralateral cystectomy) and the uterus should be encouraged [IV, B] [28]. In postmenopausal women and in patients with advanced-stage disease or with bilateral ovarian involvement, abdominal hysterectomy and bilateral salpingo-oophorectomy could be carried out with careful surgical staging [III, A].

Sex cord-stromal tumours. The place of conservative treatment in child-bearing age patients affected by SCSTs is somewhat different. Preservation of the uterus and contralateral ovary seems to be safe in macroscopic stage IA disease but should not be carried out in stages > I. Conservative surgery is also an acceptable approach in young patients with stage I SCSTs [IV, B]. In the case of juvenile granulosa cell tumours, the safety of this management approach in stage IC disease remains controversial, particularly in stage IC2 or IC3 disease [V, C]. In case of conservative treatment, an endometrial curettage (or hysterectomy in case of radical management) must be carried out to rule out concomitant uterine cancers in patients with granulosa cell tumour [IV, B]. For SCSTs, retroperitoneal evaluation is not mandatory because of the very low incidence of retroperitoneal metastases in early-stage disease [III, A]. Recent publications on incidence of lymph node metastases in SCST support the position that lymphadenectomy is not needed in these patients [29]. SLCTs frequently have

low-grade malignancy, although occasionally a retiform or poorly differentiated (sarcomatoid) form may be malignant. In postmenopausal women and in patients with advanced-stage disease or with bilateral ovarian involvement, abdominal hysterectomy and bilateral salpingo-oophorectomy should be carried out with careful surgical staging for SCST [III, A].

Small cell carcinomas of the ovary hypercalcaemic type. The prognosis of SCCOHT is very poor and the risk of extra-ovarian spread high. All suspected cases should benefit from a review by an expert pathologist and be discussed in a specialised tumour board [V, A]. Efforts should be made to treat patients in a more homogeneous way through national and international networks [V, A]. Conventional surgical treatment includes radical surgery (bilateral salpingo-oophorectomy and hysterectomy) combined with peritoneal and nodal staging surgery, even for macroscopically stage I disease [IV, A] [2]. The largest series to date reported a decline in survival in patients treated conservatively [2]. As a result of the adjuvant treatment after surgery combining high-dose ChT (HDCT) and radiotherapy (RT), the potential preservation of gonadal function is considered to be only conceptual even if one ovary and the uterus are preserved [2]. Until now, no pregnancy has been reported after this type of de-escalating surgical management [2].

Management of early stages

Germ cell tumours (Figures 1–3)

Most GCTs (60%–70%) are diagnosed at an early stage. Stage I patients have an excellent prognosis with long-term disease-free status of about 90%. Given the young age of patients, all efforts should be made to preserve fertility. Fertility-sparing surgery appears to be safe with excellent survival after long-term follow-up, yielding outcomes equivalent to patients undergoing hysterectomy with bilateral salpingo-oophorectomy [III, A]. Stage IA pure dysgerminoma should be treated with surgery only [III, A] [24]. The recurrence rate in this group of patients is relatively low (15%–25%) and they can be successfully treated at the time of relapse with a high likelihood of cure. Patients with stage IA grade 1 immature teratoma do not require further adjuvant ChT after adequate surgical staging [III, A]. The need for adjuvant ChT in stage IA G2–G3 and IB–IC is still controversial [5]. Some published data (risk of relapse ranging from 2%–20% for grade 2 to 20%–40% for grade 3 immature teratoma) indicate that all grades of immature teratoma and all stage I dysgerminomas can be managed with close surveillance after fertility-sparing surgery [III, B], reserving ChT for those cases in which post-surgery recurrence is documented [24, 30]. However, this policy is not universally accepted; the benefit of not having ChT (i.e. the avoided risk weighed against the risk of relapse and delayed treatment) needs to be discussed with the patient. All patients with stage I YSTs are treated with adjuvant ChT after surgery [31]. Recent data on paediatric patients suggest close surveillance for stage I YSTs with complete surgical staging and negative postoperative α -FP, reserving ChT for patients who experience recurrence [30], but this policy is not widely accepted [III, C].

Data from the literature show that the most used combination is the 5-day bleomycin/etoposide/cisplatin (BEP) regimen [III, A] [31].

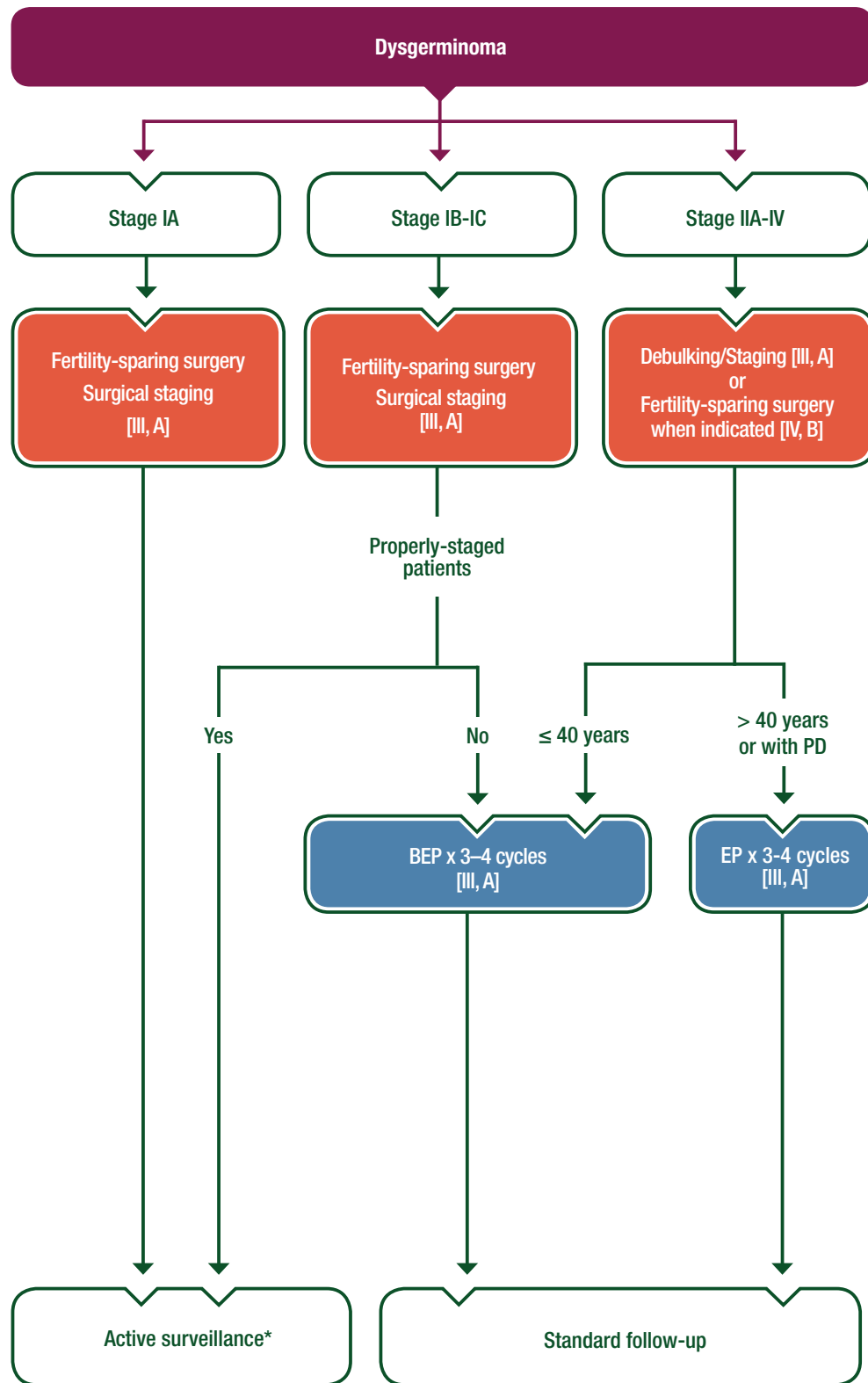


Figure 1. Management of GCTs of the ovary—dysgerminoma.

*See Table 5.

BEP, bleomycin/etoposide/cisplatin; EP, etoposide/cisplatin; GCT, germ cell tumour; PD, pulmonary disease.

When ChT is not offered, a close and active surveillance programme should be proposed [III, C]. Vazquez and Rustin postulate a surveillance schedule involving regular clinical review with clinical

examination, radiological imaging including abdomen-pelvic sonography at regular intervals and the monitoring of tumour markers to detect relapse over a period of 10 years, with a gradual

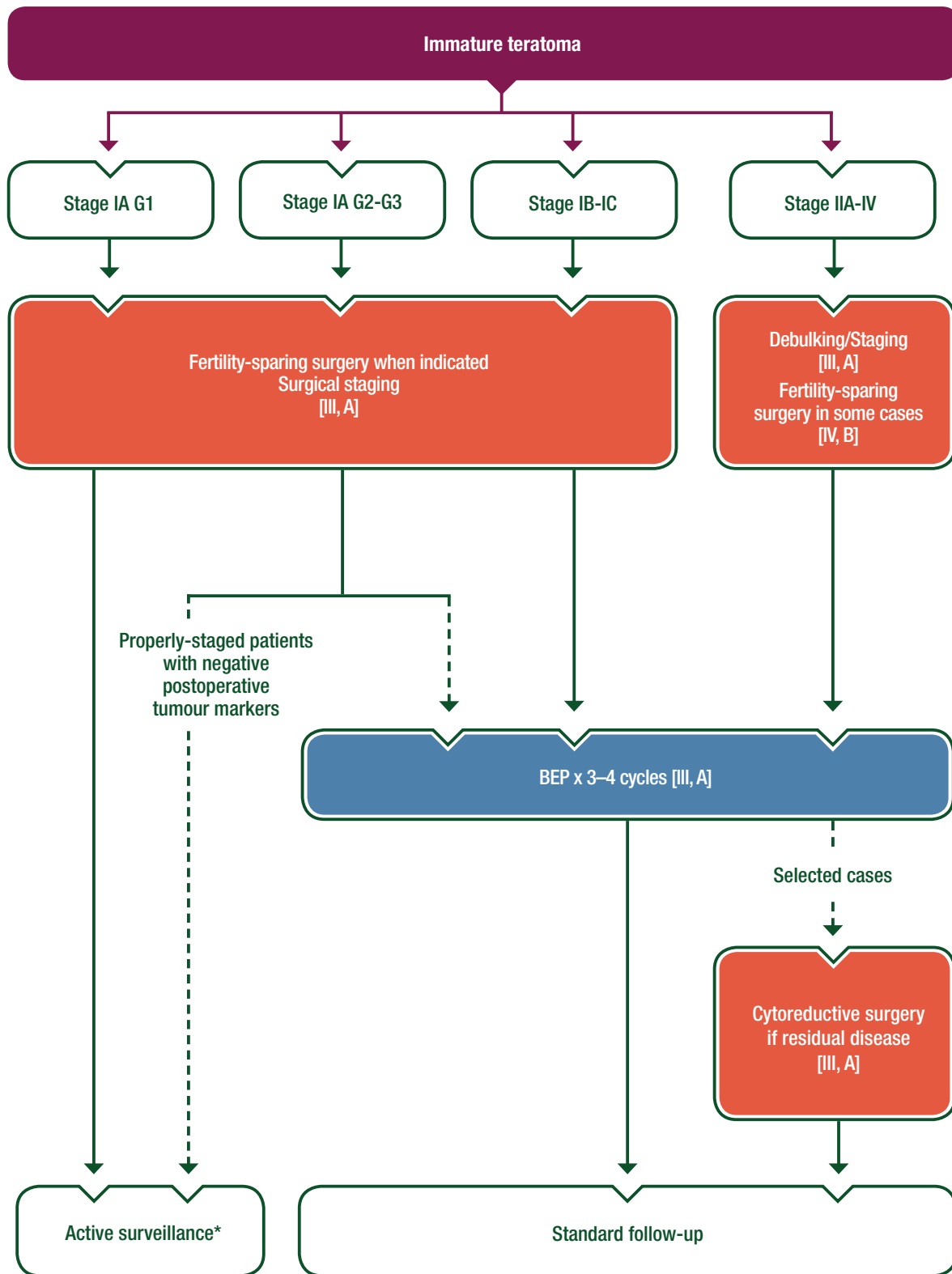


Figure 2. Management of GCTs of the ovary—immature teratoma.

*See Table 5.

--> Optional

BEP, bleomycin/etoposide/cisplatin; GCT, germ cell tumour.

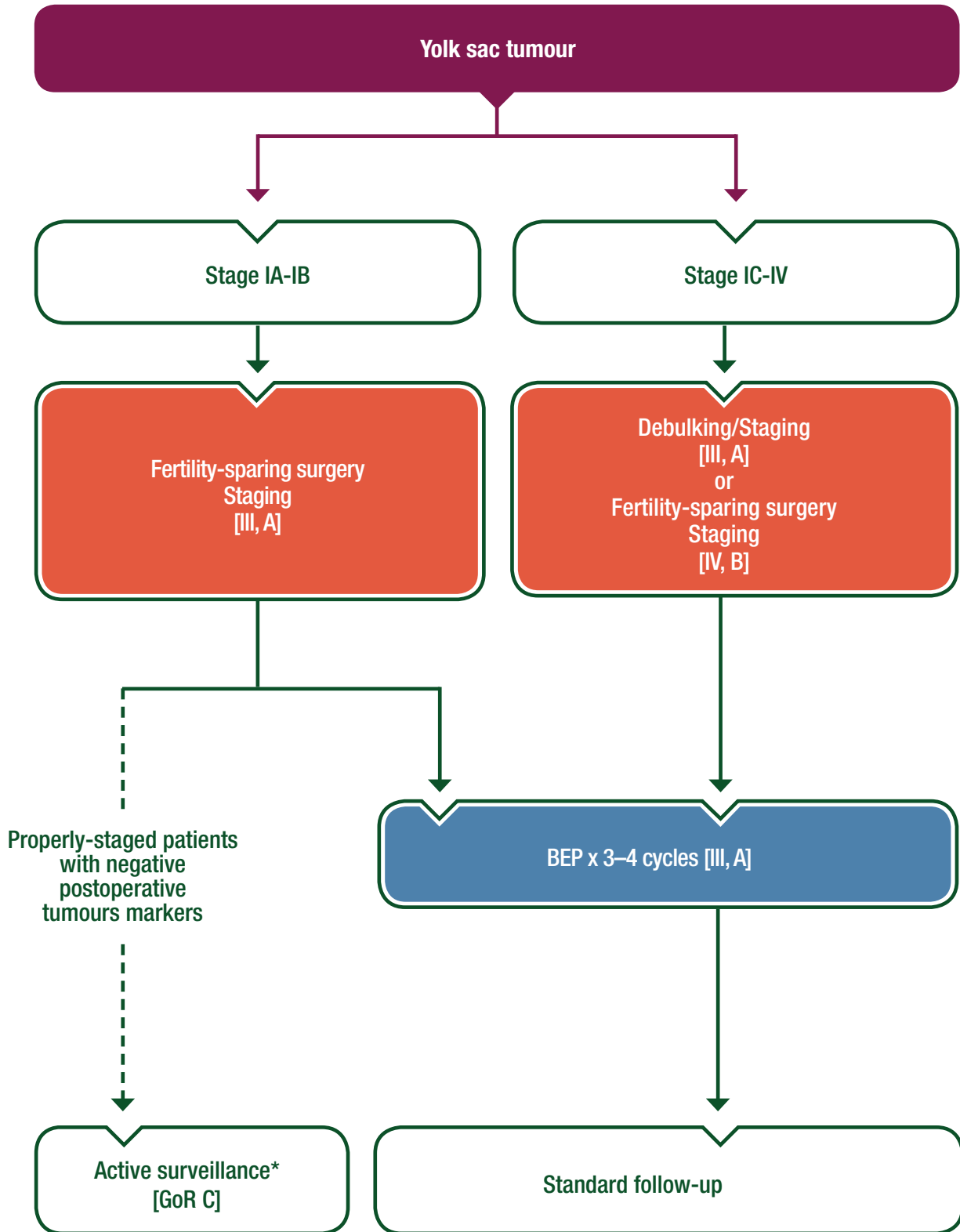


Figure 3. Management of GCTs of the ovary—yolk sac tumour.

*See Table 5.

--> Optional

BEP, bleomycin/etoposide/cisplatin; GCT, germ cell tumour; GoR, grade of recommendation.

Table 5. Active surveillance programme in the management of ovarian GCTs

Time period	Examination	Pelvic US	Tumour markers	Chest X-ray	CT chest abdomen pelvis
1st year	monthly	2 monthly	every 2 weeks (first 6 months) and then monthly	2 monthly	1 month ^a 3 months ^b 12 months
2nd year	2 monthly	4 monthly	2 monthly	4 monthly	
3rd year	3 monthly	6 monthly	3 monthly	6 monthly	
4th year	4 monthly		4 monthly	8 monthly	
5th to 10th year	6 monthly		6 monthly	annually	

^aIf not carried out preoperatively.

^bIf clear—second look laparoscopy if inadequate staging/immature teratoma.

CT, computed tomography; GCT, germ cell tumour; US, ultrasound.

Suggested surveillance programme based on Mount Vernon proposal. Modified from [32] with permission.

Table 6. Toxicity of BEP and long-term complications

Pulmonary toxicity, decreased DLCO
AML
Neuropathy
Raynaud's disease
Tinnitus
High tone hearing loss
Gonadal dysfunction
Cardiovascular disease/Hypertension
Nephrotoxicity
Osteoporosis after radical surgery for young patients

AML, acute myeloid leukaemia; BEP, bleomycin/etoposide/cisplatin;
DLCO, diffusing capacity of the lungs for carbon monoxide.

increase of the interval between clinical appointments [III, C] [32]. This is summarised in Table 5 [32]. Patient adherence to the demanding visit schedule is of paramount importance. It is extremely important to advise patients against pregnancy during the first 2 years after initial diagnosis, as most relapses occur during this time [1]. Whenever possible, patients undergoing active surveillance protocols should be included in trials or prospective registries.

Sex cord-stromal tumours (Figures 4 and 5)

Most SCSTs (60%–95%) are diagnosed at an early stage. Stage IA granulosa cell tumours have an excellent prognosis after surgery alone and do not require adjuvant therapy [III, A].

The selection of early-stage SCST patients for any postoperative treatment is controversial. To date, the relative benefit of adjuvant ChT has yet to be demonstrated. Some authors would suggest adjuvant therapy for juvenile granulosa tumour stage IC patients [IV, B]; in this case, platinum-based ChT is the treatment of choice [III, A]. Also, more relapses were reported for patients with AGCT stage IC2 compared with stage IC1 [33]; in this case, adjuvant ChT can be discussed [IV, C].

The most commonly used regimen is the BEP combination [III, A] [5]. Alternative ChT options include: paclitaxel and carboplatin

[III, B] [34]; etoposide/cisplatin (EP); cyclophosphamide/doxorubicin/cisplatin (CAP); or a platinum agent alone [III, A]. Due to the relative toxicity of BEP versus carboplatin/paclitaxel, particularly in older age groups, and the limited evidence to support its use (some non-randomised series suggest carboplatin/paclitaxel may be as effective as BEP), bleomycin should not be given to patients > 40 years old or with pre-existing pulmonary disease [III, A].

For SLCTs, postoperative adjuvant ChT should be considered for those patients with stage I poorly differentiated or with heterogeneous elements [IV, B].

Small cell carcinomas of the ovary hypercalcaemic type

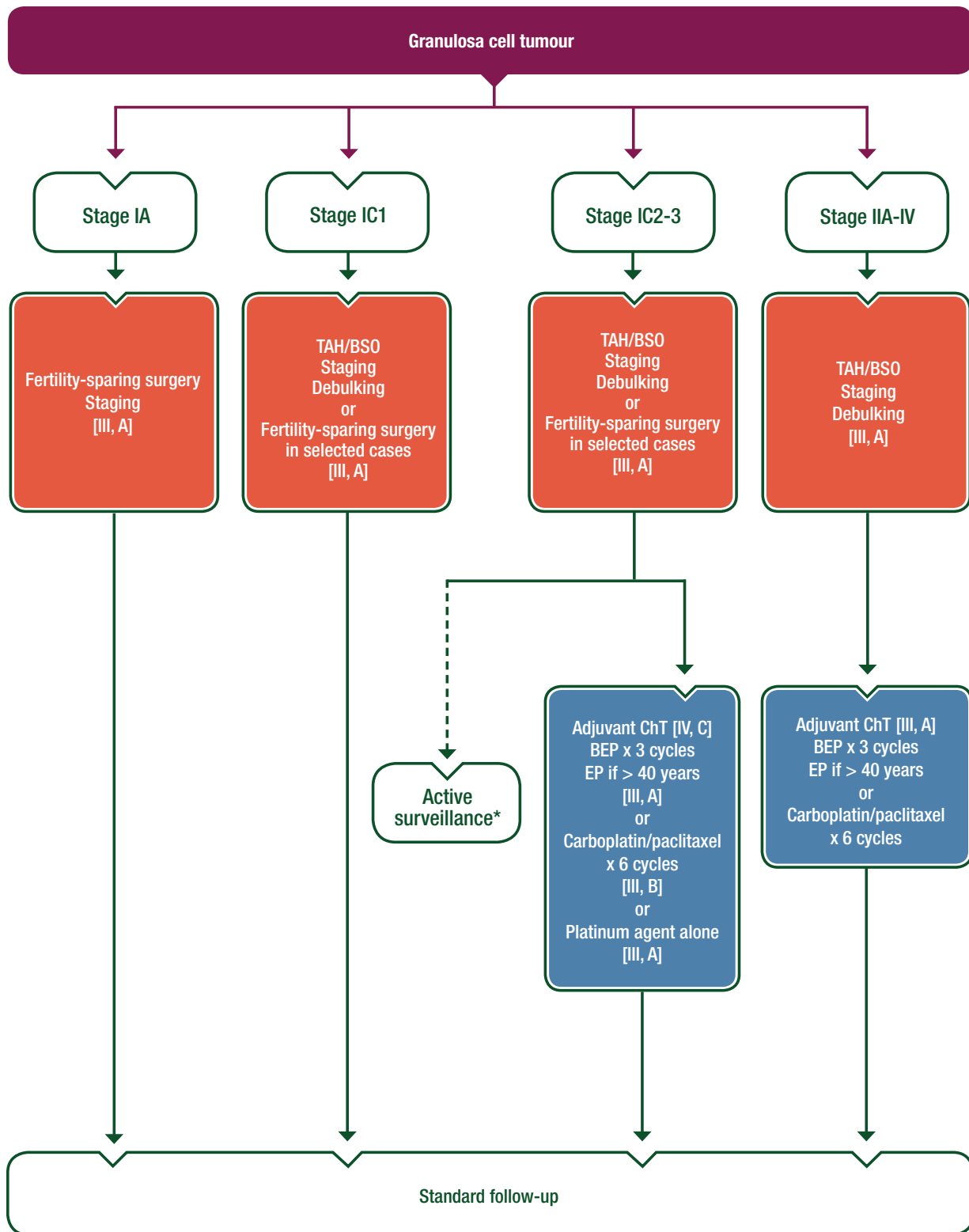
There is no international consensus regarding the optimal treatment of SCCOHT; a multimodal approach including ChT [III, B], radical surgery [IV, A] and possibly RT [IV, C] is often proposed (Figure 6). However, no randomised studies have been conducted to date, and the available published data are composed of case reports or small retrospective series with very heterogeneous management strategies [35].

SCCOHTs are particularly chemosensitive at the outset but there is a risk for a rapid relapse. The choice of regimen is generally extrapolated from data in small cell lung carcinoma. A combination of a cisplatin and etoposide-based therapy is generally considered most appropriate [III, B] [23, 36]. More recently, HDCT for patients who achieved a complete response (CR; after surgery and/or ChT) with autologous stem cell transplantation (ASCT) rescue has been proposed and is associated with better survival [II, C] [24, 36, 37].

Management of advanced disease

Germ cell tumours

Fertility-sparing surgery should also be considered in advanced stages disease as cure rates remain high [IV, B]. The aim of surgery is to remove as much gross tumour as possible; however, the procedure should be moderated to avoid delays in postoperative ChT and



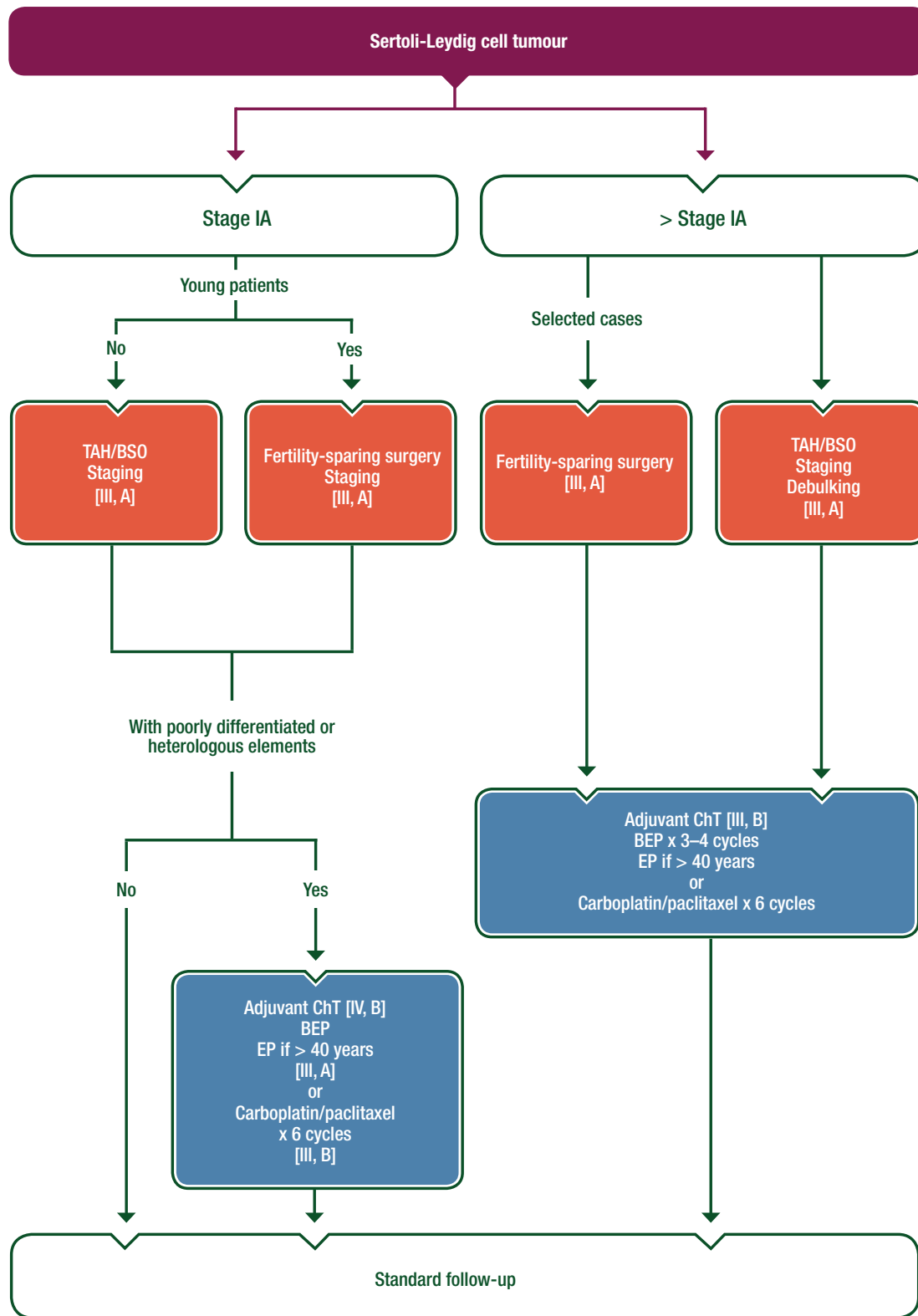
Downloaded from https://academic.oup.com/annonc/article-abstract/29/Supplement_4/iv1/4983953 by guest on 06 August 2019

Figure 4. Management of SCSTs of the ovary—granulosa cell tumour.

*See Table 5.

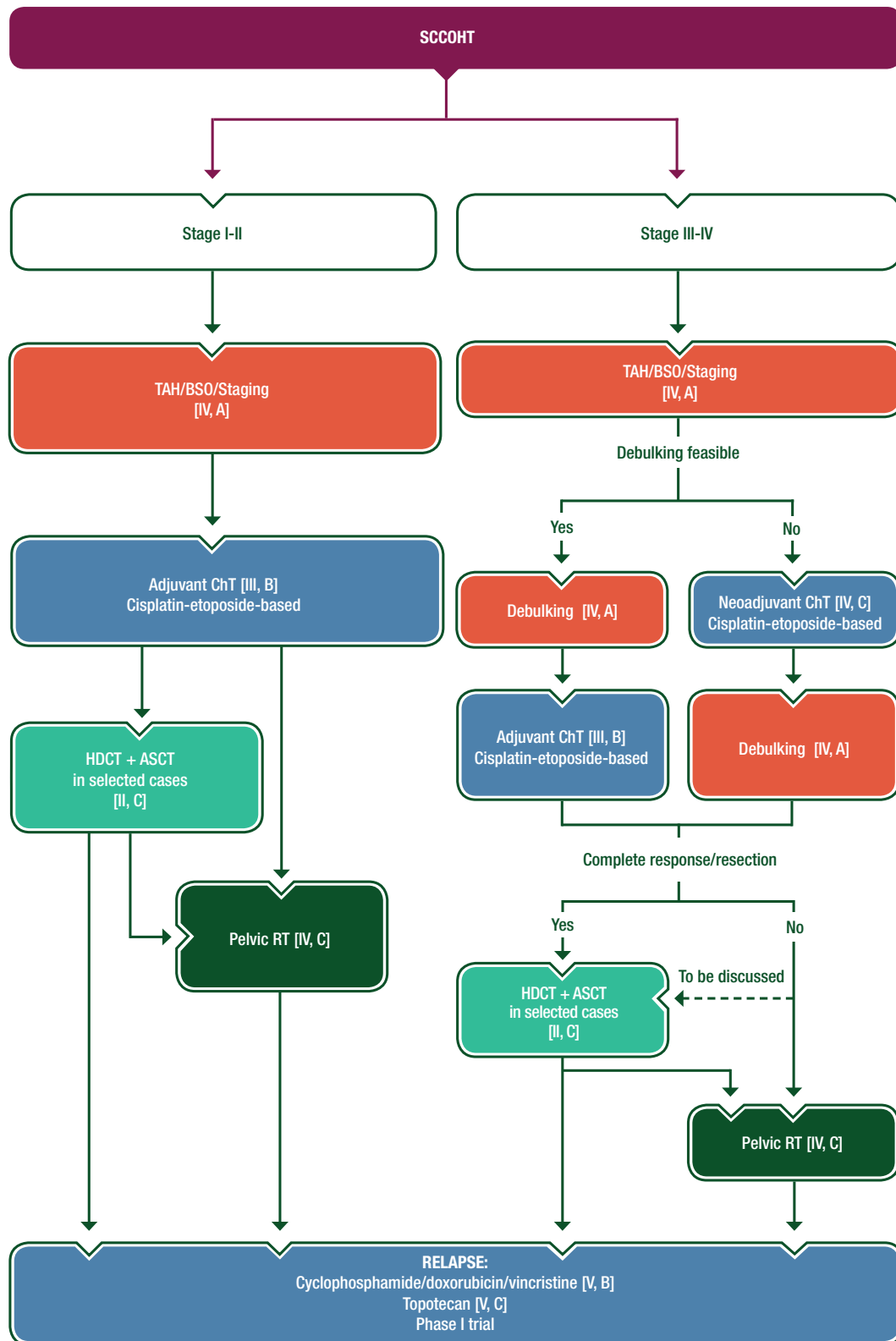
--> Optional

BEP, bleomycin/etoposide/cisplatin; BSO, bilateral salpingo-oophorectomy; ChT, chemotherapy; EP, etoposide/cisplatin; SCST, sex cord-stromal tumour; TAH, total abdominal hysterectomy.



Downloaded from https://academic.oup.com/annonc/article-abstract/29/Supplement_4/iv1/4983953 by guest on 06 August 2019

Figure 5. Management of SCSTs of the ovary—Sertoli–Leydig cell tumour. BEP, bleomycin/etoposide/cisplatin; BSO, bilateral salpingo-oophorectomy; ChT, chemotherapy; EP, etoposide/cisplatin; SCST, sex cord-stromal tumour; TAH, total abdominal hysterectomy.



Downloaded from https://academic.oup.com/annonc/article-abstract/29/Supplement_4/iv1/4983953 by guest on 06 August 2019

Figure 6. Management of SCCOHT.

--> Optional

ASCT, autologous stem cell transplantation; BSO, bilateral salpingo-oophorectomy; ChT, chemotherapy; HDCT, high-dose chemotherapy; RT, radiotherapy; SCCOHT, small cell carcinomas of the ovary hypercalcaemic type; TAH, total abdominal hysterectomy.

Table 7. Summary of recommendations

Diagnosis and pathology/molecular biology

- Diagnostic work-up should include pelvic ultrasound, abdomino-pelvic CT scan and chest X-ray and PET scan in selected cases (GCTs) [III, B]
- In young adult patients, hCG, α -FP, LDH and inhibin B levels, full blood count and liver and renal function tests should be carried out
- In case of suspected gonadoblastomas, a preoperative karyotype should be obtained on all premenarche girls
- Histological second opinion by an expert pathologist should always be considered. Diagnosis can be made on conventional histological material [IV, B]
- Neoplasms of pure ovarian stroma: in morphologically ambiguous cases, an immunopanel of inhibin alpha, calretinin and FOXL2, plus mutational analysis for FOXL2 (402C-G), is useful to confirm AGCTs [V, B]

Staging and risk assessment

- A surgical approach can be carried out through open route or, in selected cases, by laparoscopy and robotics approaches, thereby avoiding tumour rupture during surgery
- A careful examination of the abdominal cavity is required
- The staging procedure includes infracolic omentectomy, biopsy of the diaphragmatic peritoneum, paracolic gutters, pelvic peritoneum and peritoneal washings (macroscopic stage I disease)
- Unilateral salpingo-oophorectomy with preservation of the contralateral ovary and the uterus is considered an adequate surgical treatment for patients with GCTs. This should be considered even in advanced disease because of the sensitivity of the tumour to ChT [IV, B]. No systematic ovarian biopsy is necessary when the contralateral ovary is macroscopically normal [III, A]
- Given the very high chemosensitivity of GCTs, potential nodal metastasis should be cured by adjuvant ChT in these patients [III, A]
- Nodal dissection should be carried out only if evidence of nodal abnormality [III, A]
- For SCSTs, retroperitoneal evaluation is not mandatory [III, A]
- An endometrial curettage must be carried out to rule out concomitant uterine cancers in patients with granulosa cell tumours [IV, B]
- Conservative surgery is also an acceptable approach in young patients with stage I SCSTs [IV, B]
- In postmenopausal women and in patients with advanced-stage disease or with bilateral ovarian involvement, abdominal hysterectomy and bilateral salpingo-oophorectomy should be carried out with careful surgical staging for SCST [III, A]

Early-stage GCTs: management

- Stage IA pure dysgerminoma should be treated with surgery only [III, A]
- Patients with stage IA grade 1 immature teratoma do not require further adjuvant ChT after adequate surgical staging [III, A]
- Adjuvant ChT in stage IA-IC G2-G3 immature teratoma, stage IA-IB YST with negative postoperative tumour markers and IB-IC dysgerminomas is recommended but active surveillance is an option [III, B]
- 5-day BEP is the most used regimen [III, A]
- The close surveillance schedule involves regular clinical review with clinical examination, radiological imaging including abdomen-pelvic intravaginal sonography at regular intervals and the monitoring of tumour markers to detect relapse over a period of 10 years, with a gradual increase of the interval between clinical appointments [III, C]

Advanced-stage and recurrent GCTs: management

- Fertility-sparing surgery should be considered also in advanced stages [IV, B]. The aim of surgery is to remove as much gross tumour as possible; however, the procedure should be moderated to avoid delays in postoperative ChT and long-term morbidity
- In postmenopausal women with advanced-stage disease or with bilateral ovarian involvement, abdominal hysterectomy and bilateral salpingo-oophorectomy could be carried out with careful surgical staging [III, A]
- Platinum-based regimens are the treatment of choice with the BEP regimen being the most widely used, generally, three cycles of 5-day BEP regimen in completely resected disease and four cycles (bleomycin should be omitted to reduce the risk of lung toxicity after the third cycle) for patients with macroscopic residual disease [III, A]
- In patients previously treated with platinum, with platinum-sensitive relapse (progression > 4–6 weeks after completion of ChT), combinations with platinum should be considered [IV, C]
- Patients resistant to a cisplatin-based combination may receive VAC or paclitaxel/gemcitabine or gemcitabine/oxaliplatin as salvage therapy [IV, C]
- HDCT for recurrent ovarian GCTs may result in durable and prolonged remissions [IV, C]
- Any resectable residual disease should be removed, particularly for patients with normal serum marker and for patients with immature teratoma in order to avoid the growing teratoma syndrome [III, A]

Early-stage SCSTs: management

- Stage IA granulosa cell tumour disease has an excellent prognosis after surgery alone and does not require adjuvant therapy [III, A]
- Adjuvant therapy should be considered for juvenile granulosa tumour stage IC patients [IV, B] or for AGCT stage IC2-IC3 patients [IV, C]. In these cases, platinum-based ChT is the treatment of choice [III, A]
- For SLCTs, postoperative adjuvant ChT should be considered for patients with stage I poorly differentiated or heterologous elements (mesenchymal type) [IV, B]
- BEP is the most commonly used regimen [III, A]. Alternative ChT options include paclitaxel and carboplatin [III, B], EP, CAP or platinum agent alone [III, A]

Advanced-stage and recurrent SCSTs: management

- Debulking surgery remains the most effective treatment of advanced or recurrent granulosa cell tumour [III, A]
- Platinum-based ChT is currently used for patients with advanced-stage SCSTs or recurrent disease [III, A]
- BEP regimen for three cycles or six cycles of carboplatin/paclitaxel is recommended for postoperative ChT and patients with recurrent SCSTs [III, A]

Continued

Table 7. *Continued*

- Patients with steroid cell tumours that are pleomorphic, large, at an advanced stage or with an increased mitotic count should be treated with additional postoperative platinum-based ChT, either BEP (if not previously used) or a taxane–platinum combination [IV, C]
- Response to GnRH agonists, tamoxifen, progestin and AIs has been reported and could be an interesting option specifically for adult GCT [IV, B]
- For patients with persistent SLCTs, adjuvant ChT should be considered [III, B]

Early and advanced SCCOHT: management

- All suspected cases should benefit from a review by an expert pathologist and be discussed in a specialised tumour board [V, A]
- Optimal treatment: a multimodal approach including ChT [III, B], radical surgery [IV, A], HDCT [II, C] and RT [IV, C]
- Debulking surgery (initial or interval) remains the most effective treatment [IV, A]
- Combination of a cisplatin- and etoposide-based therapy is the most appropriate for all stages [III, B]
- The use of pelvic RT, either concurrently or sequentially to HDCT and ASCT, may be considered for patients after surgery [IV, C]
- Efforts should be made to treat patients in a more homogeneous way through national and international networks [V, A]

Response evaluation and follow-up after initial treatment

- Serum tumour markers (hCG, α -FP, LDH, CA 125 and inhibin B) can correlate with tumour response during ChT [V, A]
- A CT scan of the abdomen, pelvis and chest (in case of suspected lung metastases) and pelvic ultrasound are the most common and useful imaging techniques to evaluate the response to ChT [V, A]
- For GCT, follow-up visits must include history, physical examination with pelvic examination and tumour markers every 3 months for the first 2 years, then every 6 months during the third year and then yearly until progression [V, A]
- For SCSTs, follow-up visits including physical exam and tumour markers must be carried out every 6 months starting from the third year and this frequency should be maintained indefinitely [V, B]
- A pelvic ultrasound should be carried out every 6 months in those patients who have undergone fertility-sparing surgery, whereas a CT scan of the abdomen and pelvis is carried out according to clinical indication
- PET scan for tumour response evaluation or follow-up is not yet recommended [V, D]

Fertility and hormone replacement

- Oocyte cryopreservation is an option for patients scheduled to receive ChT [V, C]
- Hyperstimulation followed by oocyte cryopreservation 12 months after the end of ChT is another option [V, C]
- Fertility preservation should not jeopardise the oncological management
- HRT may be used safely for many GCTs [V, A]
- An HRT approach should be avoided for SCST [V, D]

α -FP, alpha foetoprotein; AGCT, adult granulosa cell tumour; AI, aromatase inhibitor; ASCT, autologous stem cell transplantation; BEP, bleomycin/etoposide/cisplatin; CA 125, cancer antigen 125; CAP, cyclophosphamide/doxorubicin/cisplatin; ChT, chemotherapy; CT, computed tomography; EP, etoposide/cisplatin; GCT, germ cell tumour; GnRH, gonadotropin-releasing hormone; hCG, human chorionic gonadotropin; HDCT, high-dose chemotherapy; HRT, hormone replacement therapy; LDH, lactate dehydrogenase; PET, positron emission tomography; RT, radiotherapy; SCCOHT, small cell carcinoma of the ovary hypercalcaemic type; SCST, sex cord-stromal tumour; SLCT, Sertoli-Leydig cell tumour; VAC, vincristine/actinomycin D/cyclophosphamide; YST, yolk sac tumour.

long-term morbidity. These tumours are highly chemosensitive but grow rapidly and may grow back if there is a delay in starting ChT.

Platinum-based regimens have been the treatment of choice and the 5-day-BEP regimen is the most widely used regimen [38]. While the optimal number of cycles of BEP has not been fully established in randomised trials, three cycles of BEP for completely resected stage I disease and four cycles for those with more advanced disease are recommended [III, A] [2, 39]. Bleomycin should not be given to those > 40 years of age or with pre-existing pulmonary disease, given the risk of drug-related lung injury with an approximate mortality rate of 3% [III, A].

Alternative ChT regimens [POMB/ACE (cisplatin/vincristine/methotrexate/bleomycin/actinomycin D/cyclophosphamide/etoposide) and CBOP/BEP (carboplatin/bleomycin/vincristine/cisplatin/BEP)] have been evaluated, particularly in high-risk patients, reporting high activity and impacting toxicity: unfortunately, none of them has been compared with BEP in randomised trials. A phase II Gynecologic Oncology Group (GOG) trial reported high activity with an acceptable toxicity profile for a carboplatin–etoposide combination in the adjuvant setting of completely resected stages I–III dysgerminomas [40].

Dysgerminomas are very sensitive to RT; however, its use is limited to selected cases because of the negative impact on fertility.

In patients with platinum-sensitive relapse (progression > 4–6 weeks after completion of ChT), ifosfamide/platinum (IP) with or without paclitaxel (P) should be considered as second-line treatment [IV, C] [41]. Further active ChT regimens include: vinblastine/ifosfamide/cisplatin (VeIP) and cisplatin/vinblastine/bleomycin (PVB) [IV, C] [42]. Patients resistant to a cisplatin-based combination may receive vincristine/actinomycin D/cyclophosphamide (VAC) or paclitaxel/gemcitabine or gemcitabine/oxaliplatin as salvage therapy [IV, C].

Although there is a role for ASCT in relapsed testicular cancer, it is not the standard of care for women with relapsed or recurrent malignant ovarian GCTs and its role remains undefined because of the paucity of prospective data. A recent report suggests that HDCT for recurrent ovarian GCTs may result in durable and prolonged remissions [IV, C]. In a retrospective series, Reddy Ammakkanavar et al. [43] treated 13 patients with recurrent malignant ovarian GCTs from 1990 to 2013. All patients had experienced disease progression after standard cisplatin combination treatment. HDCT consisted of tandem courses of carboplatin

Table 8. Table of levels of evidence and grades of recommendation (adapted from the Infectious Diseases Society of America–United States Public Health Service Grading System^a)

Levels of evidence

- I Evidence from at least one large randomised, controlled trial of good methodological quality (low potential for bias) or meta-analyses of well-conducted randomised trials without heterogeneity
- II Small randomised trials or large randomised trials with a suspicion of bias (lower methodological quality) or meta-analyses of such trials or of trials demonstrated heterogeneity
- III Prospective cohort studies
- IV Retrospective cohort studies or case–control studies
- V Studies without control group, case reports, expert opinions

Grades of recommendation

- A Strong evidence for efficacy with a substantial clinical benefit, strongly recommended
- B Strong or moderate evidence for efficacy but with a limited clinical benefit, generally recommended
- C Insufficient evidence for efficacy or benefit does not outweigh the risk or the disadvantages (adverse events, costs, . . .), optional
- D Moderate evidence against efficacy or for adverse outcome, generally not recommended
- E Strong evidence against efficacy or for adverse outcome, never recommended

^aBy permission of the Infectious Diseases Society of America [58].

700 mg/m² and etoposide 750 mg/m² intravenously (i.v.) daily for three consecutive days followed by stem cell infusion. Seven patients achieved CR with four of these seven patients remaining disease free at 12, 22, 120 and 270 months from treatment.

Any resectable residual disease should be removed, particularly for patients with normal serum marker in which residual disease is present on imaging after adjuvant therapy and for patients with immature teratoma, to avoid growing teratoma syndrome [III, A].

The role of secondary cytoreductive surgery for patients with recurrent or progressive ovarian GCT remains controversial. Unlike males, females who have a relapse with malignant disease after primary ChT for GCTs have a poor prognosis.

The role of the new targeted agents in GCTs is yet to be demonstrated. Targeted agents already investigated in testicular tumours and of potential interest include tyrosine kinase inhibitors (imatinib and sunitinib) and anti-angiogenic agents (bevacizumab) [44]. These recent studies involving targeted therapies have been inconclusive. Nevertheless, studies of the management of refractory GCTs are ongoing, with a focus on optimal utilisation of HDCT and ASCT, as well as the role of immune checkpoint inhibitors in refractory GCTs [45]. Studies aiming to identify the patients who may benefit from more intensive treatment up front to prevent the development of refractory disease are also in progress for testicular GCTs, and the results may be useful for ovarian GCT patients [46].

Sex cord-stromal tumours

Debulking surgery, whenever feasible, remains the most effective treatment for metastatic or recurrent granulosa cell tumours [III,

A]. Platinum-based ChT is currently used for patients with advanced-stage SCSTs or recurrent disease, with an overall response rate of 63%–80% [47]. Unfortunately, most patients with advanced disease do not have durable remissions. Patients with advanced disease have poor prognosis and they are, therefore, treated with adjuvant therapy, although the data are very limited [IV, C]. The BEP regimen for three cycles or carboplatin/paclitaxel for six cycles is currently recommended for adjuvant postoperative ChT and for patients with recurrent SCSTs [III, A].

Patients with steroid cell tumours that are pleomorphic, large, at an advanced stage or with non-operable residual disease or with an increased mitotic count should be treated with additional postoperative platinum-based ChT, either with BEP (if not previously used), or with a taxane-platinum combination [IV, C].

The GOG is currently conducting a randomised phase II trial of BEP versus the combination of paclitaxel and carboplatin for patients with newly diagnosed and ChT-naïve recurrent metastatic SCSTs of the ovary [48].

Alternative ChT options include: PVB, EP, CAP, VAC and weekly paclitaxel for relapsed patients after platins. There are limited data regarding the utility of ChT in patients with persistent SLCTs, but responses in patients with measurable disease have been reported [III, B].

Given the functional hormonal nature of granulosa cell tumours that express steroid hormone receptors, there is some rationale for a hormone-based approach. Response to gonadotropin-releasing hormone (GnRH) agonists, tamoxifen, progestin and aromatase inhibitors (AIs) has been reported. In a recent review, Van Meurs et al. reported the results of 31 patients treated with hormone therapy; a CR was described in 25.8% of patients and a partial response in 45.2% [49]. Despite limited available data, hormone therapy appears to be a useful alternative treatment for patients with advanced-stage or recurrent AGCTs [IV, B]. The role of AIs for relapsed granulosa cell tumours is being assessed in the multicentre phase II PARAGON trial (ANZGOG-0903).

Anti-angiogenic agents have also been investigated in patients with recurrent AGCT, due to the overexpression of vascular endothelial growth factor and vascularity of these tumours. A recent study at the MD Anderson Cancer Center seems to confirm the potential activity of bevacizumab [response rate 17%, stable disease (SD) 77%] [50], although the study was conducted in only 36 patients [III, C]. The GINECO group (Groupe d'Investigateurs Nationaux pour les Etudes des Cancers de l'Ovaire) is currently conducting a phase II trial (ALIENOR-ENGOT-ov7/GINECO), to explore the clinical benefit of adding bevacizumab to weekly paclitaxel followed by bevacizumab as maintenance versus weekly paclitaxel followed by observation in patients with relapsed SCSTs [51].

Small cell carcinomas of the ovary hypercalcaemic type

For selected patients with bulky stage III disease or stage IV disease where primary debulking surgery is not considered to be achievable, the use of neoadjuvant ChT may be considered on an individual basis after discussion with the tumour board [IV, C].

A combination of a cisplatin and etoposide-based therapy is generally considered most appropriate [III, B] [22, 36]. As reported in early stage, HDCT for patients who underwent a CR (after surgery and/or ChT) with ASCT rescue has been proposed and is associated with better prognosis [II, C] [23, 34, 37]. Even with intensive regimens, prognosis remains dismal, and despite frequent initial responses to ChT, relapses are frequent and tend to be refractory to second-line ChT.

The management of relapsed disease is often very challenging, and prolonged remissions are never achieved with second-line ChT regimens usually used in small cell lung carcinomas. Several schedules have been reported including the combination of cyclophosphamide, doxorubicin and vincristine [V, B]. There are anecdotal reports on carboplatin and paclitaxel including dose-dense regimens, and topotecan has also shown some modest activity as in small cell lung cancers [V, C]. To date, no targeted therapies have been tested in SCCOHT. Second-line treatment is likely to achieve short remission rates, and beyond that, patients should be considered for phase I trials if they remain of good performance status.

Follow-up, long-term implications and survivorship

Response evaluation and follow-up programme for post-ChT

Germ cell tumours. The surveillance follow-up programme for patients not undergoing postoperative ChT has been detailed previously. For patients undergoing ChT, serum tumour markers (hCG, α -FP, LDH, CA 125 and inhibin B) can accurately correlate with tumour response during ChT [V, A]. A CT scan of the abdomen, pelvis and chest (in case of suspected lung metastases) and pelvic ultrasound are the most common and useful imaging techniques to evaluate the response to ChT in patients with measurable disease [V, A]. Approximately 75% of GCT recurrences occur within the first year after initial management; the peritoneal cavity is the most common site of recurrence, while retroperitoneal lymph node involvement is very uncommon. Given that the majority of women with GCTs have an excellent survival outcome, persistence of long-term effects of treatment is highly significant. The most frequent side effects of BEP included pulmonary toxicity, decreased diffusing capacity of the lungs for carbon monoxide (DLCO), acute myeloblastic leukaemia (AML), neuropathy, Raynaud's disease, tinnitus, high tone hearing loss, gonadal dysfunction, cardiovascular disease/hypertension and nephrotoxicity (Table 6). One of the most ominous late effects of ChT, particularly for young survivors, is the risk of secondary malignancies. Contrary to what is known for testicular cancer survivors, no study so far has analysed the risk of a solid second cancer in GCTs. Recently, the Cancer Registry of Norway has reported the cumulative incidence of a second cancer in 10-year GCT survivors [19]. A second cancer was diagnosed in 23 of 139 survivors who underwent cytotoxic treatment. Interestingly, among these 23 cases, 18 had received abdominal RT and 16 of them had their second malignancy occur below the diaphragm. Three uterine tumours and two malignant melanomas occurred

among 41 patients treated only with ChT. Due to the low number of cases, the role of ChT in the development of second malignancies cannot be assessed.

Follow-up visits for GCT patients must include history, physical and pelvic examinations and exploration of tumour markers every 3 months for the first 2 years, every 6 months during the third year and then yearly until progression [V, A]. Tumour marker exploration can be avoided from the third year.

Sex cord-stromal tumours. Conversely, SCSTs have an indolent course with tendency for late recurrence (the median time to relapse is approximately 4–6 years), therefore patients with SCSTs require long-term follow-up [47]. Several reports describe relapses occurring more than 20 years (up to 37 years) after diagnosis. Common sites of recurrence are the upper abdomen (55%–70%) and the pelvis (30%–45%).

In the case of SCSTs, follow-up visits including physical exam and tumour marker exploration (e.g. inhibin B, AMH) must be carried out every 6 months starting from the third year and this frequency should be maintained indefinitely [V, B]. Pelvic ultrasound should be carried out every 6 months in those patients who have undergone fertility-sparing surgery. CT scan or magnetic resonance imaging (MRI) should be carried out when clinically indicated, based on symptoms or tumour marker elevation.

The use of PET scan for tumour response evaluation or follow-up is not well established yet, as this is not recommended in GCTs [V, D].

Fertility preservation in non-epithelial ovarian cancer. Fertility preservation should not jeopardise the oncological management. For non-epithelial ovarian cancer, much of the literature on fertility has been focused on young women who harbour GCTs.

GCTs account for less than 5% of all ovarian malignancies and are typically diagnosed in young females, at the peak of their reproductive age. After introduction of cisplatin-based ChT, most young women with GCTs treated according to the current therapeutic approach will survive the disease. However, this success must be balanced against possible treatment-associated long-term adverse effects, gonadal dysfunction being among the most feared. The likelihood of ChT-induced amenorrhoea is based on the specific administered ChT, its cumulative drug dose and duration of therapy. In general, cisplatin is viewed to be only moderately gonadotoxic; a significant association between increased cumulative doses of cisplatin-based ChT and reduced gonadal function has been shown in males with germ cell cancer [38]. Recently, the work published by Solheim et al. has shown a similar dose-dependent risk of gonadal dysfunction in females [19]. This group reports that the cumulative probability of achieving pregnancy after treatment was significantly higher in women who received no adjuvant treatment or no more than three cycles of cisplatin-based ChT compared with those who had >3 cycles of cisplatin- or non-cisplatin-based postoperative treatment. In addition, the fertility outcome, namely the return of menstruation and ovulation, depends on age: the younger the patient, the larger the reserve of oocytes harvested after ChT [52]. The infertility rate reported among women attempting conception after treatment for GCTs is 5%–10% [26, 53] which is almost comparable to the rate among age-matched women in

the general population [54]. Nevertheless, oocyte cryopreservation is an option for patients scheduled to receive ChT [V, C]. The recommended approach is to postpone cancer treatment to enable ovulation induction and oocyte aspiration. Whenever possible, the retrieved oocytes should be *in vitro* fertilised prior cryopreservation, with donor sperm offered to single patients [55]. These frozen embryos may be used to achieve pregnancies if ChT-related ovarian failures occur. Another approach is controlled ovarian hyperstimulation followed by oocyte cryopreservation 12 months after the end of ChT, in the scenario of a rapid decline in ovarian reserve [V, C]. However, due to the rarity of GCTs, experience with this approach is limited.

There is an increasing evidence for efficacy in reducing premature ovarian insufficiency with the use of GnRH agonists in patients with breast cancer undergoing ChT. However, there is no evidence in other cancers and certainly none in these rare diseases [56].

Hormone replacement therapy and contraception

ChT has long-term effects on gonadal function and may lead to ovarian dysfunction and sterility. Factors such as cumulative drug dose, duration of therapy and age at treatment influence the incidence of ovarian failure function. Those patients who suffer from iatrogenic menopause usually have more pronounced symptoms in comparison with those following a naturally occurring menopause, mainly due to the sudden cessation of ovarian hormone production and younger age. In this field, the GOG carried out an analysis evaluating the quality of life and the reproductive and psychosocial characteristics of survivors of GCTs compared with matched controls [57]. At a median follow-up of 10.2 years, these women appeared to be free of any major physical illnesses compared with matched controls. The only differences consisted of higher rates of reported hypertension, hypercholesterolaemia and hearing loss. Among chronic functional problems, numbness, tinnitus and Raynaud's symptoms were reported more frequently by survivors. In spite of persistence of a few sequelae of treatment, in general, GCT survivors enjoy a healthy life comparable to that of controls.

Hormone replacement therapy (HRT) for germ cell and sex cord ovarian malignancies is important to consider; most cases occur in young premenopausal women who could enter the menopause as a consequence of radical treatment and would be exposed to several decades of oestrogen deficiency. Symptoms of iatrogenic menopause are usually more pronounced compared with a regular menopause due to the sudden cessation of ovarian hormone production, younger age and additional physical and psychological symptoms associated with cancer therapy.

HRT is an effective treatment mainly used for the treatment of vasomotor symptoms, low mood, sexual dysfunction and urogenital symptoms following the menopause. Moreover, it may dramatically improve physical and psychological symptoms and, in the end, the quality of life in cancer patients.

Although, there is no trial evaluating the use of HRT in germ cell and sex cord ovarian cancer patients, it is generally considered that HRT may be used safely for GCTs [V, A]. In the case of ovarian granulosa cell tumours and other sex cord-stromal malignancies, e.g. SLCTs which are thought to be hormone

dependent, an HRT approach should be avoided following their diagnosis [V, D].

Hormonal contraception is not contraindicated for women diagnosed with GCTs receiving fertility-sparing treatment and wanting to postpone or avoid pregnancies [V, B].

Methodology

These Clinical Practice Guidelines were developed in accordance with the ESMO standard operating procedures for Clinical Practice Guidelines development <http://www.esmo.org/Guidelines/ESMO-Guidelines-Methodology>. The relevant literature has been selected by the expert authors. A summary of recommendations is presented in Table 7. Levels of evidence and grades of recommendation have been applied using the system presented in Table 8. Statements without grading were considered justified standard clinical practice by the experts and the ESMO faculty. This manuscript has been subjected to an anonymous peer review process.

Disclosure

IRC has reported advisory board membership for Roche, Clovis, AstraZeneca, Tesaro, PharmaMar, Amgen, Merck Sharp & Dohme, Vifor Pharma and has received research support from PharmaMar; DL has reported advisory board membership for Roche, Clovis, AstraZeneca and has received research support from PharmaMar; AO has reported advisory board membership for Roche, Clovis, AstraZeneca and PharmaMar; NC is a member of the Roche speakers' bureau; PM, JP and PP have reported no conflicts of interest.

References

- Gatta G, van der Zwan JM, Casali PG et al. Rare cancers are not so rare: the rare cancer burden in Europe. *Eur J Cancer* 2011; 47: 2493–2511.
- Young RH, Oliva E, Scully RE. Small cell carcinoma of the ovary, hypercalcemic type. A clinicopathological analysis of 150 cases. *Am J Surg Pathol* 1994; 18: 1102–1116.
- Prat J. Ovarian sex cord-stromal and steroid cell tumors (Chapter 28). In Mutter GL, Prat J (eds), *Pathology of the Female Reproductive Tract*, 3rd edition. Churchill Livingstone (Elsevier), Edinburgh 2014.
- Lane AH, Lee MM, Fuller AF Jr et al. Diagnostic utility of Müllerian inhibiting substance determination in patients with primary and recurrent granulosa cell tumors. *Gynecol Oncol* 1999; 73: 51–55.
- Gershenson DM. Current advances in the management of malignant germ cell and sex cord-stromal tumors of the ovary. *Gynecol Oncol* 2012; 125: 515–517.
- Prat J, Cao D, Carinelli S et al. Teratoma (Chapter 1: Tumours of the ovary). In Kurman RJ, Carcangiu ML, Herrington CS, Young RH (eds), *WHO Classification of Tumours of Female Reproductive Organs*, 4th edition. IARC: Lyon 2014; 57–62.
- Prat J, Cao D, Carinelli S et al. Monodermal teratomas and somatic-type tumours arising from a dermoid cyst (Chapter 1: Tumours of the ovary). In: Kurman RJ, Carcangiu ML, Herrington CS, Young RH (eds), *WHO Classification of Tumours of Female Reproductive Organs*, 4th edition. IARC: Lyon 2014; 63–66.
- O'Connor DM, Norris HJ. The influence of grade on the outcome of stage I ovarian immature (malignant) teratomas and the reproducibility of grading. *Int J Gynecol Pathol* 1994; 13: 283–289.

9. Al-Agha OM, Huwait HF, Chow C et al. FOXL2 is a sensitive and specific marker for sex cord-stromal tumors of the ovary. *Am J Surg Pathol* 2011; 35: 484–494.
10. Chang HM, Cheng JC, Taylor E, Leung PC. Oocyte-derived BMP15 but not GDF9 down-regulates connexin43 expression and decreases gap junction intercellular communication activity in immortalized human granulosa cells. *Mol Hum Reprod* 2014; 20: 373–383.
11. Foulkes WD, Clarke BA, Hasselblatt M et al. No small surprise—small cell carcinoma of the ovary, hypercalcaemic type, is a malignant rhabdoid tumour. *J Pathol* 2014; 233: 209–214.
12. Jelinic P, Mueller JJ, Olvera N et al. Recurrent SMARCA4 mutations in small cell carcinoma of the ovary. *Nat Genet* 2014; 46: 424–426.
13. Ramos P, Karnezis AN, Craig DW et al. Small cell carcinoma of the ovary, hypercalcaemic type, displays frequent inactivating germline and somatic mutations in SMARCA4. *Nat Genet* 2014; 46: 427–429.
14. Karnezis AN, Wang Y, Ramos P et al. Dual loss of the SWI/SNF complex ATPases SMARCA4/BRG1 and SMARCA2/BRM is highly sensitive and specific for small cell carcinoma of the ovary, hypercalcaemic type. *J Pathol* 2016; 238: 389–400.
15. Hasselblatt M, Gesk S, Oyen F et al. Nonsense mutation and inactivation of SMARCA4 (BRG1) in an atypical teratoid/rhabdoid tumor showing retained SMARCB1 (INI1) expression. *Am J Surg Pathol* 2011; 35: 933–935.
16. Schneppenheim R, Frühwald MC, Gesk S et al. Germline nonsense mutation and somatic inactivation of SMARCA4/BRG1 in a family with rhabdoid tumor predisposition syndrome. *Am J Hum Genet* 2010; 86: 279–284.
17. Karanian-Philippe M, Velasco V, Longy M et al. SMARCA4 (BRG1) loss of expression is a useful marker for the diagnosis of ovarian small cell carcinoma of the hypercalcaemic type (ovarian rhabdoid tumor): a comprehensive analysis of 116 rare gynecologic tumors, 9 soft tissue tumors, and 9 melanomas. *Am J Surg Pathol* 2015; 39: 1197–1205.
18. Prat J. FIGO Committee on Gynecologic Oncology. Staging classification for cancer of the ovary, fallopian tube, and peritoneum. *Int J Gynaecol Obstet* 2014; 124: 1–5.
19. Solheim O, Kærn J, Tropé CG et al. Malignant ovarian germ cell tumors: presentation, survival and second cancer in a population based Norwegian cohort (1953–2009). *Gynecol Oncol* 2013; 131: 330–335.
20. Mangili G, Sigismondi C, Gadducci A et al. Outcome and risk factors for recurrence in malignant ovarian germ cell tumors: a MITO-9 retrospective study. *Int J Gynecol Cancer* 2011; 21: 1414–1421.
21. de la Motte Rouge T, Pautier P, Genestie C et al. Prognostic significance of an early decline in serum alpha-fetoprotein during chemotherapy for ovarian yolk sac tumors. *Gynecol Oncol* 2016; 142: 452–457.
22. Reed NS, Pautier P, Avall-Lundqvist E et al. Gynecologic Cancer InterGroup (GCIG) consensus review for ovarian small cell cancers. *Int J Gynecol Cancer* 2014; 24 (9 Suppl 3): S30–S34.
23. Bristow RE, Tomacruz RS, Armstrong DK et al. Survival effect of maximal cytoreductive surgery for advanced ovarian carcinoma during the platinum era: a meta-analysis. *J Clin Oncol* 2002; 20: 1248–1259.
24. Mangili G, Sigismondi C, Lorusso D et al. The role of staging and adjuvant chemotherapy in stage I malignant ovarian germ cell tumors (MOGTs): the MITO-9 study. *Ann Oncol* 2017; 28: 333–338.
25. Billmire D, Vinocur C, Rescorla F et al. Outcome and staging evaluation in malignant germ cell tumors of the ovary in children and adolescents: an Intergroup study. *J Pediatr Surg* 2004; 39: 424–429.
26. Matei D, Brown J, Frazier L. Updates in the management of ovarian germ cell tumors. *Am Soc Clin Oncol Educ Book* 2013; e210.
27. Low JJ, Perrin LC, Crandon AJ, Hacker NF. Conservative surgery to preserve ovarian function in patients with malignant ovarian germ cell tumors. A review of 74 cases. *Cancer* 2000; 89: 391–398.
28. Brown J, Friedlander M, Backes FJ et al. Gynecologic Cancer Intergroup (GCIG) consensus review for ovarian germ cell tumors. *Int J Gynecol Cancer* 2014; 24(9 Suppl 3): S48–S54.
29. Nasioudis D, Kanninen TT, Holcomb K et al. Prevalence of lymph node metastasis and prognostic significance of lymphadenectomy in apparent early-stage malignant ovarian sex cord-stromal tumors. *Gynecol Oncol* 2017; 145: 243–247.
30. Billmire DF, Cullen JW, Rescorla FJ et al. Surveillance after initial surgery for pediatric and adolescent girls with stage I ovarian germ cell tumors: report from the Children's Oncology Group. *J Clin Oncol* 2014; 32: 465–470.
31. Dark GG, Bower M, Newlands ES et al. Surveillance policy for stage I ovarian germ cell tumors. *J Clin Oncol* 1997; 15: 620–624.
32. Vazquez I, Rustin GJ. Current controversies in the management of germ cell ovarian tumours. *Curr Opin Oncol* 2013; 25: 539–545.
33. Wilson MK, Fong P, Mesnage S et al. Stage I granulosa cell tumours: a management conundrum? Results of long-term follow up. *Gynecol Oncol* 2015; 138: 285–291.
34. Brown J, Shvartsman HS, Deavers MT et al. The activity of taxanes in the treatment of sex cord-stromal ovarian tumors. *J Clin Oncol* 2004; 22: 3517–3523.
35. Callegaro-Filho D, Gershenson DM, Nick AM et al. Small cell carcinoma of the ovary-hypercalcaemic type (SCCOHT): a review of 47 cases. *Gynecol Oncol* 2016; 140: 53–57.
36. Pautier P, Ribrag V, Duvillard P et al. Results of a prospective dose-intensive regimen in 27 patients with small cell carcinoma of the ovary of the hypercalcaemic type. *Ann Oncol* 2007; 18: 1985–1989.
37. Witkowski L, Goudie C, Ramos P et al. The influence of clinical and genetic factors on patient outcome in small cell carcinoma of the ovary, hypercalcaemic type. *Gynecol Oncol* 2016; 141: 454–460.
38. Pectasides D, Pectasides E, Kassanos D. Germ cell tumors of the ovary. *Cancer Treat Rev* 2008; 34: 427–441.
39. Williams SD. Current management of ovarian germ cell tumors. *Oncology (Williston Park)* 1994; 8: 53–60.
40. Williams SD, Kauderer J, Burnett AF et al. Adjuvant therapy of completely resected dysgerminoma with carboplatin and etoposide: a trial of the Gynecologic Oncology Group. *Gynecol Oncol* 2004; 95: 496–499.
41. Loehrer PJ Sr, Lauer R, Roth BJ et al. Salvage therapy in recurrent germ cell cancer: ifosfamide and cisplatin plus either vinblastine or etoposide. *Ann Intern Med* 1988; 109: 540–546.
42. Einhorn LH. Chemotherapeutic and surgical strategies for germ cell tumors. *Chest Surg Clin N Am* 2002; 12: 695–706.
43. Reddy Ammakkanavar N, Matei D, Abonour R, Einhorn LH. High-dose chemotherapy for recurrent ovarian germ cell tumors. *J Clin Oncol* 2015; 33: 226–227.
44. Manchana T, Ittiwut C, Mutirangura A, Kavanagh JJ. Targeted therapies for rare gynaecological cancers. *Lancet Oncol* 2010; 11: 685–693.
45. Chi EA, Schweizer MT. Durable response to immune checkpoint blockade in a platinum-refractory patient with nonseminomatous germ cell tumor. *Clin Genitourin Cancer* 2017; 15: e855–e857.
46. Allen JC, Kirschner A, Scarpatto KR, Morgans AK. Current management of refractory germ cell tumors and future directions. *Curr Oncol Rep* 2017; 19: 8.
47. Ray-Coquard I, Brown J, Harter P et al. Gynecologic Cancer InterGroup (GCIG) consensus review for ovarian sex cord stromal tumors. *Int J Gynecol Cancer* 2014; 24(9 Suppl 3): S42–S47.
48. NCT01042522. <https://clinicaltrials.gov/show/NCT01042522> (9 February 2018, date last accessed).
49. van Meurs HS, van Lonkhuijzen LR, Limpens J et al. Hormone therapy in ovarian granulosa cell tumors: a systematic review. *Gynecol Oncol* 2014; 134: 196–205.
50. Brown J, Brady WE, Schink J et al. Efficacy and safety of bevacizumab in recurrent sex cord-stromal ovarian tumors: results of a phase 2 trial of the Gynecologic Oncology Group. *Cancer* 2014; 120: 344–351.
51. NCT01770301. <https://clinicaltrials.gov/show/NCT01770301> (12 March 2018, date last accessed).
52. Gershenson DM. Treatment of ovarian cancer in young women. *Clin Obstet Gynecol* 2012; 55: 65–74.
53. Morice P, Pautier P, Fanchin R et al. Therapy Insight: fertility in women after cancer treatment. *Nat Clin Pract Endocrinol Metab* 2007; 3: 819–826.

54. Tomao F, Peccatori F, Del Pup L et al. Special issues in fertility preservation for gynecologic malignancies. *Crit Rev Oncol Hematol* 2016; 97: 206–219.
55. Tewari KS, Di Saia PJ. Ovulatory failure, fertility preservation and reproductive strategies in the setting of gynecologic and non-gynecologic malignancies. *Eur J Gynaecol Oncol* 2006; 27: 449–461.
56. Lambertini M, Ceppi M, Poggio F et al. Ovarian suppression using luteinizing hormone-releasing hormone agonists during chemotherapy to preserve ovarian function and fertility of breast cancer patients: a meta-analysis of randomized studies. *Ann Oncol* 2015; 26: 2408–2419.
57. Champion V, Williams SD, Miller A et al. Quality of life in long-term survivors of ovarian germ cell tumors: a Gynecologic Oncology Group study. *Gynecol Oncol* 2007; 105: 687–694.
58. Dykewicz CA. Summary of the guidelines for preventing opportunistic infections among hematopoietic stem cell transplant recipients. *Clin Infect Dis* 2001; 33: 139–144.