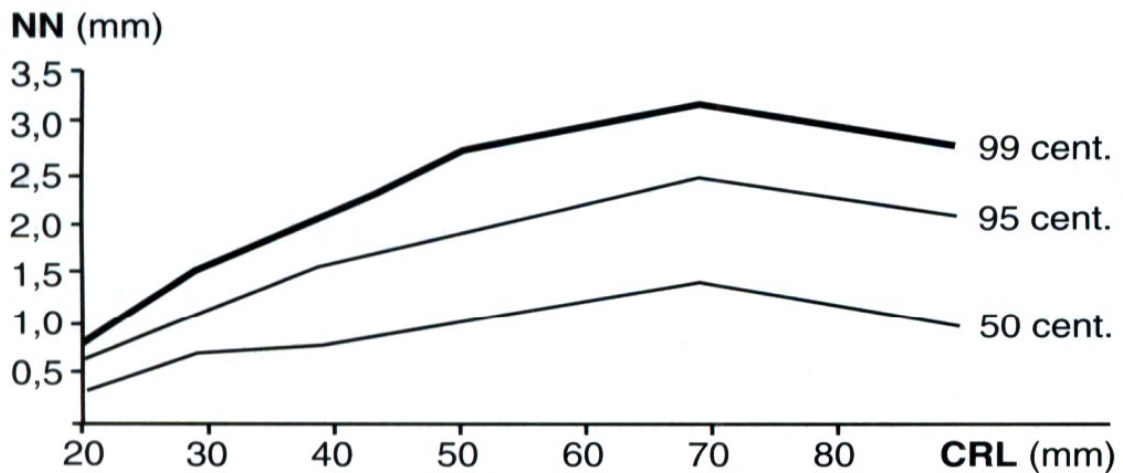


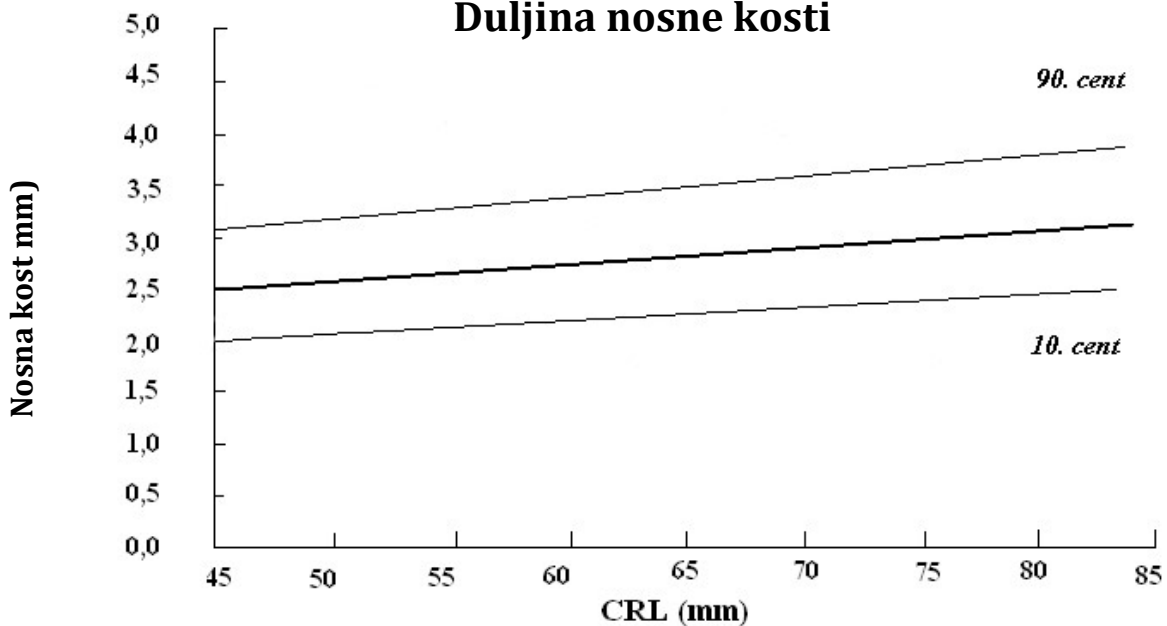


Krivulja rasta nuhalnog zadebljanja



Kurjak A. Kos M. Temelji ultrazvučne dijagnostike u ginekologiji i porodništvu. Art Studio Azinović 1998: 49.

Duljina nosne kosti



Orlandi F et al. Measurement of nasal bone length at 11-14 weeks of pregnancy and its potential role in Down syndrome risk assesment. Ultrasound Obstet Gynecol published online in Wiley Interscience (www.interscience.wiley.com)