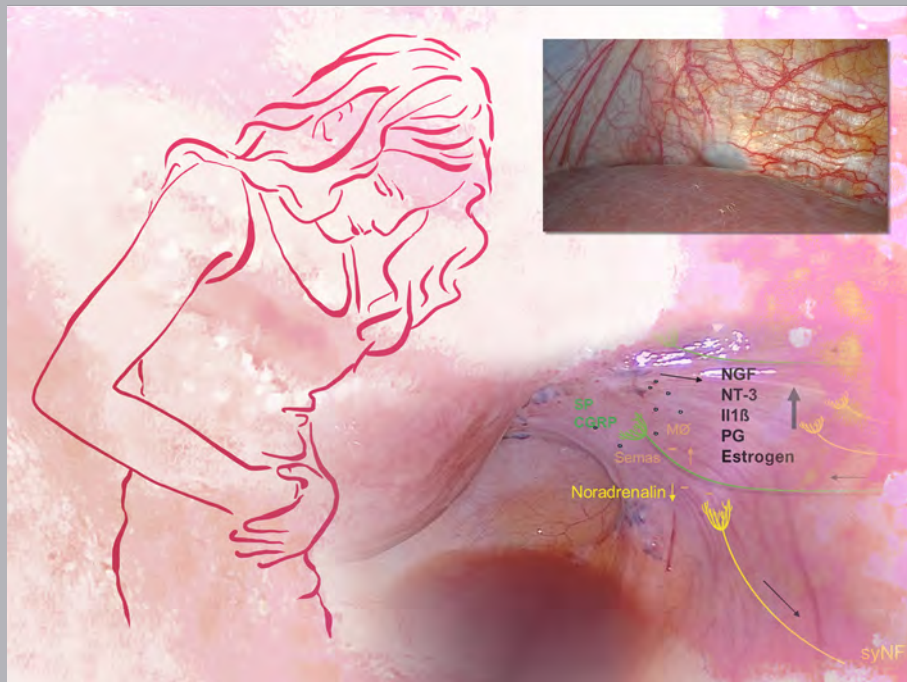


# ENDOMETRIOSIS

A Concise Practical Guide to  
Current Diagnosis and Treatment



Edited by

Liselotte METTLER, Ibrahim ALKATOUT,  
Jörg KECKSTEIN and  
Ivo MEINHOLD-HEERLEIN





# ENDOMETRIOSIS

## A Concise Practical Guide to Current Diagnosis and Treatment

Edited by

Liselotte METTLER,<sup>a</sup> Ibrahim ALKATOUT,<sup>b</sup> Jörg KECKSTEIN<sup>c</sup>  
and Ivo MEINHOLD-HEERLEIN<sup>d</sup>

<sup>a</sup> | Professor Dr. med. habil., Dr. h.c. mult., Department of Obstetrics  
and Gynecology, Kiel School of Gynecological Endoscopy,  
University Hospitals of Schleswig-Holstein, Kiel Campus,  
Kiel, Germany

<sup>b</sup> | Associate Professor Dr. med. habil., Department of Obstetrics and  
Gynecology, Head of the Kiel School of Gynecological Endoscopy,  
University Hospitals of Schleswig-Holstein, Kiel Campus,  
Kiel, Germany

<sup>c</sup> | Professor Dr. med. habil., Head of Department of  
Gynecology and Obstetrics,  
Certified Clinical-Scientific Level III Center for Endometriosis Care,  
Certified Breast Care Center,  
State Hospital of Villach, Carinthia, Austria

<sup>d</sup> | Professor h.c., Professor Dr. med. habil., Vice Director,  
Department of Gynecology and Obstetrics,  
Medical University of the RWTH Aachen, Germany

**Note:** The illustrations shown on the chapter opening pages including the cover page were made by:

**Holger Vanselow**

Im Asemwald 28 I 22  
70599 Stuttgart, Germany  
www.holgervanselow.de  
Email: holger.vanselow@icloud.com

**Important notes:**

Medical knowledge is ever changing. As new research and clinical experience broaden our knowledge, changes in treatment and therapy may be required. The authors and editors of the material herein have consulted sources believed to be reliable in their efforts to provide information that is complete and in accord with the standards accepted at the time of publication. However, in view of the possibility of human error by the authors, editors, or publisher, or changes in medical knowledge, neither the authors, editors, publisher, nor any other party who has been involved in the preparation of this book, warrants that the information contained herein is in every respect accurate or complete, and they are not responsible for any errors or omissions or for the results obtained from use of such information. The information contained within this book is intended for use by doctors and other health care professionals. This material is not intended for use as a basis for treatment decisions, and is not a substitute for professional consultation and/or use of peer-reviewed medical literature.

Some of the product names, patents, and registered designs referred to in this book are in fact registered trademarks or proprietary names even though specific reference to this fact is not always made in the text. Therefore, the appearance of a name without designation as proprietary is not to be construed as a representation by the publisher that it is in the public domain.

The use of this book as well as any implementation of the information contained within explicitly takes place at the reader's own risk. No liability shall be accepted and no guarantee is given for the work neither from the publisher or the editor nor from the author or any other party who has been involved in the preparation of this work. This particularly applies to the content, the timeliness, the correctness, the completeness as well as to the quality. Printing errors and omissions cannot be completely excluded. The publisher as well as the author or other copyright holders of this work disclaim any liability, particularly for any damages arising out of or associated with the use of the medical procedures mentioned within this book.

Any legal claims or claims for damages are excluded.

In case any references are made in this book to any 3<sup>rd</sup> party publication(s) or links to any 3<sup>rd</sup> party websites are mentioned, it is made clear that neither the publisher nor the author or other copyright holders of this book endorse in any way the content of said publication(s) and/or web sites referred to or linked from this book and do not assume any form of liability for any factual inaccuracies or breaches of law which may occur therein. Thus, no liability shall be accepted for content within the 3<sup>rd</sup> party publication(s) or 3<sup>rd</sup> party websites and no guarantee is given for any other work or any other websites at all.

**Endometriosis – A Concise Practical Guide to Current Diagnosis and Treatment**

Edited by **Liselotte Mettler**,<sup>a</sup> **Ibrahim Alkatout**,<sup>b</sup> **Jörg Keckstein**<sup>c</sup> and **Ivo Meinhold-Heerlein**<sup>d</sup>

<sup>a</sup> | Prof. Dr. med. habil. Dr. h.c. mult.; Department of Obstetrics and Gynecology, Kiel School of Gynecological Endoscopy University Hospitals of Schleswig-Holstein, Kiel Campus Kiel, Germany

<sup>b</sup> | Professor Dr. med. habil.; Department of Obstetrics and Gynecology, Head of the Kiel School of Gynecological Endoscopy University Hospitals of Schleswig-Holstein, Kiel Campus Kiel, Germany

<sup>c</sup> | Professor Dr. med. habil.; Head of Department of Gynecology and Obstetrics, Certified Clinical-Scientific Level III Center for Endometriosis Care, Certified Breast Care Center, State Hospital of Villach, Carinthia, Austria

<sup>d</sup> | Professor h.c. Professor Dr. med. habil.; Vice Director, Department of Gynecology and Obstetrics, Medical University of the RWTH Aachen, Germany

**Correspondence address of the editor-in-chief:**

Prof. Dr. med. habil. Dr. h.c. mult. **Liselotte Mettler**  
Kiel School of Gynaecological Endoscopy  
Klinik für Gynäkologie und Geburtshilfe  
Universitätsklinikum Schleswig-Holstein, Campus Kiel  
Arnold Heller Str. 3/24  
24105 Kiel, Germany  
Email: endometriose@uksh.de

All rights reserved.

1<sup>st</sup> Edition

© 2017 Endo : Press® GmbH

P.O. Box, 78503 Tuttlingen, Germany

Phone: +49 (0) 74 61/1 45 90

Fax: +49 (0) 74 61/708-529

E-mail: endopress@t-online.de

No part of this publication may be translated, reprinted or reproduced, transmitted in any form or by any means, electronic or mechanical, now known or hereafter invented, including photocopying and recording, or utilized in any information storage or retrieval system without the prior written permission of the copyright holder.

Editions in languages other than English and German are in preparation. For up-to-date information, please contact Endo : Press® GmbH at the address shown above.

**Design and Composing:**

Endo : Press® GmbH, Germany

**Printing and Binding:**

Straub Druck+Medien AG

Max-Planck-Straße 17, 78713 Schramberg, Germany

04.17-1

**ISBN 978-3-89756-402-2**

## Endometriosis and Pain

### *A Sculpture of the Stiftung Endometriose-Forschung (SEF)*

The idea to design and create a sculpture for the recipient of the bi-annual Rokitansky Award of the 'Scientific Foundation of Endometriosis' was born on the occasion of an exhibition of the Artist's Foundry at Tragwein, Austria in 2013 and was jointly developed by *Felix Buchsbaum* (owner of the hammer mill) and *Peter Oppelt* (Professor of Gynecology and Obstetrics), Linz, Austria.



The holes in the midline of the sculpture represent the center of an endometriotic lesion. The radiating grooves that emanate from the holes symbolize the typical appearance of the scarred surrounding area of such a lesion. Taking into account that a sculpture made from stainless steel would not be suited to reflect the detrimental effects that endometriosis has on women's lives, the decision was made to choose an oxidized, rusty finish.

The award is named after the Austrian pathologist *Carl von Rokitansky* (1804–1878), who was the first to describe the common occurrence of endometrium and smooth muscle cells in the wall of the uterus, which he named 'adenomyosis'.

The recipients of the prize since its inception in 2013 are:

*Paolo Vercellini*, Italy (2013)

*Liselotte Mettler*, Germany (2015)

*Jörg Keckstein*, Austria (2017)

## Preface

With up to 20 % of women suffering from endometriosis, the diagnosis and state-of-the-art treatment of this disease have enormous relevance for women's health. The mainstay for the diagnosis and treatment of endometriosis is laparoscopy surgery. As surgical techniques have been refined over the years and considering that new resection techniques and principles have enabled the gynecologic laparoscopic surgeon to remove previously inoperable deep infiltrating endometriosis, the time has come to publish an up-to-date guide to diagnosis and treatment that is written by experts in the field.

Dealing chiefly with the surgical treatment of endometriosis, this authoritative reference work has been published by an Austrian-German group of scholars, friends, and mentors at the 45-year-old Kiel School of Gynecological Endoscopy. This school is an active part of the Schleswig-Holstein University Medical Center in Kiel, Germany, which is one of the founding faculties of the 350-year-old Christian Albrechts University.

The first clinical description of endometriosis may date back to the German physician *Daniel von Schroen of Jena* (1661–1734) in 1690 and to the Austrian professor *Carl Freiherr von Rokitansky* (1804–1878), who was the first to describe the pathohistology of this condition in Vienna in 1860.

Several of our mentors and masters in Kiel laid the foundations for our work and have also influenced recent developments in endometriosis research and treatment. *Ernst Philipp* (Head of Department of Gynecology and Obstetrics from 1937 to 1961) and *Herbert Huber* (Head of Department from 1961 to 1970) devoted a large part of their scientific research to endometriosis. In 1939, Huber implanted endometriotic tissue into his upper arm as an experiment for his postdoctoral thesis and hoped to observe endometriosis growth. The 'father of laparoscopy,' *Kurt Semm* (Head of Department from 1970 to 1995), founded the German medical journal 'Endometriosis', which was published in six editions annually over a period of 20 years. He established the German and European Endometriosis Societies and is also the founding father of our Kiel School of

Gynecological Endoscopy. *Thoralf Schollmeyer* (Director of the Kiel School, 2006–2014) was senior editor of the *Practical Manual for Laparoscopic and Hysteroscopic Gynecological Surgery*, which was published in 2013 and included chapters dealing specifically with endometriosis.

This book was created with the generous and steadfast support of Dr. h. c. mult. *Sybill Storz*, our living mentor and esteemed partner in the industrial sector. We are grateful to publish our book through Endo:Press® of Tuttlingen, Germany. In addition to continuous, intensive studies and ongoing research into this still enigmatic disease, which requires treatment for life, doctors and patients rely upon high-quality imaging, instrumentation, and equipment to perform advanced endoscopic surgery of endometriosis.

The editors thank all of our authors, who are friends of the Kiel School, for their contributions and diligent work on this book. We express special thanks to our many patients, whose feedback on their sufferings and symptoms helped us to understand key details in the diagnosis and treatment of this disease. We thank *Friedrich Gagstatter*, *Nicole Guckelsberger* and *Dawn Rüter* for their tireless cooperation and secretarial support, and we gratefully acknowledge the work of our illustrator, *Holger Vanselow*. It is our dream that this book can help many of us – students, doctors, scientists, physicians, healthcare workers, and patients – to deepen and broaden our knowledge and foster a precise, individualized approach to the treatment of endometriosis patients.

*Liselotte Mettler*, *Ibrahim Alkatout*,  
*Jörg Keckstein* and *Ivo Meinhold-Heerlein*.

Kiel, Villach and Aachen, May 2017.



*Liselotte Mettler*



*Ibrahim Alkatout*



*Jörg Keckstein*



*Ivo Meinhold-Heerlein*

## Forewords

This manual on the endoscopic surgical treatment of endometriosis is a welcome addition to textbooks on endometriosis. It provides a balanced blend of endometriosis history and discourse on pathogenesis, along with descriptions of clinical symptomatology, medical and surgical therapeutic approaches, and offers suggestions for holistic care of patients. Detailed information on preparations for surgery is provided, along with what surgical instruments and approaches are recommended for various disease phenotypes. In addition, the latest in diagnostic imaging and advanced technologies for surgical therapies are described, and the perennial issue of laparoscopy or assisted reproduction for women with infertility and endometriosis is discussed. A highlight of the manual is the section on ‘special situations’ with detailed information about managing endometriosis in women with infertility, endometriosis-related pain, postsurgical management, nerve-sparing surgery, pelvic floor reconstruction, the role of robotics and definitive surgery in special situations, endometriosis-associated malignancies, treating the adolescent with endometriosis and pelvic pain,

and controversies in the surgical management of adenomyosis. Other strengths of this manual are the detailed sections on diagnosing and managing endometriosis of the urinary tract and bowel. Overall, the authors have provided a timely and practical manual that will be of great value to clinicians, patients, and trainees now and in the future.



*Linda C. Giudice*

MD, PhD, MSc

President, World Endometriosis Society.

Distinguished Professor and Chair,  
Department of Obstetrics, Gynecology  
and Reproductive Sciences.

The Robert B. Jaffe Endowed Professor  
in the Reproductive Sciences.

Director, Center for Origins and Biological  
Consequences of Human Infertility.

Director, Center for Women’s Repro-  
ductive Health Research Career  
Development, University of California,  
San Francisco, USA.



## Forewords

Endometriosis affects an estimated 10 to 15% of the female population. It has various presentations and degrees of severity. In its most severe form this disease is very debilitating for patients, compromising their social, professional, and personal life. It has become a major public health problem associated with high monetary costs and a significant decline in productivity.

Endometriosis, including its severe form, was described in the early 1900s. Since that time very little progress has been made in our understanding of the disease. Today the progressive nature of endometriosis has been called into question, and no evidence has been found to substantiate the potential for early radical or curative treatment.

It is still common to say that the elapsed time between the onset of symptoms and the diagnosis of endometriosis is approximately 9 years. This claim rests upon old data, however, and it is probably more correct to say that too many patients with endometriosis are managed poorly or improperly. This includes adolescents.

It is also common to observe that more severe cases of the disease appear to be presenting at a younger and younger age. Recent epidemiological studies do not support this claim, however.

Endometriosis is not acknowledged in society. Because of this nonacknowledgment, endometriosis is underdiagnosed. And because it is not diagnosed, endometriosis is undertreated.

The disease affects an estimated 176 million women worldwide, yet there is little evidence to establish criteria for how endometriosis should be managed to improve quality of life for the millions of women – and their families – who are affected by this condition every single day of their lives.

The editors of this book, who are well-known champions of women with endometriosis, have invited colleagues from around the world to

Our main purpose in writing this foreword is to emphasize the importance of teaching both the present and future generation of gynecologists about endometriosis. In this respect, this book is truly essential for achieving this goal. All aspects of endometriosis are covered from its pathogenesis to its most severe sites of occurrence.

The book compiles the most current knowledge on endometriosis, and the long list of contributing authors, including renowned experts as well as younger doctors, underscores the clear educational objectives of this work.

It is such an honor for me to have been asked to write this foreword, and I encourage all practitioners interested in treating endometriosis, in all of its varied forms and symptoms, to read this book carefully. They will be rewarded with the most up-to-date information available on this prevalent disease.



*Arnaud Wattiez*

MD, Professor, Department of Obstetrics and Gynecology, Strasbourg University Hospital, IRCAD, Strasbourg, France.

Latifa Hospital, Dubai Health Authority, Dubai – United Arab Emirates.

submit their opinions about endometriosis and to justify the reasons for their proposed treatment options.

These deliberations allow women with endometriosis to read, digest, evaluate, and decide what may be potential solutions for them, when it comes to managing the way in which endometriosis is impacting their lives.



*Lone Hummelshoj*

Secretary General of the World Endometriosis Society  
Publisher and Editor-in-Chief of  
[www.endometriosis.org/](http://www.endometriosis.org/)

## Editors and Contributing Authors



**Abrao, Mauricio S.**

Associate Professor, MD, PhD; Director of Endometriosis Division, Department of Obstetrics / Gynecology, Sao Paulo University, Brazil.



**Aminsharifi, Amir**

Associate Professor of Urology, MD; Department of Urology, Laparoscopy Research Center, Shiraz University of Medical Sciences, Shiraz, Iran.



**Collinet, Pierre**

Professor, Department of Obstetrics and Gynecology, Jeanne de Flandre Hospital, CHU Lille, France.



**Eid, Jose**

MD; Department of Obstetrics and Gynecology, American University of Beirut Medical Center, Beirut, Lebanon.



**Adamyan, Leila**

Professor, MD, PhD; Head Specialist in Obstetrics and Gynecology of Russian Ministry of Healthcare and Social Development; Head of Department of Surgical Gynecology;

Head of Department of Reproductive Medicine and Surgery, Faculty of Postgraduate Education, Moscow State University of Medicine and Dentistry.



**Biscione, Antonella**

MD, Department of Molecular and Developmental Medicine, University of Siena, Italy.



**Daftary, Gaurang S.**

Assistant Professor of Obstetrics and Gynecology, MD; Division of Reproductive Endocrinology and Infertility, Mayo Clinic, Rochester MN, USA.



**Exacoustos, Caterina**

Professor, MD; 'Tor Vergata' University of Rome, Department of Biomedicine and Prevention, Clinical Center for Obstetrics and Gynecology, Rome, Italy.



**Alborzi, Saeed**

Professor of Obstetrics and Gynecology, MD; Head of the Gynecologic Endoscopy Division, Laparoscopy Research Center, Department of Obstetrics and Gynecology, School

of Medicine, Shiraz University of Medical Sciences, Shiraz, Iran.



**Bretagnol, Frédéric**

Professor of Gastrointestinal Surgery, MD, PhD; Department of General and Digestive Surgery, Hôpital Louis Mourier, Paris, France.



**Darwish, Basma**

MD; Department of Gynecology and Obstetrics, Rouen University Hospital, Rouen, France.



**Farokhi, Amir**

MD; Fellowship in Endourology and Urolaparoscopy, Department of Urology, Laparoscopy Research Center, Shiraz University of Medical Sciences, Shiraz, Iran.



**Alborzi, Soroosh**

MD; Head of Cardiology Department, Khormoj Zeinabiyeh Hospital, Bushehr University of Medical Sciences, Bushehr, Iran.



**Centini, Gabriele**

MD, Department of Molecular and Developmental Medicine, University of Siena, Italy.



**Doniec, J. Marek**

MD; Private Office for Endoscopic Gastroenterology and Proctology, Kiel, Germany.



**Ferrero, Simone**

Academic Unit of Obstetrics and Gynecology, IRCCS AOU San Martino – IST, Genoa; Department of Neurosciences, Rehabilitation, Ophthalmology, Genetics, Maternal and

Child Health (DiNOGMI), University of Genoa, Italy.



**Alkatout, Ibrahim**

Associate Professor, MD, PhD, MA; Department of Obstetrics and Gynecology, Head of the Kiel School of Gynecological Endoscopy, University Hospitals of Schleswig-Holstein,

Kiel Campus, Kiel, Germany.



**Chung, Maurice**


Clinical Professor, RPh, MD; Department of OB/GYN, University of Toledo School of Medicine, Toledo, Ohio, USA; Director, Midwest Center of Excellence

for Endometriosis, Pelvic Pain and Bladder Control, Lima, Ohio, USA; Women's Center of Excellence for Pelvic Pain, Organ Prolapse and Bladder Control, Van Wert County Hospital, Van Wert, Ohio, USA.



**D'Urso, Antonio**

MD, PhD; IRCAD / EITS, Department of General, Digestive and Endocrine Surgery, Nouvel Hôpital Civil, University Hospital of Strasbourg, Strasbourg, France.



**Gabriel, Boris**

Professor, MD; Head of Department of Obstetrics and Gynecology, St. Josef's Hospital, Wiesbaden, Germany.



**Genazzani, Andrea R.**

MD; Division of Gynecology and Obstetrics, University of Pisa, Italy.



**Hudgens, Jay**

MD, MPH; Department of Obstetrics and Gynecology, Director of Minimally Invasive Surgery at Wiser Women's Hospital, University of Mississippi Medical Center, Jackson, MS, USA.



**Keckstein, Jörg**

Professor, MD; Head of Department of Gynecology and Obstetrics, Certified Clinical-Scientific Level III Center for Endometriosis Care, Certified Breast Care

Center, State Hospital of Villach, Carinthia, Austria.



**Korell, Matthias**

Professor, MD; Head of Department of Gynecology and Obstetrics, Johanna Etienne Hospital, Neuss, Germany.



**Ginn, Daniel**

DO, MPH; Ob/Gyn & Women's Health, University of Louisville Hospital Physicians Outpatient Center, Louisville, KY, USA.



**Jacobson, Tal**

Dr, MA, MBBS, FRCOG, FRANZCOG; University of Auckland; Repromed Auckland, New Zealand; Mater Hospital Brisbane, Queensland, Australia; University of Queensland; Eve Health, Queensland Fertility Group, Brisbane.



**Kemp, Marta Maria**

Fellow of the Pelvic Neurodysfunction Clinic, Department of Gynecology, Federal University of São Paulo, Brazil.



**Kruse, Alexandra**

MD; Ammerlandklinik Westerstede, Department of Urology and Pediatric Urology, Westerstede, Germany.



**Hanssens, Sandy**

Department of Obstetrics and Gynecology, Jeanne de Flandre Hospital, CHU Lille, France.



**Johnson, Neil P.**

Professor, MD, CREI, FRANZCOG, FRCOG, MRCGP; World Endometriosis Society; Robinson Research Institute; University of Adelaide, South Australia.



**Khan, Zaraq**

MBBS, MS, Assistant Professor of Obstetrics and Gynecology; Division of Reproductive Endocrinology and Infertility, Mayo Clinic, Rochester, MN, USA.



**Lakhi, Nisha**

MD; Department of Obstetrics and Gynecology, Richmond University Medical Center, Staten Island, New York, USA.



**Holland, Tom K.**

MBBS, MD (Res), MRCOG; Gynaecologist, Guy's and St Thomas' Hospital, London, United Kingdom.



**Kausch von Schmeling, Ingo**

Professor, MD; Ammerlandklinik Westerstede, Department of Urology and Pediatric Urology, Westerstede, Germany.



**Khoury, Sally**

MD; Department of Obstetrics and Gynecology, American University of Beirut Medical Center, Beirut, Lebanon.



**Lam, Alan**

Associate Professor, MD; Director of Centre for Advanced Reproductive Endosurgery (CARE), Sydney Medical School, Australia.



**Hornung, Daniela**

Professor, MD; Head of Department of Gynecology and Obstetrics, Diakonissenkrankenhaus, Karlsruhe-Rüppurr, Germany.



**Kazemi, Mahbubeh**

Gynecologist, Shiraz University of Medical Sciences, Shiraz, Iran.



**Koninckx, Philippe R.**

Professor emeritus Ob-Gyn KU Leuven, Belgium; University of Oxford-Honorary Consultant, UK; Università Cattolica, Rome, Italy and Moscow State University, Russia; Gruppo Italo Belga, Villa del Rosario, Rome, Italy.



**Lazzeri, Lucia**

MD, PhD; Department of Molecular and Developmental Medicine, University of Siena, Italy.





**Lee, Ted**  
MD; Director, Minimally Invasive Gynecologic Surgery, Magee Women's Hospital, University of Pittsburgh Medical Center, Pittsburgh, USA.



**Löhnert, Mathias S.S.**  
Professor Dr. h.c. (TashPMI), Dr. med. habil.; Department of General and Colorectal Surgery, Clinical Center Bielefeld, Germany.



**Meinhold-Heerlein, Ivo**  
Professor h.c. Professor Dr. med. habil.; Vice Director, Department of Gynecology and Obstetrics, Medical University of the RWTH Aachen, Germany.



**Nezhat, Farr**  
MD; Department of Obstetrics and Gynecology, Division Gynecologic Oncology, Weill Cornell Medicine, NY, New York, USA; Department of Obstetrics, Gynecology and Reproductive Medicine, State University of New York at Stony Brook School of Medicine, Stony Brook, NY, USA; Department of Obstetrics and Gynecology, Winthrop University Hospital, Mineola, NY, USA.



**von Leffern, Ingo**  
MD, MIC III; Director of Albertinen Women's Clinics; Head of Department of Gynecology and Obstetrics, Albertinen Hospital, Hamburg, Germany.



**Madhumathi, S.**  
Senior Consultant; Department of Gynecology, Minimal Access and Robotic Surgery, Apollo Health City, Hyderabad, Telangana, India.



**Mettler, Liselotte**  
Professor Dr. med. Dr. h.c. mult.; Department of Obstetrics and Gynecology, Kiel School of Gynecological Endoscopy, University Hospitals of Schleswig-Holstein, Kiel Campus, Kiel, Germany.



**Oppelt, Peter**  
Professor, MD, MBA; Kepler University Hospital, Medical Campus IV, Department of Gynecology, Obstetrics and Gynecological Endocrinology, Linz, Austria.



**Lemos, Nucelio L.B.M.**  
MD, PhD, Associate Professor of Obstetrics and Gynaecology; University of Toronto Faculty of Medicine, Functional Pelvic Surgery and Neuropelveology. Women's College Hospital, Toronto, Canada  
Head of the Pelvic Neurodysfunction Clinics, Department of Gynecology, Federal University of São Paulo, Brazil



**Maggiore, Umberto L.R.**  
Academic Unit of Obstetrics and Gynaecology, IRCCS AOU San Martino – IST, Genoa; Department of Neurosciences, Rehabilitation, Ophthalmology, Genetics, Maternal and Child Health (DiNOGMI), University of Genoa, Italy.



**Morrison, John E.**  
Associate Professor of Surgery, MD, FACS; Department of Surgery, Louisiana State University School of Medicine, New Orleans, Louisiana; USA.



**Pasic, Resad P.**  
MD, PhD; Ob/Gyn & Women's Health, University of Louisville Hospital Physicians Outpatient Center, Louisville, KY, USA.



**Leroy, Joël**  
MD, FRCS; IRCAD/ EITS, Department of General, Digestive and Endocrine Surgery, Hôpital Civil, University Hospital of Strasbourg, Strasbourg, France.



**Magrina, Javier F.**  
MD; Department of Gynecologic Surgery, Mayo Clinic Arizona, Phoenix, AZ, USA.



**Nassif, Joseph**  
MD; Department of Obstetrics and Gynecology, American University of Beirut Medical Center, Beirut, Lebanon.



**Peloggia, Alessandra**  
MD PhD; Fertility and Assisted Reproduction Center, Campinas, SP, Brazil; Sirio Libanês Hospital, São Paulo, SP, Brazil.



**Luisi, Stefano**  
MD, PhD; Department of Molecular and Developmental Medicine, University of Siena, Italy.



**Mechsner, Sylvia**  
Professor, MD, PhD; Head of the Charité Center for Endometriosis Care; Department of Gynaecology and Breast Centre of the Charité University Medicine, Campus Benjamin Franklin, Berlin, Germany.



**Neto, Joao Siufi**  
MD; Surgical Oncologist, Sirio-Libanês Hospital, São Paulo, SP, Brazil.



**Petraglia, Felice**  
Professor, MD; Head of Department of Obstetrics and Gynecology, "Santa Maria alle Scotte" University Policlinic of Siena, Italy.

**Petta, Carlos Alberto**

MD PhD; Fertility and Assisted Reproduction Center, Campinas, SP, Brazil; Sirio Libanês Hospital, São Paulo, SP, Brazil.

**Raymundo, Thiers Soares**

Professor, MD; Head of Department of Gynecological Endoscopy, Federal Hospital Cardoso Fontes; Director of the Postgraduate Program in Gynecological Endoscopy at the Supreme University; Consultant, Department of Gynecological Endoscopy, Pedro Ernesto University Hospital (UERJ), Rio de Janeiro, Brazil.

**Riedel, Hans Harald**


Professor, MD; Head of Department of Gynecology, Rehabilitation Clinic Prof. Schedel GmbH, Thyrnau-Kellberg, Germany.

**Samita, K.**

Resident (DNB); Department of Gynecology, Minimal Access and Robotic Surgery, Apollo Health City, Hyderabad, Telangana, India.

**Pinzauti, Serena**

MD; University of Siena, Department of Obstetric and Developmental Medicine, Siena, Italy.

**Redondo-Guisasola, C.**

Gynecologist, Endometriosis Surgery, Department of Obstetrics and Gynecology, University Hospital Fundación Jiménez Díaz, Madrid, Spain.

**Rodríguez, Brice**

Consultant Ob/Gyn; Lancashire Teaching Hospital, Lancashire, United Kingdom.

**Schmidt, Dietmar**

Professor, MD, MD h.c.; Institute of Pathology, Viersen, Germany.

**Pluchino, Nicola**

MD; Division of Gynecology and Obstetrics, University Hospital of Geneva, Switzerland; Yale University School of Medicine, New Haven, USA.

**Reich, Harry**

MD, FACOG, FACS; Wyoming Valley Health Care System, Wilkes-Barre, PA, USA; St. Vincent's Medical Center, NY, USA; CMC, Scranton, PA, USA; Lenox Hill, NY, USA.

**Roman, Horace**

MD, PhD; Department of Gynecology and Obstetrics, Rouen University Hospital, Rouen, France; Research Group 4308 'Spermatogenesis and Gamete Quality', IHU Rouen Normandy,

Reproductive Biology Laboratory, Rouen University Hospital, Rouen, France.

**Schradung, Simone**

Assoc. Professor, MD; Department of Diagnostic and Interventional Radiology, Medical University of the RWTH Aachen, Germany

**Racca, Annalisa**

MD; Academic Unit of Obstetrics and Gynecology, IRCCS AOU San Martino – IST, Genoa, Italy; Department of Neurosciences, Rehabilitation, Ophthalmology, Genetics, Maternal and

Child Health (DiNOGMI), University of Genoa, Italy.

**Remorgida, Valentino**

MD; Academic Unit of Obstetrics and Gynecology, IRCCS AOU San Martino – IST, Genoa, Italy; Department of Neurosciences, Rehabilitation, Ophthalmology,

Genetics, Maternal and Child Health (DiNOGMI), University of Genoa, Italy.


**Rubod, C.**

MD, Department of Obstetrics and Gynecology, Jeanne de Flandre Hospital, CHU Lille, France.

**Schweppe, Karl-Werner**

Professor, MD, MD h.c.; Former Director of the Ammerland Endometriosis Center, Department of Obstetrics and Gynecology, Ammerland Clinic GmbH, Academic

Teaching Hospital of the Hannover Medical School, Germany.

**Rasekhi, Aliakbar**

Associate Professor of Radiology, MD; Department of Radiology, Shiraz University of Medical Sciences, Shiraz, Iran.

**Ribeiro, A. Morgado**

MD; Fellow of the Pelvic Neurodysfunction Clinic, Department of Gynecology, Federal University of São Paulo, Brazil.

**Rupa, B.**

MD, Senior Registrar; Department of Gynecology, Minimal Access and Robotic Surgery, Apollo Health City, Hyderabad, Telangana, India.

**Seckin, S.**

MD; Department of Obstetrics and Gynecology, Mount Sinai St. Luke's and Mount Sinai West, Icahn School of Medicine at Mount Sinai, New York NY, USA.



**Seckin, Tamer**  
MD, FACOG, ACGE;  
Department of  
Obstetrics and  
Gynecology, Lenox Hill  
Hospital, New York  
NY, USA.



**Siufi,  
D. Freitas Santos**  
MD; Surgical Oncologist,  
Sirio-Libanês Hospital,  
São Paulo, SP, Brazil.



**Ussia, Anastasia**  
MD, Consultant  
Università Cattolica,  
Rome, Italy; Gruppo  
Italo Belga, Villa del  
Rosario, Rome, Italy.



**Wölfler,  
Monika Martina**  
MD; Medical University  
of Graz, Department  
of Obstetrics and  
Gynecology, Graz,  
Austria.




**Segaert, A.**  
MD; Department of  
Obstetrics and  
Gynaecology, CHU Lille,  
France.



**Stochino Loi,  
Emanuela**  
MD; Department  
of Gynecology and  
Obstetrics, Rouen  
University Hospital,  
Rouen, France.



**Vázquez, Alberto**  
MD, Gynecologist;  
Reproductive Endo-  
scopic Surgery,  
Assisted Reproduction  
Clinics, Barcelona and  
Madrid, Spain



**Zahiri, Ziba**  
Professor of Obstetrics  
and Gynecology, MD;  
Gilan University of  
Medical Sciences,  
Rasht, Iran.



**Shebl, Omar**  
Associate Professor,  
MD; Kepler University  
Hospital, Medical Cam-  
pus IV, Department of  
Gynecology, Obstetrics  
and Gynecological  
Endocrinology, Linz,  
Austria.



**Sussfeld, J.**  
MD; Department  
of Obstetrics and  
Gynaecology, CHU Lille,  
France.



**Wattiez, Arnaud**  
MD; Head of Gynecology  
Department, Latifa  
Hospital, Dubai, United  
Arab Emirates; Director  
of Advanced Courses in  
Gynecological Endo-  
scopy at IRCAD/ EITS,  
Strasbourg, France.




**Zalewski,  
Magdalena Maria**  
MD; Department  
of Gynecology and  
Obstetrics, Medical  
University of the RWTH  
Aachen, Germany.



**Sillem, Martin**  
Associate Professor, MD;  
Private Clinical Center  
'Am Rosengarten',  
Mannheim, Germany.



**Sutton,  
Christopher J.G.**  
Professor of Gynaecolo-  
gical Surgery, MA, MB,  
BCh, (Cantab) FRCOG;  
Faculty of Health  
and Social Sciences,  
University of Surrey,  
Guildford, UK; Director  
of the Minimal Access Therapy Training Unit,  
Royal Surrey County Hospital, Guildford, UK.



**Wenger,  
Jean-Marie**  
MD; Consultant, Division  
of Gynecology and  
Obstetrics, University  
Hospital of Geneva,  
Switzerland.



**Zupi, Errico**  
MD, Associate Professor  
of Obstetrics and  
Gynecology, University  
of Tor Vergata, Rome,  
Italy.



**Sinha, Rooma**  
MBBS, MD, DNB,  
MCOG, PGDMLS,  
MNAMS; Senior  
Consultant, Minimal  
Access and Robotic  
Surgeon, Department  
of Gynecology, Minimal  
Access and Robotic  
Surgery, Apollo Health City, Hyderabad,  
Telangana, India.



**Ulrich,  
Uwe Andreas**  
Professor, MD; Depart-  
ment of Obstetrics and  
Gynecology, Martin  
Luther Hospital, Berlin,  
Germany.



**Wijsmuller,  
Arthur R.**  
MD, PhD; IRCAD / EITS,  
Department of General,  
Digestive and Endocrine  
Surgery, Nouvel  
Hôpital Civil, Strasbourg  
University Hospital,  
Strasbourg, France.





## Contents

<b>1</b>	<b>Theoretical Basics, Research, and Conservative Management</b> . . . . .	<b>1</b>
1.1	Background and Purpose . . . . .	2
1.2	The History of Endometriosis . . . . .	3
1.2.1	Introduction . . . . .	3
1.2.2	The Era of Laparoscopy and Laparoscopic Surgery . . . . .	9
1.2.3	References . . . . .	12
1.3	Etiology and Pathogenesis . . . . .	15
1.3.1	Introduction . . . . .	15
1.3.2	History . . . . .	15
1.3.3	Theories on the Pathogenesis of Endometriosis . . . . .	16
1.3.4	Retrograde Menstruation . . . . .	16
1.3.5	Metaplasia . . . . .	16
1.3.6	Hormones . . . . .	17
1.3.7	Oxidative Stress and Inflammation . . . . .	17
1.3.8	Immune Dysfunction . . . . .	17
1.3.9	Suppression of Apoptosis and Alteration of Endometrial Cell Fate . . . . .	17
1.3.10	Genetics . . . . .	18
1.3.11	Stem Cells . . . . .	18
1.3.12	Discussion and Summary . . . . .	19
1.3.13	References . . . . .	19
1.4	Pathology of Endometriosis . . . . .	22
1.4.1	Introduction . . . . .	22
1.4.2	Macroscopic Findings . . . . .	22
1.4.3	Microscopic Findings . . . . .	22
1.4.4	Endometriosis-Associated Tumors . . . . .	27
1.4.5	References . . . . .	28
1.5	Anatomical Understanding for Radical Endometriotic Treatment . . . . .	31
1.5.1	Introduction . . . . .	31
1.5.2	Important Anatomic Considerations for Laparoscopic Trocar Placement in the Anterior Abdominal Wall . . . . .	31
1.5.3	References . . . . .	34
1.6	Classification of Endometriosis . . . . .	35
1.6.1	Introduction . . . . .	35
1.6.2	History . . . . .	35
1.6.3	Classification Schemes . . . . .	36
1.6.4	Endometriosis Fertility Index (EFI) . . . . .	42
1.6.5	Discussion . . . . .	43
1.6.6	References . . . . .	43
1.7	The ENZIAN Classification of Deep Infiltrating Endometriosis . . . . .	44
1.7.1	Introduction . . . . .	44
1.7.2	What is DIE? . . . . .	44
1.7.3	The ENZIAN Classification System . . . . .	46
1.7.4	Case Histories . . . . .	50
1.7.5	Validation of the ENZIAN Classification . . . . .	55
1.7.6	Summary and Recommendations . . . . .	55
1.7.7	References . . . . .	55
1.8	Medical Therapies in the Treatment of Endometriosis . . . . .	57
1.8.1	Introduction . . . . .	57
1.8.2	Anti-Inflammatory Treatment . . . . .	57
1.8.3	Endocrine Treatment . . . . .	58
1.8.4	Recommendations for Clinical Practice . . . . .	60
1.8.5	Conclusions . . . . .	62
1.8.6	References . . . . .	62
1.9	The Role of Rehabilitation in the Treatment of Endometriosis Patients . . . . .	64
1.9.1	Introduction . . . . .	64
1.9.2	Indications for Rehabilitation . . . . .	64
1.9.3	Rehabilitation Goals . . . . .	64
1.9.4	Possible Therapeutic Goals in Endometriosis Patients . . . . .	66
1.9.5	Rehabilitation Program . . . . .	66
1.9.6	References . . . . .	68
1.10	Endometriosis and Nutrition . . . . .	70
1.10.1	Introduction . . . . .	70
1.10.2	History . . . . .	70
1.10.3	Study Results . . . . .	70
1.10.4	Discussion . . . . .	71
1.10.5	Nutritional Patterns and Endometrial Cancer . . . . .	71
1.10.6	Conclusion . . . . .	73
1.10.7	References . . . . .	73
1.11	Organisation of an Endometriosis Centre . . . . .	74
1.11.1	Introduction . . . . .	74
1.11.2	Attributes of a Network of Expertise . . . . .	74
1.11.3	Establishing a Network of Expertise . . . . .	75
1.11.4	Conclusion . . . . .	77
1.11.5	References . . . . .	77
1.12	Epidemiology of Endometriosis . . . . .	79
1.12.1	Introduction . . . . .	79
1.12.2	What is Endometriosis? . . . . .	80
1.12.3	Why is There So Much Confusion Over Endometriosis? . . . . .	82
1.12.4	Why Do We Have the Impression that Prevalence is Increasing? . . . . .	83
1.12.5	Epidemiology . . . . .	84
1.12.6	Discussion and Future Outlook . . . . .	86
1.12.7	Acknowledgments . . . . .	86
1.12.8	References . . . . .	87
1.13	Progesterone and Endometriosis: From Pathogenesis to Treatment . . . . .	91
1.13.1	Introduction . . . . .	91
1.13.2	Hormonal Imbalance in Endometriosis: From an Estrogen-Dependent Disorder to a Progesterone-Resistant Disease . . . . .	91
1.13.3	Progesterone Imbalance as Target for Endometriosis Treatment . . . . .	92
1.13.4	Selective Progesterone Receptor Modulators (SPRM) . . . . .	93
1.13.5	Acknowledgments . . . . .	95
1.13.6	References . . . . .	95
<b>2</b>	<b>Diagnostic Workup and Preparation for Surgery</b> . . . . .	<b>97</b>
2.1	History Taking, Office Diagnostics and Imaging . . . . .	98
2.1.1	Introduction . . . . .	98
2.1.2	History Taking . . . . .	98
2.1.3	Symptoms . . . . .	99
2.1.4	Structured Office Diagnostics and Imaging . . . . .	100
2.1.5	Physical Examination . . . . .	100
2.1.6	Transvaginal Ultrasound . . . . .	100
2.1.7	Conclusion . . . . .	102
2.1.8	References . . . . .	103
2.2	Preparative Steps in Laparoscopic Endometriosis Surgery . . . . .	105

2.2.1	Introduction . . . . .	105	3.3.2	Indications for Surgery . . . . .	187
2.2.2	Informed Consent . . . . .	105	3.3.3	Controversies in Surgical Removal . . . . .	188
2.2.3	Laboratory Testing . . . . .	105	3.3.4	Strategy . . . . .	188
2.2.4	Bowel Preparation . . . . .	105	3.3.5	Technique . . . . .	188
2.2.5	Antibiotic Prophylaxis and Surgical Site Infection . . . . .	106	3.3.6	Statistical Analysis of Endometrioma Surgery . . . . .	194
2.2.6	Epidural Anesthesia . . . . .	106	3.3.7	Summary . . . . .	197
2.2.7	Surgical Safety Checklist . . . . .	107	3.3.8	References . . . . .	198
2.2.8	Prevention and Management of Hypothermia . . . . .	107	<b>3.4</b>	<b>Deep Infiltrating Endometriosis (DIE)</b> . . . . .	200
2.2.9	Summary . . . . .	108	3.4.1	Introduction . . . . .	200
2.2.10	References . . . . .	108	3.4.2	Surgical Approaches and Instruments . . . . .	201
<b>2.3</b>	<b>Surgical Instruments, Powered Devices and Videoendoscopic Equipment</b> . . . . .	110	3.4.3	DIE and Fertility . . . . .	203
2.3.1	Introduction . . . . .	110	3.4.4	DIE of Sacrouterine Ligament . . . . .	204
2.3.2	Laparoscopy . . . . .	111	3.4.5	DIE Involving Nerves . . . . .	204
2.3.3	Hysteroscopy . . . . .	116	3.4.6	DIE of the Ureter . . . . .	206
2.3.4	Endoscopic Imaging . . . . .	117	3.4.7	DIE of the Bladder . . . . .	208
2.3.5	Basic Instrumentation and Powered Equipment . . . . .	123	3.4.8	DIE of the Bowel . . . . .	210
2.3.6	Special Instrumentation . . . . .	127	3.4.9	DIE of the Recto-Vaginal Space and Vagina . . . . .	214
2.3.7	Auxiliary Instruments and Application Range . . . . .	138	3.4.10	DIE of the Diaphragm and/or Pericardium . . . . .	215
2.3.8	References . . . . .	140	3.4.11	Summary . . . . .	218
<b>2.4</b>	<b>Diagnostic Imaging of Endometriosis</b> . . . . .	141	3.4.12	Acknowledgment . . . . .	218
2.4.1	Introduction . . . . .	141	3.4.13	References . . . . .	219
2.4.2	Role of MRI in the Detection and Staging of Endometriosis . . . . .	141	<b>3.5</b>	<b>Uterine Adenomyosis</b> . . . . .	221
2.4.3	Future Directions of Magnetic Resonance Imaging . . . . .	148	3.5.1	Introduction . . . . .	221
2.4.4	Conclusion . . . . .	148	3.5.2	Epidemiology and Pathology . . . . .	223
2.4.5	References . . . . .	149	3.5.3	Clinical Manifestations and Diagnosis . . . . .	224
<b>2.5</b>	<b>A Comparison of Pelvic Magnetic Resonance Imaging, Transvaginal and Transrectal Sonography, and Laparoscopic Findings in the Diagnosis of Deep Infiltrating Endometriosis</b> . . . . .	152	3.5.4	Adenomyosis and Infertility . . . . .	225
2.5.1	Introduction . . . . .	152	3.5.5	Development of Laparoscopic Hysterectomy Techniques and Instruments . . . . .	229
2.5.2	Materials and Methods . . . . .	152	3.5.6	Preoperative Considerations and Preparations . . . . .	230
2.5.3	Results . . . . .	154	3.5.7	Conclusions . . . . .	254
2.5.4	Discussion . . . . .	159	3.5.8	References . . . . .	254
2.5.5	Conclusion . . . . .	160	<b>3.6</b>	<b>Extragenital Endometriosis</b> . . . . .	257
2.5.6	References . . . . .	160	3.6.1	Introduction . . . . .	257
<b>2.6</b>	<b>Ultrasound Imaging in the Diagnosis of Deep Infiltrating Endometriosis (DIE) and Adenomyosis</b> . . . . .	162	3.6.2	Endometriosis of the Abdominal Wall, Umbilicus and Surgical (Cesarean) Scar . . . . .	257
2.6.1	Introduction . . . . .	162	3.6.3	Discussion . . . . .	260
2.6.2	Ultrasound Diagnosis of Pelvic Endometriosis . . . . .	163	3.6.4	Conclusion . . . . .	261
2.6.3	Ultrasonographic Mapping for Pelvic DIE . . . . .	165	3.6.5	References . . . . .	261
2.6.4	Adenomyosis . . . . .	169	<b>3.7</b>	<b>Laparoscopic Diagnosis and Treatment of Superficial Pelvic Endometriosis</b> . . . . .	263
2.6.5	Conclusions . . . . .	175	3.7.1	Introduction . . . . .	263
2.6.6	References . . . . .	175	3.7.2	Laparoscopic Surgical Technique . . . . .	263
<b>3</b>	<b>Surgical Techniques for Different Manifestations of Endometriosis</b> . . . . .	179	3.7.3	Conclusion . . . . .	266
<b>3.1</b>	<b>Peritoneal Endometriosis</b> . . . . .	180	3.7.4	References . . . . .	267
3.1.1	Introduction . . . . .	180	<b>3.8</b>	<b>Robotic Laparoscopic Surgery for Endometriosis</b> . . . . .	268
3.1.2	Appearances and Morphology . . . . .	180	3.8.1	Introduction . . . . .	268
3.1.3	Surgical Techniques . . . . .	182	3.8.2	Robotic-Assisted Laparoscopy Set Up . . . . .	269
3.1.4	Discussion . . . . .	183	3.8.3	Surgical Excision . . . . .	269
3.1.5	References . . . . .	183	3.8.4	Bladder and Ureteral Endometriosis . . . . .	271
<b>3.2</b>	<b>General Remarks on Ovarian Endometriosis</b> . . . . .	184	3.8.5	Ovarian Endometriosis (Cystectomy) . . . . .	272
3.2.1	Introduction . . . . .	184	3.8.6	Discussion . . . . .	272
3.2.2	Ovarian Cystectomy . . . . .	184	3.8.7	References . . . . .	273
3.2.3	Ablation . . . . .	184	<b>3.9</b>	<b>Robotic-Assisted Laparoscopic Surgery for Deeply Infiltrating Endometriosis</b> . . . . .	275
3.2.4	Mixed Techniques . . . . .	185	3.9.1	Introduction . . . . .	275
3.2.5	Discussion . . . . .	185	3.9.2	Treatment of Deeply Infiltrating Endometriosis . . . . .	275
3.2.6	References . . . . .	186	3.9.3	Preoperative Evaluation . . . . .	277
<b>3.3</b>	<b>Ovarian Endometriosis and Endometriomas</b> . . . . .	187	3.9.4	Patient Positioning and Port Placement . . . . .	278
3.3.1	Introduction . . . . .	187	3.9.5	General Surgical Approach . . . . .	278
			3.9.6	Genitourinary DIE . . . . .	281
			3.9.7	Limitations to the Robotic Platform . . . . .	283

3.9.8	Conclusion	283	4.7.1	Introduction	346
3.9.9	References	283	4.7.2	Prevention of Recurrence	346
3.10	<b>Robotic Assistance in Endometriosis Surgery – Is this Technology a Game Changer?</b>	286	4.7.3	Management of Recurrent Disease	349
3.10.1	Introduction	286	4.7.4	Conclusion	349
3.10.2	Why Robotic Assistance?	286	4.7.5	References	350
3.10.3	Sequential Steps of Robotic-Assisted Endometriosis Surgery	288	4.8	<b>Definitive Surgery for Endometriosis after Completion of Family Planning</b>	351
3.10.4	The Role of Robotics in the Management of Endometriosis – A Game Changer in Three Application Fields	290	4.8.1	Introduction and Background	351
3.10.5	Conclusion	295	4.8.2	Uterine Pathology	352
3.10.6	References	295	4.8.3	Preoperative Considerations	352
4	<b>Special Conditions</b>	297	4.8.4	Endometriomas	355
4.1	<b>The Management of Endometriosis in Infertility</b>	298	4.8.5	Cystoscopy	358
4.1.1	Introduction	298	4.8.6	Summary	358
4.1.2	Clinical Treatment of Infertility in Patients with Endometriosis	298	4.8.7	References	359
4.1.3	Surgical Treatment of Infertility in Patients with Endometriosis	299	4.9	<b>Robotic Assistance for Deep Infiltrating Endometriosis Surgery</b>	360
4.1.4	Key Points in the Treatment of Infertile Women with Endometriosis	301	4.9.1	Introduction	360
4.1.5	References	301	4.9.2	History of Robotic-Assisted Laparoscopy	360
4.2	<b>Endometriosis and Pain</b>	303	4.9.3	Advantages and Drawbacks of Robotic-Assisted Laparoscopic Surgery	362
4.2.1	Introduction	303	4.9.4	Case Reports and Studies on the Use of RAL for Surgical Treatment of DIE	364
4.2.2	Pathophysiology of Endometriosis-Associated Pain	304	4.9.5	Endometriosis and Fertility	364
4.2.3	Conclusion	308	4.9.6	Conclusion	364
4.2.4	References	309	4.9.7	References	365
4.3	<b>Laparoscopic Surgery for Treatment of Endometriosis-Associated Pelvic Pain Including the Role of Presacral Neurectomy</b>	312	4.10	<b>Endometriosis-Associated Malignant Neoplasms</b>	367
4.3.1	Background	312	4.10.1	Introduction	367
4.3.2	How Does Endometriosis Cause Pain?	312	4.10.2	Histopathology	367
4.3.3	Neuro-Anatomical Innervation and Sensory Pathways for Pelvic Viscera	312	4.10.3	Molecular Findings	369
4.3.4	The Role of Surgery in the Treatment of Endometriosis-Associated Pain	313	4.10.4	Epidemiological Data	369
4.3.5	The Role of Presacral Neurectomy (PSN)	313	4.10.5	Clinical Relevance	370
4.3.6	Conclusion	315	4.10.6	References	371
4.3.7	References	315	4.11	<b>Controversies in Surgical Treatment of Adenomyosis</b>	374
4.4	<b>Postoperative Management of Endometriosis</b>	317	4.11.1	Introduction	374
4.4.1	Introduction	317	4.11.2	Major Aspects of Managing Patients with Adenomyosis	374
4.4.2	Which Strategy for the Post-Surgery Period?	317	4.11.3	Surgical Treatment of Adenomyosis	375
4.4.3	Which Drugs for the Post-Surgery Period?	318	4.11.4	Which is the Best Treatment for Adenomyosis?	378
4.4.4	Conclusion	321	4.11.5	References	379
4.4.5	References	321	5	<b>Urological Approaches</b>	381
4.5	<b>Nerve-Sparing Surgery in Endometriosis</b>	324	5.1	<b>Diagnosis and Management of Urinary Tract Endometriosis</b>	382
4.5.1	Introduction	324	5.1.1	Introduction	382
4.5.2	Neurophysiology of the Pelvic Floor	324	5.1.2	Bladder Endometriosis	382
4.5.3	Laparoscopic Anatomy of the Intrapelvic Nerves	327	5.1.3	Ureteral Endometriosis	386
4.5.4	Nerve-Sparing by Direct Visualization of Nerve Bundles by Using the Laparoscopic Neuronavigation (LANN) Technique	327	5.1.4	Summary	390
4.5.5	References	330	5.1.5	References	390
4.6	<b>Neuropelveology</b>	332	5.2	<b>Diagnosis of Urinary Tract Endometriosis, Counseling and Therapeutic Management</b>	395
4.6.1	Introduction	332	5.2.1	Introduction	395
4.6.2	Neuroanatomy of the Pelvis	332	5.2.2	Diagnosis of Urinary Tract Endometriosis	395
4.6.3	Nerve-Sparing Surgery for Deep Infiltrating Endometriosis	337	5.2.3	Counseling and Alternative Therapeutic Options	397
4.6.4	Treatment of Endometriosis-Related Sacral Radiculopathies, Sciatica and Pudendal Neuralgia	341	5.2.4	Summary	398
4.6.5	Discussion	342	5.2.5	References	398
4.6.6	Conclusion	342	5.3	<b>Ureteral Endometriosis</b>	399
4.6.7	Acknowledgment	343	5.3.1	Introduction	399
4.6.8	References	343	5.3.2	Definition and Prevalence	399
4.7	<b>Recurrent Endometriosis</b>	346	5.3.3	Pathological Findings and Location	400
			5.3.4	Diagnosis	400
			5.3.5	Treatment Options	401
			5.3.6	Conclusions	406
			5.3.7	References	406

5.4	<b>Bladder Endometriosis</b> . . . . .	409
5.4.1	Introduction and Prevalence . . . . .	409
5.4.2	Pathophysiology . . . . .	409
5.4.3	Clinical Symptomatology . . . . .	409
5.4.4	Diagnosis . . . . .	409
5.4.5	Management . . . . .	411
5.4.6	Surgical Complications and Outcomes . . . . .	412
5.4.7	Conclusion . . . . .	412
5.4.8	Acknowledgement . . . . .	413
5.4.9	References . . . . .	413
5.5	<b>Surgical Treatment of Bladder Endometriosis</b> . . . . .	415
5.5.1	Introduction . . . . .	415
5.5.2	Preoperative Workup . . . . .	415
5.5.3	Surgical Treatment . . . . .	417
5.5.4	Role of Robotic and Single-Port Surgery in the Treatment of Bladder Endometriosis . . . . .	421
5.5.5	Postoperative Complications . . . . .	422
5.5.6	Conclusion . . . . .	422
5.5.7	References . . . . .	422
<b>6</b>	<b>General Surgical Approach</b> . . . . .	423
6.1	<b>Diagnosis of Bowel Endometriosis</b> . . . . .	424
6.1.1	Introduction . . . . .	424
6.1.2	Endorectal Ultrasound – Anatomic Structures and Findings in Endometriosis Patients . . . . .	425
6.1.3	Management of Rectal Endometriosis . . . . .	427
6.1.4	Conclusion . . . . .	427
6.1.5	References . . . . .	428
6.2	<b>Surgical Management of Recto-Sigmoid Endometriosis – Resection Using EEA Stapler</b> . . . . .	429
6.2.1	Introduction . . . . .	429
6.2.2	Important Steps in Proper Function of the EEA Stapler . . . . .	430
6.2.3	Conclusions . . . . .	435
6.2.4	References . . . . .	435
6.3	<b>Bowel Surgery in Deep Infiltrating Endometriosis</b> . . . . .	436
6.3.1	Introduction . . . . .	436
6.3.2	Surgical Strategy . . . . .	437
6.3.3	Segmental Bowel Resections . . . . .	439
6.3.4	Conclusions . . . . .	442
6.3.5	References . . . . .	442



# 1 Theoretical Basics, Research, and Conservative Management



1.1	Background and Purpose	2
1.2	The History of Endometriosis	3
1.3	Etiology and Pathogenesis	15
1.4	Pathology of Endometriosis	22
1.5	Anatomical Understanding for Radical Endometriotic Treatment	31
1.6	Classification of Endometriosis	35
1.7	The ENZIAN Classification of Deep Infiltrating Endometriosis	44
1.8	Medical Therapies in the Treatment of Endometriosis	57
1.9	The Role of Rehabilitation in the Treatment of Endometriosis Patients	64
1.10	Endometriosis and Nutrition	70
1.11	Organisation of an Endometriosis Centre	74
1.12	Epidemiology of Endometriosis	79
1.13	Progesterone and Endometriosis: From Pathogenesis to Treatment	91

## 1.1

## Background and Purpose

Liselotte Mettler<sup>a</sup>

Within the multitude of books and papers available on the topic of endometriosis, there is still need for a practical guide focusing on endoscopic surgical treatment. With this goal in mind, the editors invited a distinguished panel of researchers and clinicians to familiarize readers with management aspects of this disease. Apart from that, we were fortunate to enlist a team of dedicated surgical colleagues who contributed chapters on the major operative approaches currently available in the surgical treatment of endometriosis.

Knowing that this chronic, benign, estrogen-dependent inflammatory disease is a life-long problem for our patients, we emphasize that early recognition and adequate treatment are essential. Recent literature suggests that – apart from the classic theories on the pathogenesis and spread of the various forms of endometriosis – other contributing factors such as genetic predisposition, abnormal peritoneal environment, stem cells, immune dysfunction, and inflammation are involved in the formation and propagation of endometriotic lesions. While multiple therapeutic approaches are discussed and are effective to a degree, surgery – usually by the endoscopic route – is still the mainstay for both diagnosis and treatment. Accordingly, particular emphasis has been laid on presenting the operative steps required to perform specific surgical procedures. The following chapters are, on the one hand, intended to provide patients with a better understanding of the potential difficulties to be anticipated and resolved during surgical excision, while on the other hand, they serve to guide consultants and surgeons in performing the surgical steps that are both adequate and efficient. As described later in this book, for diagnosis and treatment of endometriosis to be fully effective, virtually all forms of the disease still need to be managed by a surgical approach.

Considering that most treatment protocols currently used in the management of endometriosis are based on a surgical approach and that the large majority of medical therapies rely on manipulating ovarian steroid hormones without achieving a complete response in every patient, all authors of this book share the hope that new research results will bring fresh perspectives and insights for the continued development of new treatment strategies. With advanced technical, instrumental, optical and healthcare support from the industry, surgical endoscopic procedures have become easier, safer, less invasive, and certainly more effective.

A second purpose of this book, therefore, is to foster more effective cooperation among medicine, research, and industry. We have chosen to publish this book through Endo:Press® Tuttlingen, Germany, and the KARL STORZ Company, which has supported the Kiel School of Gynecological Endoscopy for more than 20 years.

---

<sup>a</sup> | Professor Emerita, MD; Department of Obstetrics and Gynecology, Kiel School of Gynecological Endoscopy, University Hospitals of Schleswig-Holstein, Kiel Campus, Kiel, Germany

**Corresponding author:**

Prof. Dr. med. Dr. h.c. mult. **Liselotte Mettler**  
Klinik für Gynäkologie und Geburtshilfe  
Universitätsklinikum Schleswig-Holstein (UKSH)  
Campus Kiel  
Arnold-Heller-Strasse 3  
24105 Kiel, Germany  
E-mail: endometriose@uksh.de

## 1.2

## The History of Endometriosis

Christopher J.G. Sutton<sup>a</sup>

## 1.2.1 Introduction

## 1.2.1.1 Texts from Ancient Egypt

Trying to fathom the history of female pelvic diseases is a difficult task and although it is tempting to ascribe descriptions of symptoms of pelvic pain written in ancient texts from Egypt such as the Kahun Papyrus (1825 BC) and the Ebers Papyrus (1550 BC)<sup>42</sup> to diseases such as endometriosis, this is pure conjecture since the disease could only be accurately diagnosed when the characteristic lesions could actually be seen and that would not happen for many centuries later.

## 1.2.1.2 Early Attempts at Endoscopy

Throughout recorded time doctors have had a compelling desire to look inside body cavities to advance their knowledge of disease. Some of the earliest descriptions of endoscopic examinations came from the medical school on the island of Kos, in the eastern Aegean Sea, led by *Hippocrates* (Fig. 1.1)



**Fig. 1.1** *Hippocrates* teaching on the Island of Kos. Illustration from 15<sup>th</sup> Century manuscript.

Library of the Old Faculty of Medicine, Paris, France.

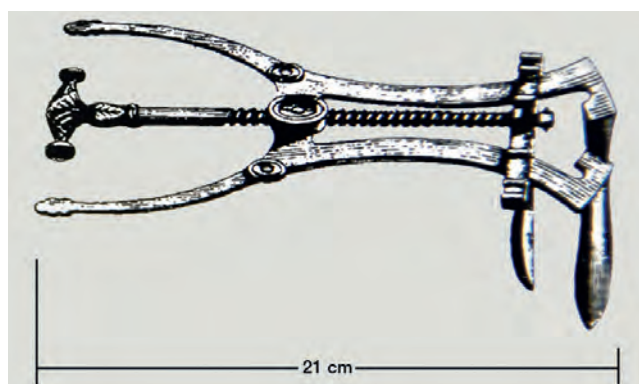
who lived between 460–375 BC and is generally regarded as ‘The Father of Medicine’ (Fig. 1.2). The Hippocratic Corpus describes a rectal speculum remarkably similar to the instruments in use today that were almost certainly used also for inspection of the vagina.

A three-bladed adjustable vaginal speculum was recovered from the molten lava and ash that engulfed the Roman city of Pompeii after the cataclysmic volcanic eruption of Mount Vesuvius in 70 AD and this remarkably sophisticated instrument (Fig. 1.3) can be seen at the Institute Rizzoli in Bologna in Northern Italy.

The Babylonian Talmud (Niddah Treatise) written in 500 AD after 300 years of preparation, described a sipherot, a tube made of lead with a wooden tip to ease insertion into the vagina, that was used to observe the cervix.<sup>18</sup> Even with improved visualisation using ‘the good light of the sun’ reflected and focussed by various mirrors there was never



**Fig. 1.2** *Hippocrates* (460–375 BC) as depicted in a fourteenth-century miniature inspecting urine. National Library, Paris, France.



**Fig. 1.3** Three-bladed vaginal speculum discovered in Pompeii in 70 AD after the eruption of Vesuvius. Institute Rizzoli, Bologna, Italy.

<sup>a</sup> MA, MB, BCh, (Cantab) FRCOG;  
Professor of Gynaecological Surgery,  
Faculty of Health and Social Sciences,  
University of Surrey, Guildford, UK  
Director of the Minimal Access Therapy Training Unit,  
Royal Surrey County Hospital, Guildford, UK

**Corresponding author:****Christopher J.G. Sutton**

MA, MB, BCh, (Cantab) FRCOG  
Gunners Farm, Stringers Common,  
Jacobs Well, Guildford, Surrey GU4 7PR, UK  
E-mail: chrislasersutton1@btinternet.com



a description of a blue-domed cyst in the posterior vaginal fornix or an endometriotic implant on the cervix which would have been obvious even without the assistance of a modern light source.

### 1.2.1.3 From Ancient Greece to Rome: Pythagoras, Hippocrates and Galen

This lack of comprehensive data is compounded by a certain mystique about female anatomy exemplified by the fact that the ancient Greeks regarded the uterus (hysteros) as the seat of the soul and they believed that the uterus wandered around the abdominal cavity and that when the organ was displaced the poor woman developed signs of hysteria.<sup>42</sup>

The Pythagoreans believed that the uterus was bifid which almost implies a knowledge of embryology and anatomy but probably arose from the fact that they were permitted to dissect animals but human dissection was forbidden. They hypothesised that the left uterine horn represented the west, or darkness, from which females were derived whereas the right side represented the east, or light, in which males developed. It is conceivable that this has laid the basis of the concept of the inferiority of women compared to men which has persisted until relatively recently.

Although these ancient writings describe female symptoms especially in regard to the influence of painful menstruation, odiferous vaginal discharge and chronic pelvic pain and suggest plentiful, and often bizarre, suggestions for natural or herbicidal treatment there is nowhere a specific suggestion indicating endometriosis as the cause.

Hippocrates did not write specifically on female anatomy, but he theorised that the uterus went wild if not fed on semen and his followers practiced an elementary form of gynaecological treatment but, nevertheless, he and his followers performed careful internal examinations of the pelvis conducted with great skill and would almost certainly have picked up the nodular fibrotic swelling of deeply infiltrating endometriosis in

the posterior fornix and signs of a painful ovarian swelling in the adnexal region suggesting a large ovarian endometrioma (chocolate cyst) and yet there is no descriptions of such signs in their writing.

The situation is completely different with uterine leiomyomata (fibroids), that are the most common benign tumours to afflict the pelvic organs of women, and references have been made to them since antiquity. Radiography of some of the remains of Egyptian mummies revealed several instances of calcified leiomyomas which can be seen in the Egyptology Section of the British Museum in London.<sup>73</sup> These lesions were certainly recognised at the time of the ancient Greeks, and *Hippocrates* called them ‘womb stones’ whilst *Galen*, (Fig. 1.4) a Roman physician who lived in the second century AD, described them as ‘scleromas’.<sup>42</sup>

Descriptions of most gynaecologic diseases can be recognized in the writings of *Hippocrates*, *Soranus of Ephesus* (Fig. 1.5), or followers of the Greek god of healing *Asclepius* (Fig. 1.6), or the Hebrew Talmud, but this is not the case with endometriosis.

Most of our knowledge of surgery in Greek and Roman times is derived from *Gynaecology*, the oldest published work on obstetrics and gynaecology written by *Soranus* and translated by *Owsei Temkin*<sup>62,63</sup> in 1956. *Soranus* was born in Ephesus in Asia Minor and, being situated between India and Greece absorbed the early medical ideas of these two great cultures. Ephesus, which has a well preserved stone amphitheatre was originally a Greek city and a famous port on the Aegean Sea but the Turks captured that part of Greece and it is now situated in Turkey, just north of Izmir, and the sea has now retreated so it is no longer a seaport. *Soranus* received his medical training in Alexandria in Egypt and later worked in Rome during the reigns of *Emperor Trajan* (AD 98–117) and *Emperor Hadrian* (AD 117–138). He wrote the first textbook of Obstetrics and Gynaecology entitled ‘Gynaecology’ and in it there is a well documented case of a vaginal hysterectomy which explained in detail an operation performed by the author which involved the removal of an inverted uterus that had become gangrenous and had turned black in colour. Rumour has it that his father had performed a similar operation as



**Fig. 1.4** *Claudius Galen* (129–201 AD) a Roman physician who described fibroids as ‘scleromas’. *Library of Congress, Washington, DC, USA.*



**Fig. 1.5** *Soranus of Ephesus* (AD 98–138) who wrote the first textbook of Gynaecology. *Photo by Chris Sutton at the Ephesus Amphitheatre.*



**Fig. 1.6** *Asclepius*, the Greek God of healing treats a young patient who has an injured shoulder. *Museum of Piraeus, Athens, Greece.*

had *Themison of Athens* a long time previously in 50 BC.<sup>69</sup> It is unlikely that the patients survived this ordeal since the bladder and ureters were invariably part of the removed uterus during these early operations.<sup>14</sup> *Soranus* was probably the first surgeon to look inside the living body even though he used the vaginal approach and he does describe filmy adhesions which are most likely to be a result of pelvic sepsis but there is no mention of lesions resembling endometriosis.

#### 1.2.1.4 Endometriosis Not Mentioned in Medical Historical Encyclopaedias

I can find no compelling evidence that endometriosis existed in ancient times and suggest that it is a relatively recent arrival in the pantheon of gynaecological diseases. This is supported by the fact that there is no reference to endometriosis in any of the medical historical encyclopaedias, such as the *Cambridge World History of Human Disease*, edited for the Cambridge University Press in 1993 by *Kenneth Kiple*.<sup>27</sup> Even the *Encyclopaedia of Medical History* by *Roderick McGrew*<sup>34</sup> published in 1985 and the extensive study by the television historian *Roy Porter*, entitled *The Greatest Benefit to Mankind*<sup>46</sup> published in 1997, does not mention endometriosis at all.

It is possible that this is due to the extreme rarity of this disease in ancient times when women were subjected to much less retrograde menstruation than their modern counterparts. Thus, girls in Roman times (Fig. 1.7) usually married at 14, or younger, and were expected to become pregnant within a few months. Further pregnancies followed in rapid succession and breast feeding was universally practiced resulting in a postpartum amenorrhoeic state until they met with an early demise, either in childbirth or naturally, since the average age of death was 35. Thus the number of exposures of a woman of those times to retrograde flow of endometrial tissue was minimal compared to her modern-day counterpart.<sup>76</sup>

#### 1.2.1.5 Endometriosis in the Middle Ages

The earliest reference in the literature to a disease that could possibly be endometriosis only appears as a vague reference as late as 1690, soon after the Great Plague and Great Fire of London when a German Physician, *Daniel Schroen* writing



**Fig. 1.7** Roman girls in bikinis playing various sports from a mosaic at the Villa Romana del Casale in Sicily, Italy. Photo by Chris Sutton.

in his *Disputato Inauguralis Medica de Ulceribus Ulceri*<sup>7</sup> describes it as 'a female disorder characteristic of those who are sexually maturing'. Almost a century later it is described more graphically by *William Smellie* from Edinburgh, the former tutor of *John Hunter's* brother *William*, in his textbook *Dissertatio medica inauguralis de utero inflammatione ejusdem*.<sup>4</sup> 'An affliction that permeated the whole female system ... producing morbid symptoms that manifestly change the disposition of the entire body. Those of us that have spent most of our working lives looking after women with this unpleasant disease will surely recognise this description'.

Although it was referred to sporadically in European texts from the 17<sup>th</sup> and 18<sup>th</sup> Centuries,<sup>4</sup> it is difficult to determine when the disease first appeared.<sup>28</sup>

#### 1.2.1.6 Is Endometriosis a Modern Disease?

Professors *Michelle Nisolle* and *Jacques Donnez*, when they were working together at the Catholic University Hospital of Louvain in Brussels, hypothesised that endometriosis is in fact three completely separate conditions; namely, superficial peritoneal endometriosis, ovarian endometriomas, and deep infiltrating disease of the rectovaginal septum and the uterosacral complex, which is in reality adenomyosis.<sup>40</sup> If one accepts the premise that retrograde menstruation is the main cause of superficial peritoneal endometriosis, then one would expect to find the disease more often in women with an increased exposure to menstruation. Such increases are inherent in the modern tendency for women to delay childbearing until their late 1930s or early 1940s. It is probably for this reason that endometriosis was regarded as an affliction of modern times and, until recently, was considered to be a disease of more affluent Western women. In recent years, however, this trend has become less evident and, with the worldwide increase in the use of laparoscopy to diagnose the condition, it is becoming all too obvious that endometriosis is not merely a disease of 'well-to-do ladies of European extraction', but it poses a significant health problem in other countries with increasing social, medical and technological development such as Singapore, Malaysia, India, China and particularly Japan, which may have the highest incidence in the world.<sup>36</sup>

A review of the relevant literature suggests that Belgium has the highest incidence of the disease in Europe. According to a report from the World Health Organisation, the highest concentrations of dioxin in breast milk in the world are in Belgium and, interestingly, the highest concentration of cases is reputedly in the main industrial corridor running along the south of the country.<sup>79</sup>

*Philippe Koninckx* and his colleagues have suggested that dioxin and polychlorinated biphenyl pollution is a possible co-factor in the initiation and/or development of deep infiltrating endometriosis<sup>30</sup> and this has resulted in a steadily increasing proportion of hysterectomies performed in Belgium for this type of disease from 10% in 1965 to over 18% in 1984 and this has continued to rise since then.<sup>37,45</sup>



Dioxin has immunosuppressive activities and is a potent inhibitor of T-lymphocyte function.<sup>21,38</sup> A group of rhesus monkeys, which were chronically exposed to dioxin for a period of 4 years and followed by serial laparoscopies, were found to have developed endometriosis 7 years after the termination of dioxin exposure and in the majority of these cases it was of the deeply infiltrating adenomyotic variety.<sup>51</sup> Dioxin is a potentially harmful by-product of the chlorine bleaching process used in the wood pulp industry, which includes the manufacture of feminine hygiene products such as tampons. It is therefore of some concern that young girls are increasingly being encouraged to use tampons and therefore may possibly be at risk of subjecting the tissues of the rectovaginal septum and posterior vaginal fornix to the chronic exposure from a known immunosuppressant from a very early age. It has been suggested that a woman may use as many as 11,000 tampons in her lifetime, and this represents a worrying level of dioxin exposure to the delicate vaginal tissue in the posterior fornix, which could result in deep infiltrating endometriosis and could explain the increasing incidence of this condition in young women.<sup>76</sup> It was unknown in ancient times and can genuinely be considered a new disease that has resulted from industrial or commercial pollutants. The fact that dioxins are released into the atmosphere as part of the incineration of domestic waste is an added cause for concern.<sup>79</sup>

The third type of endometriosis, ovarian endometriomas (chocolate cysts), would only have been discovered at laparotomy. Since the first laparotomy was performed by *Ephraim McDowell* (1771–1830) (Fig. 1.8) on Christmas Day in 1809 in Danville, Kentucky.<sup>19,75</sup> It can be seen that surgery is a relatively modern intervention in historical terms and explains why this disease is absent from ancient historical texts.



**Fig. 1.8** *Ephraim McDowell* (1771–1830). The Father of Abdominal Surgery. Performed the first laparotomy for a massive ovarian cyst on Christmas day 1809. Painting by P.W. Davenport in McDowell House, Danville, Kentucky, USA. Reprinted with permission.

#### 1.2.1.7 Anatomic Dissection in the 18<sup>th</sup> Century Leads to the Discovery of Uterine Pain Pathways

Although human dissection was forbidden in ancient Greece, it was widely practiced in 18<sup>th</sup> Century London and one of its foremost proponents was the celebrated Scottish surgeon *John Hunter*, (Fig. 1.9) one of the teachers of *Ephraim McDowell* during the two years he studied in Edinburgh. *John Hunter* was one of the most distinguished scientists and surgeons at that time and was an advocate of careful observation and scientific method in medicine. He learned anatomy by assisting his elder brother *William* with dissections in *William's* anatomy school in London and became an expert in the subject and after some years as an Army surgeon he set up his own Anatomy School. He was an avid collector of anatomical specimens eventually amassing a collection of 14,000 specimens that he bequeathed to the Royal College of Surgeons in London. This almost proved to be his undoing for there were allegations that he and his brother's former tutor, *William Smellie* (vide supra)<sup>4</sup> were responsible for the deaths of many pregnant women whose corpses were used for their studies on the anatomy of the gravid uterus.<sup>61</sup> This is unlikely since the maternal mortality in Georgian London was particularly high due to a combination of pre-eclampsia and puerperal sepsis, both of which were untreatable in those times.<sup>29</sup>

Nevertheless, it is certainly true that he acquired the skeleton of the Irish giant, *Charles Byrne* who was 2.31 metres tall, by bribing a member of the funeral party to the tune of £500 and filling the coffin with rocks during an overnight stop. This was against the wishes of the deceased who wished to be buried at sea. The skeleton is presently exhibited in the Hunterian



**Fig. 1.9** *John Hunter* (1728–1793). Scottish surgeon, anatomist and teacher of *Ephraim McDowell* (1728–1793). Painted by John Jackson, 1813, after Sir Joshua Reynolds, 1786.

Museum at the Royal College of Surgeons in Lincoln's Inn Fields, London with much of Hunter's surviving collection and there is presently a small active vociferous group that are trying to remove the skeleton to honour Charles Byrne's deathbed wish and have the skeleton committed to the deep blue sea.

In spite of lurid tales of grave robbers and medical students gathering at London's main execution site at Tyburn to steal bodies of criminals who had just been hanged, anatomical dissection became increasingly sophisticated and detailed. This is exemplified by the incredibly detailed illustrations of the plexus of nerves supplying the uterus produced by *Robert Lee* (Fig. 1.10) in 1838 while dissecting a gravid uterus of a woman who had died at seven months gestation.<sup>32</sup> He was not a happy man and had long running disputes with colleagues that lasted many years and in 1843 he briefly held the Regius Chair of Midwifery at the University of Glasgow but not being a Glasgow man he was made to feel so unwelcome that he resigned within a few weeks of his appointment.<sup>3</sup>

*Ferdinand Frankenhäuser* (1832–1894) published a more detailed description of the nervous plexus and ganglia 20 years later<sup>17</sup> and the complex innervation of the uterus is generally named eponomously as the Lee-Frankenhauser plexus.

Attempts to interrupt many of these afferent pain fibres as they pass through the utero-sacral ligaments have met with reasonable success in diminishing the pain of primary dysmenorrhoea or secondary dysmenorrhoea and dyspareunia associated with endometriosis.




**Fig. 1.10** *Robert Lee* (1793–1877). Described and illustrated the uterine nerve supply in 1838. Reproduced from *Baskett TF 'On the Shoulders of Giants'*. RCOG Press, London.

Para-cervical uterine denervation was first described by *Joseph Doyle* in 1963 and the procedure still bears his name.<sup>13</sup> When performed vaginally, a suture was placed on the posterior lip of the cervix at the apex of the vagina and traction was applied to increase the distance of the cervix from the ureter. The attachments of the utero-sacral ligaments to the posterior aspect of the cervix were then divided between a pair of Heaney clamps and tissue from the posterior peritoneum was interposed between the cut ends to prevent regrowth. Doyle felt that gynaecologists would be more comfortable with the vaginal approach, but surgeons would prefer to operate through an abdominal incision and this approach was also recommended if endometriosis or other pathology was suspected.<sup>67</sup>

Doyle's results were extremely impressive, with complete pain relief in 63 out of 73 cases (86%) with those suffering from secondary dysmenorrhoea due to endometriosis having the most favourable results. With such a satisfactory outcome it is difficult to see why the procedure sank into obscurity, but the advent of powerful prostaglandin synthetase inhibitors and the introduction of laparoscopic laser surgery allowed uterine nerve ablation to be performed with less pain and morbidity and *Chris Sutton* reported in a series of 126 patients 86% improvement in those with endometriosis and slightly less (73%) in women with primary dysmenorrhoea.<sup>71</sup>

#### 1.2.1.8 Theories of Origin

*Friedrich von Recklinghausen*, (Fig. 1.11) a German pathologist born in Gütersloh in Westphalia studied in Berlin under the tutelage of *Rudolf Virchow*, who is widely regarded as the father



**Fig. 1.11** *Friedrich von Recklinghausen* (1833–1910) was the first to name the condition as endometriosis in 1885. Reproduced from *Baskett TF 'On the Shoulders of Giants'*. RCOG Press, London.



of modern pathology. He was a Professor at the University of Würzburg and later at the University of Strasbourg and was the first to name the condition as endometriosis in 1885<sup>47</sup> and he suggested that it developed from tissue of Wolffian origin.

The first detailed pathologic description of the disease was in 1860 by *Carl von Rokitansky*,<sup>52</sup> a Czech research pathologist working in Vienna, who supervised over 100,000 autopsies in his lifetime and was a great supporter of *Ignaz Semmelweiss*. He also, with others, described the condition of vaginal atresia known as the Rokitansky-Kustner-Hauser syndrome. In the following year, he described the condition of ovarian endometriosis, which was described by him as a 'cystosarcoma adenidese ovarii uterinum'.<sup>50</sup>

In 1896, *Thomas Cullen* (Fig. 1.12) described adenomyoma of the round ligaments, which he asserted was tissue of Mullerian origin.<sup>8</sup> *Cullen* was born in Bridgewater, Ontario, in Canada from Anglo-Irish stock. He graduated from the University of Toronto. He is famous for his observation now known as Cullen's sign describing the blue-black discolouration of the umbilicus as a clue to an ectopic pregnancy, but it is ironic that the paper describing this phenomenon was only one and a half pages long. He was also among the first to describe endometrial hyperplasia as a cause of menorrhagia. Two years later, *Iwanoff*<sup>52</sup> advocated the theory of serosal metaplasia and the following year *Russell*, also writing in the Johns Hopkins Hospital Bulletin described aberrant portions of the Mullerian duct found in an ovary.<sup>53</sup> Further ideas on the pathogenesis were put forward during the late 19<sup>th</sup> century and developed in the early part of the last century. In 1919, Thomas Cullen described the adenoma of the rectovaginal septum in an address to the 'Western Surgical Association' in Kansas City, which was published in the 'Archives of Surgery' (now 'JAMA Surgery') the following year.<sup>9</sup> He described tumours of non-stripped muscle, with islands of uterine mucosa scattered throughout them, that arise from behind the cervix and that

spread laterally to blend with the anterior wall of the rectum and the uterosacral ligaments. He also mentioned that these may also invade the broad ligaments, encircle the ureter, and break through into the vagina.

At the end of his address he said to the rather astounded audience:

'Many of you have undoubtedly seen them, but may not have recognised them. They are of unusual importance and, if overlooked, will in time cause the patient to become a chronic invalid, and in some instances will undoubtedly lead to her death.'

One cannot but feel that he then got rather carried away by saying:

'In less than 10 years I feel sure that the surgeon will recognise and operate on these 'adenomyomas of the rectovaginal septum' long before the wall of the rectum or the broad ligament have been involved.'

Some 97 years later very few gynaecologists seem able to recognise this disease and appreciate the clinical importance of the findings, let alone operate decisively to cure the patient.

#### 1.2.1.9 Sampson Describes the Ovarian Endometrioma and Proposes his Theory of Retrograde Menstruation

In 1921, Dr *John Albertson Sampson* (1873–1946) (Fig. 1.13), who practiced in Albany, New York State, began a series of reports starting with a description of ovarian endometriomas, which he described as 'perforating haemorrhagic (chocolate) cysts of the ovary'.<sup>54</sup> Once his interest had been fired, he began to publish a series of reports on endometriosis, including the possibility of malignant development<sup>55,56</sup> and during the following years, his theory of retrograde menstruation as the main etiologic factor in the development of this disease was published in a series of articles.<sup>57,58</sup>



**Fig. 1.12** *Thomas S. Cullen* (1868–1953) described adenomyoma of the round ligaments in 1896 and deep infiltrating endometriosis (adenomyomas) of the recto-vaginal septum in 1919. *Reproduced from Baskett TF 'On the Shoulders of Giants'. RCOG Press, London.*



**Fig. 1.13** *John Albertson Sampson* in 1921 described perforating haemorrhagic (chocolate) cysts of the ovary and later proposed the theory of retrograde menstruation. *Reproduced from Baskett TF 'On the Shoulders of Giants'. RCOG Press, London.*



His explanation seemed eminently logical because he surmised that the actual implantation of fragments of the shed endometrium that had been regurgitated from the fimbrial ends of the tubes explained the origin of the disease. This seemed justified by the observation of menstrual blood in the cul-de-sac at the time of laparotomy, and also that the sites of implantation most frequently seen are in the pouch of Douglas and the ovary closely adjacent to the tubal fimbriae and that these viable fragments would be expected to gravitate to these sites and implant and grow to produce the characteristic lesions.

Sampson was born in Troy, New York State, and graduated from *Johns Hopkins* (1795–1873) in Baltimore in 1899. He was a bachelor and was fond of animals and trees. It is said that he once changed a new car because his dog did not like it.

After its publication, the Sampson theory gave rise to much debate and still does to this day.<sup>49</sup> The main objection to Sampson's theory of retrograde menstruation was the frequent observations of endometriosis occurring at distant sites, such as the umbilicus, inguinal lymph nodes, the dome of the diaphragm, and the pleura, and this was explained by the theory of coelomic metaplasia described by *Iwanoff*<sup>22</sup> and *Meyer*.<sup>35</sup> Other theories were put forward to explain the spread of endometriosis to distant sites and the theory of endolymphatic spread was first proposed by *Halban*.<sup>20</sup> Sampson also demonstrated metastatic or embolic endometriosis in the venous circulation, suggesting that haematogenous dissemination of the disease was a possibility.<sup>59</sup> The first report of urinary tract involvement was by *Judd* in 1921.<sup>25</sup> There is almost certainly an element of truth in all of these theories and the aetiology and pathogenesis of endometriosis are eloquently described and summarised by *Story and Kennedy*<sup>65</sup> and by *Nisolle and Foidart*.<sup>41</sup>



**Fig. 1.14** Dr. Georg Kelling (1866–1945). One of the fathers of laparoscopy. Photo by Chris Sutton from an original photo supplied by Prof. Dr. Liselotte Mettler.

### 1.2.2 The Era of Laparoscopy and Laparoscopic Surgery

Before the introduction of culdoscopy and laparoscopy endometriosis required a laparotomy for diagnosis and possible treatment. Laparotomy was a painful procedure associated with a considerable morbidity and occasional mortality so was not embarked upon merely to make a diagnosis but reserved for cases involving a large ovarian endometrioma and even then it was justified by the need to rule out malignancy.

The first endoscopy on a human was performed in 1901 by *von Ott*<sup>43</sup> from St. Petersburg, Russia, who examined the abdominal cavity of a pregnant woman through a culdoscopic incision in the posterior vaginal fornix using a head mirror to reflect the light. In 1901, Dr. *Georg Kelling* (Fig. 1.14), who was a Professor in Dresden, in an address he gave to the German Biological and Medical Society in Hamburg, described the visual examination of the stomach and oesophagus in the human and additionally the use of a cystoscope to visualise the viscera of a dog using air filtered through cotton wool to produce a pneumoperitoneum.<sup>26</sup> The credit for the first true laparoscopy on a human must go to *Hans Christian Jacobaeus* (Fig. 1.15) of Stockholm,<sup>23</sup> who in 1910 described inspection of the peritoneal, thoracic, and pericardial cavities.



**Fig. 1.15** Hans Christian Jacobaeus (1879–1937) of Stockholm, Sweden. The first person to perform laparoscopy on humans. Photo from the Archives of the Minimal Access Therapy Training Unit, Guildford, UK.

### 1.2.2.1 The Development of Operative Laparoscopy

It is interesting that surgeons from the United States of America were actively involved in the early development of laparoscopy,<sup>18</sup> but in the 1940's the technique was virtually abandoned in North America and replaced by culdoscopy in many centres.<sup>11</sup> Nevertheless, laparoscopy continued to develop in Europe under the influence of *Raoul Palmer* from Paris<sup>44</sup> (Fig. 1.16) and later *Hans Frangenheim* from Konstanz in Germany.<sup>16</sup>

Presumably, the Second World War presented difficulties in communication and exchange of ideas across the Atlantic Ocean and it was not until *Patrick Steptoe* (Fig. 1.17) visited *Raoul Palmer* in Paris and subsequently described the technique of laparoscopy in his book 'Laparoscopy in Gynaecology'



**Fig. 1.16** Dr. Raoul Palmer (1904–1985) from Paris. Generally considered the 'Father of Operative Laparoscopy' Photo by kind permission of the late Mme Elizabeth Palmer.



**Fig. 1.17** Patrick Steptoe (1913–1988) from Oldham, near Manchester, UK. One of the pioneers of In-Vitro Fertilisation who wrote the first book in English on Laparoscopy. Photo supplied by the late Patrick Steptoe.

that the first practical textbook in the English language was published in 1967.<sup>64</sup> In that volume, Steptoe described several laparoscopic operations, including aspiration of ovarian cysts and simple ovarian cystectomy, as well as laparoscopic ventro-suspension, which is rarely practiced nowadays. As is well known, Steptoe continued his interest in laparoscopy and many surgeons from the United Kingdom visited him to learn this new technique, even though it meant journeying to Oldham, an industrial town in Lancashire, in the North of England. In spite of the drabness of the surroundings, work of universal importance was taking place with the collaboration of the physiologist and embryologist *Robert Edwards* (1925–2013) from Cambridge University's Department of Physiology, which eventually resulted in the first baby produced by in vitro fertilisation in the world: *Louise Brown* was born in Oldham at nearly midnight on the 25<sup>th</sup> July 1978.

Initially laparoscopy was used for diagnosis and relatively simple therapeutic procedures such as female sterilisation and puncture or fenestration of benign ovarian cysts but gradually became more sophisticated owing much to the pioneering work of Professor *Kurt Semm*<sup>60</sup> (Fig. 1.18) of Kiel University in Northern Germany and the gifted team of surgeons led by Professor *Maurice Bruhat* (Fig. 1.19) at the University of Clermont Ferrand in the Auvergne in France.<sup>5</sup> Endometriosis was the disease that benefited most since the visualisation of the characteristic lesions afforded by the laparoscope allowed it to be diagnosed accurately and as power sources were developed which enabled it to be treated surgically at the same time.<sup>68</sup>



**Fig. 1.18** Professor Kurt Semm (1927–2003) from Kiel, Germany, one of the great advocates and teachers of laparoscopic surgery and an inventor of much of the original equipment. Photo taken by Chris Sutton on his visit to the Minimal Access Therapy Training Unit in Guildford, UK.



**Fig. 1.19** Professor Maurice Bruhat (1934–2014) from the University of the Auvergne in Clermont Ferrand in France who performed the first laparoscopic removal of an ectopic pregnancy with Dr. Hubert Manhes. Photo given to Chris Sutton by the late Maurice Bruhat.

### 1.2.2.2 The Evolution of the Laparoscopic Appearances of Endometriosis

When he was describing the appearances of endometriosis at laparotomy, *Sampson* used terms such as red raspberries, purple raspberries, blueberries, blebs, and peritoneal pockets in his original series of articles.<sup>56–58</sup> Subsequent articles tended to emphasise the blue or black classical ‘powder-burn’ appearance of endometriosis and, certainly, in the 1970s this was considered the hallmark of the diagnosis of endometriosis to the extent that this was called a ‘typical’ lesion. This attitude changed completely with the publication of the seminal paper by *Jansen* and *Russell*, entitled ‘Non-pigmented endometriosis: clinical, laparoscopic and pathological definition’, which described a whole range of different appearances such as white opacified peritoneum resembling vesicles or ‘sago-grains’, red flame-like telangiectatic lesions, and glandular lesions resembling endometrium at hysteroscopy.<sup>24</sup> *Jansen* and *Russell* showed that many of these macroscopic appearances are associated with active endometriosis by demonstrating endometrial glands and stroma on histologic inspection of peritoneal biopsies in 67–81% of cases. Other lesions such as sub-ovarian adhesions, yellow-brown peritoneal patches, and circular peritoneal defects had endometriosis in 50% of the biopsies. In fact, although *Sampson* had mentioned peritoneal pouches in his original description, they later became associated with two gynaecologists from the Southern United States, *Allen* and *Masters*.<sup>2</sup> These Southern gentlemen suggested that these lesions, which were particularly common in the Afro-Caribbean population, were due to childbirth trauma or possibly damage from vigorous sexual intercourse, but it was found that biopsy of the base of these peritoneal defects virtually always revealed endometriosis and a causal relationship was postulated.<sup>6</sup> It is my belief that they represent the early stage of cul-de-sac obliteration, which later develops into deep infiltrating endometriosis.

*Redwine* suggested that there appeared to be a relationship between the colour and the age of the endometrial implants and indeed even with the age of the patient; the non-haemorrhagic lesions are more usually found in young women and the black deposits laden with hemosiderin are more common in older patients.<sup>48</sup>

*Martin et al.* pioneered excisional techniques using the CO<sub>2</sub> laser laparoscopically for the treatment of abnormal appearing peritoneum<sup>33</sup> which provided the basis for extensive histologic studies of abnormal peritoneum, and, in a subsequent study, used up to 20 descriptive terms to characterise the appearance of endometriosis.

### 1.2.2.3 The Appliance of Science

The Carbon Dioxide laser was introduced by *Bruhat* and his team from *Clermont Ferrand*,<sup>5</sup> and in the early days of operative laparoscopy became a popular energy source for the laparoscopic vaporisation or excision of superficial peritoneal endometriosis and was shown to be safe and extremely precise with very little damage to surrounding tissue and with little residual debris the vaporised implants healed perfectly with virtually no scar formation, fibrosis or tissue contraction.<sup>66</sup> Although by modern standards this would seem an expensive way to deliver energy via the laparoscope, this was in the late 1970’s and mid 1980’s during the initial phase of laparoscopic surgery when instruments were reusable and scissors were not self sharpening or designed for single use. At that time electrosurgery did not have the same safeguards to prevent burns from insulation failure or capacitive coupling that is incorporated into modern electrosurgical generators and there was sufficient concern over the incidence of electrosurgical injuries that it was banned in Germany for a length of time and *Semm* introduced endocoagulation, whereby the tissue was heated slowly to 120 °C to denature protein and cause haemostasis and occlusion of vessels without any electric current passing through the body.<sup>76</sup>

There were many retrospective studies from Europe and the USA showing a pain relief rate of the order of 75%<sup>10,12,15,39</sup> and our own study with five year follow-up showed similar pain relief and was also associated with a pregnancy rate of 80% with most women conceiving within a few months of laser surgery.<sup>70</sup> Although these results were remarkably consistent, they were met with considerable scepticism from our academic colleagues who felt that the personality of the surgeon could influence the response of the women with regard to improvement in pain scores.

Since evidence-based studies had been used in the evaluation of medical therapy in endometriosis, we felt it necessary to perform a double blind prospective randomised controlled trial (RCT) in surgery that had never been attempted before. My research team had the difficult task of recruiting women into this study because patients had been referred specifically for laparoscopic laser surgery and were asked to take part in a trial where one arm would only have a diagnostic laparoscopy but would have the same incisions and, in order to remove bias, the operation details were sealed and follow-up was documented by a research nurse, who was unaware of the details of the surgery. Thus it was entirely double blind



comparing treatment or no treatment and neither the patient nor the nurse involved in the follow-up would know which arm of the trial they were in. The results showed a large placebo response in the no-treatment group at three months but at six months there was a significant difference in the two groups and the visual analogue pain scores had improved considerably in the laser treatment group, but had returned to pre-operative levels in the women who only had a diagnostic laparoscopy.<sup>74</sup>

Although this study had full ethical approval and in order not to penalise patients, who did not have laser treatment and failed to have pain relief, they were offered such treatment as soon as it could be arranged after the six month follow-up visit. Nevertheless, the study had certain limitations in that we were only allowed to include women with minimal, mild and moderate stages of endometriosis since our results for severe endometriosis in a previous study had been excellent and it was deemed ethically wrong to withhold treatment for those women with severe (Stage IV) disease.<sup>77</sup> Additionally, a priest on the ethics committee had deemed it unacceptable to ask questions about sex-related activity such as dyspareunia and quality of sexual satisfaction. Happily, my good friend Professor *Ray Garry* (Fig. 1.20) conducted a virtually identical study in his department at the James Cook University Hospital in Middlesbrough and addressed Quality-of-Life issues and included all stages of the disease and came up with virtually identical results.<sup>1</sup>

There was a further criticism based on the fact that our standard treatment protocol involved laser vaporisation of all endometriosis implants and vaporisation of the pain fibres in the Lee-Frankenhauser plexus that pass through the uterosacral ligaments. We then had to perform a further double blind prospective RCT with one group having a laparoscopic uterine nerve ablation (LUNA) with vaporisation of the implants and the other having vaporisation alone. This was an easier trial to recruit patients since they all had a some form of laser treatment and the results showed that the LUNA did not add anything to the pain relief.<sup>72</sup>



**Fig. 1.20** Professor *Ray Garry* from James Cook University Hospital in Middlesbrough, UK. Responsible for the best evidence based clinical trials in laparoscopic surgery and endometriosis. *Photo Chris Sutton.*

#### 1.2.2.4 Deep Infiltrating Endometriosis

In a 3-year prospective study of 643 consecutive laparoscopies in the early 1990s, *Koninckx et al.* demonstrated a highly significant correlation between pain and the depth of the endometriotic implant and showed that deeply infiltrating endometriosis was found primarily in the retroperitoneal areas in the rectovaginal septum, the uterosacral ligaments, and, occasionally, in the pelvic sidewall around the ureter and the utero-vesical fold.<sup>31</sup> These sclerotic lesions with considerable fibromuscular hyperplasia can often be palpated rather than seen and are best diagnosed by a clinical examination, preferably performed during menstruation.

As the 1990s slowly turned into the new millennium, it became increasingly obvious that most tertiary referral centres dealing with a large volume of women with endometriosis were seeing more patients with deep infiltrating disease and many with bowel involvement presenting with painful rectal bleeding during menstruation. Many of these patients had such obvious large painful nodules in the vaginal fornices that it is difficult for me to believe that this disease existed to the same extent 20 years ago. I am strongly of the opinion that it is a new disease that is increasingly common and not due to the fact that we did not recognize it in the past.

This type of disease requires patients to be referred to special centres of excellence where they can be cared by an expert team of laparoscopic gynaecological surgeons with access to power sources they are most comfortable with,<sup>78</sup> be it electrosurgery with or without ultrasonic energy, different wavelength lasers, argon neutral plasma energy or simply scissors that cut efficiently and devices to adequately seal large bleeding vessels. They should have access to 3-D cameras and Da Vinci Robots if they wish and have the requisite skills and finance to use them but, above all, they should be involved with expert laparoscopic colorectal and urological surgeons with special expertise, interest and knowledge of this strange disease and its protean manifestations. The team should be backed up by a team of caring and understanding nurses and involve pain specialists, interested physicians and pharmacologists, psychologists and even alternative medicine practitioners.

All of these, and the skills and practical approaches they employ, are covered in this comprehensive textbook that aims to make a significant therapeutic improvement in women who suffer from this strange, painful and poorly understood affliction.

#### 1.2.3 References

1. ABBOTT J, HAWE J, HUNTER D, HOLMES M, FINN P, GARRY R. Laparoscopic excision of endometriosis: a randomized, placebo-controlled trial. *Fertility and sterility* 2004; 82(4): 878–84.
2. ALLEN WM, MASTERS WH. Traumatic laceration of uterine support; the clinical syndrome and the operative treatment. *American journal of obstetrics and gynecology* 1955; 70(3): 500–13.
3. BASKETT TF. On the shoulders of giants: Eponyms and names in obstetrics and gynaecology. 2<sup>nd</sup> ed. London: RCOG Press; 2008: 439 pp.
4. BROTHERTON L. *Dissertatio medica inauguralis de utero inflammatione ejusdem.* Balfour and Smellie (eds). Edinburgh University Press. 1776: 16–22.

5. BRUHAT MA, MAGE G, MANHES H. Use of the CO<sub>2</sub> laser via laparoscopy: Proceedings of the 3rd Congress of the International Society for Laser Surgery. In: Kaplan I, ed. Laser surgery; 1979: 275–82.
6. CHATMAN DL. Pelvic peritoneal defects and endometriosis: Allen-Masters syndrome revisited. *Fertility and sterility* 1981; 36(6): 751–6.
7. CRAUSE RW, SCHRÖN DC. *Disputatio inauguralis medica de ulceribus uteri*. Jena: Literis Krebsianis; 1690.
8. CULLEN TS. Adenomyoma of the round ligament. *Johns Hopkins Hosp Bull* 1896; (7): 112–3.
9. CULLEN TS. The distribution of adenomyomas containing uterine mucosa. *Archives of Surgery* 1920; 1(2): 215–83.
10. DANIELL J. Operative Laparoscopy for Endometriosis. *Seminars in Reproductive Medicine* 1985; 3(04): 353–9.
11. DECKER A. Culdoscopy; its diagnostic value in pelvic disease. *Journal of the American Medical Association* 1949; 140(4): 378–85.
12. DONNEZ J. CO<sub>2</sub> laser laparoscopy in infertile women with endometriosis and women with adnexal adhesions. *Fertility and sterility* 1987; 48(3): 390–4.
13. DOYLE JB. Paracervical uterine denervation by transection of the cervical plexus for the relief of dysmenorrhea: *American Journal of Obstetrics & Gynecology*. *American Journal of Obstetrics & Gynecology* 1955; 70(1): 1–16.
14. EMGE LA, DURFEE RB. Pelvic organ prolapse: four thousand years of treatment. *Clin Obstet Gynecol* 1966; 9(4): 997–1032.
15. FESTE JR. Laser laparoscopy. A new modality. *The Journal of reproductive medicine* 1985; 30(5): 413–7.
16. FRANGENHEIM H, FINZER K-H. *Laparoscopy and culdoscopy in gynecology: Textbook and atlas*. London; Stuttgart: Butterworths Thieme; 1972: 109 pp.
17. FRANKENHÄUSER F. Die Nerven der Gebärmutter und ihre Endigung in den glatten Muskelfasern: Ein Beitrag zur Anatomie und Gynäkologie. Jena: Mauke; 1867: 82 pp.
18. GORDON AG, TAYLOR PJ. History and development of endoscopic surgery. In: Sutton C, Diamond MP, eds. *Endoscopic Surgery for Gynecologists*. W.B. Saunders; 1998: 1–8.
19. GRAY LA, BRYANT O. *The life and times of Ephraim McDowell*. Danville Ky.: Ephraim McDowell House; 1987: xii, 157 pp.
20. HALBAN J. *Histeroadenosis metastatica*. *Wiener Klinische Wochenschrift* 1924; 37: 1205–10.
21. HOLSAPPLE MP, SNYDER NK, WOOD SC, MORRIS DL. A review of 2,3,7,8-tetrachlorodibenzo-p-dioxin-induced changes in immunocompetence: 1991 update. *Toxicology* 1991; 69(3): 219–55.
22. IWANOFF NS. IV. Drüsiges cystenhaltiges Uterusfibromyom compliciert durch Sarcom und Carcinom. (Adenofibromyoma cysticum sarcomatodes carcinomatodesum). *Monatsschrift für Geburtshilfe und Gynäkologie* 1898; 7(3): 295–300.
23. JACOBÆUS HC. Über die Möglichkeit die Zystoskopie bei Untersuchung seröser Höhlungen anzuwenden. *Münchener Medizinische Wochenschrift* 1910; 57: 2090–2.
24. JANSEN RP, RUSSELL P. Nonpigmented endometriosis: clinical, laparoscopic, and pathologic definition. *American journal of obstetrics and gynecology* 1986; 155(6): 1154–9.
25. JUDD ES. Adenomyomata presenting as a tumour of the bladder. *Surgical Clinics of North America* 1921; 1: 1271–8.
26. KELLING G. Über Ösophagoskopie, Gastroskopie und Kōlioskopie. *Münchener Medizinische Wochenschrift* 1902; 49(1): 21–4.
27. KIPLE KF. *The Cambridge World History of Human Disease*: Cambridge University Press; 1993.
28. KNAPP VJ. How old is endometriosis? Late 17th- and 18th-century European descriptions of the disease. *Fertility and sterility* 1999; 72(1): 10–4.
29. KOBLER J, WANTZ GE. *The reluctant surgeon: a biography of John Hunter*. Garden City, N.Y.: Doubleday & Company, Inc.; 1960: 359 pp.
30. KONINCKX PR, BRAET P, KENNEDY SH, BARLOW DH. Dioxin pollution and endometriosis in Belgium. *Hum Reprod* 1994; 9(6): 1001–2.
31. KONINCKX PR, MEULEMAN C, DEMEYERE S, LESAFFRE E, CORNILLIE FJ. Suggestive evidence that pelvic endometriosis is a progressive disease, whereas deeply infiltrating endometriosis is associated with pelvic pain. *Fertility and sterility* 1991; 55(4): 759–65.
32. LEE RJ. *On the ganglia and the other nervous structures of the uterus*. London: Richard and John E. Taylor; 1842: 11 pp.
33. MARTIN DC, HUBERT GD, VANDER ZWAAG R, EL-ZEKY FA. Laparoscopic appearances of peritoneal endometriosis. *Fertility and sterility* 1989; 51(1): 63–7.
34. MCGREW RE, MCGREW MP. *Encyclopedia of medical history*: McGraw-Hill; 1985.
35. MEYER R. Über eine adenomatöse Wucherung der Serosa in einer Bauchnarbe. *Z Geburtsh Gynäk* 1903; 49: 32–41.
36. MIYAZAWA K. Incidence of endometriosis among Japanese women. *Obstet Gynecol* 1976; 48(4): 407–9.
37. NATIONAL CENTER FOR HEALTH STATISTICS. *Hysterectomies in the United States 1965–84*. Hyattsville, Md.: U.S. Dept. of Health and Human Services, Public Health Service, Centers for Disease Control; 1986: 145–56.
38. NEUBERT R, JACOB-MULLER U, HELGE H, STAHLMANN R, NEUBERT D. Polyhalogenated dibenzo-p-dioxins and dibenzofurans and the immune system. 2. In vitro effects of 2,3,7,8-tetrachlorodibenzo-p-dioxin (TCDD) on lymphocytes of venous blood from man and a non-human primate (*Callithrix jacchus*). *Arch Toxicol* 1991; 65(3): 213–9.
39. NEZHAT C, CROWGEY SR, GARRISON CP. Surgical treatment of endometriosis via laser laparoscopy. *Fertility and sterility* 1986; 45(6): 778–83.
40. NISOLLE M, DONNEZ J. Peritoneal endometriosis, ovarian endometriosis, and adenomyotic nodules of the rectovaginal septum are three different entities. *Fertility and sterility* 1997; 68(4): 585–96.
41. NISOLLE M, FOIDART J-M. Pathogenesis of peritoneal endometriosis. In: Sutton C, Jones K, Adamson GD, eds. *The modern management of endometriosis*. London; New York: Taylor & Francis; 2006: 25–40.
42. O'DOWD MJ, PHILIPP EE. *The History of Obstetrics and Gynaecology*. Carnforth Lancs: The Parthenon Publishing Group; 1994.
43. OTT DO. Illumination of the abdominal cavity (ventroscopy), as a method in vaginal laparotomy [in Russian: osveshcheniye bryushnoy polosti (ventroscopia), kak metod pri vlagalishchnom chroveosechenii]. *Zhurnal' akusherstva i zhenskikh' boleznei*; 1901(7–8): 1045–9.
44. PALMER R. *La coelioscopie [Laparoscopy]*. *Bruxelles médical* 1948; 28(6): 305–12.
45. POKRAS R, HUFNAGEL VG. *Hysterectomies in the United States. Data From the National Health Survey Series* 1987; 13(92): 1–32.

46. PORTER R. The greatest benefit to mankind: a medical history of humanity from antiquity to the present. London: Harper Collins; 1997.
47. RECKLINGHAUSEN FDV. Über die venöse Embolie und den retrograden Transport in den Venen und in den Lymphgefäßen. Virchows Archiv für pathologische Anatomie und Physiologie und für klinische Medizin 1885; (100): 503–39.
48. REDWINE DB. Age-related evolution in color appearance of endometriosis. Fertility and sterility 1987; 48(6): 1062–3.
49. REDWINE DB. Redwine DB. Was Sampson wrong? In: Redwine DB, ed. Surgical management of endometriosis. London: Martin Dunitz; 2004: 1–11.
50. RICCI JV. One hundred years of gynaecology, 1800–1900: A comprehensive review of the specialty during its greatest century with summaries and case reports of all diseases pertaining to women. 110, 157, 163, 491. Philadelphia: The Blakiston Company; 1945.
51. RIER SE, MARTIN DC, BOWMAN RE, DMOWSKI WP, BECKER JL. Endometriosis in rhesus monkeys (*Macaca mulatta*) following chronic exposure to 2,3,7,8-tetrachlorodibenzo-p-dioxin. Fundamental and applied toxicology : official journal of the Society of Toxicology 1993; 21(4): 433–41.
52. ROKITANSKY CV. Über Uterusdrüsen-Neubildung in Uterus- und Ovarial-Sarcomen. Zeitschrift der Gesellschaft der Aerzte 1860; (16): 577–81.
53. RUSSEL WW. Aberrant portions of the Mullerian duct found in an ovary. Johns Hopkins Hospital Bulletin 1899; 10: 8–10.
54. SAMPSON JA. Perforating haemorrhagic (chocolate) cysts of the ovary. Their importance and especially their relation to pelvic adenomas of endometrial type. Archives of Surgery 1921; 3(2): 245–323.
55. SAMPSON JA. Benign and malignant endometrial implants in the peritoneal cavity and their relation to certain ovarian tumors. Surg, Gynec & Obst 1924; 38: 287–311.
56. SAMPSON JA. Endometrial carcinoma of the ovary arising in endometrial tissue in that organ. Archives of Surgery 1924; 10: 1–72.
57. SAMPSON JA. Heterotopic or misplaced endometrial tissue. 1925; 10(5): 649–64.
58. SAMPSON JA. Peritoneal endometriosis due to the menstrual dissemination of endometrial tissue into the peritoneal cavity. Am J Obstet Gynecol 1927: 422–69.
59. SAMPSON JA. Metastatic or embolic endometriosis, due to the menstrual dissemination of endometrial tissue into the venous circulation. The American Journal of Pathology 1927; 3(2): 93–110.
60. SEMM K, PALMER R, RICE AL, BOROW LS, EDITORS. Atlas of gynecologic laparoscopy and hysteroscopy. Philadelphia: Saunders; 1977.
61. SHELTON DC. The Emperor's new clothes. Journal of the Royal Society of Medicine 2010; 103(2): 46–50.
62. SORANI EPHESESII. De arte obstetricia morbisque mulierum quae supersunt. Ex apographo F. R. Dietz. Koenigsberg: Regimontii Prussorum in Commissis apud Graefium et Unzerum; 1838.
63. SORANUS OF EPHEBUS. Soranus' gynecology : translated with an introduction by Owsei Temkin ; with the assistance of Nicholson J. Eastman, Ludwig Edelstein, and Alan F. Guttmacher. Baltimore: Johns Hopkins Press 1956.
64. STEPTOE PC. Laparoscopy in Gynaecology. Edinburgh: E & S Livingstone; 1967: 93 pp.
65. STORY L, KENNEDY S. Etiology of Endometriosis. In: Sutton CJG, Jones K, Adamson GD, eds. The modern management of endometriosis. London; New York: Taylor & Francis; 2006: 17–24.
66. SUTTON C. Initial experience with carbon dioxide laser laparoscopy: Lasers in Medical Science. Laser Med Sci 1986; 1(1): 25–31.
67. SUTTON C. Laser uterine nerve ablation. In: Donnez J, ed. Laser operative laparoscopy and hysteroscopy. Leuven, Belgium: Nauwelaerts Publishing; 1989: 43–52.
68. SUTTON C. Power sources in endoscopic surgery. Current opinion in obstetrics & gynecology 1995; 7(4): 248–56.
69. SUTTON C. Past, present, and future of hysterectomy. *Journal of minimally invasive gynecology* 2010; 17(4): 421–35.
70. SUTTON C, HILL D. Laser laparoscopy in the treatment of endometriosis. A 5-year study. British journal of obstetrics and gynaecology 1990; 97(2): 181–5.
71. SUTTON C, WHITELAW N. Laparoscopic uterine nerve ablation for intractable dysmenorrhea. In: Sutton CJG, Diamond MP, eds. Endoscopic surgery for gynaecologists. London, Philadelphia: W.B. Saunders; 1993: 159–68.
72. SUTTON C, POOLEY AS, JONES KD, DOVER RW, HAINES P. A prospective, randomized, double-blind controlled trial of laparoscopic uterine nerve ablation in the treatment of pelvic pain associated with endometriosis. Gynaecological Endoscopy 2001; 10(4): 217–22.
73. SUTTON CJ. Historical curiosities in the surgical management of myomas. The Journal of the American Association of Gynecologic Laparoscopists 2004; 11(1): 4–7.
74. SUTTON CJ, EWEN SP, WHITELAW N, HAINES P. Prospective, randomized, double-blind, controlled trial of laser laparoscopy in the treatment of pelvic pain associated with minimal, mild, and moderate endometriosis. Fertility and sterility 1994; 62(4): 696–700.
75. SUTTON CJG. RCOG historical lecture 1993: 150 years of hysterectomy; from Charles Clay to laparoscopic hysterectomy. In: Studd JWW, ed. Yearbook of the Royal College of Obstetricians and Gynaecologists. London: RCOG Press; 1994: 29–40.
76. SUTTON CJG. The history of endometriosis. In: Sutton CJG, Jones K, Adamson GD, eds. The modern management of endometriosis. Abingdon, Oxford: Taylor & Francis; 2006: 3–16.
77. SUTTON CJG, NAIR S, EWEN SP, HAINES PA. A comparison between the CO<sub>2</sub> and KTP lasers in the treatment of large ovarian endometriomas. Gynaecological Endoscopy 1993; 2(2): 113–7.
78. TULANDI T, BUGNAH M. Operative laparoscopy: surgical modalities. *Fertility and sterility* 1995; 63(2): 237–45.
79. WHO/EURO. Levels of PCBs, PCDDs and PCDFs in Breast Milk: Results of WHO-coordinated interlaboratory quality control studies and analytical field studies. In: Yrjanhaiki EJ, ed. Environmental Health Series Report No 34. Copenhagen: World Health Organization Regional Office for Europe; 1989.



# 1.3

## Etiology and Pathogenesis

Liselotte Mettler<sup>a</sup>

### 1.3.1 Introduction

Endometriosis was originally described more than 300 years ago. It is a chronic, estrogen-dependent, inflammatory disease with a worldwide prevalence of 10–30% in women of reproductive age. Characterized by the growth of endometrium-like tissue at aberrant sites outside the uterus, it is responsible for symptoms that may include chronic pelvic pain, inflammation, dysmenorrhea, dyspareunia, and subfertility. Symptoms of this kind are known to significantly degrade the quality of life. In Germany, the direct and indirect economic costs of endometriosis are approximately 1.5 billion euros.<sup>12</sup> The costs in the U.S. are significantly greater, estimated at 20 billion dollars.

Despite decades of research, the etiology and pathogenesis of endometriosis are not yet fully understood. This chapter aims to compile current published details on the pathogenesis of endometriosis, with a specific focus on mechanisms behind the vascularization of lesions and the contribution of immune factors. The role of hormones, immune cells, and cytokine signaling is highlighted. We also survey current pharmaceutical options available for pain management in women with this lifelong, potentially treatable disease.



Fig. 1.21 Portrait of Carl von Rokitansky (1860).

<sup>a</sup> | Professor Emerita, MD; Department of Obstetrics and Gynecology, Kiel School of Gynecological Endoscopy, University Hospitals of Schleswig-Holstein, Kiel Campus, Kiel, Germany

**Corresponding author:**

Prof. Dr. med. Dr. h.c. mult. **Liselotte Mettler**  
 Klinik für Gynäkologie und Geburtshilfe  
 Universitätsklinikum Schleswig-Holstein (UKSH)  
 Campus Kiel  
 Arnold-Heller-Strasse 3  
 24105 Kiel, Germany  
 E-mail: endometriose@uksh.de

Endometriosis continues to confront and challenge all clinicians and researchers working in the field, and especially patients suffering from the disease. In 2010 *Linda Giudice* published an evidence-based evaluation of endometriosis, in which she expressed the need for additional randomized controlled studies and clinical research.<sup>21</sup>

### 1.3.2 History

As noted in the previous chapter, *Carl von Rokitansky* (1804–1878) published the first histological description of endometriosis in 1860 (Figs. 1.21, 1.22). Endometriosis has already assumed ‘mythical’ proportions from a scientific and clinical perspective. The disease has been and is provoking scientists and clinicians in its diverse presentations as endometriosis, adenomyosis, endosalpingiosis, endosalpingitis nodosa, endocervicosis, and müllerianosis. This chronic, occult disease was described in the 19<sup>th</sup> century as having a difficult pathologic anatomy. It is hoped that the exploration of its immunologic and genetic etiologies will help to foster new treatments in the 21<sup>st</sup> century.

The most extensive survey on the history of endometriosis is a unique book written by *Ronald E. Batt*, in which he describes the philosophical, poetic, intellectual, and pathohistologic aspects of the disease.<sup>6</sup> He bases the final recognition of endometriosis by Rokitansky on the background of the Goethe University-educated *Alexander von Humboldt*, *Johannes Peter Müller*, and on the history of embryology. Rokitansky eventually emerged as the first full-time anatomic pathologist. The Viennese Medical School gave Rokitansky the opportunity to write a handbook on pathological anatomy in which he described the then-new disease (1860).



Fig. 1.22 First article by *Carl von Rokitansky* on endometriosis, published in the Journal of the Physicians' Society of Vienna, Austria. ‘New growth of uterine glands in sarcomas of the uterus and ovaries,’ 1860.<sup>54</sup>

The developmental steps in understanding endometriosis progressed from the early years of Rokitsansky to *Thomas Cullen* and *John A. Sampson*, who described the disease with reference to philosophical aspects from *Immanuel Kant*.

### 1.3.3 Theories on the Pathogenesis of Endometriosis

Eight different theories have been advanced on the etiology of endometriosis as a complex, multifactorial, benign disease involving hormonal, genetic, immunologic, and environmental components (Table 1.1). Specifically, all expressions of endometriosis, including its deep and superficial forms, can be explained by the following theories:

Theory	Mode of action
Retrograde menstruation	Transport of endometrial cells through the fallopian tubes into the lesser pelvis, allowing implantation of endometrial lesions
Metaplasia	Transformation of peritoneal tissue/cells into endometrial tissue through hormonal and/or immunological factors
Hormones	Proliferation of endometrial lesions in response to estrogens. Resistance to progesterone-mediated control of endometrial proliferation
Oxidative stress and inflammation	Activation of immune cells and cytokines to promote endometrial growth
Immune dysfunction	Hampers the elimination of menstrual debris and promotes the implantation of endometrial lesions
Apoptosis suppression	Supports the survival of endometrial cells and the down-regulation of apoptotic pathways
Genetics	Basis for the increased attachment of endometrial cells and their ability to evade immune clearance
Stem cells	Endometriotic deposits of undifferentiated cells with natural regenerative capacity

**Table 1.1** Theories on the etiology of endometriosis.

### 1.3.4 Retrograde Menstruation

The retrograde menstruation theory (according to *Sampson*) is the oldest principle explaining the etiology of endometriosis. It states that endometriosis results from the reflux of sloughed endometrial cells and debris through the fallopian tubes into the pelvic cavity during menstruation.<sup>57</sup> But retrograde menstruation occurs in 76–90% of women with patent fallopian tubes, and not all of these women develop endometriosis.<sup>59</sup> The greater volume of retrograde menstrual fluid found in the pelvises of endometriosis patients compared with healthy women may increase the risk for implantation of endometriotic lesions.<sup>34</sup> In studies of nonhuman primate models, endometriosis can be induced by inoculating autologous menstrual products simulating retrograde menstruation into the peritoneal cavity of baboons and macaques.<sup>29</sup> With a single, direct inoculation of menstrual endometrial tissue into the pelvic cavity, up to 46% of animals showed development of endometriotic lesions in the pelvic cavity.<sup>15</sup> A full 100% of animals developed peritoneal endometriotic lesions after two consecutive cycles of inoculations of curetted menstrual endometrium. These lesions were found to be histologically and clinically similar to human ectopic endometriotic lesions.<sup>14</sup> Moreover, in a

recent study deep nodular endometriosis was generated by the ectopic implantation of full-thickness endometrium including the basalis layer, underscoring the involvement of the endometrial basalis in the development of ectopic lesions.<sup>17</sup> However, only well-differentiated cells from the superficial functional layer of the endometrium are normally shed with the menstrual flow, while the deep basalis layer remains intact for life. Regeneration of the endometrial functional layer after menstrual shedding is believed to originate from the basal layer.<sup>68</sup> Thus, when this basalis tissue, with the ability to generate an endometrial functional layer, is introduced into the pelvis, the processes that occur in nonhuman primate models may not fully mimic the events of spontaneous retrograde menstruation. Further evidence to support the *Sampson* theory comes from the observation that factors obstructing menstruation, such as congenital anomalies including imperforate hymen and iatrogenic cervical stenosis, increase retrograde menstruation and heighten the risk for developing endometriosis.<sup>10</sup> Increased retrograde menstruation through experimentally induced cervical stenosis has also caused endometriosis in nonhuman primate models.<sup>15</sup> The location of superficial endometriotic lesions in the posterior aspect and left side of the pelvis may be due to gravitational effects on refluxed menstrual products and the anatomic position of the sigmoid colon.<sup>16</sup> However, this theory has been disputed in the past as it cannot explain the occurrence of endometriosis in prepubescent girls, newborns, or males. Neonatal uterine bleeding occurs in the immediate postnatal period in most girls following the withdrawal of (maternal) ovarian hormones, similar to menstrual bleeding, and the retrograde flow of this material has been proposed as the cause of prepubertal endometriosis.<sup>7</sup>

### 1.3.5 Metaplasia

Other theories suggest that endometriosis originates from extrauterine cells that abnormally transdifferentiate or transform into endometrial cells. The coelomic metaplasia theory postulates that endometriosis results from the metaplasia of specialized cells that are present in the mesothelial lining of the visceral and abdominal peritoneum.<sup>23</sup> Hormonal or immunologic factors are thought to stimulate the transformation of normal peritoneal cells and tissue into endometrium-like tissue.<sup>10</sup> The coelomic metaplasia theory may explain the occurrence of endometriosis in prepubertal girls.<sup>19</sup> However, the usual driving force for endometrial growth, estrogen, is not present in prepubertal girls, and therefore this condition may differ from endometriosis in women of reproductive age.

Ectopic endometrial tissue has also been detected in female fetuses, and it has been suggested that endometriosis may result from defective embryogenesis. According to this theory, residual embryonic wolffian or müllerian duct cells persist and develop into endometriotic lesions that are estrogen-responsive.<sup>10</sup> Moreover, recent theories have cited coelomic metaplasia as the origin for the adolescent variant of the severe, progressive form of endometriosis.<sup>8</sup> This theory is imperfect, however, due to endometriotic lesions being found in areas outside the distribution of the müllerian duct. Others have also proposed that endogenous biochemical or



immunologic factors induce resident undifferentiated cells to differentiate into endometrial-like tissue at ectopic sites, resulting in endometriosis.<sup>24</sup> This theory is supported by studies describing the hormone-dependent transformation of peritoneal cells into müllerian-type cells.<sup>5</sup>

### 1.3.6 Hormones

Steroid hormones should play a central role in the etiology of endometriosis, since it is a disease of reproductive-age women and is rare in postmenopausal women not on hormonal therapy.<sup>53</sup> Similar to the eutopic endometrium, the growth of ectopic lesions is thought to be regulated by ovarian steroid hormones. Estrogen is the driving force of endometrial proliferation, and ectopic lesions may have increased responsiveness to estrogen, thereby promoting the development of endometriosis.<sup>5</sup> Environmental toxins such as dioxin have been implicated in the etiology of endometriosis and may mimic estrogen through their interaction with estrogen receptors.<sup>53</sup> Moreover, there may be a higher bioavailability of estradiol in endometriotic tissue due to the local aromatization of circulating androgens to estradiol by endometriotic stromal cells, and the conversion of estradiol to the less potent estrone may be reduced due to a decreased expression of 17 $\beta$ -hydroxysteroid enzymes in ectopic endometriotic tissue.<sup>10</sup> These factors may explain the proliferation-promoting phenotype that has been described in ectopic endometriotic tissue.<sup>5</sup> Progesterone generally counteracts the proliferation-promoting action of estrogen in healthy, eutopic endometrium. Many authors believe that endometriosis is marked by endometrial resistance to progesterone, which plays a pivotal role in its pathogenesis.<sup>2,32</sup> The harnessing of the estrogen-driven mitotic/proliferative action of progesterone on the endometrium during the secretory phase of the cycle does not occur in endometriotic lesions, and sustained proliferative activity is seen in the eutopic endometrium of women with endometriosis during the secretory phase.<sup>9,28</sup> The progesterone resistance may result from a reduced expression of progesterone receptors in endometriotic lesions or from a functional abnormality of existing progesterone receptors.<sup>4</sup>

### 1.3.7 Oxidative Stress and Inflammation

Increased oxidation of lipoproteins has been linked to the pathogenesis of endometriosis, where reactive oxygen species (ROS) cause lipid peroxidation leading to DNA damage in endometrial cells.<sup>48</sup> The presence of water and electrolytes in the increased peritoneal fluid volume of endometriosis patients provides the source of ROS.<sup>70</sup> These patients also have iron overload in their peritoneal cavities from the breakdown of hemoglobin, which in turn causes redox reactions.<sup>36</sup> The release of proinflammatory heme products and the oxidative stress signals generated from the ROS incite an inflammatory response, leading to the recruitment of lymphocytes and to cytokine production by activated macrophages; this in turn induces enzyme oxidation and promotes endothelial growth.<sup>24</sup> The excess production of ROS is also accompanied by a decreased level of antioxidants, which normally eliminate these molecules.<sup>48,49</sup> The resulting accumulation of ROS may contribute to the propagation and maintenance of endometriosis and associated symptoms.

### 1.3.8 Immune Dysfunction

The observation that autoimmune diseases are more common in women with endometriosis suggests that the pathogenesis of endometriosis may involve an alteration of immune surveillance in these patients.<sup>63</sup> Women with endometriosis have higher levels of activated macrophages, decreased cellular immunity, and repression of NK cell function.<sup>51,62</sup> The regurgitation of endometrial cells into the peritoneum triggers an inflammatory response, leading to the local activation of macrophages and leukocytes.<sup>37</sup> This inflammatory response may alter normal immune surveillance, preventing the elimination of menstrual debris and promoting the implantation and growth of endometrial cells at ectopic sites.<sup>11</sup>

With our studies on the macrophage growth-factor (M-CSF) hypothesis in females with endometriosis, we elucidated the interaction between the immune system and an abnormal proliferation of epithelial cells in dystopic endometrium.<sup>26,45,71</sup> The concentration of M-CSF in serum and fluid from the cul-de-sac was measured in enzyme-linked immunosorbent assays (ELISA). Using an in-vitro reverse transcription polymerase chain reaction (in-vitro RT-PCR), we were able to detect c-fms mRNA encoding the M-CSF receptor in heterogenic endometrial biopsies.<sup>46</sup>

It has also been theorized that the peritoneal immune clearance occurring in nonhuman primates has been lost in humans during the evolutionary process, and that this may contribute to the persistence of menstrual debris in the pelvic cavity and the subsequent development of endometriosis.<sup>17</sup> Survival and resistance to immune-cell-mediated lysis of endometriotic cells is ensured by masking these ectopic cells to the immune system, one mechanism being the ability of ectopic endometrial cells to modulate the expression of HLA class I molecules.<sup>61,62</sup> Both immune and endometrial cells secrete cytokines and growth factors, which induce cell proliferation and angiogenesis that promote the implantation and growth of ectopic lesions.<sup>67</sup> Possibly as a consequence, women with endometriosis have a higher expression of cytokines and vascular endothelial growth factors in their peritoneal fluid, which promotes the proliferation of endometrial cells and angiogenesis.<sup>38,44</sup>

### 1.3.9 Suppression of Apoptosis and Alteration of Endometrial Cell Fate

Alteration of the endometrial cell fate to favor an antiapoptotic and proliferative phenotype is paramount for the survival of endometrial cells in the peritoneal cavity, their ability to form ectopic deposits, and for the maintenance of established lesions.<sup>27</sup> By examining matched eutopic endometrium and ectopic lesions from women with endometriosis and in baboons with induced disease, we have recently shown that telomerase enzyme may play a central role in this altered endometrial cell phenotype.<sup>27,28</sup>

In our study of apoptotic activity using the terminal deoxynucleotidyl transferase dUTP nick end labeling (TUNEL) method and proliferative activity measurement with Ki-67 antigens and monoclonal antibody Ki-S5, we found that 13–47% of women with endometriosis had positive apoptotic activity with a proliferative activity of 12–25% of epithelial cells.<sup>35,55</sup>

This led us to conclude that the persistence of dystopic endometrial particles requires proliferative epithelial cells from the middle to lower endometrial layers. Superficial dystopic epithelial cells can easily be eliminated by apoptotic activation.<sup>56</sup>

There is considerable evidence indicating an upregulation of antiapoptotic and pro-survival genes and a reciprocal downregulation of the genes regulating the apoptosis pathway in ectopic endometrial cells.<sup>18</sup> In addition to decreased scavenger activity, the endometrium in patients with endometriosis expresses higher levels of antiapoptotic factors.<sup>64</sup> The inhibition of apoptosis in endometrial cells may also be mediated by the transcriptional activation of genes that normally promote inflammation, angiogenesis, and cell proliferation.<sup>22</sup>

### 1.3.10 Genetics

A genetic basis for the development of endometriosis is suggested by reports of familial aggregation, an increased risk in those with an affected first-degree relative,<sup>60</sup> and the concordance of endometriosis in twins.<sup>25</sup> A great many studies have cited genetic polymorphisms as a contributory factor to the development of endometriosis. Endometriosis has a polygenic mode of inheritance that is likely to involve multiple loci, and some chromosomal regions were reported to be associated with the corresponding endometriosis phenotype.<sup>3</sup> Inherited as well as acquired genetic factors may predispose women to the attachment of ectopic endometrial cells to the peritoneal epithelium and the evasion of those lesions from immune clearance.<sup>16</sup> Differences in genes and protein expression between patients with and without endometriosis have been reported.<sup>43</sup> Genes that have been implicated in the pathogenesis of endometriosis include those encoding for detoxification enzymes, polymorphism in estrogen receptors, and genes involved in the innate immune system.<sup>5</sup> Genetic predisposition can increase the frequency of cellular damage. Genetic mutations that cause cell damage can promote the progression of endometriosis, since women with endometriosis show altered endometrial cell behavior that favors extrauterine adhesion and growth.<sup>33</sup> Several authors in recent decades have employed gene arrays to identify endometriosis-related genes. Using laser capture microdissection as well as high-throughput and high-resolution comparative genomic hybridization (CGH) arrays, researchers have discovered significant genomic alterations in both eutopic and ectopic endometria of women with endometriosis.<sup>1,31</sup> Recent genome-wide association studies have also identified new loci for endometriosis.<sup>3</sup> Collectively, these data suggest that different types of endometriosis may be associated with changes in different gene clusters that regulate specific functional aberrations in cells.

### 1.3.11 Stem Cells

The monthly regeneration of the endometrium after menstrual shedding and reepithelialization of the endometrium after parturition or surgical curettage support the existence of a stem cell pool.<sup>66</sup> Since the endometrial basalis is not sloughed with the monthly menstrual shedding of the functionalis, the stem cells are believed to reside in the basalis layer.<sup>52</sup> Clonogenic cells, which are thought to represent the stem cell

population in the human endometrium, have recently been identified and proposed to be involved in the formation of ectopic endometrial lesions.<sup>13</sup>

Stem cells are undifferentiated cells characterized by an ability to self-renew and differentiate into one or more types of specialized cells.<sup>30</sup> Differentiation is defined as a change in cell phenotype secondary to an alteration in its gene expression, enabling the cell to carry out a specific function.<sup>19</sup> Endometrial self-generation may occur through stem cells in specific niches of the endometrium.<sup>50</sup> The undifferentiated endometrial stem cells may be less responsive to ovarian steroids than their terminally differentiated progeny due to a lack of hormone receptor expression.<sup>20</sup> In addition to the resident endometrial stem cells, the incorporation of circulating bone-marrow-derived stem cells may contribute to the cyclic regeneration of the endometrium.<sup>65</sup>

Stem cell involvement in the formation of endometriotic deposits could result from an abnormal translocation of normal endometrial basalis via retrograde menstruation.<sup>42</sup> *Brosens et al.* postulated that uterine bleeding in neonatal girls has a high content of endometrial progenitor cells.<sup>8</sup> Some of these cells may deposit and survive in the peritoneal cavity after retrograde flow and may reactivate during adolescence in response to ovarian hormones.<sup>8</sup> However, no current data are available on the amount of endometrial stem cells or progenitor cells present in the neonatal period compared with adult endometrium. Furthermore, since even the ageing postmenopausal endometrium appears to have enough progenitor cells to generate a normal, competent functionalis with essential hormonal stimulation, it seems unlikely that there are significant differences in progenitor activity between the premenopausal and postmenopausal endometrium. *Leyendecker et al.* proposed that women with endometriosis abnormally shed endometrial basalis tissue, which can initiate endometriotic deposits after retrograde menstruation.<sup>39</sup> The observation of endometriosis induction in the baboon model, where stem-cell-rich endometrial basalis implanted in the pelvic cavity produced 100% induction of endometriosis in all animals, may further support Leyendecker's theory. If the basalis contains the stem/progenitor cells, they are more likely to survive and initiate endometriotic deposits in the pelvis than differentiated endometrial cells from the functionalis. With their natural ability to regenerate, these stem cells may give rise to new endometriotic deposits. The fact that women with endometriosis may shed significantly more of the stem-cell-rich basalis layer than healthy women,<sup>39</sup> plus the similarity noted between ectopic lesions and the basalis layer,<sup>68</sup> may support the possibility of retrograde menstruation providing an access route for endometrial stem cells to extrauterine structures.<sup>13,39</sup> Alternatively, these stem cells may be transported to ectopic sites via lymphatic or vascular pathways.<sup>41</sup> The fact that some endometrial stem cells are of bone-marrow origin further supports the hematogenous dissemination theory of these cells.<sup>40</sup> Recent studies further suggest that mobile stem cells may be involved in endometriosis progression, based on the finding that cells derived from ectopic lesions in induced endometriosis migrated to eutopic endometrium.<sup>40</sup> However, since stem cells are normally expected to differentiate into mature cells in concordance with their environmental niche,

the presumably multipotent endometrial stem cells in the peritoneal cavity should differentiate into peritoneal-type cells. It is possible that the deposition of endometrial tissue fragments containing both endometrial stem cells and their niche cells in the peritoneal cavity promote the regeneration of endometrium-like tissue, due to the signal received by the stem cells from the surrounding endometrial niche cells. On the other hand, the relocation of an aberrant or committed stem cell from the endometrium to an ectopic site may also generate endometrium-like lesions. Endometrial tissue produces several chemokines and angiogenic cytokines, which presumably induce neovascularization at the ectopic sites to ensure the establishment of the lesions.<sup>58</sup>

A further possibility of stem cell involvement in endometriosis is the transdifferentiation of peritoneal, hematopoietic, or ovarian stem cells into endometrium-like tissue. The peritoneal cavity communicates directly with the uterine cavity, enabling a free flow of cytokine- and chemokine-rich fluid between the two environments. This direct connection may regulate the endometrium-like differentiation of the resident stem cell population in the peritoneal cavity. While this theory is plausible, the reasons for such specific differentiation of peritoneal stem cells into endometrium-like tissue in no more than 10% of the female population remain unexplained.

### 1.3.12 Discussion and Summary

No theory on the pathogenesis of endometriosis covers all manifestations of this disease, although the retrograde menstruation theory is widely accepted and does explain the wide dissemination of endometrial cells. Defective immune clearance and inflammation are systems of interest in explaining the establishment of endometriotic implants. Inciting factors and genetic susceptibilities shed further light on the development of endometriosis.

The lesions of endometriosis are morphologically diverse (vesicular type, red lesions, scar type, white lesions, 'old bloodshed' type, black powder-burn lesions) and cannot always be diagnosed, even histologically.<sup>47</sup> The progression of red lesions to a fibrotic stage with white plugs occurs predominantly in older women, while a cyclic inflammatory response is typical of peritoneal endometriotic lesions in younger women. Endometriosis has a wide range of appearances, and only an orchestrated etiology can explain it.<sup>69</sup> Our present understanding of endometriosis allows for preventive strategies and novel diagnostic modalities besides classic surgical resection and holds promise for better treatment options in the future.

### 1.3.13 References

1. AFSHAR Y, HASTINGS J, ROQUEIRO D, JEONG JW, GIUDICE LC, FAZLEABAS AT. Changes in eutopic endometrial gene expression during the progression of experimental endometriosis in the baboon, *Papio anubis*. *Biol Reprod* 2013;88(2):44. doi:10.1095/biolreprod.112.104497.
2. AGHAJANOVA L, TATSUMI K, HORCAJADAS JA, AM ZAMAH, ESTEBAN FJ, HERNDON CN et al. Unique transcriptome, pathways, and networks in the human endometrial fibroblast response to progesterone in endometriosis. *Biol Reprod* 2011;84(4):801–15. doi:10.1095/biolreprod.110.086181.
3. ALBERTSEN HM, CHETTIER R, FARRINGTON P, WARD K. Genome-wide association study link novel loci to endometriosis. *PLoS One* 2013;8(3):e58257. doi:10.1371/journal.pone.0058257.
4. ATTIA GR, ZEITOUN K, EDWARDS D, JOHNS A, CARR BR, BULUN SE. Progesterone receptor isoform A but not B is expressed in endometriosis. *J Clin Endocrinol Metab* 2000;85(8):2897–902. doi:10.1210/jcem.85.8.6739.
5. AUGOULEA A, ALEXANDROU A, CREATSA M, VRACHNIS N, LAMBRINOUDAKI I. Pathogenesis of endometriosis: the role of genetics, inflammation and oxidative stress. *Arch Gynecol Obstet* 2012;286(1):99–103. doi:10.1007/s00404-012-2357-8.
6. BATT RE. *A History of Endometriosis*. London: Springer London; 2011. (ISBN No. 978-0-85729-584-2).
7. BROSENS I, BENAGIANO G. Is neonatal uterine bleeding involved in the pathogenesis of endometriosis as a source of stem cells? *Fertil Steril* 2013;100(3):622–3. doi:10.1016/j.fertnstert.2013.04.046.
8. BROSENS I, GORDTS S, BENAGIANO G. Endometriosis in adolescents is a hidden, progressive and severe disease that deserves attention, not just compassion. *Hum Reprod* 2013;28(8):2026–31. doi:10.1093/humrep/det243.
9. BULUN SE, CHENG YH, YIN P, IMIR G, UTSUNOMIYA H, ATTAR E et al. Progesterone resistance in endometriosis: link to failure to metabolize estradiol. *Mol Cell Endocrinol* 2006;248(1–2):94–103. doi:10.1016/j.mce.2005.11.041.
10. BURNEY RO, GIUDICE LC. Pathogenesis and pathophysiology of endometriosis. *Fertil Steril* 2012;98(3):511–9. doi:10.1016/j.fertnstert.2012.06.029.
11. CHRISTODOULAKOS G, AUGOULEA A, LAMBRINOUDAKI I, SIOULAS V, CREATSAS G. Pathogenesis of endometriosis: the role of defective 'immunosurveillance'. *Eur J Contracept Reprod Health Care* 2007;12(3):194–202. doi:10.1080/13625180701387266.
12. CRAMER DW, MISSMER SA. The epidemiology of endometriosis. *Ann N Y Acad Sci* 2002;955:11–22; discussion 34–6, 396–406.
13. DEANE JA, GUALANO RC, GARGETT CE. Regenerating endometrium from stem/progenitor cells: is it abnormal in endometriosis, Asherman's syndrome and infertility? *Curr Opin Obstet Gynecol* 2013;25(3):193–200. doi:10.1097/GCO.0b013e32836024e7.
14. DEHOUX JP, DEFRERE S, SQUIFFLET J, DONNEZ O, POLET R, MESTDAGT M et al. Is the baboon model appropriate for endometriosis studies? *Fertil Steril* 2011;96(3):728–733.e3. doi:10.1016/j.fertnstert.2011.06.037.
15. D'HOOGHE TM, BAMBRA CS, SULEMAN MA, DUNSELMAN GA, EVERS HL, KONINCKX PR. Development of a model of retrograde menstruation in baboons (*Papio anubis*). *Fertil Steril* 1994;62(3):635–8.
16. DMOWSKI WP, RADWANSKA E. Current concepts on pathology, histogenesis and etiology of endometriosis. *Acta Obstet Gynecol Scand Suppl* 1984;123:29–33.
17. DONNEZ O, VAN LANGENDONCKT A, DEFRERE S, COLETTE S, VAN KERK O, DEHOUX JP et al. Induction of endometriotic nodules in an experimental baboon model mimicking human deep nodular lesions. *Fertil Steril* 2013;99(3):783–789.e3. doi:10.1016/j.fertnstert.2012.10.032.
18. FERRYMAN SR, ROLLASON TP. Pathology of the uterine body. *Curr Opin Obstet Gynecol* 1994;6(4):344–50.
19. FIGUEIRA PG, ABRAO MS, KRIKUN G, TAYLOR HS. Stem cells in endometrium and their role in the pathogenesis of endometriosis. *Ann N Y Acad Sci* 2011;1221:10–7. doi:10.1111/j.1749-6632.2011.05969.x.



20. GARGETT CE, CHAN RW, SCHWAB KE. Hormone and growth factor signaling in endometrial renewal: role of stem/progenitor cells. *Mol Cell Endocrinol* 2008;288(1–2):22–9. doi:10.1016/j.mce.2008.02.026.
21. GIUDICE LC. Clinical practice. Endometriosis. *N Engl J Med* 2010;362(25):2389–98. doi:10.1056/NEJMcp1000274.
22. GONZALEZ-RAMOS R, VAN LANGENDONCKT A, DEFRERE S, LOUSSE JC, COLETTE S, DEVOTO L et al. Involvement of the nuclear factor-kappaB pathway in the pathogenesis of endometriosis. *Fertil Steril* 2010;94(6):1985–94. doi:10.1016/j.fertnstert.2010.01.013.
23. GRUENWALD P. Origin of endometriosis from the mesenchyme of the celomic walls. *American Journal of Obstetrics and Gynecology* 1942;44(3):470–4.
24. GUPTA S, AGARWAL A, KRAJCIR N, ALVAREZ JG. Role of oxidative stress in endometriosis. *Reprod Biomed Online* 2006;13(1):126–34.
25. HADFIELD RM, MARDON HJ, BARLOW DH, KENNEDY SH. Endometriosis in monozygotic twins. *Fertil Steril* 1997;68(5):941–2.
26. HANEY AF, MUSCATO JJ, WEINBERG JB. Peritoneal fluid cell populations in infertility patients. *Fertil Steril* 1981;35(6):696–8.
27. HAPANGAMA DK, TURNER MA, DRURY J, HEATHCOTE L, AFSHAR Y, MAVROGIANIS PA et al. Aberrant expression of regulators of cell-fate found in eutopic endometrium is found in matched ectopic endometrium among women and in a baboon model of endometriosis. *Hum Reprod* 2010;25(11):2840–50. doi:10.1093/humrep/deq248.
28. HAPANGAMA DK, TURNER MA, DRURY JA, QUENBY S, HART A, MADDICK M et al. Sustained replication in endometrium of women with endometriosis occurs without evoking a DNA damage response. *Hum Reprod* 2009;24(3):687–96. doi:10.1093/humrep/den416.
29. HARIRCHIAN P, GASHAW I, LIPSKIND ST, BRAUNDMEIER AG, HASTINGS JM, OLSON et al. Lesion kinetics in a non-human primate model of endometriosis. *Hum Reprod* 2012;27(8):2341–51. doi:10.1093/humrep/des196.
30. KATO K. Stem cells in human normal endometrium and endometrial cancer cells: characterization of side population cells. *Kaohsiung J Med Sci* 2012;28(2):63–71. doi:10.1016/j.kjms.2011.06.028.
31. KHAN MA, SENGUPTA J, MITTAL S, GHOSH D. Genome-wide expressions in autologous eutopic and ectopic endometrium of fertile women with endometriosis. *Reprod Biol Endocrinol* 2012;10:84. doi:10.1186/1477-7827-10-84.
32. KIM JJ, KURITA T, BULUN SE. Progesterone action in endometrial cancer, endometriosis, uterine fibroids, and breast cancer. *Endocr Rev* 2013;34(1):130–62. doi:10.1210/er.2012-1043.
33. KONINCKX PR, BARLOW D, KENNEDY S. Implantation versus infiltration: the Sampson versus the endometriotic disease theory. *Gynecol Obstet Invest* 1999;47 Suppl 1:3–9; discussion 9–10.
34. KONINCKX PR, KENNEDY SH, BARLOW DH. Endometriotic disease: the role of peritoneal fluid. *Hum Reprod Update* 1998;4(5):741–51.
35. KREIPE H, WACKER HH, HEIDEBRECHT HJ, HAAS K, HAUBERG M, TIEMANN M et al. Determination of the growth fraction in non-Hodgkin's lymphomas by monoclonal antibody Ki-S5 directed against a formalin-resistant epitope of the Ki-67 antigen. *Am J Pathol* 1993;142(6):1689–94.
36. KUMAR S, BANDYOPADHYAY U. Free heme toxicity and its detoxification systems in human. *Toxicol Lett* 2005;157(3):175–88. doi:10.1016/j.toxlet.2005.03.004.
37. KYAMA CM, MIHALYI A, SIMSA P, FALCONER H, FULOP V, MWENDA JM et al. Role of cytokines in the endometrial-peritoneal cross-talk and development of endometriosis. *Front Biosci (Elite Ed)* 2009;1:444–54.
38. LASCHKE MW, GIEBELS C, MENGER MD. Vasculogenesis: a new piece of the endometriosis puzzle. *Hum Reprod Update* 2011;17(5):628–36. doi:10.1093/humupd/dmr023.
39. LEYENDECKER G, KUNZ G, HERBERTZ M, BEIL D, HUPPERT P, MALL G et al. Uterine peristaltic activity and the development of endometriosis. *Ann N Y Acad Sci* 2004;1034:338–55. doi:10.1196/annals.1335.036.
40. MARUYAMA T, MASUDA H, ONO M, KAJITANI T, YOSHIMURA Y. Human uterine stem/progenitor cells: their possible role in uterine physiology and pathology. *Reproduction* 2010;140(1):11–22. doi:10.1530/REP-09-0438.
41. MARUYAMA T, YOSHIMURA Y. Stem cell theory for the pathogenesis of endometriosis. *Front Biosci (Elite Ed)* 2012;4:2854–63.
42. MASUDA H, MATSUZAKI Y, HIRATSU E, ONO M, NAGASHIMA T, KAJITANI T et al. Stem cell-like properties of the endometrial side population: implication in endometrial regeneration. *PLoS One* 2010;5(4):e10387. doi:10.1371/journal.pone.0010387.
43. MAY KE, VILLAR J, KIRTLEY S, KENNEDY SH, BECKER CM. Endometrial alterations in endometriosis: a systematic review of putative biomarkers. *Hum Reprod Update* 2011;17(5):637–53. doi:10.1093/humupd/dmr013.
44. MCLAREN J, PRENTICE A, CHARNOCK-JONES DS, SMITH SK. Vascular endothelial growth factor (VEGF) concentrations are elevated in peritoneal fluid of women with endometriosis. *Hum Reprod* 1996;11(1):220–3.
45. METTLER L. Pathogenesis, diagnosis and treatment of genital endometriosis. *Acta Obstet Gynecol Scand Suppl* 1989;150:31–7.
46. METTLER L, SALMASSI A, HERRMANN B. Makrophagen-Wachstumsfaktor (M-CSF) – Hypothese zur Ätiologie der Endometriose. In: Mettler L, editor. *Endometriose 2000*. Frankfurt: PMI-Verlag AG; 2000. p. 153–72.
47. METTLER L, SCHOLLMEYER T, LEHMANN-WILLENBROCK E, SCHUPPLER U, SCHMUTZLER A, SHUKLA D et al. Accuracy of laparoscopic diagnosis of endometriosis. *JLSLS* 2003;7(1):15–8.
48. MURPHY AA, PALINSKI W, RANKIN S, MORALES AJ, PARTHASARATHY S. Evidence for oxidatively modified lipid-protein complexes in endometrium and endometriosis. *Fertil Steril* 1998;69(6):1092–4.
49. MURPHY AA, SANTANAM N, MORALES AJ, PARTHASARATHY S. Lysophosphatidyl choline, a chemotactic factor for monocytes/T-lymphocytes is elevated in endometriosis. *J Clin Endocrinol Metab* 1998;83(6):2110–3. doi:10.1210/jcem.83.6.4823.
50. OLIVEIRA FR, DELA CC, DEL PHL, VILAMIL QT, REIS FM, CAMARGOS AF. Stem cells: are they the answer to the puzzling etiology of endometriosis? *Histol Histopathol* 2012;27(1):23–9.
51. OSUGA Y, KOGA K, HIROTA Y, HIRATA T, YOSHINO O, TAKETANI Y. Lymphocytes in endometriosis. *Am J Reprod Immunol* 2011;65(1):1–10. doi:10.1111/j.1600-0897.2010.00887.x.
52. PADYKULA HA. Regeneration in the primate uterus: the role of stem cells. *Ann N Y Acad Sci* 1991;622:47–56.
53. PARENTE BARBOSA C, BENTES DE SOUZA AM, BIANCO B, CHRISTOFOLINI DM. The effect of hormones on endometriosis development. *Minerva Ginecol* 2011;63(4):375–86.



54. ROKITANKSY C VON. Uterusdrüsen-Neubildungen in Uterus und Ovarial-Sarcomen. *Zeitschrift der kaiserlich königlichen Aerzte zu Wien* 1860;16(37):577–81.
55. RUDOLPH P, LAPPE T, KREIPE H, PARWARESCH MR, SCHMIDT D. Determination of proliferation activity of prostate cancers by means of nuclear proliferation-associated formalin resistant Ki-S5 antigens. *Verh Dtsch Ges Pathol* 1993;77:98–102.
56. SALMASSI A, HAUBERG M, KOCH K. Apoptose-Resistenz bei Endometriose. In: Mettler L, editor. *Endometriose 2000*. Frankfurt: PMI-Verlag AG; 2000. p. 144–52.
57. SAMPSON JA. Heterotopic or misplaced endometrial tissue. *American Journal of Obstetrics and Gynecology* 1925;10(5): 649–64.
58. SANTAMARIA X, MASSASA EE, TAYLOR HS. Migration of cells from experimental endometriosis to the uterine endometrium. *Endocrinology* 2012;153(11):5566–74. doi:10.1210/en.2012-1202.
59. SASSON IE, TAYLOR HS. Stem cells and the pathogenesis of endometriosis. *Ann N Y Acad Sci* 2008;1127:106–15. doi:10.1196/annals.1434.014.
60. SELI E, BERKKANOGLU M, ARICI A. Pathogenesis of endometriosis. *Obstet Gynecol Clin North Am* 2003;30(1):41–61.
61. SEMINO C, SEMINO A, PIETRA G, MINGARI MC, BAROCCI S, VENTURINI PL et al. Role of major histocompatibility complex class I expression and natural killer-like T cells in the genetic control of endometriosis. *Fertil Steril* 1995;64(5):909–16.
62. SIKORA J, MIELCZAREK-PALACZ A, KONDERA-ANASZ Z. Role of natural killer cell activity in the pathogenesis of endometriosis. *Curr Med Chem* 2011;18(2):200–8.
63. SINAII N, CLEARY SD, BALLWEG ML, NIEMAN LK, STRATTON P. High rates of autoimmune and endocrine disorders, fibromyalgia, chronic fatigue syndrome and atopic diseases among women with endometriosis: a survey analysis. *Hum Reprod* 2002;17(10):2715–24.
64. TANIGUCHI F, KAPONIS A, IZAWA M, KIYAMA T, DEURA I, ITO M et al. Apoptosis and endometriosis. *Front Biosci (Elite Ed)* 2011;3:648–62.
65. TAYLOR HS. Endometrial cells derived from donor stem cells in bone marrow transplant recipients. *JAMA* 2004;292(1):81–5. doi:10.1001/jama.292.1.81.
66. TSUJI S, YOSHIMOTO M, TAKAHASHI K, NODA Y, NAKAHATA T, HEIKE T. Side population cells contribute to the genesis of human endometrium. *Fertil Steril* 2008;90(4 Suppl):1528–37. doi:10.1016/j.fertnstert.2007.08.005.
67. ULUKUS M, ARICI A. Immunology of endometriosis. *Minerva Ginecol* 2005;57(3):237–48.
68. VALENTIJN AJ, PALIAL K, AL-LAMEE H, TEMPEST N, DRURY J, ZGLINICKI T VON et al. SSEA-1 isolates human endometrial basal glandular epithelial cells: phenotypic and functional characterization and implications in the pathogenesis of endometriosis. *Hum Reprod* 2013;28(10):2695–708. doi:10.1093/humrep/det285.
69. VERCELLINI P, VIGANO P, SOMIGLIANA E, FEDELE L. Endometriosis: pathogenesis and treatment. *Nat Rev Endocrinol* 2014;10(5):261–75. doi:10.1038/nrendo.2013.255.
70. WANG Y, SHARMA RK, FALCONE T, GOLDBERG J, AGARWAL A. Importance of reactive oxygen species in the peritoneal fluid of women with endometriosis or idiopathic infertility. *Fertil Steril* 1997;68(5):826–30.
71. WEINBERG JB, HANEY AF, XU FJ, RAMAKRISHNAN S. Peritoneal fluid and plasma levels of human macrophage colony-stimulating factor in relation to peritoneal fluid macrophage content. *Blood* 1991;78(2):513–6.

## 1.4

## Pathology of Endometriosis

Dietmar Schmidt<sup>a</sup>**1.4.1 Introduction**

Endometriosis is an extremely common condition, especially in women of reproductive age. Even though the clinical diagnosis is usually confirmed by histological examination, only a few representative biopsies are usually taken. Given the presence of endometriosis in the tissue specimen, diagnosis can be established in a straightforward way in the majority of cases,<sup>6</sup> but pitfalls may occur, and pathologists should be aware of these potential diagnostic problems.<sup>13</sup>

In the following, the most significant morphological features of endometriosis are described including those which do not demonstrate endometriosis itself, but may be useful in the diagnosis of the disease.

**1.4.1.1 Definition**

Endometriosis is defined as the presence of endometrial tissue consisting of glands and stroma outside the endometrium and myometrium.

**1.4.2 Macroscopic Findings**

Endometriosis may manifest with superficial 'powder burn' or 'gunshot' lesions on the ovaries, serosal surfaces and peritoneum. The lesions may present as punctate, red, blue, brown or white spots, patches or nodules. They often appear as nodules or small cysts containing old hemorrhage surrounded by a variable extent of fibrosis. Atypical or 'subtle' lesions are also common, including red implants (petechial, vesicular, polypoid, hemorrhagic, red flame-like) and serous or clear vesicles.

Endometriotic cysts (endometriomas) most often involve the ovaries. They usually have a fibrotic wall with a smooth or shaggy brown to yellow lining. Typically, they show a semi-fluid or inspissated chocolate-colored content. Such cysts are often densely adherent to the peritoneum of the ovarian fossa, and the surrounding fibrosis may involve the tubes and bowel. Mural nodules or intraluminal polypoid projections may be seen. They must be sampled in order to exclude the presence of a neoplasm originating in the cyst which is found to develop in up to 3%.

Deeply infiltrating endometriotic nodules may extend > 5 mm beneath the peritoneum and may involve the uterosacral ligaments, vagina, bowel, bladder, or ureter.

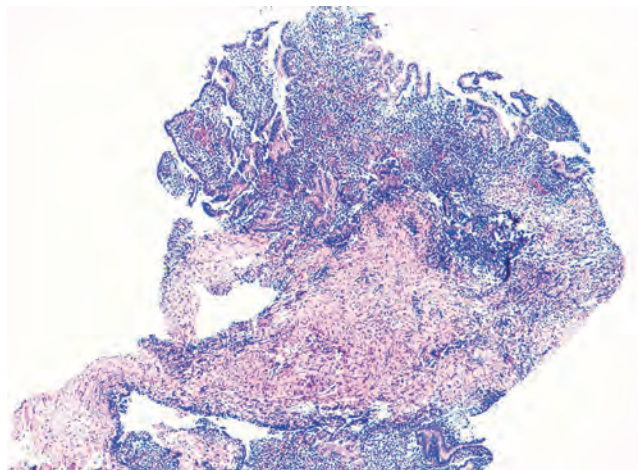
Polypoid endometriosis is characterized by polypoid, often multiple, mucosal or serosal masses that may mimick a neoplasm. Typical endometriosis is often present in the same site or elsewhere.

**1.4.3 Microscopic Findings****1.4.3.1 Typical Findings**

In most cases of endometriosis, both endometriotic epithelium and stroma are present (Fig. 1.23). However, a diagnosis of endometriosis often can be made despite the fact that only one of the two components is identified. The endometriotic foci can be hormonally responsive, but this depends on various factors including the amount of stroma surrounding the glands, the degree of vascularity, and the degree of fibrosis.

In most endometriotic foci, the glands are either inactive or slightly proliferative, only rarely secretory. They usually do not reflect the histologic appearances expected at the appropriate stages of the menstrual cycle, and commonly lack cyclic changes. Occasionally, they appear atrophic and are lined by a single layer of cuboidal or attenuated epithelial cells. Metaplastic changes are quite common, especially in cystic ovarian endometriosis including squamous, ciliated, mucinous (Fig. 1.24), hobnail-like and clear cell metaplasia (Fig. 1.25).

The stromal component usually resembles typical endometrial stroma including a network of arterioles. Delicate reticulin fibrils are present between the stromal cells. Smooth muscle cells can be seen to be associated with these cells. Incidentally, there is only a small cuff of stromal component around endometriotic glands or cysts. In other cases, the stromal cells may assume a spindle-shaped and fibroblast-like appearance. Not infrequently, identification of the stromal cells can be



**Fig. 1.23** Endometriosis of the infundibulo-pelvic ligament, consisting of glandular structures surrounded by stromal cells.

<sup>a</sup> | Professor, MD, MD h.c.; Institute of Pathology, Viersen, Germany

**Corresponding author:**

Prof. Dr. med. Dr. h. c. **Dietmar Schmidt**

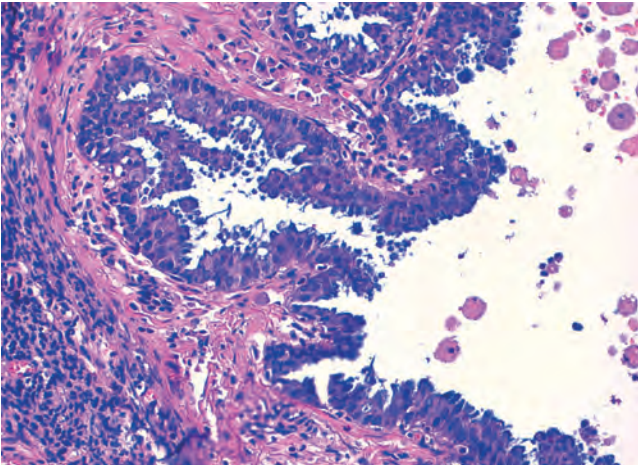
Institut für Pathologie Viersen

Gereonstr.14a

41747 Viersen, Germany

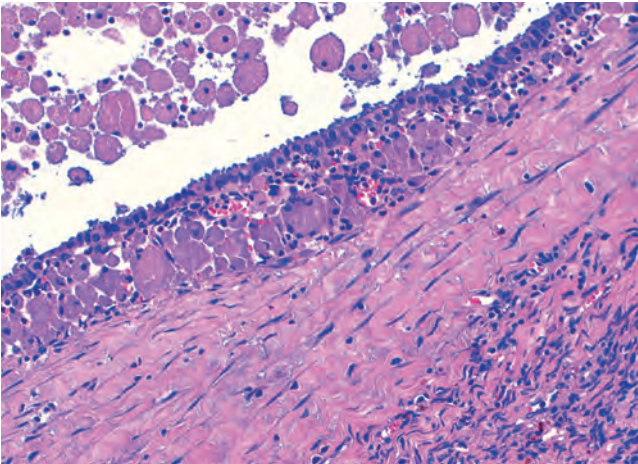
E-mail: dischmi57@gmail.com



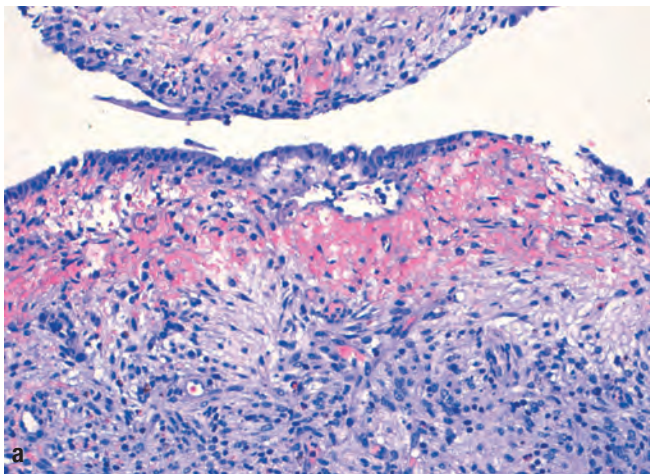


**Fig. 1.24** Epithelial cells with mucinous metaplasia (intense blue staining of mucus).

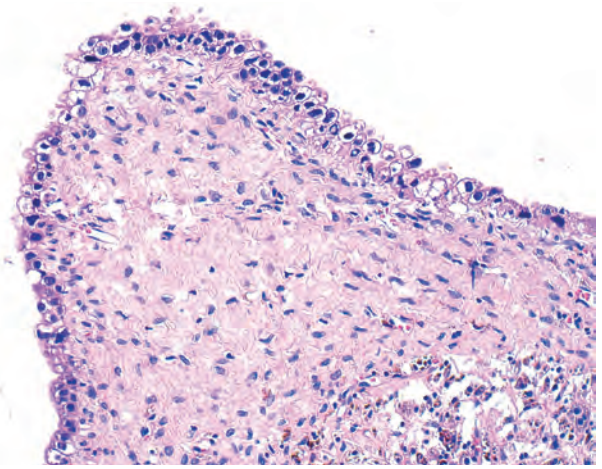
compromised by the presence of varying numbers of histiocytic cells and extravasated erythrocytes. Menstrual hemorrhage is common and may even serve as a clue to the diagnosis of endometriosis. The histiocytes typically contain lipid and two types of brown granular pigment (Fig. 1.26), ceroid (lipofuscin, hemofuscin) and hemosiderin (Fig. 1.27).



**Fig. 1.26** Pigmented histiocytes (containing ceroid) beneath the epithelial cells in an endometriotic cyst.

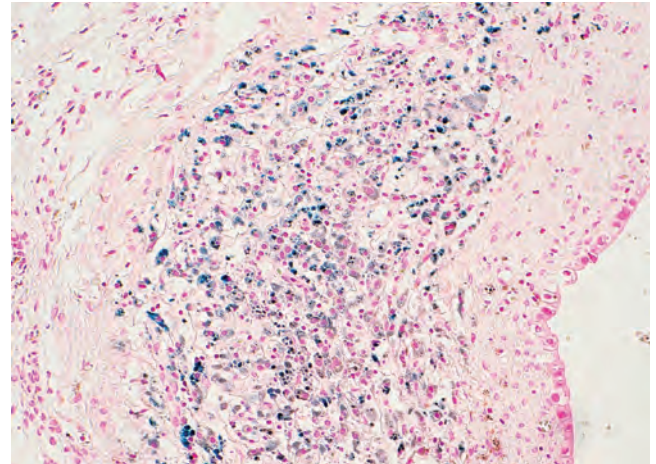


**Fig. 1.28a, b** Endometriotic cyst lined by cuboidal cells (a). Stromal cells beneath this cell layer stain positively for CD10 (b), whereas spindle cells in the adjacent ovarian cortex are CD10-negative.

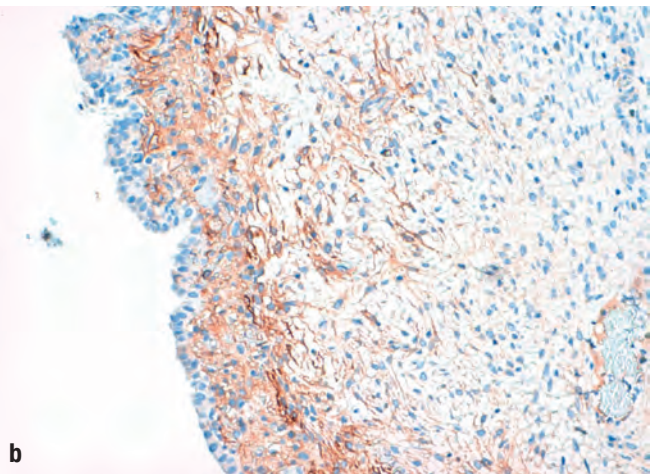


**Fig. 1.25** Endometriotic cyst with clear cell metaplasia of the epithelial lining cells.

In immunohistochemistry, the stromal cells are CD10-positive (Figs. 1.28a,b). Staining for the endometrial stromal antigen CD10 has been shown to facilitate identification when the stromal component is sparse or obscured by histiocytes. This method is also helpful in the diagnosis of cases, which lack a distinct glandular component and only consist of a stromal component.



**Fig. 1.27** Histiocytes with hemosiderin in the cytoplasm (blue staining with Prussian blue dye).

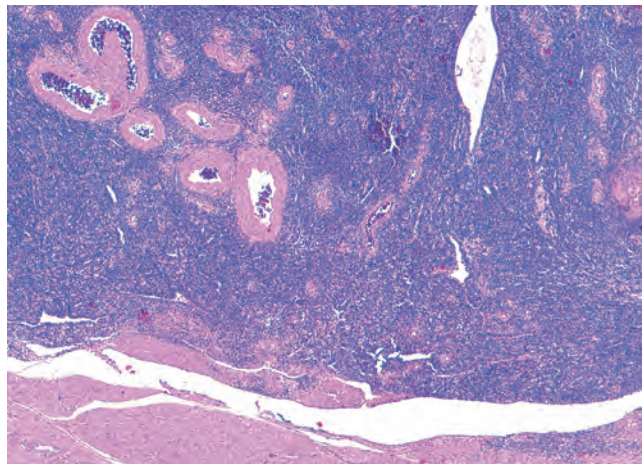




Myxoid change in the stromal component may mimic metastatic mucinous adenocarcinoma or pseudomyxoma peritonei. However, in a nutshell, the presence of typical endometrial glands and stroma is a histological finding that facilitates the diagnosis.

#### ■ *Stromal Endometriosis*

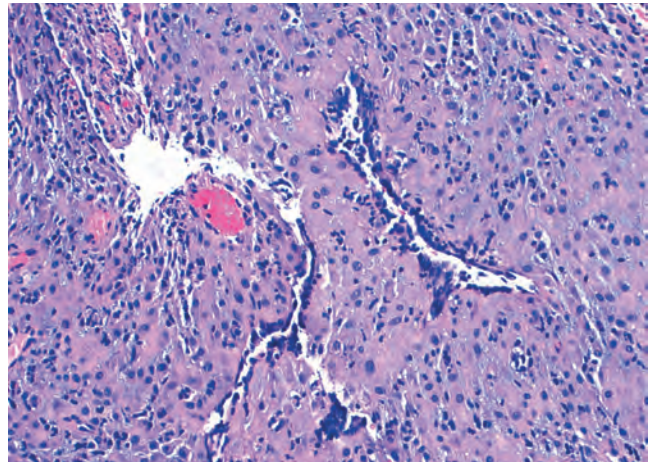
Stromal endometriosis refers to endometriotic foci composed of endometriotic stroma only. These foci can be very small and may thus be easily overlooked and underdiagnosed (Fig. 1.29). It has been described in the peritoneum, cervix, ovary, omentum and in other sites. In one study, it was identified in 44.9% of peritoneal biopsies.<sup>2</sup> These foci either occur in association with typical endometriosis or as the only manifestation of the disease. They usually present as serosal or subserosal nodules or plaques. Following completion of progestin treatment, the stromal cells can exhibit features of decidualization (Fig. 1.30). These cells may contain cytoplasmic vacuoles resembling signet-ring-like cells. However, they are cytokeratin-negative cells. Stromal endometriosis can also be found within the ovarian stroma and in the superficial stroma of the uterine cervix (Fig. 1.31). This is usually an incidental finding not associated with pelvic endometriosis.



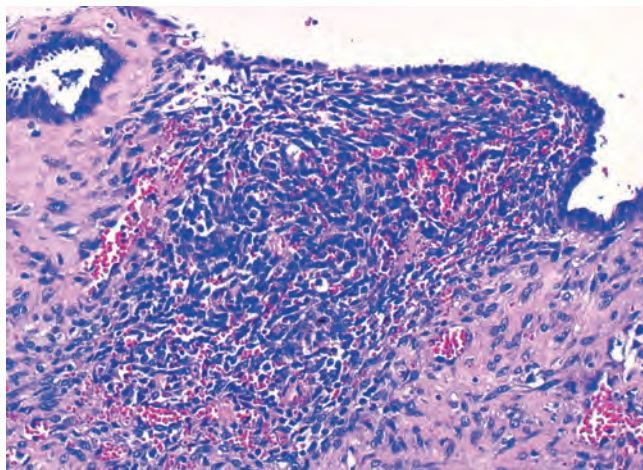
**Fig. 1.29** Stromal endometriosis with no identifiable glands.

#### ■ *Polypoid Endometriosis*

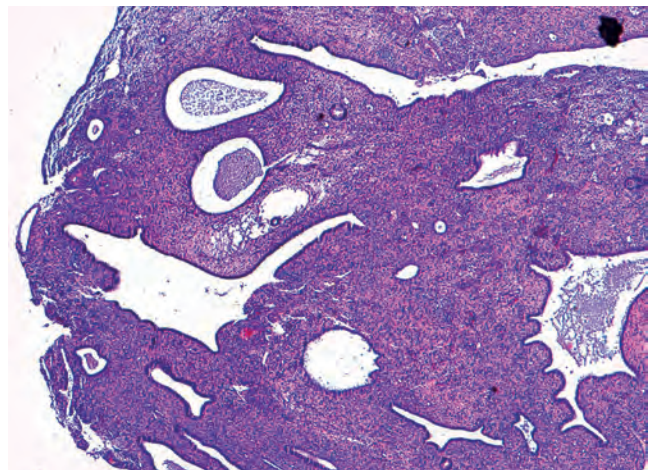
Polypoid endometriosis may mimic an endometrial polyp<sup>24</sup> or a neoplasm clinically, macroscopically and microscopically, most often adenosarcoma.<sup>5</sup> It is characterized by polypoid, often multiple, mucosal, or serosal masses (Fig. 1.32). Typical endometriosis is often present in the same site or elsewhere. The most common sites of occurrence are: colon, ovary, uterine serosa, cervicovaginal mucosa, ureter, fallopian tube, omentum, bladder, paraurethral and paravaginal soft tissue, and retroperitoneum.<sup>24</sup>



**Fig. 1.30** Endometriosis with decidualized stroma. Glands are atrophic.



**Fig. 1.31** Superficial stromal endometriosis of the cervix after preceding curettage.



**Fig. 1.32** Polypoid endometriosis consisting of a thick fragment of polypoid endometriotic tissue.



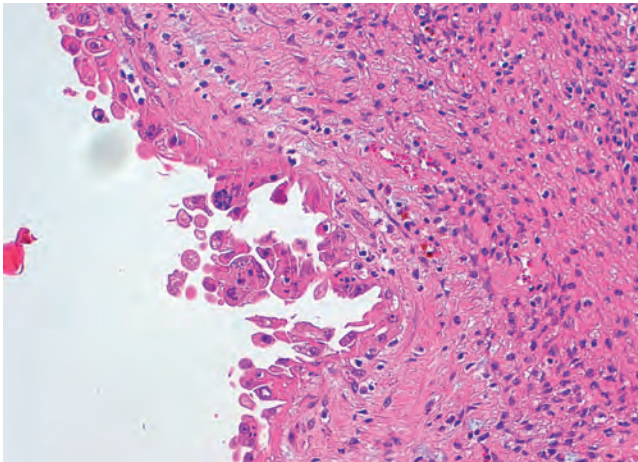
### 1.4.3.2 Atypical Endometriosis

The term 'atypical endometriosis' has been used in the literature to describe the following changes:

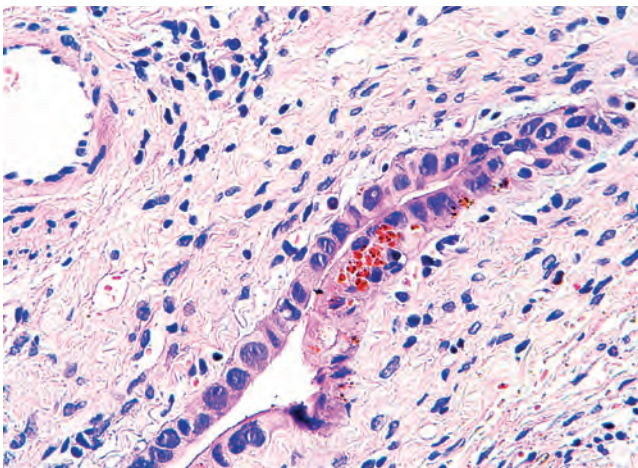
- Endometriosis with atypia of the glandular epithelium
- Endometriosis with hyperplasia, without and with atypia.

Cytologic atypia in endometriotic cysts is not a rare finding. *Czernobilsky and Morris*<sup>8</sup> report on a frequency of 22%, 3.6% with strong atypia. The atypical form is seen focally or multifocally, and consists of enlarged cells with a varying amount of eosinophilic cytoplasm (Fig. 1.33) and pleomorphic hyperchromatic nuclei with homogenized chromatin. Clear cells and hobnail cells are sometimes found coincidentally, in places with the formation of micropapillae and sometimes, in addition, with mucinous metaplasia (papillary mucinous metaplasia). According to *Ballouk et al.*,<sup>1</sup> cases with severe atypia were aneuploid, while those with minor or moderate atypia showed a diploid DNA content.

In most cases of endometriotic cysts, atypical cells can be attributed to reactive cell changes (Fig. 1.34) with a benign clinical course. Nevertheless, the concurrent appearance



**Fig. 1.33** Endometriotic cyst lined by eosinophilic cells with mild nuclear atypia.



**Fig. 1.34** Endometriotic gland with reactive nuclear changes. Hemosiderin deposits (brown granules) in the cytoplasm.

of adenocarcinoma and seromucinous borderline tumor in endometriotic cysts with atypia can give rise to suggest that in some cases the atypia is not due to regressive change but rather should be regarded as precancerous alteration. The frequency of malignant transformation amounts to 0.6–0.8%, in cases of histologically confirmed endometriosis > 10%.<sup>11</sup>

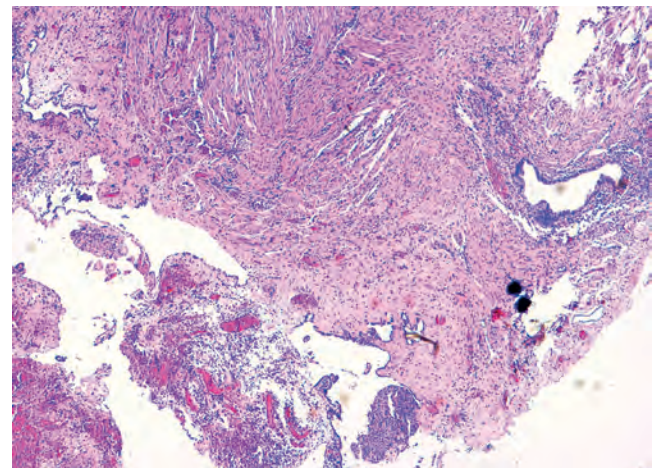
The rate of hyperplasia in endometriosis varies between 2%<sup>8</sup> and 9.4%.<sup>26</sup> Thus, it is clearly more infrequent than cytologic atypia. The risk of malignant transformation probably corresponds to that of atypical hyperplasia of the eutopic endometrium.

### 1.4.3.3 Special Sites

#### ■ Ovary

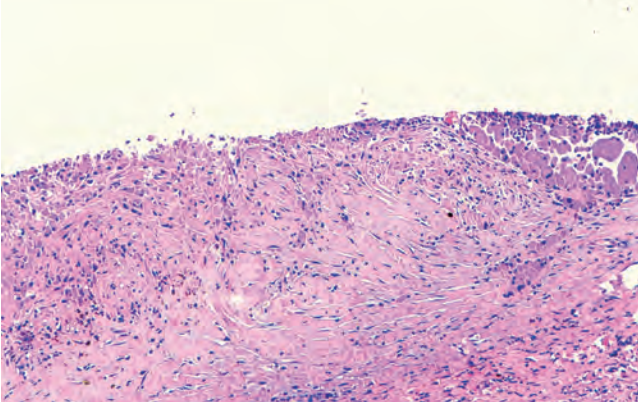
Up to 50% of cases of ovarian endometriosis appear as bilateral lesions, either as endometrium-like areas or as endometriotic cysts whose origin can be only supposed with longer existence. The size and state of these cysts is very variable and can amount up to 15 cm in size. Microscopically, the ovarian cortex is involved in most cases, occasionally the endometriotic focus is located at the ovarian surface (Fig. 1.35), possibly with concomitant adhesions. Reactive changes in the form of adhesions, inflammatory changes and mesothelial proliferations are frequently seen. In younger patients, the diagnosis of endometriosis is usually easy to make, nevertheless, in postmenopausal patients, the glands and the surrounding stroma are often atrophic, and the ectatic glands can be easily mistaken for inclusion cysts. Hyperplastic changes in the glands are rare in patients of older age.

The stroma varies considerably in its magnitude and its content of collagen fibres and cellular elements. Key diagnostic features are pigmented histiocytes (pseudoxanthoma cells) which often contain ceroid (lipofuscin, hemofuscin), but only rarely hemosiderin. Depending on the age of the cyst, a different lining can be found. In younger cysts, the endometrial origin of the cyst can be demonstrated based on the cubic to highly cylindrical epithelium. In older cysts or old cysts, only granulation tissue or a thick band of hyalinized collagenous tissue can be seen (Fig. 1.36), sometimes admixed with pseudoxanthoma cells.

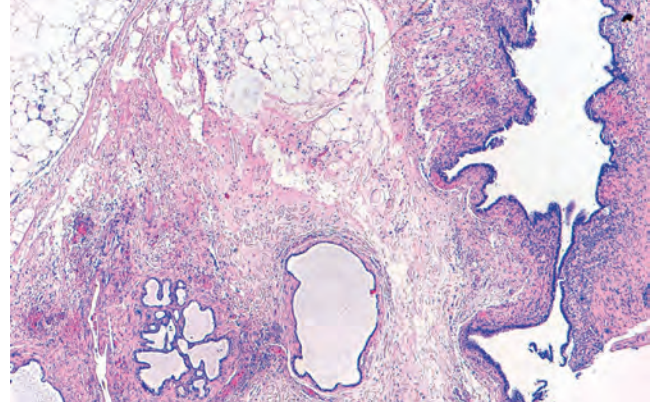


**Fig. 1.35** Endometriosis of the fallopian tube. Dilated gland in the tubal wall. Adhesions on the tubal surface.





**Fig. 1.36** Old endometriotic cyst with hyalinized cyst wall.

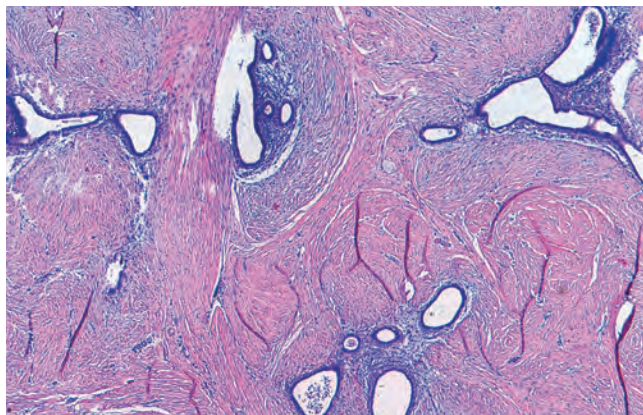


**Fig. 1.37** Endometriosis (right half) and endosalpingiosis close to each other. Endosalpingiosis is lined by serous epithelium, lacking endometrial stroma.

The lining epithelium can show the same metaplastic changes as the epithelium of the eutopic endometrium including tubal, eosinophilic, squamous, mucinous and hobnail-like metaplasia. Mucinous metaplasia is most often of endocervical type, only rarely of intestinal type with goblet cells. In a few cases, hobnail-like metaplasia takes on an atypical appearance with enlarged pleomorphic nuclei. The cytoplasm of these cells is usually eosinophilic and varies in its amount.

#### ■ Fallopian Tube

Endometriosis of the fallopian tube may exhibit various manifestations. A highly distinctive albeit uncommon form is signalled by the presence of endometrial tissue lining the tubal mucosa itself. In the majority of these cases, the endometriosis fills the entire lumen of the isthmic segment. This intraluminal growth may be a cause of infertility. A more common finding is the presence of endometriosis on the serosal surface of the fallopian tube. Depending on the age of the lesion, fibrosis and signs of repeated hemorrhage may be seen. Occasionally, endometriotic foci may be found in the tubal wall. This finding must be distinguished from salpingitis isthmica nodosa. In contrast to endometriosis, this disease resembles adenomyosis of the uterine myometrium. Salpingitis isthmica nodosa often assumes a nodular macroscopic appearance



**Fig. 1.38** Endometriosis of the abdominal wall in a scar after cesarean section.

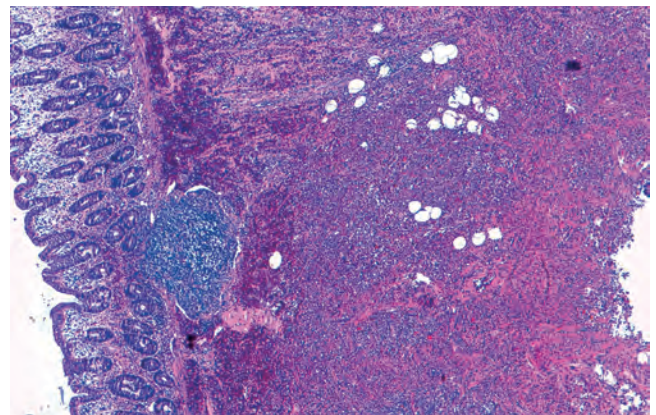
because of the reactive smooth muscle hyperplasia around the glandular epithelium. Tubal endometriosis may occur in conjunction with endosalpingiosis. This lesion consists of tubules or cysts with cuboidal or flattened epithelium-lacking endometrial stroma (Fig. 1.37). Psammoma bodies may be found in those lesions which indicate regression of the lesion. These are usually not found in endometriosis.

#### ■ Abdominal Wall Endometriosis

Endometriosis of the abdominal wall is the most frequent site of extrapelvic endometriosis. It consists of endometriotic foci of varying size interspersed between adipose and connective tissue, sometimes also in skeletal muscle (Fig. 1.38). It is usually seen in patients with a prior history of surgical procedures. The development of clear cell carcinoma in this location has been described by several authors.<sup>7,10,14,30,32</sup>

#### ■ Intestinal Endometriosis

The most common site of involvement is the rectosigmoid, followed by the proximal colon, small intestine and caecum. Endometriosis is also not an uncommon finding in the appendix. All layers of the intestinal wall may be involved. The subserosa and muscularis propria are the layers mainly affected by endometriosis. Secondary fibrosis may lead to bowel wall thickening, stricturing and luminal stenosis (Fig. 1.39). Mucosal



**Fig. 1.39** Endometriosis of the large intestine. Dense inflammatory infiltrate and fibrosis of the intestinal wall. There is no endometriotic focus visible in this area.



involvement may lead to deep fissuring into the muscularis propria. Muscularis propria involvement with associated fibrosis and/or smooth muscle hypertrophy may result in the formation of a mass and the differential diagnosis of a mesenchymal tumor. Mucosal and submucosal involvement may manifest with so-called polypoid endometriosis, mimicking a neoplastic polyp or inflammatory pseudopolyp. In the case of extensive submucosal disease with surface ulceration with rolled edges, a malignant tumor might be considered.

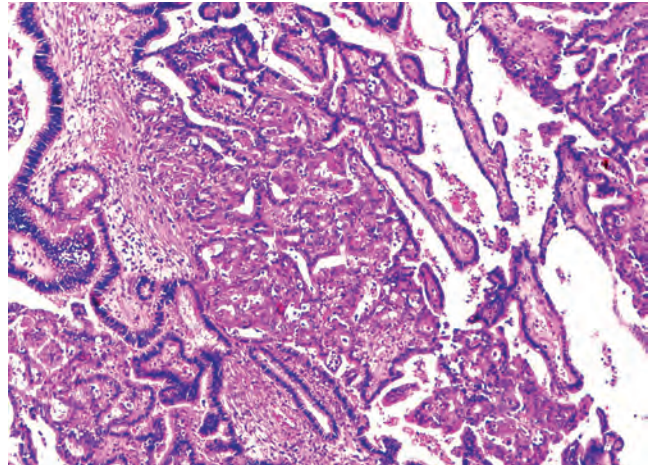
Mural changes include smooth muscle hypertrophy, neuronal hyperplasia and fibrosis around the foci of endometriosis.<sup>37</sup> Endometriotic glands may be distributed haphazardly within the mucosa and submucosa and can merge with the adjacent colonic epithelium, mimicking an adenocarcinoma, especially since some mitotic activity is not uncommon. The possible identification of cilia and endometrioid stroma, however, should prevent a misdiagnosis. Immunohistochemistry may be of great help since endometriotic glands are positive with CK7, CA125 and ER, and usually negative with CK20, CEA and CDX2, while the adjacent large intestinal glands exhibit the converse immunophenotype. The endometriotic stroma will stain with ER and CD10. Mullerian type adenocarcinomas, most commonly endometrioid and clear cell carcinoma, may rarely arise within endometriosis of the intestine.<sup>31</sup> The diagnosis is often straightforward in a resection specimen as adjacent foci of endometriosis are generally visible. Since the morphology of clear cell carcinoma differs significantly from most primary colorectal carcinomas, this diagnosis is a rather straightforward matter. Morphological features that may be helpful in diagnosing an endometrioid adenocarcinoma include a low nuclear grade, the frequent presence of squamous cells and an absence of the typical features of 'dirty' necrosis.

#### ■ Urinary Tract

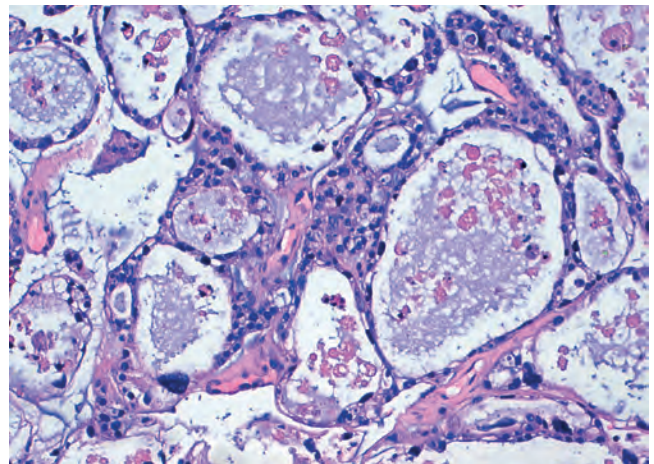
Endometriotic urinary tract involvement is rarely seen, with a prevalence of less than 1% in women suffering from endometriosis.<sup>29</sup> Most frequently, the bladder serosa is involved. In case of endometriotic involvement of the bladder wall, this is usually seen with coexisting fibrosis and muscular proliferation resulting in thickening of the bladder wall. The ureter, kidney and urethra are affected very rarely.

#### 1.4.4 Endometriosis-Associated Tumors

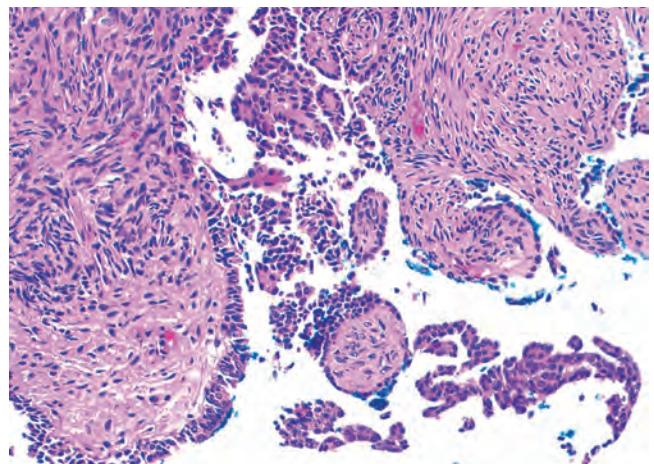
Common characteristics have been identified for malignant growth and clinical behavior of benign endometriosis. On the one hand, endometriotic tissue is capable of transgressing organ barriers and infiltrating into neighboring tissues or organs (deeply infiltrating endometriosis). On the other hand, it has been known for quite a long time that patients suffering from endometriosis in general have an increased risk of developing cancer.<sup>3</sup> It has also been shown<sup>11,22</sup> that the risk of ovarian carcinoma is clearly raised in ovarian endometriosis, in particular if this condition has been present for a long period of time. However, the increased risk is not equally distributed among all types of ovarian carcinoma, but specifically applies to endometrioid adenocarcinoma (Fig. 1.40), clear cell carcinoma (Fig. 1.41)<sup>4,27</sup> and low-grade malignant serous carcinoma.<sup>25</sup> In some cases, endometrioid ovarian carcinoma



**Fig. 1.40** Low-grade endometrioid adenocarcinoma in ovarian endometriosis.



**Fig. 1.41** Clear cell adenocarcinoma (tubulo-cystic type) in ovarian endometriosis.



**Fig. 1.42** Serous borderline tumor at the inner surface of an ovarian endometriotic cyst.

develops synchronously with endometrioid carcinoma of the endometrium.<sup>9</sup> These patients have a favorable prognosis.<sup>15</sup> In addition, patients with endometriosis have a higher risk for adenosarcoma, endometrioid stromal sarcoma as well as seromucinous borderline tumor (Fig. 1.42). Even infants can be affected.<sup>12</sup> A precursor lesion of seromucinous borderline tumor that may develop in endometriotic cysts, is papillary

mucinous metaplasia. Endometriosis-associated carcinomas affecting younger patients are diagnosed in lower stages, with a lower grade of malignancy and a more favorable prognosis than ovarian carcinomas, which have not been shown to be linked to endometriosis.<sup>11,34</sup>

- Endometrioid carcinoma
- Clear cell carcinoma
- Low-grade malignant serous carcinoma
- Seromucinous borderline tumor
- Adenosarcoma
- Endometrioid stromal sarcoma

**Table 1.2** Tumor types commonly associated with endometriosis.

Many morphological findings suggest a pathogenetic link between endometriosis and endometriosis-associated carcinomas. Apart from that, numerous molecular findings suggest a causal relationship between endometriosis and endometrioid carcinoma and clear cell carcinoma, respectively.

Loss of heterozygosity (LOH) for one locus or several loci on candidate genes for ovarian carcinoma on 6q, 9p, 11q, 17p, 17q and 22q have been demonstrated in 28% of patients with ovarian endometriosis.<sup>16</sup> LOH for the tumor suppressor gene PTEN/MMAC1 which is localized on chromosome 10q (10q23.3) was detected in 8 of 19 ovarian endometrioid carcinomas (42.1%), 6 of 22 clear cell carcinomas (27.3%) and 13 of 23 solitary endometrioid cysts (56.5%). Somatic mutations of PTEN were found in 4 of 20 ovarian endometrioid carcinomas (20.0%), 2 of 24 clear cell carcinomas (8.3%), and 7 of 34 solitary endometrioid cysts (20.6%).<sup>28</sup>

Synchronous endometriosis was found in five cases of endometrioid carcinoma and seven cases of clear cell carcinoma. Three out of five endometrioid carcinomas showed LOH, which was also detected in the associated endometriosis. Of the clear cell carcinomas with synchronous endometriosis three showed LOH, which coincides with those found in the associated endometriosis.

Wiegand *et al.*<sup>35</sup> described mutations in the ARID1A gene in endometrioid and clear cell carcinomas. Mutations were found in 55/119 (46%) of clear cell and 10/33 (30%) of endometrioid carcinomas. Mutations of ARID1A identified in the clear cell carcinomas were also found in the atypical endometriosis bordering the tumor, but not in the portion of the endometriosis at some distance from the tumor. Yamamoto *et al.*<sup>36</sup> were able to demonstrate a protein loss already in 86% of the non-atypical endometriosis.

Based on these findings it can be concluded that mutations of the ARID1A gene are an early event in the development of malignancy.

In recent studies on whole-genome sequencing and sequencing of certain genetic targets in ovarian clear cell carcinomas<sup>17</sup> frequent mutations of the PIK3CA gene and less often mutations of PPP2R1A and KRAS were identified in addition to the known mutations in the ARID1A gene. In endometrioid carcinoma mutations of PTEN, CTNNB1 ( $\beta$  Catenin) and KRAS<sup>20,23</sup> were found.

A relationship between endometriosis and clear cell carcinoma is also supported by immunohistochemical data. The marker HNF-1  $\beta$  is activated and overexpressed not only in clear cell carcinoma, but also in atypical endometriosis and in typical endometriosis.<sup>19</sup> Conversely, overexpression of HNF-1  $\beta$  is not found in endometrioid adenocarcinoma. Based on these differences Kajihara *et al.*<sup>18</sup> proposed a dichotomous model of the histogenesis of endometriosis-related adenocarcinomas of the ovary.

There are multiple interactions of the HNF-1  $\beta$  gene with other genes consisting of a gain or loss of significant genes which induce decidualization, endometrial differentiation and regeneration, hormone dependence, glycogen synthesis, detoxification, ion exchange and cell cycle regulation.<sup>33</sup>

To date, it remains unclear what causes the various genomic changes. A contributing factor could be the bloody content of the endometriotic cyst which exerts an oxidative stress on the lining cells of the cyst<sup>21</sup> because of the high iron content and the formation of free O<sub>2</sub> radicals.

#### 1.4.5 References

1. BALLOUK F, ROSS JS, WOLF BC. Ovarian endometriotic cysts. An analysis of cytologic atypia and DNA ploidy patterns. *Am J Clin Pathol* 1994;102(4):415–9.
2. BOYLE DP, MCCLUGGAGE WG. Peritoneal stromal endometriosis: a detailed morphological analysis of a large series of cases of a common and under-recognised form of endometriosis. *J Clin Pathol* 2009;62(6):530–3. doi:10.1136/jcp.2008.064261.
3. BRINTON LA, GRIDLEY G, PERSSON I, BARON J, BERGQVIST A. Cancer risk after a hospital discharge diagnosis of endometriosis. *Am J Obstet Gynecol* 1997;176(3):572–9.
4. BRINTON LA, SAKODA LC, SHERMAN ME, FREDERIKSEN K, KJAER SK, GRAUBARD BI *et al.* Relationship of benign gynecologic diseases to subsequent risk of ovarian and uterine tumors. *Cancer Epidemiol Biomarkers Prev* 2005;14(12):2929–35. doi:10.1158/1055-9965.EPI-05-0394.
5. CLARKE BA, MULLIGAN AM, IRVING JA, MCCLUGGAGE WG, OLIVA E. Mullerian adenosarcomas with unusual growth patterns: staging issues. *Int J Gynecol Pathol* 2011;30(4):340–7. doi:10.1097/PGP.0b013e31820b341e.
6. CLEMENT PB. The pathology of endometriosis: a survey of the many faces of a common disease emphasizing diagnostic pitfalls and unusual and newly appreciated aspects. *Adv Anat Pathol* 2007;14(4):241–60. doi:10.1097/PAP.0b013e3180ca7d7b.
7. COZZOLINO M, MAGNOLFI S, CORIONI S, MONCINI D, MATTEI A. Abdominal Wall Endometriosis on the Right Port Site After Laparoscopy: Case Report and Literature Review. *Ochsner J* 2015;15(3):251–5.
8. CZERNOBILSKY B, MORRIS WJ. A histologic study of ovarian endometriosis with emphasis on hyperplastic and atypical changes. *Obstet Gynecol* 1979;53(3):318–23.



9. GRAMMATIKAKIS I, ZERVOUDIS S, EVANGELINAKIS N, TZIORTZIOTI V. Endometrium and ovarian cancer synchronous to endometriosis – a retrospective study of our experience of 7 years. *J Med Life* 2010;3(1):76–9.
10. HELLER DS, HOUCK K, LEE ES, GRANICK MS. Clear cell adenocarcinoma of the abdominal wall: a case report. *J Reprod Med* 2014;59(5-6):330–2.
11. HIGASHIURA Y, KAJIHARA H, SHIGETOMI H, KOBAYASHI H. Identification of multiple pathways involved in the malignant transformation of endometriosis (Review). *Oncol Lett* 2012;4(1): 3–9. doi:10.3892/ol.2012.690.
12. HO RSL, CHAN GCF, HA SY, IP PPC. Endometriosis-associated serous borderline tumor and endometrial stromal sarcoma of the ovary: a report of a rare lesion in an infant. *Int J Gynecol Pathol* 2012;31(1):98–102. doi:10.1097/PGP.0b013e31822103ca.
13. HOUGHTON O, MCCLUGGAGE WG. Pitfalls in the diagnosis of endometriosis: A condition characterized by a plethora of unusual histological features. *Diagnostic Histopathology* 2011;17(4): 193–202. doi:10.1016/j.mpdhp.2011.01.001.
14. IJICHI S, MORI T, SUGANUMA I, YAMAMOTO T, MATSUSHIMA H, ITO F et al. Clear cell carcinoma arising from cesarean section scar endometriosis: case report and review of the literature. *Case Rep Obstet Gynecol* 2014;2014:642483. doi:10.1155/2014/642483.
15. IRVING JA, CATASUS L, GALLARDO A, BUSSAGLIA E, ROMERO M, MATIAS-GUIU X et al. Synchronous endometrioid carcinomas of the uterine corpus and ovary: alterations in the beta-catenin (CTNNB1) pathway are associated with independent primary tumors and favorable prognosis. *Hum Pathol* 2005;36(6):605–19. doi:10.1016/j.humpath.2005.03.005.
16. JIANG X, HITCHCOCK A, BRYAN EJ, WATSON RH, ENGLEFIELD P, THOMAS EJ et al. Microsatellite analysis of endometriosis reveals loss of heterozygosity at candidate ovarian tumor suppressor gene loci. *Cancer Res* 1996;56(15):3534–9.
17. JONES S, WANG T, SHIH I, MAO T, NAKAYAMA K, RODEN R et al. Frequent mutations of chromatin remodeling gene ARID1A in ovarian clear cell carcinoma. *Science* 2010;330(6001):228–31. doi:10.1126/science.1196333.
18. KAJIHARA H, YAMADA Y, SHIGETOMI H, HIGASHIURA Y, KOBAYASHI H. The dichotomy in the histogenesis of endometriosis-associated ovarian cancer: clear cell-type versus endometrioid-type adenocarcinoma. *Int J Gynecol Pathol* 2012;31(4):304–12. doi:10.1097/PGP.0b013e318243a97b.
19. KATO N, SASOU S, MOTOYAMA T. Expression of hepatocyte nuclear factor-1beta (HNF-1beta) in clear cell tumors and endometriosis of the ovary. *Mod Pathol* 2006;19(1):83–9. doi:10.1038/modpathol.3800492.
20. KOLASA IK, REMBISZEWSKA A, JANIEC-JANKOWSKA A, DANSONKA-MIESZKOWSKA A, LEWANDOWSKA AM, KONOPKA B et al. PTEN mutation, expression and LOH at its locus in ovarian carcinomas. Relation to TP53, K-RAS and BRCA1 mutations. *Gynecol Oncol* 2006;103(2):692–7. doi:10.1016/j.ygyno.2006.05.007.
21. MANDAI M, MATSUMURA N, BABA T, YAMAGUCHI K, HAMANISHI J, KONISHI I. Ovarian clear cell carcinoma as a stress-responsive cancer: influence of the microenvironment on the carcinogenesis and cancer phenotype. *Cancer Lett* 2011;310(2):129–33. doi:10.1016/j.canlet.2011.06.039.
22. MELIN A, SPAREN P, PERSSON I, BERGQVIST A. Endometriosis and the risk of cancer with special emphasis on ovarian cancer. *Hum Reprod* 2006;21(5):1237–42. doi:10.1093/humrep/dei462.
23. PALACIOS J, GAMALLO C. Mutations in the beta-catenin gene (CTNNB1) in endometrioid ovarian carcinomas. *Cancer Res* 1998;58(7):1344–7.
24. PARKER RL, DADMANESH F, YOUNG RH, CLEMENT PB. Polypoid endometriosis: a clinicopathologic analysis of 24 cases and a review of the literature. *Am J Surg Pathol* 2004;28(3): 285–97.
25. PEARCE CL, TEMPLEMAN C, ROSSING MA, LEE A, NEAR AM, WEBB PM et al. Association between endometriosis and risk of histological subtypes of ovarian cancer: a pooled analysis of case-control studies. *Lancet Oncol* 2012;13(4):385–94. doi:10.1016/S1470-2045(11)70404-1.
26. PREFUMO F, TODESCHINI F, FULCHERI E, VENTURINI PL. Epithelial abnormalities in cystic ovarian endometriosis. *Gynecol Oncol* 2002;84(2):280–4. doi:10.1006/gyno.2001.6529.
27. ROSSING MA, CUSHING-HAUGEN KL, WICKLUND KG, DOHERTY JA, WEISS NS. Risk of epithelial ovarian cancer in relation to benign ovarian conditions and ovarian surgery. *Cancer Causes Control* 2008;19(10):1357–64. doi:10.1007/s10552-008-9207-9.
28. SATO N, TSUNODA H, NISHIDA M, MORISHITA Y, TAKIMOTO Y, KUBO T et al. Loss of heterozygosity on 10q23.3 and mutation of the tumor suppressor gene PTEN in benign endometrial cyst of the ovary: possible sequence progression from benign endometrial cyst to endometrioid carcinoma and clear cell carcinoma of the ovary. *Cancer Res* 2000;60(24):7052–6.
29. SCHNEIDER A, TOULOUPIDIS S, PAPATSORIS AG, TRIANTAFYLIDIS A, KOLLIAS A, SCHWEPPE K. Endometriosis of the urinary tract in women of reproductive age. *Int J Urol* 2006;13(7):902–4. doi:10.1111/j.1442-2042.2006.01437.x.
30. SHALIN SC, HAWS AL, CARTER DG, ZARRIN-KHAMEH N. Clear cell adenocarcinoma arising from endometriosis in abdominal wall cesarean section scar: a case report and review of the literature. *J Cutan Pathol* 2012;39(11):1035–41. doi:10.1111/j.1600-0560.2012.01982.x.
31. SLAVIN RE, KRUM R, VAN DINH T. Endometriosis-associated intestinal tumors: a clinical and pathological study of 6 cases with a review of the literature. *Hum Pathol* 2000;31(4):456–63.
32. TABURIAUX L, PLUCHINO N, PETIGNAT P, WENGER J. Endometriosis-Associated Abdominal Wall Cancer: A Poor Prognosis? *Int J Gynecol Cancer* 2015;25(9):1633–8. doi:10.1097/IGC.0000000000000556.
33. UEKURI C, SHIGETOMI H, ONO S, SASAKI Y, MATSUURA M, KOBAYASHI H. Toward an understanding of the pathophysiology of clear cell carcinoma of the ovary (Review). *Oncol Lett* 2013;6(5):1163–73. doi:10.3892/ol.2013.1550.
34. VERAS E, MAO T, AYHAN A, UEDA S, LAI H, HAYRAN M et al. Cystic and adenofibromatous clear cell carcinomas of the ovary: distinctive tumors that differ in their pathogenesis and behavior: a clinicopathologic analysis of 122 cases. *Am J Surg Pathol* 2009;33(6):844–53. doi:10.1097/PAS.0b013e31819c4271.
35. WIEGAND KC, SHAH SP, AL-AGHA OM, ZHAO Y, TSE K, ZENG T et al. ARID1A mutations in endometriosis-associated ovarian carcinomas. *N Engl J Med* 2010;363(16):1532–43. doi:10.1056/NEJMoa1008433.

36. YAMAMOTO S, TSUDA H, TAKANO M, TAMAI S, MATSUBARA O. Loss of ARID1A protein expression occurs as an early event in ovarian clear-cell carcinoma development and frequently coexists with PIK3CA mutations. *Mod Pathol* 2012;25(4):615–24. doi:10.1038/modpathol.2011.189.
37. YANTISS RK, CLEMENT PB, YOUNG RH. Endometriosis of the intestinal tract: a study of 44 cases of a disease that may cause diverse challenges in clinical and pathologic evaluation. *Am J Surg Pathol* 2001;25(4):445–54.

## 1.5

## Anatomical Understanding for Radical Endometriotic Treatment

Daniel Ginn<sup>a</sup> | Joseph L. Hudgens<sup>b</sup> | Resad Pasic<sup>c</sup>**1.5.1 Introduction**

In the radical treatment of endometriosis, the most important tool available to the surgeon is expert knowledge of anatomy. Awareness of normal anatomic relationships guides the assessment, dissection, restoration, and resection of tissue damaged by endometriosis. Critical adjunct discussions of endometriosis pathology (subsection 1.4), neuropelvology (subsection 4.6.), and surgical techniques (chapter 3) are covered in detail later in this text and must be reviewed and fully understood for a safe and successful approach to radical endometriotic treatment.

The plan for surgical resection must account for the three different types of endometriosis – superficial endometriosis, ovarian endometriomas, and deeply infiltrating endometriosis (DIE). Superficial endometriosis lesions are most commonly found in the posterior compartment of the pelvis and, specifically, on the left side. Similarly, primary and recurrent ovarian endometriomas most frequently are observed in the left ovary.<sup>3</sup>

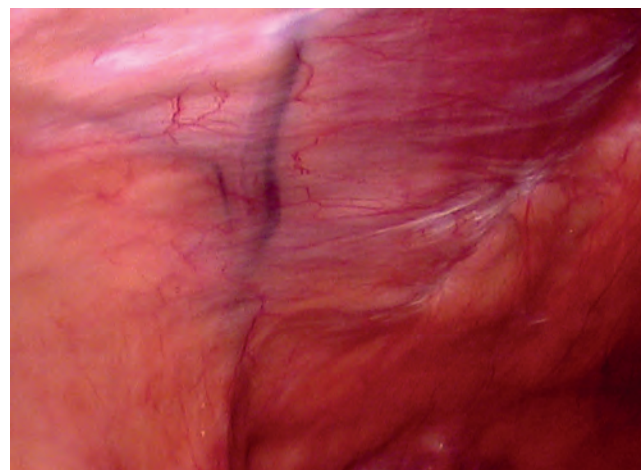
DIE lesions are those that invade tissue to a depth of more than 5 mm beneath the peritoneum and affected patients have pain symptoms that are strongly related to that depth of invasion.<sup>3</sup> Lesions are found in the pelvis in the anterior compartment invading the bladder wall muscularis and in the posterior compartment on the uterosacral ligament and vagina, including the rectovaginal septum; and also abdominally, invading the intestinal muscularis. Most often, lesions are multifocal, with the exception of the bladder wall where lesions are typically unifocal.<sup>4</sup> Overall, the left side is more prominently affected by DIE lesions to the uterosacral ligaments, intestines, and ureter. Pelvic DIE lesions occur most often in the posterior compartment while abdominal DIE lesions are more common on the appendix and ileocecal junction.<sup>3</sup> In all cases, understanding the locations of DIE is critical to achieving symptomatic improvement for patients via surgical resection.<sup>4</sup>

A routine diagnostic survey of the abdomen provides the roadmap for an overview of pelvic anatomy. In order to address severe endometriosis, dissection must occur from ‘known to unknown,’ using normal anatomic landmarks to guide restoration and treatment of distorted areas. The laparoscopic approach to endometriosis offers distinct advantages for dissection including pneumoperitoneum, which aids in hemostatic tamponade and in separation of areolar tissues, and superior magnification of areas requiring fine attention. Pelvic anatomy, particularly neurovascular structures and the course of the ureter, carries a significant rate of anomalies and, as such, blunt dissection is safest whenever possible.<sup>6</sup>

**1.5.2 Important Anatomic Considerations for Laparoscopic Trocar Placement in the Anterior Abdominal Wall**

Complete understanding of the major structures of the anterior abdominal wall is essential for safe entry into the abdomen. The two critical considerations of laparoscopic trocar placement are vascular and nerve anatomy. The course of the inferior epigastric artery is of first importance in trocar placement. The inferior epigastric artery branches from the external iliac artery at the level of the inguinal ligament. Intraabdominally, it is seen within the lateral umbilical fold on the anterior wall, medial to the insertion of the round ligament at the deep inguinal ring and is grouped with two veins.<sup>5</sup> This artery cannot be transilluminated and can be visualized directly through the laparoscope (Fig. 1.43).

In the retroperitoneal space, the most fearsome anatomic structure to consider during laparoscopic entry is the aorta. The aortic bifurcation lies at the level of L4 and varies in relation to anterior wall anatomy depending on the patient’s body mass. In a non-obese patient, the bifurcation is even with the umbilicus and can be avoided with entry at a 45-degree angle.



**Fig. 1.43** The left inferior epigastric artery is visualized directly through the laparoscope.

<sup>a</sup> | DO, MPH; Ob/Gyn & Women’s Health at University of Louisville Hospital Physicians  
Outpatient Center, Louisville, KY, USA

<sup>b</sup> | MD, MPH; Department of Obstetrics and Gynecology, Director of Minimally Invasive Surgery at Wiser Women’s Hospital, University of Mississippi Medical Center, Jackson, MS, USA

<sup>c</sup> | MD, PhD; Ob/Gyn & Women’s Health at University of Louisville Hospital Physicians  
Outpatient Center, Louisville, KY, USA

**Corresponding author:**

**Daniel Ginn**, DO, MPH  
Ob/Gyn & Women’s Health, University of Louisville Hospital  
Physicians Outpatient Center  
401 E Chestnut St # 410  
Louisville, KY 40202, U.S.A.  
E-mail: daniel.ginn@louisville.edu



In obese patients, the umbilicus is caudad to the bifurcation. Also in the retroperitoneal space is the presacral (or superior hypogastric) nerve plexus, which is anterior to both the aortic bifurcation and the left common iliac vein, which is most posterior. These structures coalesce at the level of L5.<sup>5</sup>

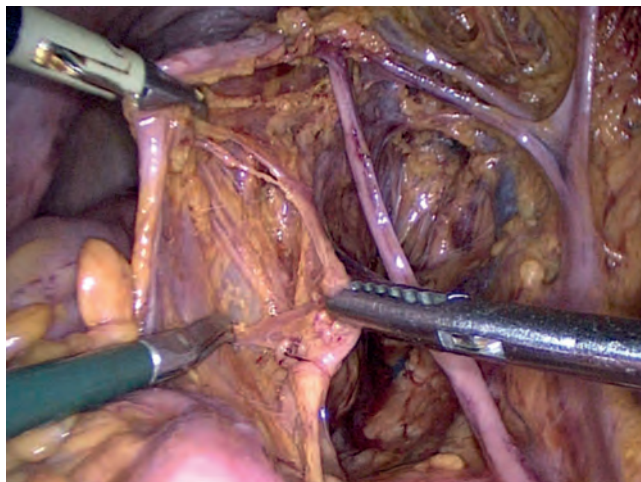
#### 1.5.2.1 Layers of the Pelvic Sidewall

There are three surgical layers to the pelvic sidewall that are demarcated by avascular planes. The retroperitoneal entry is accomplished in the space created by the round ligament anteriorly, the infundibulopelvic ligament medially, and the external iliac artery laterally. In the first layer of the pelvic sidewall, the ureter and hypogastric nerve that runs below and parallel to the ureter which is attached to the medial leaf of the broad ligament within a pseudosheath. The second layer is made up of the internal iliac vessels and the visceral anterior branches including the uterine, superior vesical, umbilical, inferior vesical, vaginal, and middle rectal arteries, as well as the visceral connective tissue containing the lymphatics and hypogastric nerves. The third layer of the pelvic sidewall contains the external iliac artery medial to the psoas muscle, the external iliac vein medial and posterior the psoas and obturator internus muscles, and the obturator neurovascular bundle on the obturator internus muscle. The obturator nerve can safely be retracted medially during blunt dissection of this space<sup>9,10</sup> (Fig. 1.44).

#### 1.5.2.2 Ureter

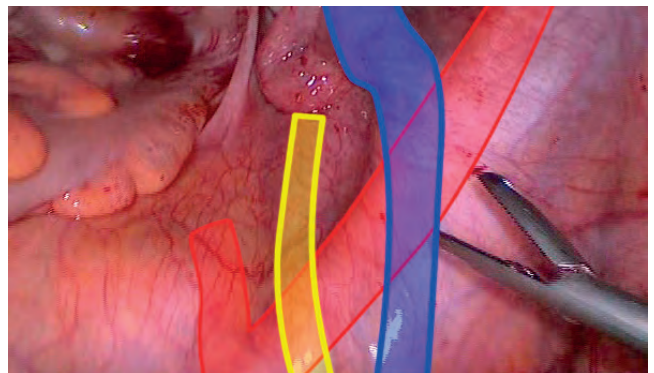Ureterolysis is frequently required for radical endometriosis surgery and resection of some adnexal masses. Full dissection of the ureter from the adventitia should be minimized, where possible, in order to preserve the supplying vasculature and prevent ischemic injury.<sup>8</sup> Above the pelvic brim, the arterial supply to the ureter is primarily medial in origin and within the pelvis, the supply approaches laterally.<sup>1</sup>

The right and left ureters must initially be considered separately. Vermiculation of the ureter should be observed to confirm identification.<sup>1</sup> The ureters lie medial to the ipsilateral

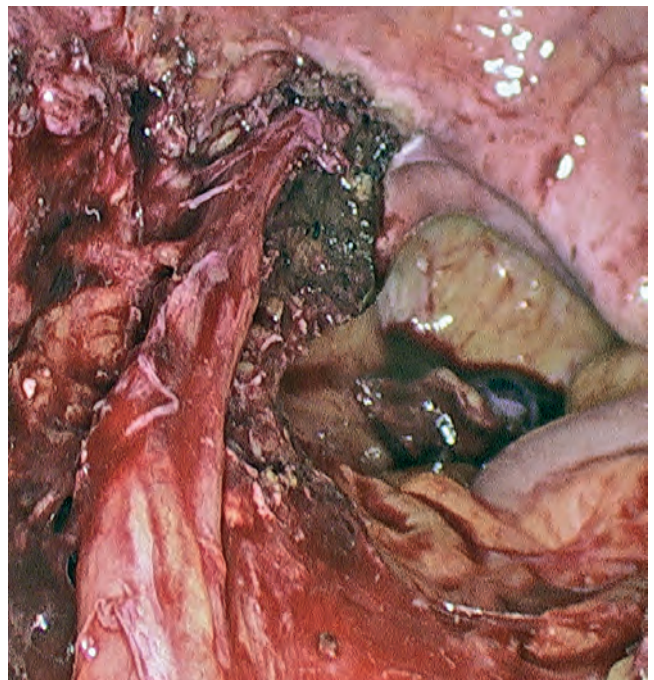


**Fig. 1.44** Cadaveric dissection of the right pelvic sidewall. The grasper is holding right hypogastric nerve. Ureter is completely freed up from the peritoneum and is seen in the middle. Right inferior iliac artery is seen with uterine artery, inferior vesical and obliterated umbilical branches.

psoas muscles and infundibulopelvic ligaments. The right ureter is easiest to view in the retroperitoneum overlying the pelvic brim and crosses over the right external iliac artery (Fig. 1.45). The left ureter is typically obscured by the sigmoid colon and can be first identified in the left ovarian fossa and then crossing over the left common iliac artery. The left ureter can best be reached by opening the peritoneum under the infundibulopelvic ligament and dissecting inferiorly on the peritoneal side (Fig. 1.46). The ureter is loosely attached to the retroperitoneal tissue and typically falls with the medial leaf of the broad ligament after opening the peritoneum parallel to the ovarian vasculature. The uterine artery travels laterally to the ureter until crossing over it to supply the uterus, at which point, the ureter is typically 1.5 centimeters lateral to the cervix.<sup>5,7</sup> The ureter is most commonly vulnerable to injury within the 2.5 centimeter space between passing under the uterine artery, traversing the upper portion of the cardinal ligament, and then inserting into the lateral trigone of the bladder.<sup>1</sup> The ureteral orifice is a continuous fusion of the ureteral muscularis to the trigone.<sup>7</sup>



**Fig. 1.45** Right ureter is seen passing under the right infundibulopelvic ligament.



**Fig. 1.46** Dissected left pelvic side wall with left ureter.



### 1.5.2.3 Space of Retzius

The space of Retzius, or the retropubic space, is bounded by the pubic symphysis anteriorly, the pubic rami and obturator internus muscles laterally, and the bladder posteriorly. When opened, the space shows the anterior bladder and proximal urethra and it is supported posteriorly by the fibro-fatty endopelvic (or pubocervical) fascia of the vaginal wall. The anterior margins of the space can be developed by blunt dissection of the adipose tissue of the bladder away from the pubic bone. Laterally, the space extends to the paravesical space.<sup>2</sup> The relevance of dissection of this space is only in cases of extensive bladder endometriosis.

### 1.5.2.4 Bladder

The bladder is a hollow, muscular pelvic organ that serves as a reservoir for urine. When empty, it lies below the level of the pubic symphysis, however, when full, the bladder can rise above the symphysis. The superior surface, or apex, of the bladder is covered by peritoneum that connects anteriorly via a fibrous cord to transversalis fascia, creating the median umbilical ligament. The bladder wall is coated internally with layers of transitional epithelium. An overlying layer of loose connective tissue permits stretching of the mucosa except at the trigone, where the mucosa is adherent to the musculature, yielding a smooth appearance of the tissue.<sup>7</sup>

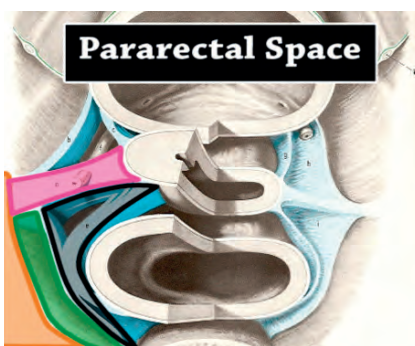### 1.5.2.5 Avascular Spaces

Knowledge of retroperitoneal anatomy and avascular spaces in the pelvis is essential for surgeons to navigate their way through the pelvis. The paravesical space opens into the space of Retzius and is bordered anteriorly by the broad ligament,

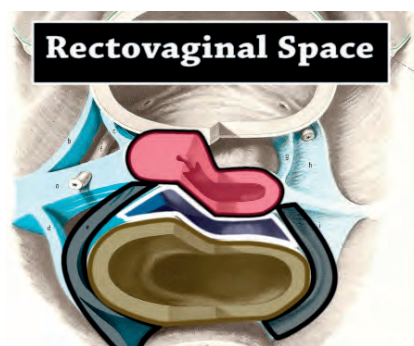medially by the bladder, and laterally by the obturator internus muscle fascia. Lateral to this space is the obturator space containing the obturator nerve and obturator vessels.<sup>9</sup> The paravesical space is divided by the cardinal ligaments and uterine artery from the pararectal space.

The pararectal space lies posterior to the base of the broad ligament and is important in lower segment ureterolysis. The boundaries of the space are the rectal pillars medially, the pelvic sidewall laterally, and the cardinal ligaments anteriolaterally. The space can be further subdivided into medial and lateral segments by the ureter. Within the lateral subdivision of the pararectal space lies the uterosacral ligament as it passes posteriorly toward the sacrum (Fig. 1.47).

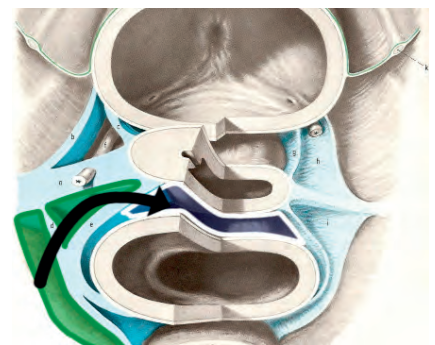
The rectovaginal space lies between the uterosacral ligaments, vaginal fascia, and rectum and is accessed via the pararectal spaces (Fig. 1.48). Obliteration of this space occurs due to endometriotic scarring of the ovarian fossae and sigmoid colon. The entry into the rectovaginal space is safely performed by dissecting the pararectal space, identifying the ureter and branches of the hypogastric nerve and entering the rectovaginal space from lateral toward medial (Fig. 1.49). The posterior cervix is incised superior to the rectum, which is then dissected inferiorly to the uterosacral ligaments and then potential space between the ureter and uterosacral ligament can be accessed and the uterosacral ligament divided to open the rectovaginal space. Care should be taken in this space with dissection medial to the uterosacral due to the vasculature of the perirectal fat.<sup>6,9</sup> When performing the dissection in this area, the surgeons should keep in mind that fat belongs to the rectum in order to avoid rectal injury.



**Fig. 1.47** Schematic drawing of the pararectal space.



**Fig. 1.48** Schematic drawing of the rectovaginal space.



**Fig. 1.49** Entry into the rectovaginal space is obtained via pararectal space.

### 1.5.3 References

1. BAGGISH MS. Identifying and Avoiding Ureteral Injury. In: Baggish MS, Karram MM, editors. Atlas of pelvic anatomy and gynecologic surgery., 3rd ed. St. Louis: Elsevier Saunders; 2011. p. 455–70.
2. BAGGISH MS, KARRAM MM. Anatomy of retropubic space. In: Baggish MS, Karram MM, editors. Atlas of pelvic anatomy and gynecologic surgery., 3rd ed. St. Louis: Elsevier Saunders; 2011. p. 401–18.
3. CHAPRON C, CHOPIN N, BORGHESE B, FOULOT H, DOUSSET B, VACHER-LAVENU MC et al. Deeply infiltrating endometriosis: pathogenetic implications of the anatomical distribution. Hum Reprod 2006;21(7):1839–45. doi:10.1093/humrep/del079.
4. CHAPRON C, FAUCONNIER A, VIEIRA M, BARAKAT H, DOUSSET B, PANSINI V et al. Anatomical distribution of deeply infiltrating endometriosis: surgical implications and proposition for a classification. Hum Reprod 2003;18(1):157–61.
5. FALCONE T, WALTERS MD. Pelvic anatomy from the laparoscopic view. In: Baggish MS, Karram MM, editors. Atlas of pelvic anatomy and gynecologic surgery., 3rd ed. St. Louis: Elsevier Saunders; 2011. p. 1283–8.
6. JANIK GM. Retroperitoneal dissection of the pelvic sidewall for benign disease. In: Pasic R, Levine RL, editors. A practical manual of laparoscopy: A clinical cookbook, 2nd ed. London: Informa Healthcare; 2007. (ISBN No. 9781842143308).
7. KARRAM MM. Surgical anatomy of the bladder and ureter. In: Baggish MS, Karram MM, editors. Atlas of pelvic anatomy and gynecologic surgery., 3rd ed. St. Louis: Elsevier Saunders; 2011. p. 1051–6.
8. MAGGIO M, TRABUCO EC, GEBHART JB. Managing ureteral injury during pelvic surgery. In: Baggish MS, Karram MM, editors. Atlas of pelvic anatomy and gynecologic surgery., 3rd ed. St. Louis: Elsevier Saunders; 2011. p. 1091–107.
9. ROGERS RM. Pelvic anatomy seen through the laparoscope. In: Pasic R, Levine RL, editors. A practical manual of laparoscopy: A clinical cookbook, 2nd ed. London: Informa Healthcare; 2007. (ISBN No. 9781842143308).
10. YADAV J, DATTA MS, NEZHAT C, NEZHAT C, NEZHAT F. Intraperitoneal and Retroperitoneal Anatomy. In: Nezhat C, editor. Nezhat's operative gynecologic laparoscopy with hysteroscopy, 3rd ed. Cambridge: Cambridge Univ. Press; 2008. p. 70–82. (ISBN No. 978-0-521-86249-3).

## 1.6

## Classification of Endometriosis

Peter Oppelt<sup>a</sup> | Omar Shebl<sup>b</sup>**1.6.1 Introduction**

Endometriosis is a disease that is becoming increasingly important, and it is therefore vital for any health care professional faced with this condition to be able to systematically classify and reproduce the findings obtained in each individual case. This is usually done using a classification system. However, considering the heterogenous symptomatic picture of endometriosis, which can range from pain to sterility, a coherent classification system capable of meeting all requirements is still lacking.

On an international level, a multitude of scoring and classification systems have been developed for endometriosis, and the *revised version of the American Society for Reproductive Medicine (rASRM)*, published in 1997, has become the one most widely used worldwide.<sup>3</sup> The latter is a scoring system that uses point scores to demarcate the stage of disease and does not allow morphologic-topographic characteristics to be taken into account. Another classification system which was very popular in the past was the *Endoscopic Endometriosis Classification (EEC)* according to *Mettler and Semm*.<sup>7</sup>

The inability of the rASRM score to reflect deeply infiltrating endometriosis prompted a German-speaking research group to revisit and explore the topic in greater detail, which finally led to the publication of the *Enzian classification*.<sup>6</sup> Its preliminary version was rather unwieldy which is why the scheme was subjected to a follow-up revision. Even though a separate edition has not been released yet, the current German version of the *Enzian classification* scheme, that dates from 2012, can be accessed for download from the website of the Foundation for Endometriosis Research (*Stiftung Endometrioseforschung*) using the internet link\* given below.<sup>8</sup> Unlike the rASRM scheme, the *Enzian classification* is not based on a scoring system, but should rather be considered a topographic and/or working description focusing on the assessment of deeply infiltrating endometriosis.

\* [www.endometriose-sef.de/dateien/ENZIAN\\_2013\\_web.pdf](http://www.endometriose-sef.de/dateien/ENZIAN_2013_web.pdf)

<sup>a</sup> | Professor, MD, MBA; Kepler University Hospital, Medical Campus IV, Department of Gynecology, Obstetrics and Gynecological Endocrinology, Linz, Austria

<sup>b</sup> | Associate Professor, MD; Kepler University Hospital, Medical Campus IV, Department of Gynecology, Obstetrics and Gynecological Endocrinology, Linz, Austria

**Corresponding author:**

Univ.-Prof. Dr. **Peter Oppelt**, MBA

Klinik für Gynäkologie, Geburtshilfe und Gynäkologische Endokrinologie  
Kepler Universitätsklinikum, Med. Campus IV

Klinik für Gynäkologie, Geburtshilfe und Gynäkologische Endokrinologie  
Krankenhausstrasse 26–30  
4020 Linz, Austria

E-mail: [peter.oppelt@kepleruniklinikum.at](mailto:peter.oppelt@kepleruniklinikum.at)

A diagnosis of endometriosis is often established in patients who wish to give birth to a child. This has not been taken into account in any of the scoring or classification systems available so far. The publication of the *Endometriosis Fertility Index (EFI)* provided a tool that uses point scores to predict a patient's probability of getting pregnant.<sup>1</sup>

The severity of pain has not been adequately reflected in any of the existing classification systems, even though this clinical feature is among those contributing factors that have a major impact on a patient's quality of life.

As already stated, a large number of scoring and classification systems are available for endometriosis, but only those mentioned above will be discussed in the following.

**1.6.2 History**

One of the oldest classification schemes for endometriosis which is still used in some textbooks, is that of *Albrecht* (1955).<sup>2</sup> In this scheme, endometriotic nodules are classified only according to their location, as described below:

- **Internal genital endometriosis:** endometriotic lesions located within the myometrium (also known as 'adenomyosis uteri').
- **External genital endometriosis:** endometriotic lesions outside the uterus, in the lesser pelvis (ovaries, sacrouterine ligaments, rectouterine pouch, bladder peritoneum).
- **Extragenital endometriosis:** endometriotic lesions outside the lesser pelvis.

Documentation of extent and size of endometriotic lesions is not at all taken into account, while only a rough mapping of locations is provided for by this classification scheme.

### 1.6.3 Classification Schemes

#### 1.6.3.1 rASRM Classification

The endometriosis classification of the *American Society for Reproductive Medicine* (rASRM)<sup>3</sup> stipulates that primary evaluation addresses two major categories. In the first category, the location of endometriotic lesions is recorded (ovary, peritoneum), along with their extent (superficial,

deeply infiltrating). Severity and extent of adhesions related to fallopian tubes and ovaries is assessed in the second category. Additional point scores are assigned in the presence of partial or complete endometriotic involvement of the rectouterine pouch (pouch of Douglas) (Fig. 1.50).

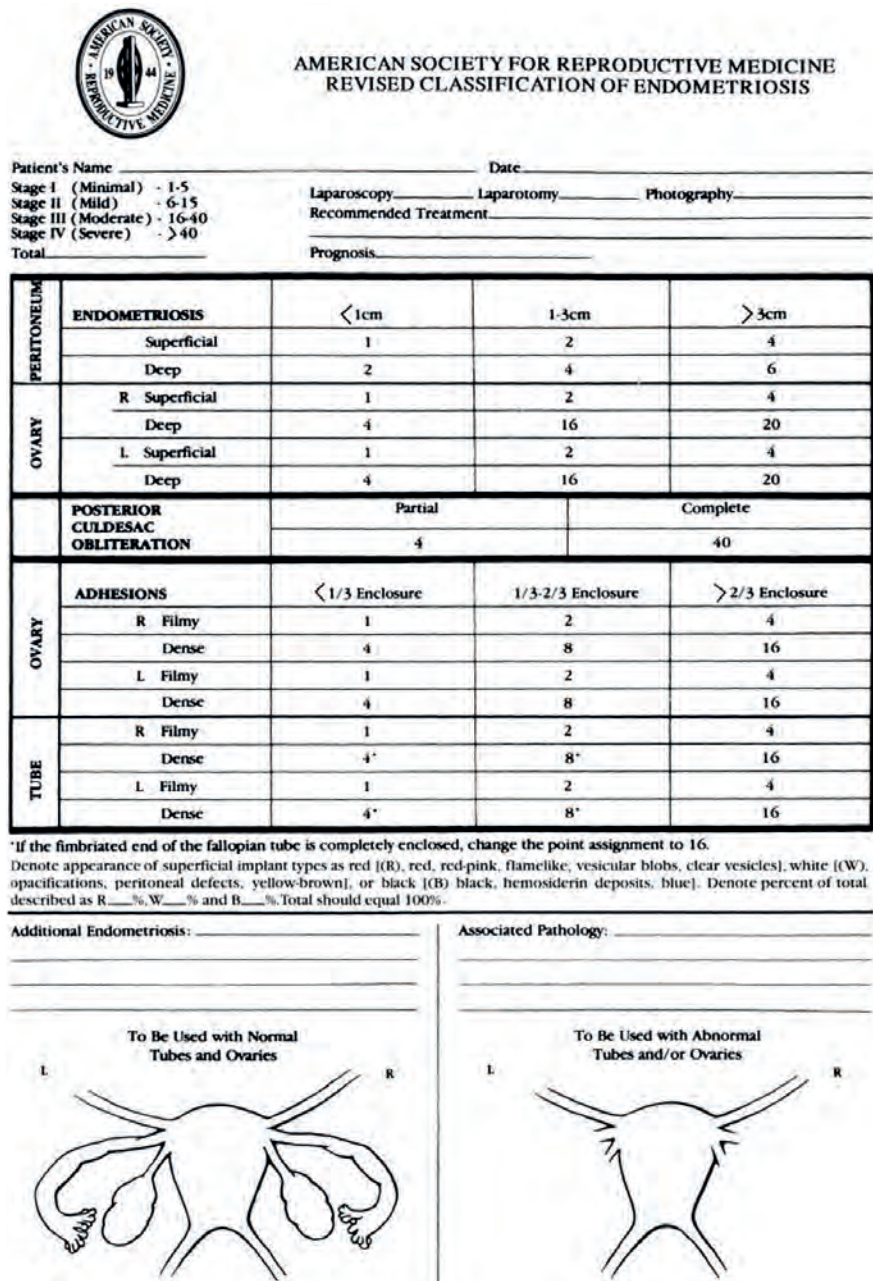
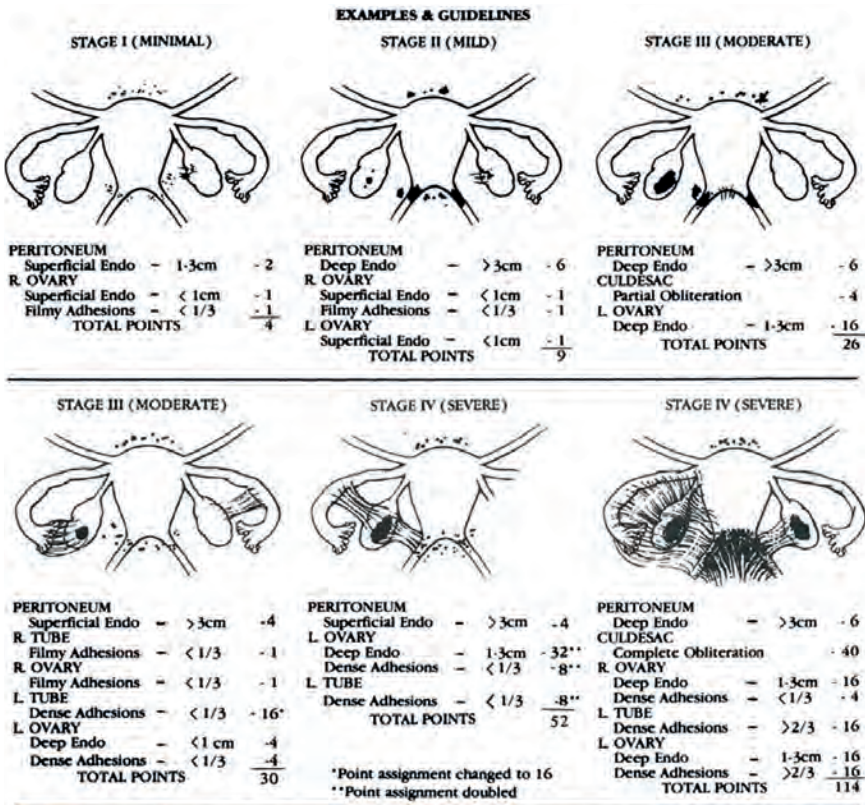


Fig. 1.50 The rASRM classification system.<sup>3</sup>



A major deficiency of the rASRM classification system lies in the fact that only the most distinct finding detected in a given area is reflected by the points that are scored in a specific category. For example, if superficial endometriotic lesions have been confirmed to extend over an area of more than 3 cm (four points) while showing an infiltration depth of more

than 3 cm (six points), then a total of 10 points is discarded, whereas a total of 6 points only, attributed to the most distinct finding (depth of infiltration), is scored. The same applies to the method of assessment with regard to ovaries and tubes (Fig. 1.51).



Determination of the stage or degree of endometrial involvement is based on a weighted point system. Distribution of points has been arbitrarily determined and may require further revision or refinement as knowledge of the disease increases.

To ensure complete evaluation, inspection of the pelvis in a clockwise or counterclockwise fashion is encouraged. Number, size and location of endometrial implants, plaques, endometriomas and/or adhesions are noted. For example, five separate 0.5cm superficial implants on the peritoneum (2.5 cm total) would be assigned 2 points. (The surface of the uterus should be considered peritoneum.) The severity of the endometriosis or adhesions should be assigned the highest score only for peritoneum, ovary, tube or culdesac. For example, a 4cm superficial and a 2cm deep implant of the peritoneum should be given a score of 6 (not 8). A 4cm

deep endometrioma of the ovary associated with more than 3cm of superficial disease should be scored 20 (not 24). In those patients with only one adnexa, points applied to disease of the remaining tube and ovary should be multiplied by two. \*\*Points assigned may be circled and totaled. Aggregation of points indicates stage of disease (minimal, mild, moderate, or severe).

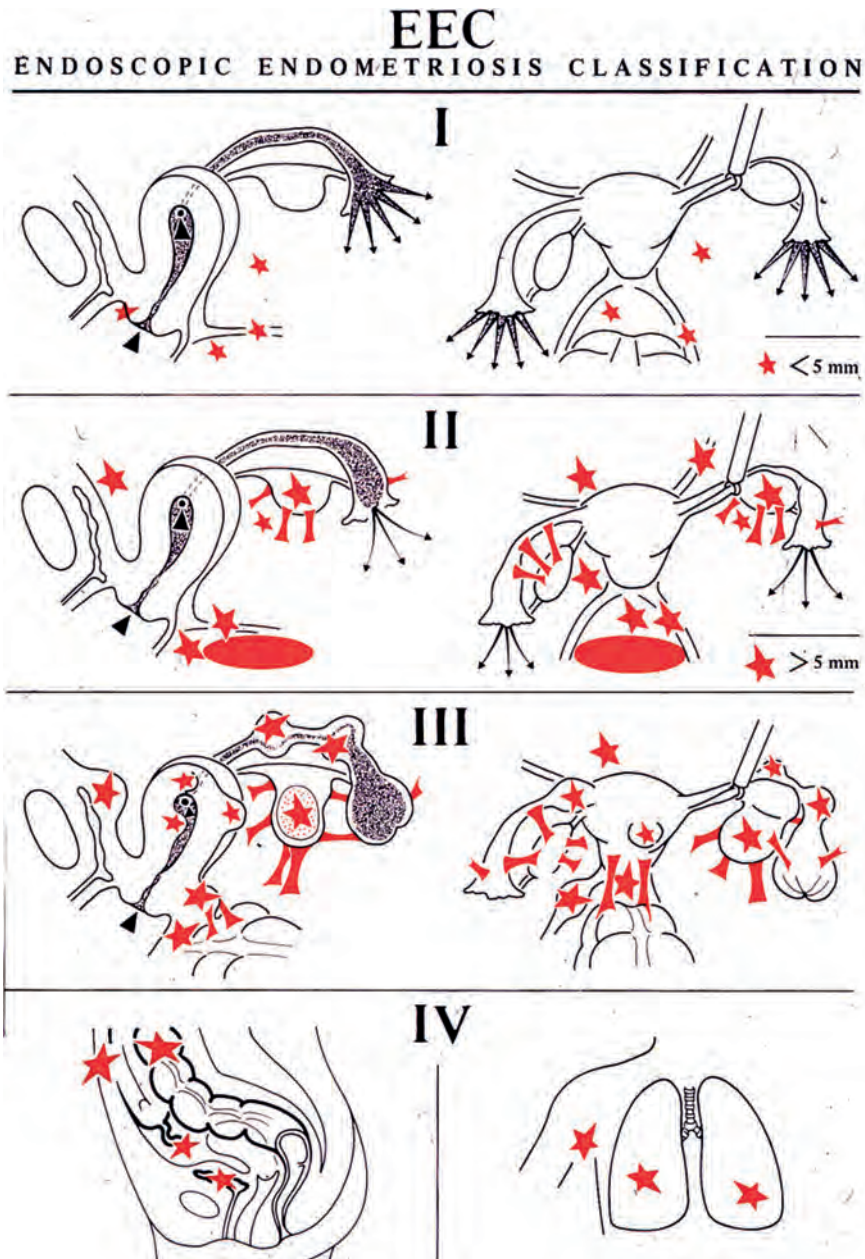
The presence of endometriosis of the bowel, urinary tract, fallopian tube, vagina, cervix, skin etc., should be documented under "additional endometriosis." Other pathology such as tubal occlusion, leiomyomata, uterine anomaly, etc., should be documented under "associated pathology." All pathology should be depicted as specifically as possible on the sketch of pelvic organs, and means of observation (laparoscopy or laparotomy) should be noted.

Fig. 1.51 Examples and guidelines of the rASRM Classification.<sup>3</sup>

### 1.6.3.2 Endoscopic Endometriosis Classification (EEC)

The EEC classification scheme was first established by *Mettler and Semm* in 1984 and is based on the endometriotic lesions visually detected at laparoscopy. The findings are graded into stages 1 – 4 (**stage 1**: lesions < 5 mm; **stage 2**:

lesions > 5 mm; **stage 3**: frozen pelvis endometriomas and extensive pelvic endometriosis; **stage 4**: distant lesions, endometriotic lesions outside of the genital tract as in bowel diaphragm, lungs etc. (Fig 1.52).<sup>7</sup>



**Fig. 1.52** EEC Classification according to *Mettler and Semm*, 1984.<sup>7</sup>

### 1.6.3.3 Enzian Classification

The term 'Enzian' is not an acronym as one might be tempted to presume, but rather the name of a distilled alcoholic beverage of Alpine provenance that is produced using gentian root. The same name was chosen to designate a hotel situated near lake Weissensee at Neusach/Austria, where the classification scheme was developed on the occasion of an

expert conference.<sup>8</sup> The aim of the Enzian classification is to establish a reproducible record of the location of deeply infiltrating endometriosis. For this purpose, the lower pelvis is divided into the following three compartments, A, B and C (Fig. 1.53):

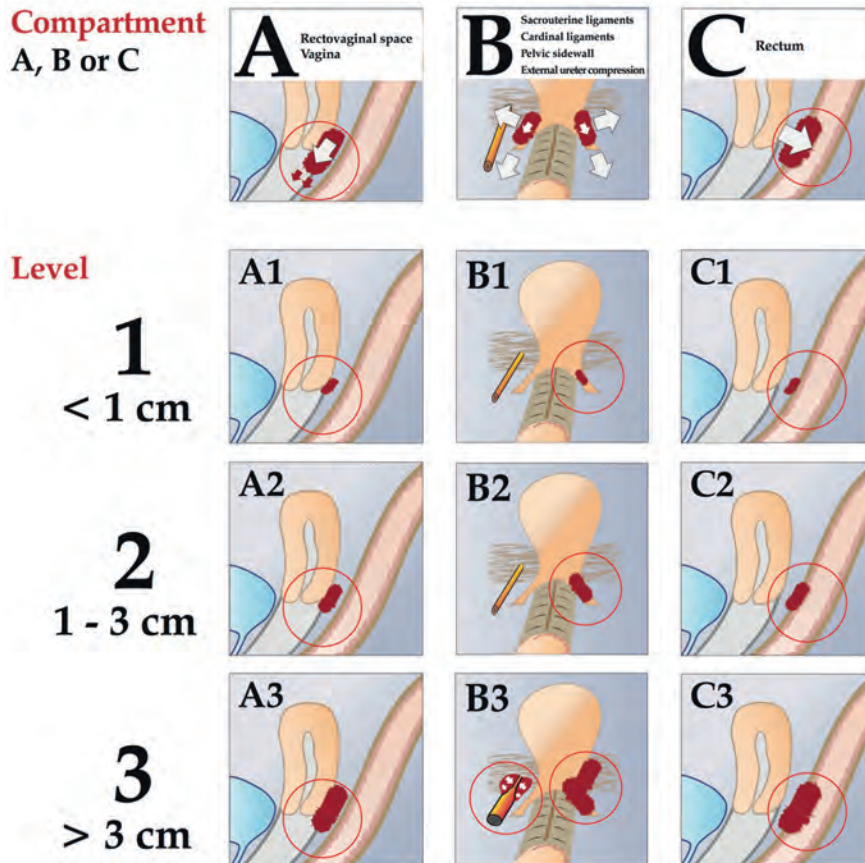
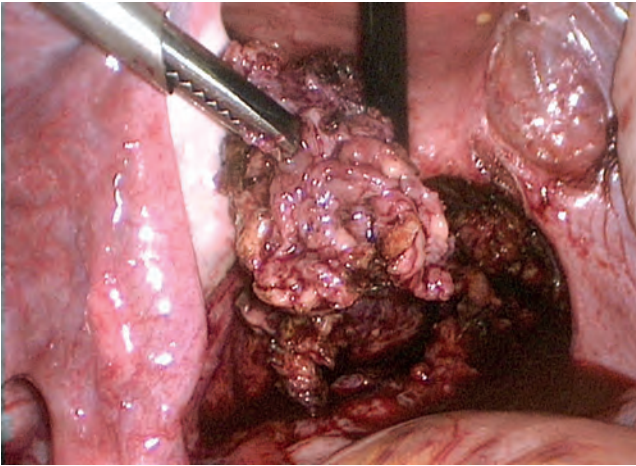
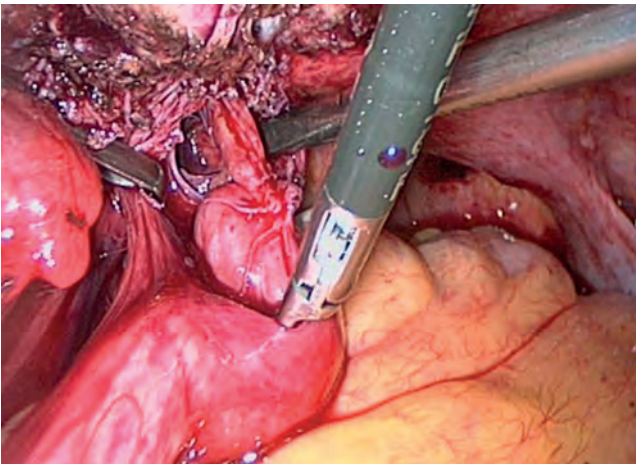


Fig. 1.53 ENZIAN Classification – Compartments A–C.<sup>8</sup>

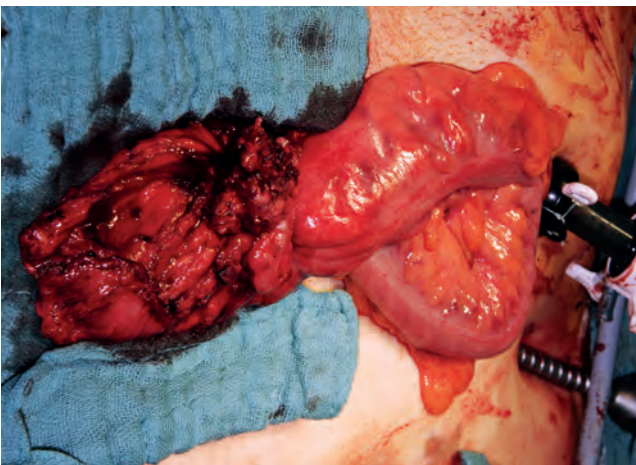




**Fig. 1.54** Endometriosis of the rectovaginal septum: ENZIAN A3.



**Fig. 1.55** Left-sided hydronephrosis resulting from endometriosis of the sacrouterine ligament: ENZIAN B3.



**Fig. 1.56** Endometriosis of the rectum: ENZIAN C2.

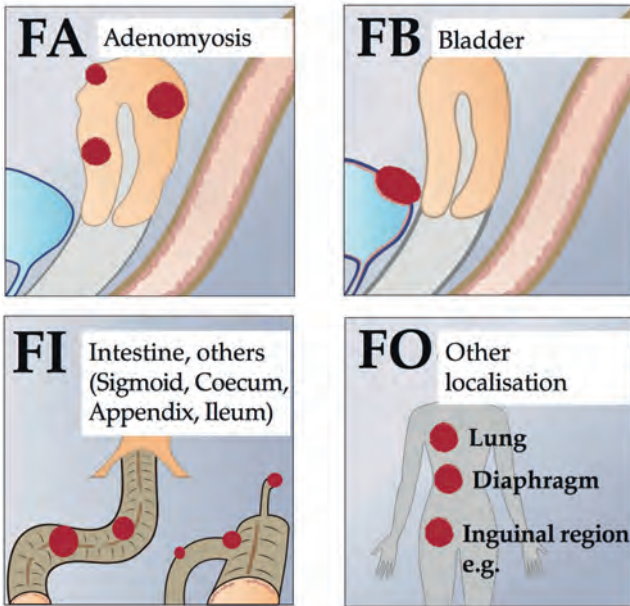
- **Compartment A** comprises the rectovaginal space including the longitudinal aspect extending towards the vagina (Fig. 1.54).
- **Compartment B** encompasses the sacrouterine ligament as far as the pelvic wall. In the presence of parametrial involvement and/or given obstructive (extrinsic) endometriotic encasement of the ureter, these findings are also assigned to compartment B (for infiltration of the ureter, see the use of suffix 'FU' as described below) (Fig. 1.55).
- **Compartment C** is assigned to denote rectal involvement only. In the presence of other types of bowel wall infiltration, the suffix 'FI' is used, as described below (Fig. 1.56).

In the documentation, taken down for each compartment affected by disease, severity is graded by a number that is added to describe the extent of endometriotic spread (termed 'level' in Fig. 1.53). A standardized description of the extent of disease is used for all three compartments (corresponding to the notation commonly used for histologic findings):

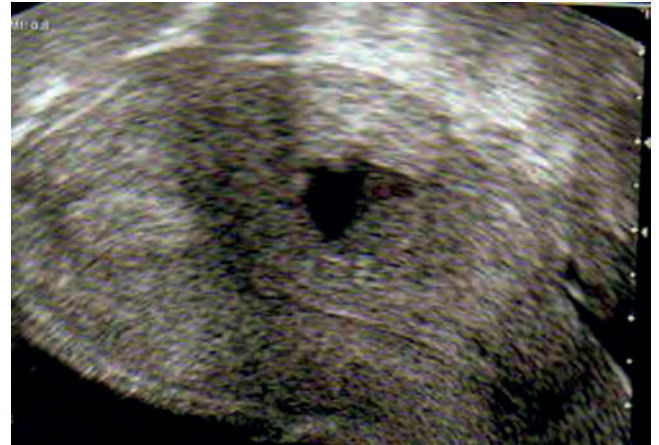
- Level 1: 1–9 mm
- Level 2: 10–29 mm
- Level 3:  $\geq$  30 mm

Since deeply infiltrating endometriosis is also observed outside the lesser pelvis, additional descriptions can be included (Fig. 1.57), however these may only indicate the site of the lesion, leaving out further details related to size.

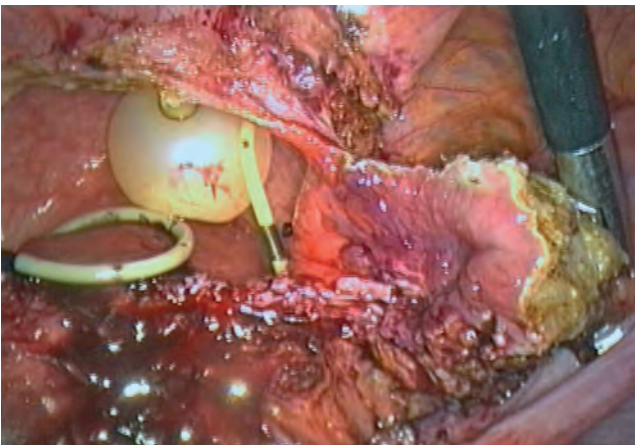
- **FA:** adenomyosis (Fig. 1.58).
- **FB:** deep infiltration of the bladder wall (Fig. 1.59).
- **FU:** infiltration of the ureteral wall = intrinsic (extrinsic = compartment B) (Fig. 1.60).
- **FO:** other locations (lung, diaphragm, inguinal region) (Figs. 1.61, 1.62).



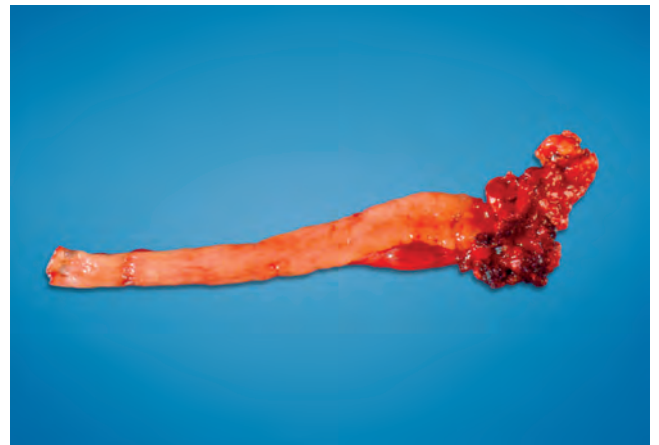**Fig. 1.57** The suffixes FA, FA, FI and FO are part of the ENZIAN classification scheme addressing the sites of endometriotic implants detected outside the lesser pelvis.<sup>8</sup>



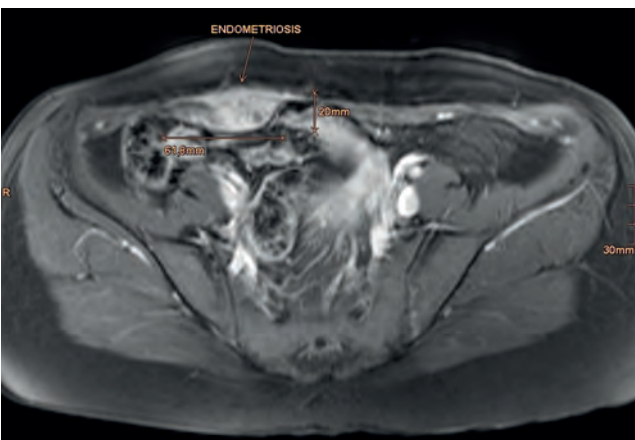**Fig. 1.58** Sonographic appearance of adenomyosis: ENZIAN FA.



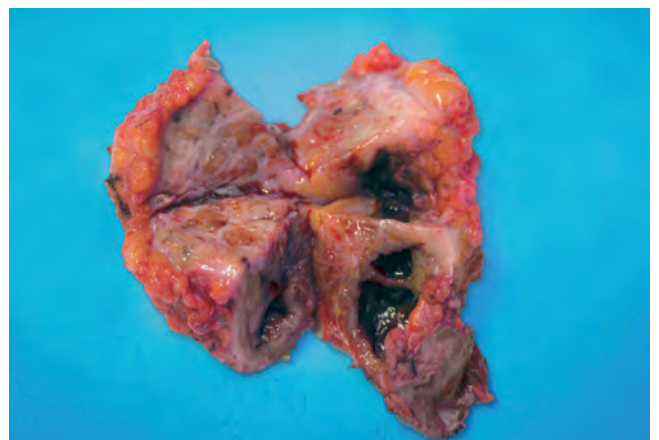**Fig. 1.59** Endometriosis of the bladder: ENZIAN FB.



**Fig. 1.60** Ureteric infiltration: ENZIAN FU, describing involvement of rectum, appendix, and ileum. Image of operative specimen with permission of Erlangen University Hospital, Dept. of Gynecology and Obstetrics, Germany.



**Fig. 1.61** Axial MRT scan showing endometriosis of the abdominal wall: ENZIAN FO.



**Fig. 1.62** Operative specimen demonstrating endometriosis of the abdominal wall: ENZIAN FO.



### 1.6.4 Endometriosis Fertility Index (EFI)

Published in 2010, the EFI is used to predict the likelihood of pregnancy in women who have undergone surgery for endometriosis.<sup>1</sup> It refers only to the probability of natural pregnancy and is not predictive of pregnancy involving in vitro fertilization (IVF) and intracytoplasmic sperm injection (ICSI). It is based on the a priori assumption that sperm and oocytes are functioning normally, so that natural pregnancy is a realistic option. Confounding factors related to IVF and ICSI cannot be included in the EFI score (Fig. 1.63). Nor does it take into account any endocrinological factors such as the presence of ovulation. The EFI represents a summation of two types of contributing factors that are related to surgery on the one hand, and medical history on the other. Variable parameters related to medical history are reflected in the age of the patient (up to age 35, 36–39, and 40 or older), duration of infertility (≤ 3 years or > 3 years), and prior history of pregnancy (yes or no). The surgical variables are addressed by a ‘least function score,’ that individually evaluates bilateral functional competency of fallopian tubes,

fimbria, and ovaries determined upon completion of surgery by a detailed description of relevant anatomical features such as residual ovarian function with normal or almost normal ovarian size and minimal or mild injury to the ovarian serosa. Functional competency is subdivided into normal, mild dysfunction, moderate dysfunction, severe dysfunction, and loss of function. Classification into subcategories defining the functional competency of the patient’s adnexae is subject to a detailed and precise presentation of findings.

The rASRM score is then added to the outcome of assessment obtained by use of the EFI. The total number of points scored in this way is intended to reflect the patient’s probability of giving birth to a child through natural pregnancy. The outcome can be presented in a graph that shows the estimated cumulative percentage of women pregnant over a period of 3 years – after surgery for endometriosis – in relation to the individual EFI score results. The cumulative pregnancy rates range from 10% to around 80% after 36 months.<sup>1</sup>

## Endometriosis Fertility Index (EFI) Surgery Form

### Least Function (LF) Score at Conclusion of Surgery

Score	Description	Left	Right
4	= Normal	<input type="checkbox"/>	<input type="checkbox"/>
3	= Mild Dysfunction	<input type="checkbox"/>	<input type="checkbox"/>
2	= Moderate Dysfunction	<input type="checkbox"/>	<input type="checkbox"/>
1	= Severe Dysfunction	<input type="checkbox"/>	<input type="checkbox"/>
0	= Absent or Nonfunctional	<input type="checkbox"/>	<input type="checkbox"/>

To calculate the LF score, add together the lowest score for the left side and the lowest score for the right side. If an ovary is absent on one side, the LF score is obtained by doubling the lowest score on the side with the ovary.

Lowest Score	<input type="checkbox"/>	+	<input type="checkbox"/>	=	<input type="text"/>
	Left		Right		LF Score

### Endometriosis Fertility Index (EFI)

Historical Factors			Surgical Factors		
Factor	Description	Points	Factor	Description	Points
Age	If age is ≤ 35 years	2	LF Score	If LF Score = 7 to 8 (high score)	3
	If age is 36 to 39 years	1		If LF Score = 4 to 6 (moderate score)	2
	If age is ≥ 40 years	0		If LF Score = 1 to 3 (low score)	0
Years Infertile	If years infertile is ≤ 3	2	AFS Endometriosis Score	If AFS Endometriosis Lesion Score is < 16	1
	If years infertile is > 3	0		If AFS Endometriosis Lesion Score is ≥ 16	0
Prior Pregnancy	If there is a history of a prior pregnancy	1	AFS Total Score	If AFS total score is < 71	1
	If there is no history of prior pregnancy	0		If AFS total score is ≥ 71	0
<b>Total Historical Factors</b>			<b>Total Surgical Factors</b>		
EFI = TOTAL HISTORICAL FACTORS + TOTAL SURGICAL FACTORS: <input type="text"/> + <input type="text"/> = <input type="text"/>			Historical      Surgical      EFI Score		

### Estimated Percentage of Pregnancies by EFI Score

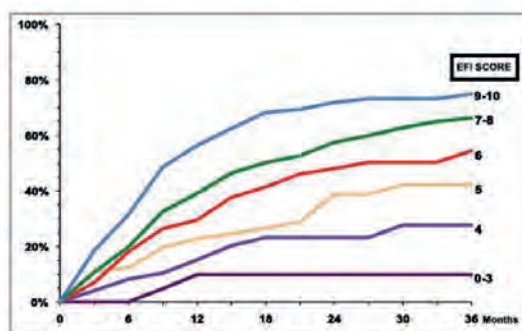


Fig. 1.63 EFI Score.<sup>1</sup>



The validity of the EFI was investigated in a retrospective study published in 2013. The authors were able to reproduce the correlation between the EFI and the rate of actual pregnancies.<sup>9</sup> Apart from other issues, the study criticized the inclusion of dependent parameters such as the rASRM in the EFI.<sup>9</sup> In another study in which the EFI was compared with the rASRM, it was found that only the EFI was predictive for pregnancy, not the rASRM,<sup>10</sup> indicating the value of the EFI for predicting spontaneous pregnancy after surgery for endometriosis.

As a matter of course, the EFI cannot be used universally and has its own deficiencies, as well as a certain element of subjectivity in the assessment process. However, it is the only tool available for predicting pregnancy following surgery for endometriosis.

### 1.6.5 Discussion

The main issue associated with any type of classification is the purpose for which it was designed. While the rASRM and EEC classifications are geared toward establishing the severity of endometriotic disease, the aim of the Enzian classification is to record deeply infiltrating endometriotic involvement in a reproducible way. Each of the classification systems, when applied on its own, is inadequate for describing endometriosis – particularly deeply infiltrating endometriosis. The Enzian system should be regarded as a complementary scheme used in addition to the rASRM, as there is no overlap between the two classifications.<sup>6</sup> Very severe symptoms can often lead to a low rASRM score in the assessment, but the extent of symptoms does correlate with the Enzian score.<sup>5</sup> In addition, there is a direct correlation between the Enzian score and the operating time required.<sup>4</sup> This correlation can be used for the purpose of surgical planning on the basis of a preoperatively established clinical score ('cEnzian'). The EFI has been shown to be very useful in improving counseling on the individual fertility prognosis of patients who already underwent endometriosis surgery. However, it does not provide any information about the potential success of attempted IVF/ICSI. A comprehensive diagnostic workup (sperm quality, endocrinology findings) and close interdisciplinary collaboration between surgeons and reproductive medicine specialists is mandatory. In comparison with the rASRM, the EFI has been shown to be superior in that it allows to predict a patient's natural fertility potential after surgery for endometriosis.<sup>10</sup>

In summary, it can be stated that an optimal classification for endometriosis is not yet available. Further aspects, such as intensity of pain, infertility, primary findings and recurrent findings are not included in any of the classifications discussed above.

### 1.6.6 References

1. ADAMSON GD, PASTA DJ. Endometriosis fertility index: the new, validated endometriosis staging system. *Fertil Steril* 2010;94(5):1609–15. doi:10.1016/j.fertnstert.2009.09.035.
2. ALBRECHT A. Die Endometriose. In: Seitz L, Amreich AJ, editors. *Biologie und Pathologie des Weibes*. vol. 4: Gynäkologie I. Berlin: Urban & Schwarzenberg; 1955. p. 190–289.
3. ASRM. Revised ASRM Classification of Endometriosis. 1996. *Fertil Steril* 1997;67(5):817-21
4. HAAS D, CHVATAL R, HABELSBERGER A, SCHIMETTA W, WAYAND W, SHAMIYEH A, OPPELT P. Preoperative planning of surgery for deeply infiltrating endometriosis using the ENZIAN classification. *Eur J Obstet Gynecol Reprod Biol* 2013;166(1): 99–103. doi:10.1016/j.ejogrb.2012.10.012.
5. HAAS D, OPPELT P, SHEBL O, SHAMIYEH A, SCHIMETTA W, MAYER R. Enzian classification: does it correlate with clinical symptoms and the rASRM score? *Acta Obstet Gynecol Scand* 2013;92(5):562–6. doi:10.1111/aogs.12118.
6. HAAS D, WURM P, SHAMIYEH A, SHEBL O, CHVATAL R, OPPELT P. Efficacy of the revised Enzian classification: a retrospective analysis. Does the revised Enzian classification solve the problem of duplicate classification in rASRM and Enzian? *Arch Gynecol Obstet* 2013;287(5):941–5. doi:10.1007/s00404-012-2647-1.
7. METTLER L. Diagnostik und Therapie der Endometriose. *Euromed* 1984;5:234–40.
8. SEF (STIFTUNG ENDOMETRIOSEFORSCHUNG). Enzian 2012: Klassifikation der tief infiltrierenden Endometriose [Internet]. Westerstede, Germany, Stiftung Endometriose Forschung; 2012; Available from: [www.endometriose-sef.de/dateien/ENZIAN\\_2013\\_web.pdf](http://www.endometriose-sef.de/dateien/ENZIAN_2013_web.pdf). Accessed 2016 Feb 17.
9. TOMASSETTI C, GEYSENBERGH B, MEULEMAN C, TIMMERMAN D, FIEUWS S, D'HOOOGHE T. External validation of the endometriosis fertility index (EFI) staging system for predicting non-ART pregnancy after endometriosis surgery. *Hum Reprod* 2013;28(5):1280–8. doi:10.1093/humrep/det017.
10. ZENG C, XU JN, ZHOU Y, ZHOU YF, ZHU SN, XUE Q. Reproductive performance after surgery for endometriosis: predictive value of the revised American Fertility Society classification and the endometriosis fertility index. *Gynecol Obstet Invest* 2014;77(3):180–5. doi:10.1159/000358390.

## 1.7

## The ENZIAN Classification of Deep Infiltrating Endometriosis

Jörg Keckstein<sup>a</sup>**1.7.1 Introduction**

Endometriosis is a condition with a highly variable clinical presentation. To date, relentless efforts have been made to fully describe and classify<sup>8</sup> the various manifestations of the condition.<sup>3,6,9,12,30</sup> The traditional classification systems of endometriosis, developed by several professional organizations worldwide, have been based on lesion appearance, pelvic adhesions, and anatomic location of disease. The primary objective of subdividing endometriosis into different grades of severity is to determine the extent of disease, and secondly, to elicit a correlation between stage of disease and symptoms, and especially, to enable an assessment of the patient's individual prospects for giving birth to a child.

In 1979,<sup>37</sup> the *American Fertility Society (AFS)* published a classification scheme that was revised in 1985.<sup>7</sup>

In 1995, the AFS was renamed the *American Society for Reproductive Medicine (ASRM)*. The subsequent revision was issued in 1997 and has become the most frequently used classification system both in clinical practice and international literature.<sup>8</sup> The corresponding staging process is based on either diagnostic laparoscopy or laparotomy. The classification scheme is used to evaluate the intraperitoneal distribution of disease (peritoneum, ovary). The main emphasis of the current rASRM classification is on the correlation between the cumulative score of assigned points and a patient's fertility potential. The classification system also takes into account the extent of adhesions, which is a major contributing factor to a patient's fertility prospects. However, one should bear in mind that adhesions do not only form as a result of endometriosis and they can also conceal deeper foci.

The rASRM score is particularly useful in the treatment of infertile patients.

Endometriosis is a disease which invades and proliferates on the affected tissue structures and organs, causing inflammation and destruction. For many patients, the disease is associated with severe pain, as well as disturbed function of the organs involved, and apart from that, it manifests with clinical, physical and psychological sequelae that can severely compromise a patient's quality of life.

While the correlations between stage of disease and symptoms are used to evaluate the efficacy of therapeutic interventions, all of the above classification schemes do not allow to take into account pelvic pain, response to medications, disease recurrence, risks of disease sequelae, quality of life measures, and other target issues similarly important to women and health care providers because they are instrumental in guiding the decision-making related to therapeutic options and prognosis.<sup>25</sup>

**1.7.1.1 Various Forms of Endometriosis Associated With Various Symptoms**

Endometriosis shows different clinical presentations depending on its localisation. The rASRM classification scheme differentiates between peritoneal endometriosis, ovarian endometriosis and deep infiltrating endometriosis.

**1.7.2 What is DIE?**

Deep infiltrating endometriosis (DIE) is a variable, poorly-defined term, which is why it cannot be used on a reproducible basis by clinicians and researchers who must rely on precise criteria and terminology.

While deep endometriosis was originally described by *Reich et al.*<sup>36</sup> in 1991 as 'deep fibrotic nodules', the scientific concept was updated and refined describing deep endometriotic lesions as being those infiltrating either from the peritoneal surface<sup>32</sup> or emanating from a deeper origin as 'adenomyosis externa'.<sup>31</sup>

The most widely accepted definitions of DIE are simply based on the (arbitrary) depth of extension beneath the peritoneal surface. For practical purposes, this definition covers almost all lesions that either involve or cause anatomical distortion of vital structures (bowel, ureters, and bladder), as well as rectovaginal lesions. However, a viable definition of DIE should be complemented by a surgical description that addresses anatomical functional deficiencies in addition to the depth of extension beneath the peritoneal surface. Hence, the statement – based on what was criticized as being weak evidence – holds true, that 'deep endometriosis should be defined as lesions extending deeper than 5 mm under the peritoneal surface'.

<sup>a</sup> | Professor, MD; Head of Department of Gynecology and Obstetrics, Certified Clinical-Scientific Level III Center for Endometriosis Care, Certified Breast Care Center, State Hospital of Villach, Carinthia, Austria

**Corresponding author:**

Prof. Dr. med. **Jörg Keckstein**

Primarius, Abteilung für Gynäkologie und Geburtshilfe  
Zertifiziertes klinisch-wissenschaftliches Endometriosezentrum  
Zertifiziertes Brustzentrum  
Landeskrankenhaus Villach  
Nikolaigasse 43  
9500 Villach, Austria  
E-mail: joerg.keckstein@lkh-vil.or.at  
www.endometriosezentrum-villach.at  
www.lkh-vil.or.at

In the literature, the anatomical sites are specified in different ways. In particular, when endometriotic invasion is revealed to extend deeply into the pelvis (pouch of Douglas, sacrouterine ligaments, cardinal ligaments, parametria, pararectal fossae, bowel infiltration, bladder infiltration, ureteric involvement, pelvic wall involvement) such findings are identified as DIE and regarded as underlying cause of the patient's severe symptoms that account for a dramatic decline in quality of life.

Major advancements in the field of minimally invasive surgery have broadened the scope of viable treatment options in recent decades and made it possible that even severe forms of endometriosis are now amenable to adequate resection, in turn enabling us to make further improvements in the quality of life for our patients. Given an adequate level of experience and expertise on the part of the surgeon, even severe manifestations such as extragenital endometriosis can be adequately resected.<sup>15,16,29</sup>

In patients with a confirmed diagnosis of endometriotic involvement of the bowel, bladder and ureter, the need for a multidisciplinary approach may arise.

However, each therapy involves the risk of side effects and complications. Even though removal of a small nodule in the pouch of Douglas may be a relatively straightforward task, the well-adapted surgical treatment of extensive endometriosis in the pouch of Douglas spreading to vagina, uterus and bowel can pose a significant challenge for the surgeon.

Occasionally, we are confronted with the paradox that a small nodule is associated with concomitant symptoms of severe pain, while on the other hand, large bowel nodules are seen in a patient with only minor symptoms.

Foci of endometriosis in the extraperitoneal space, extragenital endometrial foci (bowel, bladder, ureter, etc.) and extensive adenomyosis, however, are not adequately dealt with by the rASRM scoring system which is frequently used on a routine basis.<sup>8</sup>

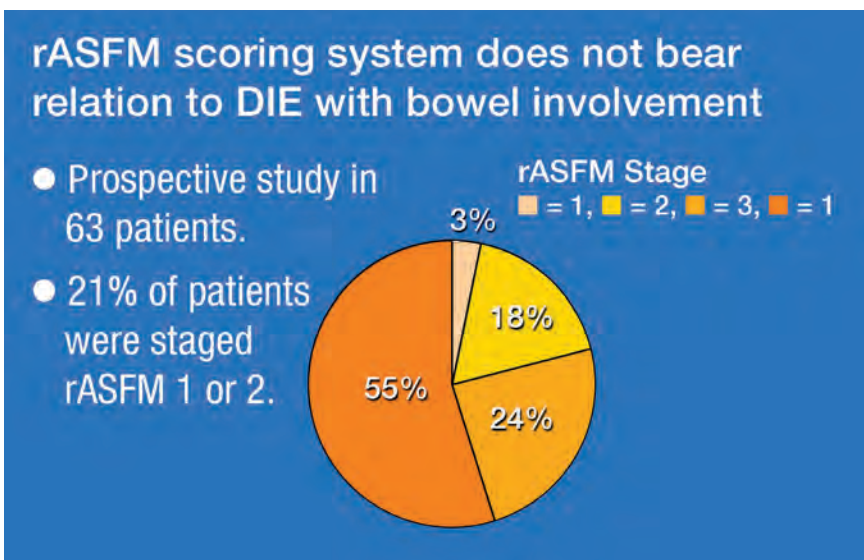
In a study based on 63 patients (State Hospital of Villach, Austria) with DIE including recto-sigmoid endometriosis, 21 % were found to have only stage 1 or 2 according to the revised ASFM scoring system (Fig. 1.64).<sup>41</sup>

Haas *et al.* (2013) confirmed these data in 160 patients with DIE.<sup>22</sup>

Owing to lack of knowledge about the extent of disease, which unavoidably gives rise to inadequate staging, both patient and clinician are faced with enormous consequences:

- Foci of endometriosis which are not revealed during laparoscopy lead to the diagnosis of a lower stage of disease.
- Hence, the outcome of the therapeutic intervention is either wrong or inadequate.
- The value of scientific studies, discussions and conclusions is called into question as a result of inadequate staging.

It is therefore of utmost importance that the current limits of our knowledge of disease be expanded through in-depth scholarly work in order to yield an improved appreciation of the anatomical changes and pathological structures that play a major role in the multifactorial etiology and pathogenesis of endometriosis.



**Fig. 1.64** Staging of endometriosis using the rASFM scoring system in 63 patients with DIE and bowel involvement (Wustlich, M. 2002).<sup>41</sup>



The need for an alternative or additional classification system, particularly in regard to DIE, is a topic currently being debated by experienced surgeons.<sup>1,2,4,5,10,11,13,17,19,35</sup>

### 1.7.3 The ENZIAN Classification System

The motives and rationale that prompted the inception of a new classification system specifically adapted to deep infiltrating endometriosis was the need to improve description of DIE and to adequately evaluate the outcome of a therapeutic intervention. Its foundations were laid in 2002 by members of the German *Stiftung Endometriose Forschung (Endometriosis Research Foundation, Westerstede, Germany)*. The need to take the initiative emerged partly as a result of controversial discussions in the literature and at various congresses, and was centered on the definition and implications of DIE, as well as on the most suitable treatment option to be offered to the patient.

Particularly in regard to the extragenital form of DIE, with involvement of the bowel, ureter and other pelvic structures, it is imperative that adequate information is obtained in the preoperative, intraoperative and postoperative phases of care. The following is a survey of issues that are of great relevance to medical experts involved in the treatment of DIE:

- Diagnostic confirmation of DIE by means of palpation, ultrasound, MR and CT imaging.
- Follow-up investigation of findings.
- Correlation between DIE and symptoms.
- Decision-making related to the most suitable therapeutic regimen.
- Decision-making related to the surgical technique to be adopted.
- Preoperative planning and completion of the surgical procedure.
- DIE and surgical complications.
- Post-operative follow up care.

The ENZIAN classification scheme was developed by a working group of the SEF in 2002 as part of the first 'Weissensee Meeting' in Carinthia, Austria.

#### SEF Members at the First 'Weissensee Meeting'

Initiators: Prof. J. Keckstein, Prof. K.-W. Schweppe

P.D. Dr. M. Sillem, Prof. Dr. R. Greb, Dr. R. Mangold, Dr. N. Reeka, Dr. O. Richter, Prof. V. Terruhn, Prof. H.-R. Tinneberg, Prof. U. Ulrich, Prof. M. Possover, Prof. K. Neis, Prof. A. E. Schindler, P.D. Dr. O. Buchweitz, Dr. F. Tuttlies.

The term ENZIAN derives from the name of a hotel where the first meeting of SEF members was held (Hotel Enzian, Neusach, Weissensee, Austria) in 2002.

The initial version of the ENZIAN classification scheme was published in 2003 by *Keckstein et al.*<sup>27–29</sup> and was complemented in 2005 by *Tuttlies and Keckstein*.<sup>38</sup> It was revised by the SEF research group in 2010, and again in 2011,

on the occasion of annual 'Weissensee Meetings'.<sup>26</sup> The latter revision was designed to reduce complexity and thus gain a wider acceptance and also help resolve unintended partial overlap with the rASRM classification scheme.<sup>23,27</sup>

The guidelines of the German, Swiss, Czech and Austrian Societies for Obstetrics and Gynecology recommend the use of the ENZIAN classification system (*Ulrich et al., 2014*).<sup>39</sup> The certification process for centres of excellence for endometriosis in these countries stipulates that the ENZIAN scheme be used in addition to the current rASRM staging system.<sup>18</sup>

In current clinical practice, use of the ENZIAN scheme is gaining more widespread acceptance not only among surgeons but also among those professionals involved in the assessment and diagnosis of endometriosis.<sup>14,20,21,23,24,34,40</sup>

#### 1.7.3.1 Scientific Basis of the ENZIAN Classification

Designed to complement the rASRM staging system, the added use of the ENZIAN classification enables a more accurate description of severe endometriosis and allows to encompass all endometriotic lesions. Consistent with the underlying objectives, the ENZIAN classification is used to describe endometriotic involvement of retroperitoneal structures with deep endometriosis. Accordingly, it is intended to serve as a morphological-descriptive classification implemented in cases of deep endometriosis and endometriosis affecting other organs, including the cul-de-sac, vagina, cervico-uterine ligaments, bladder, ureter, bowel and uterus.

In order to fully assess the extent of disease intraoperatively, a complete exploration of all structures and organs is imperative.

In many cases, staging by means of diagnostic laparoscopy alone is inadequate, taking into account that endometriotic foci buried in extraperitoneal sites can be missed.

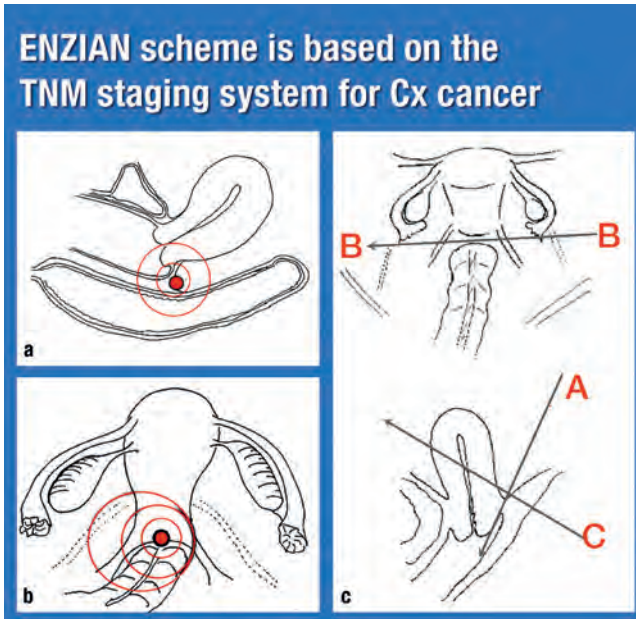
Therefore, exposure and, as required, excision of extraperitoneal structures may become necessary.

For various reasons, this is neither desired nor possible in every operation.

Imaging modalities such as ultrasound or MRI, have shown to be useful in demonstrating these structures and may be employed to facilitate adequate staging even in the setting of a diagnostic procedure.<sup>14</sup>

#### 1.7.3.2 ENZIAN Classification Based on the TNM Classification

Similarly to the TNM (tumour/node/metastasis) classification system familiar to those specialists frequently engaged in staging breast cancer and cervical cancer, organs such as bladder, ureter, bowel, vagina, uterus as well as cul-de-sac and uterine ligaments are included in the ENZIAN classification scheme (*Fig. 1.65*). The pelvis is divided into three compartments that emanate from the central pouch of Douglas. These are defined by the three axes of spread (**A**, **B**, **C**) of disease (*Fig. 1.66*).



**Fig. 1.65** The cul-de-sac as the centre of the pelvis (a, b). Three dimensions of the staging system.  
**A** = (craniocaudal) cul-de-sac, rectovaginal septum, vagina.  
**B** = (mediolateral) uterosacral lig., cardinal lig., pelvic side wall, extrinsic ureteric involvement  
**C** = (mediodorsal) rectum, rectosigmoid.

### ENZIAN 2012

Classification of Deep Infiltrating Endometriosis (according to the Endometriosis Research Foundation, SEF)

Compartment A, B or C	<b>A</b> Rectovaginal space Vagina	<b>B</b> Sacrotuberine ligaments Cardinal ligaments Pelvic sidewall External ureter compression	<b>C</b> Rectum
<b>Level</b>			
<b>1</b> < 1 cm	A1	B1	C1
<b>2</b> 1 - 3 cm	A2	B2	C2
<b>3</b> > 3 cm	A3	B3	C3

<b>F</b> Uterine and other extra-genital deep infiltrating endometriosis	<b>FA</b> Adenomyosis	<b>FB</b> Bladder	<b>FU</b> Ureter, intrinsic
	<b>FI</b> Intestine, others (Sigmoid, Coecum, Appendix, Ileum)	<b>FO</b> Other localisation	
		<ul style="list-style-type: none"> <li>● Lung</li> <li>● Diaphragm</li> <li>● Inguinal region e.g.</li> </ul>	

© Keckstein

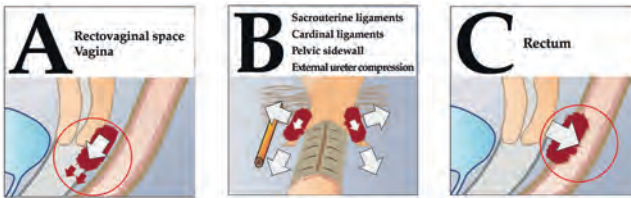
**Fig. 1.66** Graphical representation of the ENZIAN classification scheme as available via [http://www.endometriose-sef.de/dateien/ENZIAN\\_2013\\_web.pdf](http://www.endometriose-sef.de/dateien/ENZIAN_2013_web.pdf)

### 1.7.3.3 The Three Compartments A, B, and C

The ENZIAN classification comprises three axes or levels (Fig. 1.65) represented by the compartments **A**, **B**, and **C** (Fig. 1.67) to which findings, encountered in this area, can be assigned. The drawings shown in Figs. 1.65a–c (see previous page) illustrate the ENZIAN classification diagrammatically.

- **Compartment A:** the rectovaginal space and vagina;
- **Compartment B:** the uterosacral ligaments, cardinal ligaments, pelvic sidewall and extrinsic ureteric compression;
- **Compartment C:** the lower bowel (rectum and sigmoid colon).

#### Compartment A, B or C

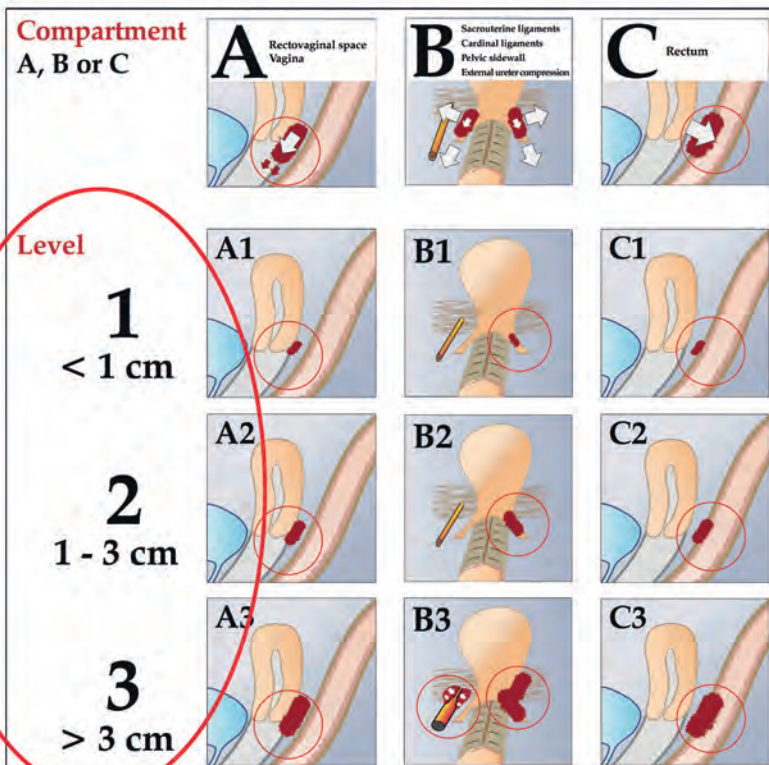


**Fig. 1.67** Pelvic compartments **A**, **B** and **C** of the ENZIAN classification scheme.

#### Grades of Severity

The **Grades of Severity**, assigned to each compartment (thus excluding apparently minor peritoneal lesions), are as follows (Fig. 1.68):

- Grade 1 invasion < 1 cm,
- Grade 2 invasion 1–3 cm,
- Grade 3 invasion > 3 cm.



**Fig. 1.68** Grading of lesions according to size.



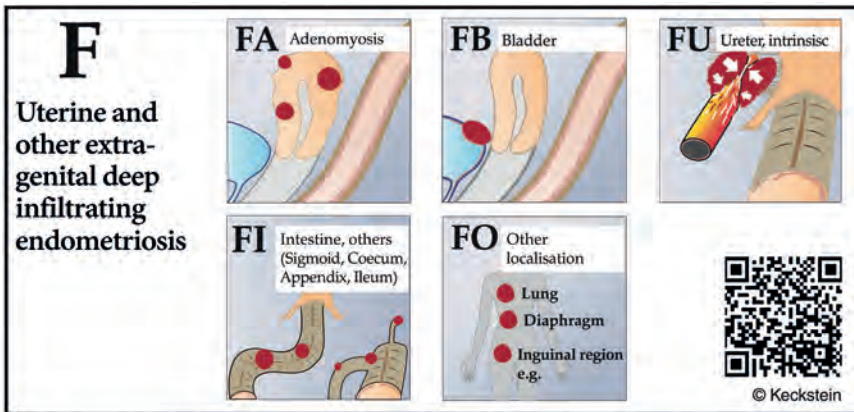
### ■ Organ Involvement and Other Types of Lesions

Deep infiltrating endometriosis extending beyond the lesser pelvis and deep invasion of the organs is stratified separately as shown below in Fig. 1.69:

Findings related to organ involvement and other types of lesions are tagged with the letter 'F'

- Adenomyosis (**FA**);
- Bladder involvement (**FB**);
- Intrinsic ureteric involvement (**FU**);
- Bowel disease (**FI**) cranial to the rectosigmoid junction (upper sigmoid, transverse colon, coecum, appendix, small bowel);
- Other locations (**FO**) such as abdominal wall or diaphragmatic endometriosis.

The prefix 'C' is used to denote a suspected lesion detected clinically by ways of diagnostic imaging, or as an intraoperative visual finding. Once a confirmed histological diagnosis of endometriosis has been established, the prefix 'C' is deleted and replaced by the term 'Enzian'. The letters 'A', 'B', 'U', 'I' or 'O' are used as a suffix that is added to the letter 'F' and denote the anatomical site (compartment) of the detected lesion, followed by a number that describes its size. The duplicated use of the same letter denotes that the assigned compartment is affected by bilateral disease.



**Fig. 1.69** Uterine and other types of extra-genital deep infiltrating endometriosis are tagged with the prefix **F** as determined by the localisation of the lesion.

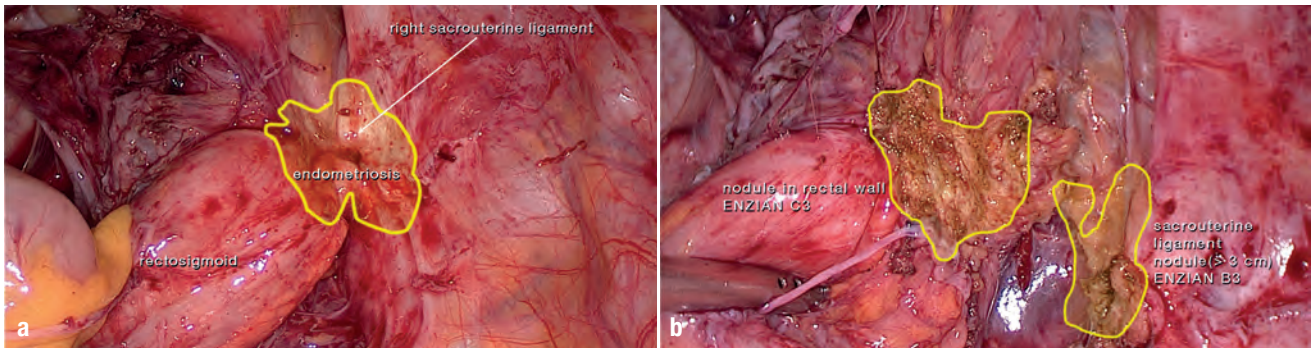
## 1.7.4 Case Histories

### 1.7.4.1 Case 1

The 29-year-old woman presented with severe symptoms of dysmenorrhoea, dyspareunia and dyschezia. The laparoscopic examination did not allow to visualize all of the anatomical sites affected by endometriosis. The rectosigmoid was attached to the posterior part of the sacrouterine ligament (Fig. 1.70b). The size of the endometriotic nodule seemed to be larger on palpation as compared to the laparoscopic finding. The preoperative workup demonstrated a deep nodule in the lateral rectal wall (> 3 cm) and another nodule located between

rectum and pelvic sidewall. Following dissection of the nodule performed in two halves, the extent of disease became visible (Fig. 1.70b). There was a deep infiltrating nodule in the rectum, > 3 cm, **ENZIAN C3** and another nodule was found to adhere to the pelvic sidewall, > 3 cm, **ENZIAN B3**. The entire extent of disease was revealed only by preoperative assessment, palpation and laparoscopic dissection.

Final score: **ENZIAN C3, B3**.

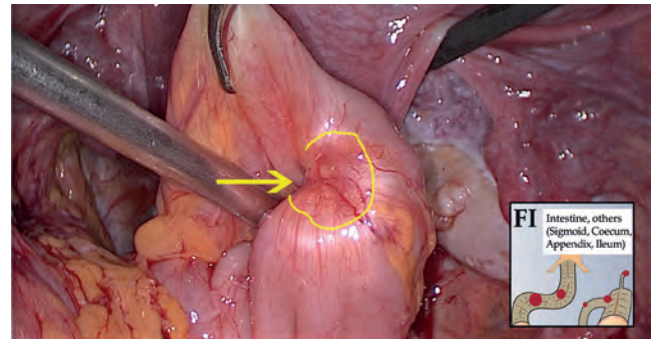


**Fig. 1.70a,b** Deep infiltrating endometriosis localized between the rectum and the right sacrouterine ligament. (a) Intraoperative view upon completion of endometriosis dissection. Final score: **ENZIAN B3, C3**. (b)

### 1.7.4.2 Case 2

The patient presented with extreme pelvic pain and lower abdominal cramping on the left side synchronous to the menstrual cycle. Colonoscopy revealed the presence of a stenosis in the upper sigmoid. The lower pelvis did not show any signs of intestinal endometriosis. Considering that the sigmoid loop lies in close proximity to the vagina, the endometriotic nodule was demonstrated by transvaginal sonography.

Final score: **ENZIAN FI**.

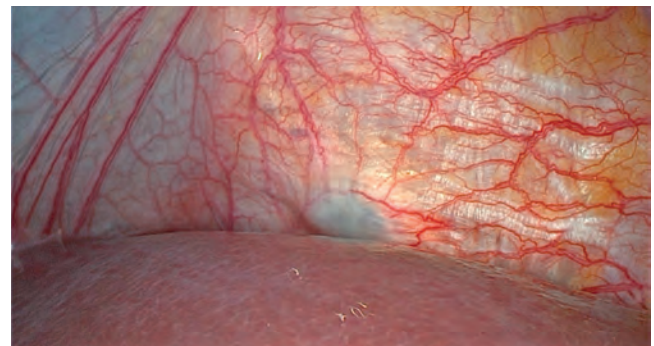

**Fig. 1.71** Endometriotic implants on the sigmoid. Final score: **ENZIAN FI**.

### 1.7.4.3 Case 3

The 35-year-old woman presented with chronic pain in the upper left abdomen close to the diaphragm. She suffered from periodical pain synchronous with inspiration. On laparoscopy, a nodule was revealed on the left diaphragm (Fig. 1.72).

Final outcome: **ENZIAN FO**.

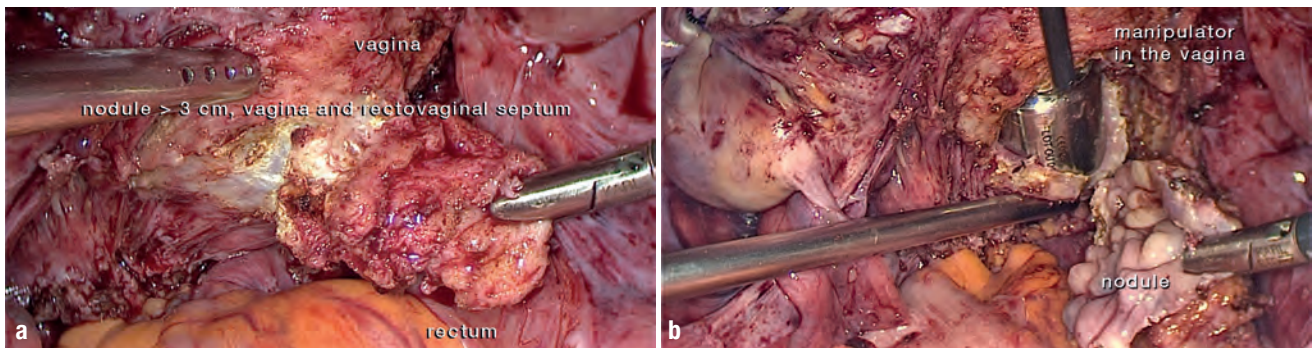


**Fig. 1.72** Laparoscopic aspect of endometriosis on the left diaphragm. Final score: **ENZIAN FO**.



## 1.7.4.4 Case 4

The 30-year-old woman suffered from deep infiltrating endometriosis in the cul de sac. The lesion was also noticeable during preoperative inspection of the posterior fornix. Transvaginal ultrasound revealed the presence of a nodule, > 4 cm in size, located in the vaginal fornix and in the space between vagina and rectum (rectovaginal septum). Involvement of the rectal wall was not demonstrable. Presence of the same nodule was confirmed on laparoscopy (Fig. 1.73) and was found to protrude from the rectovaginal septum. Integrity of the vagina was visually corroborated.



**Fig. 1.73a,b** Laparoscopic view of endometriosis in the cul de sac. (a) The intraoperative view taken after completion of dissection demonstrates the overall extent of the nodule (4 cm) spreading between the vagina and the rectovaginal septum. The rectum was not confirmed to be involved by disease. Final score: **ENZIAN A3** (b)

## 1.7.4.5 Case 5

The 30-year-old woman presented with hydronephrosis on the right side (Fig. 1.74).

She was found to have deep infiltrating endometriosis in the cardinal ligament (**ENZIAN B3**) on the right side and in the anterior rectal wall (**ENZIAN C3**).

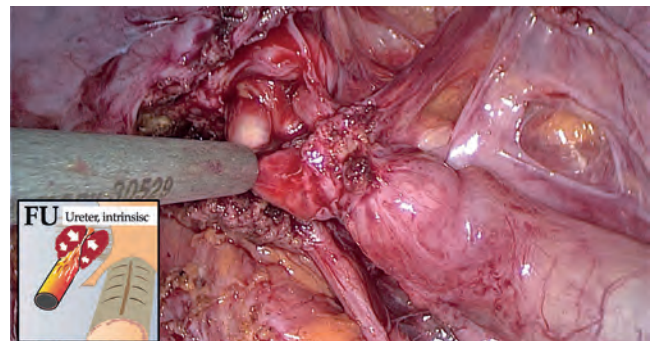
In the course of laparoscopic treatment, all of the fibrotic tissue detected in the cardinal ligament was removed. The nodule in the rectum was left behind due to lack of pain symptoms. The ureter was mobilized whereupon infiltration of the ureteral wall became visible. Segmental resection of the ureter was performed.

Final score: **ENZIAN B3, C3, FU** (intrinsic ureteral infiltration).

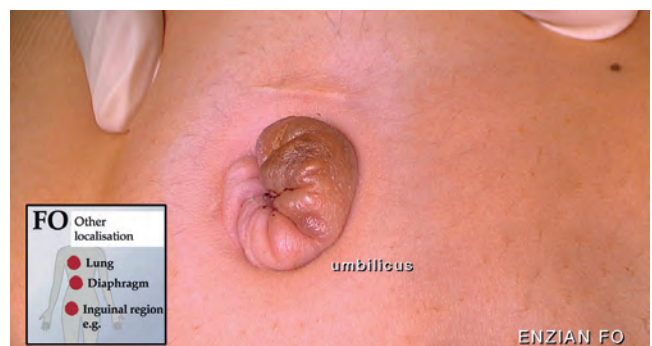## 1.7.4.6 Case 6

The 28-year-old patient presented with cyclic bleeding oozing out of the umbilicus (Fig. 1.75). The nodule was identified both by ultrasound and clinical examination. The finding was classified as deep infiltrating endometriosis outside of the pelvis.

Final score: **ENZIAN FO**.



**Fig. 1.74** Intrinsic endometriosis of the right ureter. Final score: **ENZIAN B3, C3, FU**.



**Fig. 1.75** Endometriosis of the umbilicus. Final score: **ENZIAN FO**.



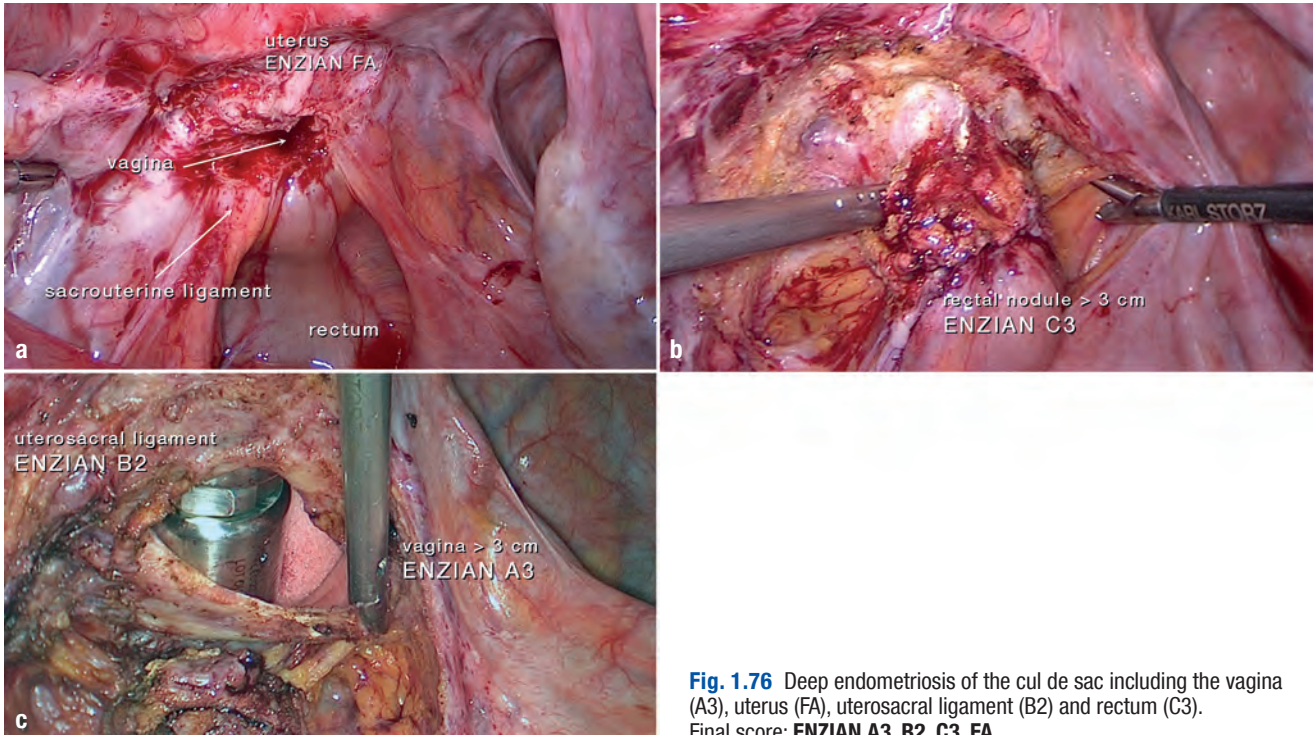
## 1.7.4.7 Case 7

The 38-year-old patient was diagnosed with deep infiltrating endometriosis of the cul de sac. As shown in Fig. 1.76a, distinct infiltration of the cul de sac, rectal anterior wall, rear part of the uterus and of the left sacrouterine ligament sacrouterinum was noticeable. Preoperative assessment also revealed the presence of a deep lesion in the vagina and in the anterior rectal wall, exhibiting a size of > 3 cm. In view of the size of the lesion, dissection was performed in two pieces. Fig. 1.76b shows the anterior rectal wall and a large endometriotic nodule of > 3 cm in size, that was found to invade the muscularis

(ENZIAN C3). Removal of the left uterosacral ligament has already been completed.

On the rear side of the uterus, an adenomyotic lesion was also dissected.

As shown on Fig. 1.76c, a fenestration to the vagina is noticeable after removal of the vaginal nodule (ENZIAN A3). Final score: **ENZIAN A3, B2, C3, FA.**



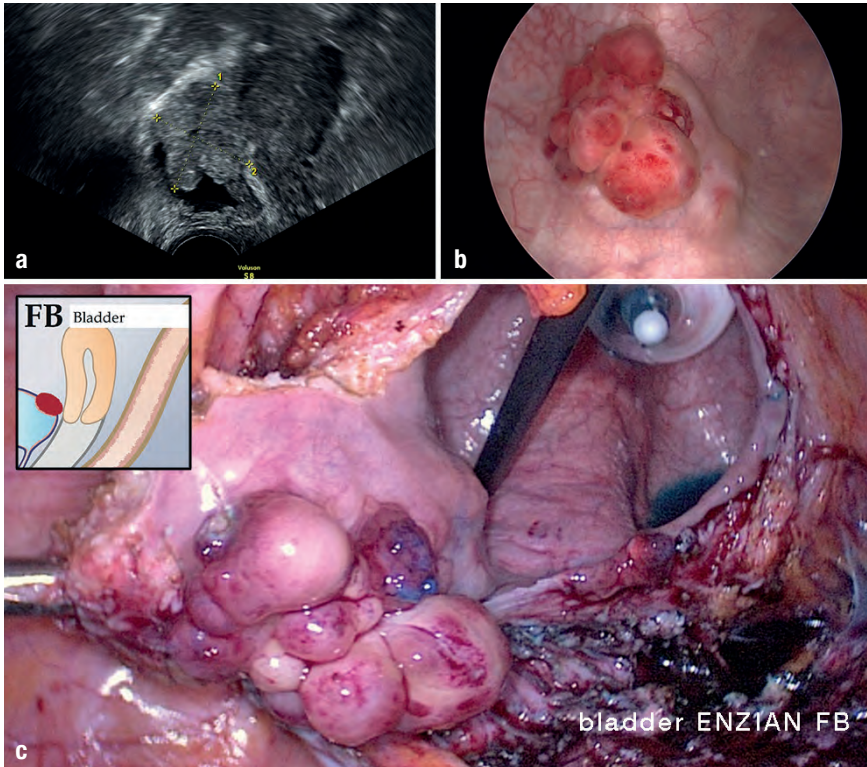
**Fig. 1.76** Deep endometriosis of the cul de sac including the vagina (A3), uterus (FA), uterosacral ligament (B2) and rectum (C3). Final score: **ENZIAN A3, B2, C3, FA.**

## 1.7.4.8 Case 8

The 35-year-old patient presented with chronic dysuria and haematuria during menstruation. Preoperative ultrasound demonstrated a nodule on the rear side of the bladder wall close to the uterus (Fig. 1.77a). As shown in Fig. 1.77b, cystoscopic inspection confirmed the tentative diagnosis of the ultrasound examination and revealed the presence of an intravesical proliferated process.

Laparoscopic dissection and removal of the nodule from the posterior bladder wall (Fig. 1.77c).

Final score: **ENZIAN FB**.



**Fig. 1.77** Endometriosis on the posterior bladder wall. Final score: **ENZIAN FB**.

#### 1.7.4.9 Case 9

The 25-year-old patient presented with a long standing history of severe dysmenorrhea, hypermenorrhoea and sterility (more than 3 years).

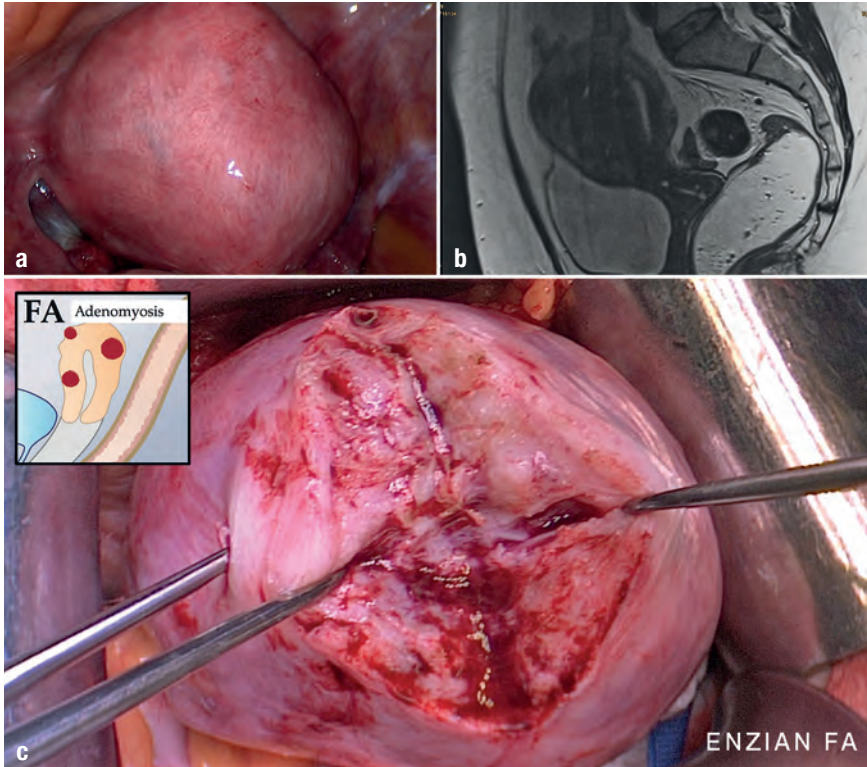
The clinical examination revealed the presence of an enlarged uterus with a thickened anterior wall.

Fig 1.78a shows the anterior wall of the enlarged uterus as visualized during laparoscopy.

MRI showed the typical appearance of a lesion suggestive of intramural adenomyosis of the anterior uterine wall (Fig. 1.78b).

In view of the large size of the nodule, conversion to laparotomy was imperative. The sagittal incision made in the anterior wall is shown on Fig. 1.78c. The adenomyotic nodule was removed completely, followed by reconstruction of the uterus.

Final score: **ENZIAN FA**.



**Fig. 1.78** Adenomyosis.  
Final score: **ENZIAN FA**.



### 1.7.5 Validation of the ENZIAN Classification

Validation of the ENZIAN classification has been the subject of a retrospective study undertaken by the SEF group on the basis of 460 women of which 187 women consented to undergo surgical treatment. A total of 270 lesions were analysed according to the revised ENZIAN classification<sup>23</sup> and 156 women were assessed preoperatively on the basis of findings obtained through clinical examination, transvaginal ultrasound and MR imaging.<sup>33</sup>

Given the presence of deep endometriosis, the ENZIAN classification affords a more complete description of the disease, when used as an adjunct to rASRM.<sup>23</sup> In the past, the adjunctive use of the ENZIAN scheme was prone to redundant scoring, thus resulting in an 'over-scoring' of women with deep endometriosis. However, the revised ENZIAN classification has been shown to better complement the rASRM score and to avoid the occurrence of redundancy.<sup>21</sup>

ENZIAN may be used for preoperative assessment based on clinical findings, transvaginal ultrasound and MR imaging. Accordingly, surgical planning can be improved by more accurate prediction of both extent of deep endometriosis and anticipated duration of the surgical procedure.<sup>20</sup>

In an analysis that was based on 156 patients with DIE and bowel involvement *Mutuku and Keckstein*<sup>33</sup> showed a clear association between preoperative and intraoperative findings evaluated with the ENZIAN scoring system. A significant correlation was noted between these findings and the presence of dyspareunia. However, no overt correlation was demonstrable between extent of disease and dysmenorrhoea and bowel symptoms.

Bilateral involvement of compartment B is associated with a significantly higher complication rate after bowel surgery ( $p = 0.002$ ). Advanced surgery may be required for complete intraoperative staging.

The preoperative use of the ENZIAN scoring system for proper diagnosis of DIE based on MR imaging and ultrasound has increasingly become the focus of interest among specialists in the field. *Di Paola et al.* (2015) compared the outcomes of diagnostic MRI based on the ENZIAN scheme with those obtained from histopathological analysis and evaluation of findings, using again the ENZIAN scheme.<sup>14</sup> The overall sensitivity, specificity, accuracy, and positive and negative predictive values relating to presence/absence of deep endometriosis were calculated for each patient. The concordance between histopathological and MRI/ENZIAN score was excellent ( $k = 0.824$ ). The diagnostic outcome of MRI correlates well with the ENZIAN score and is highly accurate in the detection and localization of deep endometriosis, thus minimising false-negative results (4%) in patients with deep endometriosis and allowing correct preoperative staging.

*Pellegrino et al.* report on their experience with the ENZIAN scheme used to evaluate the outcomes of robotic-assisted shaving technique in the treatment of deep infiltrating endometriosis of the rectovaginal space.<sup>34</sup>

### 1.7.6 Summary and Recommendations

The ENZIAN scoring system is anatomically logical and easy to use. The significant correlation between preoperative and postoperative scores obtained on the basis of the ENZIAN scheme allows for a consistent and clear classification of DIE, which in turn considerably facilitates both conservative and surgical treatments, planning of therapy, as well as follow up care.

The ENZIAN scheme can be used to further investigate the known associations between extent of disease and some symptoms with the goal of improving correlation.

Given the primary use of the rASRM classification, the ENZIAN classification system should be employed as an adjunct in the presence of deep endometriosis in order to obtain a full description of operative findings.<sup>25</sup> According to a consensus statement issued by the *World Endometriosis Society* (WES), the ENZIAN scheme is recommended for use in preoperative diagnostics on the basis of clinical findings, transvaginal ultrasound and MR imaging.<sup>25</sup>

Taking into account recommendations from *Consolidated Standards of Reporting Trials* (CONSORT), it has been proposed that the ENZIAN scheme should be used to record and report on the surgical management of patients with deep infiltrating endometriosis.<sup>40</sup>

### 1.7.7 References

1. ABRAO MS, NEME RM, CARVALHO FM, ALDRIGHI JM, PINOTTI JA. Histological classification of endometriosis as a predictor of response to treatment. *Int J Gynaecol Obstet* 2003;82(1):31–40.
2. ABRAO MS, PETRAGLIA F, FALCONE T, KECKSTEIN J, OSUGA Y, CHAPRON C. Deep endometriosis infiltrating the recto-sigmoid: critical factors to consider before management. *Hum Reprod Update* 2015;21(3):329–39. doi:10.1093/humupd/dmv003.
3. ACOSTA AA, BUTTRAM VC JR, BESCH PK, MALINAK LR, FRANKLIN RR, VANDERHEYDEN JD. A proposed classification of pelvic endometriosis. *Obstet Gynecol* 1973;42(1):19–25.
4. ADAMSON GD. Endometriosis classification: an update. *Curr Opin Obstet Gynecol* 2011;23(4):213–20. doi:10.1097/GCO.0b013e328348a3ba.
5. ADAMYAN L. Additional international perspectives. In: Nichols DH, editor. *Gynecologic and Obstetric Surgery*. St. Louis: Mosby Year Book; 1993. p. 1167–82.
6. ALABAU LACOMBA A. Endometriosis and cancer, with bases for a new classification. *Rev Esp Obstet Ginecol* 1956;15(90):325–34.
7. AMERICAN FERTILITY SOCIETY (AFS). Revised American Fertility Society Classification of Endometriosis: 1985. *Fertil Steril* 1985;43(3):351–2.
8. AMERICAN SOCIETY FOR REPRODUCTIVE MEDICINE (ASRM). rASRM Classification of Endometriosis: 1996. *Fertil Steril* 1997;67(5):817–21.
9. BEECHAM CT. Classification of endometriosis. *Obstet Gynecol* 1966;28(3):437.
10. BROSENS I, DONNEZ J, BENAGIANO G. Improving the classification of endometriosis. *Hum Reprod* 1993;8(11):1792–5.

11. BROSENS IA, CORNILLIE F, KONINCKX P, VASQUEZ G. Evolution of the Revised American Fertility Society Classification of Endometriosis. *Fertil Steril* 1985;44(5):714–6.
12. BUTTRAM VC JR. An expanded classification of endometriosis. *Fertil Steril* 1978;30(2):240–2.
13. CHAPRON C, FAUCONNIER A, VIEIRA M, BARAKAT H, DOUSSET B, PANSINI V et al. Anatomical distribution of deeply infiltrating endometriosis: surgical implications and proposition for a classification. *Hum Reprod* 2003;18(1):157–61.
14. DI PAOLA V, MANFREDI R, CASTELLI F, NEGRELLI R, MEHRABI S, POZZI MR. Detection and localization of deep endometriosis by means of MRI and correlation with the ENZIAN score. *Eur J Radiol* 2015;84(4):568–74. doi:10.1016/j.ejrad.2014.12.017.
15. DONNEZ J, NISOLLE M, GILLEROT S, SMETS M, BASSIL S, CASANAS-ROUX F. Rectovaginal septum adenomyotic nodules: a series of 500 cases. *Br J Obstet Gynaecol* 1997;104(9):1014–8.
16. DONNEZ J, SQUIFFLET J. Complications, pregnancy and recurrence in a prospective series of 500 patients operated on by the shaving technique for deep rectovaginal endometriotic nodules. *Hum Reprod* 2010;25(8):1949–58. doi:10.1093/humrep/deq135.
17. DUBUISSON JB, CHAPRON C. Classification of endometriosis. The need for modification. *Hum Reprod* 1994;9(12):2214–6.
18. EBERT AD, ULRICH U, KECKSTEIN J, MULLER M, SCHINDLER AE, SILLEM M et al. Implementation of certified endometriosis centers: 5-year experience in German-speaking Europe. *Gynecol Obstet Invest* 2013;76(1):4–9. doi:10.1159/000346457.
19. EXACOUSTOS C, MALZONI M, DI GIOVANNI A, LAZZERI L, TOSTI C, PETRAGLIA F et al. Ultrasound mapping system for the surgical management of deep infiltrating endometriosis. *Fertil Steril* 2014;102(1):143–150.e2. doi:10.1016/j.fertnstert.2014.03.043.
20. HAAS D, CHVATAL R, HABELSBERGER A, SCHIMETTA W, WAYAND W, SHAMIYEH A et al. Preoperative planning of surgery for deeply infiltrating endometriosis using the ENZIAN classification. *Eur J Obstet Gynecol Reprod Biol* 2013;166(1):99–103. doi:10.1016/j.ejogrb.2012.10.012.
21. HAAS D, OPPELT P, SHEBL O, SHAMIYEH A, SCHIMETTA W, MAYER R. Enzian classification: does it correlate with clinical symptoms and the rASRM score? *Acta Obstet Gynecol Scand* 2013;92(5):562–6. doi:10.1111/aogs.12118.
22. HAAS D, SHEBL O, SHAMIYEH A, OPPELT P. The rASRM score and the Enzian classification for endometriosis: their strengths and weaknesses. *Acta Obstet Gynecol Scand* 2013;92(1):3–7. doi:10.1111/aogs.12026.
23. HAAS D, WURM P, SHAMIYEH A, SHEBL O, CHVATAL R, OPPELT P. Efficacy of the revised Enzian classification: a retrospective analysis. Does the revised Enzian classification solve the problem of duplicate classification in rASRM and Enzian? *Arch Gynecol Obstet* 2013;287(5):941–5. doi:10.1007/s00404-012-2647-1.
24. JOHNSON NP, HUMMELSHOJ L. Consensus on current management of endometriosis. *Hum Reprod* 2013;28(6):1552–68. doi:10.1093/humrep/det050.
25. JOHNSON NP, HUMMELSHOJ L, ADAMSON GD, KECKSTEIN J, TAYLOR HS, ABRAO MS et al. Consensus of the World Endometriosis Society (WES) on the Classification of Endometriosis. *Hum Reprod* 2016 (in press).
26. KECKSTEIN J. Enzian classification of deep infiltrating endometriosis: Stiftung Endometriose Forschung (SEF) [German Endometriosis Research Foundation]; Available from: [http://www.endometriose-sef.de/dateien/ENZIAN\\_2013\\_web.pdf](http://www.endometriose-sef.de/dateien/ENZIAN_2013_web.pdf).
27. KECKSTEIN J, ULRICH U, POSSOVER M, SCHWEPPE KW. Enzian-Klassifikation der tief infiltrierenden Endometriose [Enzian classification on deep infiltrating endometriosis]. *Zentralbl Gynakol* 2003(125):291.
28. KECKSTEIN J, WIESINGER H. Deep endometriosis, including intestinal involvement – the interdisciplinary approach. *Minim Invasive Ther Allied Technol* 2005;14(3):160–6. doi:10.1080/14017430510035916.
29. KECKSTEIN J, WIESINGER H. The laparoscopic treatment of intestinal endometriosis. In: Sutton C, Jones K, Adamson GD, editors. *Modern management of endometriosis*. London: Taylor & Francis; 2005. p. 177–87. (ISBN No. 9781842142769).
30. KISTNER RW, AM SIEGLER, BEHRMAN SJ. Suggested classification for endometriosis: relationship to infertility. *Fertil Steril* 1977;28(9):1008–10.
31. KONINCKX PR, MARTIN DC. Deep endometriosis: a consequence of infiltration or retraction or possibly adenomyosis externa? *Fertil Steril* 1992;58(5):924–8.
32. KONINCKX PR, OOSTERLYNCK D, D'HOOGHE T, MEULEMAN C. Deeply infiltrating endometriosis is a disease whereas mild endometriosis could be considered a non-disease. *Ann N Y Acad Sci* 1994;734:333–41.
33. MUTUKU T. Die prä-operative Abschätzung einer tief infiltrierenden Darmendometriose mittels Untersuchungsbe fund in der ENZIAN. Klassifikation und der Symptomatik sowie Vergleich mit dem intra-operativen ENZIAN-Befund [The assessment of deep infiltrating endometriosis according to the preoperative investigation and symptoms in comparison to intraoperative findings with the ENZIAN- Classification] [MD Thesis]. Ulm: Universität [University]; 2015.
34. PELLEGRINO A, DAMIANI GR, TRIO C, FACCIOLI P, CROCE P, TAGLIABUE F et al. Robotic Shaving Technique in 25 Patients Affected by Deep Infiltrating Endometriosis of the Rectovaginal Space. *J Minim Invasive Gynecol* 2015;22(7):1287–92. doi:10.1016/j.jmig.2015.06.002.
35. REDWINE DB. American Fertility Society classification of endometriosis – the last word? *Fertil Steril* 1990;54(1):180–1.
36. REICH H, MCGLYNN F, SALVAT J. Laparoscopic treatment of cul-de-sac obliteration secondary to retrocervical deep fibrotic endometriosis. *J Reprod Med* 1991;36(7):516–22.
37. THE AMERICAN FERTILITY SOCIETY (AFS). Classification of endometriosis. *Fertil Steril* 1979;32(6):633–4.
38. TUTTLIES F, KECKSTEIN J, ULRICH U, POSSOVER M, SCHWEPPE KW, WUSTLICH M et al. ENZIAN-score, a classification of deep infiltrating endometriosis. *Zentralbl Gynakol* 2005;127(5):275–81. doi:10.1055/s-2005-836904.
39. ULRICH U, BUCHWEITZ O, GREB R, KECKSTEIN J, LEFFERN I VON, OPPELT P et al. National German Guideline (S2k): Guideline for the Diagnosis and Treatment of Endometriosis: Long Version – AWMF Registry No. 015–045. *Geburtshilfe Frauenheilkd* 2014;74(12):1104–18. doi:10.1055/s-0034-1383187.
40. VANHIE A, MEULEMAN C, TOMASSETTI C, TIMMERMAN D, D'HOORE A, WOLTHUIS A et al. Consensus on Recording Deep Endometriosis Surgery: the CORDES statement. *Hum Reprod* 2016. doi:10.1093/humrep/dew067.
41. WUSTLICH M. Laparoskopisch-assistierte Sigmasegmentresektion bei Endometriose mit Darmbeteiligung [Laparoscopic assisted resection of the rectosigmoid in endometriosis with bowel involvement] [MD Thesis]. Leipzig: Universität [University]; 2002.

## 1.8

## Medical Therapies in the Treatment of Endometriosis

Karl-Werner Schweppe<sup>a</sup>

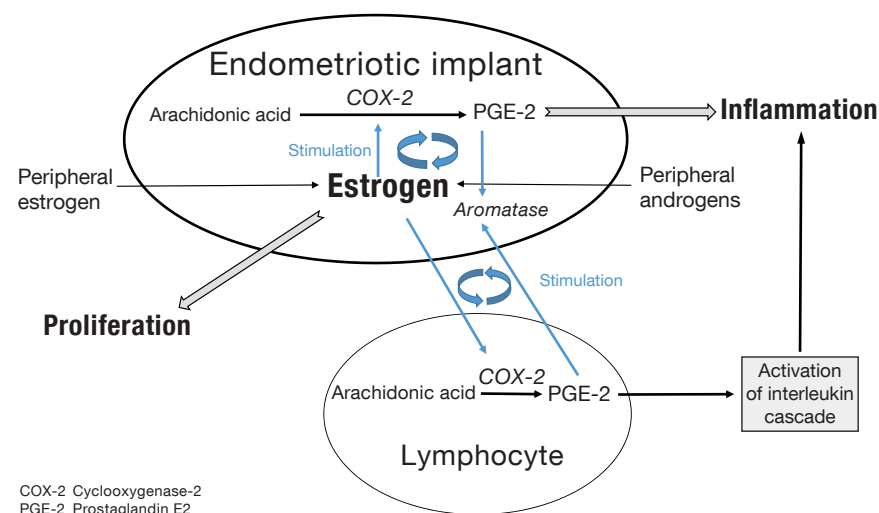
## 1.8.1 Introduction

Laparoscopic surgery does not always result in the complete excision of lesions down to normal tissue. In many cases it is impossible to visualize all of the affected tissue, while in others, incomplete resection is necessary in order to maintain fertility. In patients with endometriosis, who do not wish to give birth to a child in the near future, laparoscopic excision should therefore always be followed by medical therapies. This is to ensure removal of any residual endometriotic tissue – including microscopically small lesions – and to protect the patient from pain, while preventing irregular menstrual cycles and the recurrence of endometriotic lesions.<sup>11</sup> The medical treatment options currently available continue to be focused either on eliminating proliferative stimulation induced by ovarian oestrogens, i.e., through direct or indirect suppression of ovarian function, or on pharmaceutical regulation of the patient's prostaglandin metabolism. The latter therapeutic approach is geared toward relieving the endometriosis-associated pain symptoms, which are mainly attributed to the inflammatory response triggered within the lesions. A hormonal state of oestrogen deficiency can be achieved by using steroid drugs that act by modulating the negative feedback loop of the hypothalamic-pituitary-ovarian axis, however their metabolic pathway does not involve the

release of substances with oestrogen-like characteristics. Alternatively, a hypo-oestrogenic state can be induced by using substances like *gonadotropin-releasing hormone* (GnRH) analogues, that act on the pituitary gland and inhibit the release of gonadotropin. Substances inhibiting the synthesis of prostaglandins can be used to modulate endometriosis-related pain that arises from areas affected by disease, exhibiting an altered prostaglandin metabolism. The question as to whether this approach also has a specific impact on the endometriotic lesions themselves is the subject of current research endeavours, as *cyclooxygenase-2* (COX-2) expression has been found to be involved in the pathogenesis of different types of endometriosis.<sup>5</sup>

## 1.8.2 Anti-Inflammatory Treatment

One of the mainstays of medical therapeutic approaches is the treatment of pain that develops as a result of local inflammatory responses. Alterations in prostaglandin metabolism, the initiation of the interleukin cascade reaction, and neurogenesis, all are contributing factors to the occurrence of the pain symptoms associated with endometriosis. This is why *non-steroidal anti-inflammatory drugs* (NSAID)-type analgesics can be used to suppress the inflammatory reactions underlying the



**Fig. 1.79** Schematic representation showing the impact of prostaglandins and oestrogen on the inflammatory reaction in endometriosis tissue.

disease, and prevent pain from becoming chronic in nature. Even though the efficacy of NSAIDs in treating endometriosis-associated pain is not well established owing to a lack of studies of sufficiently high quality,<sup>1</sup> there is evidence from clinical practice to suggest that administration of naproxen or ibuprofen can have a positive effect. Selective COX-2 inhibitors, which act by inhibiting intracellular pathways responsible for COX-2 activity, are particularly useful in this regard (Fig. 1.79). At the time of writing, this type of drug has not been approved worldwide for use in the treatment of

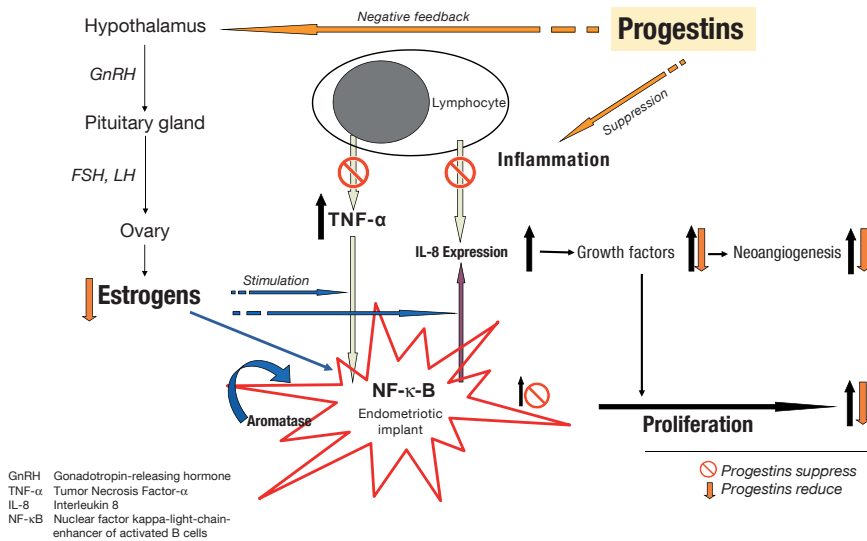
<sup>a</sup> | Professor, MD, MD h.c.; Former Director of the Ammerland Endometriosis Center, Department of Obstetrics and Gynecology, Ammerland Clinic GmbH, Academic Teaching Hospital of the Hannover Medical School, Germany

## Corresponding author:

Prof. Dr. med. Dr. h.c. **Karl-Werner Schweppe**  
Vorstandsvorsitzender der Stiftung Endometriose-Forschung  
Lange Straße 38  
26655 Westerstede, Germany  
E-mail: kwschweppe@ewetel.net







**Fig. 1.81** Mechanism of action of progestogen-based approaches to the treatment of endometriosis.

of ethinyloestradiol remains to be elucidated, progression of disease cannot be ruled out.<sup>16,19</sup> Last but not least, any such use would be considered off-label.

#### ■ Progestogen Monotherapies

For some time, a variety of progestogens have been used in the treatment of patients with endometriosis. In order to be sufficiently effective, however, the medication regimen required the patient to take the drug at a relatively high dosage. Studies have shown that continuous use of progestogens can reduce endometriosis-related symptoms in 80% of cases. In physiological terms, progestogens act in direct opposition to oestrogens. Progestogens suppress the secretion of gonadotropins through negative feedback inhibition of the hypothalamic-pituitary-ovarian axis, thereby producing an oestrogen deficiency and an excess of progestogen. The scope of activity also involves a reduction in the areas of localized peritoneal inflammation associated with endometriosis (Fig. 1.81). The licensing status of progestogens for the treatment of endometriosis varies considerably across the globe, a fact that needs to be taken into consideration when prescribing these medicines. In Germany, almost all progestogens that used to be part of the treatment armamentarium for endometriosis have now been removed from the market. Dienogest is now the only such product available that has been licensed specifically for the treatment of endometriosis.<sup>33</sup>

#### ■ The Use of Dienogest in the Treatment of Endometriosis

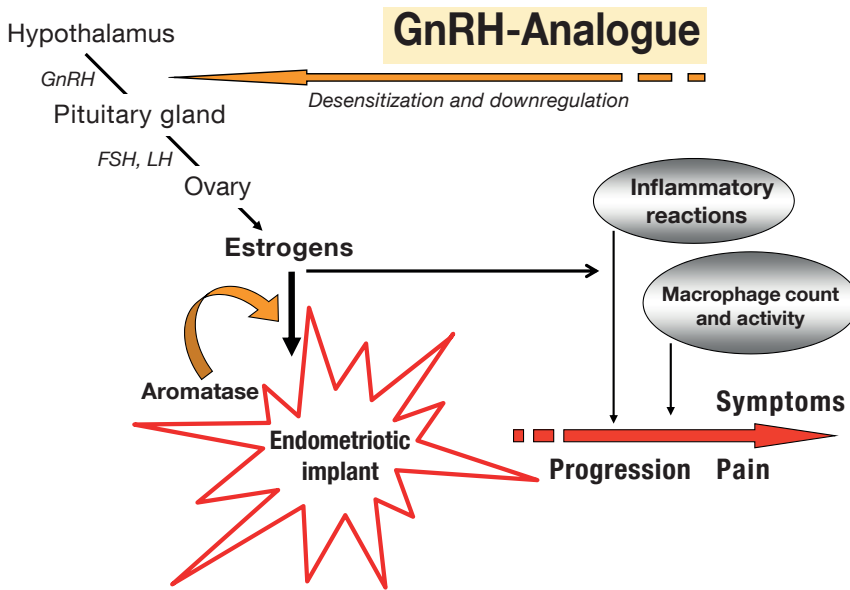
Dienogest is a 19-nortestosterone derivative that unlike other preparations of the same group, does not contain a 17 $\alpha$ -ethinyl group. Due to its unique chemical structure, it combines the benefits of both the 19-nortestosterone derivatives and the progesterone derivatives. Aside from its anti-proliferative effect, dienogest also has anti-inflammatory and anti-angiogenic properties. While it lacks androgenic properties, dienogest has a clear anti-androgenic effect.<sup>12</sup> As a progestogen, it is also moderately effective at suppressing the production of oestrogens and counteracts the stimulating effects the latter have on the ectopic endometrium. It is well-tolerated and therefore well-suited for long-term treatment.<sup>32</sup>

Data from clinical studies are available for treatment periods of up to 5 years.<sup>42</sup>

In a trial comparing dienogest with *leuprolide acetate* (LA) in 252 women with endometriosis,<sup>37</sup> dienogest was shown to be as effective as LA at reducing endometriosis-related pain (which was rated using a visual analogue scale). After a treatment period of 24 weeks, approximately 60% of the patients of both groups were free from pain. Over the treatment period, VAS scores were found to be reduced by  $47.5 \pm 28.8$  mm in the dienogest-group, and by  $46.0 \pm 24.8$  mm in the LA-group. While a dramatic reduction in oestrogen levels was recorded among women in the LA-group, dienogest appeared to cause only a moderate level of suppression. Dienogest also outperformed LA with regard to benefits related to quality of life.<sup>37</sup> In another study, researchers set out to investigate the efficacy and safety of dienogest as a long-term treatment for endometriosis.<sup>23</sup> Among a total of 168 patients enrolled in the study, 90.5% ( $n = 152$ ) completed the extended treatment period of 15 months. A significant reduction in pain levels was recorded during treatment, with mean VAS scores falling from 34.08 mm to 11.52 mm ( $p < 0.001$ ). While researchers also recorded a gradual decrease in subjective side effects, such as the frequency and intensity of bleeding, half of all patients continued to experience bleeding at the end of treatment. Other adverse events were generally mild or moderate in intensity, resulting in a 2.4% withdrawal rate. Data from the study's follow-up control visit at 24-weeks after completion of treatment were obtained from 34 women and showed that patients continued to experience reduced levels of pain throughout this period. Research results suggest that dienogest has favorable efficacy and safety profiles, and is suited for long-term treatment of women with endometriosis.

#### 1.8.3.3 The Use of GnRH Analogues in the Medical Treatment of Endometriosis

GnRH analogues constitute an effective alternative to the use of progestogens. The term "analogues" refers to both agonists and antagonists of the naturally occurring *luteinizing hormone-releasing hormones* (LHRHs), a group of substances that act directly at the pituitary and hypothalamic level. While



**Fig. 1.82** Modes of action of GnRH analogues used in the treatment of endometriosis.

GnRH antagonists are widely used in oncology and, to a more limited extent, in reproductive medicine, GnRH agonists have become a well-established type of medication in the treatment of endometriosis – in spite of their initial stimulatory effect. The use of GnRH analogues results in regression and atrophy of endometriotic lesions. This is achieved without producing any significant metabolic side effects, and involves the reversible suppression of ovarian function through pituitary desensitization (Fig. 1.82). The objective and subjective success rates reported for various substances falling into this category are basically the same.<sup>17</sup> Prolonged-release preparations are generally preferred by clinical practitioners as they produce better compliance rates and reliable ovarian suppression. As far as adverse effects are concerned, these are primarily related to oestrogen deficiency, and are comparable to symptoms of menopause. Although GnRH analogues are well-tolerated, length of treatment is limited to 6 months because the ultimate effect of these substances is to induce a hypo-oestrogenic state and in the long-term leads to bone demineralization. While this is reversible and varies greatly between individuals, mean bone loss ranges between 4–6%. The so-called ‘add-back’ therapy,<sup>10</sup> which involves the use of low-dose oestrogens or progestogens in conjunction with GnRH analogues, was introduced to reduce bone loss without impairing the treatment’s therapeutic effect. Oestradiol levels should remain within the therapeutic range (i.e. between 30 and 60 pg/ml).<sup>2,18</sup>

Prospective randomized studies have shown that GnRH analogues are better than progestogens at causing regression of endometriotic lesions,<sup>26</sup> and a comprehensive Cochrane review<sup>25</sup> confirmed that GnRH analogues are at least as effective as progestogens at reducing the pain associated with endometriosis. While the use of combined oral contraceptives (COC) is still widely accepted – due to their low cost – it is important to acknowledge that they have been shown to be less effective than GnRH analogues.<sup>43</sup> A review article by Shaw<sup>36</sup> reported that the various GnRH agonists currently available on the market are all equally effective at causing regression, and at reducing the pain associated with endometriosis. However,

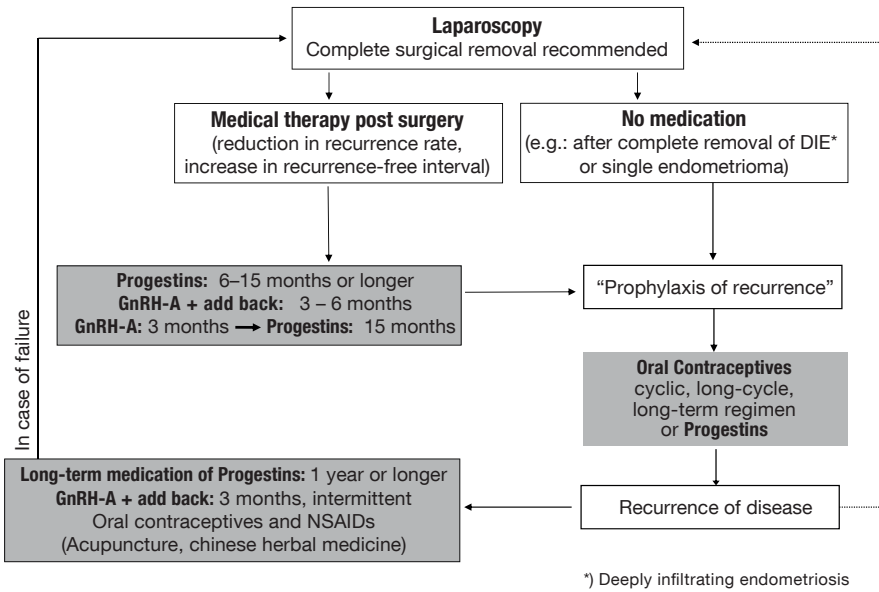
even after 6 months of treatment, 50% of patients will present with endometrial scar tissue that still contains endometrial glands and stroma.<sup>29,31</sup> This, of course, explains why, even after such potent treatment, patients with residual disease will become symptomatic again, and why recurrence is simply a matter of time.

## 1.8.4 Recommendations for Clinical Practice

### 1.8.4.1 Pain Patients

The clinical benefits associated with adjuvant medical therapy are particularly important in patients with a history of previous surgery. This is because adjuvant use of progestogens<sup>42</sup> or adjuvant GnRH agonists can reduce the overall rate of recurrence and increase the duration of the recurrence-free interval.<sup>6</sup> While GnRH agonists have been shown to be as effective at reducing the pain associated with endometriosis after only 3 months of treatment, the recurrence-free interval is significantly longer if suppression of ovulation is continued for a duration of 6 months. Symptomatic treatment with COCs has also become common practice in clinical routine, and is used in patients with pain recurrence or as prophylaxis following surgery. COCs are used as part of both cyclical and continuous regimens. While a prospective, randomized study<sup>20</sup> has shown that, during the postoperative period, COCs are less effective than GnRH agonists in treating the pain associated with endometriosis, they are also less expensive and linked with a different set of adverse effects. To date, no data exists on whether and how the various modalities of administration – transdermal patch, vaginal ring or subcutaneous implant – are contributing to the medication’s effectiveness in reducing endometriosis-related pain. One prospective study, though based on a total of 55 patients only,<sup>39</sup> showed that continuous administration of COCs is more effective than cyclical regimens. When given as prophylaxis following surgery, oral contraceptives (OCs) have been found to reduce the recurrence rates for dysmenorrhoea and ovarian cysts, and/or endometriomas.<sup>35,40</sup> With regard





**Fig. 1.83** Algorithm for medical treatment of endometriosis in clinical practice.

to the recommended therapeutic regimen, the duration of treatment still needs to be determined, and varies between 3 months and 5 years. However, symptoms will recur if the medication is discontinued.<sup>41</sup> Physicians will need to evaluate the pros and cons of the adjunctive use of these preparations in addition to other treatments designed to further increase the recurrence-free interval after adjuvant therapy with progestogens or GnRH agonists (Fig. 1.83).

#### 1.8.4.2 Long-Term Treatment Options

In patients with recurrent and/or progressive disease and in patients with *deeply infiltrating endometriosis* (DIE), there are several treatment options available in addition to surgical excision that can be used to achieve an improvement of pain symptoms. Taking into account the chronicity of the disease, these treatments can be used either continuously or intermittently, and include OCs and progestogens, prolonged-release GnRH analogues, physical therapy or homeopathy, and intrauterine progestogen delivery systems. Additional surgical procedures, in particular radical surgery, should be avoided as these are associated with a high recurrence rate and a significant risk of complications. Low-dose progestogens represent the most effective treatment option for long-term therapy. Dienogest was shown to produce a gradual reduction in pain symptoms over a duration of 15 months.<sup>34</sup> As GnRH analogues offer the option of using ‘add-back’ medication to reduce the occurrence of adverse effects, they also represent an alternative for the long-term treatment of endometriosis<sup>24</sup> in cases where progestogen-only treatment is insufficient or poorly tolerated by the patient. GnRH agonists remain effective even after repeated use in patients with recurrent disease. Another option, however, is to adopt an intermittent treatment regimen consisting of a 3-month administration of GnRH agonists and ‘add-back’ medication, interrupted by a treatment-free interval with resumption of treatment only in patients where symptoms persist or recur.<sup>30</sup> This treatment approach is cost-effective and well-tolerated by patients. Due to a lack of relevant data, however, it is not clear whether long-term treatment regimens can be discontinued after a period of

2–3 years, and whether the subsequent continuous use of an OC is likely to be sufficient. Patients who are likely to require long-term treatment should be identified early to reduce the risk of pain syndromes becoming chronic. This also applies to patients who need to be treated via an interdisciplinary approach that is geared toward managing both psychosomatic symptoms and pain symptoms.

#### 1.8.4.3 Recommendations Regarding Endometriosis-Related Infertility

Medical treatments alone are not capable of improving a patient’s fertility status. A Cochrane review<sup>14</sup> published in 2007, demonstrated clearly that the use of ovulation suppression agents does not have any beneficial effect on the fertility status in subfertile women with minimal or mild endometriosis. It is worth mentioning, however, that the above conclusion is based on studies with a small number of participants. International multi-centre studies based on a statistically relevant number of participants are required to draw scientifically valid conclusions. Down-regulation with GnRH agonists is used as part of *in vitro fertilization* (IVF) protocols prior to the start of the stimulation cycle. When compared with treatment protocols that do not include the use of GnRH agonists, this approach prevents an early LH surge, produces more eggs, and improves pregnancy rates.<sup>27</sup> The positive effects associated with GnRH agonists – which are used up to 6 months prior to starting an IVF cycle (ultra-long protocol), and irrespective of the severity grade of endometriosis – have to be assessed and discussed on a case-by-case basis. Particularly in older patients, prolonged ovarian suppression may be inappropriate as the age-related decline in ovarian reserve status may render the subsequent stimulation cycle more difficult.<sup>28</sup> The same applies to women who have a reduced number of follicles as a result of unilateral or bilateral endometriomas and surgical resection. To date, there is no consensus in the literature in regard to what constitutes a suitable candidate for GnRH treatment, or what the length of the ultra-long protocol’s GnRH cycle should be.

### 1.8.5 Conclusions

Endometriosis severely affects the quality of life in women suffering from the disease. Laparoscopy has been found to play a significant role in the diagnosis and treatment of endometriosis. In order to reduce pain and prevent recurrence, and in addition to surgical measures, patients should be treated either with GnRH analogues and 'add-back' medication, or with progestogens. Non-steroidal anti-inflammatory agents, OCs and many of the progestogens available today have demonstrated a positive effect in patients faced with a recurrence of pain symptoms. On the basis of relevant data from studies of suitable design and quality it can be concluded that the progestogen dienogest currently plays a central role in the medical treatment of endometriosis. In Germany, dienogest is the only progestogen medication available to date, that is licensed for the treatment of endometriosis and suited for long-term use. The use of GnRH agonists in combination with 'add-back' medication is a valid alternative option that helps to alleviate symptoms and induce regression of active disease. The decision-making regarding the most suitable treatment option should be based on the patient's compliance with the proposed regimen and must include a risk assessment of the potential adverse effects of the therapy under consideration.

### 1.8.6 References

- ALLEN C, HOPEWELL S, PRENTICE A, GREGORY D. Nonsteroidal anti-inflammatory drugs for pain in women with endometriosis. *The Cochrane database of systematic reviews* 2009(2):Cd004753. doi:10.1002/14651858.CD004753.pub3.
- BARBIERI RL. Endometriosis and the estrogen threshold theory. Relation to surgical and medical treatment. *The Journal of reproductive medicine* 1998;43(3 Suppl):287–92.
- BARBIERI RL, LEE H, RYAN KJ. Danazol binding to rat androgen, glucocorticoid, progesterone, and estrogen receptors: correlation with biologic activity. *Fertility and sterility* 1979;31(2):182–6.
- BARBIERI RL, RYAN KJ. Danazol: endocrine pharmacology and therapeutic applications. *American journal of obstetrics and gynecology* 1981;141(4):453–63.
- BARTLEY J, MECHSNER S, BEUTLER C, HALIS G, LANGE J, EBERT AD. COX-2-Expression in extragenitalen Endometrioseläsionen als neuer Therapieansatz? *Zentralblatt für Gynäkologie* 2003;125(07/08):252–5. doi:10.1055/s-2003-42279.
- BUSACCA M, SOMIGLIANA E, BIANCHI S, MARINIS S DE, CALIA C, CANDIANI M et al. Post-operative GnRH analogue treatment after conservative surgery for symptomatic endometriosis stage III-IV: a randomized controlled trial. *Human reproduction (Oxford, England)* 2001;16(11):2399–402.
- DMOWSKI WP. Endocrine properties and clinical application of danazol. *Fertility and sterility* 1979;31(3):237–51.
- DMOWSKI WP, COHEN MR. Antigonadotropin (danazol) in the treatment of endometriosis. Evaluation of posttreatment fertility and three-year follow-up data. *American journal of obstetrics and gynecology* 1978;130(1):41–8.
- DOGAN E, SAYGILI U, POSACI C, TUNA B, CALISKAN S, ALTUNYURT S et al. Regression of endometrial explants in rats treated with the cyclooxygenase-2 inhibitor rofecoxib. *Fertility and sterility* 2004;82 Suppl 3:1115–20. doi:10.1016/j.fertnstert.2004.06.033.
- EMONS G, ORMANN O, SCHUTZ KD. GnRH analogues in ovarian, breast and endometrial cancer. In: Lunenfeld EB, Insler V, editors. *GnRH Analogues: The State of Art 1996*. Lancaster, New York: Parthenon Publishing; 1996. p. 95–120.
- GÖRETZLEHNER G, GÖRETZLEHNER U. Orale Kontrazeptiva und Langzyklus bei Endometriose. *J Gynäkol Endokrinol* 2008(2):27–31.
- GUDERMANN T. Endokrinpharmakologie. In: Leidenberger F, Strowitzki T, Ortman O, editors. *Klinische Endokrinologie für Frauenärzte*: Springer Berlin Heidelberg; 2009. p. 217–44. (ISBN No. 978-3-540-44162-5).
- HENRIQUES ES, JOFE MH, FRIEDLANDER RL, SWARZT DP. Longterm follow up of endometriosis treated with danazol. In: Greenblatt RB, Semm K, Mettler L, editors. *Genital endometriosis in infertility*. Stuttgart: Thieme; 1982. p. 55–66. (ISBN No. 3136289013 9783136289013 086577059X 9780865770591).
- HUGHES E, BROWN J, COLLINS JJ, FARQUHAR C, FEDORKOW DM, VANDEKERCKHOVE P. Ovulation suppression for endometriosis. *The Cochrane database of systematic reviews* 2007(3):Cd000155. doi:10.1002/14651858.CD000155.pub2.
- IGARASHI M. A new therapy for pelvic endometriosis and uterine adenomyosis: local effect of vaginal and intrauterine danazol application. *Asia-Oceania journal of obstetrics and gynaecology/AOFOG* 1990;16(1):1–12.
- KAPPOU D, MATALLIOTAKIS M, MATALLIOTAKIS I. Medical treatments for endometriosis. *Minerva ginecologica* 2010;62(5):415–32.
- KIESEL L, KOHL C. Medikamentöse Therapie der Endometriose. In: Schweppe K, Schindler AE, Semm K, Runnebaum B, editors. *Endometriose*. Balingen: Demeter Verlag; 1995.
- KLEINSTEIN J. GnRH-Analoga und Add-back-Verfahren. *J. Reproduktionsmed. Endokrinol* 2008;2(2):40–3.
- KLIPPING C, DUIJKERS I, REMMERS A, FAUSTMANN T, ZURTH C, KLEIN S et al. Ovulation-inhibiting effects of dienogest in a randomized, dose-controlled pharmacodynamic trial of healthy women. *Journal of clinical pharmacology* 2012;52(11):1704–13. doi:10.1177/0091270011423664.
- MUZII L, MARANA R, CARUANA P, CATALANO GF, MARGUTTI F, PANICI PB. Postoperative administration of monophasic combined oral contraceptives after laparoscopic treatment of ovarian endometriomas: a prospective, randomized trial. *American journal of obstetrics and gynecology* 2000;183(3):588–92. doi:10.1067/mob.2000.106817.
- NEUNHOEFFER E, LAWRENZ B. Therapieoptionen der Endometriose. *Arzneimitteltherapie* 2011;29(2):35–41.
- NOBLE LS, SIMPSON ER, JOHNS A, BULUN SE. Aromatase expression in endometriosis. *The Journal of clinical endocrinology and metabolism* 1996;81(1):174–9. doi:10.1210/jcem.81.1.8550748.
- PETRAGLIA F, HORNUNG D, SEITZ C, FAUSTMANN T, GERLINGER C, LUISI S et al. Reduced pelvic pain in women with endometriosis: efficacy of long-term dienogest treatment. *Archives of gynecology and obstetrics* 2012;285(1):167–73. doi:10.1007/s00404-011-1941-7.
- PIERCE SJ, GAZVANI MR, FARQUHARSON RG. Long-term use of gonadotropin-releasing hormone analogs and hormone replacement therapy in the management of endometriosis: a randomized trial with a 6-year follow-up. *Fertility and sterility* 2000;74(5):964–8.
- PRENTICE A, DEARY AJ, BLAND E. Progestagens and anti-progestagens for pain associated with endometriosis. *The Cochrane database of systematic reviews* 2003.

26. REGIDOR PA, REGIDOR M, SCHMIDT M, RUWE B, LUBBEN G, FORTIG P et al. Prospective randomized study comparing the GnRH-agonist leuprorelin acetate and the gestagen lynestrenol in the treatment of severe endometriosis. *Gynäkologische Endokrinologie* 2001;15(3):202–9.
27. RICKES D, NICKEL I, KROPF S, KLEINSTEIN J. Increased pregnancy rates after ultralong postoperative therapy with gonadotropin-releasing hormone analogs in patients with endometriosis. *Fertility and sterility* 2002;78(4):757–62.
28. RICKES D, WEISS M, NICKEL I. Ovarielle Ansprechbarkeit auf rekombinante Gonadotropine nach ultralanger „Dornregulation“ mit GnRH-Analoga. *Zentralbl Gynäkol* 2003;125:306.
29. RUWE M, DONHUIJSEN K, REGIDOR PA, LEDER LD, SCHINDLER AE. Endometriose: Klinische, histologische und morphometrische Befunde vor und nach Gn-RH-Agonisten-Therapie. *Zentralblatt für Gynäkologie* 1998;120(8):391–8.
30. SCHWEPPE K. Longterm continuous, intermittent and recurrent treatment of endometriosis. 7th International Symposium on GnRHAnalogous in Cancer and Human Reproduction. *Gynäkologische Endokrinologie* 2003b;17 (Suppl 1)(28). doi:10.1007/s10304-006-0145-x.
31. SCHWEPPE K. Morphologie und Klinik der Endometriose. 1st ed. Stuttgart, New York: F. K. Schattauer GmbH; 1984. (ISBN No. 9783794509775).
32. SCHWEPPE K, DMOWSKI WP, WYNN RM. Ultrastructural changes in endometriotic tissue during danazol treatment. *Fertility and sterility* 1981;36(1):20–6.
33. SCHWEPPE K, DMOWSKI WP, WYNN RM. Endometriose – Entstehung, Diagnostik Behandlungsmöglichkeiten und Probleme in Klinik und Praxis. *J. Reproduktionsmed. Endokrinol* 2011;8(3): 180–94.
34. SEITZ C, GERLINGER C, FAUSTMANN T, STROWITZKI T. Safety of dienogest in the long-term treatment of endometriosis: a one-year, open-label, follow-up study. *Fertility and sterility* 2009;92:S107.
35. SERACCHIOLI R, MABROUK M, FRASCA C, MANUZZI L, SAVELLI L, VENTUROLI S. Long-term oral contraceptive pills and postoperative pain management after laparoscopic excision of ovarian endometrioma: a randomized controlled trial. *Fertility and sterility* 2010;94(2):464–71. doi:10.1016/j.fertnstert.2009.03.083.
36. SHAW RW. The role of GnRH analogues in the treatment of endometriosis. *British journal of obstetrics and gynaecology* 1992;99 Suppl 7:9–12.
37. STROWITZKI T, MARR J, GERLINGER C, FAUSTMANN T, SEITZ C. Detailed analysis of a randomized, multicenter, comparative trial of dienogest versus leuprolide acetate in endometriosis. *International journal of gynaecology and obstetrics: the official organ of the International Federation of Gynaecology and Obstetrics* 2012;117(3):228–33. doi:10.1016/j.ijgo.2012.01.009.
38. ULRICH U. Interdisziplinäre S2k-Leitlinie für die Diagnostik und Therapie der Endometriose/Arbeitsgruppe „Leitlinie für die Diagnostik und Therapie der Endometriose“. 3rd ed. München/Germering: Zuckschwerdt; 2013.
39. VERCELLINI P, FRONTINO G, GIORGI O DE, PIETROPAOLO G, PASIN R, CROSIGNANI PG. Continuous use of an oral contraceptive for endometriosis-associated recurrent dysmenorrhea that does not respond to a cyclic pill regimen. *Fertility and sterility* 2003;80(3):560–3.
40. VERCELLINI P, SOMIGLIANA E, DAGUATI R, VIGANO P, MERONI F, CROSIGNANI PG. Postoperative oral contraceptive exposure and risk of endometrioma recurrence. *American journal of obstetrics and gynecology* 2008;198(5):504.e1-5. doi:10.1016/j.ajog.2007.11.010.
41. VERCELLINI P, TRESPIDI L, COLOMBO A, VENDOLA N, MARCHINI M, CROSIGNANI PG. A gonadotropin-releasing hormone agonist versus a low-dose oral contraceptive for pelvic pain associated with endometriosis. *Fertility and sterility* 1993;60(1):75–9.
42. YOSHIKI O, MASAANI A, SHIORI Y, SAORI N, MIKA F, MIZUKI T et al. Long-term administration of dienogest reduces recurrence after excision of endometrioma. *Journal of Endometriosis and Pelvic Pain Disorders* 2015;7(2):63–7.
43. ZUPI E, MARCONI D, SBRACIA M, ZULLO F, VIVO B DE, EXACUSTOS C et al. Add-back therapy in the treatment of endometriosis-associated pain. *Fertility and sterility* 2004;82(5):1303–8. doi:10.1016/j.fertnstert.2004.03.062.



## 1.9

## The Role of Rehabilitation in the Treatment of Endometriosis Patients

Hans-Harald Riedel<sup>a</sup>**1.9.1 Introduction**

Endometriosis is a chronic, progressive gynecological disorder that affects approximately 10–15% of women aged 15–45 in Germany, making it the second most common benign disease in the female population. Many of these women experience dysmenorrhea, dyspareunia, dysuria, chronic lower abdominal pain, bowel dysfunction, and infertility, which can seriously compromise the physical, psychological and social quality of their lives. Despite 100 years of extensive research, the cause of endometriosis is still unknown. As a result, no universally effective evidence-based therapy has yet been established.

Approximately 90% of endometriosis patients suffer from some degree of lower abdominal pain that significantly impacts their work and daily activities. Because of these disabling effects, a comprehensive range of target-oriented complementary therapies should be available as adjuncts to medical and surgical pain management.

While the primary goal of rehabilitation is to achieve the best possible recovery, patients should also be counseled about the potential for long-term health restrictions. Studies have shown that endometriosis patients require up to 65 days of sick leave per year, underscoring the need for an individualized, holistic approach to pain management.

**1.9.2 Indications for Rehabilitation**

Especially after major operations, which may involve a partial bowel or bladder resection or reimplantation of the ureters, rehabilitation should start with a follow-up program after the patient has been discharged home. In Germany, the costs of these treatments are covered by health insurance or pension funds. But while follow-up is standard for cancer patients or patients who have had orthopedic surgery, the follow-up care of endometriosis patients is rarely submitted to insurance providers for reimbursement. Apart from receiving immediate follow-up care after a surgical procedure, a patient treated for endometriosis is eligible to participate in a rehabilitation program that is indicated for chronic pain. This program is geared toward the primary goals of relieving pain and improving physical fitness.

<sup>a</sup> | Professor, MD; Head of Department of Gynecology, Rehabilitation Clinic Prof. Schedel GmbH, Thyrnau-Kellberg, Germany

**Corresponding author:**

Prof. Dr. med. habil. **Hans-Harald Riedel**  
 Klinik Prof. Schedel GmbH  
 Prof.-Dr.-Schedel-Straße 2  
 94136 Thyrnau-Kellberg, Germany  
 E-mail: info@klinik-prof-schedel.com  
 www.klinik-prof-schedel.com

**1.9.3 Rehabilitation Goals**

The *Prof. Schedel Rehabilitation Center* in Kellberg, Germany, offers a rehabilitation program that places special emphasis on the following goals:

- Pain relief.
- Patient education.
- Support for women who desire pregnancy.
- Reduction of cramps and tension.
- Improvement of physical fitness.
- Development of compensation strategies.

Rehabilitation at our center follows an holistic approach that includes nutritional counseling, the use of natural remedies, yoga, and balneotherapy. These measures help to promote a more positive body awareness, an enjoyment of movement, and a significant reduction in pain.

Throughout rehabilitation, patient care is provided by a team consisting of doctors, nurses, psychologists, sports therapists, physiotherapists, social workers, and nutritionists. Educating the patient about endometriosis, especially in small group settings, is an essential part of the rehabilitation process. Social workers focus on issues concerning reintegration into the workplace and available support services.



**Fig. 1.84** Prof. Dr. *Hans-Harald Riedel*, Head of the Department of Gynecology and Endometriosis, *Prof. Schedel Rehabilitation Center*, Kellberg, Germany.



**Fig. 1.85** Prof. Schedel Rehabilitation Center in Kellberg, near Passau (a, b). City of Passau (c). Aerial photograph of the city of Passau, where the Danube river is joined by the Inn and Ilz (d).

Since there is no causal treatment for endometriosis, patients can vary widely in their individual response to the various complementary therapies.

The rehabilitation program usually lasts 3–4 weeks. Throughout this period, the aim of the rehabilitation team is not only to achieve primary pain relief but also to develop a long-term plan and decide which therapies should be continued on an outpatient basis to consolidate the gains that have been achieved.

Details regarding surgical, endocrine and medical therapies for endometriosis are beyond our present scope and are addressed elsewhere in this book.

An important fact to remember when dealing with endometriosis patients is that there is no definite correlation between the degree of endometriosis and the severity of associated pain. This is significant because it means that patients with grade I and II endometriosis will often benefit from complementary therapy, showing good response with an improvement in their general state of health.

It is also important that the rehabilitation facility be managed by a doctor who has extensive experience in the surgical and conservative treatments available for endometriosis. The author, Prof. Dr. med. *Hans-Harald Riedel*, is Head of Department of Gynecology at the *Prof. Schedel Rehabilitation Center* and is highly experienced in the treatment of endometriosis patients. He has offered specialized endometriosis treatment and consultation for many years and has successfully established and conducted a holistic rehabilitation program for the disease. Since Prof. Riedel has a license in gynecologic endocrinology and reproductive medicine, he is specifically skilled and qualified to advise and treat endometriosis patients who suffer from fertility problems.

A holistic, inpatient rehabilitation program for endometriosis should always cover the physical, psychological, and occupational aspects of the disease. As noted earlier, the attending physician should be supported by a team of therapists from various disciplines in developing and implementing a customized treatment plan.

Rehabilitation generally starts with a complete medical workup that includes a gynecologic examination and a detailed history taken by the physician in charge. When taking the history, the physician can review previous medical records (furnished by the patient) that describe the course of the disease up to that time. Particular attention should be given to any prior operations.

It is important to determine whether the patient is suffering from active endometriosis, as this will influence the planning of treatment. For example, balneologic therapies such as partial- or full-immersion peat baths would be contraindicated in patients with current active endometriosis and associated inflammation. The laboratory workup should include erythrocyte sedimentation rate (ESR), C-reactive protein (CRP), and a full blood count to exclude the presence of active inflammation. While follow-up treatment is usually initiated within 2 weeks after hospital discharge, it should be delayed for 4–6 weeks after major surgery involving a bowel or bladder resection or ureteral reimplantation. We recommend an ultrasound examination on admission to the rehabilitation center only if there is reason to believe that significant amounts of endometriotic tissue could still be present (e.g., in the form of chocolate cysts).

The use of peat therapy should be postponed in cases of this kind. If the intake examination and laboratory tests are normal, the doctor can confer with the patient to define individual goals and to develop and prescribe an appropriate plan of treatment. All therapeutic measures should be individually tailored to the patient's physical and psychological state of health. Additional medical examinations or laboratory tests may be necessary as rehabilitation proceeds. Psychological intervention for pain management in an individual or group setting should be an integral part of endometriosis rehabilitation and should be offered from the outset as an adjunct to medical therapy and complementary treatment options. A series of goals should be defined for each individual patient based on her history and physical findings and on the outcomes of previous surgical procedures and endocrine therapies.



### 1.9.4 Possible Therapeutic Goals in Endometriosis Patients

- Gaining a general knowledge and understanding of the disease, and learning about current diagnostic methods and treatment options that can improve posture and strengthen the abdominal, pelvic-floor and back muscles.
- Reducing tension.
- Improving bowel and bladder function.
- Relieving lower abdominal and back pain.
- Improving physical fitness.
- Building self-confidence and fostering an appreciation for physical exercise.
- Helping the patient come to terms with the disease, including issues of interpersonal relationships, sexuality, and inability to achieve pregnancy.
- Learning new ways to deal with pain.
- Improving the ability to relax.
- Psychological support for patients with anxiety or depression.
- Information about relevant social legislation.
- Useful tips about support and sources for information, self-help groups etc.

Of course, the therapeutic goals listed above do not apply to every patient with endometriosis. In each individual case, the goals developed for the patient should be weighed against what can be realistically accomplished with therapy. Weekly meetings are held in which the rehabilitation team tracks the patient's progress for that week and adjusts the treatment plan as the current situation requires. Treatment should always focus on the complaints that are most distressful and disabling for the patient at the time. If and when the complementary therapies are successful, they should be continued on an outpatient basis following discharge from rehabilitation.

### 1.9.5 Rehabilitation Program

The following therapies and services are available at the *Prof. Schedel Rehabilitation Center*.

- Psychosocial care.
- Relaxation techniques.
- Art therapy.
- Nutritional counseling.
- Cooking lessons.
- Informational lectures.
- Gynecologic exercise therapy.
- Pelvic floor exercises.
- Water gymnastics.
- Balneotherapy.
- Massages.
- Electrotherapy.
- Health management and behavioral therapy.
- Workplace and social counselling.
- Sexual counseling.
- Acupuncture.

The different therapies can be modified as needed to suit patients' individual needs. Their frequency is also tailored to individual needs. If certain treatments are found to be ineffective for a patient, they are eliminated from the program. Needless to say, homeopathy, traditional Chinese medicine and phytotherapy can all be integrated into the complementary therapy program.

Within the context of the balneology, peat baths play a special role along with salt baths. The use of peat baths can achieve significant pain reduction in over 80% of patients. First, however, it is important to confirm the absence of any residual active endometrial tissue after surgery, as the use of peat therapy in these cases could have adverse effects. Vaginal peat applications may be used in patients who want to become pregnant but have ovulation problems and endometriosis.



**Fig. 1.86** Yoga session (a); gymnastic therapy (b); pelvic floor exercises (c); fitness center therapy (d); massage (e); aquatic exercises (f); art therapy (g).



Balneotherapy not only improves blood flow to the ovaries, but has also been found to increase hormone production and stimulate ovulation. Anecdotal reports from rehabilitation centers in Bad Pyrmont, Germany, indicate that numerous pregnancies were achieved with this method in the 1970s.

The combined use of gynecologic therapy, physiotherapy, balneotherapy, and physical therapy in endometriosis rehabilitation has a beneficial effect on fatigue, pain, and lethargy. Even better results can be obtained by integrating additional therapies listed above. We know, for example, that the use of homeopathy can not only relieve pain in the majority of patients treated, but also improves pregnancy rates in many women with a prior history of multiple failed attempts to conceive.

As one aspect of the rehabilitation program, it is crucial that patients receive adequate information about the disease itself and about helpful guidelines. This information can be imparted in group meetings or in individual appointments. Of course, this presupposes that the rehabilitation center is staffed with an experienced specialist who has treated all stages of endometriosis and has participated in various follow-up programs over the years. It is important for patients to understand their anatomy and cycles as well as the different types of endometriosis (active and inactive, scars). Patients should also be educated about diagnostic and surgical options, possible postoperative functional disorders, and forms of endocrine therapy that may be helpful in women who desire pregnancy. Medical and alternative pain relief should also be discussed in this context, and information can be given about participation in support groups. Every patient with endometriosis should clearly understand the nature, cause, and consequences of their chronic disease. Armed with this knowledge, patients are better able to understand and comply with their treatment regimen.

Ideally, endometriosis patients should be managed by a specialist in gynecology who is proficient in gynecologic endocrinology and reproductive medicine and has access to support and advice from a urologist and another medical specialist. This reinforces the holistic concept that is so vital in the treatment of endometriosis patients. In addition to regular visits between the attending physician and the patient, necessary ultrasound and laboratory follow-ups are scheduled as required. Moreover, exercise therapists, physiotherapists, massage therapists, the nursing team, psychologists and nutritionists meet on a regular basis to review the patient's condition and evaluate her progress. The attending physician keeps the patient apprised of the results and adjusts the treatment plan according to response. Endometriosis patients at the *Prof. Schedel Center* are treated primarily by the head of the gynecology department, Prof. Riedel. The location of the center in a very quiet, rural area in southern Germany provides an ideal setting for relaxation. With the city of Passau located just a few kilometers away, a wide range of activities are available to the patients in their leisure time.

An in-depth medical examination is scheduled one to three days before the patient is discharged from the center. The results are compared with the findings on admission to see

how well the rehabilitation goals have been met, both from the perspective of the patient and her doctor. The discharge examination includes an assessment of future employment possibilities for patients who are still in the workforce. The patients are counseled on any further outpatient therapy that may be required. Each case is summarized in a final, detailed report that includes the results of laboratory tests and other diagnostic procedures.

That report is sent directly to the referring physician. During the discharge examination, each patient is required to fill out a questionnaire from the *European Endometriosis League* to document the results of her treatment, such as a possible reduction in the severity of lower abdominal pain.

During the final consultation, patients are advised that any necessary surgical procedures in the future should be conducted only at a *Level III Endometriosis Center*. Patients are also told that, after undergoing such surgery, they are again eligible for follow-up care at a rehabilitation center. Patients who experience persistent pain are entitled to attend periodic rehabilitation sessions. Unfortunately, endometriosis has a high recurrence rate even after surgical treatment, so patients should understand the importance of having regular gynecologic checkups in an outpatient setting. It is also important to make sure that patients have been adequately educated about the disease and ways of dealing with it. This is necessary to ensure that positive rehabilitation outcomes can be maintained in the long term. After assessing the rehabilitation goals that have been achieved, the doctor and patient can decide which therapies should be continued after discharge.

A detailed description of the complementary therapies that are used during rehabilitation is beyond our present scope, but we can offer a few brief observations. Physiotherapy is used in endometriosis patients to treat the functions and structures of the human body. It includes the use of massages, exercises, and the use of water, electricity, heat, and cold. Physiotherapeutic methods stimulate the circulation, aid cardiovascular function and metabolism, promote wound healing, and contribute to pain relief. The mobility and coordination of the muscles and joints can be improved, and postural faults can be corrected.

Heat packs applied to the lower abdomen or back can help to reduce pain and ease tension. Mud and peat packs work in the same way and can be particularly helpful in patients with dysmenorrhea and diffuse lower abdominal pain. Myofascial massage can reduce tension in the muscles, nerves, and surrounding tissue. In this way it can promote circulation and relieve pain in the back and lower abdomen. Since the gynecologic organs correspond to skin areas over the sacrum, therapies addressing that region can be helpful in the treatment of dysmenorrhea as well as bladder and bowel dysfunction, which are often disclosed during the intake examination. Tension in the pelvic girdle and hip area can be treated with classic massage techniques. These help to relax cramped muscles and improve blood flow, even in deeper tissues. Scar tissue and adhesions can be loosened and pain relieved. Osteopathy can also be very helpful in this

area. This method is based on a holistic view of the body in which the hands diagnose and treat functional disturbances in the organs. The main goal in osteopathy is to restore healthy body functions in order to activate self-healing mechanisms. Endometriosis patients often have a painful limitation of motion in the sacroiliac joint. An experienced osteopath can treat this condition and achieve significant pain reduction. Reflexology of the foot is also effective in treating painful menstruation, decreased sacral motion, and venous and lymphatic swelling of the legs.

It should also be noted that environmental factors, nutrition, and exercise have a direct impact on female hormones, the menstrual cycle, and the immune system. Many studies have shown that women with endometriosis tend to have a poorer diet than healthy women. They do not eat enough fruit and vegetables and consume too much animal products and carbohydrates, including sugar. The saturated fats from animal products (sausage, meat, milk, cheese) flood the body with arachidonic acid, which can promote inflammation and pain. Typically, the diet is poor in unsaturated omega-3 fatty acids. Patients will benefit from detailed nutritional counseling with an emphasis on fruits, vegetables, and pulses (beans, lentils, chickpeas, dry peas). A healthful diet also requires an adequate intake of certain vitamins such as vitamin B complex, vitamins C, E and D, and some trace elements like selenium, magnesium, and calcium. Not only can the wrong diet be a problem, but an imbalance in the intestinal flora and an increase in certain fungi can lead to digestive problems in more than 60–80% of endometriosis patients. A special laboratory assessment of the gut microflora (so-called 'cybernetic' or microbiological status) may be indicated so that specific treatment can be instituted to restore the normal intestinal flora.

Phytotherapy ('herbal medicine') may include the use of special teas, tinctures, baths, and suppositories. Again, the selection of plant extracts should be individualized for each patient. We favor the use of mistletoe therapies because they can inhibit the growth of endometriosis lesions and stimulate the immune system in general. The agent is administered in the form of subcutaneous injections or oral droplets. Traditional Chinese medicine also plays a role and may include acupuncture, acupressure, moxibustion, and relaxation techniques such as qigong and tai chi.

Chinese medicine teaches that symptoms such as pain or infertility result from a blockage or imbalance in the human body. Life energy flows along energy channels, called meridians, which connect the different areas of the body and organs to one another. Pain can be significantly reduced in the majority of patients by using special acupuncture techniques. Sometimes the complaints resolve completely.

Because endometriosis patients experience a high level of suffering, there is often a psychosomatic component to their illness which should also be addressed. Treatment may consist of individual sessions with a psychotherapist or may involve special therapies such as the Jacobson technique of progressive muscle relaxation. This approach can improve body awareness and perception and enhance the ability to

cope with pain and the restrictions it imposes. Other therapies that can help are music and art. Additional methods such as yoga, tai chi, and qigong can harmonize the body and soul. Relationship conflicts can be addressed within the context of psychosomatic care.

Exercise is an essential part of rehabilitation. Pain can often be relieved by strengthening weak muscles. Special medical exercises, equipment-based physiotherapy, Nordic walking, water gymnastics, pelvic floor exercises, ergometer training, Pilates, and yoga, all play a role. When the discharge examination has been completed, measures are recommended that can be continued on an outpatient basis. Any fertility problems should be readdressed at this time, as it is known that 50% of endometriosis patients have difficulty becoming pregnant. If it has not already taken place, counseling can be given on the causes of endometriosis-related infertility and on available options, including in vitro fertilization.

### 1.9.6 References

1. AUGUSTIN M, SCHMIEDEL V (EDS.). Leitfaden Naturheilkunde: Methoden, Konzepte und praktische Anwendung. 4th ed. München: Urban & Fischer; 2003.
2. BARRAL J. Lehrbuch der viszeralen Osteopathie: Band 2. München: Elsevier Urban & Fischer; 2002.
3. BARRAL J, MERCIER P. Lehrbuch der viszeralen Osteopathie: Band 1. München: Elsevier Urban & Fischer; 2002.
4. BEER, A, M, OSTERMANN T. Balneogynäkologische Versorgungsstrukturen in Lehre und Therapie in Deutschland. *Phys Med Rehab Kuror* 2004;14:300–7.
5. BEILECKE K, EBERT, A, D. Urogenitale Endometriose. In: Tunn R, Hanzal E, Perucchini D, editors. *Urogynäkologie in Praxis und Klinik*, 2nd ed. Berlin, New York: DeGruyter; 2010. p. 353–73.
6. BULUN SE. Endometriosis. *N Engl J Med* 2009;360(3):268–79. doi:10.1056/NEJMra0804690.
7. DITZ S. Psychotherapieverfahren. In: Neises M, Bauer E, editors. *Psychosomatische Grundversorgung in der Frauenheilkunde: Ein Kursbuch nach den Richtlinien der DGPGG und DGGG; 52 Tabellen*. Stuttgart: Thieme; 2000. p. 35–41. (ISBN No. 9783131176516).
8. EBERT, A, D, MECHNSER S, HALIS G. Endometriose – Probleme der Diagnostik und Therapie. *CME Prakt Fortbildg, Akademos Verlag* 2005;3:54–62.
9. ENGELSING A. Homöopathische Therapie in der Endometriose. *EHZ* 2006;55(9):474–9. doi:10.1055/s-2006-932374.
10. GATJE R. Neue Trends in der Konservativen und operativen Therapie der Endometriose. *Zentralbl Gynakol* 2002;124(5):280–3. doi:10.1055/s-2002-34103.
11. GERHARD I. Akupunktur in der Sterilitätsbehandlung, Ergebnisse aus der Forschung. In: Römer A, Weigel M, Zeiger W, editors. *Akupunkturtherapie in Geburtshilfe und Frauenheilkunde*. Stuttgart: Hippokrates Verlag; 1998. p. 205–10.
12. GERHARD I, BLANK A. Berücksichtigung umweltmedizinischer Einflüsse und naturheilkundlicher Methoden. In: Keckstein J, editor. *Endometriose: Die verkannte Frauenkrankheit!? ; Diagnostik und Therapie aus ganzheitsmedizinischer Sicht*. Würzburg: Diametric-Verl; 1998. p. 75–92. (ISBN No. 3-9805677-2-9).

13. GERHARD I, MONGA B, RUNNEBAUM B. Endometriose und Umwelt. *Der Frauenarzt* 1995;36:215–9.
14. GREENMAN PE, KLOFAT I, NEUMANN H. Lehrbuch der osteopathischen Medizin: Mit 9 Tabellen ; [Grundlagen und Konzepte, Techniken und Methoden, klinische Integration und Korrelation]. 2nd ed. Stuttgart: Haug; 2003. (ISBN No. 978-3830471905).
15. HALIS G, KOPF A, MECHSNER S, BARTLEY J, THODE J, EBERT, A, D. Schmerz-therapeutische Optionen bei Endometriose. *Deutsches Ärzteblatt* 2006;968–75.
16. HRUZA K. Balneologische Anwendungen bei Endometriose. In: Flaig W, Goecke C, Kauffels W, editors. *Moortherapie – Grundlagen und Anwendungen*. Wien, Berlin: Ueberreuter-Wissenschaft; 1988. p. 251–9.
17. HUDELIST G, OBERWINKLER KH, SINGER CF, TUTTLIES F, RAUTER G, RITTER O et al. Combination of transvaginal sonography and clinical examination for preoperative diagnosis of pelvic endometriosis. *Hum Reprod* 2009;24(5):1018–24. doi:10.1093/humrep/dep013.
18. HUGHES EF. Integrating complementary and alternative medicine into clinical practice. *Clin Obstet Gynecol* 2001;44(4):902–6.
19. HUGHES EF. Overview of complementary, alternative, and integrative medicine. *Clin Obstet Gynecol* 2001;44(4):774–9.
20. KAISER B, KORELL M. Endometriose und Ernährung. München: Müller & Steinicke; 2010. (ISBN No. 978-3-87569-184-9).
21. KECKSTEIN J (ED.). Endometriose: Die verkannte Frauenkrankheit ; Diagnostik und Therapie aus ganzheitsmedizinischer Sicht. 5th ed. Würzburg: Diametric-Verl; 2009. (ISBN No. 978-3-938580-17-2).
22. KUNZ G, BEIL D, HUPPERT P, NOE M, KISSLER S, LEYENDECKER G. Adenomyosis in endometriosis – prevalence and impact on fertility. Evidence from magnetic resonance imaging. *Hum Reprod* 2005;20(8):2309–16. doi:10.1093/humrep/dei021.
23. LEENERS B, IMTHURN B. Psychosomatische Aspekte der Endometriose – aktueller Stand der wissenschaftlichen Kenntnisse und der klinischen Erfahrungen. *Gynakol Geburtshilfliche Rundsch* 2007;47(3):132–9. doi:10.1159/000102575.
24. LIEM T, ABEHSERA A (EDS.). Leitfaden Osteopathie: Parietale Techniken. 2nd ed. München: Elsevier Urban & Fischer; 2005. (ISBN No. 978-3437557811).
25. LOW DOG T. Conventional and alternative treatments for endometriosis. *Altern Ther Health Med* 2001;7(6):50–6; quiz 57.
26. MALIK E, KRESSIN, P, BUCHWEITZ O, DIEDRICH K. Endometriose und Aktivität. *Gynäkologie* 2002;35:232–7.
27. MARTIN DC, LING FW. Endometriosis and pain. *Clin Obstet Gynecol* 1999;42(3):664–86.
28. NEISES M. Psychotherapie in der Gynäkologie – Problemstellungen bei der Psychotherapie in der Frauenheilkunde. In: Faller H, editor. *Psychotherapie bei somatischen Erkrankungen*. Stuttgart: Georg Thieme Verlag; 2005. p. 128–30. (ISBN No. 9783131383914).
29. OLIVE DL, PRITTS EA. Treatment of endometriosis. *N Engl J Med* 2001;345(4):266–75. doi:10.1056/NEJM200107263450407.
30. ROSENBERG JL, RAND ML, ASAY D. Körper, Selbst und Seele: Ein Weg zur Integration. 2nd ed. Oldenburg: Transform; 1999. (ISBN No. 9783926692122).
31. SCHANTZ M, SCHMÜCK M, SILLEM M, GERHARD I. Behandlung der Endometriose. Konventionelle Therapie versus gemäß der klassischen Homöopathie – eine prospektiv vergleichende Pilotstudie. In: 169. Tagung der Mittelrheinischen Gesellschaft für Geburtshilfe und Gynäkologie: Tagungsband ; 6. bis 8. Juni 1997 Homburg/Saar. München: Alete Wiss. Dienst; 1997. (ISBN No. 3-931310-07-8).
32. SCHINDLER AE. Gonadotropin-releasing hormone agonists for prevention of postoperative adhesions: an overview. *Gynecol Endocrinol* 2004;19(1):51–5.
33. SCHLÜREN E, KUHN H. Homöopathie in Frauenheilkunde und Geburtshilfe. 8th ed. Heidelberg: Haug; 2001. (ISBN No. 978-3830470304).
34. SCHNEIDER A, TOULOUPIDIS S, PAPATSORIS AG, TRIANTAFYLIDIS A, KOLLIAS A, SCHWEPPE K. Endometriosis of the urinary tract in women of reproductive age. *Int J Urol* 2006;13(7):902–4. doi:10.1111/j.1442-2042.2006.01437.x.
35. SCHWEPPE KW. Aktive und inaktive Endometriose – eine prognose- und therapierelevante Differentialdiagnose. *Zentralbl Gynakol* 1999;121(7):330–5.
36. SCHWEPPE KW, EBERT A D, KIESEL L. Endometriosezentren und Qualitätsmanagement. *Gynäkologie* 2010;43:223–40.
37. SIEGEL EV, TRAUTMANN-VOIGT S, VOIGT B. Analytische Bewegungs- und Tanztherapie. München: Reinhardt; 1999. (ISBN No. 3-497-01512-1).
38. TAYLOR H, GUARNACCIA M, OLIVE D. Alternative medical treatment for endometriosis. *Semin Reprod Endocrinol* 1997;15(3):285–90. doi:10.1055/s-2008-1068758.
39. WEINSCHENK S. Naturheilkundliche Prinzipien der Endometriosebehandlung. In: Behrendt W, Gerhard I, editors. *NATUM – Naturheilkunde und Umweltmedizin in der Frauenheilkunde*. Stuttgart: Hippokrates; 1996–2000. p. 161–6. (ISBN No. 3-7773-1249-5).
40. WEINSCHENK S (ED.). Leitfaden Neuraltherapie. München: Urban & Fischer in Elsevier; 2007. (ISBN No. 343757020X).



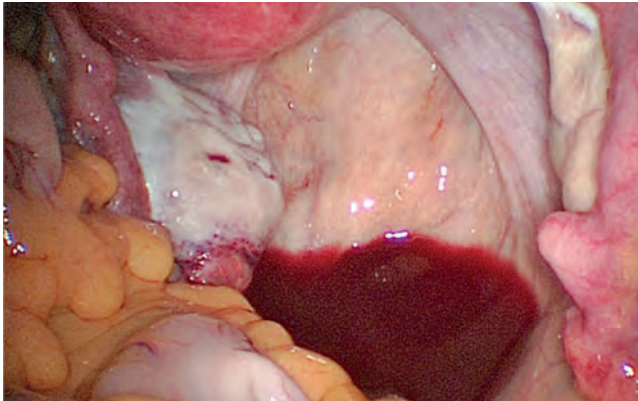
## 1.10

## Endometriosis and Nutrition

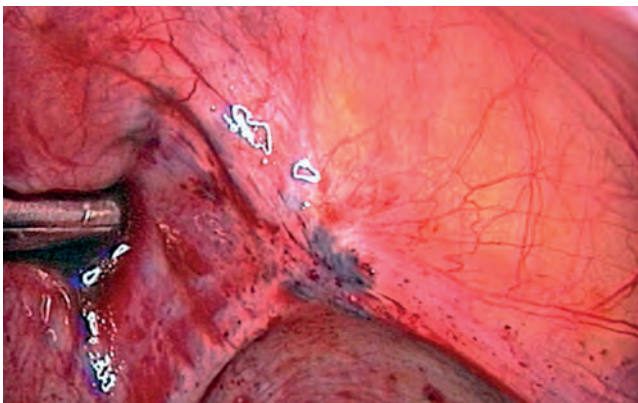
Matthias Korell<sup>a</sup>

## 1.10.1 Introduction

Endometriosis is a very common disease that imposes a significant burden on women afflicted by this condition. Even though endometriosis is amenable to a standard therapeutic approach consisting of surgery and hormonal treatment, efficacy has been limited and associated with a high recurrence rate.<sup>3</sup> A multitude of theories have been proposed on the etiology of endometriosis, and probably more than one theory is needed to build a thorough understanding of the highly complex and multifactorial nature of the disorder. The ‘*implantation theory*,’ for example, with its concept of retrograde menstruation, is among the oldest theories on this topic and was described by *Sampson* in 1927.<sup>16</sup> Retrograde



**Fig. 1.87** Residual blood in the cul-de-sac after menstruation.



**Fig. 1.88** Endometriotic implant on the right pelvic sidewall.

<sup>a</sup> | Professor, MD; Head of Department of Gynecology and Obstetrics, Johanna Etienne Hospital, Neuss, Germany

**Corresponding author:**

Prof. Dr. med. **Matthias Korell**  
 Chefarzt Gynäkologie  
 Klinik für Frauenheilkunde  
 Johanna Etienne Krankenhaus  
 Am Hasenberg 46  
 41462 Neuss, Germany  
 E-mail: m.korell@ak-neuss.de

menstruation is a fairly common diagnosis in clinical practice (Fig. 1.87). It seems very likely that endometriotic cells are implanted in the cul-de-sac, which is considered a site of predilection for endometriosis. To date, however, none of the various hypotheses on the etiology of endometriosis has been validated conclusively by scientific evidence.

Irrespective of the unknown etiology, we can see how the body ‘fights’ against endometriosis in every affected patient by noting the hemosiderin deposits, fibrotic tissue, and neoangiogenesis that are present in a typical implant (Fig. 1.88).

So then, if most women have retrograde menstruation, for example, why is endometriosis not present in every one of them? Expressed another way, one may raise the question as to what are the ‘condiments’ needed in a ‘recipe for endometriosis?’

## 1.10.2 History

More than 50 years ago, *Ansel Keys* demonstrated the tremendous impact of nutrition on coronary heart disease and brought the ‘Mediterranean diet’ to popular attention.<sup>8</sup> The *European Prospective Investigation into Cancer and Nutrition (EPIC)* study documented a dramatic reduction of diabetes (–93%), myocardial infarction (–81%), stroke (–50%), and an overall reduction of cancer development (–36%) by a ‘healthy’ diet consisting of low meat consumption and a high intake of fruits, vegetables, and whole-grain bread.<sup>5</sup>

## 1.10.2.1 But What About Endometriosis?

In their book ‘*Endometriosis – A Key to Healing through Nutrition*’, *Vernon and Mills* instituted a new approach to dealing with this disease.<sup>22</sup> The question is whether it can truly ‘fill the void left by the traditional treatment of endometriosis and provide physicians and patients with additional options,’ as stated on the book cover.

In recent years there has been a growing body of evidence to support the influence of nutrition on endometriosis in both retrospective<sup>14</sup> and prospective trials.<sup>12</sup>

## 1.10.3 Study Results

*Parazzini et al.* investigated nutritional patterns in 504 patients with confirmed endometriosis and compared it with 504 matched pairs without endometriosis.<sup>14</sup> A significant difference was noted between the two groups in their intake of red meat, ham, vegetables, and fresh fruits. While a high consumption of ham and red meat was found predominantly in patients with endometriosis, women without endometriosis showed a higher intake of vegetables and fresh fruit (Table 1.2, Fig. 1.89).

- < 3 x/week red meat → 50 % less risk of endometriosis compared with > 6 x/week.
- > 13 x/week vegetables → 70 % less risk of endometriosis compared with < 6 x/week.
- > 13 x/week fruits → 40 % less risk of endometriosis compared with < 6 x/week.

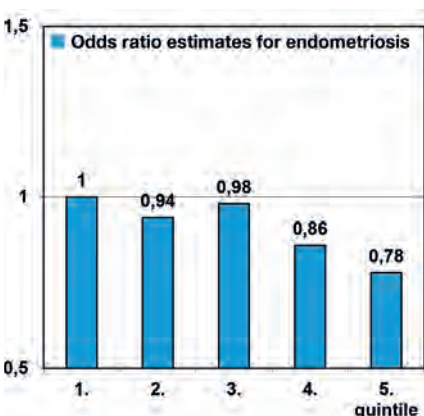
**Table 1.2** Reduced endometriosis risk by intake of selected foods expressed by odds ratio estimates (OR).<sup>14</sup>



**Fig. 1.89** Typical vegetables featured in the Mediterranean diet.

One limitation of this study is its retrospective design using matched pairs. However, there have been other, prospective studies conducted over a long period to investigate a possible link between nutritional habits and endometriosis risk.

In one prospective study, *Missmer et al.* used the enormous data pool from the *Nurses' Health Study II* to correlate fat consumption with the incidence of histologically confirmed endometriosis.<sup>12</sup> Starting in 1989, nutritional patterns were investigated via a food frequency questionnaire in 1991, 1995, and 1999. Women with the highest intake level of omega-3 fatty acids had a 22 % lower risk of endometriosis than those with the lowest consumption (**Fig. 1.90**). On the other hand, the highest consumption of trans fatty acids contributed to a rise of incidence by 48 % (**Fig. 1.91**). This study demonstrates that fat consumption plays a central role in the incidence of endometriosis.



**Fig. 1.90** Incidence of endometriosis relative to the intake of omega-3 fatty acids. First quintile = lowest intake, 5<sup>th</sup> quintile = highest intake.<sup>12</sup>

This suggests a possible benefit from a diet of fish and vegetables. However, fish intake should be limited due to marine pollution with rising levels of heavy metals and dioxins.<sup>17</sup> Specifically, cadmium is a 'metalloestrogen' suspected of increasing the risk of endometriosis. The oral intake of heavy metals and dioxins is of great importance in settings where air pollution appears to play a minor role.<sup>10,15,20</sup> A safer alternative to seafood would be to increase the consumption of omega-3 fatty acids through plant sources such as linseed.<sup>1</sup>

#### 1.10.4 Discussion

The influence of nutrition on general health is widely accepted but frequently underused. As an example, the development of type 2 diabetes mellitus could be prevented and treated more effectively with an appropriate diet than with conventional pharmacologic medication.<sup>9</sup>

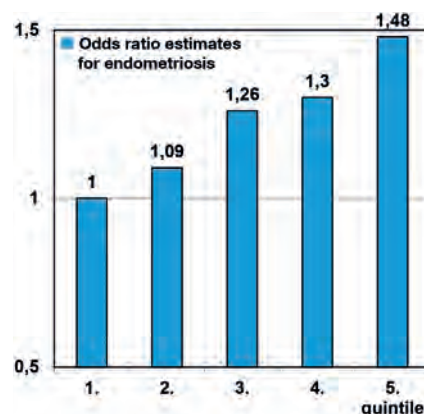
Several studies have shown that nutritional patterns have a significant impact on the prospective incidence of endometriosis. Besides the importance of vegetables as in the Mediterranean diet, the intake of fat has the greatest influence. Omega-3 fatty acids reduce the incidence of endometriosis, whereas trans fatty acids increase it.<sup>12</sup>

#### 1.10.5 Nutritional Patterns and Endometrial Cancer

The stimulation of endometrial growth appears to do more than provide an ideal environment for endometriosis. Estrogen dominance could also increase the risk of endometrial cancer. It has been shown that adherence to the Mediterranean diet leads to a 57 % reduction in the incidence of endometrial cancer.<sup>4</sup> A high intake of vegetables alone leads to a risk reduction of 36 %.

##### 1.10.5.1 Role of Dairy Fat?

It appears that milk and red meat contribute to the development of endometriosis in different ways. The source of animal fat is relevant to its biological effect on the endometrium. Women who consume more than three servings of total dairy food per day have an 18 % lower risk of endometriosis compared with two servings per day.<sup>6</sup> Accordingly, women with a high intake of dairy products have a 16 % lower risk of endometrial cancer compared with a low intake.<sup>4</sup> High dairy intake was also found to correlate with a significant risk reduction for endometrioid ovarian cancer.<sup>11</sup>



**Fig. 1.91** Incidence of endometriosis relative to the intake of trans fatty acids. – 1. First quintile = lowest intake, 5<sup>th</sup> quintile = highest intake.<sup>12</sup>

### 1.10.5.2 'An Apple or a Pill?'

The 'modern' path to better nutrition is often to reach for vitamin supplements.<sup>23</sup> Darling *et al.* compared the incidence of endometriosis relative to different amounts of vitamin intake from food sources versus vitamin supplements.<sup>2</sup> Figs. 1.92 and 1.93 show the results for vitamin C and E, respectively, which are similar for all the vitamins tested. A preventive effect was demonstrated only for vitamins ingested from food sources. None of the vitamin supplements had any preventive effect on the incidence of endometriosis in this prospective study.

Multivitamin supplements were also found to be without benefit. There was no difference in the incidence of endometriosis, even with daily multivitamin use (Fig. 1.94).

### 1.10.5.3 Nutrition and Endometriosis – Prevention and/or Therapy?

Available data on the correlation between nutrition and the incidence of endometriosis support the preventive effects of a special diet (Figs. 1.90–1.93). But what about women who are already diagnosed with endometriosis? Is it possible to modify the course of endometriosis, comparable to the reversal of coronary heart disease, by implementing lifestyle changes?<sup>13</sup>

There is evidence for the efficacy of omega-3 fatty acids, vitamins B1, B3, and E, and magnesium in relieving pain and reducing the need for additional medication.<sup>18</sup> These

substances may act by reducing the release of prostaglandins, which can cause inflammation, pain, and spastic uterine contractions. Vitamin E, for example, was found to be effective in the treatment of primary dysmenorrhea.<sup>24</sup> A prospective randomized study found that a special diet could reduce pain severity relative to a placebo when rated on a visual analog scale (VAS scores of 4.7 vs. 6.2 on a 0–10 point scale) and was just as effective as GnRHa or a contraceptive pill (VAS 5.3 vs. 5.0).<sup>19</sup> In our experience, nutritional counseling alone can lead to a significant reduction in pain level from 6.7 (VAS) before counseling to 3.2 afterward.<sup>7</sup> We found a concomitant gain in well-being from 2.6 to 6.6<sup>7</sup> (Fig. 1.95).

We do not know how effective a nutritional change is for secondary prophylaxis in patients with confirmed endometriosis. Nevertheless, the existing data support the claim that nutritional counseling should be an important component of multimodal therapy in patients with endometriosis. Especially in women who desire pregnancy or have other contraindications to oral contraceptive use, nutritional counseling offers patients a self-determined alternative tool.

The role of nutrition in women at risk for endometriosis should be included in published guidelines.<sup>3,21</sup> This could be helpful not only for the patients themselves but also for their daughters.

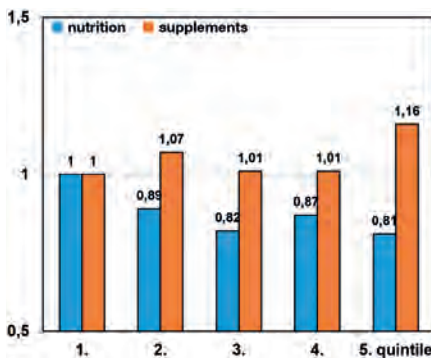


Fig. 1.92 Incidence of endometriosis relative to the intake of vitamin C from food sources versus supplements. First quintile = lowest intake, 5<sup>th</sup> quintile = highest intake.<sup>2</sup>

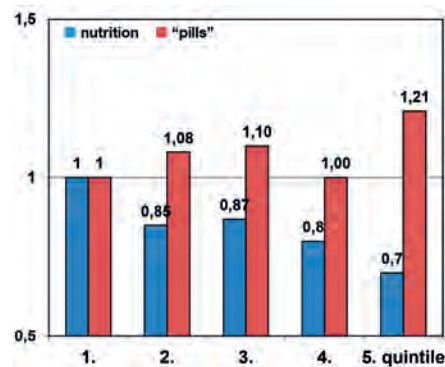


Fig. 1.93 Incidence of endometriosis relative to the intake of vitamin E from food sources versus supplements. First quintile = lowest intake, 5<sup>th</sup> quintile = highest intake.<sup>2</sup>

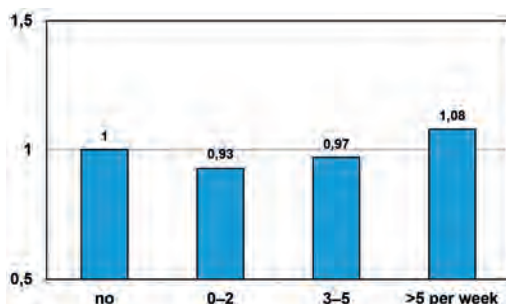


Fig. 1.94 Incidence of endometriosis (odds ratio) relative to the intake of multivitamin supplements.<sup>2</sup>

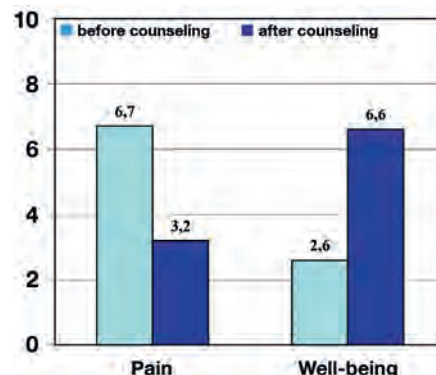


Fig. 1.95 Effects of nutritional counseling on pain and well-being, assessed on a 10-point visual analog scale.<sup>7</sup>



### 1.10.6 Conclusion

Studies have clearly shown that nutritional habits have a significant and relevant effect on the incidence of endometriosis. Nutritional recommendations should be included in the guidelines. Identifying the various contributing factors for the development and course of endometriosis will be the future challenge in our efforts to better understand this common disease. Nutrition appears to be one of these factors. Patients and physicians should be more aware of its importance.

### 1.10.7 References

- BENAÏSSA N, MERZOUK H, MERZOUK SA, NARCE M. Effects of Maternal Linseed Oil Supplementation on Metabolic Parameters in Cafeteria Diet-induced Obese Rats. *Biomed Environ Sci* 2015;28(4):298–302. doi:10.3967/bes2015.041.
- DARLING AM, CHAVARRO JE, MALSPEIS S, HARRIS HR, MISSMER SA. A prospective cohort study of Vitamins B, C, E, and multivitamin intake and endometriosis. *J Endometr* 2013;5(1): 17–26. doi:10.5301/je.5000151.
- DUNSELMAN GA, VERMEULEN N, BECKER C, CALHAZ-JORGE C, D'HOOGHE T, BIE B DE et al. ESHRE guideline: management of women with endometriosis. *Hum Reprod* 2014;29(3):400–12. doi:10.1093/humrep/det457.
- FILOMENO M, BOSETTI C, BIDOLI E, LEVI F, SERRAINO D, MONTELLA M et al. Mediterranean diet and risk of endometrial cancer: a pooled analysis of three Italian case-control studies. *Br J Cancer* 2015;112(11):1816–21. doi:10.1038/bjc.2015.153.
- FORD ES, BERGMANN MM, KROGER J, SCHIENKIEWITZ A, WEIKERT C, BOEING H. Healthy living is the best revenge: findings from the European Prospective Investigation Into Cancer and Nutrition-Potsdam study. *Arch Intern Med* 2009;169(15):1355–62. doi:10.1001/archinternmed.2009.237.
- HARRIS HR, CHAVARRO JE, MALSPEIS S, WILLETT WC, MISSMER SA. Dairy-food, calcium, magnesium, and vitamin D intake and endometriosis: a prospective cohort study. *Am J Epidemiol* 2013;177(5):420–30. doi:10.1093/aje/kws247.
- KAISER B, KORELL M. Ergebnisse der Ernährungsberatung bei Frauen mit Endometriose. *J Gynäkol Endokrinol* 2008;18(2):58–61.
- KEYS A. Diet and the epidemiology of coronary heart disease. *J Am Med Assoc* 1957;164(17):1912–9.
- KNOWLER WC, BARRETT-CONNOR E, FOWLER SE, HAMMAN RF, LACHIN JM, WALKER EA et al. Reduction in the incidence of type 2 diabetes with lifestyle intervention or metformin. *N Engl J Med* 2002;346(6):393–403. doi:10.1056/NEJMoa012512.
- MAHALINGAIAH S, HART JE, LADEN F, ASCHENGRAU A, MISSMER SA. Air pollution exposures during adulthood and risk of endometriosis in the Nurses' Health Study II. *Environ Health Perspect* 2014;122(1):58–64. doi:10.1289/ehp.1306627.
- MERRITT MA, POOLE EM, HANKINSON SE, WILLETT WC, TWOROGER SS. Dairy food and nutrient intake in different life periods in relation to risk of ovarian cancer. *Cancer Causes Control* 2014;25(7):795–808. doi:10.1007/s10552-014-0381-7.
- MISSMER SA, CHAVARRO JE, MALSPEIS S, BERTONE-JOHNSON ER, HORNSTEIN MD, SPIEGELMAN D et al. A prospective study of dietary fat consumption and endometriosis risk. *Hum Reprod* 2010;25(6):1528–35. doi:10.1093/humrep/deq044.
- ORNISH D, SCHERWITZ LW, BILLINGS JH, BROWN SE, GOULD KL, MERRITT TA et al. Intensive lifestyle changes for reversal of coronary heart disease. *JAMA* 1998;280(23):2001–7.
- PARAZZINI F, CHIAFFARINO F, SURACE M, CHATENOU D, CIPRIANI S, CHIANTERA V et al. Selected food intake and risk of endometriosis. *Hum Reprod* 2004;19(8):1755–9. doi:10.1093/humrep/deh395.
- RZYMSKI P, TOMCZYK K, PONIEDZIALEK B, OPALA T, WILCZAK M. Impact of heavy metals on the female reproductive system. *Ann Agric Environ Med* 2015;22(2):259–64. doi:10.5604/12321966.1152077.
- SAMPSON JA. Peritoneal endometriosis due to the menstrual dissemination of endometrial tissue into the peritoneal cavity. *Am J Obstet Gynecol* 1927(14):422–69.
- SARKAR A, RAY D, SHRIVASTAVA AN, SARKER S. Molecular Biomarkers: their significance and application in marine pollution monitoring. *Ecotoxicology* 2006;15(4):333–40. doi:10.1007/s10646-006-0069-1.
- SESTI F, CAPOZZOLO T, PIETROPOLLI A, COLLALTI M, BOLLEA, PICCIONE E. Dietary therapy: a new strategy for management of chronic pelvic pain. *Nutr Res Rev* 2011;24(1):31–8. doi:10.1017/S0954422410000272.
- SESTI F, PIETROPOLLI A, CAPOZZOLO T, BROCCOLI P, PIERANGELI S, BOLLEA et al. Hormonal suppression treatment or dietary therapy versus placebo in the control of painful symptoms after conservative surgery for endometriosis stage III-IV. A randomized comparative trial. *Fertil Steril* 2007;88(6):1541–7. doi:10.1016/j.fertnstert.2007.01.053.
- SOAVE I, CASERTA D, WENGER JM, DESSOLE S, PERINO A, MARCI R. Environment and Endometriosis: a toxic relationship. *Eur Rev Med Pharmacol Sci* 2015;19(11):1964–72.
- ULRICH U, BUCHWEITZ O, GREB R, KECKSTEIN J, LEFFERN I VON, OPPELT P et al. National German Guideline (S2k): Guideline for the Diagnosis and Treatment of Endometriosis: Long Version - AWMF Registry No. 015-045. *Geburtshilfe Frauenheilkd* 2014;74(12):1104–18. doi:10.1055/s-0034-1383187.
- VERNON M, MILLS DS. A key to healing through nutrition. London: Thorsons; 2002. (ISBN No. 0007133103).
- WALLACE TC. Twenty Years of the Dietary Supplement Health and Education Act – How Should Dietary Supplements Be Regulated? *J Nutr* 2015;145(8):1683–6. doi:10.3945/jn.115.211102.
- ZIAEI S, ZAKERI M, KAZEMNEJAD A. A randomised controlled trial of vitamin E in the treatment of primary dysmenorrhoea. *BJOG* 2005;112(4):466–9. doi:10.1111/j.1471-0528.2004.00495.x.

## 1.11

## Organisation of an Endometriosis Centre

Neil P. Johnson<sup>a</sup> | Tal Jacobson<sup>b</sup>

### 1.11.1 Introduction

Models of care for women with endometriosis are as diverse as there are clinicians with a passion and commitment to treating endometriosis.<sup>2</sup> The crux of this is that there has traditionally been no consensus and there are no guidelines as to how an endometriosis centre should be organised.

Over the years the concept of the endometriosis centre of excellence.<sup>2</sup> has been replaced by the endometriosis network of expertise,<sup>6</sup> illustrating that an endometriosis centre does not need to be sited, for example, in an academic teaching centre, and in fact may have multiple geographical loci contributing to the centre, as long as all the essential ingredients are present in such a 'network'.

At the core of a network of expertise is the ability to consistently deliver co-ordinated care for women with endometriosis within a multi-disciplinary centre or network of accredited practitioners, who each specialise in a specific discipline.<sup>2</sup>

So what are the key ingredients for a successful endometriosis network of expertise? There remains no agreed definition of a network or centre of expertise for endometriosis nor for its accreditation requirements. One simple and aspirational definition of a centre of excellence was 'a place where the highest standards of achievement are aimed for in a particular sphere of activity'.<sup>5</sup> There is agreement that a network of expertise should include specialists who have undergone specific training in endometriosis, advanced surgeons with a high case-load of managing deep endometriosis, ready access to an endometriosis organisation with substantial input on behalf of women, and a track record of commitment to collaborative research.<sup>6</sup>

Whilst unclear in terms of definition, the aims of networks of expertise might be considered from a global perspective as reducing time to diagnosis and reducing time to individualised specialist care; increasing evidence based treatment and reducing the requirement for fertility treatment if the disease is controlled before fertility is affected.<sup>2</sup>

It is tempting to think that the services provided by a network of expertise will inevitably be better than that received

outside of a network of expertise setting, although there is little evidence for this. This would be difficult to investigate adequately. Once a 'centre' has gone down the pathway of setting up a network of expertise, it might be considered a retrograde step to then randomise women to care through the network of expertise versus traditional care outside the network of expertise setting. However this would be a valuable piece of research that a centre could undertake if there were funding restrictions to delivery of services such that not every woman with endometriosis could receive care through the network of expertise. In settings in which access to a network of expertise is restricted, a randomised controlled trial investigating its effectiveness (versus 'standard care') would be a more valuable method of allocating women to the scarce resource of the network of expertise rather than setting rationing criteria to undertake this allocation. Despite the lack of evidence, there is majority consensus the *World Endometriosis Society Montpellier Consortium*, supporting the 'good practice point' statement '*individualised care benefits from a multi-disciplinary network of experts sufficiently skilled in providing advice on and treatment of endometriosis and its associated symptoms, based on the best available knowledge, their extensive experience, and their transparent record of success rates*'.<sup>6</sup>

### 1.11.2 Attributes of a Network of Expertise

It is only by setting specific standards and monitoring those standards that it will be possible to assess outcomes from a network of expertise. The standards to be achieved should preferably relate to clinical outcomes. Improved quality of life should be the main aim, thus there is a need for auditable standards that reflect this. For endometriosis this could mean improved objective quality of life measures, lowered pain symptoms, increased fertility, lower complication rates etc. There are many secondary or alternative outcomes that may be relevant such as waiting times, patient satisfaction rates, cost effectiveness and research outputs.

#### 1.11.2.1 Audit

To define these outcomes there must be audit undertaken in order to assess each network's outcomes and establish local, national or international benchmarking to compare those outcomes to. Audit and self assessment is therefore a primary component of any network of expertise.

#### 1.11.2.2 Criteria

In a UK study that surveyed consultant gynaecologists,<sup>3</sup> 85% expressed support for centres of excellence and many felt that a colorectal surgeon, pain management team, specialist nurse, access to counselling and access to complementary therapies were important components of a centre of excellence.

<sup>a</sup> | Professor, MD, CREI, FRANZCOG, FRCOG, MRCGP; World Endometriosis Society; Robinson Research Institute; University of Adelaide, South Australia

<sup>b</sup> | Dr, MA, MBBS, FRCOG, FRANZCOG; University of Auckland; Repromed Auckland, New Zealand; Mater Hospital Brisbane, Queensland, Australia; University of Queensland; Eve Health, Queensland Fertility Group, Brisbane

#### Corresponding author:

Professor **Neil P Johnson** MD CREI FRANZCOG FRCOG MRCGP  
Repromed Auckland, 105 Remuera Road, Auckland, New Zealand  
E-mail: neiljohnson1964@gmail.com

Around the latter part of the first decade of this millennium, the *British Society of Gynaecological Endoscopy (BSGE)* proposed specific criteria for its members to have their centres accepted as centres of excellence.<sup>5</sup> It required the centre to treat a minimum of 12 rectovaginal nodules per year, have a named colorectal surgeon, submit data to a national database, surgeons to attend centre meetings and be willing to hold meetings for other UK centres of excellence. Other criteria included a willingness to demonstrate surgery, have a pelvic pain specialist in addition to gynaecological/colorectal surgeons, and a dedicated pelvic pain clinic scheduled for appropriate patients

The original report defining centres/networks of excellence suggested that they should be defined by 'proper training, adherence to evidence-based guidelines, quality management and continuous measurement of patient outcome as a central focus'.<sup>2</sup>

### 1.11.2.3 Models

There are number of potential models for networks of expertise. With a team approach there may be a group of gynaecologists with an interest in endometriosis. The service delivery is likely to be guideline-based and have an institutional approach to treatment rather than that of a specific surgeon. There is also the individual approach with an expert and highly experienced surgeon running his or her practice. They are likely to have developed their own highly skilled support or multidisciplinary team. Other models may involve collaboration over several sites with relevant expertise being coordinated by an endometriosis expert who may not themselves have the specific surgical skills or facilities to provide the more complex surgery that is sometimes required. This latter model might be regarded as the 'network of expertise' model. In the United States, the *American Association of Gynecological Laparoscopists (AAGL)* have partnered with the *Surgical Review Corporation* and developed a program to designate *Centres of Excellence in Minimally Invasive Gynecology (COEMIG)*. Although it does not focus specifically on endometriosis they have defined a specific set of criteria that are required for accreditation as a COEMIG.<sup>8</sup> These include surgical experience with surgeons required to have performed a minimum of 50 qualifying gynaecological laparoscopic procedures in the preceding 24 months. Clinical care pathways must be established and patients must be provided with comprehensive preoperative patient education. Collaboration with and access to appropriately qualified and experienced specialists including an anaesthetist, vascular surgeon, general surgeon, urologist and radiologist are required. Facilities must provide ongoing, regularly scheduled education programs in minimally invasive gynaecological surgery and collect prospective outcome data on all patients.<sup>8</sup>

### 1.11.3 Establishing a Network of Expertise

Both authors were involved in establishing a self-defined network of expertise (which, at the time, we called a centre of excellence) with a group of like-minded colleagues in 2006.\*

\* <http://www.endometriosisauckland.co.nz>

\*\* <http://www.nzendo.org.nz/>

In order to do this there was considerable discussion about the attributes of a network of expertise and the following were identified as important components of a network of expertise:

- Offer evidence-based surgical, medical, alternative and supportive therapy;
- Encourage a multidisciplinary approach;
- Collect data with a view to critically analysing and auditing the centre;
- Link with an endometriosis organisation (part of the function of which is a patient support group) and promote education and information sharing for women with endometriosis about the condition and its management – this is something that *Endometriosis New Zealand*,\*\* the world's longest standing patient-representative – led endometriosis organisation has done with great success;
- Promote education for fellow specialists and general practitioners;
- Promote and undertake research into endometriosis;
- Foster national and international collaborations with other networks of expertise.

In order to achieve these goals, the services highlighted in [Table 1.3](#) need to be available – the lists have been stratified in order to see how a network of expertise can evolve as expertise and facilities improve.

Components of an endometriosis centre / network of expertise	
<b>Essential</b>	<ul style="list-style-type: none"> <li>■ Adequate case mix</li> <li>■ Adequate frequency of complex cases</li> <li>■ Colorectal surgeon</li> <li>■ Dedicated theatre team</li> <li>■ Audit and risk management process</li> <li>■ Evidence based approach</li> </ul>
<b>Preferable</b>	<ul style="list-style-type: none"> <li>■ Accreditation</li> <li>■ Links with patient support groups</li> <li>■ Specialist nurse</li> <li>■ More than one gynaecological surgeon</li> <li>■ Pain Team</li> <li>■ Urologist</li> <li>■ Specialist physiotherapist</li> <li>■ Specialist psychologist</li> <li>■ Future participation in EPHeCT</li> </ul>
<b>Desirable</b>	<ul style="list-style-type: none"> <li>■ Close ties with tertiary fertility services</li> <li>■ Links with other centres/networks of expertise</li> <li>■ Digital operating theatre environment</li> <li>■ Research focus</li> <li>■ Run training courses and demonstrate surgery</li> <li>■ Able to train future specialists</li> <li>■ Links with complementary therapists</li> </ul>

**Table 1.3** Components of an endometriosis centre / network of expertise.



Centres or networks of expertise (as an example of evidence from observational studies)		
Description	Either a centre or a network in which a multidisciplinary team of experts collaborate to optimise the management.	
Mechanism of action	Precise definitions of a centre or network of expertise, along with its accreditation requirements, yet to be finalised. Most experts agree this should include specialists who have undergone specific training in endometriosis, advanced surgeons with a high caseload of managing deep endometriosis, ready access to an endometriosis organisation with substantial input on behalf of women, and a track record of commitment to collaborative research. The centre/network should have a transparent record of outcome-based success rates.	
Volume of evidence	Observational studies only.	
Consistency of evidence	Unclear.	
Applicability of evidence	Probably applicable, but on-going evaluation important.	
Effectiveness	Proving effectiveness of centres/networks of expertise is elusive, but logic suggests that, based on the sound principles/mechanisms of a centres/network of expertise, outcomes for women should be improved.	
Adverse effects	Minimal	
* GRADE – evidence quality	Moderate – observational studies and expert opinion only, but there appears to be no down side to the development of centres/networks of expertise.	
** Consensus statement and grading	Women with endometriosis require individualised care over a long term period, where priorities may change owing to the type and severity of symptoms, impact of these symptoms, current or future fertility wish, and lifestyle factors (strong GPP ***).	α
	Individualised care benefits from a multi-disciplinary network of experts sufficiently skilled in providing advice on and treatment of endometriosis and its associated symptoms, based on the best available knowledge, their extensive experience, and their transparent record of success rates (strong GPP).	β
References	<i>D'Hooghe and Hummelshoj, 2006</i> <sup>2</sup>	
* Criteria for assigning grade of evidence to observational studies – supplied to members of the WES Montpellier Consortium (can be applied to observational studies as well as interventions). <sup>6</sup>		
** Criteria for 'α' (unanimous or near unanimous) consensus was where more than 80% of contributors agreed without caveat and fewer than 5% disagreed; 'β' (unanimous with caveat) consensus was where fewer than 5% disagreed, but fewer than 80% agreed without caveat.		
*** Good Practice Point (GPP)		

**Table 1.4** Evidence table for networks of expertise from WES Montpellier consortium on current treatment of endometriosis. Reproduced with permission from *Human Reproduction*.<sup>6</sup>

### 1.11.3.1 Essential Components of a Network of Expertise

An adequate case mix is important to allow a centre/network to gain experience, maintain skills and offer training. There may be considerable variation in complexity of surgical cases as well as different patient need regarding fertility or pain control.

Case frequency is a reflection of the level of specialisation of the centre/network and in the case of a single practitioner there needs to be adequate case numbers to justify a 'network of expertise' status. The BSGE previously defined this as at least 12 operations for rectovaginal nodules per year.<sup>5</sup> Other specialists may view this as less relevant to their practice but still consider their service to be a network of expertise.

It would be expected that a network of expertise would offer a laparoscopic approach to surgery as the default approach as there are clear and well known advantages over laparotomy.<sup>6</sup>

- Collaboration with a colorectal surgeon with an interest in endometriosis and preferably the training and experience to operate laparoscopically is an essential part of any network of expertise.
- The nature and complexity of the surgical procedures would be optimised by a dedicated theatre team in order to provide consistent and safe outcomes.
- The importance of audit and the relevant audit tools has already been discussed above.

### 1.11.3.2 Preferable Components of a Network of Expertise

As the attributes of a network of expertise become more closely defined and accepted it will be important to be involved in an accreditation process that recognises and gives legitimacy to the individual centre. This process is likely to vary between territories but eventually this will become an essential rather than preferable component of a network of expertise. The *World Endometriosis Society (WES)* is interested in defining more precisely these attributes, but whether this organisation is the one that becomes responsible for such accreditation standards internationally is moot.

The role of the specialist nurse is of great value to a network of expertise. Their role may vary in different settings including involvement in patient education; assisting surgery and patient follow up.

In the authors' view there are real advantages to having two or more gynaecological surgeons involved in a network of expertise. This allows for sharing of knowledge and skills, the ability to discuss complex patients regularly and provide cover for weekends, nights and holidays which may otherwise be lacking in some settings. A range of other multi-disciplinary specialists can be included in a network of expertise. In particular an urologist for cases with ureteric involvement. Again, some gynaecological laparoscopic surgical experts will be happy to proceed with these procedures but in a setting where a urologist is available it is prudent for the urologist to be involved in the re-anastomosis or re-implantation of a ureter.

Pain specialists or a formal pain team have a highly specialised perspective on pain management and can be very valuable in the more challenging cases.

The link with layperson-led professional endometriosis organisations and patient support groups is highly valued by many patients. The focus of patient support groups clearly

varies in different settings and it is important that the network of expertise has a constructive and mutual understanding of the service that is available and vice versa.

Direct links to a physiotherapist with expertise in women's health, a psychologist with a similar focus, a dietician and a highly experienced endometriosis patient educator (whose role might also be fulfilled by a specialist nurse) are of prime importance.

### 1.11.3.3 Desirable Components of a Network of Expertise

Surgical equipment is an important part of surgical treatment of endometriosis and although no specific equipment is necessary the development of integrated digital laparoscopic theatres has enhanced the ergonomics of laparoscopic surgery and the ability to document procedures. In some settings there are significant constraints on operating time. If an institution is able to facilitate long complex procedures with relative ease, this is beneficial.

For many women with endometriosis fertility is a very important component of their treatment and it is desirable for one or more of the gynaecologists in the network of expertise to have involvement with tertiary fertility services which would allow seamless transfer or integration into those services.

Research is an important part of the development of the specialty and should be considered to be a highly desirable component of a network of expertise. The evidence base of endometriosis management is growing but there remain many unanswered questions and it is reasonable to expect networks of expertise to contribute to the published literature in this field.

Although there are no randomised controlled trials to show that complementary therapies are beneficial there are many individual studies of less exacting design suggesting benefit from complementary therapies, which should be considered and offered through a network of expertise if appropriate.

## 1.11.5 References

1. BECKER CM, LAUFER, STRATTON P, HUMMELSHOJ L, MISSMER SA, ZONDERVAN KT et al. World Endometriosis Research Foundation Endometriosis Phenome and Biobanking Harmonisation Project: I. Surgical phenotype data collection in endometriosis research. *Fertil Steril* 2014;102(5):1213–22. doi:10.1016/j.fertnstert.2014.07.709.
2. D'HOOGHE T, HUMMELSHOJ L. Multi-disciplinary centres/networks of excellence for endometriosis management and research: a proposal. *Hum Reprod* 2006;21(11):2743–8. doi:10.1093/humrep/del123.
3. ENGLISH J, FORD J. Centres of excellence for the management of advanced endometriosis: Where are they and what do they do? *Gynecol Surg* 2004;1(3). doi:10.1007/s10397-004-0039-7.
4. FASSBENDER A, RAHMIOGLU N, VITONIS AF, VIGANO P, GIUDICE LC, D'HOOGHE TM et al. World Endometriosis Research Foundation Endometriosis Phenome and Biobanking Harmonisation Project: IV. Tissue collection, processing, and storage in endometriosis research. *Fertil Steril* 2014;102(5):1244–53. doi:10.1016/j.fertnstert.2014.07.1209.
5. JACOBSON T. Developing consensus on endometriosis centres of excellence. In: Rombauts L (ed.). *World Endometriosis Soc eJournal* 2009; July–August.
6. JOHNSON NP, HUMMELSHOJ L. The World Endometriosis Society Montpellier Consortium. Consensus on Current Management of Endometriosis. *Hum Reprod* 2013;28(6):1552–68. doi:10.1093/humrep/det050.
7. KONINCKX PR. Videoregistration of surgery should be used as a quality control. *J Minim Invasive Gynecol* 2008;15(2):248–53. doi:10.1016/j.jmig.2007.12.001.
8. MOAWAD NS. Centers of excellence in minimally invasive gynecology: Raising the bar for quality in women's health. *WJOG* 2014;3(1):1. doi:10.5317/wjog.v3.i1.1.
9. RAHMIOGLU N, FASSBENDER A, VITONIS AF, TWOROGER SS, HUMMELSHOJ L, D'HOOGHE TM et al. World Endometriosis Research Foundation Endometriosis Phenome and Biobanking Harmonization Project: III. Fluid biospecimen collection, processing, and storage in endometriosis research. *Fertil Steril* 2014;102(5):1233–43. doi:10.1016/j.fertnstert.2014.07.1208.

### 1.11.3.4 Critical Ingredients for Network of Expertise in the Future

The importance of collecting data that can be harmonised with those collected in other centres is increasingly recognised as being key, not only to maintaining standards across centres of expertise, but also to the ability to pool data with those of other centres/networks, in order to work collaboratively to improve our collective understanding of endometriosis. The *EPHect (Endometriosis Phenome and Biobanking Harmonisation) Programme*<sup>1,4,9,10</sup> is a distillation of a number of years work by experts appointed by the *World Endometriosis Research Foundation (WERF)* that is a unique tool through which all networks of expertise can work collaboratively to combine data, undertake collaborative research and, without doubt, presents an opportunity to advance understanding in the field of endometriosis at a uniquely rapid pace.

There are templates for collection of demographic and clinical data from women who have (or might have) endometriosis prior to surgery.<sup>10</sup> There are templates for standardisation of the date collected at the time of surgery – including standardised way to undertake laparoscopy for diagnostic purposes and objective recording of standardised laparoscopic photographs in order to document surgical findings,<sup>1</sup> although there is a groundswell of support for video-laparoscopy recording in order to optimally document objectively and archive laparoscopic findings.<sup>7</sup> There are also standardised techniques for fluid biospecimen<sup>9</sup> and tissue<sup>4</sup> collection.

It seems likely, in the near future, that centres will need to be part of the global EPHect programme to be truly considered to be part of a global network of expertise.

## 1.11.4 Conclusion

The concept of a network of expertise (replacing the more traditional concept of a centre of excellence) for endometriosis is valid and as formal criteria and accreditation are established it is hoped that the goal of improved outcomes for women with endometriosis will be achieved.

10. VITONIS AF, VINCENT K, RAHMIOGLU N, FASSBENDER A, BUCK LGM, HUMMELSHOJ L et al. World Endometriosis Research Foundation Endometriosis Phenome and Biobanking Harmonization Project: II. Clinical and covariate phenotype data collection in endometriosis research. *Fertil Steril* 2014;102(5): 1223–32. doi:10.1016/j.fertnstert.2014.07.1244.



## 1.12

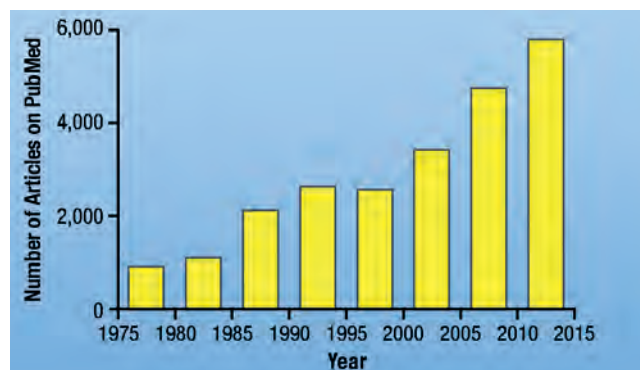
## Epidemiology of Endometriosis

Philippe R. Koninckx<sup>a,b</sup> | Anastasia Ussia<sup>c,b</sup> | Jörg Keckstein<sup>d</sup> | Arnaud Wattiez<sup>e</sup> | Leila Adamyan<sup>f</sup>

### 1.12.1 Introduction

Endometriosis is still poorly understood despite 22,398 peer-reviewed articles on PubMed (1 Feb, 2016) and 9.13 million search hits on Google, surpassing even the entries for 'hysterectomy' (8 million) and 'oral contraception' (3.5 million). The number of publications on endometriosis doubled after 1980, owing largely to the advent of laparoscopy. The exponential rise in publications since 2000 underscores the hype and information glut that have come to surround the topic of endometriosis (Fig. 1.96). This is also reflected in the rising number of congresses focused on endometriosis, the burgeoning discussion groups on social media, and the proliferation of lobbying groups throughout the world.

Endometriosis has not been adequately defined to date, and the criteria used for differential diagnosis have changed over time, contributing to biases in the literature. With the advent of laparoscopy, endometriosis was described as consisting of severe lesions occasionally found during surgery, such as deep rectovaginal endometriosis and cystic ovarian endometriosis as described in the early 20<sup>th</sup> century,<sup>15–17,72,73,100,101</sup> as well as other lesions in the pelvis<sup>13,103</sup> or umbilicus.<sup>64</sup> After the introduction of endoscopy in the late 1960s, the apparent prevalence increased as black-puckered endometriotic lesions became a frequent observation in women with pain and/or infertility.<sup>10</sup> In the mid-1980s, the prevalence of the disease almost doubled due to the observation that nonpigmented or subtle lesions contained glands and stroma.<sup>38,67,69,106</sup> From



**Fig. 1.96** Number of articles on endometriosis listed on PubMed, indicated for 5-year periods since 1975.

the 1990s onwards, the detection of deep endometriosis was dramatically improved, and this increased the apparent prevalence even further.

Both the pathophysiology and natural history of endometriosis are poorly understood. It remains unclear whether endometriosis constitutes one or several different entities. It is a widely accepted hypothesis that endometriosis is chronic in nature, has a major adverse impact on fertility, and is associated with chronic pelvic pain. It remains controversial whether endometriosis is a progressive and recurrent disease. Our limited understanding of the disease is at odds with the substantial costs incurred by prolonged absence from work, medical and surgical therapies, infertility treatments and frequent reoperations.

The epidemiology of endometriosis is an issue of vital importance, and the ongoing lively debate among healthcare providers seems to suggest that the prevalence and severity of endometriosis have been rising due to societal factors. Indeed, the prevalence of endometriosis has purportedly been linked to our modern style of living.<sup>24,113</sup> Some authors relate the disease to environmental exposures (e.g., dioxin, polychlorinated biphenyls (PCB), radiation) while others have characterized it as a 'career woman's disease.' The validity of available epidemiological data is limited by the following factors:

- Laparoscopic confirmation is needed to establish the diagnosis.
- Recognition depends on the expertise and specific interest of the laparoscopist.
- Pathology confirms the presumptive diagnosis in just 50 to 90 % of cases.
- The diagnostic criteria used to define endometriotic lesions, and thus the observed prevalence, have varied constantly over time.

<sup>a</sup> | Professor emeritus Ob-Gyn KU Leuven, Belgium; University of Oxford-Honorary Consultant, UK; Università Cattolica, Rome, Italy and Moscow State University, Russia

<sup>b</sup> | Gruppo Italo Belga, Villa del Rosario, Rome, Italy

<sup>c</sup> | MD, Consultant Università Cattolica, Rome, Italy

<sup>d</sup> | Professor, MD; Head of Department of Gynecology and Obstetrics, Certified Clinical-Scientific Level III Center for Endometriosis Care, Certified Breast Care Center, State Hospital of Villach, Carinthia, Austria

<sup>e</sup> | MD; Head of Gynecology Department, Latifa Hospital, Dubai, United Arab Emirates; Director of Advanced Courses in Gynecological Endoscopy at IRCAD/ EITS, Strasbourg, France

<sup>f</sup> | MD, PhD, Professor; Head Specialist in Obstetrics and Gynecology of Russian Ministry of Healthcare and Social Development Head of Department of Surgical Gynecology Head of Department of Reproductive Medicine and Surgery, Faculty of Postgraduate Education, Moscow State University of Medicine and Dentistry

#### Corresponding author:

##### Philippe R. Koninckx

Vuilenbos 2, 3360 Bierbeek, Belgium

E-mail: Pkoninckx@gmail.com

#### Note:

The content of this subsection is adapted from:

Koninckx PR, et al. (2016).<sup>62</sup> Copyright permission by courtesy of Springer International Publishing AG, Cham, Switzerland.

Thus, before discussing the epidemiology of endometriosis from a clinician's point of view, the authors will present a concise definition of endometriosis, address its pathophysiology and natural history, and explain why there is so much confusion about endometriosis.

### 1.12.2 What is Endometriosis?

It is the authors' opinion that the definition of endometriosis as 'endometrial glands and stroma outside the uterus' should be changed.

Endometriosis was defined more than a century years ago as the extrauterine presence of endometrial glands and stroma. As early as 1899, *Russell*<sup>99</sup> wrote, 'Upon microscopic study of the ovary, we were astonished to find areas which were an exact prototype of the uterine glands and interglandular connective tissue.' At the turn of the century, *Cullen*<sup>15-17,40</sup> and *Meyer*<sup>72,73</sup> described 'adenomyosis externa,' which is known today as deep endometriosis. The term 'endometriosis'<sup>100,101</sup> was introduced by *Sampson* when he described glands and stroma in ovarian 'chocolate cysts.' In 1940 he described the theory of retrograde menstruation and implantation,<sup>102</sup> and in 1942 *Gruenwald* advanced the theory of metaplasia.<sup>28</sup> Endometriosis was thus defined on the basis of pathology – the only tool available at that time – as 'endometrial glands and stroma outside the uterus.' This definition had the advantage of simplicity; it was widely adopted and is still in use today. We should note, however, that a histologic description is not the same as the definition of a disease, and that this definition has never been proven or experimentally tested. In fact, when viewed from a current perspective, this 'historical' definition should be considered incomplete and a frequent source of error.

It is generally known that 'glands and stroma outside the uterus' are not always classified as pathology. Based on the observation that retrograde menstruation<sup>35,55</sup> occurs in almost all women, and considering that the phenomenon involves viable cells,<sup>63</sup> it was logical to postulate that implantation should occur more frequently, perhaps even in all women, and to look for early lesions that arise from tissue implantation on the peritoneum. This led to the description of minimal lesions by *scanning electron microscopy* (SEM)<sup>78,110</sup> and to the detection of macroscopically visible nonpigmented lesions,<sup>38,40</sup> later called 'subtle lesions',<sup>106</sup> and of microscopic lesions found on normal-looking peritoneum in some 20 % of women.<sup>80</sup> This even led to techniques such as peritoneal washings<sup>92</sup> and blood painting<sup>94</sup> to diagnose microscopic endometriosis.

Since macroscopically visible subtle lesions were found in up to 90 % of women with pain and or infertility<sup>58</sup> (Fig. 1.97), and considering that these subtle lesions could undergo fundamental changes such as disappearing and reappearing at other sites, it was suggested that subtle lesions were a normal condition occurring at least intermittently in all women.<sup>47</sup> To the best of our knowledge, no evidence has been furnished to date that subtle lesions are a cause of infertility or pain. Indeed, there is even some evidence that subtle lesions do not cause infertility since the luteinized unruptured follicle syndrome – an established cause of infertility – is associated with typical

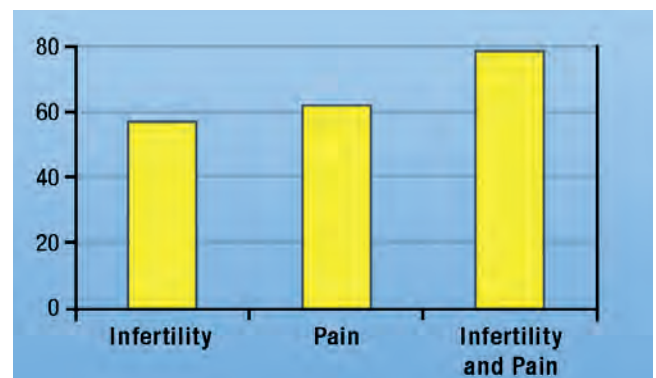
lesions and not with subtle lesions.<sup>48</sup> This finding necessarily holds true for microscopic endometriosis as well.

In a recent study, glands and stroma were found in the perirectal lymph nodes in 18 to 20 % of women with deep endometriosis.<sup>71</sup> On the other hand, no one has yet described any clinical pathology that can be linked to this finding. Similarly, in bowel resections performed for deep endometriosis, clusters of glands and stroma may be found up to 5 cm from the nodule.<sup>4</sup> It should be noted that recurrence rates after bowel resections and after a more conservative discoid or local resection for deep endometriosis are not manifestly different from each other. This finding is strong evidence that these microscopic clusters of glands and stroma should not always be classified as pathology.

In conclusion, clinical observational evidence strongly suggests that subtle lesions and microscopic glands and stroma do occur in most women, at least intermittently. Given that no proven clinical significance has yet been attributed to these findings, it seems obvious that they should be considered normal. This does not contradict the concept that some of these extrauterine clusters of endometrial glands and stroma could have the potential to develop into more severe lesions. Unfortunately, today we cannot distinguish between extrauterine glands and stroma that have no clinical significance and may disappear spontaneously, and those that will develop into endometriosis causing pain and infertility.<sup>54</sup> The authors recommended, therefore, that the general term 'endometriosis' be replaced with more specific nomenclature: *subtle endometriosis*, *typical endometriosis*, *cystic endometriosis* and *deep endometriosis*. This distinction would help to prevent much of the current confusion surrounding the topic.

#### 1.12.2.1 Pathophysiology and Natural History

None of the classic pathogenetic theories such as retrograde menstruation,<sup>102</sup> coelomic metaplasia<sup>28</sup> and Müllerian remnants can explain all the different types of endometriosis described so far.<sup>112</sup> Indeed, clinical observation has revealed an increased incidence of endometriotic lesions in women with obstructed outflow.<sup>2,3,81,108</sup> Endometriosis was also detected in a woman with Rokitsansky-Kuster-Hauser syndrome, however, and even in one male patient. A common finding in all these observations is that once implantation or metaplasia has taken place, the normal endometrial cells will inevitably develop into typical



**Fig. 1.97** Prevalence of endometriosis in women with **infertility** (n = 1297), **pain** (n = 918), and **infertility plus pain** (n=267).<sup>58</sup>

cystic ovarian lesions or into deep lesions. Clearly, however, this hypothesis is not consistent with clinical observations<sup>95</sup> when we note that most of the lesions do not progress after implantation and may even resolve spontaneously. While some lesions may still have the potential to progress, this theory fails to explain why the development of disease occurs only in some women and why progression manifests with typical, cystic, or deep lesions.<sup>112</sup>

The endometriotic disease theory<sup>56</sup> postulates the occurrence of a cellular incident or mutation similar to that seen with most benign tumors, and that the type of mutation is a crucial determinant mediating the course of progression into typical, cystic, or deep endometriosis. This theory is supported by the fact that endometriosis is hereditary<sup>31–34,42–44,79</sup> and that cystic and deep lesions are clonal in origin.<sup>40,107,116</sup> Moreover, the theory is consistent with the observation that dioxin and total body irradiation, both acting at the level of the genome, may be causally related to the onset of endometriotic disease.<sup>49</sup> Even though these cells can grow and develop, they will nonetheless be contained by the immune defense mechanisms of the body. This results in ‘powder burn’ lesions with fibrotic or scar tissue as remnants of local inflammation, containing some endometrial cells and shielded from the bloodstream and immunocompetent cells, comparable to bacteria harbored in an abscess. Cellular incidents are more common in predisposed women, and the many differences seen in the endometrium of women with or without endometriosis should be interpreted as an underlying cause rather than a consequence of endometriosis.

Regardless of whether endometriosis cells should be classified as normal (*Sampson*) or abnormal (endometriotic disease theory), the environment of these cells obviously seems to be abnormal considering that the peritoneal cavity and peritoneal fluid are a specific microenvironment determined by various factors such as concentrations and chronological pathways of steroid hormones, cytokines, immune defense mechanisms,<sup>5,21</sup> angiogenic factors and many others which differ greatly from those in plasma and the intrauterine milieu.<sup>57</sup> Similarly, the intraovarian hormone concentrations are even much higher. Aside from that, immunological defense in women suffering from endometriosis is different insofar as there is decreased natural killer cell activity in the plasma<sup>84</sup> and in peritoneal fluid.<sup>88</sup> This defective immune surveillance is presumed to exist before the onset of disease, as it does not correct after surgery.<sup>86</sup> Apart from the very specific properties of the endocrine environment, the uterine endometrium is bordered by the junctional zone, which appears to play a key role in maternal immune system adaptation to pregnancy as well as the induction of physiologic changes in the spiral arteries.<sup>8,12</sup>

The natural history of endometriosis is not yet fully understood, and the misconception persists that endometriosis is a progressive and recurrent disease. This rationale is rooted in Sampson’s theory, but conclusive evidence is still lacking. Clinical observation suggests that endometriosis is **not** a recurrent disease. Indeed, the range of recurrence rates after surgery is 5 to 10 % for cystic endometriosis and even less for deep endometriosis. These clinical findings are not consistent

with a recurrent disease. Moreover, endometriosis is **not** a progressive disease. Clinical observation clearly indicates that at the time of diagnosis, most endometriotic lesions no longer exhibit a progressive course. Based on histopathologic analysis, the majority of lesions exhibit an inactive, ‘burned-out’ state while deep lesions, when followed longitudinally, remain mostly unchanged, at least over a period of several years. In our experience, however, approximately 10 out of 3,000 deep endometriotic nodules undergo rapid proliferative growth, which is confirmed both by clinical observation and by their macroscopic appearance at surgery.

### 1.12.2.2 Conclusion: Typical, Cystic, and Deep Endometriosis are Different Diseases

In the absence of any evidence that microscopic endometriosis, subtle lesions, glands and stroma in lymph nodes, and lesions located up to 5 cm from a deep endometriotic nodule of the bowel can progress or cause pain or infertility, these findings should not be classified as a disease but rather as a natural condition occurring (intermittently) in all women. The clinical impact of this conclusion is far-ranging. Indeed, women with microscopic or subtle lesions should not be concerned about the risk of progression. This also provides a compelling rationale to opt for a more conservative approach in the treatment of bowel endometriosis and to refrain from the use of bowel resection intended for complete surgical removal.

The pathogenetic theories such as retrograde menstruation (*Sampson*),<sup>102</sup> coelomic metaplasia,<sup>28</sup> and Müllerian remnants are manifestly incomplete to explain the disease. According to the endometriotic disease theory, the major contributing factors to disease onset are the type of cellular incident, such as mutation, as well as the specific milieu and the individual immunologic profile of the patient. Some of these lesions will grow for a period of time and develop into typical, cystic, or deep lesions as determined by interactions between the aforementioned factors. Following this period of growth, the great majority of these lesions – similar to most fibromas – will remain inactive for a variable period of time. A small number of deep lesions, however, may spontaneously exhibit a rapidly progressive course, although the cause of quiescence or growth reactivation remains unclear. Most importantly, no one to date has observed or described the evolution of one type of endometriosis into another. There is only rare anecdotal evidence for the progression of one type of endometriosis.<sup>1</sup> Apart from that, not all deep lesions are biochemically similar since during pregnancy most will decidualize and become inactive while others will grow during stimulation and pregnancy, and some may even cause a spontaneous bowel or bladder rupture.<sup>104</sup>

Typical, cystic, and deep endometriotic lesions are different pathologic entities, and the authors postulate that in the future we will even be able to distinguish different types of deep endometriosis. This is consistent with the current explanatory model of uterine leiomyoma formation, in which different genomic alterations have been described and different patients may have quite different responses to pharmacologic agents such as ulipristal acetate.



The epidemiology of typical, cystic, and deep endometriosis should be discussed separately, therefore, similar to the epidemiologies of other entities as adenomyosis, peritoneal pockets, Müllerianosis and stromatosis.

### 1.12.3 Why is There So Much Confusion Over Endometriosis?

Pain, infertility, and irregular or abnormal bleeding are major complaints in gynecology, and endometriosis has been linked to all of these symptoms. Oral contraceptives, which are the most commonly prescribed drugs in women, have also been applied in the treatment of pain and endometriosis. Endometriosis, moreover, has been linked to a great variety of factors such as diet, fatigue, and infection.

#### 1.12.3.1 Lack of an Animal Model

The lack of an animal model has greatly limited our ability to investigate the pathophysiology, natural history, and medical treatment of endometriosis. Aside from the fact that occasional spontaneous typical and cystic endometriosis have been observed in baboons and rhesus monkeys, experimental attempts to induce these lesions have been inconsistent. The many articles describing systematic retrograde menstruation and its consequences in baboons are actually viewed with doubt and are omitted from professional discussions. Indeed, one study found that retrograde menstruation did not occur in baboons even after cervical ligation.<sup>22</sup> What remains are important observations such as the heredity of spontaneous typical lesions, that total body irradiation<sup>25</sup> incites typical endometriotic lesions, and that dioxin induces cystic ovarian endometriosis of dose-dependent severity.<sup>97</sup> In one study, lesions similar to deep endometriosis were produced by injecting slices of endometrium with myometrium.<sup>22</sup> These data are consistent with the fact that it takes many years before a genomic incident becomes apparent.<sup>96,97</sup> The relationship between functional endometrium, basal endometrium, and the junctional zone certainly warrants further investigation, particularly as it relates to the concept of stem cells.

#### 1.12.3.2 Problems with the Endometriosis Literature

We have described the problems with the endometriosis literature as the ‘elephant in the room.’<sup>150</sup> Given the multitude of published articles, it is virtually impossible to read them all and conduct an adequate review. Quality control is another issue, since the publication costs for online journals are paid by the authors, not by readers. In addition, as search engines become more powerful and authors use key words in titles and abstracts, most of us have time to read only the abstract, without reviewing the original data. This situation, coupled with the numerous lay press articles, websites and social media, results in information that is confusing, not always supported by data, and often erroneous.

#### 1.12.3.3 Overuse of Medical Therapy Without a Diagnosis

Medical therapy can at best make endometriotic lesions less active and can reduce pain, but not in all women. Since patients are often young and the great majority of physicians avoid surgery, many women are treated medically for years

before they are diagnosed. We should realize that there is little evidence for the belief that medical therapy can prevent lesion progression or recurrence. The evidence is limited to scant data on the progression of typical lesions<sup>65</sup> and on recurrences during the initial months after surgery for cystic ovarian endometriosis. It is conceivable that some lesions may grow during prolonged medical therapy, making subsequent surgery more difficult. Though unlikely, it must be acknowledged that the widespread use of medical therapy to prevent surgery may contribute to the epidemiology of endometriosis.

#### 1.12.3.4 Difficulties in the Diagnosis of Typical, Cystic, and Deep Endometriosis

The diagnosis of typical lesions requires laparoscopy. The recognition of typical lesions varies with the expertise of the surgeon, and the rate of histologic confirmation is only 76%<sup>75</sup> or even 50%.<sup>115</sup> Endometriosis of the diaphragm is underreported since not all surgeons will systematically inspect the diaphragm with a 30° scope in a steep anti-Trendelenburg position. The detection rate of subtle lesions is unspecified in most reports.

Cystic ovarian endometriosis cannot be consistently diagnosed with ultrasound, which has a sensitivity and specificity of approximately 90%.<sup>37,66</sup> The most common source of error is a cystic corpus luteum, which may persist as a ‘chocolate cyst’ for more than 4 months even during treatment with an LH-RH agonist or oral contraceptive. Ca125 levels are also of limited value.<sup>60</sup> Cystic endometriosis can even be difficult to diagnose at laparoscopy. CA125 in chocolate fluid has been reported to have a sensitivity and specificity of nearly 100%,<sup>61</sup> but there is no stick assay or other rapid test available for intraoperative use. Since cystic ovarian endometriosis is so strongly associated with adhesions,<sup>58</sup> a clinical rule of thumb is that a ‘chocolate cyst’ without adhesions is almost always a cystic corpus luteum. Given the diagnostic difficulties, one group of authors recommended inspecting the interior of the cyst by ovarioscopy<sup>9</sup> to help make a correct diagnosis, noting that ‘Those with a flattened appearance and red or red and brown mottled ridges generally were endometriosis, and those with a dark uniform base, an intracavitary clot, or a yellowish rim generally were corpus luteum or albicans.’ Another bias stems from the fact that it is generally unclear whether a diagnosis has been confirmed by pathology. When surgical pathology is available, the report often describes the cyst as being ‘compatible with endometriosis’ without positively identifying endometrial glands or stroma. This problem is well known, especially for larger cysts, but is rarely addressed specifically in the literature, making it difficult to judge the accuracy of the diagnosis.<sup>11,68</sup>

The clinical diagnosis of deep endometriosis is unreliable, since only about 50% of larger nodules are detected on routine clinical exam.<sup>58,59</sup> Even during menstruation, high-sited deep endometriosis will be missed on physical examination. MRI and ultrasound have no more than 90% overall sensitivity and specificity, and it is unclear whether imaging is really helpful in diagnosing smaller foci of deep endometriosis. Even during surgery, some deep endometriotic lesions are difficult to find,

especially when located in the sigmoid colon or cecum, and often the surgeon is faced with the dilemma of doing nothing or proceeding with the risk of making a hole in the bowel. The sciatic nerve and sacral nerve roots are other potential sites where endometriosis is likely to be missed.

In conclusion, the reliability of the reported prevalences of typical, cystic, and deep endometriosis will vary with the interest of the surgeon. A major problem is the reliability of large databases with hospital discharge records. The lack of reliability was noted in a comment<sup>52</sup> on a report that endometriosis risk increased with dietary fat consumption.

#### 1.12.3.5 Misunderstanding of Evidence-Based Medicine

Evidence-based medicine is a common source of misunderstanding. A randomized controlled trial (RCT) is mathematically ideal, but this study design requires strict randomization to neutralize confounding variables, blinding to eliminate outcome bias, and large case numbers to detect infrequent problems. In addition, most RCTs apply strict inclusion and exclusion criteria to increase sensitivity, but this makes it difficult to extrapolate the results to the population as a whole. To date, only one rigorously blinded RCT has investigated the medical treatment of pain in endometriosis, finding that tumor necrosis factor  $\alpha$  (TNF $\alpha$ ) was ineffective for deep endometriosis.<sup>53</sup> The many other reported trials have limited validity, since blinding of the patients was not done and was even impossible with drugs that affected menstruation. This is in line with the many problems of industry-sponsored RCTs, as recently reported.<sup>29,111</sup>

The only definitive treatment for endometriosis is surgical excision. It is beyond the scope of this chapter to review the results of surgical excision. What is clear, however, is that RCTs are difficult to perform in women with severe endometriosis since the numbers required are prohibitive, and the outcome will always reflect the skill and expertise of the surgeon and will vary over time.

#### 1.12.3.6 We Should Manage our Patients rather than 'Treat Endometriosis'

Endometriosis is not a life-threatening disease and does not require treatment in the absence of symptoms. In symptomatic women, diagnosis and counseling should come first, followed by informed consent before treatment. Informed consent is a problematic issue. First, it presupposes that the information given is correct. Second, medical treatment does not require written informed consent, while informed consent rarely mentions what information was furnished. Disclosure is obviously difficult for an ill-defined disease with an unknown pathophysiology and natural history. Moreover, a large majority of doctors who do not perform surgery tend to exaggerate the risk of complications, while pelvic surgeons are a small group. It is equally unclear whether preoperative informed consent should include information on the experience, results, and complications of the individual surgeon.

#### 1.12.3.7 Conclusion

In order to understand the epidemiology of typical, cystic, and deep endometriosis, we should understand the problems

associated with the baboon model, the biases in the endometriosis literature, the problems of disease recognition and reporting, and the limited value of randomized controlled trials when blinding is impossible for a drug affecting menstruation, or when outcomes vary with the skill of the surgeon.

### 1.12.4 Why Do We Have the Impression that Prevalence is Increasing ?

#### 1.12.4.1 Focus on Endometriosis

Since endometriosis may be the cause of almost any gynecologic complaint such as infertility, pain, or bleeding problems as well as fatigue and sexual problems, it is not surprising that both patients and doctors will consider endometriosis in almost all symptomatic cases. Also, given that the diagnosis cannot be confirmed or excluded without laparoscopy, many women without a diagnosis are still treated for endometriosis and live with the idea that they have endometriosis. Their fears are compounded by the common beliefs that endometriosis causes infertility, is progressive, increases the risk of a hysterectomy later in life, and is untreatable except by surgery, which can be dangerous. This climate in the age of social media is sufficient to explain the hype.

After the millennium, we have also come to appreciate the problems of pollution, radiation, and global warming as significant concerns. Pollution and waste products such as dioxins and PCBs have been linked to the development of endometriosis, especially severe endometriosis. Additionally, in recent decades we have witnessed a progressive postponement of the first pregnancy, which is a cofactor in reducing fertility. This increases the pressure on women to seek immediate infertility treatment if they do not achieve pregnancy within a short time. Considering the prevalence of subtle lesions, a laparoscopy will almost invariably detect endometriosis in these women, strengthening the belief that endometriosis is very widespread and causes infertility.

These factors contribute to the fact that the focus on and fear of endometriosis are steadily rising, as evidenced by the growing number of support groups.

#### 1.12.4.2 Bias of Prevalence Data

We previously noted the gradual shifts in the definition of endometriosis over time. The most important development was the recognition of subtle endometriosis in the mid-1980s, which has increased the apparent prevalence of endometriosis. The tendency to confuse cystic ovarian endometriosis and cystic corpora lutea may account for up to 30% of reported cases. The growing awareness of deep endometriosis has increased the apparent prevalence. The fact that smaller deep lesions are usually undetected even at laparoscopy suggests that the prevalence of deep endometriosis is underreported.

To understand the epidemiology of endometriosis, it is important to note the inherent inaccuracy of the data that we have. Superficial endometriosis can be diagnosed only by laparoscopy. And when laparoscopy is performed, it is generally

unclear whether lesions are of the subtle or typical type. The most widely used system for classifying endometriosis, the rASRM classification, does not even make this distinction. One bias in surgeons who scrutinize women with pain or infertility is rarely considered: the finding of endometriosis is perceived as a relief because it fulfills the need to ‘get a diagnosis.’

Ultrasound has unrivaled accuracy and sensitivity in the diagnosis of cystic ovarian endometriosis. Whereas until recently an ovarian cyst smaller than 2–3 cm was not considered pathologic, the sensitivity of modern ultrasound – now a routine examination at many centers – has been inflating the diagnosis of cystic ovarian lesions. As a result, it has become unclear whether small foci of cystic ovarian endometriosis should be left alone, should be treated by transvaginal hydroculdoscopy in young women,<sup>27</sup> or whether we should proceed to IVF without surgery.

Deep endometriosis is considered the ultimate surgical challenge in gynecology. Thus it is likely that most centers will exaggerate the diagnosis of deep endometriosis in order to belong to the club of hospitals that perform deep endometriosis surgery. The large number of endometriosis centers in the UK has at least given that impression. Major deep endometriosis surgery is technically demanding and is fraught with potential complications. Before conservative surgery was largely replaced by bowel resections, which can be performed by any gastrointestinal surgeon, referral for deep endometriosis was done systematically, and the referrals increased with the growing awareness and diagnosis of deep endometriosis. This referral bias has been obvious in Leuven, Oxford, and later in Rome. Moreover, the number and size of the deep endometriosis nodules has increased over the years. A third bias is that today most women seen in the larger units have already had two or more previous operations. Surgery becomes more complicated and prolonged, which gives the erroneous impression that the severity of endometriosis is increasing relative to the period when most patients did not have prior surgery.

Endometriosis is widely believed to be associated with pain and infertility. It is much less clear that these lesions are the cause of the pain or infertility. In the case of subtle lesions, there is no evidence of a cause-and-effect relationship. For typical lesions as well, it is uncertain that pain disappears or fertility improves after surgical excision – a discussion which is beyond the scope of this chapter.

## 1.12.5 Epidemiology

### 1.12.5.1 Prevalence, Age, and Heredity

With all the limitations imposed by the inherent selection bias in Leuven, in 1991 we found that endometriosis was present in 71 % of a group of 900 women with pain and/or infertility. Among the women found to have endometriosis, 49 % had subtle lesions, 29 % had typical lesions, 31 % had cystic ovarian endometriosis, and 18 % had deep endometriosis. Although the overall incidence remained constant with age, subtle lesions decreased significantly with age whereas typical, cystic, and deep lesions increased with age<sup>58</sup>(Fig. 1.98).

Endometriosis is clearly an hereditary disease<sup>33,43,44;31–34,79;105</sup> The prevalence in first-degree relatives is approximately 7 times higher than in control groups and is up to 15 times higher in monozygotic twins. Genome-wide association studies have identified common genetic variants.<sup>26,36,41,77,91</sup> Severity and early onset also appear to be hereditary.

Endometriosis is more frequent and more severe in women with outflow obstruction.<sup>2,3,81,108</sup>

### 1.12.5.2 Subtle Endometriosis

The prevalence of subtle lesions decreases with age.<sup>58,93</sup>

There are no data to show that prevalence is increasing. No studies are available demonstrating a clear association with any of the variables considered important such as early menarche, short cycles, heavy or painful periods, subfertility, canalization defects of the cervix, race, dioxin exposure, total body radiation, or any other factor.

### 1.12.5.3 Typical Endometriosis

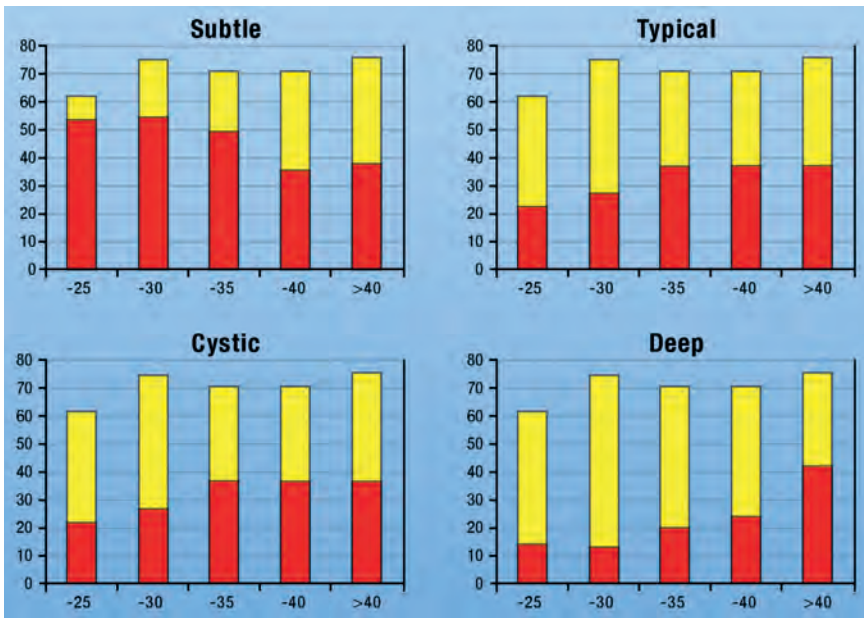
Epidemiological data deal almost exclusively with typical lesions. While it is generally unclear whether subtle lesions were included as endometriosis, we will assume that typical endometriosis contributes predominantly to the reported prevalences.

The prevalence in asymptomatic women was approximately 4 % of women undergoing tubal ligation.<sup>115</sup> A prevalence of 0.16 % white females aged 15–49 was reported in the U.S. during the 1970s,<sup>14</sup> as compared with 2.2 % in a large study comprising all women in one county in Norway.<sup>76</sup> In this study early menarche, frequent menstruations, pelvic pain, infertility, and nulliparity were associated with endometriosis.

A controlled study found similar rates of stage I endometriosis in women with infertility and a normal partner and in women with an azoospermic partner. Stage II endometriosis was found to be more common in the infertile women (3.3 % vs. 5.7 %).<sup>70</sup>

Higher incidences have been found in women with pain. Fifty percent of teenagers with intractable dysmenorrhea had endometriosis.<sup>39</sup> Prevalences of 40 to 70 % were reported in women with pain and infertility, resulting in 33 % after meta-analysis.<sup>30</sup> There is a nonvalidated clinical impression that endometriosis could vary with race, as blacks have been noted to have lower rates and Asians higher rates than in whites. The





**Fig. 1.98** Prevalence (red) of subtle, typical, and deep endometriosis in women with infertility ( $n = 1297$ ), pain ( $n = 918$ ), and infertility plus pain ( $n = 267$ ). Subtle endometriosis declines with age whereas typical, cystic, and deep endometriosis tend to increase with age. The total prevalence (yellow) remains unchanged.<sup>58</sup>

belief that endometriosis increases with earlier menarche and heavy retrograde menstruation has not been substantiated in women. Data describing an increased prevalence in primates with obstructed uterine outflow were not confirmed by subsequent studies showing that the primates did not have retrograde menstruation. It has been suggested that dioxin exposure is causally related to endometriosis,<sup>97,98</sup> but evidence in humans is scanty.<sup>36,49,51</sup> The Seveso accident, which involved massive population exposure, was associated with a nonsignificant doubling of prevalence.<sup>23</sup> Although breast-fed girls should be exposed to dioxins in milk, an unexpectedly lower rate of endometriosis was reported in their adult life.<sup>109</sup> There are no data linking total body irradiation to an increased prevalence of endometriosis in humans.

Decreased natural-killer-cell activity in plasma and in peritoneal fluid<sup>82–89,114</sup> has fueled speculation about the role of the immune system in the pathogenesis of endometriosis.<sup>7,20,21</sup> To date, however, no clear association has been found between endometriosis prevalence and chronic immunosuppression (e.g., in transplant patients), or with smoking affecting NK activity, or with caffeine or alcohol, or with any lifestyle variable.

Stress could be causally related to endometriosis. This concept is derived from the association of endometriosis and luteinized unruptured follicle (LUF) syndrome and from the association between a higher trait anxiety and LUF syndrome.<sup>18,19,46</sup> We postulated that reduced steroid hormone levels in peritoneal fluid could favor the implantation and development of endometriosis.<sup>55</sup> This hypothesis cannot be tested, however, as there is no suitable animal model. Another argument to link endometriosis and stress is the widely held belief that endometriosis is a 'career woman's disease.' This could also be explained, however, by the postponement of childbearing in this subset of women, with the inevitable increase of infertility with age and a higher prevalence of endometriosis found at laparoscopy.

Nulliparity could be a consequence of the disease, but a large study in Italy found that the prevalence decreased with increasing parity.<sup>90</sup> Oral contraceptive use has been reported to be associated with a decreased prevalence.<sup>65</sup>

#### 1.12.5.4 Cystic Ovarian Endometriosis

The incidence of cystic ovarian endometriosis increases with age.<sup>58</sup> Cystic ovarian endometriosis is clonal in origin.<sup>40,107,116</sup>

There is no evidence of a rising trend in the prevalence of cystic ovarian endometriosis.

#### 1.12.5.5 Deep Endometriosis

The incidence of deep endometriosis increases with age.<sup>58</sup>

Rectovaginal endometriosis was known since the beginning of the century, but a high prevalence of deep endometriosis was not suspected until fairly recently. The prevalence of deep endometriosis in the general population is estimated at 3–10% based on the 10–20% figures reported in Leuven from 1988 to 1991, a period in which endoscopic surgery was not yet well developed and deep endometriosis was not yet well known. Referrals, therefore, were exclusively for infertility and pain, not for deep endometriosis.

It is unclear whether the prevalence of deep endometriosis is rising. Although the number of articles in the literature suggest a rising trend, the underlying biases of referral and enhanced diagnosis prevent a definite conclusion.

The overall impression of deep endometriosis surgeons practicing over the past 20 years is that the severity and prevalence of deep endometriosis are increasing. The majority, including *Adamian*, *Donnez*, *Koh*, *Keckstein*, *Koninckx*, *Ussia*, and *Wattiez*, have a strong positive impression while others, such as *Nezhat*, are less convinced.

#### 1.12.5.6 Adenomyosis, Müllerianosis, Peritoneal Pockets, and Stromatosis

These diseases, often considered variants of endometriosis, will not be discussed. Stromatosis does not contain endometrial cells, while Müllerianosis is too rare to allow for prevalence discussion. The pathophysiology of adenomyosis is even more enigmatic than endometriosis. Several forms are known, and prevalence data vary with the diagnostic method.

#### 1.12.6 Discussion and Future Outlook

The epidemiology of endometriosis is an important topic with far-reaching implications. Indeed, the conclusion that the prevalence and especially the severity of endometriotic disease are rising would increase our level of concern about pollution, radiation exposure, and our changing lifestyle. A delay in childbirth would be the first suspect, but many other aspects show such a high temporal association that it is difficult to rule them out. We can speculate as to whether oral contraceptive use and years of medical treatment for pelvic pain without a diagnosis might stimulate the development of severe forms of endometriosis. We can also speculate that our modern food industry, globalization, and even global warming could be involved.

The hereditary aspect of endometriosis seems well established, and the initial results of genome-wide scans appear to be positive. This makes a causal relationship with dioxin, polychlorinated biphenyls,<sup>6</sup> and total body irradiation understandable, since these agents act at the level of the genome. This and the clonality of cystic and deep endometriosis tend to support the endometriotic disease theory, which regards typical, cystic, and deep endometriosis as a benign tumor caused by a genomic alteration, facilitated by genetic background and epigenetic modifications.<sup>45</sup> The many differences between the endometrium of women with and without endometriosis would thus be considered the cause, with the first hit contributing to susceptibility rather than causing endometriosis itself. Typical, cystic, and deep endometriotic lesions increase with age, at least in women with pain and/or infertility, following a pattern that is similar for all benign tumors. It is unclear why subtle lesions decrease with age. The growth pattern of endometriotic lesions is also similar to that of benign tumors such as fibromas of the uterus or breast, in that a period of active growth is followed by a cessation of growth. Indeed, most endometriotic lesions are burned out by pathology at the time of diagnosis and are no longer clinically progressive. Clinical data show that it is unlikely that typical endometriotic lesions develop into cystic or deep lesions, and vice-versa. This concept does not exclude the possibility that some deep lesions are different, with a minority undergoing active growth and causing problems such as bowel perforation during pregnancy.

Excellent reviews on the epidemiology of endometriosis conclude that the literature is not consistent and that it is unclear whether lifestyle and environmental factors (see review<sup>74</sup>) affect epidemiology. The accuracy of published data is called into question, however, by numerous diagnostic problems and by the underlying concepts that 'glands and stroma outside the uterus' are pathologic by definition and that

women with subtle lesions should be considered as having endometriosis. But we know that retrograde menstruation occurs in almost all women and, at least in women with pain and/or infertility, the prevalence of subtle lesions and/or microscopic endometriosis will be close to 100%. Most of these subtle and microscopic lesions may disappear spontaneously over time and reappear at other sites. There is no evidence to date that they cause pain or infertility. This view of subtle and microscopic endometriosis has far-ranging implications.

- The definition of what constitutes 'endometriosis' should be changed.
- The Sampson theory should be recognized as flawed since implantation does not mean inevitable progression.
- Women with subtle lesions should be classified as normal and should be counseled accordingly.
- Given the uncertainty about whether these lesions should be treated, they at least should not be treated aggressively and do not warrant a bowel resection for the sake of completeness.
- Epidemiology should take into account only typical, cystic, and deep endometriosis. This does not contradict the observation that the volume of retrograde menstruation could increase the risk of severe endometriotic disease if the oxidative stress of iron in the peritoneal cavity is considered a mutagen.

That the prevalence of severe endometriosis has been rising in recent decades is a widely held impression by the authors and by the great majority of deep endometriosis surgeons, as we confirmed by asking specific questions at numerous meetings. On the other hand, we are fully aware of referral bias and the fact that more and more women have had multiple prior surgeries, which could compound the difficulty of further interventions. The major conclusion, therefore, is not evidence-based but observational and authority-based by surgeons who all were pioneers well versed in deep endometriosis surgery and who witnessed the developments that have taken place during the past 25 years.

In conclusion, subtle and microscopic endometriosis should not be considered pathologic. The impression of surgeons that the prevalence and severity of deep endometriosis are rising is sufficient to raise legitimate concerns about environment, lifestyle, and associated factors. It at least warrants a thorough investigation.

#### 1.12.7 Acknowledgments

We express thanks to *Jacques Donnez* of Belgium, *Jörg Keckstein* of Austria, *Arnaud Wattiez* of France, and *Charles Koh* and *Camran Nezhat* of the U.S. for sharing their impressions on the prevalence and severity of deep endometriosis.

### 1.12.8 References

- ADAMYAN LV. Additional international perspectives. In: Nichols DH, editor. *Gynecological and Obstetric Surgery*. St. Louis, MO: Mosby; 1993. p. 1167–82.
- ADAMYAN LV, KULAKOV VI, HASHUKOEVA AZ. Malformations of the uterus and vagina [Poroki razwitya matki i wlagalischja]. In: Adamyan LV, Kulakov VI, editors. *Endometriosis in Medicine*; 1998.
- ADAMYAN LV, YAROTSKAYA EL. Endoscopic diagnosis and correction of malformations of female genitalia. Chapt. 28. In: Pasic RP, editor. *A Practical Manual of Laparoscopy and Minimally Invasive Gynecology: A Clinical Cookbook*, 2<sup>nd</sup> ed. Hoboken: CRC Press; 2007. (ISBN No. 9781439804315).
- BADESCU A, ROMAN H, AZIZ M, PUSCASIU L, MOLNAR C, HUET E et al. Mapping of bowel occult microscopic endometriosis implants surrounding deep endometriosis nodules infiltrating the bowel. *Fertil Steril* 2016;105(2):430–434.e26. doi:10.1016/j.fertnstert.2015.11.006.
- BERKKANOGLU M, ARICI A. Immunology and endometriosis. *Am J Reprod Immunol* 2003;50(1):48–59.
- BIRNBAUM LS, AM CUMMINGS. Dioxins and endometriosis: a plausible hypothesis. *Environ Health Perspect* 2002;110(1):15–21.
- BRAUN DP, DING J, DMOWSKI WP. Peritoneal fluid-mediated enhancement of eutopic and ectopic endometrial cell proliferation is dependent on tumor necrosis factor-alpha in women with endometriosis. *Fertil Steril* 2002;78(4):727–32.
- BROSENS I, ROBERTSON WB, DIXON HG. The physiological response of the vessels of the placental bed to normal pregnancy. *J Pathol Bacteriol* 1967;93(2):569–79. doi:10.1002/path.1700930218.
- BROSENS IA. Endoscopic exploration and classification of the chocolate cysts. *Hum Reprod* 1994;9(12):2213–4.
- BROSENS IA, KONINCKX PR, CORVELEYN PA. A study of plasma progesterone, oestradiol-17beta, prolactin and LH levels, and of the luteal phase appearance of the ovaries in patients with endometriosis and infertility. *Br J Obstet Gynaecol* 1978;85(4):246–50.
- BROSENS IA, PUTTEMANS PJ, DEPREST J. The endoscopic localization of endometrial implants in the ovarian chocolate cyst. *Fertil Steril* 1994;61(6):1034–8.
- BROSENS IA, ROBERTSON WB, DIXON HG. The role of the spiral arteries in the pathogenesis of preeclampsia. *Obstet Gynecol Annu* 1972;1:177–91.
- BURMEISTER RE, FECHNER RE, FRANKLIN RR. Endosalpingiosis of the peritoneum. *Obstet Gynecol* 1969;34(3):310–8.
- CRAMER DW, MISSMER SA. The epidemiology of endometriosis. *Ann N Y Acad Sci* 2002;955:11–22; discussion 34–6, 396–406.
- CULLEN TS. Adenoma-myoma uteri diffusum benignum. *Bull Johns Hopkins Hosp* 1896;6:133–7.
- CULLEN TS. Adenomyoma of the round ligament. *Bull Johns Hopkins Hosp* 1896;7:112–4.
- CULLEN TS. The distribution of adenomyomata containing uterine mucosa. *Am J Obstet Gynecol* 1919;80:130–8.
- DEMYTTENAERE K, NIJS P, EVERS-KIEBOOMS G, KONINCKX PR. The effect of a specific emotional stressor on prolactin, cortisol, and testosterone concentrations in women varies with their trait anxiety. *Fertil Steril* 1989;52(6):942–8.
- DEMYTTENAERE K, NIJS P, EVERS-KIEBOOMS G, KONINCKX PR. Coping, ineffectiveness of coping and the psychoendocrinological stress responses during in-vitro fertilization. *J Psychosom Res* 1991;35(2-3):231–43.
- DING J, SHEN J, BRAUN DP, RANA N, DMOWSKI WP. Endometrial apoptosis, macrophage content, and TNF $\alpha$  expression in endometriosis. *Fertil Steril* 2002;77:S1–S2. doi:10.1016/S0015-0282(01)03014-X.
- DMOWSKI WP. Immunology of endometriosis. *Arq Matern Dr Alfredo Da Costa* 1992(12):40–3.
- DONNEZ O, VAN LANGENDONCKT A, DEFRERE S, COLETTE S, VAN KERK O, DEHOUX JP et al. Induction of endometriotic nodules in an experimental baboon model mimicking human deep nodular lesions. *Fertil Steril* 2013;99(3):783–789.e3. doi:10.1016/j.fertnstert.2012.10.032.
- ESKENAZI B, MOCARELLI P, WARNER M, SAMUELS S, VERCELLINI P, OLIVE D et al. Serum dioxin concentrations and endometriosis: a cohort study in Seveso, Italy. *Environ Health Perspect* 2002;110(7):629–34.
- ESKENAZI B, WARNER ML. Epidemiology of endometriosis. *Obstet Gynecol Clin North Am* 1997;24(2):235–58.
- FANTON JW, GOLDEN JG. Radiation-induced endometriosis in *Macaca mulatta*. *Radiat Res* 1991;126(2):141–6.
- FOSTER WG. Endocrine toxicants including 2,3,7,8-tetrachlorodibenzo-p-dioxin (TCDD) and dioxin-like chemicals and endometriosis: is there a link? *J Toxicol Environ Health B Crit Rev* 2008;11(3-4):177–87. doi:10.1080/10937400701873456.
- GORDTS S, PUTTEMANS P, VALKENBURG M, BROSENS I, CAMPO R. Transvaginal endoscopy and small ovarian endometriomas: unravelling the missing link? *Gynecol Surg* 2014;11:3–7. doi:10.1007/s10397-013-0817-1.
- GRUENWALD P. Origin of endometriosis from the mesenchyme of the celomic walls. *American Journal of Obstetrics & Gynecology*;44(3):470–4. doi:10.5555/uri:pii:S0002937842904848.
- GUO SW. An overview of the current status of clinical trials on endometriosis: issues and concerns. *Fertil Steril* 2014;101(1):183–190.e4. doi:10.1016/j.fertnstert.2013.08.050.
- GUO SW, WANG Y. The prevalence of endometriosis in women with chronic pelvic pain. *Gynecol Obstet Invest* 2006;62(3):121–30. doi:10.1159/000093019.
- HADFIELD RM, MANEK S, NAKAGO S, MUKHERJEE S, WEEKS DE, MARDON HJ et al. Absence of a relationship between endometriosis and the N314D polymorphism of galactose-1-phosphate uridylyl transferase in a UK population. *Mol Hum Reprod* 1999;5(10):990–3.
- HADFIELD RM, MANEK S, WEEKS DE, MARDON HJ, BARLOW DH, KENNEDY SH. Linkage and association studies of the relationship between endometriosis and genes encoding the detoxification enzymes GSTM1, GSTT1 and CYP1A1. *Mol Hum Reprod* 2001;7(11):1073–8.
- HADFIELD RM, MARDON HJ, BARLOW DH, KENNEDY SH. Endometriosis in monozygotic twins. *Fertil Steril* 1997;68(5):941–2.
- HADFIELD RM, PULLEN JG, DAVIES KF, WOLFENSOHN SE, KEMNITZ JW, WEEKS DE et al. Toward developing a genome-wide microsatellite marker set for linkage analysis in the rhesus macaque (*Macaca mulatta*): identification of 76 polymorphic markers. *Am J Primatol* 2001;54(4):223–31. doi:10.1002/ajp.1032.
- HALME J, HAMMOND MG, HULKA JF, RAJ SG, TALBERT LM. Retrograde menstruation in healthy women and in patients with endometriosis. *Obstet Gynecol* 1984;64(2):151–4.
- HEILIER JF, DONNEZ J, LISON D. Organochlorines and endometriosis: a mini-review. *Chemosphere* 2008;71(2):203–10. doi:10.1016/j.chemosphere.2007.09.044.



37. HOLSBEKE C VAN, CALSTER B VAN, GUERRIERO S, SAVELLI L, PALADINI D, LISSONI AA et al. Endometriomas: their ultrasound characteristics. *Ultrasound Obstet Gynecol* 2010;35(6):730–40. doi:10.1002/uog.7668.
38. JANSEN RP. Minimal endometriosis and reduced fecundability: prospective evidence from an artificial insemination by donor program. *Fertil Steril* 1986;46(1):141–3.
39. JANSSEN EB, RIJKERS AC, HOPPENBROUWERS K, MEULEMAN C, D’HOOGHE TM. Prevalence of endometriosis diagnosed by laparoscopy in adolescents with dysmenorrhea or chronic pelvic pain: a systematic review. *Hum Reprod Update* 2013;19(5):570–82. doi:10.1093/humupd/dmt016.
40. JIMBO H, HITOMI Y, YOSHIKAWA H, YANO T, MOMOEDA M, SAKAMOTO A et al. Evidence for monoclonal expansion of epithelial cells in ovarian endometrial cysts. *Am J Pathol* 1997;150(4):1173–8.
41. JIMBO H, YOSHIKAWA H, ONDA T, YASUGI T, SAKAMOTO A, TAKETANI Y. Prevalence of ovarian endometriosis in epithelial ovarian cancer. *Int J Gynaecol Obstet* 1997;59(3):245–50.
42. KENNEDY S. Genetics of endometriosis: a review of the positional cloning approaches. *Semin Reprod Med* 2003;21(2):111–8. doi:10.1055/s-2003-41317.
43. KENNEDY S, HADFIELD R, MARDON H, BARLOW D. Age of onset of pain symptoms in non-twin sisters concordant for endometriosis. *Hum Reprod* 1996;11(2):403–5.
44. KENNEDY S, MARDON H, BARLOW D. Familial endometriosis. *J Assist Reprod Genet* 1995;12(1):32–4.
45. KOBAYASHI H, IMANAKA S, NAKAMURA H, TSUJI A. Understanding the role of epigenomic, genomic and genetic alterations in the development of endometriosis (review). *Mol Med Rep* 2014;9(5):1483–505. doi:10.3892/mmr.2014.2057.
46. KONINCKX PR. Pelvic endometriosis: a consequence of stress? *Contrib Gynecol Obstet* 1987;16:56–9.
47. KONINCKX PR. Is mild endometriosis a condition occurring intermittently in all women? *Hum Reprod* 1994;9(12):2202–5.
48. KONINCKX PR. Biases in the endometriosis literature. Illustrated by 20 years of endometriosis research in Leuven. *Eur J Obstet Gynecol Reprod Biol* 1998;81(2):259–71.
49. KONINCKX PR. The physiopathology of endometriosis: pollution and dioxin. *Gynecol Obstet Invest* 1999;47 Suppl 1:47-9; discussion 50.
50. KONINCKX PR, BATT RE, HUMMELSHOJ L, MCVEIGH E, USSIA A, YEH J. The elephant in the room: quality control of endometriosis data. *J Minim Invasive Gynecol* 2010;17(5):637–40. doi:10.1016/j.jmig.2010.04.005.
51. KONINCKX PR, BRAET P, KENNEDY SH, BARLOW DH. Dioxin pollution and endometriosis in Belgium. *Hum Reprod* 1994;9(6):1001–2.
52. KONINCKX PR, BROSENS IA. Dietary fat consumption and endometriosis risk. *Hum Reprod* 2011;26(3):731-2; author reply 732. doi:10.1093/humrep/deq353.
53. KONINCKX PR, CRAESSAERTS M, TIMMERMAN D, CORNILLIE F, KENNEDY S. Anti-TNF-alpha treatment for deep endometriosis-associated pain: a randomized placebo-controlled trial. *Hum Reprod* 2008;23(9):2017–23. doi:10.1093/humrep/den177.
54. KONINCKX PR, DONNEZ J, BROSENS I. Microscopic endometriosis: impact on our understanding of the disease and its surgery. *Fertil Steril* 2016;105(2):305–6. doi:10.1016/j.fertnstert.2015.10.038.
55. KONINCKX PR, IDE P, VANDENBROUCKE W, BROSENS IA. New aspects of the pathophysiology of endometriosis and associated infertility. *J Reprod Med* 1980;24(6):257–60.
56. KONINCKX PR, KENNEDY SH, BARLOW DH. Endometriotic disease: the role of peritoneal fluid. *Hum Reprod Update* 1998;4(5):741–51.
57. KONINCKX PR, KENNEDY SH, BARLOW DH. Pathogenesis of endometriosis: the role of peritoneal fluid. *Gynecol Obstet Invest* 1999;47 Suppl 1:23–33.
58. KONINCKX PR, MEULEMAN C, DEMEYERE S, LESAFFRE E, CORNILLIE FJ. Suggestive evidence that pelvic endometriosis is a progressive disease, whereas deeply infiltrating endometriosis is associated with pelvic pain. *Fertil Steril* 1991;55(4):759–65.
59. KONINCKX PR, MEULEMAN C, OOSTERLYNCK D, CORNILLIE FJ. Diagnosis of deep endometriosis by clinical examination during menstruation and plasma CA-125 concentration. *Fertil Steril* 1996;65(2):280–7.
60. KONINCKX PR, MUYLDERMANS M, MEULEMAN C, CORNILLIE FJ. CA 125 in the management of endometriosis. *Eur J Obstet Gynecol Reprod Biol* 1993;49(1-2):109–13.
61. KONINCKX PR, MUYLDERMANS M, MOERMAN P, MEULEMAN C, DEPREST J, CORNILLIE F. CA 125 concentrations in ovarian ‘chocolate’ cyst fluid can differentiate an endometriotic cyst from a cystic corpus luteum. *Hum Reprod* 1992;7(9):1314–7.
62. KONINCKX PR, USSIA A, KECKSTEIN J, WATTIEZ A, ADAMYAN L. Epidemiology of subtle, typical, cystic, and deep endometriosis: A systematic review. *Gynecol Surg* 2016;13(4):457–67. doi:10.1007/s10397-016-0970-4.
63. KRUITWAGEN RF, POELS LG, WILLEMSSEN WN, RONDE IJ DE, JAP PH, ROLLAND R. Endometrial epithelial cells in peritoneal fluid during the early follicular phase. *Fertil Steril* 1991;55(2):297–303.
64. LATCHER JW. Endometriosis of the umbilicus. *American Journal of Obstetrics and Gynecology* 1953;66(1):161–8.
65. MAHMOOD TA, TEMPLETON A. Prevalence and genesis of endometriosis. *Hum Reprod* 1991;6(4):544–9.
66. MAIS V, GUERRIERO S, AJOSSA S, ANGIOLUCCI M, AM PAOLETTI, MELIS GB. The efficiency of transvaginal ultrasonography in the diagnosis of endometrioma. *Fertil Steril* 1993;60(5):776–80.
67. MARTIN DC, AHMIC R, EL-ZEKY FA, VANDER ZWAAG R, PICKENS MT, CHERRY K. Increased Histologic Confirmation of Endometriosis. *Journal of Gynecologic Surgery* 1990;6(4):275–9. doi:10.1089/gyn.1990.6.275.
68. MARTIN DC, DEMOS BERRY J. Histology of Chocolate Cysts. *Journal of Gynecologic Surgery* 1990;6(1):43–6. doi:10.1089/gyn.1990.6.43.
69. MARTIN DC, HUBERT GD, VANDER ZR, EL-ZEKY FA. Laparoscopic appearances of peritoneal endometriosis. *Fertil Steril* 1989;51(1):63–7.
70. MATORRAS R, RODRIGUEZ F, PIJOAN JI, ETXANOJAUREGUI A, NEYRO JL, ELORRIAGA MA et al. Women who are not exposed to spermatozoa and infertile women have similar rates of stage I endometriosis. *Fertil Steril* 2001;76(5):923–8.
71. MECHSNER S, WEICHBRODT M, RIEDLINGER WF, AM KAUFMANN, SCHNEIDER A, KOHLER C. Immunohistochemical evaluation of endometriotic lesions and disseminated endometriosis-like cells in incidental lymph nodes of patients with endometriosis. *Fertil Steril* 2010;94(2):457–63. doi:10.1016/j.fertnstert.2009.03.097.

72. MEYER R. Über den Stand der Frage der Adenomyositis und Adenomyome im Allgemeinen und insbesondere über Adenomyositis seroepithelialis und Adenomyometritis sarcomatosa 1919(43):745–50.
73. MEYER R. Zur Frage der Urnieren-Genese von Adenomyomen. *Zentralbl Gynakol* 1923;15(577–587).
74. MISSMER SA, CRAMER DW. The epidemiology of endometriosis. *Obstet Gynecol Clin North Am* 2003;30(1):1–19, vii.
75. MOEN MH, HALVORSEN TB. Histologic confirmation of endometriosis in different peritoneal lesions. *Acta Obstet Gynecol Scand* 1992;71(5):337–42.
76. MOEN MH, SCHEI B. Epidemiology of endometriosis in a Norwegian county. *Acta Obstet Gynecol Scand* 1997;76(6):559–62.
77. MONTGOMERY GW, NYHOLT, ZHAO ZZ, TRELOAR SA, PAINTER JN, MISSMER SA et al. The search for genes contributing to endometriosis risk. *Hum Reprod Update* 2008;14(5):447–57. doi:10.1093/humupd/dmn016.
78. MURPHY AA, GREEN WR, BOBBIE D, DELA CZC, ROCK JA. Unsuspected endometriosis documented by scanning electron microscopy in visually normal peritoneum. *Fertil Steril* 1986;46(3):522–4.
79. NAKAGO S, HADFIELD RM, ZONDERVAN KT, MARDON H, MANEK S, WEEKS DE et al. Association between endometriosis and N-acetyl transferase 2 polymorphisms in a UK population. *Mol Hum Reprod* 2001;7(11):1079–83.
80. NISOLLE M, PAINDAVEINE B, BOURDON A, BERLIERE M, CASANAS-ROUX F, DONNEZ J. Histologic study of peritoneal endometriosis in infertile women. *Fertil Steril* 1990;53(6):984–8.
81. OLIVE DL, HENDERSON DY. Endometriosis and müllerian anomalies. *Obstet Gynecol* 1987;69(3 Pt 1):412–5.
82. OOSTERLYNCK D. Natural killer cells and endometriosis [PhD Thesis]; 1983.
83. OOSTERLYNCK DJ, CORNILLIE FJ, WAER M, KONINCKX PR. Immunohistochemical characterization of leucocyte subpopulations in endometriotic lesions. *Arch Gynecol Obstet* 1993;253(4):197–206.
84. OOSTERLYNCK DJ, CORNILLIE FJ, WAER M, VANDEPUTTE M, KONINCKX PR. Women with endometriosis show a defect in natural killer activity resulting in a decreased cytotoxicity to autologous endometrium. *Fertil Steril* 1991;56(1):45–51.
85. OOSTERLYNCK DJ, LACQUET FA, WAER M, KONINCKX PR. Lymphokine-activated killer activity in women with endometriosis. *Gynecol Obstet Invest* 1994;37(3):185–90.
86. OOSTERLYNCK DJ, MEULEMAN C, WAER M, KONINCKX PR. CO-laser excision of endometriosis does not improve the decreased natural killer activity. *Acta Obstet Gynecol Scand* 1994;73(4):333–7. doi:10.3109/00016349409015774.
87. OOSTERLYNCK DJ, MEULEMAN C, WAER M, KONINCKX PR. Transforming growth factor-beta activity is increased in peritoneal fluid from women with endometriosis. *Obstet Gynecol* 1994;83(2):287–92.
88. OOSTERLYNCK DJ, MEULEMAN C, WAER M, KONINCKX PR, VANDEPUTTE M. Immunosuppressive activity of peritoneal fluid in women with endometriosis. *Obstet Gynecol* 1993;82(2):206–12.
89. OOSTERLYNCK DJ, MEULEMAN C, WAER M, VANDEPUTTE M, KONINCKX PR. The natural killer activity of peritoneal fluid lymphocytes is decreased in women with endometriosis. *Fertil Steril* 1992;58(2):290–5.
90. PARAZZINI F, LUCHINI L, VEZZOLI F, MEZZANOTTE C, VERCELLINI P, ROMANINI C. Gruppo italiano per lo studio dell'endometriosi. Prevalence and anatomical distribution of endometriosis in women with selected gynaecological conditions: results from a multicentric Italian study. *Hum Reprod* 1994;9(6):1158–62.
91. RAHMIOGLU N, NYHOLT, MORRIS AP, MISSMER SA, MONTGOMERY GW, ZONDERVAN KT. Genetic variants underlying risk of endometriosis: insights from meta-analysis of eight genome-wide association and replication datasets. *Hum Reprod Update* 2014;20(5):702–16. doi:10.1093/humupd/dmu015.
92. RAVINSKY E. Cytology of peritoneal washings in gynecologic patients. Diagnostic criteria and pitfalls. *Acta Cytol* 1986;30(1):8–16.
93. REDWINE DB. Age-related evolution in color appearance of endometriosis. *Fertil Steril* 1987;48(6):1062–3.
94. REDWINE DB. Peritoneal blood painting: an aid in the diagnosis of endometriosis. *American Journal of Obstetrics and Gynecology* 1989;161(4):865–6.
95. REDWINE DB. Was Sampson wrong? *Fertil Steril* 2002;78(4):686–93.
96. RIER SE. Environmental immune disruption: a comorbidity factor for reproduction? *Fertil Steril* 2008;89(2 Suppl):e103–8. doi:10.1016/j.fertnstert.2007.12.040.
97. RIER SE, MARTIN DC, BOWMAN RE, DMOWSKI WP, BECKER JL. Endometriosis in rhesus monkeys (*Macaca mulatta*) following chronic exposure to 2,3,7,8-tetrachlorodibenzo-p-dioxin. *Fundam Appl Toxicol* 1993;21(4):433–41.
98. RIER SE, TURNER WE, MARTIN DC, MORRIS R, LUCIER GW, CLARK GC. Serum levels of TCDD and dioxin-like chemicals in Rhesus monkeys chronically exposed to dioxin: correlation of increased serum PCB levels with endometriosis. *Toxicol Sci* 2001;59(1):147–59.
99. RUSSELL WW. Aberrant portions of the Müllerian duct found in an ovary. *Johns Hopkins Hosp Bull* 1899;10:8–10.
100. SAMPSON JA. Heterotopic or misplaced endometrial tissue. *American Journal of Obstetrics and Gynecology* 1925;10(5):649–64. doi:10.1016/S0002-9378(25)90629-1.
101. SAMPSON JA. Peritoneal endometriosis due to the menstrual dissemination of endometrial tissue into the peritoneal cavity. *Am J Obstet Gynecol* 1927;14:422–69.
102. SAMPSON JA. The development of the implantation theory for the origin of peritoneal endometriosis. *Am J Obstet Gynecol* 1940;40:549–57.
103. SCOTT RB, TELINDE RW. External endometriosis – the scourge of the private patient. *Ann Surg* 1950;131(5):697–720.
104. SETUBAL A, SIDIROPOULOU Z, TORGAL M, CASAL E, LOURENCO C, KONINCKX P. Bowel complications of deep endometriosis during pregnancy or in vitro fertilization. *Fertil Steril* 2014;101(2):442–6. doi:10.1016/j.fertnstert.2013.11.001.
105. SPITSYN VA, ANDREEVA EN, ADAMIAN LV, AGAPOVA RK, SANDOVAL' K. Genetic aspects of endometriosis: features of the distribution of polymorphic gene frequencies. *Genetika* 1996;32(12):1693–9.
106. STRIPLING MC, MARTIN DC, CHATMAN DL, ZWAAG RV, POSTON WM. Subtle appearance of pelvic endometriosis. *Fertil Steril* 1988;49(3):427–31.

107. TAMURA M, FUKAYA T, MURAKAMI T, UEHARA S, YAJIMA A. Analysis of clonality in human endometriotic cysts based on evaluation of X chromosome inactivation in archival formalin-fixed, paraffin-embedded tissue. *Lab Invest* 1998;78(2):213–8.
108. TONG J, ZHU L, CHEN N, LANG J. Endometriosis in association with Herlyn-Werner-Wunderlich syndrome. *Fertil Steril* 2014;102(3):790–4. doi:10.1016/j.fertnstert.2014.05.025.
109. TSUTSUMI O, MOMOEDA M, TAKAI Y, ONO M, TAKETANI Y. Breast-fed infants, possibly exposed to dioxins in milk, have unexpectedly lower incidence of endometriosis in adult life. *Int J Gynaecol Obstet* 2000;68(2):151–3.
110. VASQUEZ G, CORNILLIE F, BROSENS IA. Peritoneal endometriosis: scanning electron microscopy and histology of minimal pelvic endometriotic lesions. *Fertil Steril* 1984;42(5):696–703.
111. VERCELLINI P. Endometriosis: the elusive gray area between evidence-based and evidence-biased medicine. *Fertil Steril* 2014;101(1):45–6. doi:10.1016/j.fertnstert.2013.09.023.
112. VERCELLINI P, VIGANO P, SOMIGLIANA E, FEDELE L. Endometriosis: pathogenesis and treatment. *Nat Rev Endocrinol* 2014;10(5):261–75. doi:10.1038/nrendo.2013.255.
113. VIGANO P, PARAZZINI F, SOMIGLIANA E, VERCELLINI P. Endometriosis: epidemiology and aetiological factors. *Best Pract Res Clin Obstet Gynaecol* 2004;18(2):177–200. doi:10.1016/j.bpobgyn.2004.01.007.
114. VINATIER D, DUFOUR P, OOSTERLYNCK D. Immunological aspects of endometriosis. *Hum Reprod Update* 1996;2(5):371–84.
115. WALTER AJ, HENTZ JG, MAGTIBAY PM, CORNELLA JL, MAGRINA JF. Endometriosis: correlation between histologic and visual findings at laparoscopy. *American Journal of Obstetrics and Gynecology* 2001;184(7):1407–11; discussion 1411–3.
116. YANO T, JIMBO H, YOSHIKAWA H, TSUTSUMI O, TAKETANI Y. Molecular analysis of clonality in ovarian endometrial cysts. *Gynecol Obstet Invest* 1999;47 Suppl 1:41–5; discussion 46.



## 1.13

## Progesterone and Endometriosis: From Pathogenesis to Treatment

Nicola Pluchino<sup>a</sup> | Jean-Marie Wenger<sup>b</sup> | Andrea R. Genazzani<sup>c</sup>**1.13.1 Introduction**

Investigations involving the pathophysiology of endometriosis have revealed several well-established molecular hallmarks of the disease: genetic predisposition and epigenetic modifications, hormonal imbalance and inflammation. Hormonal imbalance includes estrogen synthesis metabolism and responsiveness, and progesterone resistance. These hormonal alterations contribute to the ability of endometrial cells to proliferate, migrate and to infiltrate the mesothelium, causing inflammation, pain and infertility. Hormonal imbalance in endometriosis also represents a target in the treatment of the disease.<sup>7,16</sup>

Ovarian progesterone synthesis represents the master signal for ovulation, embryo implantation, decidualization, and menstrual shedding. However, the remodeling of the endometrium during reproductive events is also dependent on the influx of distinct immune cells and controlled local inflammation, and the ability of progesterone to balance the endocrine/immune physiology. Endometrial immune responses reflect the balance between the proinflammatory effect of estrogen and the immunosuppressant effect of progesterone. Actions of estrogen (and progesterone) on the immune response are, nevertheless, quite complex and often contradictory depending on the cell type being examined.<sup>2,6,30</sup>

Although it is likely that numerous converging factors determine the risk for developing endometriosis, scientists generally accept Sampson's theory of retrograde menstruation as a major underlying mechanism contributing to the development of ectopic endometrial growth. Since most cycling women exhibit retrograde menstruation, alterations in key biological processes must additionally be present to allow displaced endometrial tissue to successfully attach and survive ectopically in only a subset of women.<sup>6</sup> In this regard, progesterone resistance in the eutopic and ectopic endometrium of endometriosis patients, combined with the altered nature of immune cells and their proinflammatory products, may collectively promote the successful establishment of ectopic disease.<sup>5,6,30,42</sup>

In this chapter, we provide an overview on progesterone-related mechanisms involved in the development of endometriotic lesions. The development phase of new molecules targeting these pathways is also discussed.

**1.13.2 Hormonal Imbalance in Endometriosis: From an Estrogen-Dependent Disorder to a Progesterone-Resistant Disease**

The actions of estrogen and progesterone processes are tightly and reciprocally controlled through regulated expression of steroid receptors, cofactors, chaperone proteins, and downstream signaling components. The loss of balance between progesterone and estrogen actions appears to be a central theme in the pathogenesis of endometriosis and the associated infertility.<sup>24</sup>

**1.13.2.1 Estrogen Homeostasis Imbalance**

Endometriosis lesions are associated with estrogen imbalance.<sup>22</sup> The expression patterns of steroid receptors in endometriotic tissues and eutopic endometrium have been compared. Electron microscopic analysis has shown that one third of endometriotic implants are out of phase with the menstrual cycle<sup>4</sup>, and a light microscopic study showed that only 13% of endometriotic implants were synchronous with the corresponding eutopic endometrial tissue. *Estrogen receptor beta* (ER beta) levels are higher and *estrogen receptor alpha* (ER alpha) are lower in women with endometriosis than in those with normal endometrium.<sup>25,45</sup>

Higher ER beta levels are caused by hypomethylation of a CpG island at the promoter region of this gene. ER beta excess is responsible for the estrogen-dependent response and this expression inhibits ER alpha action.<sup>11</sup>

Endometriotic tissue showed markedly increased expression of the aromatase enzyme and decreased expression of *17 $\beta$ -hydroxysteroid dehydrogenase type 2* (17 $\beta$ -HSD2).<sup>4,31</sup> A positive feed-back loop indicates that aromatase and COX-2, a PGE2 synthesis enzyme, are responsible for the continuous local synthesis of estrogen and PGE2 in endometriosis stroma cells. Aromatase expression is induced by PGE2 in endometriotic cells, where it catalyzes the production of estradiol, which, in turn, promotes PGE2 production by inducing COX-2 expression. In addition, endometriotic tissue contains 17 $\beta$ -hydroxysteroid dehydrogenase type 1 (17 $\beta$ -HSD1), an enzyme that converts estrone (E1) to the more potent estradiol, whereas the tissue lacks 17 $\beta$ -HSD2, an enzyme responsible for conversion of E2 to E1. This enzymatic imbalance raises the local estrogen activity level.<sup>31</sup>

In addition, estrogen can also act via a more rapid, non-genomic mechanism. The *G protein-coupled estrogen receptor 1* (GPER), also termed *G protein-coupled receptor 30*

<sup>a</sup> | MD; Division of Gynecology and Obstetrics, University Hospital of Geneva, Switzerland; Yale University School of Medicine, New Haven, USA

<sup>b</sup> | MD; Consultant, Division of Gynecology and Obstetrics, University Hospital of Geneva, Switzerland

<sup>c</sup> | MD; Division of Gynecology and Obstetrics, University of Pisa, Italy

**Corresponding author:**Dr. med. **Nicola Pluchino**

Division of Obstetrics and Gynecology

Hôpitaux Universitaires de Genève – HUG

30 Bd de la Cluse

1211 Genève, Switzerland

E-mail: nicola.pluchino@hcuge.ch

(GPR30), is a seven-transmembrane receptor that is thought to be part of the rapid, non-genomic estrogen responses that can, in contrast to the classic or genomic modes of ER activity, occur within minutes.<sup>18</sup>

GPER expression is detectable in the cytoplasm and the nucleus of endometrial and endometriotic cells. Epithelial and stromal endometrial and endometriotic cells exhibited a distinct expression pattern of GPER. Cytoplasmic GPER expression was significantly higher in the epithelium of all types of endometriosis (peritoneal, ovarian and deep infiltrating endometriotic tissues) compared to normal endometrium, suggesting the potential involvement of GPER in the pathogenesis of endometriosis.<sup>18</sup>

#### 1.13.2.2 Progesterone Homeostasis Imbalance

In addition to estrogen dependence, there is increasing evidence to support a profile of progesterone resistance in the pathophysiology of endometriosis.<sup>9</sup> Progesterone imbalance in endometriotic lesions may facilitate the development and the persistence of disease, while the progesterone imbalance in eutopic endometrium is associated with deficient blastocyst implantation and infertility. It has recently been proposed that the loss or reduction of progesterone action affects the ability to down-regulate endometrial estrogen-mediated actions leading to cellular proliferation and chronic inflammation.<sup>6,24</sup>

The *progesterone receptor* (PR) has two isoforms, PR-A and PR-B, and the ratio of PR-B to PR-A is tissue-specifically regulated. Studies with PR isoform-specific gene ablation mice have revealed that only PR-A plays a crucial role in ovarian and uterine function, whereas PR-B, but not PR-A, is required for mammary gland development.<sup>10,24</sup> By modifying the ratio of PR-A to PR-B, *Tan et al.* identified differential gene expression allowing them to independently assign function to both isoforms.<sup>24,38</sup> In addition, progesterone induces ‘non-genomic’ or ‘rapid’ actions without the interaction with DNA, and several additional putative receptors have been evaluated. Although non-genomic actions of progesterone have been widely described to occur in the brain, their role in disorders such as endometriosis remains largely elusive.

Endometriotic lesions exhibit an overall reduction in PR expression relative to eutopic endometrium and the lack of PR-B due to hypermethylation of the PR gene.<sup>3,12,44</sup> In addition, overexpression of ER beta occupies the *estrogen response element* (ERE) at the PR promoter region and blocks transcription of PR that is normally activated by estrogen receptor (ER) alpha. Moreover, the reduced ER alpha expression in endometriotic lesions further reduces the PR expression. This mechanism is thought to contribute to the resistance to selective actions of progesterone in these cells, which is manifested by perturbations in a number of downstream progesterone target genes.<sup>21</sup>

In addition, other mechanisms have been implicated in the development of progesterone resistance in endometrium and in endometriosis lesions. They are strictly related to mechanisms of regulation of the genomic action of progesterone in endometrial cells. Deletion of *Fkbp52*, an *immunophilin cochaperone for PR*, results in uterine-specific P4 resistance in mice and facilitates the development of the disease.<sup>17</sup> Reduction of coregulators such as hydrogen peroxide-inducible *clone 5/*

*androgen receptor coactivator 55* (HIC-5/ARA55) is associated with a reduced progesterone activity in the endometrium of endometriosis patients. HIC-5 is a coregulator that potentiates PR, but it does not alter ER activity; a deficiency in Hic-5 gene expression appears to be closely associated with the development of endometriosis.<sup>1,24</sup>

Moreover, progesterone resistance is also enhanced by inflammation. The signaling pathway is modified by mechanisms of competition or interference with pro-inflammatory transcriptional factors, such as *forkhead box protein O1* (FOXO1) or *nuclear factor-kappa B* (NF-κB). In particular, NF-κB is chronically increased in endometriosis and directly suppresses PR activity. Thus, the inflammation process induced by the disease may contribute to the dynamic steroid hormone expression and hormonal imbalance demonstrated in ectopic lesions.<sup>6,24</sup>

In conclusion, steroid perturbation and estrogen/progesterone imbalance is critical for the entire process of endometriosis lesion formation, including tissue-adhesive properties, activity of matrix metalloproteinases and stimulation of angiogenesis<sup>22</sup> maintaining the loop between abnormal steroid synthesis, responsiveness and inflammation.<sup>33</sup>

#### 1.13.3 Progesterone Imbalance as Target for Endometriosis Treatment

According to the *Practice Committee of the American Society for Reproductive Medicine*, ‘endometriosis should be viewed as a chronic disease that requires a life-long individualized management plan with the goal of maximizing the use of medical treatment and avoiding repeated surgical procedures’. In the last few decades several studies have been conducted in order to introduce new drugs into clinical practice for treating endometriosis-associated pelvic pain as a primary treatment or in reducing the recurrence of symptoms/disease.

Although the general principles that should guide medical management of endometriosis are not different from those applicable to other chronic inflammatory disorders, fertility preservation and improvement are peculiar aspects that characterize this reproductive, inflammatory, chronic disease as *unique*.

Treatment strategies for endometriosis may be differentiated in relation to hormonal targets involved in their main actions:

- estrogen synthesis, metabolism and responsiveness,
- progesterone responsiveness.<sup>30</sup>

Currently, hormonal contraceptives, progestins, danazol, GnRH-agonists and antagonists and aromatase inhibitors are used in clinical settings for the medical management of endometriosis-associated pain and for secondary prevention. In particular, progestins have the potential to reduce ovarian estrogen synthesis by negative feedback at the hypothalamic-pituitary axis and counteract the effects of estrogens on endometriosis growth and inflammation (Table 1.5). Actual hormonal treatments do not eradicate the disease but partly control pain symptoms, and the effect is comparable among different molecules. However, symptoms and endometriotic

lesions frequently recur after discontinuation of treatment and no positive effect on spontaneous fertility has been demonstrated. New insight into the complexity of progesterone signaling in endometriosis and the limits of current medications, support the development of new treatments.

### 1.13.3.1 Drugs Acting on Progesterone Responsiveness

#### ■ Mifepristone

Mifepristone is an oral active progesterone antagonist at the receptor level, best known for its use in the induction of medical abortions. It has a high affinity for progesterone and glucocorticoid type II receptors. With its antiprogestone effect, mifepristone prevents progesterone from exerting its action. It also has a direct inhibitory effect on human endometrial cells and can modulate the estrogen and progesterone receptor expression in both eutopic and ectopic endometrium.<sup>36</sup> Additionally, it suppresses endometrial prostaglandin production, providing the background for relief of endometriosis-related pain. Three small clinical trials have been reported using three different dose schedules of mifepristone (5 mg or 50 mg per day for 6 months or 100 mg per day for 3 months).<sup>20</sup> There was an improvement in symptoms in all treated patients independent of the dose, and a 55% mean regression of visible endometriosis after 6

months of treatment (50 mg/day) was observed.<sup>20</sup> Mifepristone has antiglucocorticoid properties and its long-term safety should be studied. Recently, a mifepristone-loaded implant made of PCL/Pluronic F68 compounds was prepared for the long-term treatment of endometriosis. The data in this study showed that the  $C_{max}$  and  $AUC_{0-inf}$  were proportional to implant length and dose, and all groups reached plasma  $C_{max}$  at about the same time (approximately 7 days). There were inhibitory effects on the growth of endometrial explants in Wistar rats in a dose-dependent manner after administration of mifepristone-loaded implants with implant length from 1.5 to 9.0 cm for 1–3 months.<sup>26</sup>

### 1.13.4 Selective Progesterone Receptor Modulators (SPRM)

As mifepristone does not differentiate between progesterone receptor (PR) and glucocorticoid receptor (GR), a series of experiments were conducted to develop compounds capable of modulating either receptor selectively. The group of SPRM with potent antiprogestone activity and minimal antiglucocorticoid effects includes ZK-98299 (*onapristone*), ZK-230211 (*lonaprisan*), CDB-2914 (*ulipristal*), CDB-4124 (*telapristone*), ORG-31710, ORG-33628, J-867 (*asoprisnil*) and *vilaprisnil*.

Name of Synthetic Progestogen	Selected Pertinent Literature	Regime of Administration
<b>Cyproterone acetate</b>	<i>Vercellini P, Giorgi O de, Mosconi P, Stellato G, Vicentini S, Crosignani PG.</i> Cyproterone acetate versus a continuous monophasic oral contraceptive in the treatment of recurrent pelvic pain after conservative surgery for symptomatic endometriosis. <i>Fertil Steril</i> 2002;77(1):52–61. <sup>40</sup> <i>Oger P, Alifano M, Regnard JF, Gompel A.</i> Difficult management of recurrent catamenial pneumothorax. <i>Gynecol Endocrinol</i> 2006;22(12):713–5. <sup>29</sup>	12.5–50 mg/day
<b>Gestrinone</b>	<i>Gestrinone Italian Study Group.</i> Gestrinone versus a gonadotropin-releasing hormone agonist for the treatment of pelvic pain associated with endometriosis: a multicenter, randomized, double-blind study. <i>Fertil Steril</i> 1996;66(6):911–9. <sup>15</sup>	2.5 mg twice weekly
<b>Lynestrenol</b>	<i>Regidor PA, Regidor M, Schmidt M, Ruwe B, Lubben G, Fortig P et al.</i> Prospective randomized study comparing the GnRH-agonist leuprorelin acetate and the gestagen lynestrenol in the treatment of severe endometriosis. <i>Gynecol Endocrinol</i> 2001;15(3):202–9. <sup>32</sup>	10 mg/day
<b>Medroxyprogesterone acetate</b>	<i>Moghissi KS, Boyce CR.</i> Management of endometriosis with oral medroxyprogesterone acetate. <i>Obstet Gynecol</i> 1976;47(3):265–7. <sup>27</sup> <i>Crosignani PG, Luciano A, Ray A, Bergqvist A.</i> Subcutaneous depot medroxyprogesterone acetate versus leuprolide acetate in the treatment of endometriosis-associated pain. <i>Hum Reprod</i> 2006;21(1):248–56. <sup>14</sup>	30 mg/day 150 mg/3 months (depot)
<b>Megestrol acetate</b>	<i>Schlaff WD, Dugoff L, Damewood MD, Rock JA.</i> Megestrol acetate for treatment of endometriosis. <i>Obstet Gynecol</i> 1990;75(4):646–8. <sup>35</sup>	40 mg/day
<b>Norethindrone acetate</b>	<i>Muneyyirci-Delale O, Jalou S, Rahman M, Nacharaju V.</i> Can we decrease breakthrough bleeding in patients with endometriosis on norethindrone acetate? <i>Int J Fertil Womens Med</i> 2003;48(1):32–6. <sup>28</sup> <i>Vercellini P, Pietropaolo G, Giorgi O de, Pasin R, Chiodini A, Crosignani PG.</i> Treatment of symptomatic rectovaginal endometriosis with an estrogen-progestogen combination versus low-dose norethindrone acetate. <i>Fertil Steril</i> 2005;84(5):1375–87. <sup>41</sup>	2.5–5 mg/day;
<b>Levonorgestrel – IUD</b>	<i>Vercellini P, Aimi G, Panazza S, Giorgi O de, Pesole A, Crosignani PG.</i> A levonorgestrel-releasing intrauterine system for the treatment of dysmenorrhea associated with endometriosis: a pilot study. <i>Fertil Steril</i> 1999;72(3):505–8. <sup>39</sup>	20 micrograms (µg)/day

**Table 1.5** Progestins used in the management of endometriosis-associated pain.



SPRM are novel progesterone receptor ligands defined by tissue-dependent agonistic and/or antagonistic activity. They have the potential to induce reversible amenorrhea through selective inhibition of endometrial proliferation, a direct effect on endometrial blood vessels, and the suppression of endometrial prostaglandin production in a tissue-specific manner without the systemic effects of estrogen deprivation, providing a rationale for the treatment of endometriosis-related pain.<sup>36</sup>

Asoprisnil was the first investigational SPRM to reach an advanced stage of clinical development for the treatment of endometriosis. Clinical phase-III trials were discontinued on 11, February 2009. Asoprisnil can suppress both the menstrual cycle and endometrial growth. To date, there is only one published randomized, placebo-controlled trial of asoprisnil (5, 10 and 25 mg/day) for 12 weeks in 130 women with a laparoscopic diagnosis of endometriosis who exhibited moderate or severe pelvic pain at baseline. All doses of asoprisnil reduced nonmenstrual pelvic pain as well as dysmenorrhea; however, the effect on bleeding pattern was dose-dependent.<sup>13</sup>

No serious, drug-related adverse events were reported during the treatment or follow-up period. A favorable safety and tolerability profile of asoprisnil with no signs of estrogen deprivation was reported.<sup>13</sup>

Promising results were also obtained with onapristone until studies were terminated because of liver toxicity.<sup>23</sup>

Telapristone acetate is also under investigation for use in patients with endometriosis. In 2009, *Ioffe et al.* evaluated endometrial samples from 58 premenopausal women treated with daily oral doses of 12.5, 25 or 50 mg for endometriosis or uterine leiomyomas.<sup>19</sup> At 3 or 6 months, 103 out of 174 biopsies contained several histological changes: the endometrium was generally inactive or atrophic with a superimposed formation of cystic dilated glands and secretory changes coexisting with mitoses and apoptotic bodies, but no hyperplasia.<sup>19</sup> Clinical effects on pain symptoms are still unpublished. An additional phase II clinical trial is ongoing to evaluate the safety and efficacy of 6 and 12 mg of telapristone acetate in patients with confirmed endometriosis. Results are expected in June 2016.<sup>34</sup>

Ulipristal acetate reduced both volume and weight of lesions (< 50%), comparable with the effect of dienogest or GnRH analogues.<sup>37</sup> The dose of ulipristal acetate used in rats was 0.1 mg/day, which is comparable with the dose used as emergency contraception in women (30 mg ulipristal acetate/day), but much higher than the dose used in the treatment of leiomyoma (0.01 mg/day in rats; 5 mg/day for 3 months in women). Intrauterine administration of ulipristal acetate may be a solution to this potential problem.

A phase IV pilot study on “*Ulipristal Acetate for Treatment of Endometriosis-Related Pelvic Pain*” is ongoing.<sup>8</sup> Twenty-five women with chronic, endometriosis-related pelvic pain refractory to medical and/or surgical therapies will receive 15 mg ulipristal every other day (three times a week – Monday, Thursday, Saturday) for three months. Results are expected in 2018.

A recent study compared the progesterone receptor (PR) antagonistic activity of different SPRMs, including new SPRMs, vilaprisan and lonaprisan, in an endometriosis model. Oral administration of different SPRMs to rats showed full inhibition of implantation starting from 0.3 mg/kg\*/day (lonaprisan/ZK230211) up to 10 mg/kg\*/day (ulipristal acetate). Antagonistic effects on endometrial transformation could be observed at doses from 1 mg/kg\*/day (lonaprisan, vilaprisan) up to 10 mg/kg\*/day (mifepristone, ulipristal acetate). Hormonally stimulated autologous endometrial tissue transplanted onto the peritoneal wall and treated with different doses of vilaprisan for 4 weeks showed a statistically significant reduction of lesion area of approximately 75% at 1 mg/kg\*/day ( $p < 0.01$ ). The authors state that all compounds were efficacious in the tested in vivo models, with vilaprisan and lonaprisan being the most potent SPRM representatives<sup>43</sup> (Table 1.6).

#### 1.13.4.1 Conclusion and Perspectives

The homeostasis imbalance in the eutopic and ectopic endometrium of women with endometriosis is associated (and enhanced) with chronic inflammation. Estrogen/progesterone imbalance also represents a target for

\* per kg body weight

Selective Progesterone Receptor Modulator	Advantages	Current Limitations
<b>Mifepristone</b>	Clinical trials reported an improvement in symptoms. A mifepristone-loaded implant has been prepared for long-term treatment.	Antiglucocorticoid properties and long-term safety should be further studied. Number of patients enrolled in clinical trials is limited. Only animal studies for mifepristone-loaded implant have been explored.
<b>Asoprisnil</b>	Asoprisnil reduced non-menstrual pelvic pain and dysmenorrhea.	Number of patients enrolled is limited.
<b>Ulipristal acetate</b>	Ulipristal acetate reduced both volume and weight of lesion in the animal model and shows a safety profile in clinical studies (at lower doses).	Number of patients enrolled is limited. Evidence only from endometriosis in-vivo studies
<b>Telapristone acetate</b>	Endometrial changes consistent with other SPRMs	No available data on endometriosis patients
<b>Vilaprisan</b>	Highly effective in in-vivo studies	No available data in clinical studies
<b>Lonaprisan</b>	Highly effective in in-vivo studies	No available data in clinical studies

**Table 1.6** Advantages and current limits of new drugs acting on progesterone responsiveness.

treatment. The currently first-line treatments for endometriosis were derived from research on hormonal contraception, while the newest generation of medical treatments act on specific features of the disease. This represents a remarkable innovation in endometriosis research. Often treatments evaluated in the context of symptomatic endometriosis are also under development for the treatment of other endocrine-related disease like breast cancer, prostate cancer and uterine leiomyomas. Apart from that, the development of new compounds is aimed at overcoming the limits of current treatments, specifically the side effects and lack of effectiveness. However, endometriosis is a chronic disease involving young women and additional biological targets of estrogen and progesterone pharmacological approaches (brain, bone and cardiovascular tissue) need to be considered in order to improve the compliance of medical treatment in endometriosis patients.

The use of SPRMs for the treatment of endometriosis is promising. Ulipristal acetate shows an acceptable safety profile when applied at a dose of 5 mg/day. However, the use of higher doses in endometriosis for a longer time might raise concerns about side effects and endometrial safety. Results from the ongoing phase IV study are needed.

Although some small studies support the beneficial effects of mifepristone on pain, its long-term use in endometriosis patients may be limited by the associated anti-glucocorticoid activity. Among other SPRMs, only asoprisnil and telapristone acetate are under evaluation in endometriosis patients, although no clinical data are actually available.

In conclusion, several new interesting molecules acting on progesterone responsiveness are under evaluation and probably will be available on the market in the next five years. However, they still have some limitations that are crucial for endometriosis and that are opposed to an ideal treatment:

- The clinical effect in human studies has been demonstrated only on pain symptoms without a clear cytoreductive effect on lesions.
- All drugs have the potential to limit natural conception and their effect on subsequent fertility is largely unknown.
- Comparative studies with current treatment (progestogens) are lacking.

In addition to hormonal imbalance, the development of endometriotic lesions is characterized by abnormal immunologic reactions, neoangiogenesis, neuroinflammation and epigenetic modifications. New drugs acting on the immune system and neoangiogenesis are also under development. The combination of different drugs acting on hormonal and immune system/neuroinflammation will be the next step for improving the medical management of endometriosis.

### 1.13.5 Acknowledgments

The authors are grateful to *Joshua Huttler* for editing the chapter.

### 1.13.6 References

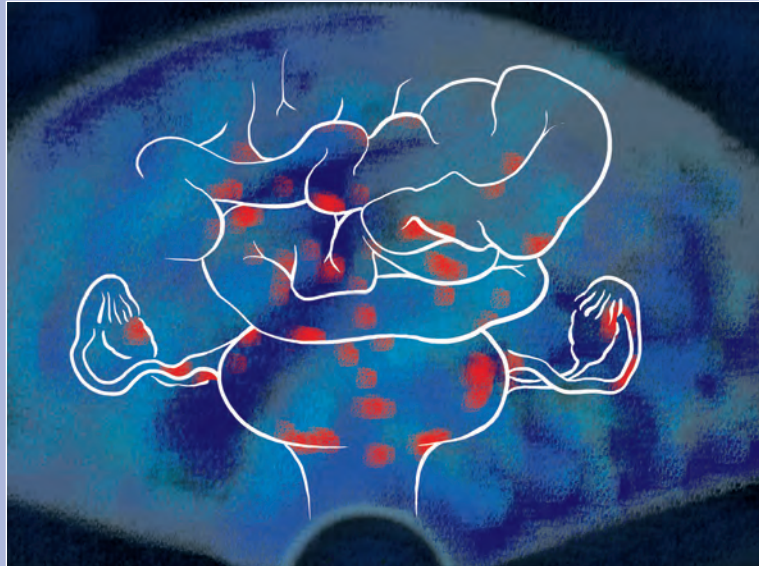
1. AGHAJANOVA L, VELARDE MC, GIUDICE LC. The progesterone receptor coactivator Hic-5 is involved in the pathophysiology of endometriosis. *Endocrinology* 2009;150(8):3863–70. doi:10.1210/en.2009-0008.
2. AL-SABBAGH M, LAM EW, BROSENS JJ. Mechanisms of endometrial progesterone resistance. *Mol Cell Endocrinol* 2012;358(2):208–15. doi:10.1016/j.mce.2011.10.035.
3. ATTIA GR, ZEITOUN K, EDWARDS D, JOHNS A, CARR BR, BULUN SE. Progesterone receptor isoform A but not B is expressed in endometriosis. *J Clin Endocrinol Metab* 2000;85(8):2897–902. doi:10.1210/jcem.85.8.6739.
4. BRANDENBERGER AW, DI LEOVIC, TEE MK, RYAN IP, TSENG JF, JAFFE RB et al. Oestrogen receptor (ER)-alpha and ER-beta isoforms in normal endometrial and endometriosis-derived stromal cells. *Mol Hum Reprod* 1999;5(7):651–5.
5. BROSENS I, BENAGIANO G. Perinatal origin of endometriosis revisited. *Gynecol Endocrinol* 2015;31(6):419–21. doi:10.3109/09513590.2015.1017458.
6. BRUNER-TRAN KL, HERINGTON JL, DULEBA AJ, TAYLOR HS, OSTEEEN KG. Medical management of endometriosis: emerging evidence linking inflammation to disease pathophysiology. *Minerva Ginecol* 2013;65(2):199–213.
7. BULUN SE. Endometriosis. *N Engl J Med* 2009;360(3):268–79. doi:10.1056/NEJMr0804690.
8. BULUN SE. Northwestern University. Ulipristal for Endometriosis-related Pelvic Pain; Available from: <https://clinicaltrials.gov/ct2/show/NCT02213081?term=ulipristal+and+endometriosis&rank=1>.
9. BULUN SE, CHENG Y, YIN P, IMIR G, UTSUNOMIYA H, ATTAR E et al. Progesterone resistance in endometriosis: link to failure to metabolize estradiol. *Mol Cell Endocrinol* 2006;248(1-2):94–103. doi:10.1016/j.mce.2005.11.041.
10. BULUN SE, MONSAVAIS D, PAVONE ME, DYSON M, XUE Q, ATTAR E et al. Role of estrogen receptor-beta in endometriosis. *Semin Reprod Med* 2012;30(1):39–45. doi:10.1055/s-0031-1299596.
11. BULUN SE, MONSAVAIS D, KAKINUMA T, FURUKAWA Y, BERNARDI L, PAVONE ME et al. Molecular biology of endometriosis: from aromatase to genomic abnormalities. *Semin Reprod Med* 2015;33(3):220–4. doi:10.1055/s-0035-1554053.
12. BURNEY RO, TALBI S, HAMILTON AE, VO KC, NYEGAARD M, NEZHAT CR et al. Gene expression analysis of endometrium reveals progesterone resistance and candidate susceptibility genes in women with endometriosis. *Endocrinology* 2007;148(8):3814–26. doi:10.1210/en.2006-1692.
13. CHWALISZ K, PEREZ MC, DEMANNO D, WINKEL C, SCHUBERT G, ELGER W. Selective progesterone receptor modulator development and use in the treatment of leiomyomata and endometriosis. *Endocr Rev* 2005;26(3):423–38. doi:10.1210/er.2005-0001.
14. CROSIGNANI PG, LUCIANO A, RAY A, BERGQVIST A. Subcutaneous depot medroxyprogesterone acetate versus leuprolide acetate in the treatment of endometriosis-associated pain. *Hum Reprod* 2006;21(1):248–56. doi:10.1093/humrep/dei290.
15. GESTRINONE ITALIAN STUDY GROUP. Gestrinone versus a gonadotropin-releasing hormone agonist for the treatment of pelvic pain associated with endometriosis: a multicenter, randomized, double-blind study. *Fertil Steril* 1996;66(6):911–9.
16. GIUDICE LC. Clinical practice. Endometriosis. *N Engl J Med* 2010;362(25):2389–98. doi:10.1056/NEJMcp1000274.

17. HIROTA Y, TRANGUCH S, DAIKOKU T, HASEGAWA A, OSUGA Y, TAKETANI Y et al. Deficiency of immunophilin FKBP52 promotes endometriosis. *Am J Pathol* 2008;173(6):1747–57. doi:10.2353/ajpath.2008.080527.
18. IMESCH P, SAMARTZIS EP, DEDES KJ, FINK D, FEDIER A. Histone deacetylase inhibitors down-regulate G-protein-coupled estrogen receptor and the GPER-antagonist G-15 inhibits proliferation in endometriotic cells. *Fertil Steril* 2013;100(3):770–6. doi:10.1016/j.fertnstert.2013.05.008.
19. IOFFE OB, ZAINO RJ, MUTTER GL. Endometrial changes from short-term therapy with CDB-4124, a selective progesterone receptor modulator. *Mod Pathol* 2009;22(3):450–9. doi:10.1038/modpathol.2008.204.
20. KETTEL LM, MURPHY AA, MORALES AJ, YEN SS. Preliminary report on the treatment of endometriosis with low-dose mifepristone (RU 486). *Am J Obstet Gynecol* 1998;178(6):1151–6.
21. KIM JJ, KURITA T, BULUN SE. Progesterone action in endometrial cancer, endometriosis, uterine fibroids, and breast cancer. *Endocr Rev* 2013;34(1):130–62. doi:10.1210/er.2012-1043.
22. KITAWAKI J, KADO N, ISHIHARA H, KOSHIBA H, KITAOKA Y, HONJO H. Endometriosis: the pathophysiology as an estrogen-dependent disease. *J Steroid Biochem Mol Biol* 2002;83(1-5):149–55.
23. KLIJN JG, SETYONO-HAN B, FOEKENS JA. Progesterone antagonists and progesterone receptor modulators in the treatment of breast cancer. *Steroids* 2000;65(10-11):825–30.
24. LESSEY BA, YOUNG SL. Homeostasis imbalance in the endometrium of women with implantation defects: the role of estrogen and progesterone. *Semin Reprod Med* 2014;32(5):365–75. doi:10.1055/s-0034-1376355.
25. MATSUZAKI S, MURAKAMI T, UEHARA S, CANIS M, SASANO H, OKAMURA K. Expression of estrogen receptor alpha and beta in peritoneal and ovarian endometriosis. *Fertil Steril* 2001;75(6):1198–205.
26. MEI L, BAO J, TANG L, ZHANG C, WANG H, SUN L et al. A novel mifepristone-loaded implant for long-term treatment of endometriosis: in vitro and in vivo studies. *Eur J Pharm Sci* 2010;39(5):421–7. doi:10.1016/j.ejps.2010.01.012.
27. MOGHISSI KS, BOYCE CR. Management of endometriosis with oral medroxyprogesterone acetate. *Obstet Gynecol* 1976;47(3):265–7.
28. MUNEYYIRCI-DELALE O, JALOU S, RAHMAN M, NACHARAJU V. Can we decrease breakthrough bleeding in patients with endometriosis on norethindrone acetate? *Int J Fertil Womens Med* 2003;48(1):32–6.
29. OGER P, ALIFANO M, REGNARD JF, GOMPEL A. Difficult management of recurrent catamenial pneumothorax. *Gynecol Endocrinol* 2006;22(12):713–5. doi:10.1080/09513590601015051.
30. PLUCHINO N, FRESCHI L, WENGER JM, STREULI I. Innovations in classical hormonal targets for endometriosis. *Expert Rev Clin Pharmacol* 2016;9(2):317–27. doi:10.1586/17512433.2016.112989.
31. PROSSNITZ ER, ARTERBURN JB, LA SKLAR. GPR30: A G protein-coupled receptor for estrogen. *Mol Cell Endocrinol* 2007;265-266:138–42. doi:10.1016/j.mce.2006.12.010.
32. REGIDOR PA, REGIDOR M, SCHMIDT M, RUWE B, LUBBEN G, FORTIG P et al. Prospective randomized study comparing the GnRH-agonist leuprorelin acetate and the gestagen lynestrenol in the treatment of severe endometriosis. *Gynecol Endocrinol* 2001;15(3):202–9.
33. REIS FM, PETRAGLIA F, TAYLOR RN. Endometriosis: hormone regulation and clinical consequences of chemotaxis and apoptosis. *Hum Reprod Update* 2013;19(4):406–18. doi:10.1093/humupd/dmt010.
34. REPROS THERAPEUTICS INC. Study Evaluating the Safety and Efficacy of Proellex® in the Treatment of Endometriosis-extension Study; Available from: <https://clinicaltrials.gov/ct2/show/record/NCT00958412?term=proellex&rank=19>.
35. SCHLAFF WD, DUGOFF L, DAMEWOOD MD, ROCK JA. Megestrol acetate for treatment of endometriosis. *Obstet Gynecol* 1990;75(4):646–8.
36. SPITZ IM. Mifepristone: where do we come from and where are we going? Clinical development over a quarter of a century. *Contraception* 2010;82(5):442–52. doi:10.1016/j.contraception.2009.12.012.
37. STOECKEMANN K, HEGELE-HARTUNG C, CHWALISZ K. Effects of the progesterone antagonists onapristone (ZK 98 299) and ZK 136 799 on surgically induced endometriosis in intact rats. *Hum Reprod* 1995;10(12):3264–71.
38. TAN H, YI L, ROTE NS, HURD WW, MESIANO S. Progesterone receptor-A and -B have opposite effects on proinflammatory gene expression in human myometrial cells: implications for progesterone actions in human pregnancy and parturition. *J Clin Endocrinol Metab* 2012;97(5):E719-30. doi:10.1210/jc.2011-3251.
39. VERCELLINI P, AIMI G, PANAZZA S, GIORGI O DE, PESOLE A, CROSIGNANI PG. A levonorgestrel-releasing intrauterine system for the treatment of dysmenorrhea associated with endometriosis: a pilot study. *Fertil Steril* 1999;72(3):505–8.
40. VERCELLINI P, GIORGI O DE, MOSCONI P, STELLATO G, VICENTINI S, CROSIGNANI PG. Cyproterone acetate versus a continuous monophasic oral contraceptive in the treatment of recurrent pelvic pain after conservative surgery for symptomatic endometriosis. *Fertil Steril* 2002;77(1):52–61.
41. VERCELLINI P, PIETROPAOLO G, GIORGI O DE, PASIN R, CHIODINI A, CROSIGNANI PG. Treatment of symptomatic rectovaginal endometriosis with an estrogen-progestogen combination versus low-dose norethindrone acetate. *Fertil Steril* 2005;84(5):1375–87. doi:10.1016/j.fertnstert.2005.03.083.
42. VERCELLINI P, VIGANO P, SOMIGLIANA E, FEDELE L. Endometriosis: pathogenesis and treatment. *Nat Rev Endocrinol* 2014;10(5):261–75. doi:10.1038/nrendo.2013.255.
43. WAGENFELD A, MOELLER C, ZOLLNER TM. Efficacy of Vilaprisan in an Endometriosis Model and Comparison of Its PR Antagonistic Activity With Other SPRMs in Different Animal Models.
44. WU Y, STRAWN E, BASIR Z, HALVERSON G, GUO SW. Promoter hypermethylation of progesterone receptor isoform B (PR-B) in endometriosis. *Epigenetics* 2006;1(2):106–11.
45. XUE Q, LIN Z, CHENG YH, HUANG CC, MARSH E, YIN P et al. Promoter methylation regulates estrogen receptor 2 in human endometrium and endometriosis. *Biol Reprod* 2007;77(4):681–7. doi:10.1095/biolreprod.107.061804.



# 2 Diagnostic Workup and Preparation for Surgery

---



2.1	History Taking, Office Diagnostics and Imaging .....	98
2.2	Preparative Steps in Laparoscopic Endometriosis Surgery. ....	105
2.3	Surgical Instruments, Powered Devices and Videoendoscopic Equipment	110
2.4	Diagnostic Imaging of Endometriosis. ....	141
2.5	A Comparison of Pelvic Magnetic Resonance Imaging, Transvaginal and Transrectal Sonography, and Laparoscopic Findings in the Diagnosis of Deep Infiltrating Endometriosis. ....	152
2.6	Ultrasound Imaging in the Diagnosis of Deep Infiltrating Endometriosis (DIE) and Adenomyosis. ....	162

Monika Wöfler<sup>a</sup> | Tom Holland<sup>b</sup> | Ivo Meinhold-Heerlein<sup>c</sup>

### 2.1.1 Introduction

Endometriosis is a variable disease with numerous manifestations and associated clinical problems and there is no clear correlation between anatomic severity and symptoms.<sup>35</sup> Some women have relatively minimal disease but severe pain symptoms and others are found incidentally with severe anatomical disease but minimal pain. A complete symptom history in combination with examination findings and diagnostic imaging are essential to understanding the impact that the disease has on the patient in order to plan a treatment strategy.

One of the goals of a complete history is to identify patients at risk of having endometriosis. This reduces diagnostic delay and provides early detection and treatment of the disease.<sup>17</sup> Another goal is to achieve an equivalent estimation of the severity of the disease in order to plan surgery appropriately. Yet the efficacy and accuracy of anamnesis or a detailed analysis of pain symptoms by standardized questionnaires are limited when it comes to predicting the location and severity of endometriosis.<sup>1,4,8</sup>

The diagnosis of endometriosis is corroborated by additional physical examination and imaging techniques – especially by transvaginal ultrasound – and is ultimately proven by laparoscopic findings and histological examination of specimens excised.<sup>7</sup>

### 2.1.2 History Taking

What is the best way to take a complete history and evaluate pain in a revealing way in patients with suspected endometriosis? One strategy is to begin the interview with open questioning and then follow with targeted questions. Physician assessed symptoms however may introduce bias and therefore standardized questionnaires such as the *Endometriosis Health Profile (EPH-30)*<sup>21</sup> which assess effects on quality of life, when filled out in advance, can provide a good basis for the subsequent interview. These standardized scoring systems also provide an unbiased tool for assessing improvement in symptoms after any given intervention and for researching new interventions. The EPH-30 is displayed in Fig. 2.1.

The figure displays four panels of the Endometriosis Health Profile Questionnaire (EPH-30). The first panel shows the title and the core questionnaire section with 7 questions. The second panel shows the 'Domestics' section with 14 questions. The third panel shows the 'Sexual' section with 12 questions. The fourth panel shows the 'Social' section with 10 questions. Each question is followed by a Likert scale from 1 to 5.

Fig. 2.1 Endometriosis Health Profile Questionnaire (EPH-30).

<sup>a</sup> MD; Medical University of Graz, Department of Obstetrics and Gynecology, Graz, Austria

<sup>b</sup> MBBS, MD (Res), MRCOG; Gynaecologist, Guy's and St Thomas' Hospital, London, United Kingdom

<sup>c</sup> Professor h.c., Professor Dr. med. habil. Vice Director, Department of Gynecology and Obstetrics, Medical University of the RWTH Aachen, Germany

#### Corresponding author:

OA Dr. med. **Monika Martina Wöfler**  
 Universitätsklinik für Frauenheilkunde und Geburtshilfe  
 Landeskrankenhaus Universitätsklinikum Graz  
 Auenbrugger Platz 14  
 8036 Graz, Austria  
 E-mail: monika.woelfler@medunigraz.at

According to a review by *Bourdel et al.*, the *visual analogue scale (VAS)* and numerical rating scale (NRS) are the most frequently used pain scales. They seem best suited to endometriosis pain measurement. Moreover, using VAS or NRS for several types of typical pain conditions related to endometriosis (dysmenorrhea, deep dyspareunia and non-menstrual pelvic pain) combined with a quality-of-life scale proves a tool for evaluating treatment response and optimizing a patient's counseling on a continuing basis.<sup>3</sup> Although pain symptoms as determined by standardized questionnaires are of limited value as to the severity of disease in general, a differentiated analysis of the mentioned symptoms may still be very valuable in concrete situations. For instance, there is evidence that severe pain in patients with sonographic

suspicion of endometrioma is associated with *deep infiltrating endometriosis* (DIE). *Lafay-Pillet et al.* identified four variables that are independently associated with DIE in patients with suspected endometriomas: VAS = 5 of gastro-intestinal symptoms or VAS = 5 for deep dyspareunia, duration of pain > 24 months, severe secondary dysmenorrhea, and primary or secondary infertility. A score out of these factors defined a low-risk group where the probability of DIE was 10% and a high-risk group where the probability of DIE was 88%.<sup>23</sup> Thus, history and evaluation of pain symptoms associated with DIE suggest which patients may have severe disease in order to plan further diagnostic steps and facilitate optimized planning of the surgical strategy in this population.

### 2.1.3 Symptoms

Descriptions of the symptoms of endometriosis by patients and doctors are often discordant. For instance, according to a study by *Fauconnier et al.* patients often do not report a clear distinction between pelvic pain and dysmenorrhea. Patients tend to express a dimension of suffering and impaired quality of life inherent to painful symptoms.<sup>9</sup> It is important to keep this in mind during the interview and to record symptoms in detail.

#### 2.1.3.1 Dysmenorrhea

Secondary dysmenorrhea requiring analgesia is highly indicative of the presence of endometriosis, adenomyosis of the uterus, or both. Especially in a low prevalence population, when no other symptoms but cyclical pelvic pain are reported, the evaluation of this symptom can be very useful in detecting endometriosis and consecutively referring the patient to laparoscopic diagnosis and therapy at an early stage.<sup>8</sup>

Review data on adolescent girls with severe dysmenorrhea and chronic pelvic pain revealed that two thirds of these adolescents had laparoscopic evidence of endometriosis; one third of these had moderate or severe endometriosis.<sup>20,32</sup> Moreover, a case series of adolescent endometriosis patients demonstrated that severe secondary dysmenorrhea, menorrhagia, and gastrointestinal symptoms during menstruation were the most frequent symptoms indicative of endometriosis.<sup>6</sup>

According to a large cohort study, about 90% of endometriosis patients suffered from severe dysmenorrhea. There was no significant difference whether peritoneum, ovaries, or both were involved or whether DIE was diagnosed. Moreover, no marked difference emerged between the severity of dysmenorrhea and the site and stage of endometriosis; only women with ovarian endometriosis had lower scores.<sup>11</sup>

Thus, dysmenorrhea is a key symptom in adenomyosis as well as it is in the diagnosis of endometriosis.

#### 2.1.3.2 Non-Menstrual (Chronic) Pelvic Pain

As previously mentioned, patients tend to not differentiate between dysmenorrhea and non-menstrual pelvic pain, in particular when they suffer from *chronic pelvic pain* (CPP). Pain scores were found to be of limited efficacy in predicting the location and severity of endometriosis. A history of CPP of more than 24 months, however, was shown to be associated with endometriosis (often DIE) when concurrent

symptoms were present, in particular severe dysmenorrhea, deep dyspareunia and infertility.<sup>22,23</sup> Where frequent or severe non-menstrual pelvic pain and dyspareunia are reported, no clear association has emerged in those cases between the presence and severity of dysmenorrhea and the site of endometriosis.<sup>31</sup>

In case of CPP without other cardinal symptoms indicative of endometriosis, where pelvic examination and ultrasound are normal, other causes of CPP must be considered in the differential diagnosis, including functional pelvic pain, irritable bowel syndrome, and interstitial cystitis/bladder pain syndrome.<sup>34</sup> Many chronic pain patients are also likely to have central sensitization<sup>37</sup> whereby the initial stimulus can trigger increased spinal sensitivity and ongoing painful sensations even in the absence of the original stimulus. These patients require the input of specialists in chronic pain modification.

#### 2.1.3.3 Dyspareunia and Sexual Dysfunction

Several studies have reported that endometriotic lesions of the posterior cul-de-sac, uterosacral ligaments, and DIE lesions of the rectovaginal septum, pelvic wall, and rectosigmoid are associated with deep dyspareunia.<sup>8,31</sup> Deep dyspareunia is often accompanied by pathologic findings during pelvic palpation and/or ultrasound.

Female sexual distress and sexual dysfunction are frequently observed in endometriosis patients, correlated with pain intensity during or after sexual intercourse. Often the results are fewer episodes of sexual intercourse per month, greater feelings of guilt toward the partner, and lowered feelings of femininity.<sup>10</sup> Moreover, in this multicenter cohort study almost two-thirds of women agreed that the primary motivation for sexual intercourse was to conceive, and nearly half stated that satisfying the partner was the primary motivation for sexual contact.

It is essential to address this topic openly during the interview since patients might not bring up dyspareunia or sexual dysfunction by themselves.

#### 2.1.3.4 Reproductive History

Endometriosis affects a significant proportion of reproductive-age women. Plenty of evidence associates primary and secondary infertility with endometriosis, but a causal relationship has yet to be resolved. Thus, in women who wish to conceive, and have minimal or mild endometriosis, there is good evidence that surgical ablation or resection will improve natural conception rates. In women with endometriomas who wish to conceive spontaneously, excision of the endometrioma capsule is preferable to drainage and diathermy. In women with deep infiltrating endometriosis or severe tubal occlusive disease there is no clear evidence that surgical excision improves success by assisted reproductive techniques and any surgery to the ovary can reduce the ovarian reserve. For these patients it may be preferable to focus on the fertility aspects first and the pain treatment once they have either completed their family or finished with fertility treatment. The treatment of patients with severe endometriosis and infertility should be left in expert hands.<sup>7,34</sup>



### 2.1.3.5 Gastro-Intestinal Symptoms

Digestive symptoms might be the result of cyclic inflammatory phenomena leading to irritation of the digestive tract. They are not necessarily the result of actual involvement of the digestive tract by endometriosis itself, because they frequently occur in women free of nodules in the rectum or other intestinal sites.<sup>29</sup> However, severe pain on defecation associated with menstruation (cyclic dyschezia) is highly suggestive of bowel DIE.

Based on a large case series, *Roman et al.* found that cyclic defecation pain, cyclic constipation, and a longer stool evacuation time are significantly associated with rectal endometriosis. However, these complaints were also frequent in women with superficial and deep endometriosis without digestive involvement. Therefore, specific diagnostics for the detection of rectal endometriosis are essential. In the studied population, only one-quarter of women with rectal endometriosis actually had rectal stenosis. These women reported significantly more often about constipation, defecation pain, appetite disorders, longer evacuation time, and increased stool consistency without laxatives.<sup>30</sup>

### 2.1.3.6 Urinary Tract Symptoms

Dysuria associated with menstruation, and cyclic hematuria are suggestive of endometriotic involvement of the bladder and warrant further investigation with imaging. Excision of bladder endometriosis is relatively straightforward for experienced practitioners and often relieves symptoms completely. Referral to endometriosis centres is recommended if bladder endometriosis is suspected. DIE of the uterosacral ligaments which can infiltrate the pelvic side wall can encircle the ureter and cause stenosis. Progression of this stenosis often goes unnoticed as symptoms are rare and it can lead to hydronephrosis and loss of renal function.<sup>34</sup>

### 2.1.3.7 Other Symptoms

Some patients suffering from severe dysmenorrhea or CPP might report symptoms of a vasovagal reaction like syncope, nausea, or sometimes even vomiting. The evidence that these symptoms are associated with the presence or severity of endometriosis is poor.

Pain symptoms or cyclic pain in the umbilicus, inguinal canal, perineum or scars from intraperitoneal surgery (especially caesarean section) with or without palpable masses should always be evaluated properly, since extragenital endometriosis is a rare but often painful condition that can most often be resolved by surgical excision.<sup>5</sup>

## 2.1.4 Structured Office Diagnostics and Imaging

According to the ESHRE as well as to the German Endometriosis Guidelines, clinicians should perform physical examination of all women suspected of endometriosis.<sup>7,34</sup>

Generally recommended diagnostic steps are:

- Inspection and palpation of the abdomen
- Physical examination of the pelvis including
  - Inspection and visualization of the posterior vaginal fornix
  - Bimanual transvaginal palpation of the pelvis
  - Transrectal palpation (upon suspicion of DIE)
- Transvaginal ultrasound
- Renal ultrasound (upon suspicion of DIE or ureteral endometriosis)

## 2.1.5 Physical Examination

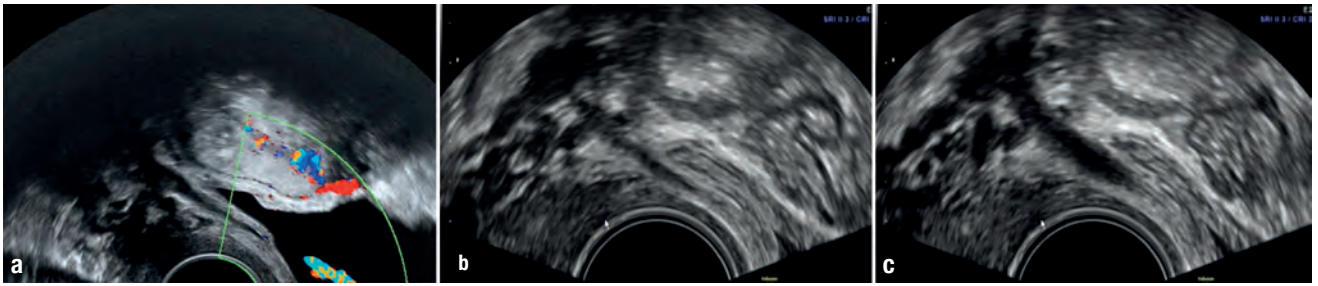
Inspection, physical examination, and transvaginal ultrasound in the pre-operative work-up are standard procedures for most gynecologic disorders. Inspection and palpation of the abdomen, as well as of scars from previous surgery if present, can provide a general first impression. The patient should be motivated to indicate the precise location of painful sensations. During inspection of the vagina and cervix in particular the posterior vaginal fornix should be visualized.

Vaginal examination may be inappropriate for adolescents and/or women who have not had previous sexual intercourse. In such cases, rectal palpation can be helpful for the diagnosis of endometriosis.<sup>7</sup>

When there is suspicion of endometriosis, special attention should be paid to the examination of adnexal masses, painful induration, and/or nodules of the rectovaginal wall, sacrouterine ligaments, pelvic wall, and the rectum during vaginal and rectal palpation.<sup>2</sup> However, the value of the physical examination alone might be limited because it cannot be reproduced and depends on the clinician's skills. It has also been shown to be less accurate than transvaginal ultrasound, even when performed by very experienced surgeons<sup>15</sup> especially for ovarian, uterosacral and rectosigmoid endometriosis. The combination of physical examination and transvaginal ultrasound, however, allows accurate prediction of endometriosis affecting the ovaries, vagina, rectum, uterosacral ligaments, rectovaginal space, and pouch of Douglas.<sup>18</sup> Thus, a routine combination of pelvic palpation and transvaginal ultrasound is recommended for primary assessment of all patients upon suspicion of endometriosis.

## 2.1.6 Transvaginal Ultrasound

The development of *transvaginal sonography* (TVS) has significantly influenced the therapeutic approach to endometriosis. Ovarian disease and moderate or severe disease can be accurately predicted with the correct technique and experience<sup>14</sup> and this technique has been shown to be reproducible.<sup>13</sup> Minimal and mild disease, which can be extremely painful, can not be diagnosed accurately as the lesions are too small to see on ultrasound. The only features of mild disease which can be detected are ovarian adhesions. An accurate non-invasive diagnosis of the stage of disease is helpful as: there is significant overlap of symptoms with other diseases such as adenomyosis; patients may choose fertility treatment prior to surgery; when surgery is chosen it enables



**Fig. 2.2** Ureteric jet into the bladder on colour Doppler ultrasound (a). Normal ureter before filling (b). Normal ureter after filling (c).

a complete preoperative counseling of the risks and benefits (informed consent); the most appropriate place and surgeon will depend on the severity of the disease; other specialties (colorectal or urological) may be needed.<sup>15</sup>

Plenty of studies report a learning curve with TVS used to diagnose endometriosis, in particular to diagnose DIE. In a recent study Hudelist et al. demonstrated that TVS is an accurate and highly reproducible method for non-invasive diagnosis of DIE when performed by well-trained professionals.<sup>33</sup> This group also introduced the 'uterine sliding sign' as a simple but highly accurate sonographic predictor of DIE of the rectum.<sup>16</sup> Recently, a TVS-based endometriosis scoring system was introduced to predict the complexity level of laparoscopic surgery against endometriosis. The authors suggest that this scoring system might facilitate triage of women with suspected endometriosis to the most appropriate required surgical expertise.<sup>24</sup>

#### 2.1.6.1 Endometrioma and Ovarian and Pelvic Adhesions

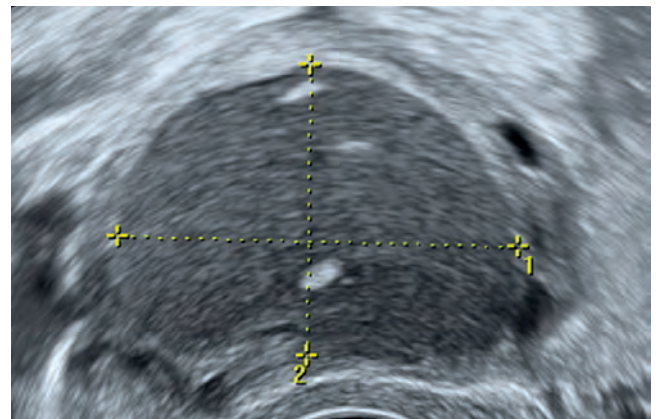
In women with pelvic endometriosis, ultrasound examination enables diagnosis of ovarian endometriomas with a high degree of accuracy. A decade ago other endometriotic lesions were considered undetectable.<sup>12,25</sup> Now with careful assessment ovarian and pouch of Douglas adhesions can be accurately detected.<sup>12</sup>

It is useful to always follow the same routine when assessing the pelvis for endometriosis. Patients should be examined in the dorsolithotomy position and the free hand should be used for palpation of the abdomen. Ultrasound has the advantage of being a dynamic technique and this movement of organs, either by gentle pressure with the ultrasound probe or from above with the free hand will elicit free movement of organs against one another when no adhesions exist. The absence of this movement can be interpreted as adhesions.

First the endometrial cavity should be assessed both for anomalies and for any pathology. Then the myometrium should be assessed for adenomyosis (see below) and fibroids. Next the uterovesical fold and the bladder should be assessed. It is helpful to ask the patient to empty their bladder before the history is taken so that there is a small amount of urine. The bladder should be easily separated from the uterus by gentle pressure between the bladder and uterus with the probe. Adhesions in this area can be from scarring secondary to caesarean section but also from endometriosis. If the bladder wall is thickened at the point where it is stuck to the uterus this is highly suggestive of DIE (see following chapter). Next the ureteric orifice in the bladder can be identified as a raised

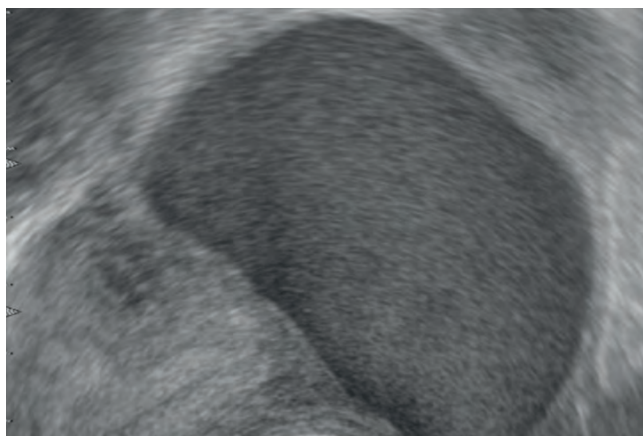
structure (urine can be seen venting from this intermittently (Fig. 2.2a) and, running posterolateral to this), the intravesical portion of the ureter can be followed. This can be traced out of the bladder and into the pelvic side wall (Figs. 2.2b, c). The distal ureter typically appears as a long tubular hypoechoic structure with a thick hyperechoic mantle.<sup>28</sup> The ureters should be fairly straight and peristalsis should be seen to freely down the length of the ureter. With severe endometriosis affecting the ureter there may be deviation from the normal path with bending of the ureter and ultimately stenosis leading to hydronephrosis and eventually hydronephrosis. The main advantage of routinely visualising the ureters on ultrasound examination is detection of partial ureteric obstruction before hydronephrosis develops. In these women early treatment with ureteric laparoscopic ureterolysis and/or stenting helps to prevent any loss of renal function.<sup>27</sup>

Next, the adnexae should be assessed for the presence of adhesions and pathology. Ovarian endometriomas typically appear as well-circumscribed, thick-walled cysts containing homogenous low-level internal echoes (ground glass) (Fig. 2.3). Adjacent to the ovaries, care should be taken to examine for tubal dilatation. Ovarian mobility should be assessed by a combination of gentle pressure with the vaginal probe and abdominal pressure with the examiner's free hand, as in a bimanual examination. The ovary was deemed to be completely free when all of its borders could be seen sliding across the surrounding structures. Adhesion of the ovaries present when they can not be separated from surrounding structures. Common locations for ovarian adhesions are the



**Fig. 2.3** Typical appearance of an endometrioma with ground glass contents, the cyst located within the centre of the ovary and loss of ovarian capsule at the point of adherence.





**Fig. 2.4** Ovarian endometrioma with adhesions to uterus.

pelvic side wall (ovarian fossa), uterosacral ligaments and the posterolateral aspects of the uterus (Fig. 2.4).

Next the posterior compartment should be assessed. The presence of adhesions in the pouch of Douglas was assessed by evaluating the uterus. A combination of pressure on the fundus with the examiner's free hand on the abdominal wall, alternating with pressure on the cervix with the ultrasound probe, lets the uterus be mobilized gently. The interface of the bowel behind and the posterior uterine serosa in front is observed to ensure that the two structures slide easily across one another. If these two surfaces were completely free of one another, then adhesions were assumed to be unlikely. If these two planes do not slide then adhesions are likely to be present. If adhesions are present then further evaluation of the posterior structures (such as the rectal muscularis, uterosacral ligaments, and posterior vaginal wall) is essential as DIE is likely to be present.<sup>12</sup>

With this standardized technique the TVS diagnosis of endometriotic lesions is very specific. False positive results are rare, however, negative findings are less reliable, and women with significant symptoms may still benefit from further investigation even when TVS findings are normal as minimal and mild disease may still benefit from surgical treatment.

The accuracy of ultrasound diagnosis is significantly affected by the location and number of endometriotic lesions. In particular, diagnosis of endometrioma, ovarian adhesions, and pouch of Douglas obliteration was shown to be highly accurate.<sup>19</sup>

Transvaginal ultrasound imaging to diagnose DIE is treated in detail in a subsequent chapter.

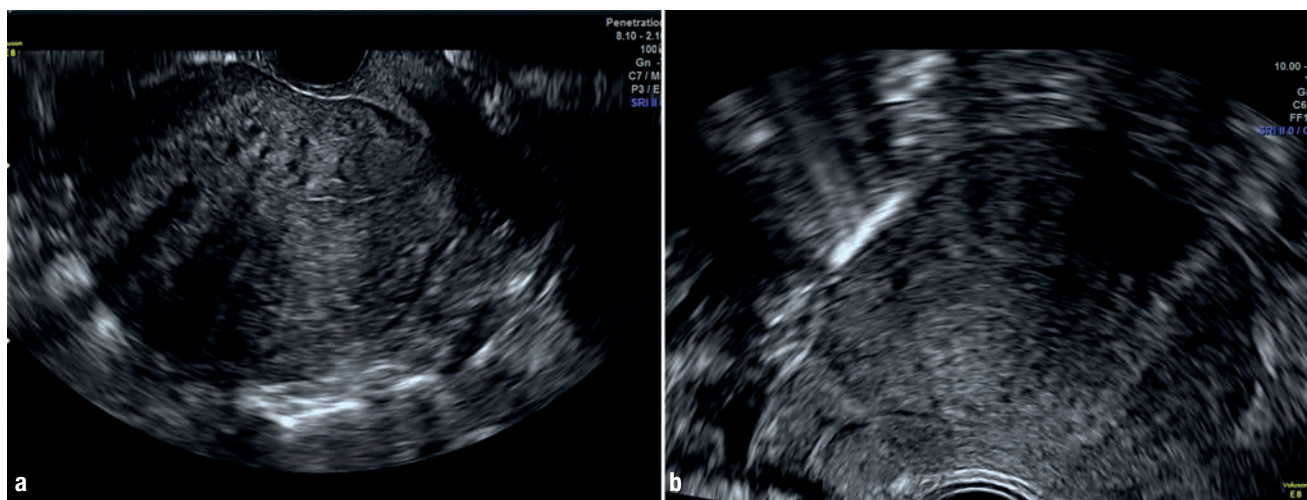
#### 2.1.6.2 Adenomyosis

Adenomyosis and endometriosis frequently coexist. Both are highly associated with the symptom of severe dysmenorrhea. There is a significant correlation of histologic diagnosis of adenomyosis and certain ultrasound features, which are described as asymmetrical myometrial thickening, myometrial cysts, linear striations, parallel shadowing, adenomyomas, hyperechoic islands (Fig. 2.5a, b), and irregular endometrial-myometrial junction either on B-mode or 3-dimensional imaging.<sup>26</sup>

The presence of adenomyosis significantly reduces the likelihood of pregnancy in women trying to conceive. According to recent review data, adenomyosis appears to impact negatively on the IVF/ICSI outcome owing to a reduced likelihood of clinical pregnancy and implantation. It is also associated with an increased risk of early pregnancy loss.<sup>36</sup> Therefore, adenomyosis screening should be encouraged prior to medically assisted reproductive procedures and comprehensive patient counseling is required.

#### 2.1.7 Conclusion

In summary, this chapter has examined in detail how a comprehensive physical examination and meticulous transvaginal ultrasound imaging can provide highly accurate prediction of endometriosis. It should be performed by well-trained professionals following a complete history that accounts for the patient's needs and potential indications for an operation. These are prerequisites for adequate triage and appropriate planning of a therapeutic strategy.



**Fig. 2.5** Typical appearance of adenomyotic uterus (a). Typical appearance of adenomyotic uterus (b).



### 2.1.8 References

1. BALLARD KD, SEAMAN HE, VRIES CS DE, WRIGHT JT. Can symptomatology help in the diagnosis of endometriosis? Findings from a national case-control study – Part 1. *BJOG* 2008;115(11):1382–91. doi:10.1111/j.1471-0528.2008.01878.x.
2. BAZOT M, LAFONT C, ROUZIER R, ROSEAU G, THOMASSIN-NAGGARA I, DARAI E. Diagnostic accuracy of physical examination, transvaginal sonography, rectal endoscopic sonography, and magnetic resonance imaging to diagnose deep infiltrating endometriosis. *Fertil Steril* 2009;92(6):1825–33. doi:10.1016/j.fertnstert.2008.09.005.
3. BOURDEL N, ALVES J, PICKERING G, RAMILO I, ROMAN H, CANIS M. Systematic review of endometriosis pain assessment: how to choose a scale? *Hum Reprod Update* 2015;21(1):136–52. doi:10.1093/humupd/dmu046.
4. CHAPRON C, BARAKAT H, FRITEL X, DUBUISSON JB, BREART G, FAUCONNIER A. Presurgical diagnosis of posterior deep infiltrating endometriosis based on a standardized questionnaire. *Hum Reprod* 2005;20(2):507–13. doi:10.1093/humrep/deh627.
5. DOUGLAS C, ROTIMI O. Extragenital endometriosis – a clinicopathological review of a Glasgow hospital experience with case illustrations. *J Obstet Gynaecol* 2004;24(7):804–8. doi:10.1080/01443610400009568.
6. DUN EC, KHO KA, MOROZOV VV, KEARNEY S, ZURAWIN JL, NEZHAT CH. Endometriosis in adolescents. *JSLs* 2015;19(2). doi:10.4293/JSLs.2015.00019.
7. DUNSELMAN GA, VERMEULEN N, BECKER C, CALHAZ-JORGE C, D'HOOGHE T, BIE B DE et al. ESHRE guideline: management of women with endometriosis. *Hum Reprod* 2014;29(3):400–12. doi:10.1093/humrep/det457.
8. FAUCONNIER A, CHAPRON C. Endometriosis and pelvic pain: epidemiological evidence of the relationship and implications. *Hum Reprod Update* 2005;11(6):595–606. doi:10.1093/humupd/dmi029.
9. FAUCONNIER A, STARACI S, HUCHON C, ROMAN H, PANEL P, DESCAMPS P. Comparison of patient- and physician-based descriptions of symptoms of endometriosis: a qualitative study. *Hum Reprod* 2013;28(10):2686–94. doi:10.1093/humrep/det310.
10. FRITZER N, HAAS D, OPPELT P, RENNER S, HORNING D, WÖFLER M et al. More than just bad sex: sexual dysfunction and distress in patients with endometriosis. *Eur J Obstet Gynecol Reprod Biol* 2013;169(2):392–6. doi:10.1016/j.ejogrb.2013.04.001.
11. GRUPPO ITALIANO PER LO STUDIO DELL'ENDOMETRIOSI. Relationship between stage, site and morphological characteristics of pelvic endometriosis and pain. *Hum Reprod* 2001;16(12):2668–71.
12. HOLLAND TK, CUTNER A, SARIDOGAN E, MAVRELOS D, PATEMAN K, JURKOVIC D. Ultrasound mapping of pelvic endometriosis: does the location and number of lesions affect the diagnostic accuracy? A multicentre diagnostic accuracy study. *BMC Womens Health* 2013;13:43. doi:10.1186/1472-6874-13-43.
13. HOLLAND TK, HOO WL, MAVRELOS D, SARIDOGAN E, CUTNER A, JURKOVIC D. Reproducibility of assessment of severity of pelvic endometriosis using transvaginal ultrasound. *Ultrasound Obstet Gynecol* 2013;41(2):210–5. doi:10.1002/uog.11216.
14. HOLLAND TK, YAZBEK J, CUTNER A, SARIDOGAN E, HOO WL, JURKOVIC D. Value of transvaginal ultrasound in assessing severity of pelvic endometriosis. *Ultrasound Obstet Gynecol* 2010;36(2):241–8. doi:10.1002/uog.7689.
15. HUDELIST G, ENGLISH J, THOMAS AE, TINELLI A, SINGER CF, KECKSTEIN J. Diagnostic accuracy of transvaginal ultrasound for non-invasive diagnosis of bowel endometriosis: systematic review and meta-analysis. *Ultrasound Obstet Gynecol* 2011;37(3):257–63. doi:10.1002/uog.8858.
16. HUDELIST G, FRITZER N, STAETTNER S, TAMMAA A, TINELLI A, SPARIC R et al. Uterine sliding sign: a simple sonographic predictor for presence of deep infiltrating endometriosis of the rectum. *Ultrasound Obstet Gynecol* 2013;41(6):692–5. doi:10.1002/uog.12431.
17. HUDELIST G, FRITZER N, THOMAS A, NIEHUES C, OPPELT P, HAAS D et al. Diagnostic delay for endometriosis in Austria and Germany: causes and possible consequences. *Hum Reprod* 2012;27(12):3412–6. doi:10.1093/humrep/des316.
18. HUDELIST G, OBERWINKLER KH, SINGER CF, TUTTLIES F, RAUTER G, RITTER O et al. Combination of transvaginal sonography and clinical examination for preoperative diagnosis of pelvic endometriosis. *Hum Reprod* 2009;24(5):1018–24. doi:10.1093/humrep/dep013.
19. HUDELIST G, TUTTLIES F, RAUTER G, PUCHER S, KECKSTEIN J. Can transvaginal sonography predict infiltration depth in patients with deep infiltrating endometriosis of the rectum? *Hum Reprod* 2009;24(5):1012–7. doi:10.1093/humrep/dep014.
20. JANSSEN EB, RIJKERS AC, HOPPENBROUWERS K, MEULEMAN C, D'HOOGHE TM. Prevalence of endometriosis diagnosed by laparoscopy in adolescents with dysmenorrhea or chronic pelvic pain: a systematic review. *Hum Reprod Update* 2013;19(5):570–82. doi:10.1093/humupd/dmt016.
21. JONES G, KENNEDY S, BARNARD A, WONG J, JENKINSON C. Development of an endometriosis quality-of-life instrument: The Endometriosis Health Profile-30. *Obstet Gynecol* 2001;98(2):258–64.
22. KONINCKX PR, USSIA A, ADAMYAN L, WATTIEZ A, DONNEZ J. Deep endometriosis: definition, diagnosis, and treatment. *Fertil Steril* 2012;98(3):564–71. doi:10.1016/j.fertnstert.2012.07.1061.
23. LAFAY-PILLET MC, HUCHON C, SANTULLI P, BORGHESE B, CHAPRON C, FAUCONNIER A. A clinical score can predict associated deep infiltrating endometriosis before surgery for an endometrioma. *Hum Reprod* 2014;29(8):1666–76. doi:10.1093/humrep/deu128.
24. MENAKAYA U, REID S, LU C, GERGES B, INFANTE F, CONDOUS G. Performance of an Ultrasound Based Endometriosis Staging System (UBESS) for predicting the level of complexity of laparoscopic surgery for endometriosis. *Ultrasound Obstet Gynecol* 2016. doi:10.1002/uog.15858.
25. MOORE J, COPLEY S, MORRIS J, LINDSELL D, GOLDING S, KENNEDY S. A systematic review of the accuracy of ultrasound in the diagnosis of endometriosis. *Ultrasound Obstet Gynecol* 2002;20(6):630–4. doi:10.1046/j.1469-0705.2002.00862.x.
26. NAFTALIN J, HOO W, NUNES N, HOLLAND T, MAVRELOS D, JURKOVIC D. The association between ultrasound features of adenomyosis and severity of menstrual pain. *Ultrasound Obstet Gynecol* 2015. doi:10.1002/uog.15798.
27. PATEMAN K, HOLLAND TK, KNEZ J, DERDELIS G, CUTNER A, SARIDOGAN E et al. Should a detailed ultrasound examination of the complete urinary tract be routinely performed in women with suspected pelvic endometriosis? *Hum Reprod* 2015;30(12):2802–7. doi:10.1093/humrep/dev246.
28. PATEMAN K, MAVRELOS D, HOO WL, HOLLAND T, NAFTALIN J, JURKOVIC D. Visualization of ureters on standard gynecological transvaginal scan: a feasibility study. *Ultrasound Obstet Gynecol* 2013;41(6):696–701. doi:10.1002/uog.12468.
29. ROMAN H, BRIDOUX V, TUECH JJ, MARPEAU L, DA CC, SAVOYE G et al. Bowel dysfunction before and after surgery for endometriosis. *Am J Obstet Gynecol* 2013;209(6):524–30. doi:10.1016/j.ajog.2013.04.015.

30. ROMAN H, NESS J, SUCIU N, BRIDOUX V, GOURCEROL G, AM LEROI et al. Are digestive symptoms in women presenting with pelvic endometriosis specific to lesion localizations? A preliminary prospective study. *Hum Reprod* 2012;27(12):3440–9. doi:10.1093/humrep/des322.
31. SCHLIEP KC, MUMFORD SL, PETERSON CM, CHEN Z, JOHNSTONE EB, SHARP HT et al. Pain typology and incident endometriosis. *Hum Reprod* 2015;30(10):2427–38. doi:10.1093/humrep/dev147.
32. STAVROULIS AI, SARIDOGAN E, CREIGHTON SM, CUTNER AS. Laparoscopic treatment of endometriosis in teenagers. *Eur J Obstet Gynecol Reprod Biol* 2006;125(2):248–50. doi:10.1016/j.ejogrb.2005.08.024.
33. TAMMAA A, FRITZER N, LOZANO P, KRELL A, SALZER H, SALAMA M et al. Interobserver agreement and accuracy of non-invasive diagnosis of endometriosis by transvaginal sonography. *Ultrasound Obstet Gynecol* 2015;46(6):737–40. doi:10.1002/uog.14843.
34. ULRICH U, BUCHWEITZ O, GREB R, KECKSTEIN J, LEFFERN I VON, OPPELT P et al. National German Guideline (S2k): Guideline for the Diagnosis and Treatment of Endometriosis: Long Version – AWMF Registry No. 015-045. *Geburtshilfe Frauenheilkd* 2014;74(12):1104–18. doi:10.1055/s-0034-1383187.
35. VERCELLINI P. Introduction: Management of endometriosis: moving toward a problem-oriented and patient-centered approach. *Fertil Steril* 2015;104(4):761–3. doi:10.1016/j.fertnstert.2015.09.004.
36. VERCELLINI P, CONSONNI D, DRIDI D, BRACCO B, FRATTARUOLO MP, SOMIGLIANA E. Uterine adenomyosis and in vitro fertilization outcome: a systematic review and meta-analysis. *Hum Reprod* 2014;29(5):964–77. doi:10.1093/humrep/deu041.
37. WOOLF CJ. Central sensitization: implications for the diagnosis and treatment of pain. *Pain* 2011;152(3 Suppl):S2–15. doi:10.1016/j.pain.2010.09.030.

## 2.2

## Preparative Steps in Laparoscopic Endometriosis Surgery

Magdalena Maria Zalewski<sup>a</sup>

### 2.2.1 Introduction

The success of a laparoscopic procedure in endometriosis patients is based on a detailed anamnesis and thorough clinical diagnostics. Once the decision for surgery has been made, there is a set of preparative steps that should be observed in order to facilitate the planned procedure. This also requires that adequate consideration be given to the potential benefits derived from the application of bowel preparation, antibiotics and epidural anesthesia. Besides, it is widely accepted that temperature management plays a crucial role in the avoidance of preventable complications. A standardized and structured approach is an imperative goal for every surgical team.

### 2.2.2 Informed Consent

It is utterly impossible to undertake a surgical procedure without having obtained a signed informed consent document from the patient or his/her legal representative. This document is to prove that a personal conversation between the patient and his/her surgeon was held covering the essential details of the planned surgery, possible complications and all of the alternative options of the surgical procedure. In the course of this conversation, it is important to emphasize the necessity and the urgency of the intervention. Especially in endometriosis patients, this can be a challenge, as endometriosis is not a life-threatening disease. Surgical treatment has “only” the potential of fighting the symptoms of disease, such as pain, or may help to resolve infertility issues.

It is important to make sure that the patient has understood the steps of surgical treatment as well as the common risks and possible complications. This involves that the surgeon is familiar with the patient’s mindset and capable of communicating effectively on patient level.

Care should be taken that the patient is given enough time for consideration before signing the informed consent document. The informed consent conversation should take place at the latest on the day prior to the date of the scheduled surgical procedure.

The patient’s consent must be given as a free, voluntary and conscious decision. Therefore, the surgeon must make sure that the patient wants to have surgery for her own best interests and not for the sake of another person or because she feels obliged to consent to the recommended surgery.

<sup>a</sup> | MD; Department of Gynecology and Obstetrics, Medical University of the RWTH Aachen, Germany

#### Corresponding author:

Dr. med. **Magdalena Maria Zalewski**  
Klinik für Gynäkologie und Geburtsmedizin  
Universitätsklinikum RWTH Aachen  
Pauwelsstraße 30  
52074 Aachen, Germany

It can be helpful for the patient to receive extra information on potential adjuvant treatment options which may already be imparted in the setting of the preoperative workup. It is not mandatory that this be discussed during the preoperative informed consent process, but it helps the patient to develop a good understanding of the complete therapeutic concept.

#### Informed Consent – Important Topics

- One-on-one discussion about the recommended therapy and alternative options.
- Making clear the necessity and the urgency of the planned procedure.
- Possible risks.
- Making sure the patient understands everything (especially with foreign patients).
- Giving enough time (day before surgery at the latest).
- The consent must be given as a free, voluntary decision.

Table 2.1

### 2.2.3 Laboratory Testing

As endometriosis patients tend to be young and otherwise healthy subjects, in general, there is no need for special laboratory testing in the preparatory phase prior to laparoscopic endometriosis surgery.<sup>16</sup> The only recommended laboratory testing is a pregnancy test to prevent surgery in a woman at an early state of gestation, particularly when decision-making related to family planning has not been completed yet. Apart from that, another useful test is the measurement of the hemoglobin level. For patients with an existing anemia who are candidates for an elective operative procedure foreseeably associated with a technically demanding course, blood typing, and possibly, cross-matching, have been shown to be useful in avoiding long waiting periods in the event of blood loss.

Evaluation of renal function can be helpful in patients with endometriosis and concomitant hydronephrosis.

### 2.2.4 Bowel Preparation

The rationale for bowel preparation in gynecologic surgery is to improve surgical vision and facilitate bowel handling, and – in case of iatrogenic bowel injury – to reduce the risk of infection-related complications. Therefore, it is good clinical practice to prepare the patient’s bowel, particularly before surgery of the posterior pelvic compartment. However, data available in the current literature do not show a significant benefit related to the aforementioned aspects after oral bowel preparation compared to a low-residue diet (liquid diet two days before surgery).<sup>25</sup> Based on a report published by *Kantartzis et al.* (2015), it is usually hard for surgeons to tell apart whether a patient received bowel preparation or not, and



it has been shown that no negative impact on perioperative outcome is entailed from the omission of this preparatory measure.<sup>9</sup> The results are the same, even in the case of laparoscopic hysterectomy. Bowel preparation did not yield any improvements in terms of intraoperative visualization, bowel handling or ease of procedure.<sup>18,23</sup>

If the decision is made to arrange for a bowel preparation, this can be done in different ways. There is always the option of using enemas only, or an oral preparation. There are various active substances that may be used for bowel preparation, however no recommendation for the use of a special substance can be given.

Patients subjected to oral preparation usually report on nasty sensations and problems with the high volume intake or side effects such as increased abdominal symptoms, nausea and even vomiting.<sup>17</sup> Hence, the rates of inadequate preparation vary between 20 and 40%. In cases where patients dislike the taste of the fluid, regular use of menthol sugar-free sweets during the procedure has been found to improve patient compliance.<sup>21</sup>

Apart from intake-related shortcomings in bowel preparation, there are also medical reasons like chronic constipation or the use of constipating medications (e.g. opioids) that may account for ineffectiveness of this measure. In these cases, it is important to use a more aggressive bowel cleansing regimen.

When an oral preparation is used, it is recommended that the procedure be undertaken at the hospital because in this setting, patients may be more compliant since they are in constant attendance by the nursing staff. Furthermore, possible consequences like dehydration or an electrolyte imbalance which can lead to various symptoms, can be treated.

### 2.2.5 Antibiotic Prophylaxis and Surgical Site Infection

The *United States Centres for Disease Control and Prevention* (CDC) issued an internationally accepted definition of *surgical site infection* (SSI).<sup>3</sup> The term SSI is defined as an infection of the skin or the subcutaneous tissue of the incision occurring within 30 days post surgery. Antimicrobial prophylaxis can help to avoid SSI.

The decision regarding the use of antimicrobial prophylaxis in a surgical procedure should be based on a standardized risk stratification scheme of objective indicators for the potential onset of SSI. The use of a risk assessment stratification protocol for evaluation of wounds (clean, clean-contaminated, contaminated, dirty wounds) is the most important tool in the decision-making process. Hysterectomy, for example, is defined as a surgical procedure with a clean-contaminated wound and, therefore, there is a certain risk of perioperative infection that requires the implementation of adequate prophylactic measures.

There is only limited data available on the use of antimicrobial prophylaxis in gynecologic surgery. In general, SSI occurs less frequently in laparoscopic surgery than in abdominal surgery.<sup>13</sup>

The use of antibiotic prophylaxis is generally indicated for cancer surgery and hysterectomy.

For gynecological laparoscopy without opening of the vagina, there does not seem to be an indication for routine use of perioperative antibiotic prophylaxis.<sup>4,14</sup> A comparison analysis did not show any significant reduction in SSI rates in those women who underwent surgery without prophylactic administration of antibiotic medication.<sup>11</sup>

Several contributing risk factors are known to increase the risk of SSI:<sup>1,24</sup>

- Advanced patient age.
- Comorbidities (especially diabetes and immunosuppression).
- Obesity.
- Nicotine or drug abuse.
- Preoperative infections.
- Length of surgery (more than 2 hours).
- Blood transfusions.
- Hypothermia.
- Previous radiotherapy.
- Previous surgery.

If the patient eligible for surgery is identified to have risk factors (see panel), a prophylaxis can be implemented even in a planned laparoscopy. To date, there are no precise recommendations on how to decide whether an antimicrobial prophylaxis should be used.

The correct timing plays a key role in the efficiency of antimicrobial prophylaxis. The ideal point in time for the first application is 30 to 60 minutes before the skin incision is made. Administration later than 60 minutes before skin incision has been shown to significantly increase the risk of SSI. For surgical procedures taking less than 2 hours, a single-shot antibiotic prophylaxis is sufficient. Longer procedures require repetitive administration. Timing of multiple administrations depends on the half-life of the chosen antimicrobial agent. Repetitive administration is needed after two half-life periods of the antibiotic in use (e.g. half-life of cefuroxime: 70 minutes; half-life of metronidazole: 7 hours). In general, there is no need for continuing the prophylaxis after completion of the procedure.

### 2.2.6 Epidural Anesthesia

It is widely accepted that laparoscopic procedures should be performed under general anesthesia. Used in addition, an epidural anesthesia may also be considered. Even though studies are still needed to determine the possible benefits and drawbacks of the added administration of epidural anesthetics, some data have been established, elucidating some beneficial aspects of the procedure.

The major advantage of epidural anesthesia is predicated on the fact that it provides for improved postoperative pain control. It is widely accepted practice that adequate pain relief without concomitant severe complications can be achieved by

added use of epidural anesthesia. The benefits of additional epidural anesthesia – as compared to intravenous application of pain medication – in major gynecological cancer surgery include a reduced sedative and respiratory depressant effect during the postoperative period as well as a reduced incidence of *postoperative nausea and vomiting* (PONV). At the same time, effectiveness in terms of pain relief is similar or even better.<sup>5,7,15</sup> Apart from that, there is evidence suggesting an improved recovery of gastrointestinal function in patients with postoperative epidural pain management compared to systematic analgesia in abdominal surgery.<sup>22</sup> Still, there is no clear data available concerning the use of epidural anesthesia for gynecological laparoscopic procedures in particular.

Epidural anesthesia may also be used for perioperative pain management. The modality has been found to decrease total dose consumption related to systemic opioid and analgetic treatment.

### 2.2.7 Surgical Safety Checklist

Nowadays, it should be generally understood that a surgical safety checklist is a valuable tool that must be used in the operating room. The *World Health Organization* (WHO) has published a checklist and an implementation manual available to everyone via internet.<sup>26</sup> By going through a checklist that covers the key phases and critical details of a surgical procedure, patient safety can be improved and the most common and avoidable risks can be minimized. The implementation manual gives suggestions on how to use the checklist.

Phases of the surgical safety checklist	Point in time intended for implementing the safety check
Sign in	Before induction of anaesthesia
Time out	Before skin incision
Sign out	Before patient leaves operating room

**Table 2.2**

A brief summary can help to draw attention to the critical waypoints of the surgical procedure:

- One individual has been assigned to assume responsibility as a coordinator for checking the boxes of the list in all phases of the operation.
- Upon completion of the “sign in” phase, the checklist coordinator must make sure that all tasks have been completed by the surgery team prior to induction of anesthesia. The checklist addresses all relevant parameters and tasks such as the patient’s identity, the planned procedure, the site and special problems like allergies, risk of blood loss, etc.
- The “time out” phase is the last checkpoint prior to initiating the skin incision. At this moment, all team members are called upon to engage in a clearly structured dialogue. All team members introduce themselves by name and role, verbally confirm the patient’s name and the planned procedure, make themselves aware of the possible risks like blood loss, and ensure that an antibiotic prophylaxis has been given, if necessary.

- The “sign out” phase should be completed before the patient leaves the operating room. In this phase it is again important to verbally confirm the procedure, to make sure that all counts related to instruments, sponges and needles are correct and specimens are labeled. Furthermore, the most important management issues for the immediate postoperative period should also be reviewed.

### 2.2.8 Prevention and Management of Hypothermia

The human body has different homeostatic mechanisms that help to avoid hypothermia. During general anesthesia, these physiological circuits are partly inactivated. Hence, hypothermia is a general risk during surgery. It is defined as a temperature loss of 0.5°C in comparison to the baseline temperature measured in the awake person prior to starting surgery. Usually, the patient’s temperature decreases 1°C per hour during surgery,<sup>8</sup> and the decline may be even more rapid in combined general and epidural anesthesia.<sup>6</sup>

Temperature measurement can be carried out in the esophagus, the rectum and the bladder. In surgeries of the lower abdomen, a vesical measurement can be imprecise.

A review of 26 randomised controlled trials that was based on a total of 2,070 patients showed a higher risk of cardiac events, blood transfusions and wound infections in hypothermal patients.<sup>20</sup> In particular, the risk of wound infections after colorectal surgery, which can be necessary in patients treated for endometriosis, is significantly higher in those suffering from intraoperative hypothermia.<sup>10</sup> Apart from that, most patients usually feel uncomfortable when experiencing coldness upon waking up in the post anaesthesia recovery area.<sup>12</sup>

The possibilities of thermal management are multifaceted and have to be discussed with the anesthesiological department. It is always important to monitor and maintain body temperature from the very beginning of the procedure because rewarming the patient is an even more challenging task to fulfill. Possible prophylactic methods are a prewarming procedure before induction of anesthesia in the patient preparation area, the use of forced-air warmers and the use of warm infusions when patients need to get more volume than 1 L per hour. In addition, it is crucial to cover as much of the body surface as possible.

It could be demonstrated that the gaseous medium (dry and cold CO<sub>2</sub>) commonly used in laparoscopy causes hypothermia.<sup>2</sup> The peritoneum emits thermal energy to reach an equilibrium in temperature, which, in turn, induces a decline in body core temperature. As an alternative option, prewarmed and humidified gas can be used in laparoscopy. A meta-analysis of 10 randomised controlled trials with a total number of 565 patients showed a lower risk of hypothermia in those patients subjected to laparoscopy using an insufflator with preheated and humidified gas.<sup>19</sup> Additionally, this modality was found to be associated with reduced postoperative pain. In view of these conclusive benefits, it is well-advised to implement this auxiliary measure, especially in long surgeries.

### 2.2.9 Summary

It is well known that one key requisite for successful and good surgical outcome is adequate experience and circumspection on the part of the surgeon. However, good preoperative preparation of the patient and adherence to established principles of good clinical practice is just as instrumental in minimizing the risks and improving the quality of a surgical procedure. This last paragraph summarizes the most important issues that need to be considered prior to surgery.

Adherence to the preventive measures and principles described below can help to reduce perioperative morbidity.

- In order to meet the objectives of the informed consent process, the surgeon must discuss the most important facts and risks of the planned procedure with the patient, making sure that an adequate level of knowledge and comprehension has been achieved.
- Laboratory testing may be of secondary importance, except for a pregnancy test, that should be done before undertaking a surgical procedure on the genital tract.
- The necessity of preoperative bowel preparation needs to be scrutinized carefully.
- One of the most common complications associated with operative procedures is a surgical site infection, which is defined as an infection of the skin or the subcutaneous tissue of the incision occurring within 30 days post surgery. A perioperative antibiotic prophylaxis can help to prevent those infections. In most laparoscopic gynecological surgeries, a prophylaxis does not seem to be necessary, unless in the case of patients with additional risk factors.
- Pain management can be complemented by epidural anesthesia. Benefits for the patient have been demonstrated, particularly in terms of postoperative pain management.
- The use of a surgical safety checklist should be mandatory in every operating room in order to prevent potentially avoidable complications and flawed practice.
- Perioperative hypothermia is associated with a significant higher rate of complications. Therefore, targeted efforts should be made to maintain normothermia by choosing from the various prophylactic methods available today.

### 2.2.10 References

1. Arbeitskreis „Krankenhaus- und Praxishygiene“ der AWMF. Perioperative Antibiotikaprophylaxe: AWMF-Register Nr. 029/022 Klasse: S1++IDA; Available from: [http://www.awmf.org/uploads/tx\\_szleitlinien/029-022l\\_S1\\_Perioperative\\_Antibiotikaprophylaxe\\_2012-02.pdf](http://www.awmf.org/uploads/tx_szleitlinien/029-022l_S1_Perioperative_Antibiotikaprophylaxe_2012-02.pdf).
2. BINDA MM. Humidification during laparoscopic surgery: overview of the clinical benefits of using humidified gas during laparoscopic surgery. *Arch Gynecol Obstet* 2015;292(5):955–71. doi:10.1007/s00404-015-3717-y.
3. CENTERS FOR DISEASE CONTROL AND PREVENTION. The National Healthcare Safety Network. Surgical Site Infection (SSI) Event. Procedure-associated Module SSI; Available from: <http://www.cdc.gov/nhsn/PDFs/pscManual/9pscSSICurrent.pdf>.
4. EYK N VAN, SCHALKWYK J VAN. Antibiotic prophylaxis in gynaecologic procedures. *J Obstet Gynaecol Can* 2012;34(4):382–91.
5. FERGUSON SE, MALHOTRA T, SESHAN VE, LEVINE DA, SONODA Y, CHI DS et al. A prospective randomized trial comparing patient-controlled epidural analgesia to patient-controlled intravenous analgesia on postoperative pain control and recovery after major open gynecologic cancer surgery. *Gynecol Oncol* 2009;114(1):111–6. doi:10.1016/j.ygyno.2009.03.014.
6. FORSTOT RM. The etiology and management of inadvertent perioperative hypothermia. *J Clin Anesth* 1995;7(8):657–74.
7. HENSEL M, FRENZEL J, SPAKER M, KEIL E, REINHOLD N. Postoperative pain management after minimally invasive hysterectomy: thoracic epidural analgesia versus intravenous patient-controlled analgesia. *Anaesthesist* 2013;62(10):797–807. doi:10.1007/s00101-013-2234-2.
8. HORN E, TOROSSIAN A. Perioperative Hypothermie – Prophylaxe, Therapie und Physiologie. *Anästhesiol Intensivmed Notfallmed Schmerzther* 2010;45(03):160–7. doi:10.1055/s-0030-1249396.
9. KANTARTZIS KL, SHEPHERD JP. The use of mechanical bowel preparation in laparoscopic gynecologic surgery: a decision analysis. *Am J Obstet Gynecol* 2015;213(5):721.e1-5. doi:10.1016/j.ajog.2015.05.017.
10. KURZ A, SESSLER DI, LENHARDT R. Perioperative normothermia to reduce the incidence of surgical-wound infection and shorten hospitalization. Study of Wound Infection and Temperature Group. *N Engl J Med* 1996;334(19):1209–15. doi:10.1056/NEJM199605093341901.
11. LITTA P, SACCO G, TSIROGLOU D, COSMI E, CIAVATTINI A. Is antibiotic prophylaxis necessary in elective laparoscopic surgery for benign gynecologic conditions? *Gynecol Obstet Invest* 2010;69(2):136–9. doi:10.1159/000267322.
12. MACARIO A, WEINGER M, CARNEY S, KIM A. Which clinical anesthesia outcomes are important to avoid? The perspective of patients. *Anesth Analg* 1999;89(3):652–8.
13. MAHDI H, GOODRICH S, LOCKHART D, DEBERNARDO R, MOSLEMI-KEBRIA M. Predictors of surgical site infection in women undergoing hysterectomy for benign gynecologic disease: a multicenter analysis using the national surgical quality improvement program data. *J Minim Invasive Gynecol* 2014;21(5):901–9. doi:10.1016/j.jmig.2014.04.003.
14. MORRILL MY, SCHIMPF MO, ABED H, CARBERRY C, MARGULIES RU, WHITE AB et al. Antibiotic prophylaxis for selected gynecologic surgeries. *Int J Gynaecol Obstet* 2013;120(1):10–5. doi:10.1016/j.ijgo.2012.06.023.
15. MOSLEMI F, RASOOLI S, BAYBORDI A, GOLZARI SEJ. A Comparison of Patient Controlled Epidural Analgesia With Intravenous Patient Controlled Analgesia for Postoperative Pain Management After Major Gynecologic Oncologic Surgeries: A Randomized Controlled Clinical Trial. *Anesth Pain Med* 2015;5(5):e29540. doi:10.5812/aapm.29540.
16. NARR BJ, HANSEN TR, WARNER MA. Preoperative laboratory screening in healthy Mayo patients: cost-effective elimination of tests and unchanged outcomes. *Mayo Clin Proc* 1991;66(2):155–9.
17. REX DK. Optimal bowel preparation – a practical guide for clinicians. *Nat Rev Gastroenterol Hepatol* 2014;11(7):419–25. doi:10.1038/nrgastro.2014.35.
18. RYAN NA, NG VS, SANGI-HAGHPEYKAR H, GUAN X. Evaluating Mechanical Bowel Preparation Prior to Total Laparoscopic Hysterectomy. *JLS* 2015;19(3). doi:10.4293/JLS.2015.00035.
19. SAJID MS, MALLICK AS, RIMPEL J, BOKARI SA, CHEEK E, BAIG MK. Effect of heated and humidified carbon dioxide on patients after laparoscopic procedures: a meta-analysis. *Surg Laparosc Endosc Percutan Tech* 2008;18(6):539–46. doi:10.1097/SLE.0b013e3181886ff4.



20. SCOTT EM, BUCKLAND R. A systematic review of intraoperative warming to prevent postoperative complications. *AORN J* 2006;83(5):1090-104, 1107-13.
21. SHARARA AI, EL-HALABI MM, ABOU FADEL CG, SARKIS FS. Sugar-free menthol candy drops improve the palatability and bowel cleansing effect of polyethylene glycol electrolyte solution. *Gastrointest Endosc* 2013;78(6):886-91. doi:10.1016/j.gie.2013.05.015.
22. SHI W, MIAO Y, YAKOUB MY, CAO J, ZHANG H, JIANG Y et al. Recovery of gastrointestinal function with thoracic epidural vs. systemic analgesia following gastrointestinal surgery. *Acta Anaesthesiol Scand* 2014;58(8):923-32. doi:10.1111/aas.12375.
23. SIEDHOFF MT, CLARK LH, HOBBS KA, FINDLEY AD, MOULDER JK, GARRETT JM. Mechanical bowel preparation before laparoscopic hysterectomy: a randomized controlled trial. *Obstet Gynecol* 2014;123(3):562-7. doi:10.1097/AOG.000000000000121.
24. WACHA H, HOYME U, ISENMANN R, KUJATH P, LEBERT C, NABER K et al. Perioperative Antibiotika-Prophylaxe: Empfehlungen einer Expertenkommission der Paul-Ehrlich-Gesellschaft für Chemotherapie e. V. *Chemotherapie Journal* 2010;19(3).
25. WON H, MALEY P, SALIM S, RAO A, CAMPBELL NT, ABBOTT JA. Surgical and patient outcomes using mechanical bowel preparation before laparoscopic gynecologic surgery: a randomized controlled trial. *Obstet Gynecol* 2013;121(3):538-46. doi:10.1097/AOG.0b013e318282ed92.
26. World Alliance for Patient Safety. WHO Surgical Safety Checklist and Implementation Manual. [23, February 2016]; Available from: [http://www.who.int/patientsafety/safesurgery/ss\\_checklist/en/](http://www.who.int/patientsafety/safesurgery/ss_checklist/en/).

## 2.3

## Surgical Instruments, Powered Devices and Videoendoscopic Equipment

Ibrahim Alkatout<sup>a</sup>

## 2.3.1 Introduction

Minimally invasive surgery has been the subject of a consistent and dynamic evolution that is driven by continuous scientific and technological advancements. The minimally invasive approach has transformed surgery altogether<sup>18</sup> and

the benefits that can be drawn from it – compared to those afforded by open surgery as well as transvaginal surgical approaches – are well known and widely accepted in our specialty (Tables 2.4a–c).<sup>1,5,19</sup>

Vaginal approach versus abdominal approach	
<p><b>Advantages</b></p> <ul style="list-style-type: none"> <li>■ Shorter hospital stay (on average 1 day, 95% CI 0.7–1.2).</li> <li>■ Earlier return to activities of daily living (mean difference, 9.5 days, 95% CI 6.4–12.6).</li> <li>■ Lower infection rate, lower rate of postoperative fever episodes (OR 0.42, 95% CI 0.21–0.83).</li> <li>■ Lower complication rate, such as hernia formation or impaired wound healing.</li> <li>■ Optional use of regional anesthesia.</li> <li>■ Superior outcome in terms of cosmesis.</li> </ul>	<p><b>Disadvantages</b></p> <ul style="list-style-type: none"> <li>■ Treatment of comorbidities is not feasible in the same session.</li> <li>■ The operation is technically more demanding because of the confined space available for maneuvering instruments and scope.</li> </ul>

**Table 2.4a** Advantages/disadvantages of vaginal approach versus abdominal approach.

Laparoscopic approach versus abdominal approach	
<p><b>Advantages</b></p> <ul style="list-style-type: none"> <li>■ Lower blood loss (mean difference 45.3 ml, 95% CI 17.9–72.7).</li> <li>■ Shorter hospital stay (on average 2 days, 95% CI 1.9–2.2).</li> <li>■ Earlier return to activities of daily living (mean difference 13.6 days, 95% CI 11.8–15.4).</li> <li>■ Lower infection rate, lower rate of postoperative fever episodes (OR 0.32, 95% CI 0.12–0.85).</li> <li>■ Lower complication rate, such as hernia formation or impaired wound healing.</li> <li>■ Reduced rate of adhesion formation.</li> <li>■ Superior outcome in terms of cosmesis.</li> <li>■ Enhanced and enlarged videoendoscopic view owing to freely adjustable distance from the scope tip to the operative site.</li> <li>■ Videoendoscopic view of the operative site available to all members of the surgical team throughout the entire surgical procedure.</li> <li>■ Fine-tuned surgery due to the availability of innovative articulating multipurpose instruments and versatile scopes.</li> </ul>	<p><b>Disadvantages</b></p> <ul style="list-style-type: none"> <li>■ Longer operating time (mean difference 10.6 minutes, 95% CI 7.4–13.8).</li> <li>■ Prolonged learning curve; level of complexity, inherent to each operative step is higher.</li> <li>■ Higher rate of complications, such as ureteral lesions, bowel lesions, or vascular lesions (OR 2.61, 95% CI 1.22–5.60).</li> <li>■ Limited tactile feedback.</li> <li>■ Three-dimensional imaging feasible only in rare cases.</li> <li>■ Higher costs.</li> </ul>

**Table 2.4b** Advantages/disadvantages of laparoscopic approach versus abdominal approach.

<sup>a</sup> | Associate Professor, PhD, MA; Department of Obstetrics and Gynecology, Head of the Kiel School of Gynecological Endoscopy, University Hospitals of Schleswig-Holstein, Kiel Campus Kiel, Germany

## Corresponding author:

## Ibrahim Alkatout

Priv.-Doz. Dr. med., Oberarzt, Klinik für Gynäkologie und Geburtshilfe, Leiter der Kiel School of Gynaecological Endoscopy, Universitätsklinikum Schleswig-Holstein, Campus Kiel, Klinik für Gynäkologie und Geburtshilfe

Arnold-Heller-Strasse 3/Haus 24

24105 Kiel, Germany

E-mail: ibrahim.alkatout@uksh.de

kiel.school@uksh.de

Laparoscopic approach versus vaginal approach	
<p><b>Advantages</b></p> <ul style="list-style-type: none"> <li>■ Less blood loss (mean difference 45.3 ml, 95 % CI 17.9–72.7).</li> <li>■ Organs and/or structures affected by comorbidities can be operated on in the same session.</li> <li>■ Lower infection rate, lower rate of fever episodes (OR 0.32, 95 % CI 0.12–0.85).</li> <li>■ Reduced rate of adhesion formation.</li> <li>■ Enhanced and enlarged videoendoscopic view owing to freely adjustable distance from the scope tip to the operative site.</li> <li>■ Videoendoscopic view of the operative site available to all members of the surgical team throughout the entire surgical procedure.</li> <li>■ Fine-tuned surgery due to the availability of innovative articulating multipurpose instruments and versatile scopes.</li> <li>■ Intraoperative decision-making is less dependent on the accuracy of the preoperative diagnostic work-up.</li> </ul>	<p><b>Disadvantages</b></p> <ul style="list-style-type: none"> <li>■ Longer operating time (mean difference 41.5 min, 95 % CI 33.7–49.4).</li> <li>■ Prolonged learning curve; level of complexity inherent to each operative step is higher.</li> <li>■ Limited tactile feedback.</li> <li>■ Three-dimensional imaging feasible only in rare cases.</li> <li>■ Worse cosmetic outcome.</li> <li>■ Higher costs.</li> </ul>

**Table 2.4c** Advantages/disadvantages of laparoscopic approach versus vaginal approach.

Recent decades have witnessed a wide range of technological innovations. Major achievements have been made in the miniaturization of instruments and have significantly contributed to the minimal invasiveness of most surgical approaches used in clinical practice.<sup>20</sup> Taking into account the outstanding improvements made in terms of image definition and data processing/transmission rates, and considering the successful introduction of 3D laparoscopic imaging in clinical practice, surgeons are now enabled to perform highly delicate operative procedures with greatest accuracy while reducing blood loss to a minimum. A key feature of state-of-the-art video camera systems is the possibility to take a close-up view of areas of interest, which for instance, may be necessary to scrutinize focal patterns of highly vascularized tissue layers. Provided the surgeon has reached a good level of proficiency and strictly adheres to established principles of best clinical practice, complications such as postoperative pain, infection, or the formation of adhesions can be reduced to a minimum. Finally, a new generation of sealing instruments – based on ultrasonic energy or bipolar high frequency – mainly employed in the form of disposable items, has proven to be very useful in coagulating and cutting tissues and vessels.

Technical advancements, especially those made in recent decades, spurred the development of miniaturized instruments and have largely contributed to reducing the surgical trauma for the patient.<sup>20</sup> The advent of high-definition digital imaging and 3D technology in laparoscopy made it possible to perform highly delicate surgical procedures with greatest accuracy while reducing blood loss to a minimum.<sup>1</sup> The optional use of a magnified view on the screen is of particular benefit to the surgeon in that it affords a targeted inspection of areas of interest, e.g., strongly vascularized tissue, and allows for enhanced differentiation between the various tissue layers. Complications such as postoperative pain, infection, or the formation of adhesions have been reduced to a minimum.

Adequate hemostasis is paramount to the safety of laparoscopic procedures and provides for a clear and unimpeded view of the operative field, enabling vital structures such as blood vessels, ureter or bowel, to be identified, thus preserving their integrity. There is a large variety of laparoscopic instruments to choose from for this purpose. These instruments can be used to carefully dissect

tissue and expose specific anatomical structures in order to trace vessels, that may then be coagulated and transected selectively and safely.<sup>30</sup> In the event of intraoperative bleeding during laparoscopy, dedicated multipurpose instruments are used to achieve safe and efficient hemostasis and thus prevent the need for conversion to open surgery.<sup>4</sup> Technical advancements have led to the availability of sophisticated sealing instruments which – by the aid of ultrasound and/or bipolar current – can be used to perform both coagulation and transection. Upon their inception, these instruments were available only as disposable items. The decision-making on the acquisition and use of sealing instruments is a rather complex issue, not only from an economic but also from a medical point of view. Apart from the fact, that coagulation can be performed more safely, another advantage derived from the use of these versatile tools is that they eliminate the need for repeated instrument changes.

The trend toward dedicated hysteroscopic instruments has essentially followed two main directions which are aimed at reducing complications on the one hand, and continued miniaturization, on the other hand. The potential risk of the dreaded condition of hypotonic hyperhydration (known as ‘TUR syndrome’ from endo-urology) can be largely prevented by the use of bipolar electrosurgical systems and physiological saline instead of electrolyte-free solutions.

### 2.3.2 Laparoscopy

Laparoscopic procedures are commonly performed through one or more small incisions and require the prior creation of a pneumoperitoneum established either through an incision-free access (Veress needle, entry under direct viewing) or an open access (Hasson technique). Once the pneumoperitoneum has been created, a single or multiple ports are placed. The laparoscope – coupled to a video camera – and the working instruments are introduced through the various ports.

The classical method of entry is described in the following paragraphs.



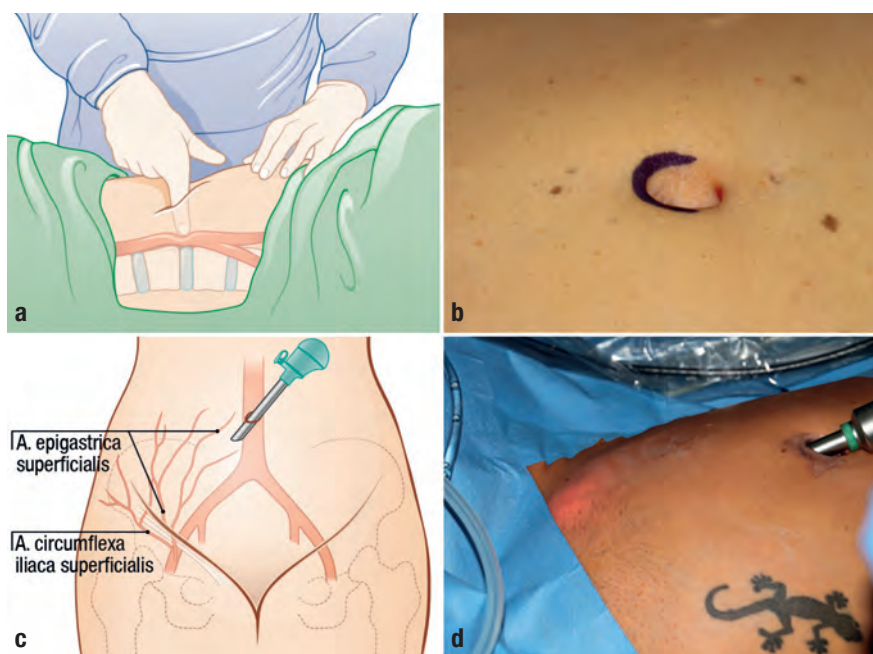
### 2.3.2.1 Veress Needle Technique

The operating table is placed in a horizontal position before introducing the Veress needle. Once the pneumoperitoneum has been established, the table is adjusted to Trendelenburg position. Most commonly, the Veress needle is introduced in the umbilical region because the layers of the abdominal wall are thinnest at this site. Prior to making the skin incision, the course of the aorta and the site of the iliac bifurcation is palpable in slim persons (Fig. 2.6).<sup>32</sup>

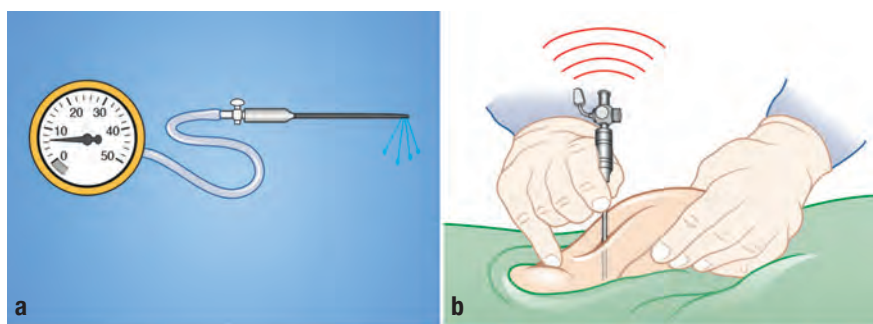
Once a test has confirmed proper function, the Veress needle is introduced at an angle of 45° to the abdominal wall and

directed toward the uterus. In this way, the risk of iatrogenic injury to large vessels or the intestines is minimized. While inserting the needle, the skin of the abdominal wall is slightly elevated (Fig. 2.7). The more obese a patient is at this site, the steeper the angle of entry should be. In patients without a history of prior surgery, the surgeon may need to make two attempts before opting for an alternative entry technique or introducing the needle at a different entry point.

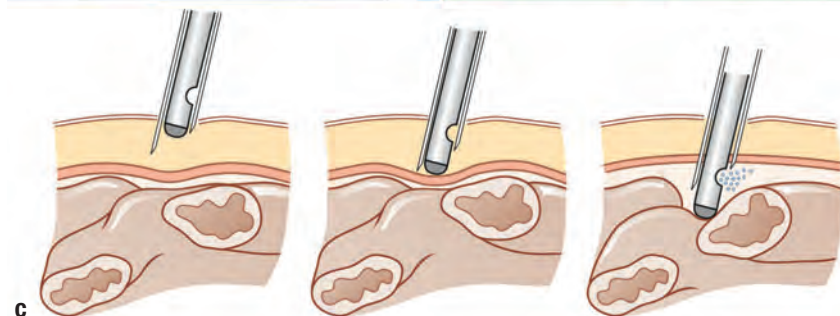
When introducing the Veress needle, as a rule, two audible 'snaps' can be heard. The first one occurs after perforating the muscle fascia and the second after perforating the peritoneum.



**Fig. 2.6** Typical point of palpation in the subumbilical region (a). The finger tip is pointing to the aorta and the promontory. Subumbilical incision (skin marking, b) and local palpation reveal the short distance from the skin to the spine. The anticipated insertion points of ancillary trocars are determined by use of transillumination (d) demarcating the superficial epigastric artery and the superficial circumflex iliac artery.



**Fig. 2.7** Veress needle and its insertion. Proper function of the Veress needle must be checked in advance to make sure that the spring-action of the safety mechanism is fully operational, and that gas flow is between 6 and 8 mmHg (a). As a rule, two audible 'snaps' can be heard while passing the needle through the abdominal wall (b). The safety mechanism avoids damage or injury to the bowel or vessels (c).



### ■ Aspiration Test

Following insertion of the Veress needle, 5 ml of saline solution are injected and – given proper placement of the needle – aspiration of saline should *not* be feasible. In case of incorrect insertion of the needle, a blood vessel or bowel may be punctured, which in turn should result in aspiration of the related body fluid in the barrel of the syringe.


### ■ Hanging Drop Test and ‘Fluid Inflow’

Once the needle has been introduced, the abdominal wall is elevated (Fig. 2.7b), thereby causing a negative intraabdominal pressure. When placing a drop of water on the open Luer connector, the vacuum will cause the drop to disappear down the shaft of the Veress needle. The needle should not be moved after it has been introduced in the abdomen. If the needle has been inserted incorrectly, the small intraabdominal defect may propagate and result in a complex and hazardous lesion (which is why any torque from the abdominal wall must be avoided!).

### 2.3.2.2 Alternative Options of Laparoscopic Entry

To date, a variety of approaches have been proposed for creating a pneumoperitoneum, which may also be achieved directly by using a dedicated trocar. The first description of this entry technique was provided by *Artin Ternamian*,<sup>28</sup> who designed a trocar cannula with an atraumatic outer thread that allows to enter the abdomen under direct vision before or after creation of the pneumoperitoneum (Fig. 2.8). As an alternative option, the pneumoperitoneum can be established – without prior use of a Veress needle – by insufflating CO<sub>2</sub> gas through the first trocar inserted directly/bluntly into the abdomen under direct vision. Accordingly, the pneumoperitoneum can be set up much faster with fewer instruments, while obviating the need for going through multiple precautionary steps (Fig. 2.9).

Insufflation may then be started by adjusting the flow rate of CO<sub>2</sub> gas to 1 liter per minute, which is then increased to 3–5 liters per minute. The total volume of insufflated CO<sub>2</sub> gas is determined by the patient’s height and degree of relaxation. Even after insufflation of 300 ml of CO<sub>2</sub> gas distributed uniformly in the intraabdominal aspect, a physiological damping of liver percussion is noticeable. The initial target value of intra-abdominal pressure can be set to 20–25 mmHg in order to achieve a maximum distance between the abdominal wall and intraabdominal structures.<sup>25</sup>

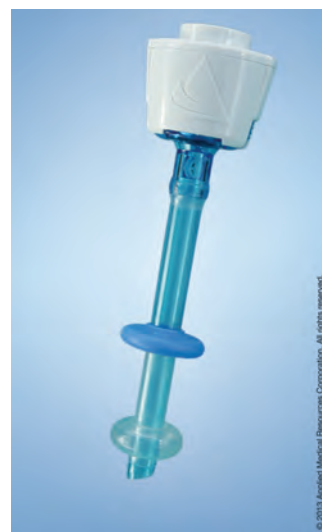

**Fig. 2.8** Direct trocar insertion is possible with the TERNAMIAN EndoTip cannula (KARL STORZ Tuttlingen, Germany).

First, a 5-mm optical trocar may be introduced, if the size of the trocar offers adequate vision for the anticipated procedure. As an alternative option, a 10-mm optical trocar may be introduced. The trocar must be introduced using the so-called ‘Z-technique’ which involves that a twisting motion is used while deflecting the trocar sideways subcutaneously by a few millimeters in order to achieve functional closure of the fascia and prevent hernia formation in the postoperative period. However, a maximum level of safety is maintained when using a stepwise approach. *Step 1* involves the introduction of a 5-mm optical trocar and is intended to avoid iatrogenic injury or formation of adhesions secondary to surgery. Prior to initiating dilatation to 10 mm, insufflation of CO<sub>2</sub> gas is continued safely through the 5-mm trocar already in place. *Step 2* involves the insertion of a place holder that is passed through the 5-mm trocar, followed by introduction of the 10-mm trocar.<sup>25</sup>

### 2.3.2.3 Subcostal Insufflation Technique (Palmer’s Point or Lee Huang Point)

None of the entry techniques applied so far is entirely devoid of the risk of gas embolism, injury to vessels, the urinary tract, or the bowel. However, entry through Palmer’s point provides maximum safety, especially in cases where the presence of umbilical pathologies is anticipated. In 1974, *Raul Palmer* described an alternative entry point in the midclavicular line, about 3 cm below the costal arch.<sup>22</sup> In rare instances, when the patient presents with a history of previous surgery in the left subcostal region, the Lee Huang point, located in the midline below the xiphoid, may be used. However, when introducing the trocar, it should always be borne in mind that the falciform ligament – on account of its intraabdominal location – may directly get in the way. As a routine precaution, it is imperative that gastric suction be performed before introducing the Veress needle or the trocar (Fig. 2.10, see overleaf).<sup>25</sup>



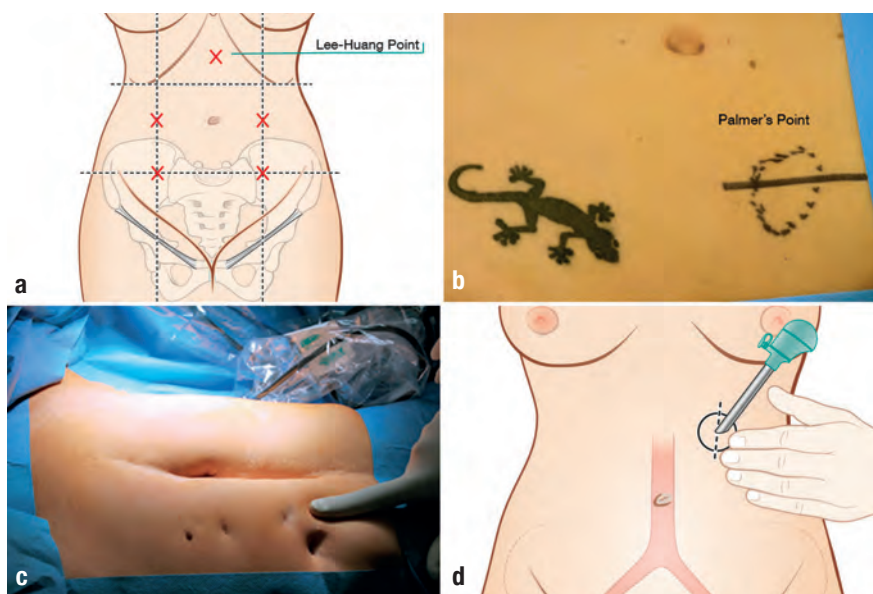
**Fig. 2.9** Kji® Advanced Fixation Sleeve (*Applied Medical Resources Corp.*, Rancho Santa Margarita, CA, USA). Offers unsurpassed abdominal wall fixation with minimal depth into the peritoneal cavity. The non-latex, non-fragmenting balloon provides superior abdominal wall retention compared to other sleeves and ensures minimum penetration of the trocar into the operative field. The retention disk slides down to maintain the sleeve position in the abdomen, securing the trocar in place and virtually eliminating unintentional displacement or forward migration.

2.3.2.4 Introduction of Working Trocars

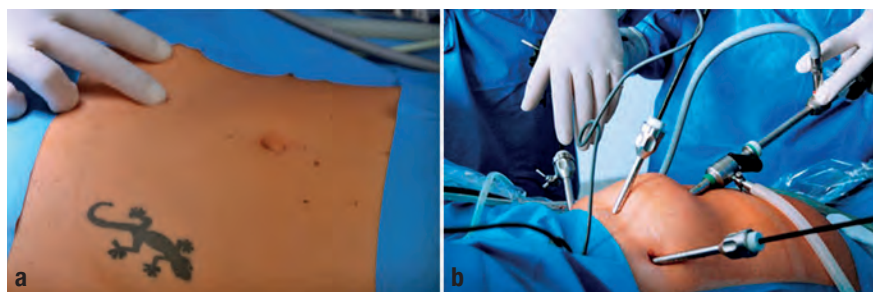
The patient is moved to Trendelenburg position before introducing the working trocars. All working trocars should be placed only after intraabdominal pressure has reached the predefined maximum level, and after it has been ascertained that absolutely clear vision is maintained. The inferior epigastric artery is visualized from inside the abdomen in the lateral umbilical plica. The region lateral to this point must be scrutinized for superficial arteries (the superficial iliac circumflex artery and the superficial epigastric artery) by use of diaphanoscopy. Viewed from the outside, the area of interest is located approximately two finger breadths medial to the anterosuperior aspect of the iliac spine (Fig. 2.11a). Once

the working trocar has been passed through the peritoneum, it is swung around and directed toward the uterus, thus moving away from large vessels and bowel.

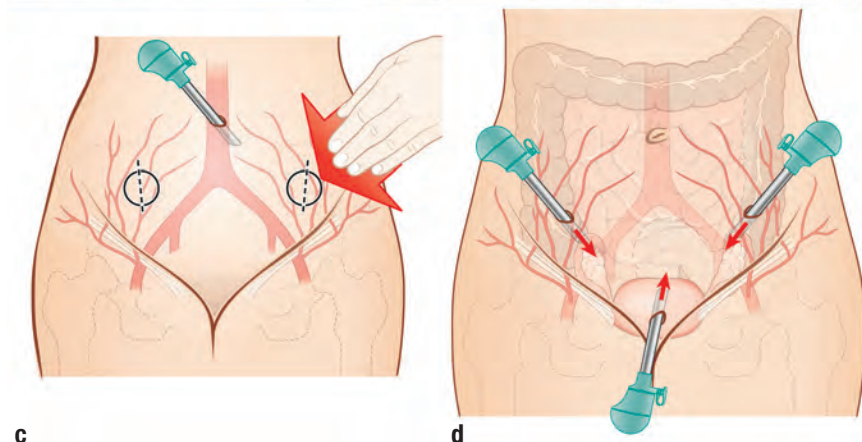
The number of working trocars is variable. The same applies to the preferred trocar positions. The selected configuration may result in symmetrical trocar positions on the left and right side, or in an asymmetrical arrangement, with left and midline positions, or with left and left mid-abdominal positions (Figs. 2.11–2.13).<sup>3,25</sup> For this purpose, the surgeon may choose between a large variety of trocars available as single-use or reusable items.



**Fig. 2.10** The Lee-Huang point (a) is an alternative entry site located at or above the level of the umbilicus (in cases of a large uterus). The use of this entry site is recommended for video-assisted laparoscopy or in cases suggestive of adhesions in the region of Palmer's point (c). Palmer's point is situated in the midclavicular line, about 3 cm below the costal margin (d).

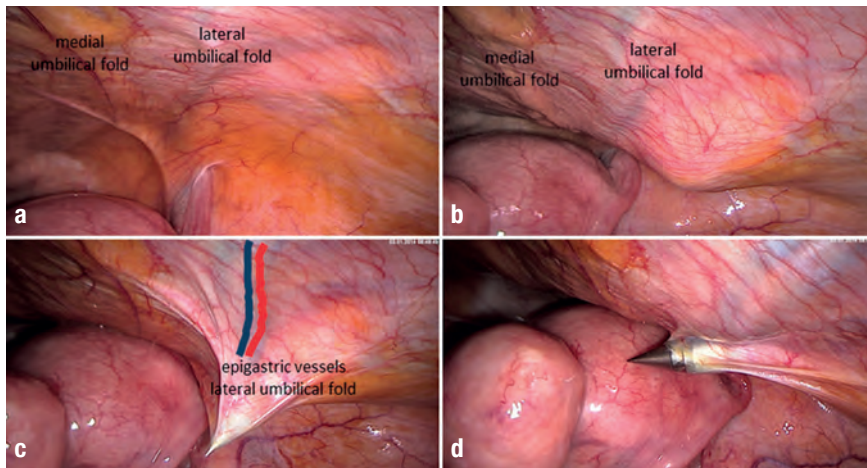


**Fig. 2.11** Point of insertion viewed from the outside (two finger breadths medial to the anterior superior spine) (a). The trocar is inserted perpendicular to the skin surface, with penetration of all layers of the abdominal wall. Trocar insertion site lateral to the lateral umbilical fold (c). Overview after insertion of the laparoscope and 3 ancillary trocars (d).

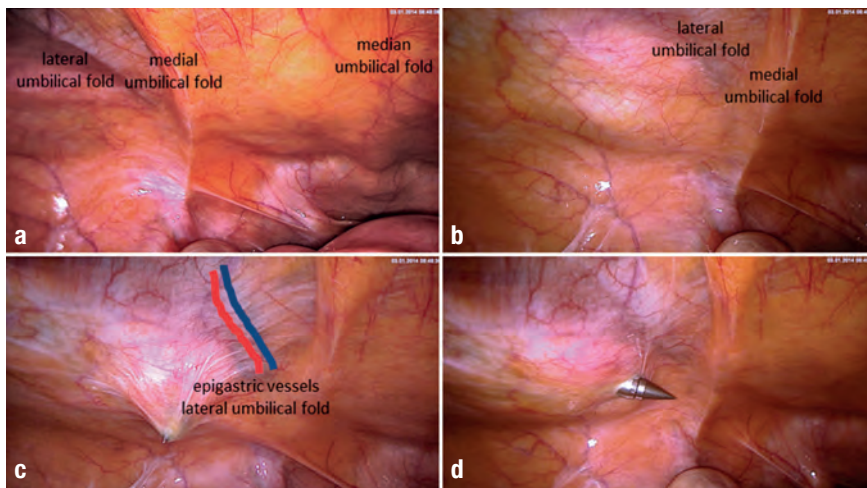


**c** **d**





**Fig. 2.12** Laparoscopic view of secondary trocar placement. Entry in the *right* lower abdomen. The three different plicae are visualized (a). The palpating finger marks the area lateral to the lateral umbilical fold (b). The sharp ancillary trocar enters the lateral aspect of the lateral umbilical fold (c). Once the trocar has been passed through the peritoneum, it is directed to the uterine fundus to avoid injury to major vessels and bowel (d).



**Fig. 2.13** Laparoscopic view of secondary trocar placement. Entry in the *left* lower abdomen. The three different plicae are visualized (b). The palpating finger marks the area lateral to the lateral umbilical fold (b). The sharp ancillary trocar enters the lateral aspect of the lateral umbilical fold (c). Once the trocar has been passed through the peritoneum, it is directed to the uterine fundus to avoid injury to major vessels and bowel (d).

### 2.3.2.5 Practical Handling of Instruments

During laparoscopic surgery, particularly in complex cases, surgeons are often faced with circumstances that constitute a limiting factor in the set-up of the operating field and in the choice and handling of instruments and scope. Altogether, this can pose a challenge even to experts, especially in the presence of profuse intraoperative bleeding or complications arising from specific conditions such as extreme obesity, a limited head-down tilt position, comorbidities, or adhesions. Unlike in open surgery, a laparoscopic surgeon must cope with loss of depth perception on account of the two-dimensional view provided by the current generation of standard laparoscopes. Another inherent drawback of most standard scopes is that they usually come with a fixed angle of vision offering only a limited intra-abdominal field of vision. As a result, some instruments – while being withdrawn from the operative site – may escape the surgeon's visual control which may entail inadvertent effects or cause iatrogenic damage to healthy tissue, while going unnoticed. Occult bleeding or injury to organs occurring outside the field of vision may also escape the attention of the operating surgeon. In contrast to open surgery procedures, most laparoscopic instruments have a range of motion that is greatly limited. The missing degrees of freedom (four versus seven) and the fixed fulcrum at the entry site of the trocar on the abdominal wall account for a limited

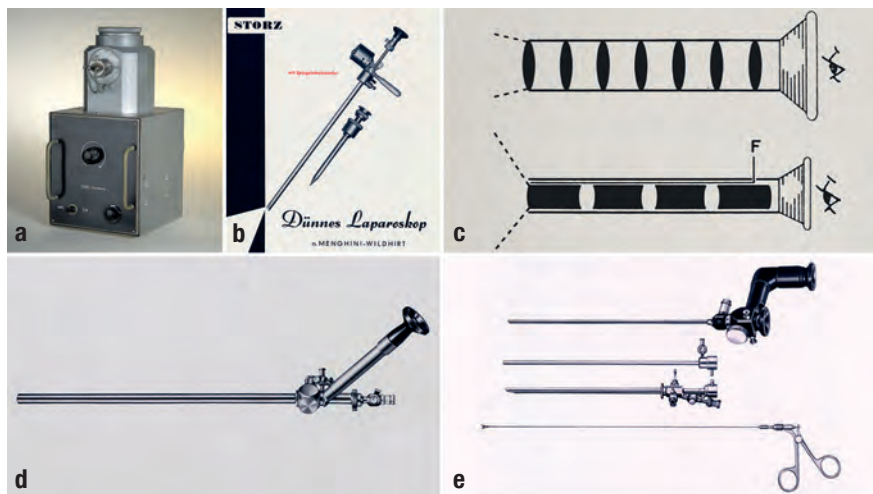
view of the operative field and can lead to situations where specific organ structures cannot be viewed at all because they are hidden in a blind spot. Additional difficulties may arise from circumstances where multiple laparoscopic instruments are used concurrently whereby they can get in the way of each other ('clashing'). Another limiting factor is the fact that trocar placement is largely determined by the patient's individual anatomy.

The quality of the video image of the operative field can be impaired by stains or debris on the distal lens of the scope which may result from contact with blood, secretion of body fluids, or from condensation of vapor or fog precipitating on the lens surface during coagulation. This can trigger the need to open the trocar valves repeatedly for ventilation, which can cause fluctuations in intraabdominal pressure and in the temperature of CO<sub>2</sub> gas. The spectral range of the light emitted by the cold light source may also contribute to poor visibility in cases of profuse hemorrhage. Another distinguishing feature of laparoscopy is that surgeons, particularly when going through initial stages of the learning curve, must get used to counter-intuitive paradoxical hand movements, such as *left is right*, *right is left*, *below is above*, *above is below*, *inward is inward*, whereas, *outward is outward*, *clockwise is clockwise*, and *anticlockwise is anticlockwise*.

### 2.3.3 Hysteroscopy

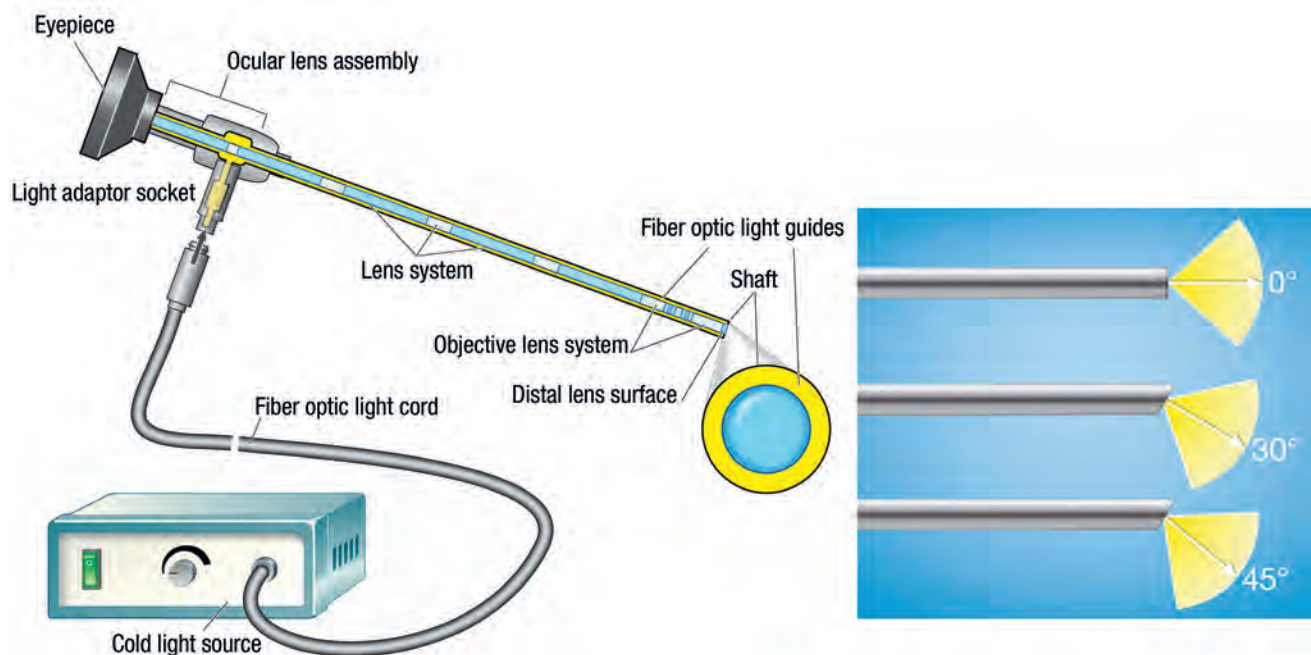
In a hysteroscopic approach, the entry technique is limited by the type of setting (diagnostic or operative hysteroscopy) and dilatation of the cervical canal. This is traditionally achieved by probing and dilating the cervical canal to Hegar number 8 for diagnostic hysteroscopy and Hegar number 9 for operative hysteroscopy. Preparation of the cervix with misoprostol (400 µg administered no later than 12 hours preoperatively) reduces the risk of injury (avulsion injury caused by forceps, perforation, bleeding).

The hysteroscope is commonly composed of an outer sheath and an inner sheath, the latter being used for insertion of the scope. The complex design of hysteroscopes – that provides for light/image transmission, in- and outflow of distension medium and channels for operating instruments – has been developed and perfected over many years. However, the indication range for hysteroscopic treatment of endometriosis is limited to rare cases such as diagnostic evaluation and/or surgical treatment performed in the same session, including chromopertubation.



**Fig. 2.14** A timeline of major landmarks in the history of endoscopic gynecology. 1960: Invention of the cold light source (a). 1962: WILDHIRT-MENGHINI slender scope marking the advent of laparoscopy (b). 1965: Introduction of the HOPKINS® rod lens system (c). 1973: The advent of endoscopy in diagnostic and operative gynecology (d). 1980: Inception of the HAMOU® Micro Contact Hysteroscope with just 5 mm in diameter (e).

By courtesy of KARL STORZ Tuttlingen, Germany.



**Fig. 2.15** Light adaptor socket – the socket where the fiberoptic light cord is attached to the scope.

*Fiber optic light guides* – glass fibers transmitting light from the adapter socket to the distal tip of the scope.

*Objective lens system* – a collection of lenses, apertures, and/or prisms located at the distal tip of the scope. In standard scopes, the fixed direction of view of the objective lens ranges from 0° to 120° allowing the endoscopist to see areas that might otherwise be out of view. The schematic drawing on the right shows 0°, 30° and 45° directions of view, commonly used in clinical practice.

*Lens system* – a series of rod-shaped glass lenses and optical spacers, which altogether provide for image acquisition and transmission through the shaft of the scope.

*Shaft* – stainless steel tube that houses the lens system.

*Ocular lens assembly* – the focusing lens located near the proximal part of the scope.

*Eyepiece* – the ocular at the proximal part of the scope. The image may either be viewed with the naked eye, or the eyepiece can be coupled to a camera adapter to view the image on a video screen.

### 2.3.4 Endoscopic Imaging

Even though minimally invasive surgery is a rather modern achievement, its origins date back more than 100 years when, in 1901, *Kelling* was the first to use a rigid endoscope for inspecting the intraabdominal organs in a dog.<sup>16</sup> Subsequent advancements were mainly hampered by lack of adequate light sources. A multitude of revolutionary scientific discoveries and technological advancements occurring virtually in parallel, along with substantial innovations generated by the industry, account for the great success story of minimally invasive surgery (Fig. 2.14).<sup>24,26,27</sup>

#### 2.3.4.1 Endoscope

For the most part, laparoscopes have a rigid design. They are used for the dual purpose of illuminating the abdominal cavity and transmitting the captured images to optical sensors of the video camera from where the resulting output signals are conveyed to a video screen and/or a recording device. In special cases, the laparoscope itself can be used for blunt operative manipulations. Conventional laparoscopes are available with a lens system offering a fixed angle of view, most commonly of 0°, 30° or 45° (Fig. 2.15). Among the technological innovations that have recently emerged in the field of rigid medical scopes are those equipped with a continuously adjustable angle of view (e.g., *ENDOCAMELEON*<sup>®</sup>, KARL STORZ Tuttlingen, Germany) (Fig. 2.16). Another area where headway has been made recently is that of stereoscopic laparoscopy which allows three-dimensional images to be viewed on the video screen. The decision as to which type of

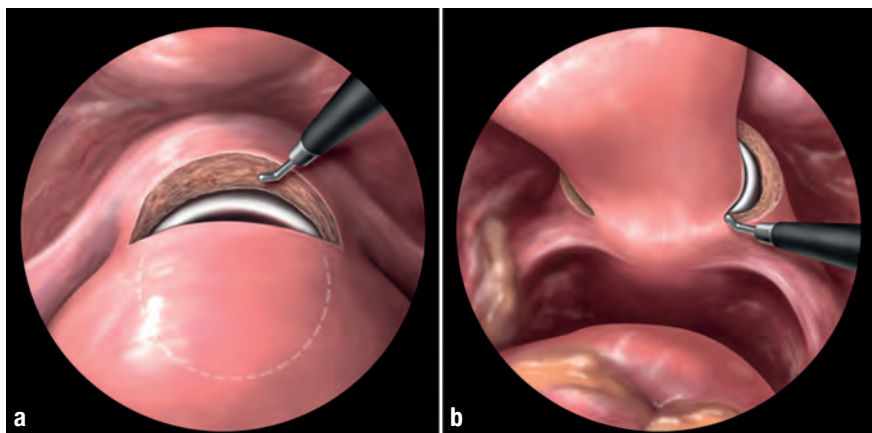


**Fig. 2.16** The *ENDOCAMELEON*<sup>®</sup> (KARL STORZ Tuttlingen, Germany) is a versatile laparoscope that allows the surgeon to adjust viewing directions from 0 to 120° as determined by operative circumstances and individual preferences of the surgeon. The core component of its unique design is a swing prism (insert image) at the distal tip of the scope. While image orientation is maintained as in any rigid standard scope, the direction of view is selected by simply turning a rotating wheel until the desired angle is indicated on the dial.

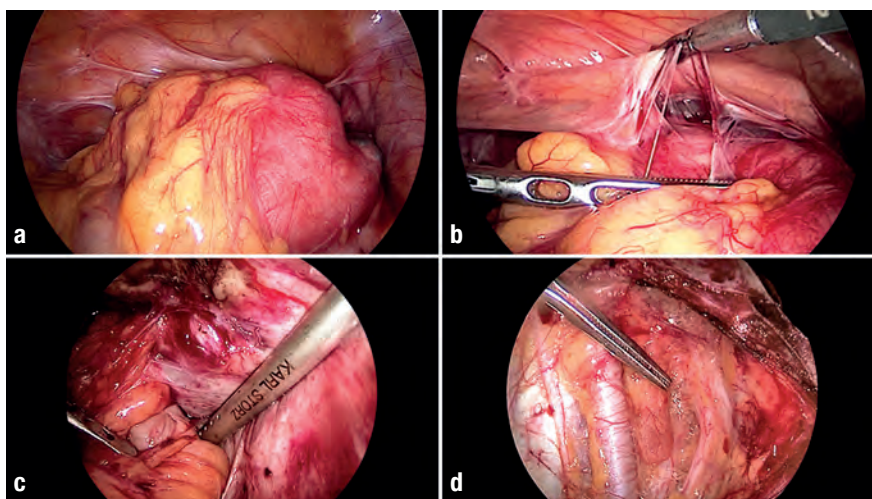


laparoscope suits best for the intended operative procedure depends on surgeon's preferences and local availability. The large majority of laparoscopic procedures in gynecology can be performed with a 0° scope. In specific situations, such as removal of the uterus in laparoscopic hysterectomy or in the surgical treatment of DIE, where exposure and dissection of

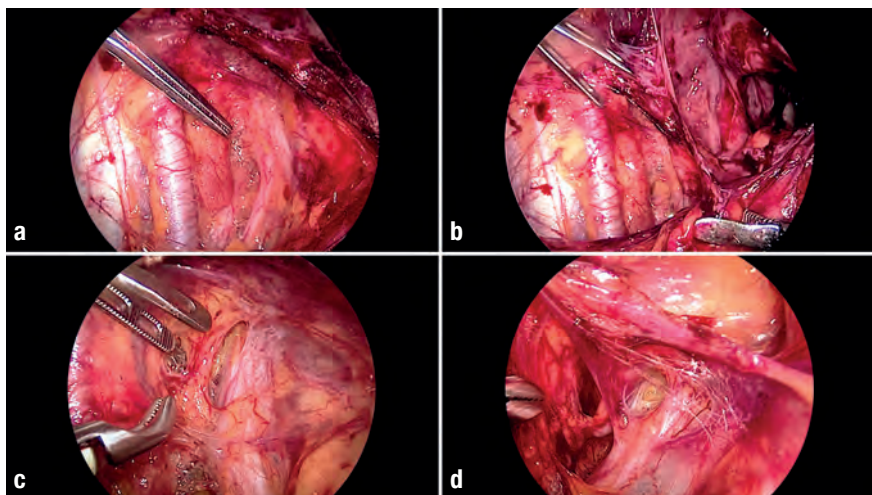
endometriotic lesions is carried deeply into the pelvic wall, the use of a 30°-scope is more appropriate in that it permits a targeted inspection of specific areas of interest which otherwise would be partly visible only or would escape the field of vision if a 0°-scope was used (Figs. 2.17–2.22).



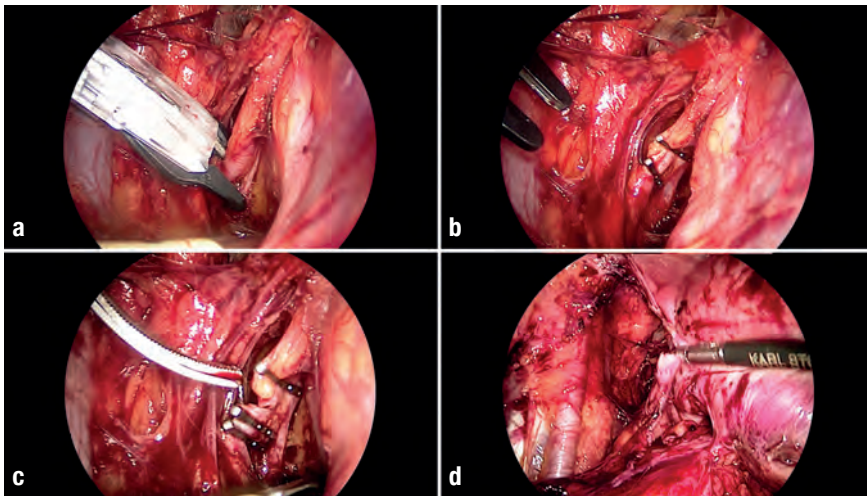
**Fig. 2.17** Schematic illustration of uterine dissection. Colpotomy is usually started in the anterior part, on the palpable cap of the uterine manipulator (a). Intrafascial hysterectomy can be completed with the sacrouterine ligaments in view (b).



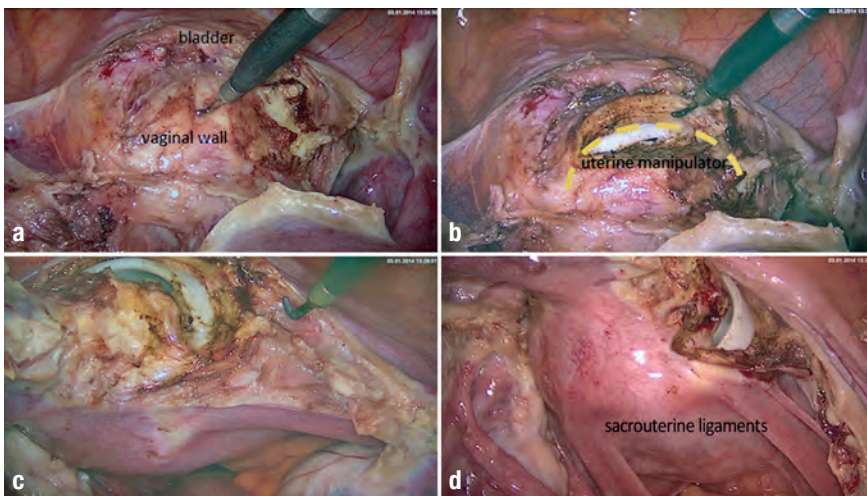
**Fig. 2.18** A patient suffering from severe adenomyosis of the uterus with concomitant adhesions of the bowel (a) and the bladder (b) peritoneum. Access to the lateral aspect of the uterus is obscured (c) making it necessary to adopt a retroperitoneal approach (d).



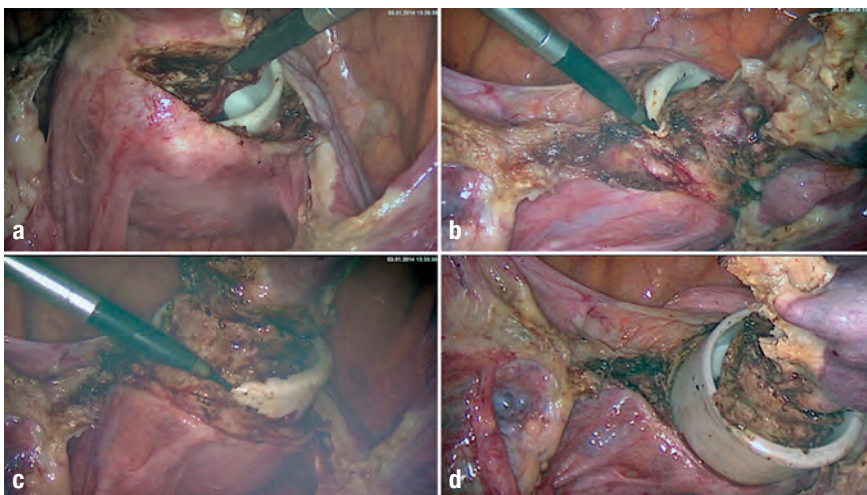
**Fig. 2.19** After localization of the external iliac artery, the ureter is usually found adherent to the peritoneum. A major lymph node lies in between. Access to the pararectal (b) and paravesical (c) fossa is obtained. The crossing point of the uterine artery and the ureter is demarcated, and the ureter is left in its adventitia to avoid skeletonization and denudation (d).



**Fig. 2.20** Ligation clips may be inserted (**a, b**) and the artery is closed and cut (**c**). The uterine (deep) vein is seen just beneath the artery that was cut (**c**). Overview of the exposed situs (**d**). After closure of the arteries, blanching of the uterus is noticeable on the right side (**d**).



**Fig. 2.21** In this case of laparoscopic total hysterectomy (LTH), the distance between vagina and bladder is increased following exposure of the bladder peritoneum (**a**). The intrauterine manipulator is firmly placed in the abdomen and dissection of the uterus from the vagina is performed in a stepwise manner (**b–d**). The conjunction of the sacrouterine ligaments is left in place.



**Fig. 2.22** Dissection of the vagina from the cervix has been completed (**a–d**). Retraction of the uterine cervix, which is grasped transvaginally by the manipulator forceps, has only just begun (**b**). Excessive fogging of the distal lens resulting from the use of a monopolar hook electrode makes it necessary to pause for a moment until vision is clear enough to proceed with accurate exposure. This can be done during simultaneous retraction/manipulation under laparoscopic vision using the 30° scope. The surgeon's view of the operative site may worsen abruptly when CO<sub>2</sub> gas leaks through the colpotomy. As a result of poor visibility, in such instance, application of monopolar energy is a hazardous maneuver that must be avoided at all costs.



### ■ Core Components of the Endoscopic Imaging Chain

A rigid endoscope is made of a solid metal outer tube with integrated inner tube which houses the rod-lens system (made of quartz glass), the latter being the core component of endoscopic image acquisition. The proximal end of the scope is firmly fixed to the eyepiece and can be coupled to a video camera by use of a C-mount adapter. The intraoperative picture captured by the scope's lens system is transmitted to optical sensors in the video camera where analog signals are converted to binary data, which are routed to the camera control unit for digital image processing. In this way, a continuous stream of image frames is generated that can be viewed on a video screen while at the same time being saved on a data storage device. The major elements of a laparoscope are shown in Figs. 2.14c and 2.15.

As mentioned above, the outer tube of the laparoscope has an integrated inner tube containing the rod-lens system, which is the primary component of the endoscopic imaging chain. The resulting jacket space between outer and inner tube of the laparoscope accommodates the bundled optical fibers through which the light – generated by an external cold light source – is conducted to the tip of the scope.

In view of the high level of light intensity offered by the latest generation of cold light sources, the diameter of lenses used in modern scopes can be reduced to a minimum without causing a decline in the illumination level needed to safely perform a surgical procedure. The outer diameter of rigid scopes ranges between 3 and 12 millimeters. For obvious reasons, the illumination levels obtained from small-calibre (miniature) scopes are not as good as those offered by their large-calibre counterparts.

### 2.3.4.2 Cold Light Sources, Light Guides and Video Cameras

#### ■ Cold Light Sources

Adequate illumination is requisite for the safe performance of any surgical procedure. In the large majority of modern scopes, the light source – firstly, for the sake of space saving and, secondly, because of the heat generated by even a xenon lamp – is not integrated in the shaft of the scope but accommodated in a housing placed outside the operating field. Cold light sources with xenon lamps are commonly used in laparoscopy, however they are quite costly and have a short service life. Cold light sources with lamps made of light-emitting diodes (LED) have offered entirely new options and are an interesting alternative for experimental applications (Fig. 2.23).

#### ■ Light Guides

Glass fibers that are bundled and sheathed in a cable (fiber optic cables) (Fig. 2.24, ①) are most commonly used for light transmission in laparoscopic procedures. As an alternative option, the use of cables filled with a liquid-crystal gel may be considered (Fig. 2.24, ②). Even though the latter provide better luminous efficacy, they are not as deflectable and more expensive than fiber optic cables. The rate of light transmission into body cavities increases with the number of glass fibers, with diameter, and the power consumption of the light source. Fiber optic light cables are composed of several thousands of glass fibers each of which measuring 7 to 10  $\mu\text{m}$  in diameter. As a result, a total of 3,000 to 42,000 or 75 x 45 to 240 x 180 pixels can be achieved. The specific properties of a fiber optic light cable can have an impact on optical parameters such as brightness and color.



**Fig. 2.23** Cold light fountains XENON 300 (①) and POWER LED 175 (②) (KARL STORZ Tuttlingen, Germany).

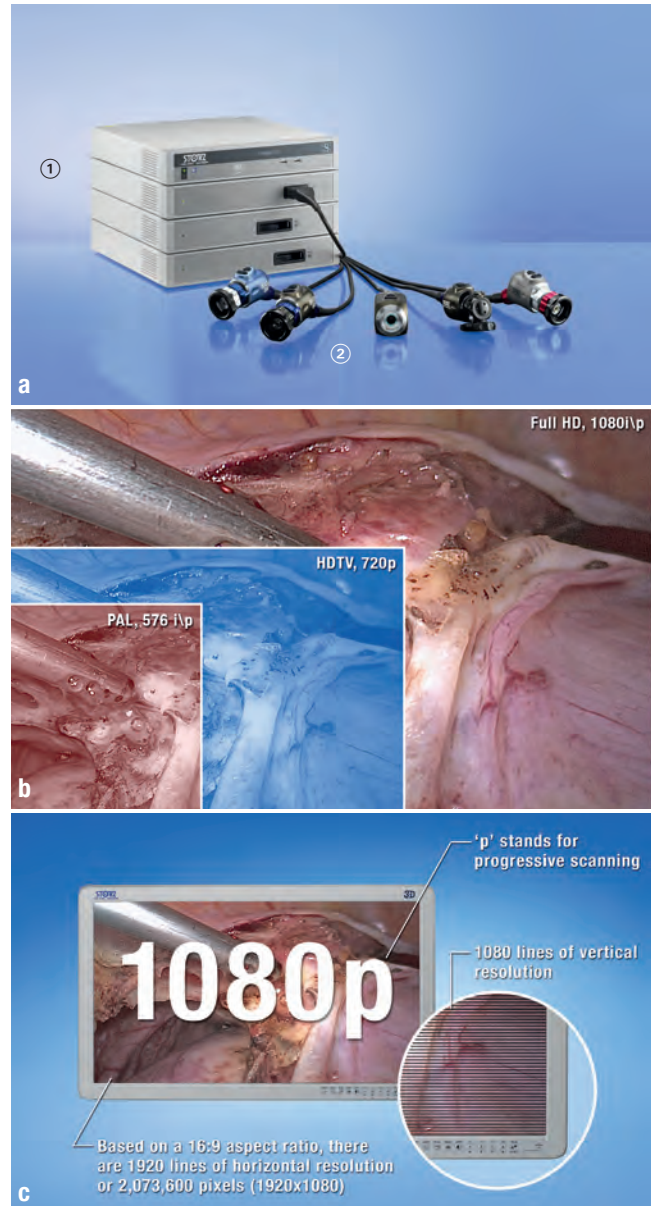
**Fig. 2.24** Light guides based on glass fibers (①) and liquid crystal gel (②).



### ■ Video Cameras

The core component of any high-definition (HD) video camera is the digital image sensor, which is typically based on three-chip charge-coupled device (CCD) technology – one CCD chip for each of the primary colors (red, green and blue) generated from the incident white light by passing through semi-transparent beam splitter prisms – and offers the advantage of improved color fidelity, enhanced image resolution and reduced noise. Single-chip CCD sensors detect only one color component per photodiode (also termed ‘picture element’ or ‘pixel’ or ‘dot’) and interpolate the missing two with a demosaicing algorithm, however, this adversely affects the quality of the image, both in terms of color and sharpness. Proven CCD technology ensures low noise and a high level of light sensitivity. A three-chip CCD sensor delivers detail-rich, sharp images with true-to-life color reproduction in all areas of the image, whether light or dark. The optical parfocal zoom at the camera head makes it possible to enlarge the image by a factor of 2 while obviating the need for refocusing. Unlike with digital pixel enlargement, the optical zoom function offers a higher level of detail and, owing to its user-friendly, convenient handling, the zoom can be used efficiently while staying focused on the task at hand.

Among the various standards defined for high-definition television (HDTV or HD), one of the most common formats is 1920×1080 (16:9 aspect ratio, the width-to-height ratio of the screen), progressive scanning, requiring 2.073 megapixels per frame. This format is also known as 1080p or *Full HD* (Fig. 2.25b, c). Given approximately 2 megapixels per frame, HDTV provides about five times as many pixels as standard-definition television (SDTV or SD). With HDTV, the entire image is recorded in one exposure interval (progressive scanning), which is superior to interlaced scanning, where an image is divided into two halves, each of which being recorded separately and then combined with the other. Delayed capturing of half images can result in motion artefacts or blurring, if there is movement. In endoscopy, blurring can arise from irrigation, smoke or instrumentation. The frame rate of 50 to 60 Hz (or frames per second) inherent to Full HD technology, is considerably higher than the frame rate of 25 or 30 Hz commonly achieved by SD technology. The 1920×1080 progressive scanning delivers an extremely stable image, with no flickering or interference. For medical use, this improved image quality largely contributes to reduced eye fatigue often experienced in long procedures.



**Fig. 2.25** IMAGE1 S (1) is a versatile camera platform that allows to simultaneously integrate up to two endoscopic imaging technologies (rigid/flexible/3D scopes) and is compatible for use with a large variety of camera heads (2). By courtesy of KARL STORZ Tuttlingen, Germany. (a) TV standards through 1080p. The red-tinted insert shows 576i or 576p resolution. The blue-tinted insert shows 720p resolution, a HDTV level of resolution. The full-color image shows 1080p resolution. (b) Among the various standards defined for high-definition television (HDTV), one of the most common formats is 1920×1080, progressive scanning, requiring about 2.07 megapixels per frame. (c)

### 2.3.4.3 3D Endoscopic Imaging

In open surgery as well as in activities of daily living, we are accustomed to binocular vision which is crucial in the perception of depth and the three-dimensional nature of objects. Getting acquainted with two-dimensional viewing conditions is among the challenges a laparoscopic surgeon must cope with when going through the learning curve required to develop an adequate level of skills in minimally invasive surgery. Even though standard laparoscopy affords only a two-dimensional image on the video screen, the use of monocular cues related to motion and size of objects commonly enable an experienced observer to mentally rebuild a three-dimensional image of the operative field.<sup>7</sup> The perception of depth, however, is not as vivid as that obtained from a real three-dimensional scene viewed with two eyes. The use of special viewing aids that provide for a near-realistic three-dimensional image in laparoscopy make it possible to visualize the operative field in virtually the same way as in natural viewing conditions. Most importantly, the use of such optical aids in laparoscopy allow the surgeon to differentiate more clearly between the various components of complex structures, including their location and relative position in the body. In conclusion, this innovative technology holds the prospect of a shorter learning curve, reduced duration of surgery, and fewer complications.

Given the multitude of stereoscopic systems currently available on the market, the following is a short description of one of the technological solutions currently used in 3D laparoscopic imaging. The endoscopic 3D system described herein is based on a stereoscopic camera system, that is connected to a bi-channeled laparoscope combining two lens systems in one shaft. The images generated by each lens system are transferred to separate video cameras (Figs. 2.27, 2.28). The underlying design principles for stereopsis are the same as those found in normal individuals with binocular vision. The development of stereoscopic imaging systems dates back 100 years in history, although to date, they are still far from being widely accepted in clinical practice. The primary obstacle that needs to be overcome to generate a three-dimensional image, is *binocular disparity*, a phenomenon that is based on slight differences in the images constantly created on the retina of the left/right eye. Binocular disparity allows the human brain to mentally build a realistic estimation of depth and distance, in other words, to produce a three-dimensional image. Wearing anaglyph 3D glasses may be a viable option, although this has proven inconvenient in a routine operative setting (Fig. 2.26). Recent technological advancements have made it possible to provide 3D images on the video screen while obviating the need for wearing 3D glasses. The authors



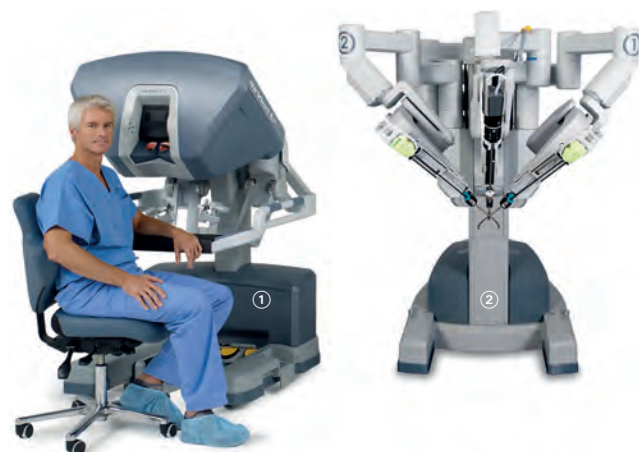
**Fig. 2.26** Hands-on training with the KARL STORZ 3D trainer at the Kiel School of Gynecological Endoscopy.



**Fig. 2.27** TIPCAM®1 S 3D LAP with two distal FULL HD image sensors (KARL STORZ Tuttlingen, Germany).



**Fig. 2.28** IMAGE1 S camera platform with D3-LINK and TIPCAM®1 S 3D LAP endoscopes. The insert images show the distal end of the TIPCAM®1 S 3D LAP with 0° (1) and 30° (2) direction of view (KARL STORZ Tuttlingen, Germany).



**Fig. 2.29** The 'da Vinci Surgical System' (Intuitive Surgical Corp., Sunnyvale, CA, USA). The surgeon console (1) and patient-side cart (2).



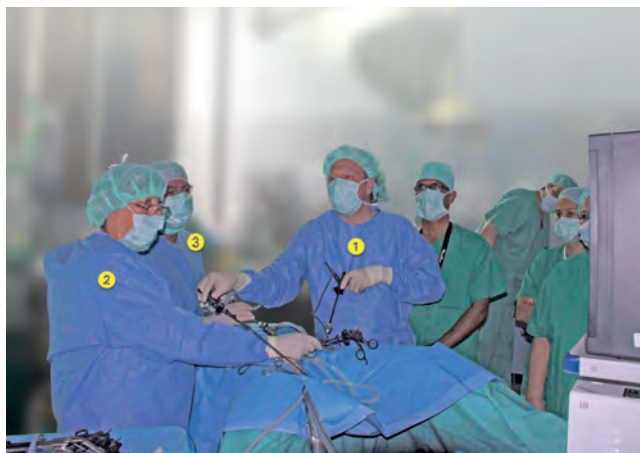hold the opinion, that the full technological potential of stereoendoscopic imaging in laparoscopy has not been realized yet.

Since the inception of 3D visualization aids, pioneers in the field of robotic surgery – a subspecialty of minimally invasive surgery – have made constant efforts to integrate this innovative technology in robotic systems. As mentioned above, two separate lens systems are integrated in a bi-channeled laparoscope and each of them is connected to different video cameras similarly to the basic principles of stereopsis in humans. The image is optimized digitally and then transferred to the surgeon console. In robotic systems such as the ‘*da Vinci Surgical System*’ (Intuitive Surgical, Inc., Sunnyvale, CA, USA), a pioneer of surgical robotics, the three-dimensional image is transmitted via separate video displays, i.e., one for each eye.<sup>13</sup> (Fig. 2.29).

### 2.3.5 Basic Instrumentation and Powered Equipment

#### 2.3.5.1 Operating Team

Most commonly, the first surgeon (①) – with the first assistant (camera operator,③) alongside to the right – stands on the left side of the patient while the scrub nurse (②) stands on the patient’s right (Fig. 2.30). The scrub nurse assumes a position next to the camera operator, and a second assistant (if needed) can be placed between the patient’s legs. For specific operative procedures, the first surgeon stands between the patient’s legs and the first assistant (camera operator) assumes a position next to the surgeon. The anesthesiologist’s position is usually at the patient’s head.

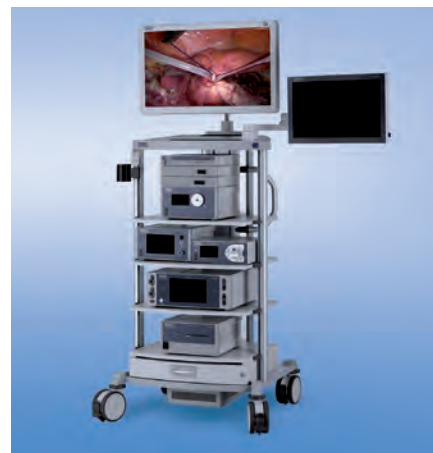

**Fig. 2.30** View of the surgical team during a training course at the *Kiel School of Gynecological Laparoscopy*. The first surgeon (①), the first assistant (camera operator, ③) and the scrub nurse (②).

#### 2.3.5.2 Powered Instruments, Units and Videoendoscopic Equipment

All control panels of the videoendoscopic units and medical devices are positioned such that both surgeons and the scrub nurse assume a comfortable posture for optimal hand-eye coordination which requires the visual axis (surgeon-to-monitor axis) to be optimally aligned with the forearm-instrument motor axis (Fig. 2.30).<sup>11,14,31</sup>

Therefore, video monitors, pertinent control units and additional devices that are instrumental in the planned procedure, are best suspended from ceiling mounts considering that mobile carts (Fig. 2.31) take up a lot of space and clutter the floor of the operating room with cables and tubings.<sup>31</sup> In most cases, the video monitor is placed between the patient’s legs. Care should be taken during room set-up to make sure that video monitors are at eye level, allowing the surgeon(s) to operate while the head and neck area is in a comfortable relaxed position.<sup>31</sup> The insufflation unit and cold light source are placed beneath the video screen, with the suction-irrigation unit below. The electrosurgical generator is positioned separately. A member of the staff should be defined in advance to take charge of auxiliary devices and/or instruments that are kept on standby on a separate instrument table.



**Fig. 2.31** Laparoscopic endocart (KARL STORZ Tuttlingen, Germany).



### ■ Insufflation Device

Constant pressure control is of critical importance to CO<sub>2</sub> insufflation during initiation and maintenance of the pneumoperitoneum, which is why an automated insufflation system (Fig. 2.32) should be used throughout any laparoscopic procedure to prevent the occurrence of undue pressure peaks or relevant pressure drops. The use of an automated insufflator that allows humidified CO<sub>2</sub> gas to be heated to body temperature before entry into the peritoneum not only helps prevent lens fogging in cases where the rate of gas exchange is abruptly increased, but has also been shown to reduce subphrenic pain in the postoperative period. The touch display of the unit (Fig. 2.32) shows the intraabdominal pressure (actual value), gas flow per minute, gas reserve, and the total volume of consumed CO<sub>2</sub>. The set value of intraabdominal pressure is preadjusted manually on the display and should measure no more than 15 mmHg for longer periods. Even though the maximum permissible pressure value may be exceeded temporarily at the start of the operation (while establishing the pneumoperitoneum and introducing the working trocars), special attention must be given to the fact that ventilation is limited under these circumstances and the surgeon should be alerted to the possible event of bradycardia.



**Fig. 2.32** ENDOFLATOR® 50 SCB Insufflation System (KARL STORZ Tuttlingen, Germany).

### ■ Suction-Irrigation Device

Since the vast majority of operative procedures in gynecology (hysteroscopy and laparoscopy) are not feasible without irrigation and suction of fluid, it is of key importance in routine clinical practice that such a device integrates both functions in a single unit. The use of prewarmed irrigation fluid helps prevent fogging of the scope's distal lens and reduces the risk of hypothermia for the patient (Figs. 2.33).

### ■ Electrosurgical Generator

Electrosurgical generator units (ESU) are widely used in clinical practice to generate specific surgical effects – such as cutting, coagulation, or a combination of both – mainly for dissecting tissue and for hemostasis. The high-frequency electrical current is delivered by the ESU (Fig. 2.34) passing from the active electrode through the dispersive electrode (Fig. 2.35) (in layman terms also known as ‘ground pad’ or ‘neutral electrode’)<sup>21</sup> and back to the ESU.

### Physics of High-Frequency Surgery

Good knowledge of the physical phenomena underlying high-frequency surgery is not only requisite to the targeted



**Fig. 2.33** ENDOMAT SELECT Suction-Irrigation system (KARL STORZ Tuttlingen, Germany).



**Fig. 2.34** Electrosurgical generator unit AUTOCON III 400 (KARL STORZ Tuttlingen, Germany).



**Fig. 2.35** Universal dispersive electrode for use with AUTOCON III 400 (KARL STORZ Tuttlingen, Germany). Depending on the operative site, the dispersive electrode should be placed on the closest upper arm or thigh, but no closer than 20 cm from the operative site and at a sufficient distance from ECG electrodes or implants (such as bone screws, bone plates, or endoprotheses). The dispersive electrode should be placed on the supine patient, on the upper side of the body, not in the vicinity of body fluids and also at a distance from the region of sterile washing.

application of specific waveforms and modes (bipolar versus monopolar circuitry) at a desired power output, but is equally important in understanding the associated tissue effects and reducing to a minimum the potential health risks that may arise from the use of electrosurgical devices.

The use of electrical energy for surgical purposes is based on the fact that the water content of the human body can be utilized as a conductor. Alternating currents with a frequency ranging between approximately 300 kHz and 3 MHz cause only minimal neuromuscular stimulation and – provided adequate precautions are observed – inadvertent harm to the patient can be well prevented.<sup>6</sup> The flow of electrons through tissue during a defined period of time (electrical current) is associated with specific effects:

- **Electrolytic Effect.** If a *direct current* (DC) is applied, the cations tend to migrate toward the direction of the negative electrode while the anions orient to the positive electrode as unidirectional current flow is established. This phenomenon is termed *Electrolytic* or *Galvanic Effect* and is used for medical purposes only in iontophoresis (transdermal electromotive administration of a charged substance/medication), whereas in electrosurgery this unwanted effect can jeopardize the structural integrity of cells and tissue.<sup>17</sup>
- **Faradic Effect.** Provided an *alternating current* (AC) is applied, anions and cations oscillate within the cellular cytoplasm in synchrony with the changing polarity of the output applied. If the frequency of AC is relatively low (20–30 kHz), the impact of the high-frequency energy will incite depolarization of muscles and nerves and induce action potentials that trigger muscle fasciculation and related pain, a phenomenon known as the *Faradic effect*.<sup>21</sup> However, nerve and muscle membranes are not sensitive enough to respond to the very short duration ‘pulses’ when using electromagnetic energy derived from the spectral range of high frequency (300 kHz– 3 MHz).

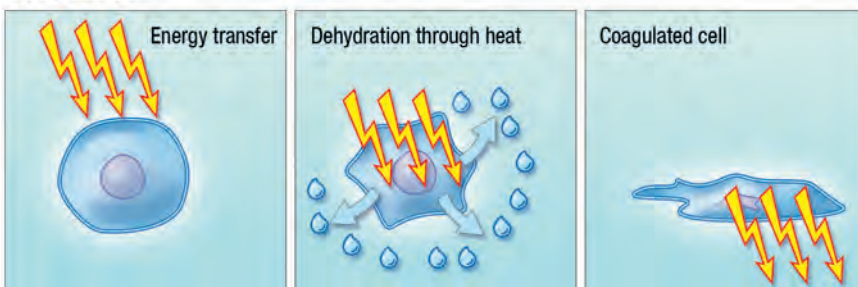
- **Thermal Effect.** When applying AC at a frequency above 300 kHz – unlike the depolarization process occurring with the use of DC – the cations and anions rapidly oscillate within the cellular cytoplasm leading to a conversion of electromagnetic energy to mechanical (kinetic) energy. As a result of this rapid motion and, especially in the instance of large protein molecules, frictional forces account for the conversion of kinetic energy to thermal energy. The impact of thermal energy on the tissue depends on various factors, e.g., *power output, waveform of the output, impedance of the target tissue, surface area of the electrode interfacing with the tissue, and the proximity of the electrode to the target tissue (contact or noncontact)*.<sup>21</sup>

The targeted release of thermal energy is the intended primary effect in high-frequency surgery, which is a mainstay of surgical modalities commonly used in operative laparoscopy.

#### *Impact of Alternating Current on Cells*

No relevant cell damage occurs until 40°C. Depending on the duration of exposure, reversible damage of tissue occurs between 40°C and 49°C. Irreversible cell damage occurs at temperatures above 49°C. Such damage is caused by the coagulation of cell proteins. Initially, the cell matrix remains intact, although some solitary cells may have perished already. Such damage can be compensated, depending on the regeneration potential of the tissue. Temperatures above 60°C cause desiccation due to the evaporation of intracellular and extracellular water. In the presence of water particles, the tissue temperature remains below the boiling point of 100°C. The progressive loss of cellular water (desiccation) causes the temperature to rise further, and in turn leads to carbonization often associated with a black and/or brown appearance, which is why it is sometimes referred to as ‘black coagulation’ (Fig. 2.36).

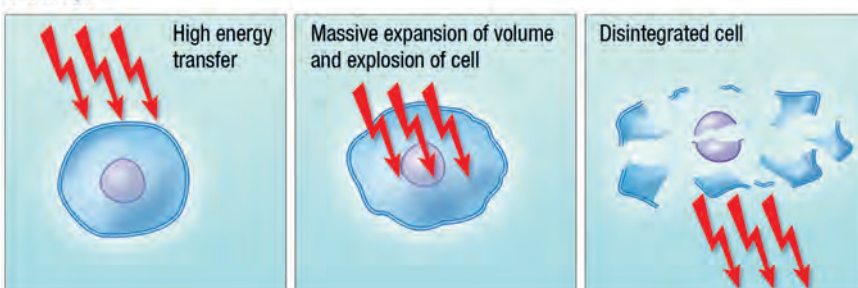
#### Coagulation



**Fig. 2.36** The impact of electrical current on the cell depends on power output, electrode size/shape, waveform, peak voltage and speed of electrode.

**Note:** For the sake of simplification, in the diagrammatic representation the above factors (see ‘Thermal Effect’) are reduced to ‘energy transfer’ versus ‘high energy transfer’.

#### Cutting



High-frequency surgery commonly involves the application of an alternating current ranging from 300 kHz to 1 MHz. The thermal energy released while employing this surgical modality is the intended primary effect.

### Electrocoagulation

A coagulation effect occurs when tissue is heated rather slowly to more than 60 °C. Several changes occur during this 'boiling' process, such as denaturation of protein, evaporation of intracellular and extracellular water, and volumetric shrinkage of tissue. Depending on the specific waveform of the current ('cut', 'coag' or 'blend') and the application mode, a distinction is made in high-frequency surgery between *contact coagulation*, *forced coagulation*, *desiccation* (coagulation through a needle electrode), *spray coagulation* (fulguration), *argon plasma coagulation* (APC), *bipolar coagulation*, and *bipolar vessel sealing*.

### Electrotomy

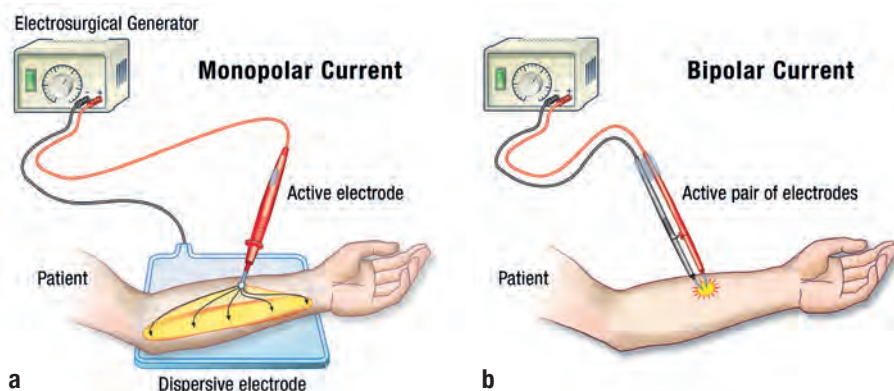
A cutting effect is achieved by rapid heating of tissue to more than 90–100 °C. Ensuingly, a liquid-to-gas conversion is induced leading to the creation of a 'steam envelope' (of steam, ions, and organic matter),<sup>21</sup> ultimately tearing the cell walls and acting as an insulator. From approximately 200 V onward, the cutting current arcs between the electrode and tissue, causing the (repeated) transmission of sparks. A very high current density is present at the base points. The environment (air, fluid) is of no relevance to the formation of this electric arc. If a high-voltage modulated (intermittent) output is used, this will cause additional coagulation of the wound margins. Depending on the spark intensity (peak voltage), a distinction is made between 'smooth' and 'scabbed' incision. Other heat-induced effects which are of secondary relevance to the clinical use of high-frequency surgery include carbonization (from about 200 °C onward) and fulguration (at several hundred degrees centigrade) (Fig. 2.36).

### Monopolar Electrosurgery

When using monopolar electrical current, the patient's body is included in the electrical circuit (Fig. 2.37a), a circumstance that involves the potential risk of current diversion.<sup>21</sup> The active electrode is designed to focus the current/power on the surgical target, thereby generating the desired tissue effect. The passive (or dispersive) electrode is positioned on the patient in a location remote from the surgical site and is relatively large in surface area, which serves to defocus or disperse the current while preventing injury to healthy tissue.<sup>21</sup> The high-frequency current used for resection is of low-voltage, continuous output in the form of a sine wave. This causes an almost instantaneous rise in tissue temperature, followed by cell vaporization and greater permeability of tissue.<sup>21</sup> The so-called 'coagulation' waveform is an interrupted, dampened, and relatively high-voltage waveform. Typically, the current is 'on' only 6% of the time interval, referred to as a 6% duty cycle.<sup>21</sup> The intermittent output from the 6% duty cycle waveform causes a brief and superficial elevation of tissue temperature, sufficient to cause focal coagulation, desiccation, and, in many instances, carbonization.<sup>21</sup>

Defects in the insulation of instruments or trocars may facilitate capacitive coupling of electricity and lead to undetected tissue damage. Likewise, coagulation in the proximity of a thin tissue bridge may cause thermal defects following passage of the current through such a structure. The resulting heat may cause iatrogenic damage at a considerable distance from the surgical target area.

Care must be taken that the dispersive electrode be placed at a site where the anticipated pathway of the current between the active and the dispersive electrode is as short as possible and 'runs' longitudinally or diagonally through the body because muscles in the direction of the fibrils possess greater conductivity. The dispersive electrode must be in full contact with the skin and its proper function requires that the current



**Fig. 2.37** Schematic representation of **monopolar (a)** and **bipolar (b)** high-frequency surgery systems.

As a matter of fact, all electrosurgery is 'bipolar' for it is necessary to have two electrodes. What differs, is the location and purpose of the second electrode.<sup>21</sup> Monopolar instruments are used in monopolar systems (a). One of the two electrodes in such systems is designed to concentrate the current/power to achieve a surgical effect (the so-called 'active' electrode), while the second electrode is placed remotely on the patient to disperse the current thereby preventing the elevation of tissue temperature. Monopolar systems include the entire patient in the circuit, a circumstance that carries the potential risk of current diversion.<sup>21</sup>

**Bipolar systems** include both electrodes in one hand instrument (b).<sup>21</sup> In most (but not all) instances, both electrodes are of small enough surface area to operate as 'active' electrodes thereby creating a surgical effect. In some instances, the electrode on the instrument serves as a dispersive electrode. The only part of the patient involved in the circuit is that adjacent to the electrodes, a circumstance that makes current diversion a virtual impossibility. Note that the same ESU can usually support both systems.<sup>21</sup>



is spread over a large surface area in order to prevent injury to healthy tissue. Nowadays, the standard configuration of any dispersive electrode (Fig. 2.35) comes with integrated contact quality monitoring, also termed 'split pad' design, which incorporates an interrogation circuit that actively monitors the impedance at the patient/electrode interface and – in the event of high impedance – automatically deactivates the ESU.<sup>8</sup> For safety reasons, however, the use of bipolar high-frequency surgery is widely recommended (Fig. 2.37b).

### *Bipolar Electrosurgery*

Both bipolar and monopolar electrosurgical systems have in common that they are designed to generate alternating current which is converted first to kinetic energy, then to thermal energy. However, in bipolar electrosurgical systems, the active and the dispersive electrode are as close to each other as possible and possess the same mass. Accordingly, only the surgical target site interposed between the pair of jaws/electrodes – and not the entire patient as with the bipolar technique – is included in the electrical circuit. A bipolar instrument with a pair of jaws is designed such that the wires from/to the ESU – each connecting to one of the jaws/blades – are insulated from each other. Activation of the electrical current induces a rise in tissue temperature and ensuingly results in coagulation. In most bipolar instruments, both electrodes (jaws) are of small enough surface area to serve as 'active' electrodes, obviating the need for a dedicated dispersive electrode (Fig. 2.37b).

The application of excessive thermal energy is fraught with the risk of iatrogenic damage to vulnerable structures and organs in the immediate vicinity of the activated electrode (bowel, bladder, ureter, blood vessels).

The use of monopolar and bipolar electrosurgical systems has become widely accepted both in laparoscopy and hysteroscopy. The application of monopolar current in hysteroscopy permits precise exposure, however, at the expense of a higher risk of electrolyte imbalance due to the imperative use of electrolyte-free solutions.

## 2.3.6 Special Instrumentation

### 2.3.6.1 Hysteroscopy

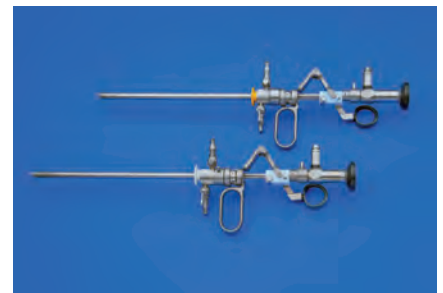The diagnostic hysteroscope is equipped with a separate small working channel for introducing instruments such as microscissors or forceps commonly used for dissection and minor operative maneuvers, e.g., biopsy sampling. Similarly to their counterparts from the field of urology, gynecological resectoscopes are most commonly available with a dual-sheath design (inner/outer sheath) that provides for continuous-flow irrigation and suction. The operative sheath of a resectoscope is designed for use with electrosurgical instruments, such as a cutting loop, a hook-shaped or barrel-shaped electrode, etc. These instruments may be used either with bipolar or monopolar current and allow tissue to be resected and coagulated in a precise manner (Figs. 2.38–2.42). Advancements in hysteroscopy – both in terms of instrument design and surgical technique – have made it possible to use small-calibre scopes and instruments (office or mini-hysteroscopy) that offer the advantage of a virtually atraumatic access to the intrauterine cavity while obviating the need for prior dilatation or anesthesia.



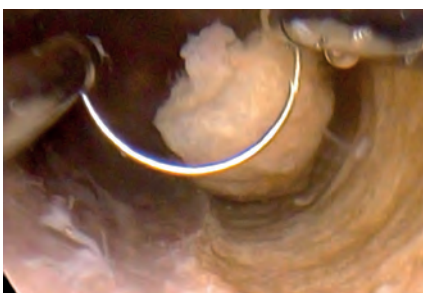**Fig. 2.38** The CAMPO Compact Hysteroscope (TROPHYscope®) with tenaculum forceps inserted in the working channel.



**Fig. 2.39** Operative hysteroscopes with working inserts.



**Fig. 2.40** Bipolar resectoscopes (22 and 26 Charr.) (KARL STORZ Tuttlingen, Germany).



**Fig. 2.41** Hysteroscopic removal of slices of tissue ('chips') from the uterine wall.



**Fig. 2.42** The CAMPO Compact Hysteroscope (TROPHYscope®) with diagnostic sheath and outer continuous-flow operative sheath.

### 2.3.6.2 Laparoscopy

This subsection provides up-to-date information about a few innovative developments in the field of laparoscopy and gives a concise historical review, ranging from concept to inception and implementation in the past decades, followed by an outlook of future directions. In an attempt to overcome the inherent limitations imposed by two-dimensional visualization, the constant refinement of 3D laparoscopes has largely contributed to an increase in clinical acceptance and has made laparoscopic procedures safer and easier to learn. Two-dimensional viewing still remains one of the major shortcomings of standard laparoscopic procedures when compared to open surgery. Now, that this major issue has been resolved, yet another obstacle that needs to be overcome by innovative solutions, is the handicap of limited degrees of freedom. While open surgery permits 7 degrees of freedom for the surgeon's hands, endoscopic instruments provide only 4 degrees of freedom. With the aid of a robotic system, the surgeon is offered 7 degrees of freedom, improved intuitive manual control and better hand-eye-coordination as compared to standard laparoscopy. None of the conventional attempts (such as those made by *Terumo Medical Corporation*) have attained widespread acceptance so far. Therefore, the author holds the opinion that the development of a new generation of instruments offering improved dexterity and an extended range of motion will be even more important in the future.

### 2.3.6.3 Single-Port Laparoscopy

To date, the use of single-port devices still lacks widespread acceptance among experts in the field of laparoscopic surgery. Its main advantages stem from handling both scope and working instruments through a single multichannel port – commonly placed through a subumbilical incision – and are mainly related to the creation of a single scar, improved cosmesis and less postoperative pain from the port site.<sup>9,12</sup> There is a large variety of single-port devices available on the market (Figs. 2.43, 2.44). Even though the latest generation of the S-PORT (single portal access system; KARL STORZ Tuttlingen,

Germany; Fig. 2.44) offers the major advantage of adapting the length of incision to the specific needs of the case, the use of an open entry (Hasson) technique and meticulous incisional closure at the end of surgery is still imperative in any single-port procedure. It is noteworthy that triangulation – a tenet of standard laparoscopy, defined by the multiple ports by which both instruments and scope/camera are maneuvered – is considerably reduced when using a single-port access. This is mainly due to the fulcrum points for instrumentation being closely adjacent to each other. Dexterous handling of instruments and scope without inadvertent 'clashing' is a challenging task that requires beginners to go through a distinct learning curve until an adequate level of proficiency is attained. Even though angulated instruments and precurved shafts are available to compensate for the shortcomings described above, the long learning curve along with the need for specialized precurved instruments seems to constitute a major deterrent to a more widespread use of the single-port technique. The latest generation of single-port systems allow the incision size to be preadjusted to the needs of the procedure and offer a certain degree of triangulation which facilitates a more intuitive and dexterous handling of instruments. Another aspect worthy of mention is the cost-benefit ratio. A large proportion of single-port systems currently available on the market are disposable items. Good examples of this type of medical products are systems like GelPOINT Advanced Access Platform (*Applied Medical Resources Corp.*, USA) (Fig. 2.43), Octoport (*Dalim-SurgNET Co. Ltd.*, Korea), SILS™ Port (*Medtronic*, USA) and QuadPort+ (*Olympus Corp.*, Japan). A good alternative option for the use of disposable items is a set of reusable products manufactured and marketed by KARL STORZ Tuttlingen, Germany (*CUSCHIERI ENDOCONE Single Portal Surgery Access System* and the new *LEROY S-PORT*). The cost-effective reusable *LEROY S-PORT* enables the surgeon to use very small incisions of less than 12 mm and offers maximum movability for instruments (measuring from 3 mm–15 mm) and scope, which are inserted through finger-shaped highly deflectable channels made of semi-rigid rubber material (Fig. 2.44).



**Fig. 2.43** GelPOINT Advanced Access Platform (*Applied Medical Resources Corp.*, USA).

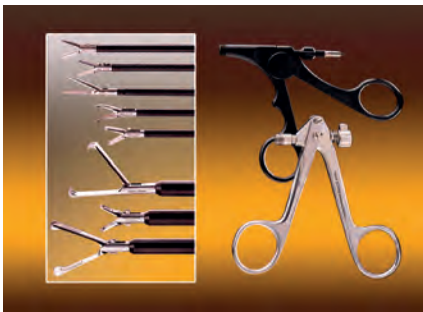

**Fig. 2.44** The new *LEROY S-PORT* (KARL STORZ Tuttlingen, Germany) is a highly versatile single-port device that offers an increased range of motion for handling up to three instruments and one scope through highly deflectable channels. In terms of reprocessing and maintenance, the modular design of the *S-PORT* offers all of the benefits typically provided by a reusable item. Yet another advantage is that the size of the incision can be chosen as determined by individual preferences and the specific requirements of the anticipated procedure.

### 2.3.6.4 Standard Laparoscopy

In the mid-1990s, KARL STORZ Tuttlingen, Germany, introduced its first generation of dismantling instruments (Fig. 2.45). A unique feature of these instruments is the simplicity of their modular design – which can be completely disassembled into handle, outer sheath and working insert – and allows them to be cleaned and reprocessed using automated autoclave sterilization (Fig. 2.46). This helps reduce OR costs per case and simplifies inventory management, eliminating the need to store large quantities of disposable

items. Working inserts are easily and swiftly replaced at the click of a button, e.g., if the need arises to sharpen the jaws/blades. Highly accurate operative instruments are of vital importance in any surgical procedure, and this is even more true for surgeries with a higher level of complexity. In view of the current trends in minimally invasive surgery (MIS), the question remains as to whether miniaturization of scopes and instruments (Fig. 2.52), required to perform mini-laparoscopic procedures, will gain widespread acceptance in the future.



**Fig. 2.45** Historical photograph (1992) of the first generation of TAKE-APART® laparoscopic hand instruments for laparoscopy (KARL STORZ Tuttlingen, Germany).



**Fig. 2.46** KOH Macro Needle Holder (KARL STORZ Tuttlingen, Germany). Close-up view of the single-action jaws (curved left, ①) and right, ②). Gross aspect of the same instrument with ergonomic pistol-shaped (③) and axial (④) handle. The lower part of the image shows all components of the disassembled instruments.



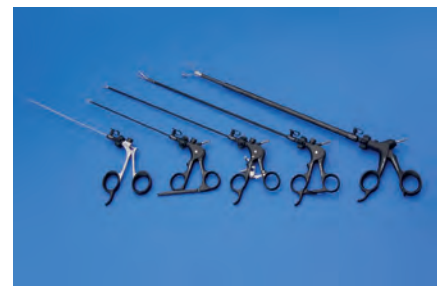**Fig. 2.47** Suction-irrigation tubes connected to a straight (①) and pistol-shaped (②) handle (KARL STORZ Tuttlingen, Germany).



**Fig. 2.48** GORDTS-CAMPO Suction-irrigation tube (KARL STORZ Tuttlingen, Germany).



**Fig. 2.49** Various types of CLICKLINE scissors (KARL STORZ Tuttlingen, Germany).



**Fig. 2.50** Set of CLICKLINE instruments (KARL STORZ Tuttlingen, Germany).

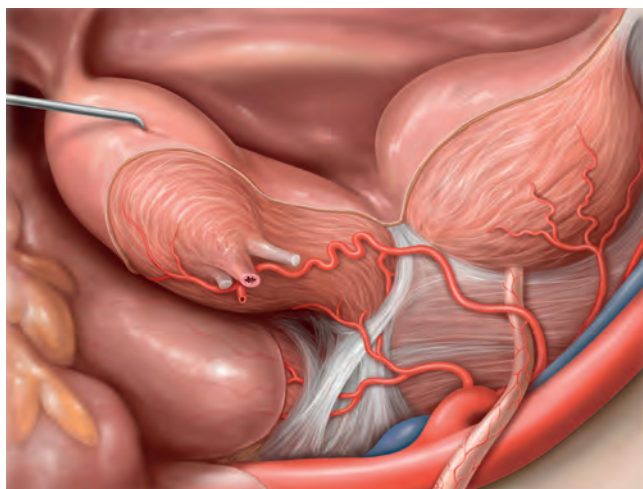


**Fig. 2.51** ROBI® KELLY Dissecting and Grasping Forceps, CLERMONT-FERRAND model (KARL STORZ Tuttlingen, Germany).

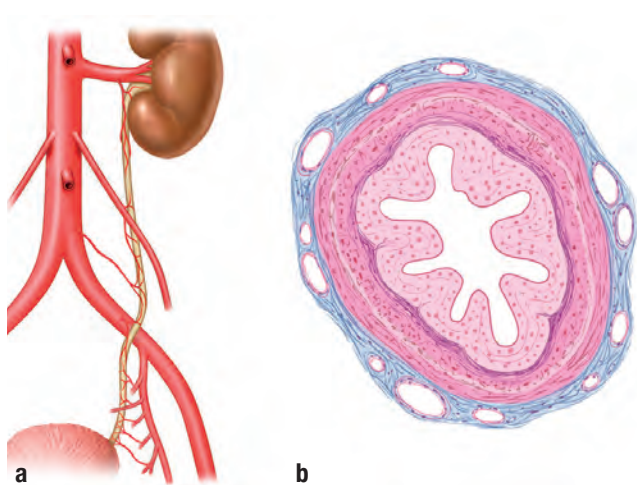


**Fig. 2.52** Minilaparoscopy set (KARL STORZ Tuttlingen, Germany).

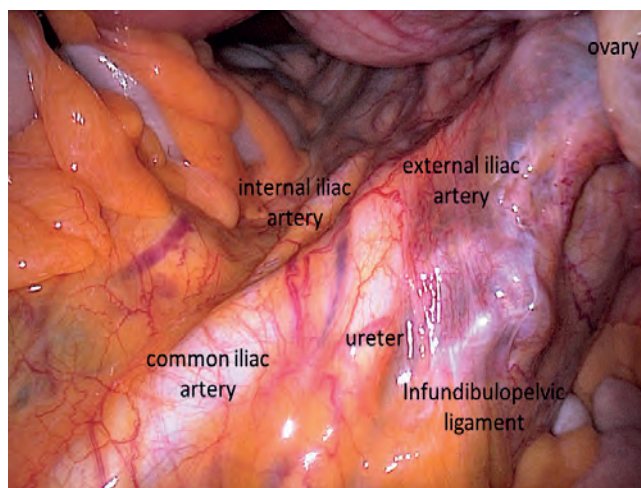




**Fig. 2.53** The anatomical illustration shows the relationship of the uterine vessels to the ureter in the pelvic wall, as compared with its location close to the uterus. The tortuous course of the ascending branch of the uterine artery is clearly appreciated. The uterus, bladder and rectum are embedded in a ligament-based pelvic floor.



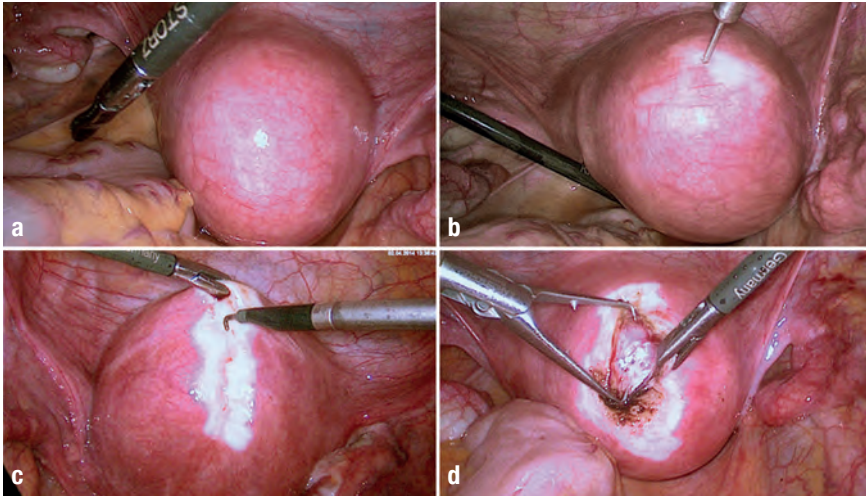
**Fig. 2.54** Ureteral anatomy provides crucial information (a, b). The upper part of the ureter is supplied chiefly by the renal artery, ovarian artery, and aorta (a). The lower part is supplied by the iliac vessels and uterine artery (a). Blunt dissection causes minor bleeding at the respective levels. Histologic cross-section of the ureter demonstrates the location of the vessels in the adventitia (b). Because of this arrangement, electrocautery or any manipulation that destroys the adventitia may eventually result in secondary fistulation and/or leakage.



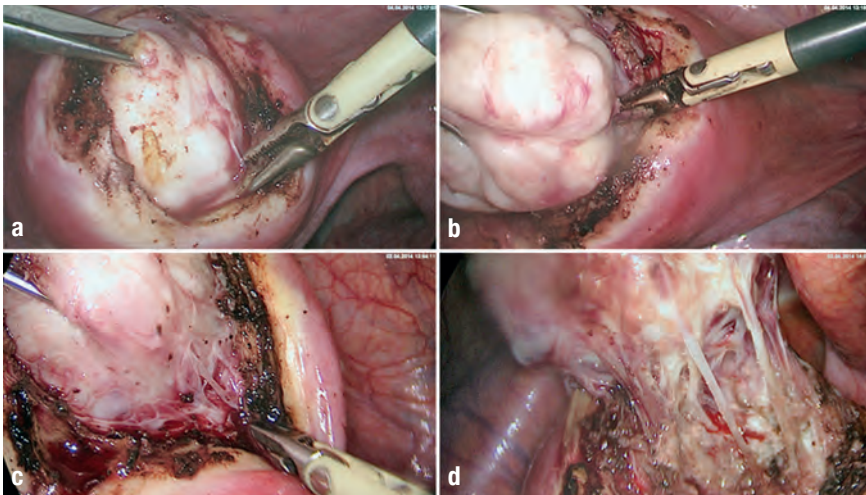
**Fig. 2.55** Preliminary inspection of the uterus and the surrounding organs. The lower pelvis as well as the ligaments, vessels and the ureter can be well-appreciated in relation to the uterus. In slim patients, the crossing point of the ureter and the common iliac artery is clearly visible. The infundibulopelvic ligament is identified and mobilized towards the lateral wall in order to improve exposure of the surgical site.

When faced with complex anatomical circumstances and target structures that are difficult to access (Figs. 2.53, 2.54), visualization is greatly facilitated by the use of a state-of-the-art scope coupled to an HD camera with integrated zoom function. This allows the operative gynecologist to take a closer look on areas of interest by magnifying the video image (Fig. 2.55) which can be constantly followed by other members of the surgical team, thereby improving intraoperative collaboration as compared to open or conventional vaginal surgery.

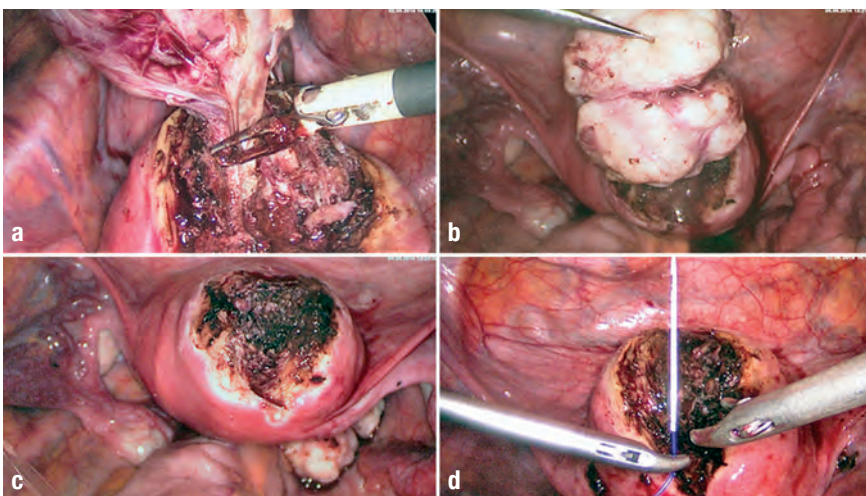
Many operations can be performed very precisely with minimal bleeding while sparing healthy tissue to the maximum extent feasible, as in the illustrative case of a patient undergoing myoma enucleation with reconstruction of the uterine wall (Figs. 2.56–2.62).



**Fig. 2.56 Laparoscopic myoma enucleation.** Operative site of a fundal/anterior wall fibroid (a). Prophylactic administration of 1:100 vasopressin solution (terlipressin acetate) diluted in separate vials. The injection – given between the superficial healthy tissue of the myometrium and the capsule/fibroid surface (b) – is intended to separate the pseudocapsule from the fibroid and to reduce bleeding. Bipolar superficial coagulation of the longitudinal incision line and opening of the uterine wall with a monopolar hook or needle electrode as far as the fibroid surface (c). The fibroid is grasped and enucleation is initiated (d). The pseudocapsule remains within the uterine wall and is pushed off bluntly.

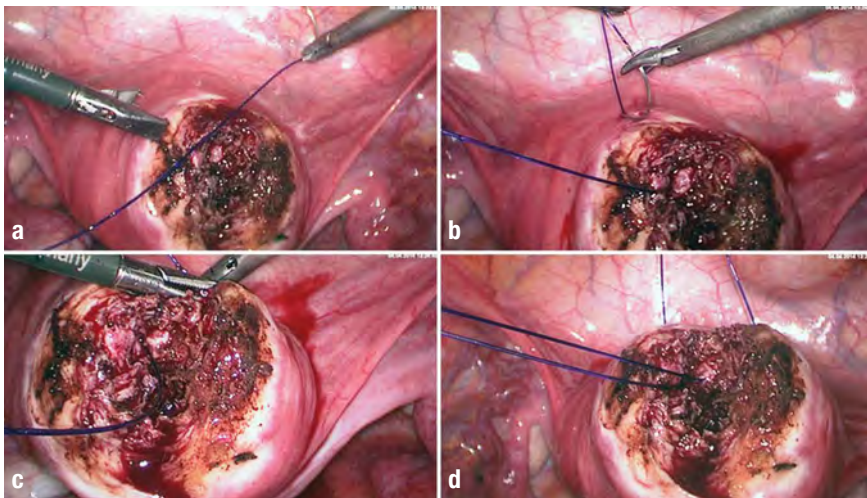


**Fig. 2.57 Laparoscopic myoma enucleation.** Traction is applied on the fibroid with a tenaculum to bluntly delineate and expose the leading edge of the pseudocapsule (a). Focal bipolar coagulation of vessels in the basal layer (b). Continuous enucleation of the fibroid under traction and targeted coagulation of capsule fibers containing vessels (c). Close-up view of the remaining capsule fibers which are coagulated and cut (d).



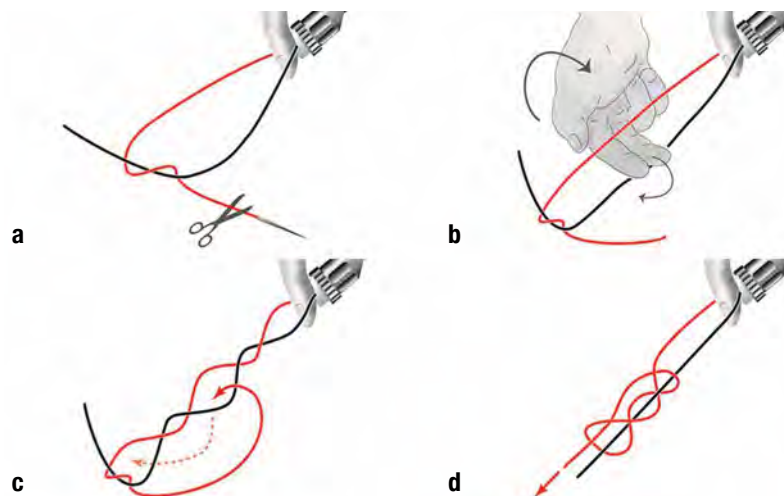
**Fig. 2.58 Laparoscopic myoma enucleation.** Final aspect of the coagulation of capsular vessels (a). Fibroid with invaginated midsection after complete enucleation (b). Minimal coagulation of bleeding vessels under suction and irrigation (c). Approximation of wound edges with a straight or round sharp needle using delayed absorbable monofilament suture (d).





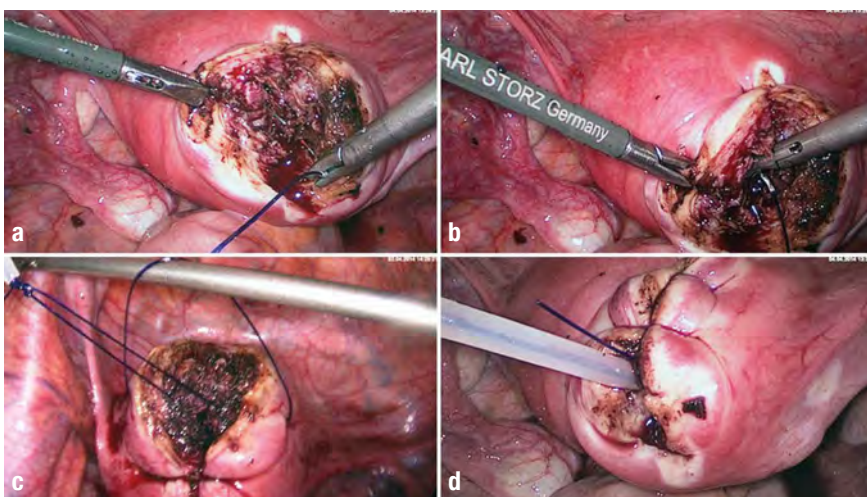
**Fig. 2.59 Laparoscopic myoma enucleation.** Laparoscopic myoma enucleation. Advantages of a circular needle stitch (a):

- 1) The wound margin is elevated safely and completely when raised with a forceps;
  - 2) Deeper myometrial layers can be grasped more easily with a circular needle.
- Needle exit and simplified re-grasping with the assistant needle holder (b). Final stitch to invert the knot (c). Retrieval of the needle, completion of the extracorporeal knot, and preparation for sliding down the extracorporeal knot with a knot pusher (d).



**Fig. 2.60 The extracorporeal 'von Leffern' knot.**

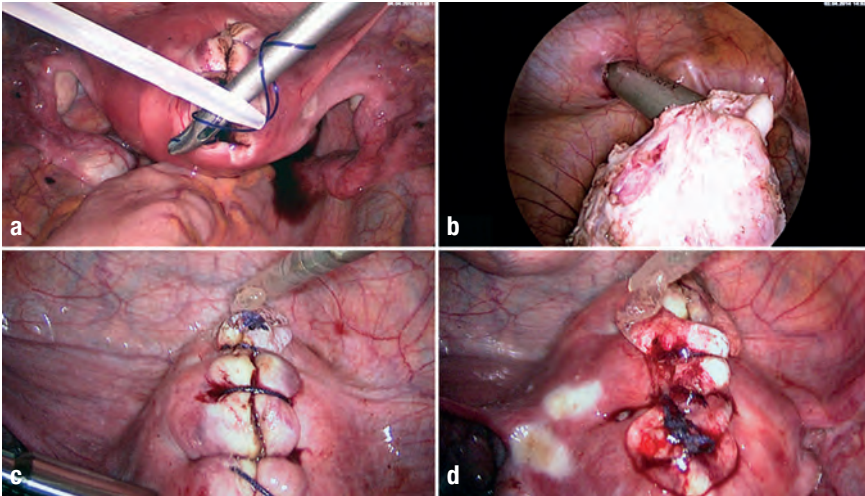
The suture is withdrawn and the needle removed, followed by a half hitch (a). The knot is pressed down by the tip of the left finger while reaching over with the right hand (b). The short end is grasped from below and lead through in a retrograde fashion, exiting before the half hitch (c). The knot is slid down to the operative site. Maintaining traction on the straight strand of the suture, the knot is tied down (d).



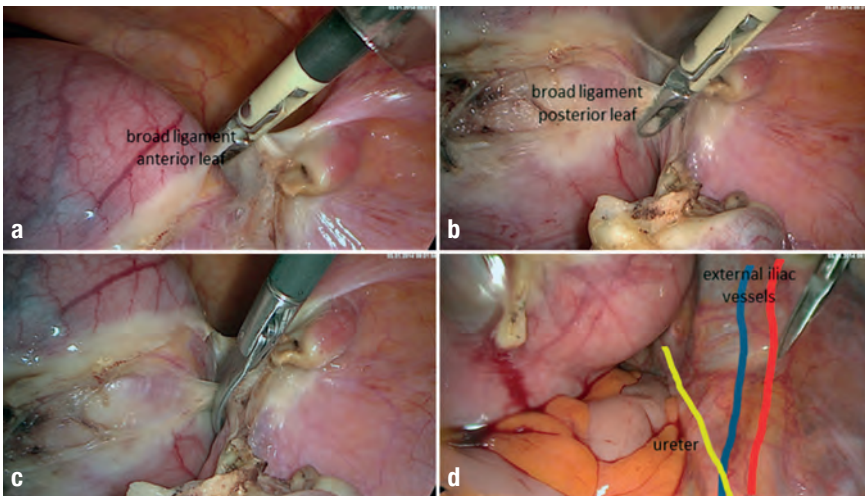
**Fig. 2.61 Laparoscopic myoma enucleation.**

The second single suture is placed as deeply as possible in the uterine wound (a). The needle exits on the left wound margin (immediately adjacent to the forceps) (b). Once the stitch has been completed, the 'von Leffern knot' is tied extracorporeally (c). The needle holder elevates the strand to avoid tearing of the uterine wall while applying traction on the monofilament suture (PDS) (c). The extracorporeal knot is slid down with a plastic knot pusher and buried in the depth of the wound, thus minimizing the residual outer part of the suture (d).





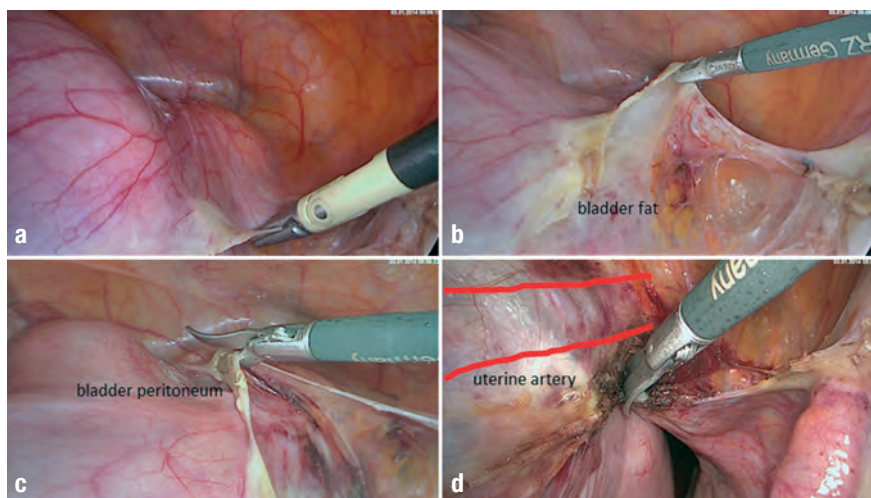
**Fig. 2.62** Laparoscopic myoma enucleation. An intracorporeal safety knot is placed on the one that has already been tied extracorporeally (a). Morcellation of the fibroid using a ROTO-CUT morcellator (KARL STORZ Tuttlingen, Germany) with a skinning technique (b). Final aspect of the operative site showing the extracorporeal sutures approximating the uterine wound edges (c). Application of Hyalobarrier® gel (Nordic Pharma GmbH, Switzerland) for adhesion prevention (d).



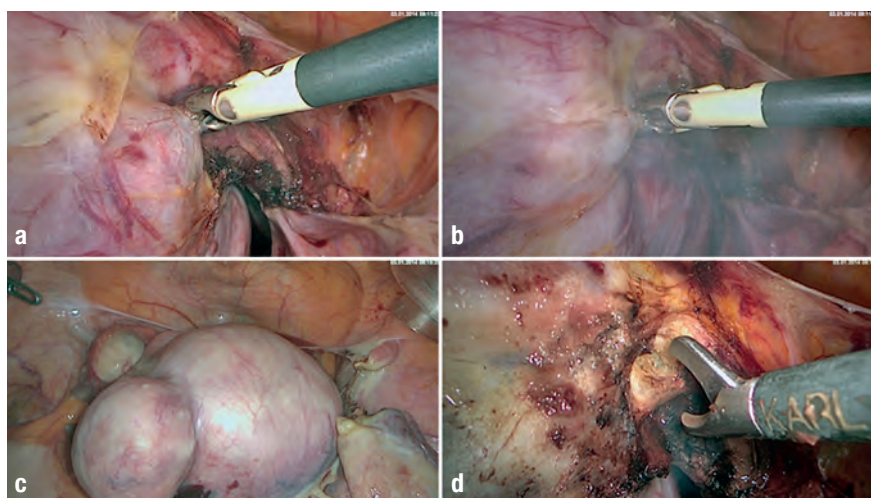
**Fig. 2.63** Separation of the anterior and posterior leaf of the broad ligament (a–c) in relation to the ureter and the pelvic vessels (d). The broad ligament is coagulated and dissected as close to the uterus as possible without compromising integrity of the uterine artery. While performing this surgical maneuver, the ascending branch of the uterine artery is readily identified and spared. Care should be taken to make sure that the tip of the scissors' curved blades (c) is directed strictly away from the uterine wall.

Cameras are an important integral part of any surgical procedure and requires the assistant to handle both the scope (which offers a direction of view suited for the specific purpose) and the video camera. This typically requires that a suitable zoom factor be chosen while maintaining an adequate distance from the anatomical target site. Even in complex situations (e.g., in the presence of bulky organs, adhesions, endometriosis, obesity) a high level of safety is maintained

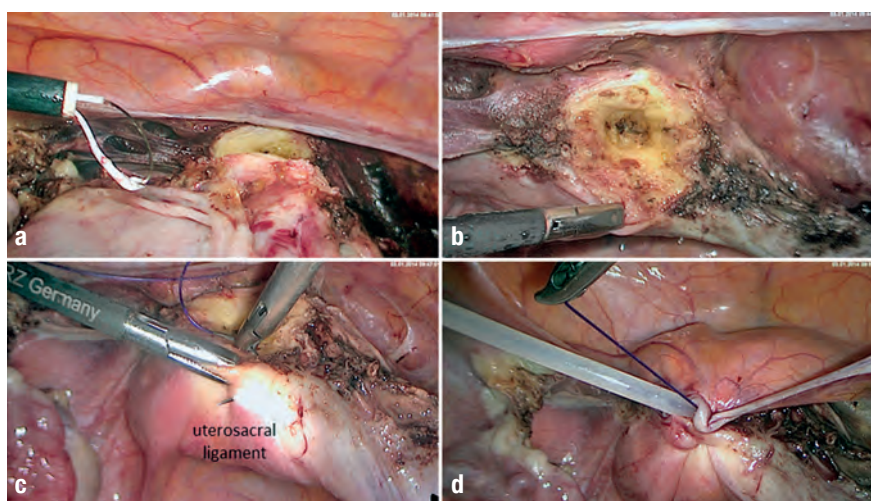
if the selected instruments are well-suited for the intended purpose. Once the surgeon-in-training has gone through the initial stages of the learning curve, the primary steps – which often are tedious and time-consuming – can be performed more rapidly with the appropriate instruments, as shown in the illustrative case of a patient with a large myomatous uterus treated by total laparoscopic hysterectomy (Figs. 2.63–2.69).



**Fig. 2.64** The bladder peritoneum is opened from the right side (a–c). The starting point of the incision on the bladder peritoneum can be easily identified. The incision line should neither be above this zone nor reach too far into the caudal aspect. As CO<sub>2</sub> gas flows into the created space, the site of the bladder pillar is revealed. The bundle of uterine vessels (d) is freed by coagulating and dissecting above and below it. The ureter is at a safe distance lateral to the area of exposure.

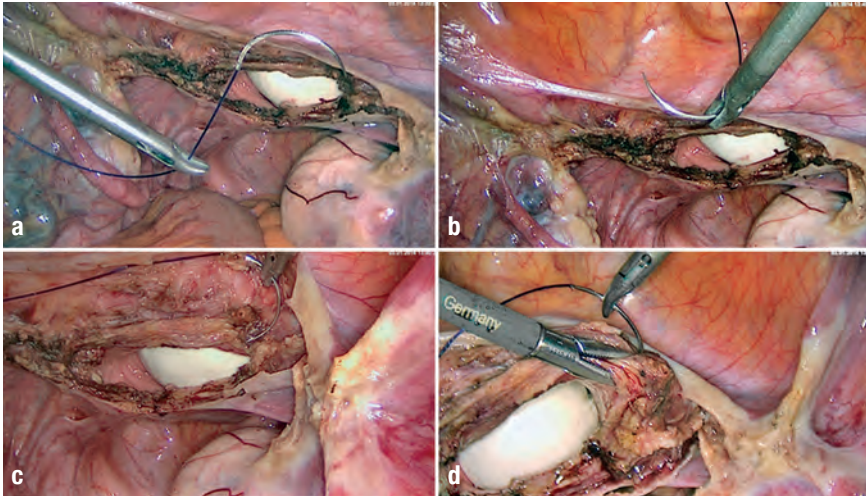


**Fig. 2.65** Bipolar coagulation and dissection of uterine vessels. In order to prevent retrograde bleeding from the uterine artery as a consequence of dissection, its pper segment must be included in the area of coagulation (b). The uterus assumes a whitish-grey appearance (blanching) (c). A deeper cut can be avoided by using hook scissors (d). Dissection of the uterine artery is carried out in two steps enabling the surgeon to proceed with coagulation of the tissue lying just behind the artery and thus avoid cumbersome venous bleeding (d).

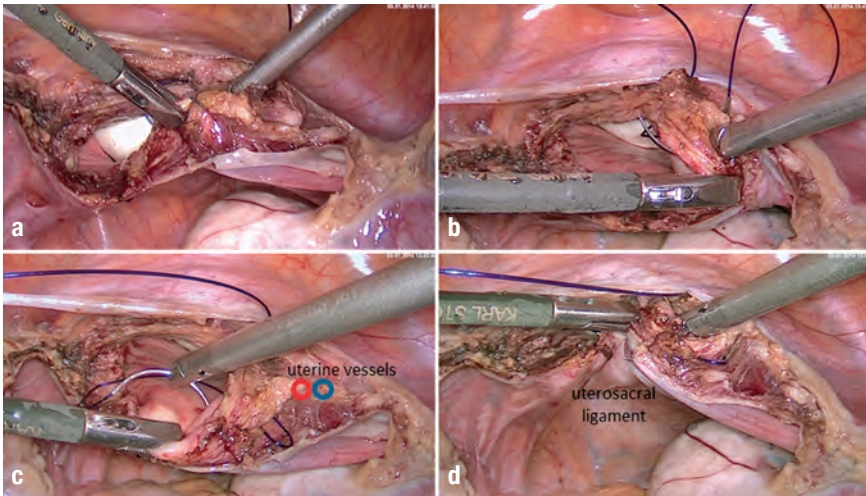


**Fig. 2.66** Selectively, the uterine corpus is cut from the cervix (a). The cervical stump remains in situ after a shallow cone has been created by use of a monopolar loop, cutting gently through the tissue while traction is applied (b). Peritoneal closure is an optional step, but when choosing to adopt this measure, a cervicopexy may then be performed in the same session for prolapse prevention (d).<sup>2</sup>

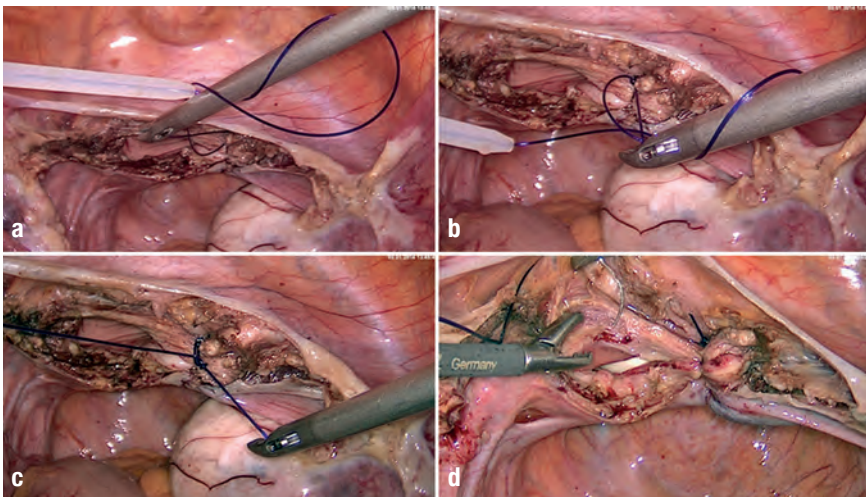




**Fig. 2.67 Laparoscopic Total Hysterectomy.** Right corner suture coalescing the anterior and posterior vaginal wall, the posterior peritoneum and the right sacrouterine ligament. The bladder is identified and spared. A sharp forceps is needed to permit a secure grip on the vaginal epithelium. If the suture incorporates the vaginal wall while excluding the epithelium, there is a high susceptibility to postoperative granuloma formation.



**Fig. 2.68 Laparoscopic Total Hysterectomy.** Right corner suture (continued from Fig. 2.68). The right sacrouterine ligament is grasped. The vessel stumps are lateralized and excluded from the suture bites. Vessels are mechanically compressed when this type of suture is used.



**Fig. 2.69 Laparoscopic Total Hysterectomy.** The right corner suture is tied intracorporeally and the tail is cut.



### 2.3.6.5 Vessel Sealing


Vessels with a diameter of more than 2 mm are not amenable to being treated by conventional electrocoagulation. Reliable hemostasis with a permanent seal is accomplished only by use of bipolar vessel sealing or ligation. The vascular pedicle or tissue bundle to be sealed is grasped by the jaws of a special instrument that allows predefined coaptive pressure to be applied while bipolar energy is delivered. The specialized bipolar electrosurgery unit provides for constant monitoring of various parameters that contribute to the thermal impact on the tissue by automated control of energy output and preselected waveform ('continuous' versus 'pulsed') which is locally regulated using continuous impedance feedback. In this way, the approximated tissue walls are uniformly compressed and merged, ultimately producing a permanent fusion zone. The use of such sealing instruments commonly obviates the need for prior skeletonization of vessels. It is typically sufficient to grasp and compress the tissue bundle along with the vessels therein, and activate the sealing cycle. While it is technically possible to achieve bipolar sealing in vessels up to 10 mm in diameter, the method has been clinically validated and approved for vessels with a diameter of up to 7 mm.<sup>23</sup> Due caution must be exercised during and immediately after activation of the device to make sure that the instrument tip is at a safe distance from vulnerable nearby structures. Care should also be taken to prevent iatrogenic coagulation from occurring as a result of inadvertent tissue contact or when moving the instrument sideways. The latest generation of these innovative instruments combines bipolar and ultrasonic energy. Sealing can be achieved by using bipolar energy alone, or by simultaneous sealing and cutting through a combination of bipolar and ultrasonic energy. Bipolar energy is applied laterally, while ultrasonic energy is applied centrally.<sup>15</sup> The blade of the ultrasonic scalpel has been shown to reach higher peak temperatures than those produced by an insulated bipolar instrument.<sup>10</sup> In more than 90% of cases, the mean burst pressure is higher than 400 mmHg (up to 900 mmHg) and thus usually much higher than the clinically observed blood pressure values of about 130 mmHg.<sup>23,29</sup>

Histological studies revealed that standard (monopolar/bipolar) coagulation applied for hemostasis is associated with shrinkage of the vascular wall and the formation of a coagulum which occludes the vessel. Conversely, tissue fusion and vessel sealing by use of bipolar and/or ultrasonic energy is caused by denaturation of collagen and fusion of opposing layers, whereupon the elastic internal membrane, whose fibers become denatured at a temperature beyond 100 °C, is largely preserved. The lateral margin of the well-circumscribed and homogeneous coagulation zone is demarcated by a transition zone of 1–2 mm where thermal damage occurs. On immunohistochemistry, this zone is


approximately two-fold larger in width and is followed by a zone of sterile, inflammation-related resorption, particularly noticeable in the surrounding connective tissue, but without any (not even transient) signs of voids or incomplete sealing. When comparing the hemostatic properties of conventional ligature, suturing and clip application with those offered by bipolar vascular sealing, the latter has the main advantage of fast exposure, rapid and safe vessel closure, absence of foreign material in the surgical site, and lower costs. This is reflected in shorter operating times, decreased blood loss and reduced stress for the patient, which is why the use of such instruments has already become widely accepted in both open surgery and vaginal surgery (Fig. 2.70).

Some surgical situations call for a specific course of action involving some degree of physical effort and exposing the instrument to a higher level of wear and fatigue than normally incurred. The use of innovative instruments that are well-suited to cope with these tasks is very helpful in such a scenario (Figs. 2.71–2.73). The specific properties and design features of all materials and components used in the manufacturing process of vessel sealing instruments must fulfill the demands of routine and non-routine clinical applications. Manufacturing of the handle as well as the sophisticated instrument tip require the highest level of workmanship and engineering expertise. Bipolar vessel sealers must meet a wide range of criteria. Apart from core features such as superior dissection characteristics, surgeons attach great value to ergonomic handling and ease of control. The design must provide for a minimal risk of collateral thermal impact on nearby organs and should obviate the need for repeated instrument changes, the latter being considerably helpful in reducing the duration of surgery. An integrated blade mechanism that permits precise cutting through manual control adds to the versatility of the device.

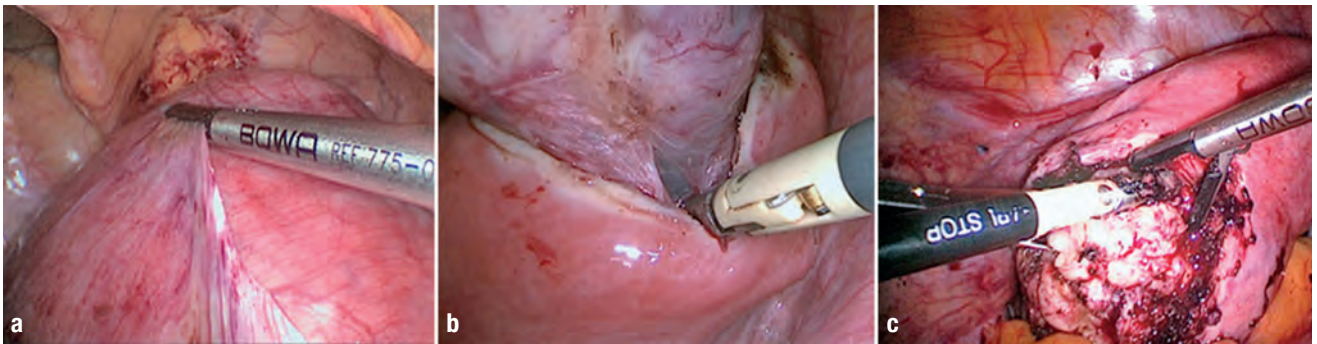
Depending upon which mode of electrical energy transfer, waveform/duty cycle, power density and current frequency is applied, either a Faradic (stimulating nerves and muscles) or thermal effect is produced. In a nutshell, the major action mechanism involves conversion of electromagnetic energy to mechanical energy, which then is converted to thermal energy by frictional forces. Alternating currents with a frequency of at least 200 kHz are used in electrosurgery, and the thermal effect is predominant. Apart from the various electrical parameters mentioned above, the impact on the tissue is further determined by exposure time and the specific impedance of tissue which, simply put, drops with increasing water content and/or rising degree of perfusion. The potential for stray currents to non-target tissue – resulting from insulation failure, capacitive coupling, and direct coupling, thereby posing the risk of iatrogenic thermal injury – is another important issue to be considered in a clinical setting (e.g., during irrigation, while employing monopolar rather than bipolar current).



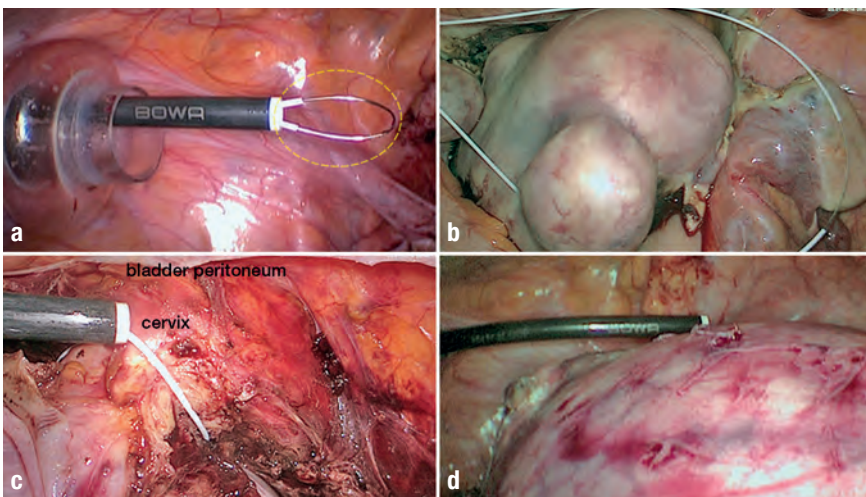
**Fig. 2.70** The ERGO 310D is a 5-mm single-use vessel-sealing instrument for permanent ligation of large-diameter vascular pedicles and tissues (BOWA-electronic GmbH & Co. KG, Gomaringen, Germany).



**Fig. 2.71** MetraLOOP monopolar electrode for supracervical hysterectomy (BOWA-electronic GmbH & Co. KG, Gomaringen, Germany).



**Fig. 2.72** The surface of the intact serosa and myometrium is coagulated and cut with a bipolar vessel sealing instrument (ERGO 310D, BOWA-electronic GmbH & Co. KG, Gomaringen, Germany) which offers the advantage of reduced lateral thermal spread and excellent coagulation properties as compared to standard bipolar systems (a). The integrated (mechanical) surgical blade allows the surgeon to coagulate and cut the target tissue (a). Commonly, the non-dominant hand (in this case, the left) is used to place traction on the myoma while using the other hand to manipulate, coagulate and cut the capsule (b). Such action is associated with high loads on the working element (in this case, controlled with the dominant hand) which bipolar instruments usually are not designed to bear (c). When faced with the need to perform traction-and-leverage maneuvers in the management of a bulky myoma, inexpensive disposable sealing instruments tend better to withstand the strain of such peak loads without the risk of breakage.



**Fig. 2.73** The MetraLOOP (BOWA-electronic GmbH & Co. KG, Gomaringen, Germany) is advanced to the operative site where the tip section of the cutting loop (broken line) is visible (a). Available in two sizes, the MetraLOOP enables the surgeon to perform laparoscopic supracervical hysterectomy (LSH) even in cases of a large uterus (b). The cutting line is above the cervix and medial to the vessel stumps (c). The tube of the outer shaft is made of glass-fiber reinforced plastic allowing even a large uterus to be mobilized upward while preventing monopolar current from getting into contact with the bowel or pelvic sidewalls (d).

## 2.3.7 Auxiliary Instruments and Application Range

### 2.3.7.1 Ultrasonic Scalpel and Bipolar Tissue Sealing Device

Johnson & Johnson (New Brunswick, NJ, USA) is among the forerunners in the development and manufacture of ultrasonic tissue sealing devices. The *Harmonic Scalpel ACE* (Ethicon Endo-Surgery Inc., Cincinnati, OH, USA) is based on advanced ultrasonic technology that allows for controlled hemostasis and cutting, making it a versatile tool in various medical fields (Fig. 2.74).

Unlike the *Harmonic Scalpel ACE* (Fig. 2.74), which now is available with a particularly slender tip making it very suitable for use in more delicate operative steps, the *EnSeal® G2 Articulating Tissue Sealer* (Ethicon Endo-Surgery Inc.) (Fig. 2.75) combines mechanical pressure with the application of bipolar energy. Moreover, it is equipped with a deflectable tip section that enables a perpendicular approach to vessels, offering improved access to tissue in deep or tight spaces, as well as in single-port surgery.

### 2.3.7.2 TachoSil® Hemostatic Patch

In today's clinical practice, the adjunctive use of auxiliary medical substances such as hemostatic agents has become widely accepted, particularly in the field of laparoscopy, considering that prolonged active compression is not feasible by wearing an elastic postsurgical belt in the abdominal area. The use of auxiliary substances is strongly linked with patient safety. Any surgeon should be fully aware of the potential hazards arising from the use of electrical energy and must make sure that adequate safety precautions and due restraint is exercised in the proximity of vulnerable structures and organs (close to the ureter or bowel). When faced with the need for rapid and reliable bleeding control and tissue sealing in such areas, surgeons frequently resort to the adjunctive use of surgical patches such as TachoSil® (Takeda Pharmaceutical Company Ltd., Osaka, Japan) (Fig. 2.76). Hemostatic patches developed specifically for use in laparoscopic procedures are introduced and applied easily while providing additional protection and safety for the patient (Figs. 2.77–2.78).

### 2.3.7.3 Barrier Substances

In gynecological operations performed for benign indications, a major cause for operative therapy is the presence of adhesions or the need for managing sequelae of prior surgery. In order to minimize the risk of adhesion formation, the surgeon can choose from a variety of barrier substances, available either in the form of fluid formulations, such as liquids or gels (e.g., hyaluronic acid) (Fig. 2.79), or in the form of powder.

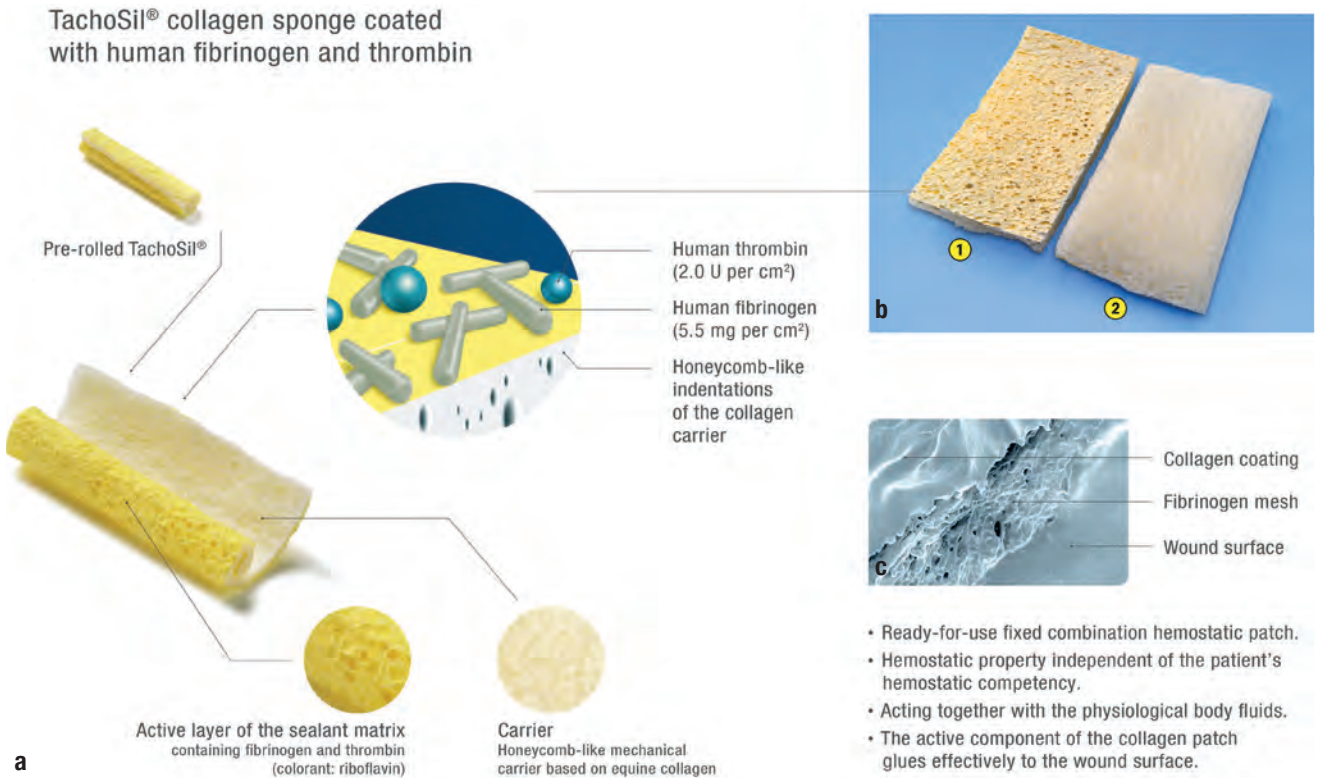


**Fig. 2.74** *Harmonic Scalpel ACE* (Johnson & Johnson/Ethicon). Shown on the insert image is the isolated upper jaw and the vibrating lower jaw where heat is generated.

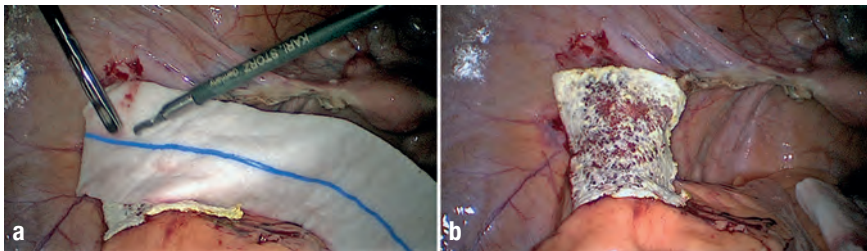


**Fig. 2.75** *EnSeal Articulating Tissue Sealer* with deflectable tip section (Johnson & Johnson/Ethicon).

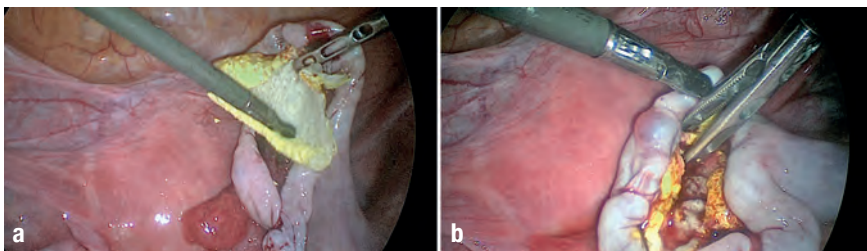




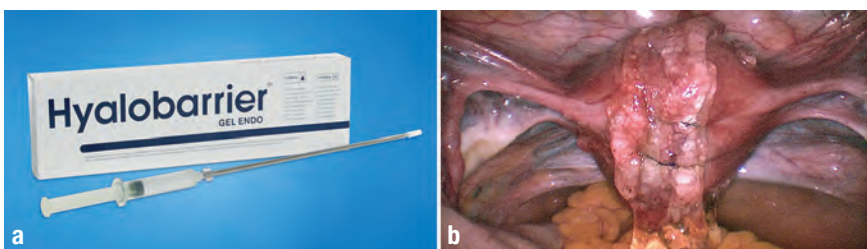
**Fig. 2.76** Schematic diagram showing the components of the TachoSil® hemostatic patch (Takeda Pharmaceutical Company Ltd., Osaka, Japan) (a). The active layer of the classical TachoSil® patch, noticeable by its distinct yellow appearance, is oriented upwards (①) while in the adjacent patch (②), the carrier component is on top (b). Scanning electron microscopy appearance (c) of a TachoSil® patch demonstrating the coating of the human plasma components (fibrinogen/thrombin) which are anchored to the honeycomb-like indentations of the collagen carrier. The deposition of fibrin clots resulting from the active components of the sealant matrix causes hemostasis and conglutination of the TachoSil® patch to the wound surface.



**Fig. 2.77** Intraoperative view taken during laparoscopic application of TachoSil® patch (a) on the pelvic wall. A moistened gauze pad (b) is used to lightly press the patch onto the area of minor bleeding until the tissue surface is fully saturated.



**Fig. 2.78** Following removal of the endometrium, TachoSil® is applied to the ovary. Hemostasis is achieved while avoiding the risk of thermal injury to follicles, the latter being potentially associated with the use of electrocautery.



**Fig. 2.79** Hyalobarrier® (Nordic Pharma GmbH, Switzerland) (a) is a hyaluronic acid-based gel for open intrauterine and laparoscopic application for the prevention of adhesion formation. Intraoperative use of Hyalobarrier® after myoma enucleation (b).

### 2.3.8 References

1. ALKATOUT I, EGBERTS JH, METTLER L, DONIEC M, WEDEL T, JUNEMANN KP et al. Interdisciplinary Diagnosis and Treatment of Deep Infiltrating Endometriosis. *Zentralbl Chir* 2015. doi:10.1055/s-0034-1383272.
2. ALKATOUT I, METTLER L, GUNTHER V, MAASS N, ECKMANN-SCHOLZ C, ELESSAWY M et al. Safety and economical innovations regarding surgical treatment of fibroids. *Minim Invasive Ther Allied Technol* 2016;25(6):301–13. doi:10.1080/13645706.2016.1190380.
3. ALKATOUT I, METTLER L, MAASS N, NOÉ GK, ELESSAWY M. Abdominal anatomy in the context of port placement and trocars. *J Turkish German Gynecol Assoc* 2015;16(4):241–51. doi:10.5152/jtga.
4. ALKATOUT I, SCHOLLMEYER T, HAWALDAR NA, SHARMA N, METTLER L. Principles and safety measures of electrosurgery in laparoscopy. *JLS* 2012;16(1):130–9. doi:10.4293/108680812X13291597716348.
5. AZZIZ R, STEINKAMPF MP, MURPHY A. Postoperative recuperation: relation to the extent of endoscopic surgery. *Fertil Steril* 1989;51(6):1061–4.
6. BITTNER JG, AWAD MM, VARELA JE. Laparoscopic Hemostasis: Energy Sources. In: Soper NJ, Scott-Conner CE, editors. *The SAGES Manual: Volume 1 Basic Laparoscopy and Endoscopy*, 3rd ed. New York, NY: Springer New York; 2012. p. 105–20. (ISBN No. 9781461423430).
7. BOGDANOVA R, BOULANGER P, ZHENG B. Depth Perception of Surgeons in Minimally Invasive Surgery. *Surg Innov* 2016;23(5): 515–24. doi:10.1177/1553350616639141.
8. BRILL AI, GOMEL V (EDS.). *Reconstructive and reproductive surgery in gynecology*. London, New York: Informa Healthcare; 2010. (ISBN No. 9781841847573).
9. CHEN YJ, WANG PH, OCAMPO EJ, TWU NF, YEN MS, CHAO KC. Single-port compared with conventional laparoscopic-assisted vaginal hysterectomy: a randomized controlled trial. *Obstet Gynecol* 2011;117(4):906–12. doi:10.1097/AOG.0b013e31820c666a.
10. EMAM TA, CUSCHIERI A. How safe is high-power ultrasonic dissection? *Ann Surg* 2003;237(2):186–91. doi:10.1097/01.SLA.0000048454.11276.62.
11. EMAM TA, HANNA G, CUSCHIERI A. Ergonomic principles of task alignment, visual display, and direction of execution of laparoscopic bowel suturing. *Surg Endosc* 2002;16(2):267–71. doi:10.1007/s00464-001-8152-4.
12. FAGOTTI A, BOTTONI C, VIZZIELLI G, GUELI AS, SCAMBIA G, MARANA E et al. Postoperative pain after conventional laparoscopy and laparoendoscopic single site surgery (LESS) for benign adnexal disease: a randomized trial. *Fertil Steril* 2011;96(1):255–259.e2. doi:10.1016/j.fertnstert.2011.04.006.
13. FONG Y, GIULIANOTTI PC, LEWIS J, GROOT KOERKAMP B, REINER T. *Imaging and Visualization in The Modern Operating Room*. New York, NY: Springer New York; 2015. (ISBN No. 978-1-4939-2325-0).
14. HANNA GB, SHIMI SM, CUSCHIERI A. Task performance in endoscopic surgery is influenced by location of the image display. *Ann Surg* 1998;227(4):481–4.
15. JONES HW, ROCK JA. *Te Linde's operative gynecology*. 11th ed. Philadelphia: Wolters Kluwer; 2015. (ISBN No. 1451177364).
16. KELLING G. Die Tamponade der Bauchhöhle mit Luft zur Stillung lebensgefährlicher Intestinalblutungen. *Münch Med Wochenschr* 1901;48:1480–1483; 1535–1538.
17. KRAMME R. *Medizintechnik: Verfahren – Systeme – Informationsverarbeitung*. 4th ed. Berlin, Heidelberg: Springer-Verlag Berlin Heidelberg; 2011. (ISBN No. 978-3-642-16186-5).
18. METTLER L, CLEVIN L, TERNAMIAN A, PUNTAMBEKAR S, SCHOLLMEYER T, ALKATOUT I. The past, present and future of minimally invasive endoscopy in gynecology: A review and speculative outlook. *Minimally Invasive Therapy & Allied Technologies* 2013;22(4):210–26. doi:10.3109/13645706.2013.823451.
19. METTLER L, ECKMANN-SCHOLZ C, SEMM I, ALKATOUT I. Factors to consider in gynecological surgery. *Womens Health (Lond Engl)* 2014;10(3):323–38. doi:10.2217/whe.14.10.
20. METTLER L, SCHOLLMEYER T, ALKATOUT I. Adhesions during and after surgical procedures, their prevention and impact on women's health. *Womens Health (Lond Engl)* 2012;8(5):495–8. doi:10.2217/whe.12.34.
21. MUNRO MG. *Fundamentals of Electrosurgery: Part I: Principles of Radiofrequency Energy for Surgery*. Chapt. 2. In: Feldman L, Fuchshuber P, Jones DB, editors. *The SAGES Manual on the Fundamental Use of Surgical Energy (FUSE)*. Boston, MA: Springer US; 2012. p. 15–59. (ISBN No. 978-1-4614-2073-6).
22. PALMER R. Safety in laparoscopy. *J Reprod Med* 1974;13(1):1–5.
23. PARK CW, PORTENIER DD. Bipolar Electrosurgical Devices. Chapt. 5. In: Feldman L, Fuchshuber P, Jones DB, editors. *The SAGES Manual on the Fundamental Use of Surgical Energy (FUSE)*. Boston, MA: Springer US; 2012. p. 93–106. (ISBN No. 978-1-4614-2073-6).
24. SCHOLLMEYER T, SOYINKA AS, SCHOLLMEYER M, MEINHOLD-HEERLEIN I. Georg Kelling (1866–1945): the root of modern day minimal invasive surgery. A forgotten legend? *Arch Gynecol Obstet* 2007;276(5):505–9. doi:10.1007/s00404-007-0372-y.
25. SEMM K. Hysterectomy via laparotomy or pelviscopy. A new CASH method without colpotomy. *Geburtshilfe Frauenheilkd* 1991;51(12):996–1003. doi:10.1055/s-2008-1026252.
26. SPANER SJ, WARNOCK GL. A brief history of endoscopy, laparoscopy, and laparoscopic surgery. *J Laparoendosc Adv Surg Tech A* 1997;7(6):369–73.
27. STELLATO TA. History of laparoscopic surgery. *Surg Clin North Am* 1992;72(5):997–1002.
28. TERNAMIAN AM. How to improve laparoscopic access safety: ENDOTIP. *Minim Invasive Ther Allied Technol* 2001;10(1):31–9. doi:10.1080/13645700152598897.
29. TIMM RW, ASHER RM, TELLIO KR, WELLING AL, CLYMER JW, AMARAL JF. Sealing vessels up to 7 mm in diameter solely with ultrasonic technology. *Med Devices (Auckl)* 2014;7:263–71. doi:10.2147/MDER.S66848.
30. TINELLI A, METTLER L, MALVASI A, HURST B, CATHERINO W, MYNBAEV OA et al. Impact of surgical approach on blood loss during intracapsular myomectomy. *Minim Invasive Ther Allied Technol* 2014;23(2):87–95. doi:10.3109/13645706.2013.839951.
31. VAN DET MJ, MEIJERINK WJ, HOFF C, TOTTE ER, PIERIE JP. Optimal ergonomics for laparoscopic surgery in minimally invasive surgery suites: a review and guidelines. *Surg Endosc* 2009;23(6):1279–85. doi:10.1007/s00464-008-0148-x.
32. VERESS J. Neues Instrument zur Ausführung von Brust- oder Bauchpunktionen und Pneumothoraxbehandlung. *Dtsch med Wochenschr* 1938;64(41):1480–1. doi:10.1055/s-0028-1123401.

## 2.4

## Diagnostic Imaging of Endometriosis

Simone Schrading<sup>a</sup>

## 2.4.1 Introduction

The current definitive method for diagnosing and staging endometriosis and evaluating the recurrence of disease after treatment is laparoscopy. Imaging techniques have improved significantly in the last decade, however, and have contributed greatly to the preoperative workup of endometriosis. Current nonsurgical diagnostic options are transvaginal sonography, barium enema, contrast-enhanced computed tomography (CT), and magnetic resonance imaging (MRI). Because of its low cost and wide availability, transvaginal sonography is the initial imaging study used to diagnose endometriosis. But with the advent of high-contrast, high-resolution MRI techniques using high-field systems, MRI has become an accurate modality in the diagnosis of endometriosis. MRI is extremely helpful in evaluating endometriomas. It can detect deep infiltrating endometriosis of the pelvis, even in patients with inconclusive ultrasound findings.<sup>30,57</sup>

Conventional tests such as barium enema, intravenous urography, and contrast-enhanced CT usually give equivocal results in diagnosing endometriosis. Their use is limited in current practice due to radiation exposure concerns. Thus, conventional imaging and CT are not recommended for the detection and staging of endometriosis.<sup>50</sup>

Below, we shall discuss the utilization and accuracy of MRI for the detection and staging of ovarian endometriomas and deep infiltrating endometriosis. We will then explore the characteristic MRI features of various typical and atypical forms of endometriosis.

## 2.4.2 Role of MRI in the Detection and Staging of Endometriosis

## 2.4.2.1 MRI Technique

MRI of the pelvis to detect endometriosis employs high-field MRI scanners with field strengths of 1.5 and 3 Tesla. Multi-element surface coils are used. The patient is scanned in the supine or prone position. Antiperistaltic medication is usually administered to suppress bowel motility and minimize motion-related artifacts.

The imaging protocol should include a combination of T1- and T2-weighted sequences (Table 2.5). High spatial resolution and high-contrast sequences are essential to ensure that even small lesions are detected (Fig. 2.80). Intravenous contrast administration (gadolinium) and *diffusion-weighted imaging* (DWI) have not shown any advantage over plain MRI with

Sequence	T2-TSE	T2-TSE	T2-TSE	T1-TSE precontrast with fat suppression	DWI	T1-TSE pre- and post- contrast
Orientation	axial	sagittal	coronal	axial	axial	axial
TE (ms)	120	120	120	8	62	1.96
TR (ms)	4922	4914	4914	542	2578	5.5
FOV (mm)	300	300	300	300	210	262
Acquisition matrix	656	656	656	512	144	256
Voxel size (mm <sup>3</sup> )	0.45 x 0.45 x 3.0	0.45 x 0.45 x 3.0	0.45 x 0.45 x 3.0	0.58 x 0.58 x 3.0	1.35 x 1.36 x 3.0	1.02 x 1.02 x 6.0
b values	n.a.	n.a.	n.a.	n.a.	0, 800, 1000, 1400	n.a.
Contrast agent	n.a.	n.a.	n.a.	n.a.	n.a.	0.1 mmol/kg body weight gadobutrol
Acquisition time (min:sec)	04:20	05:04	04:34	04:26	04:05	08:35

**Table 2.5** MRI protocol for endometriosis.

Key to acronyms: *Echo time* (TE); *repetition time* (TR); *turbo spin echo* (TSE); *diffusion-weighted magnetic resonance imaging* (DWI); *field of view* (FOW); *not available* (n.a.).

<sup>a</sup> Assoc. Professor, MD; Department of Diagnostic and Interventional Radiology, Medical University of the RWTH Aachen, Germany

## Corresponding author:

Priv.-Doz. Dr. med. **Simone Schrading**

Universitätsklinikum RWTH Aachen

Klinik für Diagnostische und Interventionelle Radiologie

Pauwelsstr. 30, 52074 Aachen, Germany

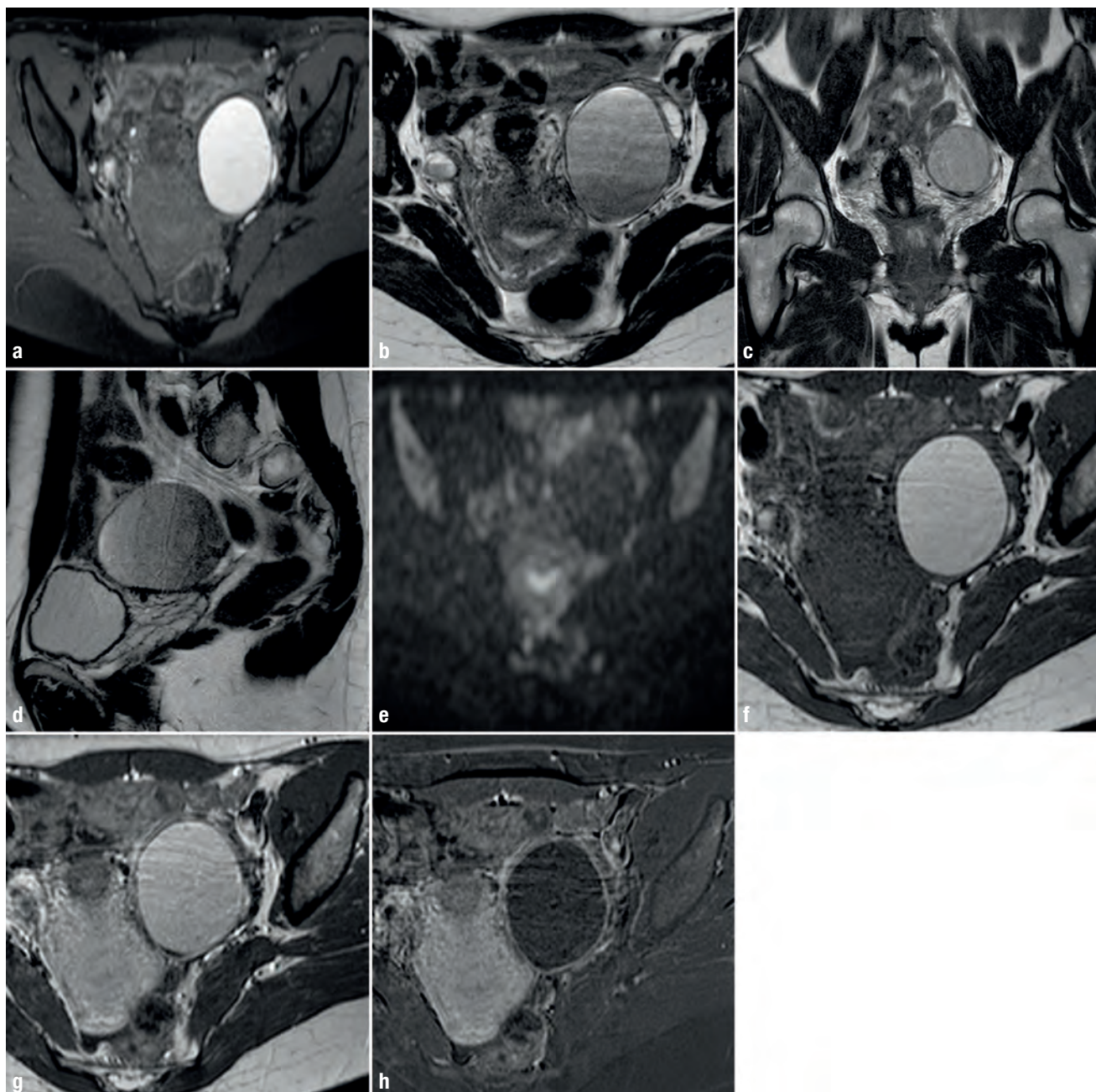
E-mail: sschrading@ukaachen.de



high-contrast, high-resolution T2-weighted and unenhanced T1-weighted sequences in the detection of endometriosis.<sup>37,51</sup> Intravenous contrast medium and DWI are recommended when malignancy is suspected, however.

The signal intensity of endometriosis lesions on MRI depends on their content of proteins and blood breakdown products. Acute hemorrhage gives a hypointense (dark) signal on T1- and T2-weighted images. By contrast, lesions containing degraded blood products like methemoglobin, proteins, and iron are hyperintense (bright) on T1-weighted images and hypointense on T2-weighted images.

Because fatty tissue also has high T1-weighted signal intensity, T1-weighted images are routinely acquired using fat-suppressed sequences. There are two reasons for this.<sup>4,45</sup> First, the loss of signal intensity within a T1-hyperintense adnexal mass in fat-suppressed sequences allows the mass to be characterized as a mature cystic teratoma. Second, elimination of the high signal intensity of fat enhances contrast with non-fat-containing T1-hyperintense structures. This in turn enables the sensitive detection of smaller, hyperintense endometrial lesions in T1-weighted images. Accordingly, precontrast fat-suppressed T1-weighted images are the most important sequences for diagnosing endometriosis. They should always be part of the MRI protocol (Fig. 2.80a).



**Fig. 2.80** Axial T1-weighted turbo spin echo (TSE) sequence with fat saturation (a). Axial T2-weighted TSE sequence (b). Coronal T2-weighted TSE sequence (c). Sagittal T2-weighted TSE sequence (d). Axial diffusion-weighted sequence (e). Axial T1-weighted TSE sequence before contrast administration (f). Axial T1-weighted TSE sequence after contrast administration (g) and subtraction image (h).

### 2.4.2.2 MR Imaging of Ovarian Endometriosis (Endometriomas)

Endometriomas are frequently diagnosed with transvaginal ultrasound. MRI is performed to exclude malignancy whenever sonographic features of ovarian masses are indeterminate.<sup>69</sup> Due to cyclic bleeding, endometriomas contain blood products of varying age. The typical diagnostic MRI appearance of endometriomas is an ovarian lesion with high signal intensity in both T1- and T2-weighted sequences that persists in subsequent fat-suppressed T1-weighted images<sup>42</sup> (Fig. 2.80). Fat suppression is mandatory as it helps differentiate endometriomas from cystic teratomas. Teratomas, because they contain fat, show a partial loss of signal intensity in fat-suppressed sequences.<sup>43</sup>

#### ■ Clinical Case 1

**MRI Protocol for Endometriosis.** Typical endometrioma of the left ovary in a 38-year-old woman. The endometrioma shows typical high signal intensity in T1-weighted images (Fig. 2.80a,f–h) and subtle shading in T2-weighted images (Fig. 2.80b,d). The lesion does not show restricted diffusion (Fig. 2.80e) or suspicious contrast enhancement (Figs. 2.80f–h).

Another MRI feature of endometriomas is the presence of cystic masses with high signal intensity on T1-weighted images and loss of signal intensity on T2-weighted images. This phenomenon, called “*shading*”, is due to a high concentration of protein and iron from recurrent hemorrhage within the endometrioma<sup>21,36</sup> (Fig. 2.81a–f). It can range from

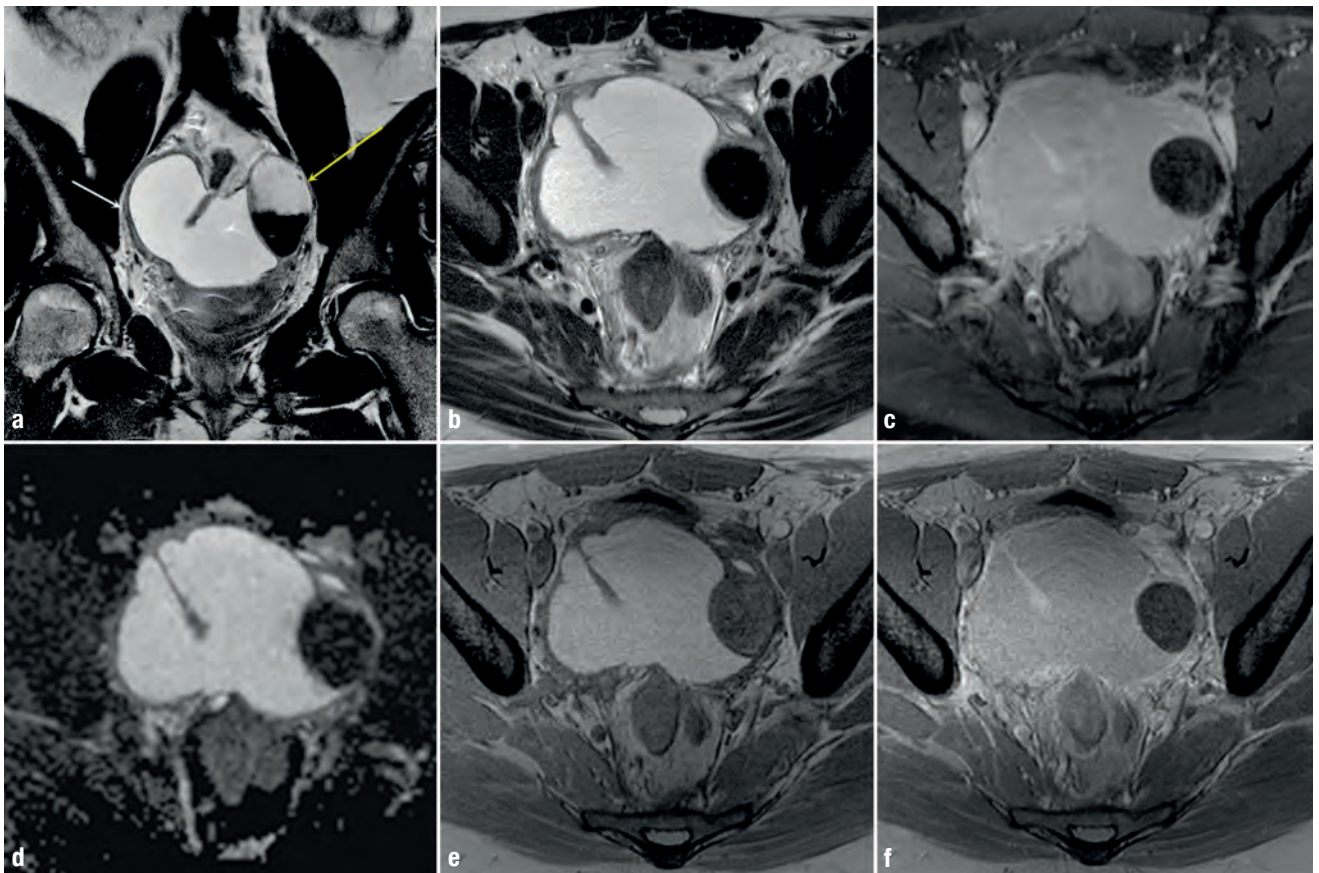
subtle layering to a complete signal void (black). This specific feature helps to differentiate endometriomas from functional hemorrhagic cysts, as the latter do not exhibit shading. Instead they are mostly unilocular and resolve on follow-up imaging.

#### ■ Clinical Case 2

**Endometrioma (“Shading”).** Typical endometrioma of the left ovary in a 41-year-old woman. The endometrioma shows typical shading on T2-weighted images (yellow arrow, Fig. 2.81a–c), no restricted diffusion (Fig. 2.81e) and no suspicious enhancement (Fig. 2.81f). A mucinous cystadenoma of the left ovary has high signal intensity on T1- and T2-weighted images (white arrow).

Through the use of typical diagnostic criteria such as T1-hyperintense cysts with T2 shading or multiple T1-hyperintense cysts regardless of T2 signal intensity, MRI has been shown to provide sensitivity and specificity levels of 90% and 98%, respectively, for the definitive diagnoses of endometriomas.<sup>32,52</sup>

When atypical features of endometriomas are present, the primary purpose of MRI is to exclude malignancy. Typical signs of malignancy are solid components and localized wall thickening within the cyst. Because intense enhancement of the solid components in postcontrast T1-weighted sequences is strongly suggestive of malignancy, the use of intravenous contrast medium is mandatory.



**Fig. 2.81** Coronal T2-weighted TSE sequence (a). Axial T2-weighted TSE sequence (b). Axial T1-weighted TSE sequence with fat saturation (c). Axial diffusion-weighted sequence (d). Axial T1-weighted gradient echo sequence before contrast administration (e). Axial T1-weighted gradient echo sequence after contrast administration (f).



### 2.4.2.3 MR Imaging of Deep Infiltrating Endometriosis

From 15% to 30% of endometriosis patients may have deep infiltrating endometriosis.<sup>55,66</sup> The most common regions involved by deep infiltrating endometriosis are, in descending order of frequency, the uterosacral ligaments, rectosigmoid colon, and the vagina or bladder.<sup>18,55,65</sup>

Deep infiltrating endometriosis is a challenging diagnosis because symptoms are often nonspecific and vaginal examination does not disclose abnormalities in many affected patients.<sup>14,16</sup> Several studies of deep infiltrating endometriosis document a significant improvement of symptoms after laparoscopic eradication of all visible implants.<sup>28,40</sup> Precise preoperative imaging of the location and extent of lesions is essential, therefore, in order to direct treatment planning and aid selection of the most suitable procedure.

The main indication for MRI is for detecting and staging the various manifestations of deep infiltrating endometriosis. Sonography provides relatively low sensitivity for the same purpose, and it is often difficult for clinical and laparoscopic examination to identify subperitoneal lesions.<sup>1,10</sup>

Solid lesions of deep infiltrating endometriosis show uniform low signal intensity on T2-weighted images and low to intermediate signal intensity on T1-weighted images, with interspersed punctate areas of high signal intensity<sup>29</sup> (Fig. 2.82). The high-signal areas are foci of hemorrhage surrounded by solid fibrous tissue. These findings can mimic metastatic lesions arising from intraperitoneal malignancies such as ovarian carcinoma. The two entities can be differentiated by the low T2-weighted signal intensity of endometriotic lesions, which are often associated with endometrial cysts.

#### ■ Clinical Case 3

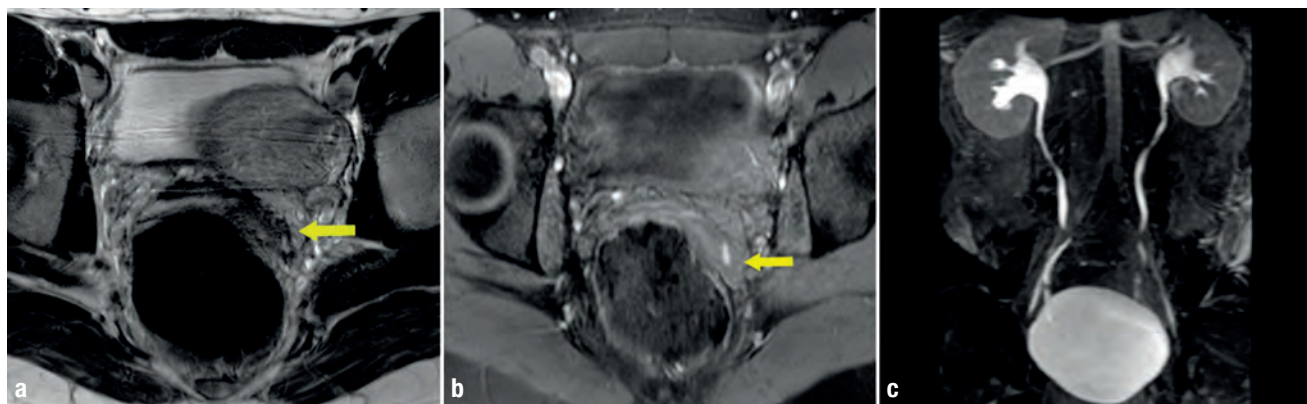**Deep infiltrating endometriosis** in a 40-year-old woman. Manifestation of deep infiltrating endometriosis in the cul-de-sac (yellow arrow) with typical low signal in the T2-weighted image (Fig. 2.82a) and hyperintense foci in the fat-saturated T1-weighted image (Fig. 2.82b). Ureteral compression was excluded by MR urography (Fig. 2.82c).

Endometriosis lesions located in the cul-de-sac, posterior vaginal fornix, and uterosacral ligaments may contain a large proportion of glandular material with little fibrotic reaction. This produces moderately high signal intensity in T2-weighted images. Frequently the signal intensity may be insufficient to reveal deep endometriosis in the uterosacral ligaments, especially if punctate hemorrhagic foci are absent in the lesion. In such cases the diagnosis is often based on thickening of the ligaments. Bilateral or asymmetric thickening of the ligaments to more than 9 mm, especially when nodular thickening is present, is considered diagnostic for endometriosis of the uterosacral ligaments on MRI.

MRI is reported to have a sensitivity of 76–86% and a specificity greater than 90% for the diagnosis of uterosacral ligament endometriosis.<sup>1,6,7,29</sup> MRI was more accurate than either endovaginal or endorectal ultrasound according to one study.<sup>1</sup>

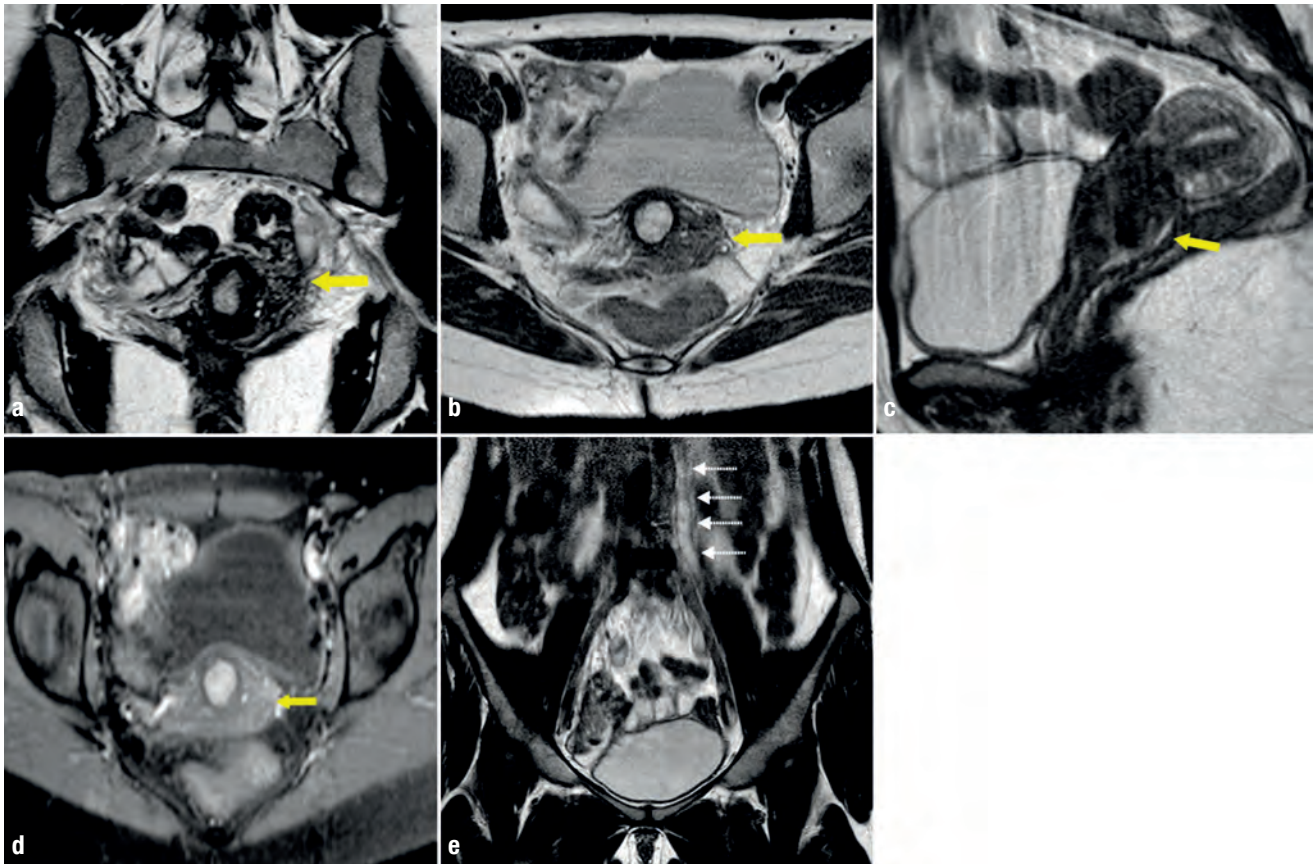
Lesions in the cul-de-sac are typically isointense to myometrium on T2-weighted images. Approximation of the anterior rectal wall may be due to adhesion between the cul-de-sac nodule and the rectal serosa. Or it may be due to direct extension with invasion of the muscle at the rectosigmoid junction (Fig. 2.84). MRI has a reported sensitivity of 83% in diagnosing deep endometriosis of the cul-de-sac.<sup>6,7</sup>

Endometriosis of the vagina is usually diagnosed on physical examination.<sup>23</sup> The sensitivity of ultrasound is reported to be as low as 29%.<sup>23</sup> The difficulty arises from the configuration of endovaginal probes with the receiver oriented toward the vaginal fornix. Vaginal lesions are problematic not only in terms of diagnosis but also in choosing the appropriate surgical option. An imaging modality that can accurately display the location, extent, and infiltration of vaginal lesions is of key importance, therefore. MRI has been described as achieving a sensitivity of 80% and a specificity of 93%.<sup>9,22,23</sup> The MRI features of vaginal endometriosis are similar to those found at other sites: low signal intensity on T2-weighted images and variable signal intensity at T1-weighted images. Most patients with vaginal involvement also show obliteration of the cul-de-sac. MRI has therefore become the ideal complement to ultrasound and physical examination for evaluating the upward and posterior extension of endometriosis lesions.



**Fig. 2.82** Axial T2-weighted TSE sequence (a). Axial T1-weighted TSE sequence with fat saturation (b). MR urography (c).





**Fig. 2.83** Coronal T2-weighted TSE sequence (a). Axial T2-weighted TSE sequence (b). Sagittal T2-weighted TSE sequence (c). Axial T1-weighted TSE sequence with fat saturation (d). Coronal T2-weighted TSE sequence (e).

#### 2.4.2.4 MR Imaging of Urinary Tract Endometriosis

Bladder lesions develop in approximately 6% of patients with endometriosis.<sup>2,23,31,44</sup> The lesions of bladder endometriosis are predominantly located anterior to the vesicouterine pouch. The lesions appear on T2-weighted MRI as isointense, often heterogeneous areas of bladder wall thickening with irregular margins and frequent T1-hyperintense spots.<sup>33,56</sup> Contrast-enhanced MRI can depict small endometriotic lesions within the bladder wall because lesions show greater enhancement than the unaffected portion of the detrusor. Sensitivity, specificity, and accuracy of MRI in diagnosing bladder endometriosis have been reported at 88%, 99%, and 98%, respectively.<sup>33</sup>

An important surgical question concerns possible involvement of the distal ureter requiring ureteral reimplantation at the time of operation. Direct invasion of the muscularis and lamina propria by local extension from other sites of deep endometriosis, such as the uterosacral ligaments of the ureter, can cause dilatation and obstruction. But ureteral obstruction is more often due to extrinsic compression by large endometriomas than by direct ureteral invasion (Fig. 2.83).

#### ■ Clinical Case 4

**Deep infiltrating endometriosis with ureteral compression** in a 39-year-old woman. Deep infiltrating endometriosis of the cul-de-sac (yellow arrow) shows typical low signal intensity

on T2-weighted images (Fig. 2.83a–c). Focal hyperintense lesions are seen in the fat-saturated T1-weighted image (Fig. 2.83d). Associated compression and dilatation of the left ureter (Fig. 2.83e) is clearly demonstrated by MRI (dotted white arrows).

The clinical and imaging context of other sites of pelvic endometriosis help to suggest ureteral involvement. Direct ureteral endometriosis is detectable in T2-weighted sequences. The most frequent presentation of ureteral endometriosis is a hypointense nodule associated with hyperintense foci close to the ureter in both T2- and T1-weighted sequences. Infiltration of the ureter may be suspected when the fat plane between the nodule and ureter is no longer visible in T2-weighted sequences.

Ureterohydronephrosis is easily detected by MR urography using 2D T2-weighted sequences or delayed contrast-enhanced 3D sequences with higher spatial resolution (Fig. 2.82c). With its ability to define all portions of the urinary tract and explore all pelvic sites of endometriosis in the same examination, MRI provides an ideal all-in-one approach for patients with suspected urinary tract endometriosis.

#### 2.4.2.5 MR Imaging of Bowel Endometriosis

Intestinal endometriosis occurs in 4% to 37% of patients with deep infiltrating endometriosis. The rectosigmoid colon is affected in 85% of cases, followed by the distal ileum, appendix, and cecum.<sup>48</sup> The lesions invade the serosa, subserosa, and muscularis propria, which respond with hypertrophy and fibrosis.

Various imaging techniques have been proposed to diagnose intestinal involvement by endometriosis.

Transabdominal, transrectal, and transvaginal sonographic approaches have been described. A comparative study of transrectal and transvaginal sonography in patients with clinical suspicion of posterior endometriosis yielded equivalent results, with a sensitivity of 84% and a specificity of 99%.<sup>8</sup>

Several studies have shown that MRI provides a sensitivity of 84–93% and specificity of 99% in patients with intestinal involvement by endometriosis.<sup>15,46,53,62,67</sup>

Diagnostic criteria for rectal invasion by endometriosis at MRI include colorectal wall thickening with anterior triangular distortion of the rectum or asymmetric thickening of the lower surface of the sigmoid wall (Fig. 2.84). However, bowel thickening alone may be due to peristaltic contraction and should not be interpreted as an endometriotic lesion. A few studies have shown improved discrimination of the endometriotic lesion from the normal rectal wall after intravenous contrast injection.<sup>62</sup>

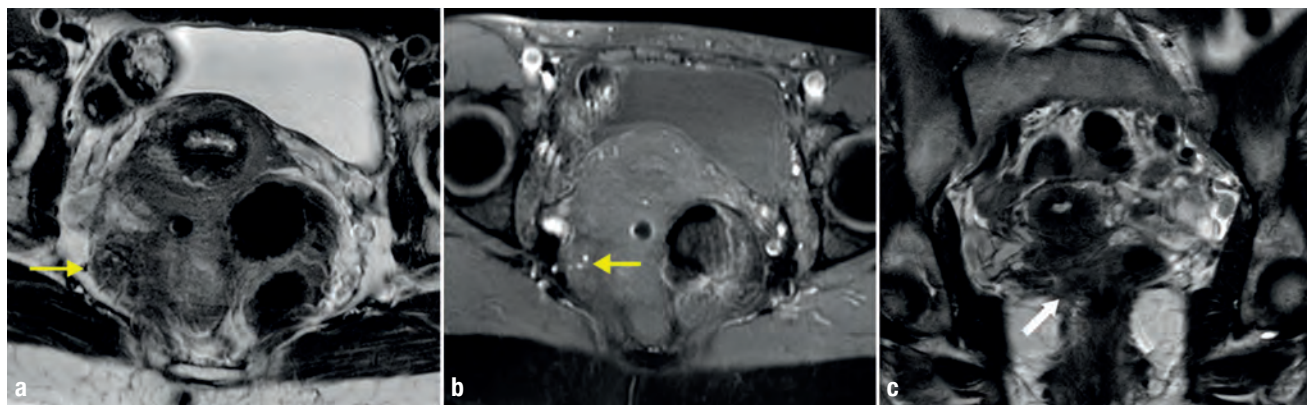
#### ■ Clinical Case 5

**Deep infiltrating endometriosis with bowel involvement** in a 41-year-old woman (yellow arrows). Images show rectal infiltration by endometriosis with associated thickening of the rectal wall (white arrow, Fig. 2.84c).

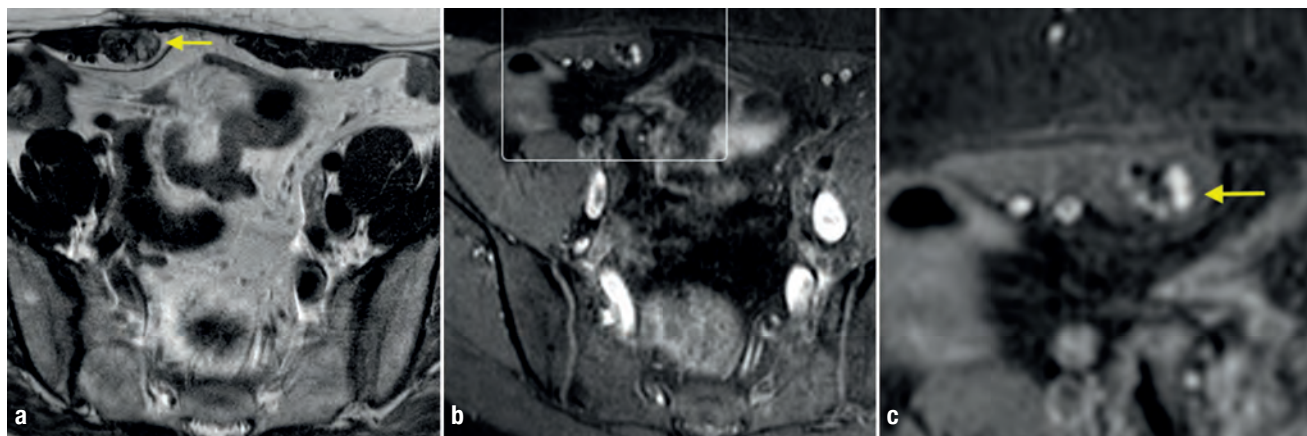
Reported comparisons of MRI with rectal endoscopic sonography indicate a similar sensitivity for both modalities.<sup>15,46,62</sup> But since isolated, focal bowel lesions are reportedly found in fewer than 21% of women with intestinal involvement, the ideal imaging study should at least be able to cover the entire pelvis so that all associated lesions are diagnosed. MRI appears to be the modality of choice for detecting all possible sites of endometriosis extension, and therefore it appears to be superior to transrectal sonography in clinical practice.

One difficulty is that neither pelvic MRI nor sonography can detect lesions located outside the field of view. Lesions of the sigmoid, right-sided bowel, and especially the ileum are often missed by sonography and standard pelvic MRI.

Endometriotic lesions of the small bowel are most commonly identified in the last 10 cm of ileum. Radiographic findings from enteroclysis, small-bowel follow-through or double-contrast barium enema are usually nonspecific and demonstrate an extrinsic mass effect or tethering.<sup>34,54</sup> The diagnosis of terminal ileal endometriosis has been described using a combination of CT and colon enteroclysis.<sup>12</sup> This technique is



**Fig. 2.84** Axial T2-weighted TSE sequence (a). Axial T1-weighted TSE sequence with fat saturation (b). Sagittal T2-weighted TSE sequence (c).



**Fig. 2.85** Axial T2-weighted TSE sequence (a). Axial T1-weighted TSE sequence with fat saturation (b). Magnified view of the lesion (c).



invasive, however, and requires ionizing radiation, which is a serious disadvantage particularly in young patients.

A promising technique for diagnosing small-bowel endometrial lesions is MR enterography. This study employs antegrade (oral) contrast administration to opacify the bowel. The entire abdomen including all intestinal structures are imaged. MR enterography is widely used to explore small bowel and ileocecal diseases, especially in patients with chronic inflammatory bowel disease.<sup>3,35</sup> Initial experience with MR enterography in patients with small bowel endometriosis indicated a 100% positive predictive value in the diagnosis of endometrial bowel lesions located above the rectosigmoid junction.<sup>49</sup>

#### 2.4.2.6 MR Imaging of Endometrioses at Other Sites

Ectopic endometrial glands and stroma can develop at sites of previous gynecologic surgery, e.g., at scars from a prior caesarian section or laparoscopy, or they may develop spontaneously within the abdominal wall at the recti abdomini.<sup>5,20,25</sup> With MRI, sites of abdominal wall involvement are easily identified in T1-weighted fat-suppressed images as hyperintense spots within the abdominal wall (Fig. 2.85). Nodules may be hidden in T2-weighted images because they are isointense to muscle.

#### ■ Clinical Case 6

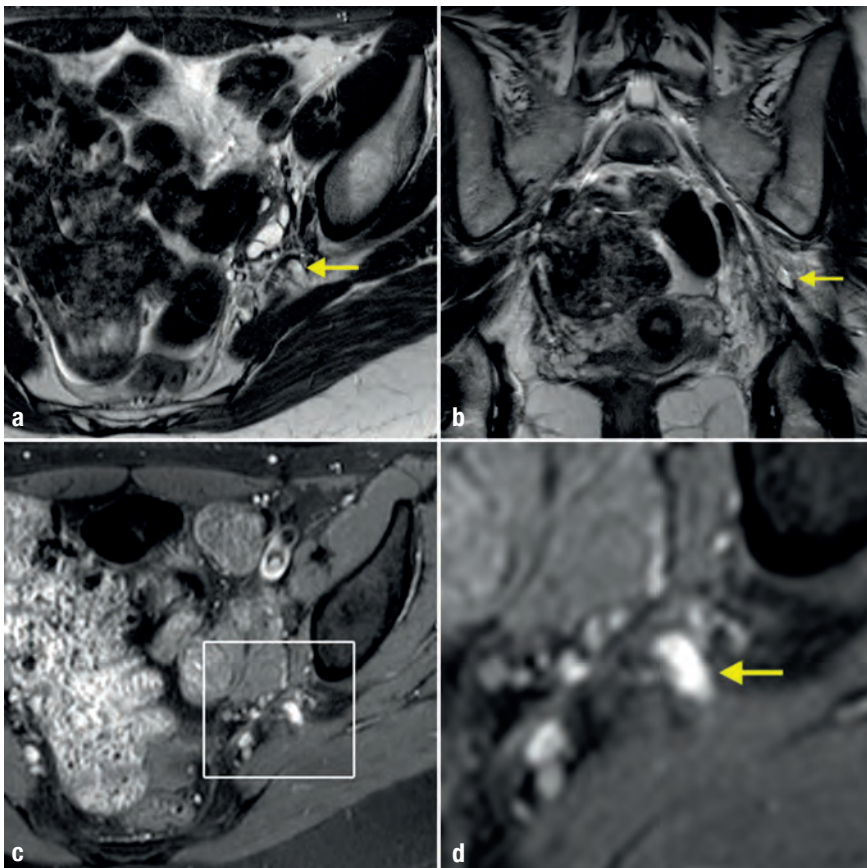
**Endometriosis of the rectus abdominis** in a 39-year-old woman. Endometriosis of the right rectus abdominis (arrow) shows moderately high signal intensity on T2-weighted images (Fig. 2.85a) and focal hyperintensity on T1-weighted images (Figs. 2.85b, c).

Other sub- or retroperitoneal sites of involvement by endometriosis have been described including the ischioanal fossa, sciatic nerve (Fig. 2.86), round ligament, and lymph nodes.<sup>27,61,64</sup> Other rare lesion sites are the inguinal canal (Fig. 2.87) and vulva. All of these lesions show imaging features identical to those seen in deep infiltrating endometriosis.

Sites of involvement on the surface of the liver or within the chest are very rare and are usually diagnosed by CT.<sup>24,26</sup>

#### ■ Clinical Case 7

**Endometriosis in contact with the left sciatic nerve** of a 33-year-old woman with left leg pain. Endometriosis in the left ischioanal fossa has caused compression of the left sciatic nerve (arrow). The endometriosis lesion shows typical high signal intensity on T2-weighted (Figs. 2.86a, b) and T1-weighted images (Figs. 2.86c, d).



**Fig. 2.86** Axial T2-weighted TSE sequence (a). Coronal T2-weighted TSE sequence (b). Axial T1-weighted TSE sequence with fat saturation (c). Magnified view (d) of the lesion highlighted in (c).



### ■ Clinical Case 8

**Endometriosis invading the inguinal canal** in a 37-year-old woman (arrow, Fig. 2.87a).

#### 2.4.2.7 MR Imaging of Malignant Transformation in Endometriosis

Malignant transformation in endometriomas is a rare complication, with an incidence of approximately 2.5%.<sup>63</sup> Malignant transformation is relatively common in younger patients, however, and so its exclusion by imaging is of key importance.

The diagnosis or exclusion of malignancy in endometriosis patients is a major indication for performing MRI. Malignant tumors in gonadal and extragonadal locations show a wide range of different histologies. Clear cell and endometrioid ovarian cancer are the most common tumor entities. Diagnostic features on MRI that support suspicion of malignancy include loss of T2 shading in malignant endometriomas. This is caused by the dilution of hemorrhagic fluid due to tumor secretions and enhancing mural nodules within a cystic mass.<sup>11,38,60</sup>

DWI with quantitative assessment of apparent diffusion coefficient (ADC) values is widely used in pelvic MRI protocols.<sup>13,41,47,68</sup> The presence of restricted diffusion and low ADC values within an adnexal lesion has a low positive predictive value and specificity for a diagnosis of malignancy. The low accuracy of DWI is due to the fact that malignant tumors are not the only entities that show restricted diffusion. Benign hemorrhagic ovarian cysts, endometriomas, solid endometrial implants, and benign mature cystic teratomas do so as well.<sup>19</sup> On a diffusion-weighted image obtained with a low b value (a type of T2-weighted fat-suppressed image), an endometrioma exhibits low signal intensity that resembles T2 shading. Thus, endometriomas have lower signal intensity on images obtained with higher b values than do adnexal masses, whose T2 signal intensity is higher. Because the ADC value is based on the slope of the signal intensity loss between acquisitions at low b values versus those at higher b values, endometriomas often have low ADC values.

## 2.4.3 Future Directions of Magnetic Resonance Imaging

### 2.4.3.1 Susceptibility-Weighted Imaging

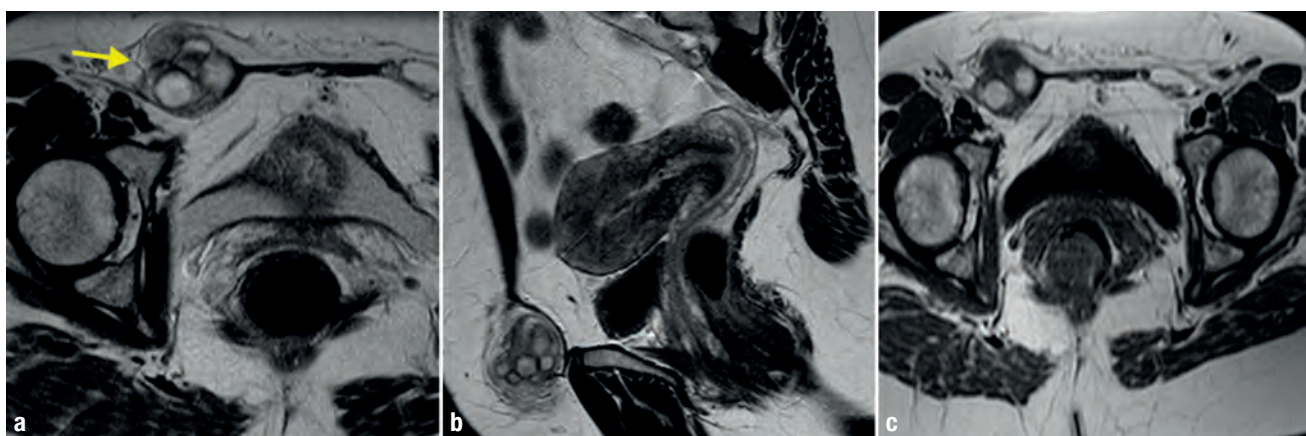
Susceptibility-weighted imaging (SWI) is a new MRI technique. Because it maximizes sensitivity to susceptibility effects, it offers extremely high sensitivity for detecting blood products. Thus, SWI has the potential to aid the diagnosis of deep infiltrating endometriosis by depicting different phases of hemorrhage. Recent studies evaluating how SWI performs in patients with endometriosis have shown that SWI is a sensitive and specific MRI technique for detecting very small, deeply infiltrating endometriosis lesions not visualized in conventional sequences. SWI may improve future MRI characterization in patients with endometriosis.<sup>17,58,59</sup>

### 2.4.3.2 Imaging Fusion Techniques

MRI and transvaginal sonography provide complementary information in the detection and staging of endometriosis. Fusion imaging (also known as real-time virtual sonography) is a new technique that uses MRI and ultrasound imaging information with magnetic navigation and computer software for the synchronized display of real-time ultrasound and multiplanar reconstructed MR images.<sup>39,70</sup> The few studies investigating the performance and clinical utility of these new techniques have demonstrated improved visualization of the main anatomical sites affected by deep infiltrating endometriosis. These fusion techniques thus have the potential to improve the performance of ultrasound and MRI. They may help to guide surgery in patients with endometriosis.

## 2.4.4 Conclusion

Endometriosis of the pelvis presents a large distribution of lesion sites and imaging features. The goal of pretherapeutic imaging is to precisely evaluate the extent of disease, thereby enabling the complete surgical treatment of all symptomatic endometriotic deep lesions in one procedure. Even though MRI is capable of detecting all sites of endometriosis, ultrasound continues to be the initial imaging study of choice because it is immediately available and accessible. But in patients with chronic dysmenorrhea, dyspareunia, clinical suspicion of deep endometriosis, or inconclusive sonographic



**Fig. 2.87** Axial T2-weighted TSE sequence (a). Sagittal T2-weighted TSE sequence with fat saturation (b). Axial T1-weighted TSE sequence (c).

findings, MRI is able to display endometriotic lesions due to its very high tissue contrast. MRI identifies endometriosis at all sites with high diagnostic accuracy, particularly in the cul-de-sac, uterosacral ligaments, upper vagina, or bowel. This makes MRI the optimum imaging modality for diagnosing endometriosis and accurately defining its extent. MRI aids in achieving the best possible preoperative workup and surgical management, and it should be offered to patients with equivocal ultrasound findings at specialized centers with a multidisciplinary approach.

### 2.4.5 References

1. ABRAO MS, GONCALVES, MANOEL ORLANDO DA C, DIAS JA JR, PODGAEC S, CHAMIE LP, BLASBALG R. Comparison between clinical examination, transvaginal sonography and magnetic resonance imaging for the diagnosis of deep endometriosis. *Hum Reprod* 2007;22(12):3092–7. doi:10.1093/humrep/dem187.
2. AGARWAL S, DELLA ZAZZERA V, PASCALI D, SINGH SS. Deep Endometriosis Infiltrating the Bladder Mucosa. *J Minim Invasive Gynecol* 2015. doi:10.1016/j.jmig.2015.06.010.
3. AMZALLAG-BELLENGER E, OUDJIT A, RUIZ A, CADIOT G, SOYER PA, HOFFFEL CC. Effectiveness of MR enterography for the assessment of small-bowel diseases beyond Crohn disease. *Radiographics* 2012;32(5):1423–44. doi:10.1148/rg.325115088.
4. ASCHER SM, AGRAWAL R, BIS KG, BROWN ED, MAXIMOVICH A, MARKHAM SM et al. Endometriosis: appearance and detection with conventional and contrast-enhanced fat-suppressed spin-echo techniques. *J Magn Reson Imaging* 1995;5(3):251–7.
5. BALLEYGUIER C, CHAPRON C, CHOPIN N, HELENON O, MENU Y. Abdominal wall and surgical scar endometriosis: results of magnetic resonance imaging. *Gynecol Obstet Invest* 2003;55(4):220–4.
6. BAZOT M, BORNIER C, DUBERNARD G, ROSEAU G, CORTEZ A, DARAI E. Accuracy of magnetic resonance imaging and rectal endoscopic sonography for the prediction of location of deep pelvic endometriosis. *Hum Reprod* 2007;22(5):1457–63. doi:10.1093/humrep/dem008.
7. BAZOT M, DARAI E, HOURANI R, THOMASSIN I, CORTEZ A, UZAN S et al. Deep pelvic endometriosis: MR imaging for diagnosis and prediction of extension of disease. *Radiology* 2004;232(2):379–89. doi:10.1148/radiol.2322030762.
8. BAZOT M, DETCHEV R, CORTEZ A, AMOUYAL P, UZAN S, DARAI E. Transvaginal sonography and rectal endoscopic sonography for the assessment of pelvic endometriosis: a preliminary comparison. *Hum Reprod* 2003;18(8):1686–92.
9. BAZOT M, LAFONT C, ROUZIER R, ROSEAU G, THOMASSIN-NAGGARA I, DARAI E. Diagnostic accuracy of physical examination, transvaginal sonography, rectal endoscopic sonography, and magnetic resonance imaging to diagnose deep infiltrating endometriosis. *Fertil Steril* 2009;92(6):1825–33. doi:10.1016/j.fertnstert.2008.09.005.
10. BAZOT M, THOMASSIN I, HOURANI R, CORTEZ A, DARAI E. Diagnostic accuracy of transvaginal sonography for deep pelvic endometriosis. *Ultrasound Obstet Gynecol* 2004;24(2):180–5. doi:10.1002/uog.1108.
11. BENNETT GL, SLYWOTZKY CM, CANTERA M, HECHT EM. Unusual manifestations and complications of endometriosis – spectrum of imaging findings: pictorial review. *AJR Am J Roentgenol* 2010;194(6 Suppl):WS34–46. doi:10.2214/AJR.07.7142.
12. BISCALDI E, FERRERO S, FULCHERI E, RAGNI N, REMORGIDA V, ROLLANDI GA. Multislice CT enteroclysis in the diagnosis of bowel endometriosis. *Eur Radiol* 2007;17(1):211–9. doi:10.1007/s00330-006-0364-5.
13. BUSARD MPH, MIJATOVIC V, VAN KUIJK C, PIETERS-VAN DEN BOS, I C, HOMPES PGA, VAN WAESBERGHE, JHTM. Magnetic resonance imaging in the evaluation of (deep infiltrating) endometriosis: the value of diffusion-weighted imaging. *J Magn Reson Imaging* 2010;32(4):1003–9. doi:10.1002/jmri.22310.
14. CHAPRON C, DUBUISSON J, PANSINI V, VIEIRA M, FAUCONNIER A, BARAKAT H et al. Routine clinical examination is not sufficient for diagnosing and locating deeply infiltrating endometriosis. *J Am Assoc Gynecol Laparosc* 2002;9(2):115–9.
15. CHAPRON C, VIEIRA M, CHOPIN N, BALLEYGUIER C, BARAKAT H, DUMONTIER I et al. Accuracy of rectal endoscopic ultrasonography and magnetic resonance imaging in the diagnosis of rectal involvement for patients presenting with deeply infiltrating endometriosis. *Ultrasound Obstet Gynecol* 2004;24(2):175–9. doi:10.1002/uog.1107.
16. CHEEWADHANARAKS S, PEEYANANJARASSRI K, DHANAWORAVIBUL K, LIABSUETRAKUL T. Positive predictive value of clinical diagnosis of endometriosis. *J Med Assoc Thai* 2004;87(7):740–4.
17. CIMSIT C, YOLDEMIR T, GUCLU M, AKPINAR IN. Susceptibility-weighted magnetic resonance imaging for the evaluation of deep infiltrating endometriosis: preliminary results. *Acta Radiol* 2015. doi:10.1177/0284185115602147.
18. FAUCONNIER A, CHAPRON C. Endometriosis and pelvic pain: epidemiological evidence of the relationship and implications. *Hum Reprod Update* 2005;11(6):595–606. doi:10.1093/humupd/dmi029.
19. FEUERLEIN S, PAULS S, JUCHEMS MS, STUBER T, HOFFMANN MHK, BRAMBS H et al. Pitfalls in abdominal diffusion-weighted imaging: how predictive is restricted water diffusion for malignancy. *AJR Am J Roentgenol* 2009;193(4):1070–6. doi:10.2214/AJR.08.2093.
20. FRANCICA G, GIARDIELLO C, ANGELONE G, CRISTIANO S, FINELLI R, TRAMONTANO G. Abdominal wall endometriomas near cesarean delivery scars: sonographic and color doppler findings in a series of 12 patients. *J Ultrasound Med* 2003;22(10):1041–7.
21. GLASTONBURY CM. The shading sign. *Radiology* 2002;224(1):199–201. doi:10.1148/radiol.2241010361.
22. GRASSO RF, DI GIACOMO V, SEDATI P, SIZZI O, FLORIO G, FAIELLA E et al. Diagnosis of deep infiltrating endometriosis: accuracy of magnetic resonance imaging and transvaginal 3D ultrasonography. *Abdom Imaging* 2010;35(6):716–25. doi:10.1007/s00261-009-9587-7.
23. GUERRIERO S, AJOSSA S, MINGUEZ JA, JURADO M, MAIS V, MELIS GB et al. Accuracy of transvaginal ultrasound for diagnosis of deep endometriosis in uterosacral ligaments, rectovaginal septum, vagina and bladder: systematic review and meta-analysis. *Ultrasound Obstet Gynecol* 2015;46(5):534–45. doi:10.1002/uog.15667.
24. HUANG W, CHEN W, CHEN C, CHENG Y, WANG J, ENG H. Endometrial cyst of the liver: a case report and review of the literature. *J Clin Pathol* 2002;55(9):715–7.
25. IDEYI SC, SCHEIN M, NIAZI M, GERST PH. Spontaneous endometriosis of the abdominal wall. *Dig Surg* 2003;20(3):246–8.
26. JOSEPH J, SAHN SA. Thoracic endometriosis syndrome: new observations from an analysis of 110 cases. *Am J Med* 1996;100(2):164–70.

27. KAPAN M, KAPAN S, DURGUN AV, GOKSOY E. Inguinal endometriosis. *Arch Gynecol Obstet* 2005;271(1):76–8. doi:10.1007/s00404-004-0624-z.
28. KECKSTEIN J, ULRICH U, KANDOLF O, WIESINGER H, WUSTLICH M. Laparoscopic therapy of intestinal endometriosis and the ranking of drug treatment. *Zentralbl Gynakol* 2003;125(7–8):259–66. doi:10.1055/s-2003-42281.
29. KINKEL K, CHAPRON C, BALLEYGUIER C, FRITEL X, DUBUISSON JB, MOREAU JF. Magnetic resonance imaging characteristics of deep endometriosis. *Hum Reprod* 1999;14(4):1080–6.
30. KINKEL K, LU Y, MEHDIZADE A, PELTE M, HRICAK H. Indeterminate ovarian mass at US: incremental value of second imaging test for characterization – meta-analysis and Bayesian analysis. *Radiology* 2005;236(1):85–94. doi:10.1148/radiol.2361041618.
31. KOLODZIEJ A, KRAJEWSKI W, DOLOWY L, HIRNLE L. Urinary Tract Endometriosis. *Urol J* 2015;12(4):2213–7.
32. KOZAWA E, INOUE K, IWASA N, FUJIWARA K, YASUDA M, TANAKA J et al. MR imaging of polypoid endometriosis of the ovary. *Magn Reson Med Sci* 2012;11(3):201–4.
33. KRUGER K, GILLY L, NIEDOBITEK-KREUTER G, MPINOUL, EBERT AD. Bladder endometriosis: characterization by magnetic resonance imaging and the value of documenting ureteral involvement. *Eur J Obstet Gynecol Reprod Biol* 2014;176:39–43. doi:10.1016/j.ejogrb.2014.02.019.
34. LANDI S, BARBIERI F, FIACCAVENTO A, MAINARDI P, RUFFO G, SELVAGGI L et al. Preoperative double-contrast barium enema in patients with suspected intestinal endometriosis. *J Am Assoc Gynecol Laparosc* 2004;11(2):223–8.
35. LEYENDECKER JR, BLOOMFELD RS, DISANTIS DJ, WATERS GS, MOTT R, BECHTOLD RE. MR enterography in the management of patients with Crohn disease. *Radiographics* 2009;29(6):1827–46. doi:10.1148/rg.296095510.
36. LOPES DIAS J, VELOSO GOMES F, LUCAS R, CUNHA TM. The shading sign: is it exclusive of endometriomas? *Abdom Imaging* 2015;40(7):2566–72. doi:10.1007/s00261-015-0465-1.
37. MARCAL L, NOTHAFT MA, COELHO F, CHOI H. Deep pelvic endometriosis: MR imaging. *Abdom Imaging* 2010;35(6):708–15. doi:10.1007/s00261-010-9611-y.
38. MCDERMOTT S, OEI TN, IYER VR, LEE SI. MR imaging of malignancies arising in endometriomas and extraovarian endometriosis. *Radiographics* 2012;32(3):845–63. doi:10.1148/rg.323115736.
39. MILLISCHER A, SALOMON LJ, SANTULLI P, BORGHESE B, DOUSSET B, CHAPRON C. Fusion imaging for evaluation of deep infiltrating endometriosis: feasibility and preliminary results. *Ultrasound Obstet Gynecol* 2015;46(1):109–17. doi:10.1002/uog.14712.
40. MINELLI L, CECCARONI M, RUFFO G, BRUNI F, POMINI P, PONTRELLI G et al. Laparoscopic conservative surgery for stage IV symptomatic endometriosis: short-term surgical complications. *Fertil Steril* 2010;94(4):1218–22. doi:10.1016/j.fertnstert.2009.08.035.
41. NAMIMOTO T, AWAI K, NAKAURA T, YANAGA Y, HIRAI T, YAMASHITA Y. Role of diffusion-weighted imaging in the diagnosis of gynecological diseases. *Eur Radiol* 2009;19(3):745–60. doi:10.1007/s00330-008-1185-5.
42. OUTWATER E, SCHIEBLER ML, OWEN RS, SCHNALL MD. Characterization of hemorrhagic adnexal lesions with MR imaging: blinded reader study. *Radiology* 1993;186(2):489–94. doi:10.1148/radiology.186.2.8421756.
43. OUTWATER EK, SIEGELMAN ES, HUNT JL. Ovarian teratomas: tumor types and imaging characteristics. *Radiographics* 2001;21(2):475–90. doi:10.1148/radiographics.21.2.g01mr09475.
44. PANEL P, HUCHON C, ESTRADE-HUCHON S, LE TOHIC A, FRITEL X, FAUCONNIER A. Bladder symptoms and urodynamic observations of patients with endometriosis confirmed by laparoscopy. *Int Urogynecol J* 2015. doi:10.1007/s00192-015-2848-9.
45. PEREIRA JM, SIRLIN CB, PINTO PS, CASOLA G. CT and MR imaging of extrahepatic fatty masses of the abdomen and pelvis: techniques, diagnosis, differential diagnosis, and pitfalls. *Radiographics* 2005;25(1):69–85. doi:10.1148/rg.251045074.
46. PHILIP C, BISCH C, COULON A, SAINT-HILAIRE P DE, RUDIGOZ R, DUBERNARD G. Correlation between three-dimensional rectosonography and magnetic resonance imaging in the diagnosis of rectosigmoid endometriosis: a preliminary study on the first fifty cases. *Eur J Obstet Gynecol Reprod Biol* 2015;187:35–40. doi:10.1016/j.ejogrb.2015.02.006.
47. QAYYUM A. Diffusion-weighted imaging in the abdomen and pelvis: concepts and applications. *Radiographics* 2009;29(6):1797–810. doi:10.1148/rg.296095521.
48. REMORGIDA V, FERRERO S, FULCHERI E, RAGNI N, MARTIN DC. Bowel endometriosis: presentation, diagnosis, and treatment. *Obstet Gynecol Surv* 2007;62(7):461–70. doi:10.1097/01.ogx.0000268688.55653.5c.
49. ROUSSET P, PEYRON N, CHARLOT M, CHATEAU F, GOLFIER F, RAUDRANT D et al. Bowel endometriosis: preoperative diagnostic accuracy of 3.0-T MR enterography – initial results. *Radiology* 2014;273(1):117–24. doi:10.1148/radiol.14132803.
50. S2K-LEITLINIE. 015/045 – Diagnostik und Therapie der Endometriose. Stand: 08/2013; Available from: [http://www.awmf.org/uploads/tx\\_szleitlinien/015045\\_S2k\\_Diagnostik\\_Therapie\\_Endometriose\\_2013-10.pdf](http://www.awmf.org/uploads/tx_szleitlinien/015045_S2k_Diagnostik_Therapie_Endometriose_2013-10.pdf).
51. SABA L, SULCIS R, MELIS GB, CECCO CN DE, LAGHI A, PIGA M et al. Endometriosis: the role of magnetic resonance imaging. *Acta Radiol* 2015;56(3):355–67. doi:10.1177/0284185114526086.
52. SABA L, SULCIS R, MELIS GB, IBBA G, ALCAZAR JL, PIGA M et al. Diagnostic confidence analysis in the magnetic resonance imaging of ovarian and deep endometriosis: comparison with surgical results. *Eur Radiol* 2014;24(2):335–43. doi:10.1007/s00330-013-3013-9.
53. SACCARDI C, COSMI E, BORGHERO A, TREGNAGHI A, DESSOLE S, LITTA P. Comparison between transvaginal sonography, saline contrast sonovaginography and magnetic resonance imaging in the diagnosis of posterior deep infiltrating endometriosis. *Ultrasound Obstet Gynecol* 2012;40(4):464–9. doi:10.1002/uog.11102.
54. SCARMATO VJ, LEVINE MS, HERLINGER H, WICKSTROM M, FURTH EE, TURECK RW. Ileal endometriosis: radiographic findings in five cases. *Radiology* 2000;214(2):509–12. doi:10.1148/radiology.214.2.r00fe35509.
55. SCHINDLER AE. Pathophysiology, diagnosis and treatment of endometriosis. *Minerva Ginecol* 2004;56(5):419–35.
56. SILLOU S, POIREE S, MILLISCHER AE, CHAPRON C, HELENON O. Urinary endometriosis: MR imaging appearance with surgical and histological correlations. *Diagn Interv Imaging* 2015;96(4):373–81. doi:10.1016/j.diii.2014.11.010.
57. SUGIMURA K, OKIZUKA H, IMAOKA I, KAJI Y, TAKAHASHI K, KITAO M et al. Pelvic endometriosis: detection and diagnosis with chemical shift MR imaging. *Radiology* 1993;188(2):435–8. doi:10.1148/radiology.188.2.8327693.



58. TAKEUCHI M, MATSUZAKI K, HARADA M. Susceptibility-weighted MRI of extra-ovarian endometriosis: preliminary results. *Abdom Imaging* 2015;40(7):2512–6. doi:10.1007/s00261-015-0378-z.
59. TAKEUCHI M, MATSUZAKI K, NISHITANI H. Susceptibility-weighted MRI of endometrioma: preliminary results. *AJR Am J Roentgenol* 2008;191(5):1366–70. doi:10.2214/AJR.07.3974.
60. TANAKA YO, YOSHIZAKO T, NISHIDA M, YAMAGUCHI M, SUGIMURA K, ITAI Y. Ovarian carcinoma in patients with endometriosis: MR imaging findings. *AJR Am J Roentgenol* 2000;175(5):1423–30. doi:10.2214/ajr.175.5.1751423.
61. TURPIN F, DACLIN PY, KARAM R, MENY R, SALANON AP, PARAMELLE PJ et al. A case of muscular and canal of nuck involvement by endometriosis. *J Radiol* 2001;82(8):933–5.
62. VALENTINI AL, GUI B, MICCO M, MINGOTE MC, NINIVAGGI V, GUIDO M et al. How to improve MRI accuracy in detecting deep infiltrating colorectal endometriosis: MRI findings vs. laparoscopy and histopathology. *Radiol Med* 2014;119(5):291–7. doi:10.1007/s11547-013-0336-1.
63. VAN GORP T, AMANT F, NEVEN P, VERGOTE I, MOERMAN P. Endometriosis and the development of malignant tumours of the pelvis. A review of literature. *Best Pract Res Clin Obstet Gynaecol* 2004;18(2):349–71. doi:10.1016/j.bpobgyn.2003.03.001.
64. VERCELLINI P, CHAPRON C, FEDELE L, FRONTINO G, ZAINA B, CROSIGNANI PG. Evidence for asymmetric distribution of sciatic nerve endometriosis. *Obstet Gynecol* 2003;102(2):383–7.
65. VERCELLINI P, TRESPIDI L, GIORGI O DE, CORTESI I, PARAZZINI F, CROSIGNANI PG. Endometriosis and pelvic pain: relation to disease stage and localization. *Fertil Steril* 1996;65(2):299–304.
66. VIGANO P, PARAZZINI F, SOMIGLIANA E, VERCELLINI P. Endometriosis: epidemiology and aetiological factors. *Best Pract Res Clin Obstet Gynaecol* 2004;18(2):177–200. doi:10.1016/j.bpobgyn.2004.01.007.
67. VIMERCATI A, ACHILARRE MT, SCARDAPANE A, LORUSSO F, CECI O, MANGIATORDI G et al. Accuracy of transvaginal sonography and contrast-enhanced magnetic resonance-colonography for the presurgical staging of deep infiltrating endometriosis. *Ultrasound Obstet Gynecol* 2012;40(5):592–603. doi:10.1002/uog.11179.
68. WHITTAKER CS, COADY A, CULVER L, RUSTIN G, PADWICK M, PADHANI AR. Diffusion-weighted MR imaging of female pelvic tumors: a pictorial review. *Radiographics* 2009;29(3):759–74; discussion 774–8. doi:10.1148/rg.293085130.
69. WU TT, COAKLEY FV, QAYYUM A, YEH BM, JOE BN, CHEN L. Magnetic resonance imaging of ovarian cancer arising in endometriomas. *J Comput Assist Tomogr* 2004;28(6):836–8.
70. YAVARIABDI A, BARTOLI A, SAMIR C, ARTIGUES M, CANIS M. Mapping and characterizing endometrial implants by registering 2D transvaginal ultrasound to 3D pelvic magnetic resonance images. *Comput Med Imaging Graph* 2015;45:11–25. doi:10.1016/j.compmedimag.2015.07.007.

## A Comparison of Pelvic Magnetic Resonance Imaging, Transvaginal and Transrectal Sonography, and Laparoscopic Findings in the Diagnosis of Deep Infiltrating Endometriosis

Saeed Alborzi<sup>a</sup> | Aliakbar Rasekhi<sup>b</sup> | Mahbubeh Kazemi<sup>c</sup> | Soroosh Alborzi<sup>d</sup> | Mehrnoosh Alborzi<sup>e</sup> | Ziba Zahiri<sup>f</sup>

### 2.5.1 Introduction

It has been estimated that 15 to 30% of patients with endometriosis suffer from *deep infiltrating endometriosis* (DIE).<sup>21</sup> The severity of symptoms in patients with DIE is directly proportional to the depth of the lesions. Common sites of occurrence for DIE include the uterosacral ligaments, posterior vaginal wall, and anterior rectal wall.<sup>21</sup> Unlike superficial endometriosis, which is best explained by the retrograde menstruation and implantation theory, the leading theory for the pathogenesis of DIE lesions is the transformation of pluripotent peritoneal mesothelium, referred to as the coelomic metaplasia theory.<sup>21</sup>

The first-line modality for the definitive diagnosis of DIE is direct endoscopic visualization of the lesion, with a biopsy taken in the same session by laparoscopy or laparotomy<sup>15</sup> The diagnosis of DIE poses a challenge for any gynecologist. Various imaging modalities such as *magnetic resonance imaging* (MRI), *transvaginal sonography* (TVS), *transrectal sonography* (TRS), and *3D ultrasound* are currently available for this purpose. Several studies have been conducted to analyze the sensitivity and specificity of these modalities in the diagnosis of DIE.<sup>10,12,18,19</sup>

Taking accessibility into consideration, TVS is usually the first imaging study requested in females with symptoms of DIE. When performed by an expert sonographer, this method provides a high sensitivity for the diagnosis of rectal and retrocervical DIE (98.1% and 95.1%, respectively).<sup>18</sup> TRS may

perhaps be an acceptable alternative to TVS, as its sensitivity and specificity are comparable to MRI at certain anatomic locations. Also, virginity is not considered a limitation for TRS as it would be for TVS. The role of *rectal endoscopic sonography* (RES) has also been described in the literature. The most widely used RES devices are available in two different designs: the radial array and curved linear array. Radial echoendoscopes provide a 360° image in a plane perpendicular to the long axis of the insertion tube of the endoscope, whereas linear devices produce sector-shaped images in a plane parallel to the long axis of the insertion tube.<sup>9,20</sup>

Finally, MRI is a noninvasive but more costly modality for the preoperative assessment of DIE that provides more accurate data about the extent, location, and penetration of the lesions. The sensitivity of MRI for the diagnosis of rectal and retrocervical DIE is reported at 83.3% and 76%, respectively.<sup>18</sup>

The surgical resection of DIE is facilitated by preoperative assessments to define the location, depth, and extent of endometriotic lesions. However, selecting the preferred imaging modality for diagnosis and preoperative assessment continues to be a challenge. Our study was an attempt to determine the sensitivity and specificity of the three different imaging modalities (TVS, MRI, and TRS) and to compare their accuracy in DIE patients who were referred to the tertiary gynecologic surgery centers where we practice.

### 2.5.2 Materials and Methods

#### 2.5.2.1 Patients

Based on presenting clinical symptoms suggestive of DIE (chronic pelvic pain, dyspareunia and dysmenorrhea) and physical examination findings, patients who were primarily referred to private clinics and hospitals (affiliated with the Shiraz University of Medical Sciences, Iran) were selected to enter the study.<sup>2,3</sup> Subsequently, patients were scheduled for diagnostic laparoscopy to exclude the presence of DIE. Prior to diagnostic laparoscopy, all subjects enrolled in the study underwent imaging procedures including TVS, TRS, and MRI. Those patients with a clinically confirmed diagnosis of DIE were managed by surgical treatment provided promptly during the course of the laparoscopic procedure. Kelsey and Fleiss sample size formulae\* (with continuity correction) were employed for sample size calculation.

- <sup>a</sup> | Professor of Obstetrics and Gynecology, MD; Head of the Gynecologic Endoscopy Division, Laparoscopy Research Center, Department of Obstetrics and Gynecology, School of Medicine, Shiraz University of Medical Sciences, Shiraz, Iran
- <sup>b</sup> | Associate Professor of Radiology, MD; Department of Radiology, Shiraz University of Medical Sciences, Shiraz, Iran
- <sup>c</sup> | Gynecologist, Shiraz University of Medical Sciences, Shiraz, Iran
- <sup>d</sup> | MD; Head of Cardiology Department, Khormoj Zeinabyieh Hospital, Bushehr University of Medical Sciences, Bushehr, Iran
- <sup>e</sup> | DDS, MSc candidate, Faculty of Dentistry, Mc Gill University, Montreal, Canada
- <sup>f</sup> | Professor of Obstetrics and Gynecology, MD; Gilan University of Medical Sciences, Rasht, Iran

#### Corresponding author:

##### Saeed Alborzi

Professor of Obstetrics and Gynecology,  
Head of the Gynecologic Endoscopy Division,  
Laparoscopy Research Center,  
Department of Obstetrics and Gynecology,  
School of Medicine, Shiraz University of Medical Sciences  
Shiraz, Iran  
E-mail: alborzisa@gmail.com

\* Statistical methods used to calculate sample size in unmatched case-control studies

Patients from all age groups were included. Exclusion criteria were as follows:

- Claustrophobia that prevented the patient from entering the MRI scanner.
- Renal failure or any other contraindication to the use of gadolinium contrast medium.
- Confirmed diagnosis of any type of malignancy.
- Medical history of metallic implants or prostheses in the body that would contraindicate MRI.
- Structural anomalies of the reproductive system.
- Existing pregnancy.
- Refusal of informed consent or lack of patient compliance with TVS or TRS.

Patients were briefed about their enrollment in the research project, after which they furnished written informed consent. All aspects of the study were in compliance with ethical guidelines and were approved by an institutional review board.

#### 2.5.2.2 Transvaginal Sonography

TVS was performed by a qualified gynecologist blinded to the clinical findings in the subjects examined. A 7.5-MHz probe (Ultrasonix ultrasound system, British Columbia, Canada) was used, and the examination was performed on nonmenstrual days of the cycle. Patients were asked to have semifull bladders and bowel preps to ensure better visualization of the pelvic organs by TVS and TRS. Interpretations were done in real time, and sonograms were documented in each patient's file. The examination protocol included visualization of the peritoneum and structures in the anterior and posterior compartments, as well as the uterus and ovaries. Nodular, hypoechoic solid lesions with or without cystic components located at various sites in the pelvic cavity were considered highly suggestive of DIE. Abnormal, hyperechoic thickening of the peritoneum was also considered a sign of DIE.

#### 2.5.2.3 Transrectal Sonography

TRS was scheduled on the same day as TVS. The examination was performed by the same gynecologist using a 7.5-MHz probe (Ultrasonix OP machine, British Columbia, Canada) following bowel preparation. To ensure an adequate bowel prep, each patient was instructed to consume a soft diet on the day before their ultrasound, taking 2 spoonfuls of milk of magnesia (MOM) orally after lunch and inserting two 10-mg bisacodyl suppositories (Temad Co. Tehran, Iran) at 6 p.m. and 12 midnight on the day before the procedure. Patients were asked to skip breakfast and insert 2 more bisacodyl suppositories at 6 a.m. on the morning of the procedure. The procedure was performed on an empty bladder, without sedation, and with the use of lubricant gel. Image interpretation was done in real time, and sonograms were documented in each patient's file for future reference. The examination protocol was similar to that of TVS, and the same diagnostic criteria were applied.

#### 2.5.2.4 Magnetic Resonance Imaging

MRI was performed in each patient after a 4-hour fast with a semifull bladder, before and after the intravenous injection of gadolinium contrast medium at a dose of 0.01 mmol/kg. Each patient was scanned through the body and pelvis in a 1.5 Tesla system (Avanto Magnetom, Siemens, Erlangen, Germany) without an endovaginal coil. For better delineation of the rectal and vaginal walls, 60 cc of lubricant gel was inserted into the vaginal cuff, and one vial of hyoscine was administered by intramuscular injection. To capture details of anatomy and pathology, the protocol included axial, coronal, and sagittal T1- and T2-weighted sequences. Axial and sagittal fat-saturated T1-weighted images were also acquired before and after i.v. contrast administration. The bladder wall and rectovaginal septum were evaluated in sagittal and axial T2-weighted sections. The uterosacral ligaments and rectal wall were mostly evaluated in coronal and axial T2-weighted images. Endometriomas were characterized by high signal intensity in T1-weighted images and low signal intensity in T2-weighted images. DIE, on the other hand, showed low signal intensity or a signal void in T2-weighted images. Wall thickening was considered suggestive of involvement. All MRI evaluations were reported by a board-certified radiologist with MRI fellowship, blinded to the patients' history and physical examination.

#### 2.5.2.5 Laparoscopy

Following a complete bowel preparation and induction of general anesthesia, operative laparoscopy was performed by the same gynecologist using laparoscopic instruments. The surgeon was blinded to the imaging results obtained prior to laparoscopy. Uterine manipulation was avoided, and the only measuring device used during the procedure was a hysteroscope. The pelvis was systematically assessed in all laparoscopies, following the standard protocol at our center.<sup>4,5</sup> The pelvic cavity was explored and endometriosis was classified based on the *revised American Society for Reproductive Medicine (rASRM)* classification.<sup>6</sup> The pararectal, paravesical, and rectovaginal spaces were dissected as required, depending on lesion location. All adhesions were released by sharp dissection, and all DIE-suspicious lesions were resected to restore normal anatomic relations as much as possible. The excised tissues were submitted for pathology. Meticulous hemostasis was achieved with bipolar cautery, and sutures were placed as needed. In patients with rectal lesions, the pararectal and rectovaginal spaces were dissected and inspected for suspicious areas. The suspicious lesions were excised by disk resection or segmental resection, and the bowel was reanastomosed as required. Ureterolysis and excision with reanastomosis were performed in patients with extrinsic and intrinsic ureteral lesions, respectively. In patients who had bladder lesions, either shaving or partial cystectomy was performed based on the depth of the lesions. A colorectal surgeon and urologist were standing by in the event that major colorectal or urinary system lesions were encountered.<sup>13</sup>

#### 2.5.2.6 Histopathologic Evaluation

A diagnosis of endometriosis was confirmed for all surgical samples based on an evaluation of both the glandular and stromal tissues.



### 2.5.2.7 Statistical Analysis

The definitive diagnosis of DIE as well as the size and location of pathology were determined based on the laparoscopic findings. Preoperative imaging findings were then compared with the benchmark surgical observations, and each modality was assessed for its sensitivity, specificity, negative and positive predictive values, miss rate, accuracy, and positive and negative likelihood ratios. The Cohen kappa coefficient was used to determine agreement between the alternative methods. The kappa coefficient value ranges from 0 to 1 ( $0 \leq \kappa \leq 1$ ), and the closer it is to 1, the more agreement there is regarding a particular diagnosis. The statistical values were obtained for each imaging technique and different sites of DIE involvement using the following terminology, abbreviations, and formulas:

Sensitivity	true positive (TP)/TP+ false negative (FN)
Specificity	true negative (TN)/TN+ false positive (FP)
Precision or positive predictive value	TP/TP + FP
Negative predictive value	TN/TN + FN
Miss rate	FN/FN + TP
Total positive and total negative	P + N
Accuracy	(TP + TN)/(P + N)
Likelihood ratio positive (LR+)	sensitivity/(1 – specificity)
Likelihood ratio negative (LR-)	(1 – sensitivity)/specificity

### 2.5.3 Results

Between March of 2010 and December of 2014, more than 500 patients underwent laparoscopic surgery for endometriosis in our setting. Of this number, 317 cases (non-virgins only) were enrolled in the study through a consecutive sampling method. Virgin subjects were excluded because they were not acceptable candidates for TVS examination. The mean age of the enrolled patients was  $31 \pm 5.4$  years. Operative laparoscopy confirmed the diagnosis of DIE in 252 of the 317 enrolled subjects, although the remaining 65 patients who were negative for DIE by laparoscopy may have had an endometrioma or superficial endometriosis. The 252 confirmed patients had a total of 350 lesions.

All the patients had stage 3 or stage 4 endometriosis. As mentioned earlier, 350 DIE lesions were identified in these 317 patients during laparoscopy; 151 of the lesions were located in the uterosacral ligament (43.1%), making it the most frequent site of involvement. Next in frequency were the ovarian fossa ( $n = 59$ , 16.9%), rectal wall ( $n = 52$ , 14.9%), rectovaginal septum ( $n = 44$ , 12.6%), retrocervical area ( $n = 38$ , 10.9%), bladder

( $n = 4$ , 1.1%), and ureter ( $n = 2$ , 0.57%). Of the 252 patients with laparoscopically confirmed DIE, 152 had 1 lesion, 73 had 2 lesions, 16 had 3 lesions, and 2 had 4 lesions.

Of the 310 DIE lesions detected by TVS, 254 were confirmed as endometriosis at laparoscopy. Similarly, 270/339 and 238/289 DIE lesions that were reported on TRS and MRI, respectively, were declared positive at laparoscopy.

#### 2.5.3.1 Comparison of TVS, TRS, and MRI for the Visualization of DIE, Categorized by Sites of Predilection

For the most prevalent site of DIE involvement, the uterosacral ligaments, our data analysis showed that TRS, TVS, and MRI had respective sensitivities of 82.8%, 70.9%, and 63.6%. The miss rates for TRS, TVS, and MRI stood at 0.17, 0.29, and 0.36 respectively. On the other hand, specificity had a reverse trend that favored MRI (93.9% vs. 92.8% for TVS and 89.8% for TRS).

For lesions located in the rectovaginal septum, the sensitivity and accuracy values were comparable for TVS, TRS, and MRI. These values were 86.4% and 93.7% for TVS, 84% and 92.4% for TRS, and 72.7% and 92.1% for MRI. Similarly, the specificity of MRI was comparable to TVS and TRS (95.2% vs. 94.9% and 93.8% respectively).

For DIE lesions in the ovarian fossa, MRI had a comparable sensitivity to that of TRS and TVS (66.1% vs. 64.4% and 62.7%, respectively). Specificity and accuracy were also similar in MRI (98.1% and 92.1%), TVS (95.7% and 89.6%), and TRS (93.4% and 88%).

As for the lesions in the rectal walls, TVS, TRS, and MRI were found to have comparable sensitivity and specificity (88.5% and 98.9% in TVS, 86.5% and 97.7% in TRS, and 76.9% and 96.6% in MRI).

MRI proved to be superior to TRS and TVS in its sensitivity, specificity, and accuracy for the diagnosis of retrocervical DIE lesions.

The three modalities were found to be equivalent in the diagnosis of bladder and ureteral DIE, however. The sensitivity, specificity, and accuracy values were similar for all three tests.

In [Tables 2.6–2.8](#), the results documented for TVS, TRS, MRI, and laparoscopy in the diagnosis of DIE are summarized and compared for lesion sites in the uterosacral ligaments and ovarian fossa ([Table 2.6](#)), the retrocervical area and rectovaginal septum ([Table 2.7](#)), and the rectal wall, bladder, and ureter ([Table 2.8](#)).

Utero-sacral ligaments	Laparoscopic findings			Total	Sensitivity (%)	Specificity (%)	PPV (%)	NPV (%)	Accuracy (%)	Miss rate (%)	LR +	LR-	Kappa	P value
		+	-											
TVS	+	107	12	119	70.86	92.77	89.9	77.78	82.33	0.29	9.8	0.31	0.64	< 0.001
	-	44	154	198										
	Total	151	166	317										
TRS	+	125	17	142	82.76	89.76	88.03	85.14	86.44	0.17	8.08	0.19	0.73	< 0.001
	-	56	149	175										
	Total	37	166	317										
MRI	+	96	10	106	63.58	93.98	90.57	73.93	97.50	0.36	10.55	0.39	0.58	< 0.001
	-	55	156	211										
	Total	151	166	317										
<b>Ovarian fossa</b>														
TVS	+	37	11	48	62.71	95.74	77.08	91.82	89.59	0.37	14.71	0.39	0.63	< 0.001
	-	22	247	269										
	Total	59	258	317										
TRS	+	38	17	55	64.41	93.41	69.09	91.98	88.01	0.36	9.77	0.38	0.59	< 0.001
	-	21	241	262										
	Total	59	258	317										
MRI	+	39	5	44	66.1	98.06	88.64	92.67	92.11	0.34	34.11	0.35	0.71	< 0.001
	-	20	253	273										
	Total	59	258	317										

**Table 2.6** Comparison of the results for TVS, TRS, MRI, and laparoscopy in the diagnosis of DIE in the uterosacral ligaments and ovarian fossa. Key to acronyms: transvaginal sonography (TVS); transrectal sonography (TRS); magnetic resonance imaging (MRI), true positive (TP), true negative (TN); false positive (FP); false negative (FN); likelihood ratio positive (LR+); likelihood ratio negative (LR-).

Retro-cervical	Laparoscopic findings			Total	Sensitivity (%)	Specificity (%)	PPV (%)	NPV (%)	Accuracy (%)	Miss rate (%)	LR +	LR-	Kappa	P value
		+	-											
TVS	+	20	15	35	52.83	94.62	57.14	93.62	89.59	0.47	9.79	0.5	0.49	< 0.001
	-	18	264	282										
	Total	38	279	317										
TRS	+	19	11	30	50	96.06	63.33	93.38	90.54	0.5	12.68	0.52	0.51	< 0.001
	-	19	268	287										
	Total	38	279	317										
MRI	+	25	10	35	65.79	96.42	71.43	95.39	92.74	0.34	18.36	0.35	0.64	< 0.001
	-	13	269	282										
	Total	38	279	317										
<b>Rectovaginal septum</b>														
TVS	+	38	14	52	86.36	94.87	73.08	97.74	93.69	0.14	16.84	0.14	0.75	< 0.001
	-	6	259	265										
	Total	44	273	317										
TRS	+	37	17	54	84.09	93.77	68.52	97.34	92.43	0.16	13.5	0.17	0.71	< 0.001
	-	7	256	263										
	Total	44	273	317										
MRI	+	32	13	45	72.73	95.24	71.11	95.59	92.11	0.27	15.27	0.29	0.67	< 0.001
	-	12	260	272										
	Total	44	273	317										

**Table 2.7** Comparison of the results for TVS, TRS, MRI, and laparoscopy in the diagnosis of DIE in the retrocervical area and rectovaginal septum. Key to acronyms: transvaginal sonography (TVS); transrectal sonography (TRS); magnetic resonance imaging (MRI), true positive (TP), true negative (TN); false positive (FP); false negative (FN); likelihood ratio positive (LR+); likelihood ratio negative (LR-).

Rectal wall	Laparoscopic findings			Total	Sensitivity (%)	Specificity (%)	PPV (%)	NPV (%)	Accuracy (%)	Miss rate (%)	LR +	LR–	Kappa	P value
		+	–											
TVS	+	46	3	49	88.46	98.87	93.88	97.76	97.16	0.12	78.14	0.12	0.89	< 0.001
	–	6	262	268										
	Total	52	265	317										
TRS	+	45	6	51	86.54	97.74	88.24	97.37	95.9	0.13	38.22	0.14	0.85	< 0.001
	–	7	259	266										
	Total	52	265	317										
MRI	+	40	9	49	76.92	96.60	81.63	95.52	93.38	0.23	22.65	0.24	0.75	< 0.001
	–	12	256	268										
	Total	52	265	317										
<b>Bladder</b>														
TVS	+	4	1	5	100	99.68	80	100	99.68	0	313	0.38	0.89	< 0.001
	–	0	312	312										
	Total	4	313	317										
TRS	+	4	1	5	100	99.68	80	100	99.68	0	313	0	0.89	< 0.001
	–	0	312	312										
	Total	4	313	317										
MRI	+	4	1	5	100	99.68	80	100	99.68	0	313	0	0.89	< 0.001
	–	0	312	312										
	Total	4	313	317										
<b>Ureter</b>														
TVS	+	2	0	2	100	100	100	100	100	0	–	0	1	< 0.001
	–	0	315	315										
	Total	2	315	317										
TRS	+	2	0	2	100	100	100	100	100	0	–	0	1	< 0.001
	–	0	315	315										
	Total	2	315	317										
MRI	+	2	0	2	100	100	100	100	100	0	–	0	1	< 0.001
	–	0	315	315										
	Total	2	315	317										

**Table 2.8** Comparison of the results for TVS, TRS, MRI, and laparoscopy in the diagnosis of DIE in the rectal wall, bladder, and ureter.

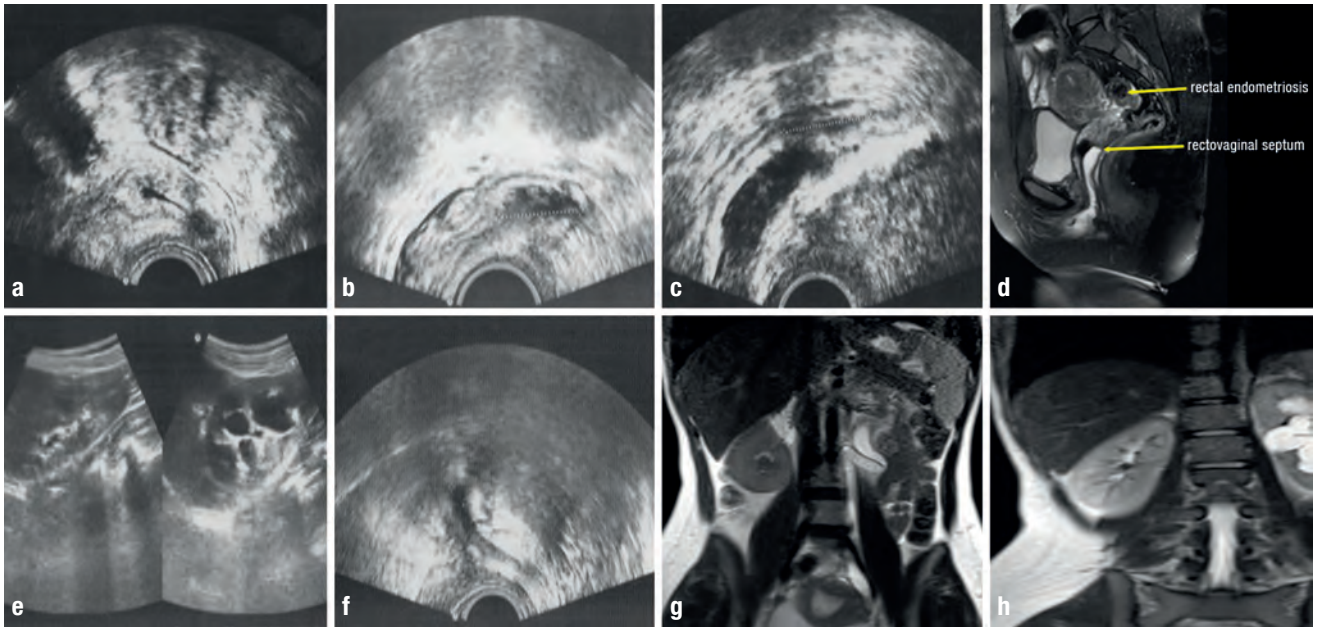
Key to acronyms: transvaginal sonography (TVS); transrectal sonography (TRS); magnetic resonance imaging (MRI), true positive (TP), true negative (TN); false positive (FP); false negative (FN); likelihood ratio positive (LR+); likelihood ratio negative (LR–).

### 2.5.3.2 Comparison of TVS, TRS, and MRI for the Visualization of DIE Lesions as a Whole

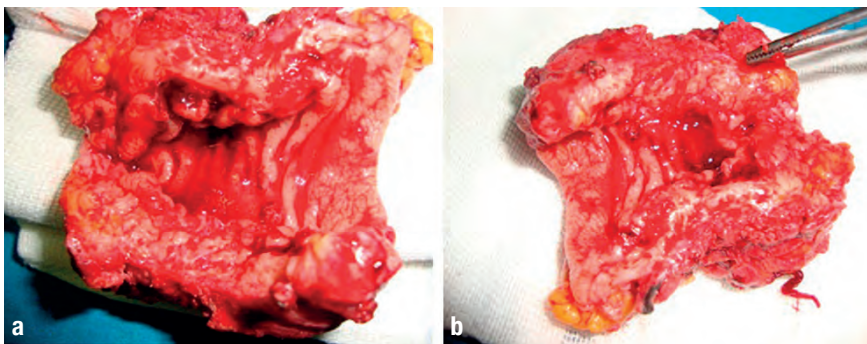
Regardless of lesion location, the sensitivity of TRS in the diagnosis of DIE lesions was comparable to that of TVS and MRI (81.1% vs. 80.1% and 77.9% respectively). MRI, TVS, and TRS had respective specificities of 97.1%, 96.6%, and 95.8%. The accuracy of TRS was similar to that of TVS and MRI (93.3% vs. 93.1% and 92.8%, respectively).

Fig. 2.88 presents some snapshots from the sonographic and MR imaging of DIE in the rectal wall (a–d) and ureter (e–h). Figs. 2.89–2.92 illustrate the visual and imaging appearances of DIE at different anatomic sites using various techniques. Table 2.9 compares the results of TVS vs. TRS, TVS vs. MRI, and TRS vs. MRI in the diagnosis of DIE at various sites.

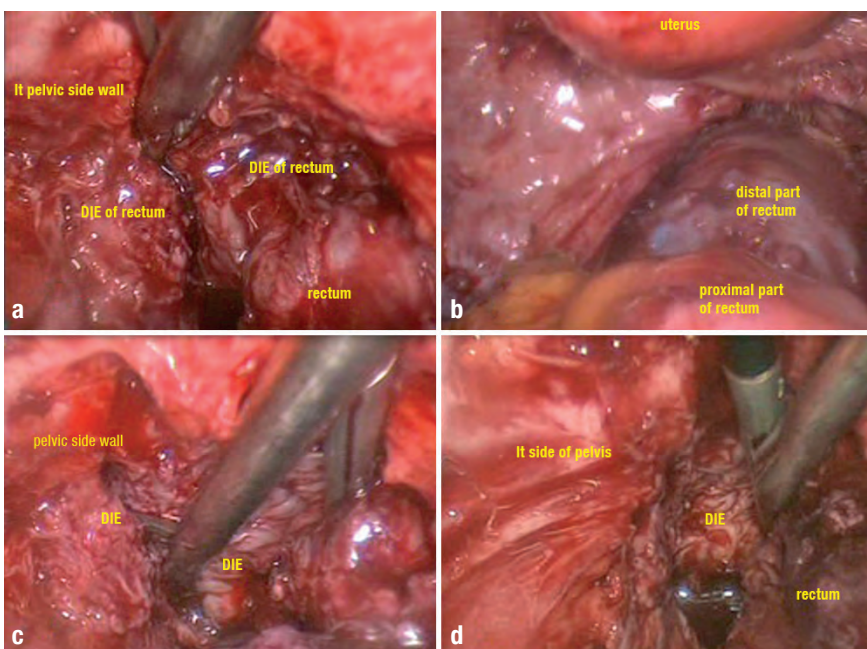




**Fig. 2.88** Transvaginal sonography (TVS) suggesting DIE of the rectovaginal septum =. TVS, TRS, renal ultrasound, and MR images consistent with involvement of the rectal wall (b–d) and ureter (e–h) by DIE.

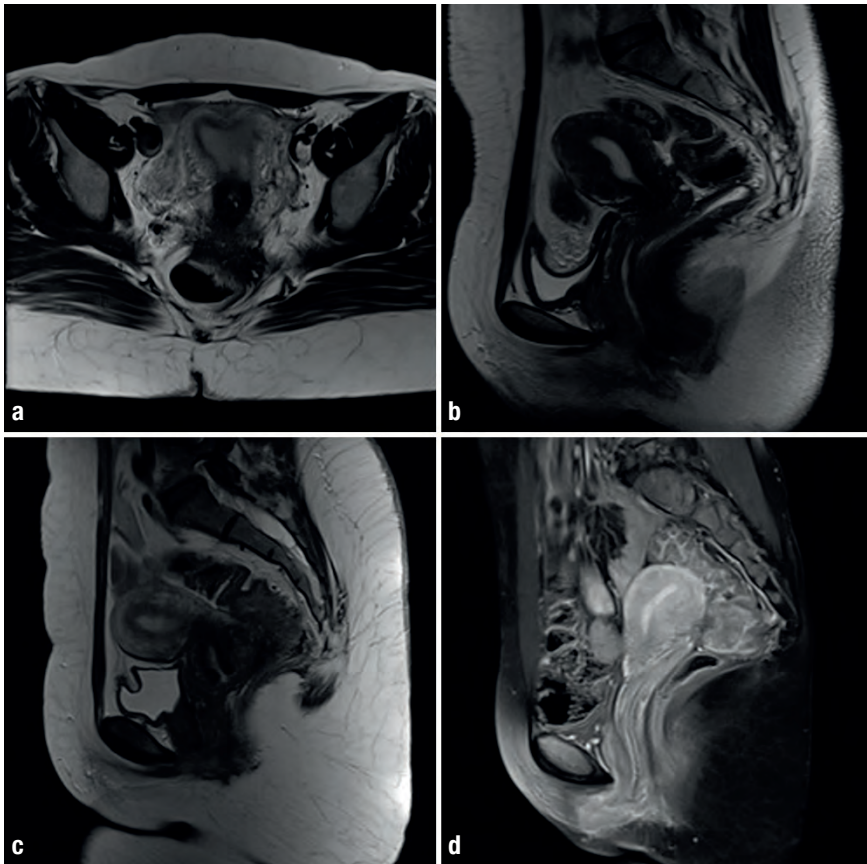


**Fig. 2.89** Macroscopic view of extracted specimens. Involvement of rectal wall by DIE (mucosal layer is intact) (a, b).



**Fig. 2.90** DIE of the rectum extending to the left pelvis as far as the periosteal layer (a–c). Reanastomosis of the rectum with a circular stapler (d).



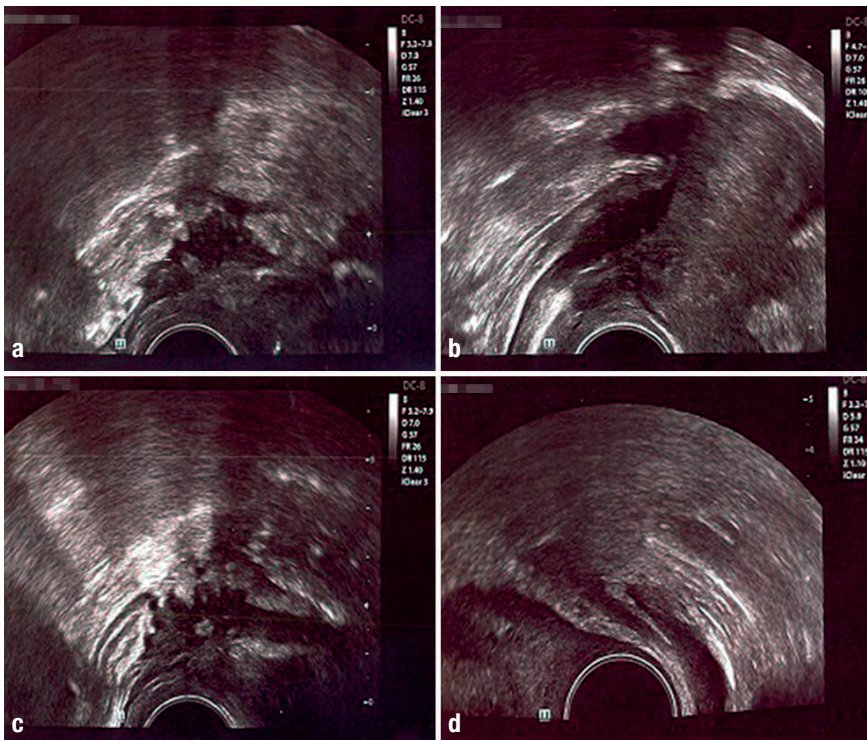


**Fig. 2.91** Involvement of the rectal wall and posterior cul-de-sac (coronal T2-weighted MRI, **a**).

Endometriotic involvement of the anterior rectal wall and posterior cul-de-sac (sagittal MRI, **b**).

Endometriotic involvement of the anterior rectal wall without DIE of cul-de-sac (sagittal MRI, **c**).

Endometriotic involvement of the retrocervical area and anterior rectal wall (sagittal MRI, **d**).



**Fig. 2.92** TVS image; DIE of the rectal wall (**a**).

TVS image; DIE of the anterior rectal wall (**b**).

TRS image; DIE of the anterior rectal wall (**c**).

TRS image; hydroureter, catheterized (**d**).

		TVS	TRS	P value	CI	TVS	MRI	P value	CI	TRS	MRI	P value	CI
Sensitivity	Uterosacral ligaments	70.86	82.78	0.001	-0.04 to 0.16	70.86	63.58	0.229	-0.41 to 0.18	82.78	63.58	<0.001	-0.1 to 0.25
	Ovarian fossa	62.71	64.41	1	-0.13 to 0.16	62.71	66.1	0.84	-0.14 to 0.20	64.41	66.1	1	-0.15 to 0.18
	Retrocervical	52.63	50	1	-0.09 to 0.11	52.63	65.79	0.40	-0.13 to 0.36	50	65.79	0.26	-0.09 to 0.36
	Rectovaginal septum	86.36	84.09	1	-0.11 to 0.14	86.36	72.73	0.21	-0.06 to 0.28	84.09	72.73	0.33	-0.09 to 0.27
	Rectal wall	88.46	86.54	1	-0.012 to 0.019	88.46	76.92	0.109	-0.02 to 0.18	86.54	76.92	0.22	-0.04 to 0.18
	Bladder	100	100	1	-	100	100	1	-	100	100	1	-
	Ureter	100	100	1	-	100	100	1	-	100	100	1	-
Specificity	Uterosacral ligaments	92.77	89.76	0.063	-0.001 to 0.03	92.77	93.98	0.81	-0.04 to 0.06	89.76	93.98	0.118	-0.009 to 0.07
	Ovarian fossa	95.74	93.41	0.109	-0.004 to 0.03	95.74	98.06	0.109	-0.04 to 0.03	93.41	98.6	0.0005	-0.02 to 0.04
	Retrocervical area	94.62	96.06	0.344	-0.01 to 0.03	94.62	96.42	0.405	-0.001 to 0.04	96.06	96.42	1	-0.02 to 0.03
	Rectovaginal septum	94.87	93.77	0.508	-0.01 to 0.02	94.87	95.24	1	-0.032 to 0.039	93.77	95.24	0.541	-0.02 to 0.04
	Rectal wall	98.87	97.74	0.375	-0.008 to 0.01	98.87	96.6	0.07	-0.001 to 0.02	97.74	96.6	0.508	-0.01 to 0.02
	Bladder	99.68	99.68	1	-	99.68	99.68	1	-	99.68	99.68	1	-
	Ureter	100	100	1	-	100	100	1	-	100	100	1	-

**Table 2.9** Comparison of the results of TVS vs. TRS, TVS vs. MRI, and TRS vs. MRI for the diagnosis of DIE at various anatomic sites. Key to acronyms: transvaginal sonography (TVS); transrectal sonography (TRS); magnetic resonance imaging (MRI); confidence interval (CI).

### 2.5.4 Discussion

The present results have added new insights for selecting the most appropriate imaging modalities for diagnosis and preoperative planning in patients with suspected DIE. Earlier studies assessed the performance capabilities of each modality, but we believe that our study has numerous advantages over previous research. These advantages include a large sample population, which enabled us to compare the results of TVS, TRS, and MRI and classify the results according to lesion location. In our view, these advantages should encourage gynecologists to revisit previous data.

Once a diagnosis of DIE is suspected in a woman of childbearing age, it should then be asked, “Which imaging modality is most appropriate for confirming the diagnosis of DIE?” At our tertiary center, three main options are currently available and are routinely employed for identifying these lesions prior to surgery: TVS, TRS, and pelvic MRI. Our findings documented the comparable sensitivities of these three modalities for the preoperative diagnosis of DIE. TVS was found to be a useful test in the diagnosis of rectal wall DIE. MRI yielded more favorable results for certain sites such as the ovarian fossa and retrocervical area. This may relate to the limited accessibility of these regions to ultrasound. On the other hand, TVS, TRS and MRI were found to yield similar results for bladder and ureteral involvement by DIE.

The performance of each diagnostic modality was compared against the results of operative laparoscopy, for DIE as a

whole, and for different sites of involvement. For lesions in the uterosacral ligament, which is the most common site comprising 43% of all lesions, TRS demonstrated better sensitivity than TVS and MRI, with a lower miss rate. TRS was superior for lesions involving the uterosacral ligament. Our findings are consistent with an earlier report<sup>19</sup> on the performance of MRI in detecting DIE lesions within the uterosacral ligaments (sensitivity of 63.5%, specificity of 93.9%, PPV 90.5 and NPV 73.9%, miss rate of 0.36, accuracy of 79.5%, LR+ of 10.55 and LR- of 0.39). Our results also agree with the sensitivity and likelihood ratios found in another study on the ability of MRI to detect DIE of the uterosacral ligaments.<sup>9</sup>

With regard to retrocervical lesions, *Abrao et al.* found that TVS had better sensitivity, specificity, NPV, PPV, and accuracy than MRI.<sup>1</sup> By contrast, our study found that MRI performed better than TVS (sensitivity of 65.8% vs. 52.6%, specificity of 96.4 vs. 94.6%, PPV of 71.4 vs. 57.1%, NPV of 95.4 vs. 93.6%, miss rate of 0.34 vs. 0.47, and accuracy of 92.7 vs. 89.6%, respectively). Such a disparity in results may be due at least in part to a notable difference in sample size.

For DIE lesions within the rectovaginal septum, unlike a previous study which found MRI to be superior to TVS,<sup>9</sup> we found that TVS had a higher sensitivity, accuracy, likelihood ratio, and a lower miss rate than MRI in the detection of DIE (sensitivity of 86.4% and 72.7%, PPV of 73% and 71.1%, NPV of 97.7% and 95.6%, miss rates of 0.14 and 0.27,



accuracy of 93.7% and 92.1%, LR+ of 16.8 and 15.27, LR- of 0.14 and 0.29, respectively). On the other hand, MRI was found to have higher specificity than TVS (95.2% vs. 94.9%). In a recent investigation of an ultrasound mapping system for the surgical management of DIE, TVS was found to have a sensitivity of 73.9%, specificity of 86.2%, PPV of 80.9%, and NPV of 80.7% for DIE lesions.<sup>16</sup> Our results for rectal DIE were similar to those of *Bazot et al.*,<sup>9</sup> indicating that TVS achieved better sensitivity and specificity than MRI (88.46% and 98.87% for TVS vs. 76.92% and 96.6% for MRI).

Regarding bladder DIE, our study suggested similar results for all three modalities. *Fedele et al.* reported that TVS was superior to MRI and transabdominal sonography in determining lesion location, but these authors had a small study population and their investigation dates back to the time when the use of these modalities for the diagnosis of DIE were in their prime.<sup>16,17</sup> Meanwhile, our findings were in agreement with other reports<sup>8,9,11</sup> identifying TVS as an accurate method for the diagnosis of DIE in the bladder. An earlier study by *Grasso et al.*<sup>19</sup> found that MRI had a sensitivity of 83.3%, specificity of 100%, PPV of 100%, and NPV of 92.5% in the detection of bladder DIE, while our study indicated a higher sensitivity (100%) and lower precision (PPV) of 80% for this application. According to *Balleyguier et al.*, MRI yields more accurate results than TVS in detecting DIE lesions of the bladder, especially for posterior DIE with deep extension and for small lesions missed by TVS.<sup>7</sup> Our study supported the findings of a recent investigation reporting a sensitivity of 100%, specificity of 96.8%, PPV of 72.7%, and NPV of 100% for TVS.<sup>16</sup>

The 100% sensitivity of TVS, TRS, and MRI for the detection of ureteral DIE observed in our study did not agree with the results of *Chamie* and *Grasso* (MRI sensitivity of 66.6% and 50%, respectively).<sup>14,19</sup>

*Bazot et al.* suggested using TVS as a first-line screening study and saving MRI for symptomatic women with normal TVS findings, and ultimately using TRS for individuals with discrepant results on TVS and MRI.<sup>9</sup> Interestingly, our results indicate that TRS has comparable sensitivity to TVS and MRI in the diagnosis of DIE lesions based on its overall performance (sensitivities of 81.1%, 80.1%, and 77.9%, respectively).

Because TRS is less costly than MRI but provides comparable sensitivity, it may be considered a modality of choice for the diagnosis of DIE prior to MRI. Moreover, since the use of TVS is contraindicated for virgin subjects in our practice, we propose TRS as a reasonable alternative for diagnosing DIE when a transvaginal approach is not available or acceptable.

### 2.5.5 Conclusion

Although TVS is among the preferred imaging modalities for the preoperative assessment of DIE lesions, we conclude that TRS, when performed by an experienced gynecologist, can provide similar sensitivity and acceptable specificity in the diagnosis of DIE. Given the comparable performance of TVS and TRS in diagnosing DIE and their availability and affordability compared with MRI, they are both viewed as

reasonable diagnostic options. Moreover, TRS is suggested as the method of choice for virgin individuals in whom TVS would be unacceptable. MRI should be considered as a complementary modality in patients with suspected involvement of the ovarian fossa and ureter by DIE.

### 2.5.6 References

1. ABRAO MS, GONCALVES MO, DIAS JA JR, PODGAEC S, CHAMIE LP, BLASBALG R. Comparison between clinical examination, transvaginal sonography and magnetic resonance imaging for the diagnosis of deep endometriosis. *Hum Reprod* 2007;22(12):3092–7. doi:10.1093/humrep/dem187.
2. ALBORZI S. A comparison of pelvic magnetic resonance imaging, trans-vaginal and trans-rectal sonography with laparoscopic findings in diagnosis of deep infiltrating endometriosis: Presented at 16th Congress on Reproductive Biomedicine and 11th Congress on Stem Cell Biology and Technology, Tehran, Iran, 2–4, September, 2015. *International Journal of Fertility and Sterility* Volume 2015;9(Supplement 1):33.
3. ALBORZI S. A comparison of pelvic magnetic resonance imaging, trans-vaginal and trans-rectal sonography with laparoscopic findings in diagnosis of deep infiltrating endometriosis: Presented at 2nd Congress of the Society of Endometriosis and Uterine Disorders (SEUD) 12–14, May 2016. [8, July 2016]; Available from: [http://seud-congress.com/files/107/COMM\\_2015/SAMEDI/G/06.-saeed-alborzi.pdf](http://seud-congress.com/files/107/COMM_2015/SAMEDI/G/06.-saeed-alborzi.pdf).
4. ALBORZI S, KERAMATI P, YOUNESI M, SAMSAMI A, DADRAS N. The impact of laparoscopic cystectomy on ovarian reserve in patients with unilateral and bilateral endometriomas. *Fertil Steril* 2014;101(2):427–34. doi:10.1016/j.fertnstert.2013.10.019.
5. ALBORZI S, MOMTAHAN M, PARSANEZHAD ME, DEHBASHI S, ZOLGHADRI J. A prospective, randomized study comparing laparoscopic ovarian cystectomy versus fenestration and coagulation in patients with endometriomas. *Fertil Steril* 2004;82(6):1633–7. doi:10.1016/j.fertnstert.2004.04.067.
6. AMERICAN FERTILITY SOCIETY. rAFS Classification of Endometriosis: 1985. *Fertil Steril* 1985;43(3):351–2.
7. BALLEYGUIER C, CHAPRON C, DUBUISSON JB, KINKEL K, FAUCONNIER A, VIEIRA M et al. Comparison of magnetic resonance imaging and transvaginal ultrasonography in diagnosing bladder endometriosis. *J Am Assoc Gynecol Laparosc* 2002;9(1):15–23.
8. BAZOT M, DETCHEV R, CORTEZ A, AMOUYAL P, UZAN S, DARAI E. Transvaginal sonography and rectal endoscopic sonography for the assessment of pelvic endometriosis: a preliminary comparison. *Hum Reprod* 2003;18(8):1686–92.
9. BAZOT M, LAFONT C, ROUZIER R, ROSEAU G, THOMASSIN-NAGGARA I, DARAI E. Diagnostic accuracy of physical examination, transvaginal sonography, rectal endoscopic sonography, and magnetic resonance imaging to diagnose deep infiltrating endometriosis. *Fertil Steril* 2009;92(6):1825–33. doi:10.1016/j.fertnstert.2008.09.005.
10. BAZOT M, MALZY P, CORTEZ A, ROSEAU G, AMOUYAL P, DARAI E. Accuracy of transvaginal sonography and rectal endoscopic sonography in the diagnosis of deep infiltrating endometriosis. *Ultrasound Obstet Gynecol* 2007;30(7):994–1001. doi:10.1002/uog.4070.
11. BAZOT M, THOMASSIN I, HOURANI R, CORTEZ A, DARAI E. Diagnostic accuracy of transvaginal sonography for deep pelvic endometriosis. *Ultrasound Obstet Gynecol* 2004;24(2):180–5. doi:10.1002/uog.1108.

12. BENACERRAF BR, GROSZMANN Y. Sonography should be the first imaging examination done to evaluate patients with suspected endometriosis. *J Ultrasound Med* 2012;31(4):651–3.
13. BENACERRAF BR, GROSZMANN Y, HORNSTEIN MD, BROMLEY B. Deep infiltrating endometriosis of the bowel wall: the comet sign. *J Ultrasound Med* 2015;34(3):537–42. doi:10.7863/ultra.34.3.537.
14. CHAMIE LP, BLASBALG R, GONCALVES MO, CARVALHO FM, ABRAO MS, OLIVEIRA IS DE. Accuracy of magnetic resonance imaging for diagnosis and preoperative assessment of deeply infiltrating endometriosis. *Int J Gynaecol Obstet* 2009;106(3):198–201. doi:10.1016/j.ijgo.2009.04.013.
15. COCCIA ME, RIZZELLO F. Ultrasonographic staging: a new staging system for deep endometriosis. *Ann N Y Acad Sci* 2011;1221:61–9. doi:10.1111/j.1749-6632.2011.05951.x.
16. EXACOUSTOS C, MALZONI M, DI GIOVANNI A, LAZZERI L, TOSTI C, PETRAGLIA F et al. Ultrasound mapping system for the surgical management of deep infiltrating endometriosis. *Fertil Steril* 2014;102(1):143–150.e2. doi:10.1016/j.fertnstert.2014.03.043.
17. FEDELE L, BIANCHI S, RAFFAELLI R, PORTUESE A. Pre-operative assessment of bladder endometriosis. *Hum Reprod* 1997;12(11):2519–22.
18. GONCALVES MO, DIAS JA JR, PODGAEC S, AVERBACH M, ABRAO MS. Transvaginal ultrasound for diagnosis of deeply infiltrating endometriosis. *Int J Gynaecol Obstet* 2009;104(2):156–60. doi:10.1016/j.ijgo.2008.10.005.
19. GRASSO RF, DI GIACOMO V, SEDATI P, SIZZI O, FLORIO G, FAIELLA E et al. Diagnosis of deep infiltrating endometriosis: accuracy of magnetic resonance imaging and transvaginal 3D ultrasonography. *Abdom Imaging* 2010;35(6):716–25. doi:10.1007/s00261-009-9587-7.
20. SIDDIQUI AA, FAYIGA Y, HUERTA S. The role of endoscopic ultrasound in the evaluation of rectal cancer. *Int Semin Surg Oncol* 2006;3:36. doi:10.1186/1477-7800-3-36.
21. VIMERCATI A, ACHILARRE MT, SCARDAPANE A, LORUSSO F, CECI O, MANGIATORDI G et al. Accuracy of transvaginal sonography and contrast-enhanced magnetic resonance-colonography for the presurgical staging of deep infiltrating endometriosis. *Ultrasound Obstet Gynecol* 2012;40(5):592–603. doi:10.1002/uog.11179.

## 2.6

## Ultrasound Imaging in the Diagnosis of Deep Infiltrating Endometriosis (DIE) and Adenomyosis

Caterina Exacoustos<sup>a</sup>

### 2.6.1 Introduction

Endometriosis usually appears in three different forms: ovarian endometriosis (endometrioma), peritoneal endometriosis and adhesions and deep endometriosis. Pelvic endometriosis, especially in severe stages, is strongly associated with adenomyosis, a condition which plays an important role in that it accounts for dysmenorrhea, menorrhagia and infertility in women diagnosed with endometriosis.

The ovaries are the prevalent predilection area for endometriotic lesions, typically presenting as ovarian cysts. Deep infiltrating endometriosis (DIE) is defined as an endometriotic lesion infiltrating the peritoneum and penetrating into the retroperitoneal space or the wall of the pelvic organs to a depth of at least 5 mm<sup>57</sup> and affects between 4 % and 37 % of patients with endometriosis. These different forms of presentation tend to appear in various imaging patterns that pose specific problems related to diagnostic imaging. Several scoring systems have been used to stage the extension of endometriosis also in relationship to different locations inside the pelvis. The most common classification system used to evaluate the disease is the revised scheme of the *American Society of Reproductive Medicine (rASRM)* which followed the *American Fertility Society (AFS)* scheme.<sup>5</sup> The rASRM classification scheme – as is the case with others – does not consider adenomyosis as part of the disease, which nonetheless continues to exist after surgical treatment of extra-uterine lesions, and still manifests with persistence of symptoms related to pelvic endometriosis.

The ENZIAN-classification<sup>90</sup> is based upon the anatomical distribution of the extraperitoneal lesions and is subdivided into four grades of disease depending on the size<sup>45</sup> and extent of disease. It is regarded as a supplement to the rASRM scheme and the classification is very precise regarding localization and severity of lesions. Moreover, it correlates to some extent with the symptoms,<sup>44</sup> but there is still controversy on whether the ENZIAN system or other classifications systems should be implemented in clinical routine.<sup>3</sup> Additional classification schemes, with minor modifications, have also been proposed.<sup>19,56</sup> However, a uniform classification system is needed, that is based on the findings obtained through

various imaging modalities for the purpose of systematic mapping of DIE according to location and extent of disease.

The main diagnostic problems related to endometriosis are as follows:

- Difficulty in detecting the disease, especially in the absence of endometriotic cysts or in case of minimal lesions.
- Evaluation of extension of disease, which is further complicated by the absence of an established reference for classification.

History and symptoms of the patients, pelvic examination together with the experience of the medical sonographer or radiologist, are major contributing factors in an attempt to further improve diagnostic accuracy of pelvic endometriosis.

In patients diagnosed with endometriosis, it is important to find out whether there is co-existent adenomyosis contributing to their pain and/or abnormal uterine bleeding symptoms. In patients undergoing surgery for endometriosis, prevalence of adenomyosis diagnosed by ultrasound, is reported to be 22 %. It has also been observed that DIE is strongly associated with adenomyosis.<sup>23,61,70</sup>

The correct diagnosis of pelvic endometriosis is instrumental in defining the best treatment strategy which is why non-invasive methods are required to establish an accurate diagnosis with regard to localization and extent of endometriotic lesions. Most commonly, two imaging modalities are used to identify and determine endometriotic lesions: *Transvaginal sonography (TVS)* and *magnetic resonance imaging (MRI)*.

*Transvaginal sonography (TVS)* has been proposed as the first-line imaging technique because it allows extensive exploration of the pelvis, it is well-tolerated by patients and widely available in practice.

Magnetic resonance imaging (MRI) is employed as a second-line modality in the examination of the female pelvis. The role of MRI in the evaluation of endometriosis, especially in the case of DIE, has been widely demonstrated. MRI is performed in selected patients as determined by the outcome of TVS and the severity of symptoms. Other diagnostic procedures like rectal sonography, barium enema or computed tomography-urography play complementary roles in the identification of endometriosis, depending on the site of disease, and may be used selectively for the decision-making on which surgical approach should be adopted. Transabdominal ultrasound does not provide for an adequately accurate detection of endometriosis, which is mainly due to bowel gas and adhesions hampering the chances to sufficiently evaluate pelvic organs. This particularly applies to DIE lesions of mainly retroperitoneal infiltration pattern, or to bowel lesions which are difficult to identify with transabdominal ultrasound.<sup>58</sup>

A detailed non-invasive examination of the pelvis evaluating the extension of endometriotic lesions can be very helpful in the decision-making with regard to both a safe and individualized, custom-made surgical or medical strategy planning.<sup>57</sup>

<sup>a</sup> | Professor, MD; 'Tor Vergata' University of Rome, Department of Biomedicine and Prevention, Obstetrics and Gynecological Clinic, Rome, Italy

#### Corresponding author:

Prof. **Caterina Exacoustos**

Università degli Studi di Roma 'Tor Vergata'

Dipartimento di biomedicina e prevenzione

Clinica di ginecologia e ostetricia

Viale Oxford 81,

00133 Roma, Italy

E-mail: caterinaexacoustos@tiscali.it



### 2.6.2 Ultrasound Diagnosis of Pelvic Endometriosis

Ovarian endometriomas are frequently associated with other endometriotic lesions<sup>20</sup> such as adhesions and deeply infiltrating endometriosis, which are difficult to diagnose. Underestimation of extensive adhesions in patients with endometriomas prior to surgery is considered one of the main factors contributing to incomplete surgical removal,<sup>20</sup> which often gives rise to the need for reoperation. Endoscopic surgery has permitted laparoscopic treatment of ovarian cysts, which in the past required laparotomy.<sup>72</sup> Laparoscopic management of ovarian endometriosis is the technique of first choice, however adhesions and DIE lesions still constitute the major limitation in adequate surgical treatment of endometriosis.<sup>72</sup> For obvious reasons, the impact of this limitation differs according to surgeon's experience and skills. Therefore, the author highly suggests that preoperative patient selection should be managed according to pelvic extension of the disease. Women diagnosed with severe disease and extensive adhesions should be referred to centres of excellence to ensure complete surgical excision, which can only be provided by adequately trained and educated personnel with a high level of laparoscopic surgical proficiency and experience.<sup>27</sup>

#### 2.6.2.1 Adhesions

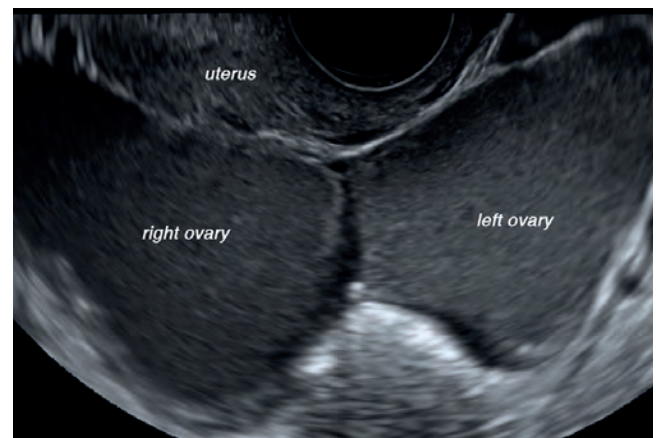
Endometriosis is often accompanied by the presence of pelvic adhesions. Ultrasound diagnosis of pelvic adhesions in patients with concomitant ovarian or peritoneal endometriosis actually poses a diagnostic challenge. This deadlock situation becomes particularly evident in cases with no clinically detectable ovarian endometriomas and coexistent endometriosis causing adhesions and small nodules in pelvic organs, which are very difficult – if not impossible – to recognize by ultrasound. It has been reported that peritoneal disease and adhesions are more common than ovarian disease.<sup>79</sup> Therefore, in patients suffering from infertility or chronic pelvic pain, it is important, – also in the absence of ovarian endometriomas – to look for sonographic signs of adhesions. Only a few studies have attempted to assess the diagnostic potential of transvaginal sonography in the detection and grading of pelvic adhesions in women with pelvic endometriosis.<sup>32,36,46,73</sup>

Under normal circumstances, uterus and ovaries are mobile and are not adherent to the surrounding tissues. On palpation with a probe and /or abdominal palpation with the hand, natural movements of these organs are viewed on ultrasound ('sliding sign'). Upon palpation with an ultrasound probe and /or abdominal palpation with the hand, absence of the 'sliding sign' allows to suspect that ovaries and/or uterus are adherent to adjacent structures (broad ligament, pouch of Douglas, bladder, rectum, and parietal peritoneum). Occasionally, in the presence of pelvic fluid, filmy septa or strands of tissue (adhesions) can be seen between the ovary, the endometrioma and uterus or the peritoneum of the pouch of Douglas.<sup>32,36,46,73</sup> Endometriomas are usually fixed posteriorly to the uterus, in the pouch of Douglas. Particularly in the case of bilateral endometrioma, this condition can cause both ovaries to become attached posteriorly to the uterus, and adherent to the contralateral ovary ('kissing ovaries') (Fig. 2.93). The inability to mobilise the ovary on palpation (fixed ovary)

and an increased distance between the ovary and the probe, which persists even after cessation of abdominal palpation,<sup>39</sup> are highly suggestive of ovarian adhesions to the lateral pelvic side wall.

Recently, preoperative diagnosis of partial or complete obliteration of the pouch of Douglas (POD) has been described.<sup>49,50,54,82</sup> The POD is examined using real-time ultrasound imaging to determine the presence or absence of POD obliteration with regard to the 'sliding sign'. In order to assess the 'sliding sign', gentle pressure is placed against the cervix with the transvaginal probe to establish whether the anterior rectum glides freely across the posterior aspect of the cervix (posterior cervical region) and posterior vaginal wall.

In studies, that assessed the diagnostic accuracy of transvaginal sonography in the detection of pelvic adhesions, severity of adhesions was classified as either minimal, moderate or severe in accordance with the rASRM classification.<sup>5</sup> In terms of sensitivity and specificity, the diagnostic accuracy of TVS in predicting stage 3 and 4 endometriosis including pelvic adhesions, compared to laparoscopy, was reported to be 86 % and 82 %, respectively, for stage 3 and 76 % and 91 %, respectively, for stage 4 disease.<sup>32</sup> *Guerrero et al.*<sup>36</sup> obtained a sensitivity and specificity of 89 % and 90 %, respectively, for fixation of the ovaries to the uterus. The real-time preoperative dynamic transvaginal ultrasound examination of POD obliteration, using the 'sliding sign' technique, seems to be useful in identifying women who are at increased risk for bowel endometriosis. *Hudelist et al.*<sup>49</sup> reported that a negative 'sliding sign' on transvaginal sonography predicted DIE of rectum with a sensitivity of 85 %, specificity of 96 % and an accuracy of 93.1 %. *Reid et al.*<sup>82</sup> demonstrated a sensitivity and specificity of 83.3 % and 97.1 %, respectively, for prediction of POD obliteration.<sup>49,82</sup> The inter- and intra-observer agreement and diagnostic accuracy of the TVS 'sliding sign' in the prediction of POD obliteration has been found to be acceptable, ranging from substantial to almost perfect agreement for observers who specialise in gynaecological ultrasound.<sup>65,81,82</sup>



**Fig. 2.93** Ultrasound image of bilateral endometriomas with both ovaries adherent to each other ('kissing ovaries') and posteriorly, to the uterus.

### 2.6.2.2 Hydrosalpinx

In the presence of pelvic endometriosis, the salpinges frequently can be involved by disease, which commonly manifests with adhesions altering the normal tubal course and occluding the tube, or with foci of DIE affecting the tubal walls. As a consequence, hydrosalpinx can be observed near the endometriotic lesion. In case of salpingeal endometriosis, a typical aspect of dilated Fallopian tube with wall thickening and incomplete septa is visible with a dense fluid content similar to that of endometrioma (hematosalpinx).<sup>89</sup> In case of tubal occlusion due to adhesion or DIE involving the distal tubal portion and the fimbrial extremities, hydrosalpinx is seen with the typical 'beads-on-a-string' sign, defined as hyperechoic mural nodules measuring about 2–3 mm and seen on the cross-section of the fluid-filled distended tube.<sup>89</sup> Considering that the presence of hydrosalpinx in infertile patients is an indication for surgical tubal removal,<sup>52</sup> the author emphasizes the need for a meticulous assessment of the tubal state in cases of endometrioma or DIE.

Endometriosis affecting ovary and tube, can result in a tubo-ovarian complex in which the ovaries and tubes are indeed identified and recognized on ultrasound, however the ovaries cannot be separated by pushing the tube with the vaginal probe.<sup>31</sup> It rarely occurs, that the normal architecture of one or both adnexa and tubes is not detectable, with formation of a conglomerate of endometrial cysts in which neither the ovary nor the tubes can be separately identified by ultrasound.<sup>89</sup>

### 2.6.2.3 Deep Infiltrating Endometriosis

Patients with suspected endometriotic disease should undergo a detailed systematic examination of the pelvis to evaluate the anatomy of the uterus and the adnexa, both in the sagittal and horizontal plane, using gentle probe movements to assess the presence of adhesions. A careful evaluation of all the painful sites is performed by applying gentle pressure with the probe ('tenderness-guided' ultrasonography).<sup>37</sup> The TVS examination is based on a detailed evaluation of organ and tissues dividing the pelvis in anterior and posterior compartments according to the DIE classification of *Chapron* and others.<sup>19,90</sup>

Taking into account that a slightly filled bladder has been shown to facilitate evaluation of the bladder walls for detection and delineation of endometriotic nodules, patients should be asked not to empty their bladder completely before the ultrasound examination. The transducer is positioned in the vaginal introitus and slowly withdrawn through the vagina to allow visualization of the urethra and the rectum. Subsequently, the transducer is positioned in the anterior vaginal fornix to visualize the bladder, uterus and cervix, and finally in the posterior vaginal fornix, which allows to evaluate the posterior pelvic compartment. Some authors advocate the use of bowel preparation to eliminate fecal residue and gas in the rectosigmoid,<sup>16,91</sup> however, this is not mandatory. In a recent meta-analysis, the use of TVS, either with or without bowel preparation, was found to be an accurate predictor of rectosigmoid DIE.<sup>48</sup> TVS is a highly accurate and reproducible method for non-invasive diagnosis of DIE when performed by well-trained staff.<sup>40,41</sup>

If the need arises, endometriotic nodules of the rectum may also be evaluated via the transrectal route using the same transvaginal convex probe. This offers the advantage of improved visualization of the vagina, recto-vaginal septum and inferior rectal walls. During transrectal examination, a fluid contrast medium can be inserted in the vagina to enhance delineation of the rectovaginal septum (sonovaginography).<sup>21</sup> It has been reported that adding water contrast in the rectum during transvaginal ultrasonography (RWC-TVS) improves the diagnosis of rectal infiltration in women with rectovaginal endometriosis.<sup>67,91</sup> The method is based on the injection of saline solution through a catheter into the rectal lumen under ultrasonographic control.

Three dimensional (3D) transvaginal sonography has been also proposed for evaluation of posterior locations of DIE without intestinal involvement in order to improve the diagnostic accuracy of 2D ultrasonography.<sup>42</sup> One research team reported introital 3D ultrasonography to be an effective and reproducible method for detecting and delineating endometriosis in the RVS.<sup>43,74</sup> However, there are only few studies available, which demonstrate that 3D ultrasound is superior to 2D ultrasound in the detection or characterization of DIE.

Transabdominal ultrasound does not allow for an adequately accurate detection of DIE, which is mainly due to bowel gases diminishing the chances to sufficiently evaluate abdominal retroperitoneal or small bowel lesions. Only endometriotic nodules of the abdominal wall can be easily evaluated by using a high-frequency transabdominal probe.

In the presence of DIE, it is essential to undertake a systematic evaluation in order to elicit details of anatomical localization, size and number of DIE nodules, depth of infiltration of the nodules and the degree to which the bowel lumen appears to be stenosed. All these aspects are of vital importance in the planning of surgical procedures, accurate counseling of patients and proper selection of the members of the surgical team.

With the aid of transvaginal ultrasound, an accurate assessment should cover the vagina, particularly the areas of the posterior and lateral vaginal fornices, the retrocervical area with torus uterinus and uterosacral ligaments, and the rectovaginal septum. In the presence of endometriotic lesions on the uterosacral ligaments and homolateral parametria, special attention should be paid to evaluation of the ureter in the paracervical tract. In order to assess rectal wall infiltration, if suspected, transrectal evaluation, using a TVS probe, may be performed. Particular care should be given to the patient's pain sensations in order to carefully evaluate all sites of specific tenderness noticeable during application of gentle pressure with the probe ('tenderness-guided' ultrasonography).<sup>37</sup>

### 2.6.3 Ultrasonographic Mapping for Pelvic DIE

#### 2.6.3.1 DIE of Anterior Compartment (Bladder)

**Bladder:** Patients are invited **not** to empty the bladder completely before the TVS scan. A slightly filled bladder facilitates evaluation of the structural pattern of the walls and the detection of endometriotic nodules.<sup>29</sup> Nodules appear as hypoechoic linear or circular lesions with or without cystic areas and regular/irregular margins of the bladder wall, bulging into the lumen, involving the serosa, muscularis (most common) or (sub)mucosa of the bladder.<sup>8,34,37,47,86</sup>

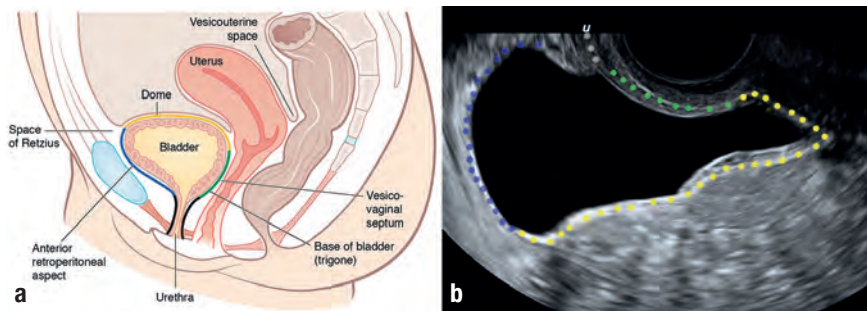
For assessment of DIE of the bladder, the condition is classified according to the area of the bladder wall involved by disease:

- The trigonal zone or vesical base.
- The vesical dome (lying superior to the trigone, at an intra-abdominal location).
- The anterior retro-peritoneal bladder.

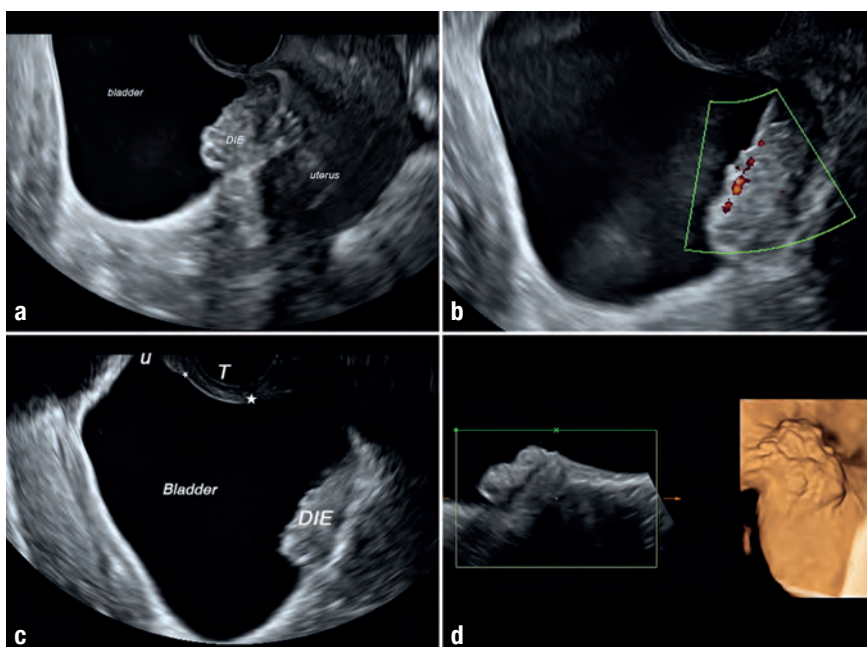
On TVS, the trigone appears as bright thickening of the bladder wall, noticeable within 3 cm of the urethral opening, laterally delimited by the two ureteral orifices (Figs. 2.94, 2.95).

Most frequently, bladder endometriosis is located in the vesical dome on the posterior bladder wall close to the vesico-uterine pouch. The dimensions of the nodule should be recorded as well as the distance between the nodule and the ureters and the trigone.

Evaluation of bladder adhesions of the vesico-uterine pouch must include the presence/absence of the 'sliding sign' between uterus and bladder. Bladder endometriosis is considered only in cases where the disease has infiltrated the bladder wall, but not in the presence of adhesions or superficial peritoneal implants on the bladder serosa.



**Fig. 2.94a,b** Schematic drawing of the bladder showing the three bladder zones: trigone (green), vesical dome (yellow) and retro-peritoneal bladder (blue) (a). Transvaginal ultrasound scan of the bladder showing the three bladder zones: urethra (u), trigone (green), vesical dome (yellow) and retroperitoneal bladder (blue) (b).



**Fig. 2.95a-d** Ultrasound image of an endometriotic bladder nodule. The slightly filled bladder allows to visualize the irregular margins of the hyperechoic lesion bulging into the lumen of the bladder, infiltrating the wall of the bladder dome. The nodule is attached to the uterine anterior wall (a). The same bladder lesion is evaluated by power Doppler showing only few vessels inside the lesion (b). The distance from the trigone (T) can be evaluated (c). The 3D evaluation shows an irregular surface without infiltration of the mucosa (d).



### 2.6.3.2 DIE of the Lateral Compartment

**Parametria:** In case of endometriotic lesions involving the uterosacral ligament, special attention must be paid to the parametrium and to the pelvic portion of the ureter, particularly in the paracervical area. The parametria are examined lateral to the uterine cervix, at first on the sagittal plane, with the probe moving from a lateral site, where the parametrium is attached to the cervix, to the bifurcation of uterine vessels, to the lateral pelvic wall and then, on transverse plane, scanning from the uterine isthmus to the external cervical os. Parametrial involvement is seen as an infiltrating hypoechoic irregular tissue, which can be medially distinguished from the cervical vascular plexuses with the aid of color or power Doppler.

**Ureter:** Endometriosis of the ureter usually arises by extension from pelvic foci and ovarian endometriosis.<sup>34</sup> The prevalence of ureteral endometriosis ranges from 0.01% to 1% of all patients affected by the disease and most often involves the distal segment of the ureter.<sup>64</sup> There are two types of endometriotic involvement of ureters:

- Extrinsic involvement accounts for 75–80% of cases and is defined as the presence of endometrial tissue in the outer adventitia of the ureter, which manifests as a nodule encasing the ureter by extension from pelvic foci;
- Intrinsic involvement accounts for 20–25% of cases and is defined as the presence of endometrial tissue in the mucosal and/or muscular layer of the ureter. Ultrasound imaging signs are nodular lesions or a mass seen along the course of the ureter, dilatation of the pelvic ureteral tract or ureteropelvic hydronephrosis superior to the suspected lesion.

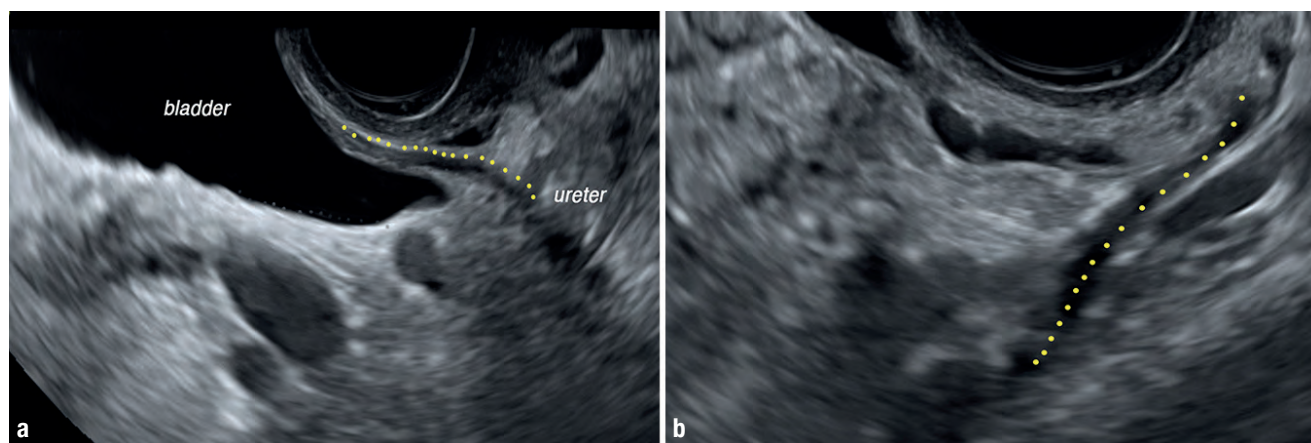
Extrinsic ureteral compression is treated by ureterolysis whereas segmental resection and re-anastomosis is indicated in cases of intrinsic localization of the disease. Therefore, an accurate evaluation of the urinary tract, often complemented by computed tomography or MRI urography, is needed in those cases where TVS raises the suspicion of ureteral involvement.

Pelvic ureteral dilation is readily detectable on transvaginal ultrasound as a tubular anechoic pattern with or without movements in the parametrial tissue, very similar to those of a blood vessel, but with negative color/power Doppler signs. In cases of extrinsic compression without stenosis of the ureter, it can be difficult to establish a diagnosis merely on the basis of TVS. The distal portion of the ureter can be identified adjacent to the bladder trigone, and followed laterally to the cervix, to the pelvic brim and to the level where it crosses the common iliac vessels<sup>76</sup> (Fig. 2.96). An extrinsic compression, also without ureteral dilatation, can be suspected in those cases where a DIE lesion is located close to the ureter.

In all women with DIE, a transabdominal ultrasound scan of the kidney to search for ureteral stenosis is required, taking into account that the prevalence of endometriotic lesions in the urinary tract may be underestimated and women with DIE involving the ureter may be asymptomatic.<sup>15,55,80</sup>

### 2.6.3.3 DIE of the Posterior Compartment

**Vagina:** DIE of the vagina is seen as a nodular thickening of the vaginal wall that does not become thinner with probe compression. The nodule may be hypoechoic, homogeneous or inhomogeneous with or without cystic areas and there may also be some signs of vascularization on power Doppler, more than those of a nodule viewed at another site. More frequently, lesions are localized in the posterior vaginal fornix and, owing to the compression caused by the probe, they can be misdiagnosed. The injection of saline solution in the vagina (sonovaginography) has proven to facilitate visualization of these lesions.<sup>12</sup> Improved detection of DIE of the posterior vagina may also be achieved by increasing the amount of ultrasonographic gel inside the probe's cover, resulting in enhanced visualization of vaginal walls as well as posterior and anterior fornix.<sup>38</sup> The low accuracy of transvaginal sonography in detecting vaginal endometriosis reported in published studies,<sup>50,88</sup> allows to conclude that a digital gynaecological examination should rather be performed than transvaginal sonography (Figs. 2.97, 2.98).

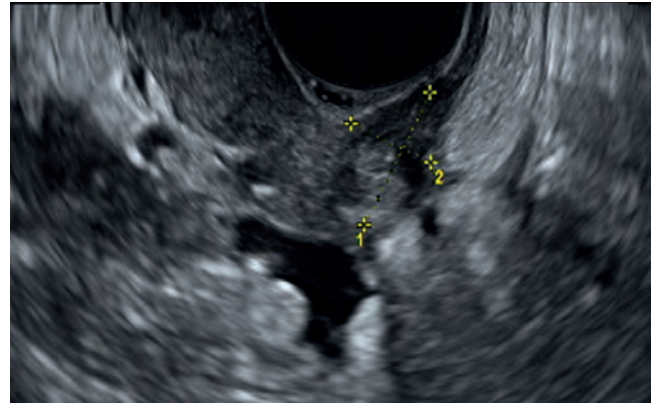


**Fig. 2.96a, b** Ultrasound image of a normal ureter seen by transvaginal ultrasound (yellow dots). Intramural part (a). Pelvic segment (b).

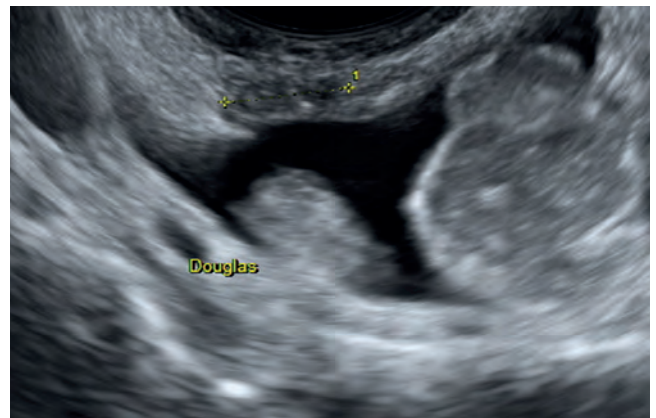**Recto-vaginal septum (RVS):** The rectovaginal space is the anatomical layer between the posterior vagina and anterior rectum.<sup>30</sup> The roof of this layer is formed by the peritoneum of the pouch of Douglas whereas the inferior boundary is at the level of the perineum. On ultrasound, in case of DIE of the RVS, lesions manifest with hypoechoic instead of hyperechoic appearance of this layer. Considering that the RVS is very thin, a solitary DIE nodule at this anatomical site is of very rare occurrence, whereas DIE of the vagina and lower tract of the rectum is seen more frequently. Occasionally, sonographic identification of the peritoneum of the pouch of Douglas can be difficult, which is particularly true in case of adhesions and coexistent DIE. As a result, the exact site of DIE between rectum and vagina may not always be determined. Various sonographic landmarks have been proposed to improve identification of the upper roof of the RVS (below the inferior boundary of the posterior cervical lip in mid-sagittal plane or below a plane that passes through the USL). Indeed, for the purpose of preoperative mapping of DIE, it may simply suffice to note that the lesion is located below the peritoneum between vagina and rectum. In general, DIE of the RVS has been described as endometriotic lesions that mainly invade the RVS with potential extension to the rectum and/or to the posterior vaginal fornix.

**Uterosacral ligaments (USL):** Normal USLs are usually not visible on ultrasound. Deeply infiltrating lesions of the USL can be seen in the longitudinal view of the uterus at the site of insertion on the postero-lateral cervical wall, appearing as a nodule with regular or stellate margins or in the form of a hypoechoic linear thickening. On transverse cervical section, these hypoechoic nodules can be visualized in the postero-lateral part of the cervix, disrupting the hyperchoic appearance of the external cervical fascia. Deeply infiltrating lesions of the USL are visualized best by placing the transvaginal probe in the posterior vaginal fornix in the midline in sagittal plane and then sweeping the probe infero-laterally to the cervix (Fig. 2.99).

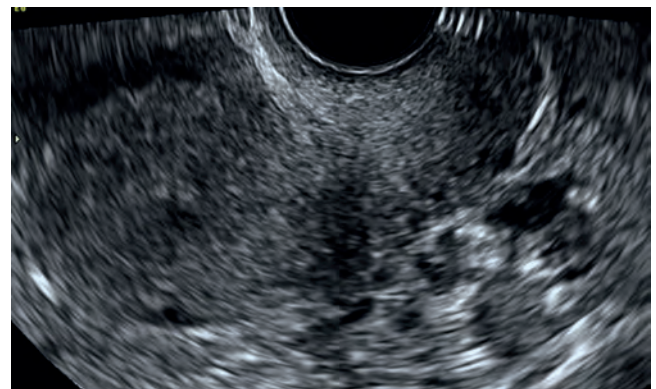Lesions of the USLs can be localized or can be part of a larger nodule extending into the vagina or into other surrounding structures. The thickness of a 'thickened' USL can be measured at the insertion of the ligament on the cervix provided that the ligament can be clearly distinguished from adjacent structures. In some cases, a deeply infiltrating lesion involving the USL is located at the torus uterinum. If this is the case, it is seen as a central thickening of the retrocervical area between both USLs.<sup>8,29,30</sup>



**Fig. 2.97** Transvaginal ultrasound appearance of an isolated nodule of DIE in the rectal vaginal septum and posterior vaginal fornix. Note the signs of fluid in the pouch of Douglas, not infiltrated by DIE.



**Fig. 2.98** Transvaginal ultrasound appearance of an isolated DIE nodule of the vaginal wall in the posterior fornix. Note the signs of fluid in the pouch of Douglas, not infiltrated by DIE.



**Fig. 2.99** Transvaginal ultrasound appearance of a nodule of DIE of the uterosacral ligament. Note the hypoechoic tissue beyond the cervix at the level of the internal cervical os.



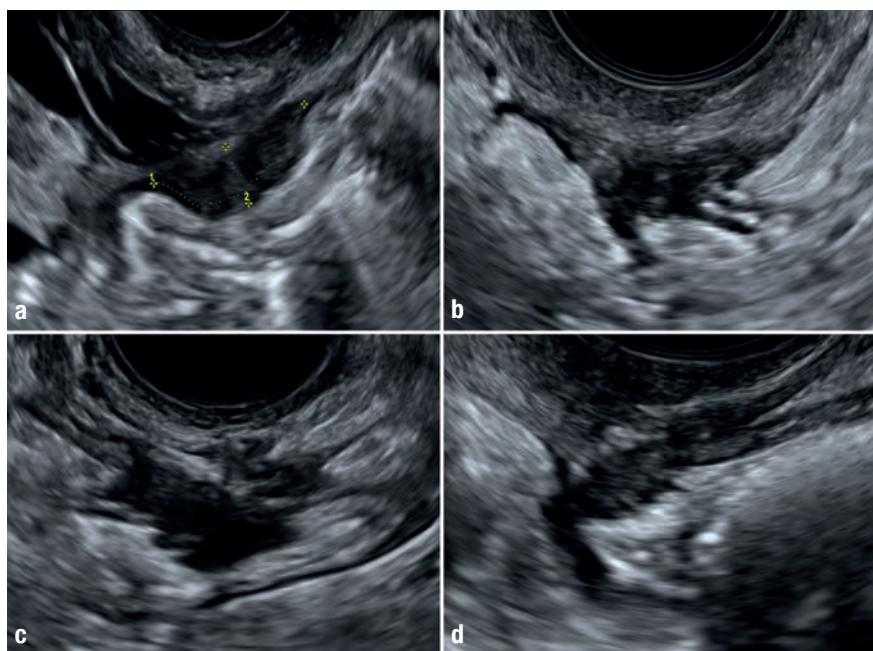
**Rectum and recto-sigmoid junction:** The rectum and the recto-sigmoid segment is a predilection area of bowel involvement accounting for 70–88% of cases of bowel endometriosis, followed by the sigmoid colon, rectum, ileum, appendix and cecum. Endometrial glands and stroma are found to invade the bowel growing from the serosa into the muscularis propria and become surrounded by smooth muscle hyperplasia and fibrosis, which can produce mural thickening and stenosis, but rarely involves the submucosa or mucosa.<sup>57</sup> Deep nodes appear as hypoechoic lesions, linear or nodular retroperitoneal thickening with irregular borders, and with sparse vessels at power Doppler evaluation,<sup>1,8,29,30,77</sup> on which nodules appear as irregular hypoechoic mass penetrating into the intestinal wall and distorting its normal structure (Fig. 2.100).

At transvaginal sonography, the normal rectal wall layers are seen: the rectal serosa and smooth muscle layer appear as a thin, hypoechoic line covered by the rectal submucosa and mucosa which is visualized as a hyperechoic rim covering the rectal smooth muscle layer.<sup>51</sup> With respect to the posterior uterine wall, intestinal nodules located below the peritoneum of the pouch of Douglas (or at the level of the insertion of the USLs on the cervix, in case the POD is obliterated) are defined as low rectal lesions, while the ones above this level

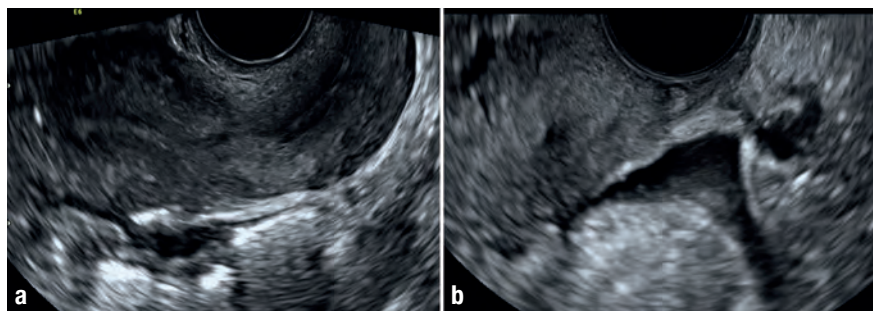
are termed upper rectal or recto-sigmoid junction lesions. The virtual plane of reference runs beneath the peritoneum of the pouch of Douglas and reaches laterally to the parametria and medially to the recto-vaginal septum<sup>4</sup> (Fig. 2.101). The diameter (longitudinal, transversal and antero-posterior) of each lesion should be noted, even if its irregular margin may not allow for an adequately accurate measurement.

The most inferior site of the nodule should be determined on the bowel wall, because surgical removal of low rectal lesions by shaving or segmental resection can be more difficult, and apart from that, is associated with a high complication rate.<sup>57</sup> The distance from the anus can be assessed by transrectal sonography, positioning the tip of the probe on the endometriotic lesion and evaluating the distance from the anal opening on the outside of the body to the tip of the probe.

Sonographic evaluation should also include the number of lesions detected on the bowel. Multifocal lesions are defined as deep lesions located within a circumference of 2 cm from the main lesions, or as multiple endometriotic lesions involving the same area. Multicentric involvement is defined as a satellite deep nodule visible at more than 2 cm from the main lesions or as endometriotic lesions infiltrating several digestive segments<sup>2,9,18</sup> (Fig. 2.102).

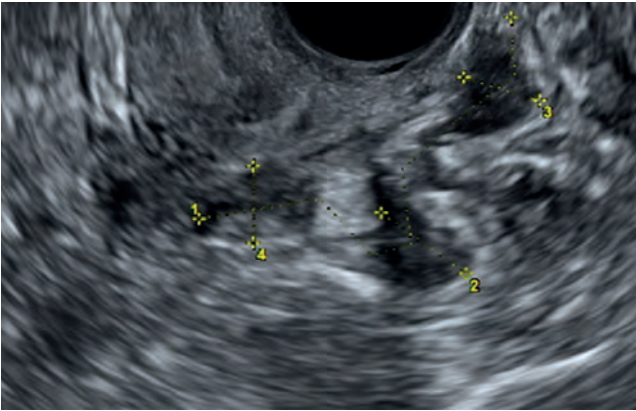


**Fig. 2.100a–d** Ultrasound appearance of four different nodules of deep infiltrating endometriosis of the rectum. Note the hypoechoic tissue infiltrating the muscular layer of the bowel, exhibiting irregular margins and bizarre forms.



**Fig. 2.101 a, b** Transvaginal ultrasound appearance of DIE nodule in the cranial rectum (recto-sigmoid) (a) and in the lower rectum (b). The nodule is located above the level where the uterosacral ligaments are inserted on the cervix and appears to be in the upper rectum or recto-sigmoid (a). The nodule is located below the peritoneum of the pouch of Douglas, exhibiting signs of fluid accumulation (b).





**Fig. 2.102** Transvaginal ultrasound appearance of DIE nodule of the recto-sigmoid. Note the multifocal lesions.

Transvaginal sonography was shown to have a low accuracy in diagnosing infiltration of the mucosal layer.<sup>57</sup> Likewise, transrectal ultrasound – which is a valuable tool for detecting rectal endometriosis, considering that infiltration of the muscularis layer can be predicted accurately – is less accurate in assessing involvement of the submucosal/mucosal layer.<sup>77,85</sup> Therefore, transvaginal and transrectal sonography is not helpful in the decision-making on segmental or discoid resection of the lesion. Accordingly, this question should be dealt with as determined by the patient's symptoms, while also taking into account the diameter of infiltrated tissue and the degree of lumen stenosis. It has been reported that adding water contrast in the rectum during transvaginal ultrasonography (RWC-TVS) improves the diagnosis of rectal infiltration in women with rectovaginal endometriosis.<sup>67,91</sup> RWC-TVS has been shown to reveal more accurately than TVS alone, the presence of rectovaginal nodules infiltrating the rectal muscularis propria.<sup>91</sup> The use of RWC-TVS is indicated when transvaginal sonography cannot reliably exclude the presence of rectal infiltration. In case of suspected bowel stenosis, based on symptoms and on TVS findings, a barium enema may be useful to determine the need for segmental resection.

**Pouch of Douglas (POD) obliteration:** This type of obliteration is assessed using the 'sliding sign' by applying gentle pressure with the transvaginal probe to the cervix in order to evaluate whether the anterior rectum is gliding freely across the posterior aspect of the cervix, or by placing the left hand over the patient's lower anterior abdominal wall, balloting the uterus between the palpating hand and the transvaginal probe to check on whether the recto-sigmoid is gliding freely over the posterior aspect of the upper uterus/fundus.<sup>81,82</sup>

### 2.6.4 Adenomyosis

Adenomyosis is a common gynecologic disease characterized by migration of endometrial glands and stroma from the basal layer of endometrium into the myometrium, and is associated with smooth muscle hyperplasia, which on ultrasound presents with ill-defined lesions noticeable within the myometrium. Adenomyosis can be regarded as a disease of the *junctional zone* (JZ), where the endometrial-myometrial barrier is disrupted, allowing endometrial tissue to infiltrate the myometrium.<sup>62</sup> Migration of endometrial tissue into the JZ is accompanied by hyperplasia and hypertrophy of myocytes surrounding heterotopic endometrial tissue. There is considerable individual variation in the degree of myometrial invasion and the proportion to which endometrial glandular structures, endometrial stroma and hypertrophic muscle elements are found within and around adenomyotic foci.<sup>92</sup> Adenomyosis may be localized or present at multiple sites within the uterine wall, or can involve most of the myometrium and is often dispersed within the myometrium rather than forming a confined lesion ('diffuse adenomyosis'). On the other hand, the unilocular form of adenomyosis, noticeable in one part of the myometrium only, is called 'focal adenomyosis'. Adenomyoma can be defined as focal adenomyosis with additional compensatory hypertrophy of the surrounding myometrium. In rare instances, the condition may also present as a large cyst ('adenomyotic cyst' or 'cystic adenomyoma').

Detection methods for adenomyosis remain a diagnostic challenge. TVS, along with MRI has been shown to demonstrate high levels of accuracy in the preoperative diagnosis of adenomyosis.<sup>24</sup> Several studies have provided evidence that sensitivity and specificity of 2D (two dimensional) TVS in diagnosing adenomyosis are comparable to MRI and/or histology, ranging from 75%–88% and 67%–93% respectively.<sup>6,17,25,26,83</sup> Conversely, in comparison to MRI, transvaginal ultrasound is tolerated well by patients, it is repeatable and inexpensive, and has the advantage of wide availability.

#### 2.6.4.1 2D Transvaginal Sonographic Features of Adenomyosis

Continual advancements have been made in improving the resolution of transvaginal ultrasound, which allows for a more detailed assessment of uterine architecture. As a result, this has facilitated the visualization of specific ultrasound features of myometrial adenomyosis, which in the past were not detectable when using older equipment.

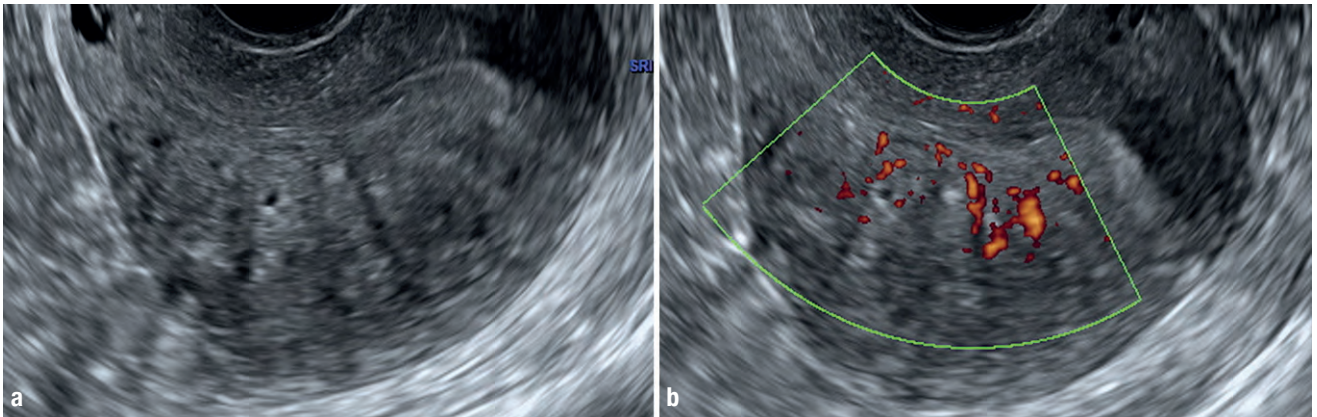
According to several studies,<sup>6,13,24,53,83,84,92</sup> the 2D-TVS features described below were found to be associated with adenomyosis (Table 2.10):

- Globally enlarged uterus: the fundus of the uterus appears enlarged (Fig. 2.103).
- Asymmetrically enlarged uterus (e.g., anterior wall thicker than posterior wall or vice versa) unrelated to leiomyoma (Figs. 2.103, 2.104).
- Round cystic area within the myometrium (Figs. 2.105, 2.106).
- Inhomogeneous, irregular myometrial echotexture in an ill-defined myometrial area with decreased or increased echogenicity; hyperechoic islands, subendometrial lines and buds (Fig. 2.107).
- Myometrial hypoechoic linear striations seen as a radiating pattern of thin acoustic shadows not arising from echogenic foci or leiomyoma (fan-shaped shadowing).
- Indistinct, fuzzy endometrial-myometrial junction (ill-defined endometrial stripe).
- Presence of diffuse minimal vascularity seen as a diffuse spread of small vessels which do not present the normal course of arcuate and radial arteries inside the myometrium.
- 'Question mark' sign<sup>22</sup> can be detected when the uterine corpus is retroflexed, while the uterine fundus faces the posterior pelvic compartment and the cervix is directed frontally towards the urinary bladder (Fig. 2.108).

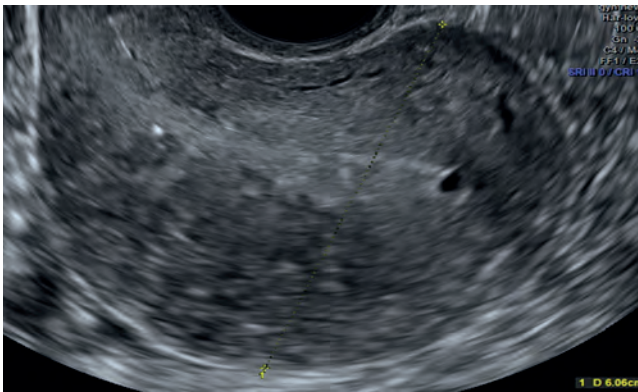
Summary of Ultrasound Features Associated with Histological Diagnosis of Different Types of Adenomyosis			
2D US Features	Diffuse Adenomyosis	Focal Adenomyosis	Adenomyoma
<b>Serosal contour of the uterus</b>	Often globally enlarged uterus	Often regular	Lobulated or regular
<b>Definition of lesion</b>	Ill-defined	Ill-defined or well-defined in case of cystic lesions	May be well-defined
<b>Symmetry of uterine walls</b>	Myometrial anterior-posterior asymmetry	Often symmetric	Asymmetrical in presence of well-defined lesion
<b>Outline</b>	Ill-defined	Ill-defined	Ill-defined
<b>Shape</b>	Ill-defined	Ill-defined, oval appearance in case of cystic lesions	Round, oval, lobulated
<b>Contour</b>	Ill-defined	Irregular or ill-defined	Irregular or ill-defined
<b>Rim</b>	No rim	No rim, Hyperechoic appearance in case of cystic lesions	Rim may be present, hypo- or hyperechoic
<b>Shadowing</b>	No edge shadows; Fan-shaped shadowing; Linear hypoechoic striation	No edge shadows; Rarely fan-shaped shadowing, or linear hypoechoic striation	Edge shadows may be present; Internal often fan-shaped shadowing
<b>Echogenicity</b>	Heterogenous, diffuse presence of intra-myometrial diffuse areas of: <ul style="list-style-type: none"> <li>■ mixed echogenicity,</li> <li>■ cyst,</li> <li>■ hyperechoic islands,</li> <li>■ subendometrial echogenic lines or buds</li> </ul>	Focal, often solitary presence of intra-myometrial small areas of : <ul style="list-style-type: none"> <li>■ mixed echogenicity,</li> <li>■ cyst,</li> <li>■ hyperechoic islands,</li> <li>■ subendometrial echogenic lines or buds</li> </ul>	Focal, lobulated presence in hyper-, iso-, hypoechoic intramyometrial lobulated areas of: <ul style="list-style-type: none"> <li>■ cyst ,</li> <li>■ hyperechoic islands</li> </ul>
<b>Vascularity</b>	Translesional flow; Diffuse, minimal or few vessels	Diffuse minimal sporadic vessels	Translesional flow; Diffuse vessels, Rarely circumferential flow
<b>Endometrial rim</b>	Irregular or ill-defined; Distorted or indented	Often regular or indented by subendometrial focal lesion	Often regular or distorted by the lobulated lesion

**Table 2.10** Summary of ultrasound features associated with histological diagnosis of different types of adenomyosis.

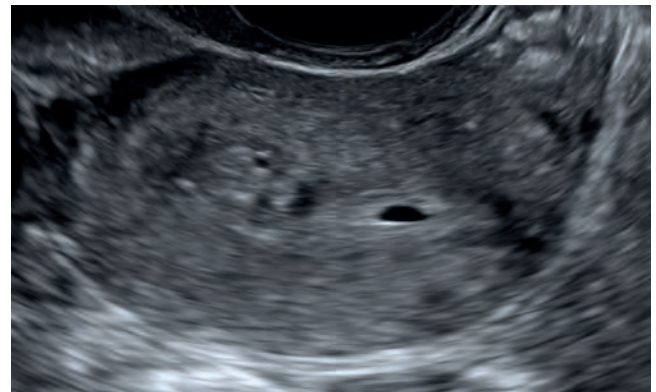




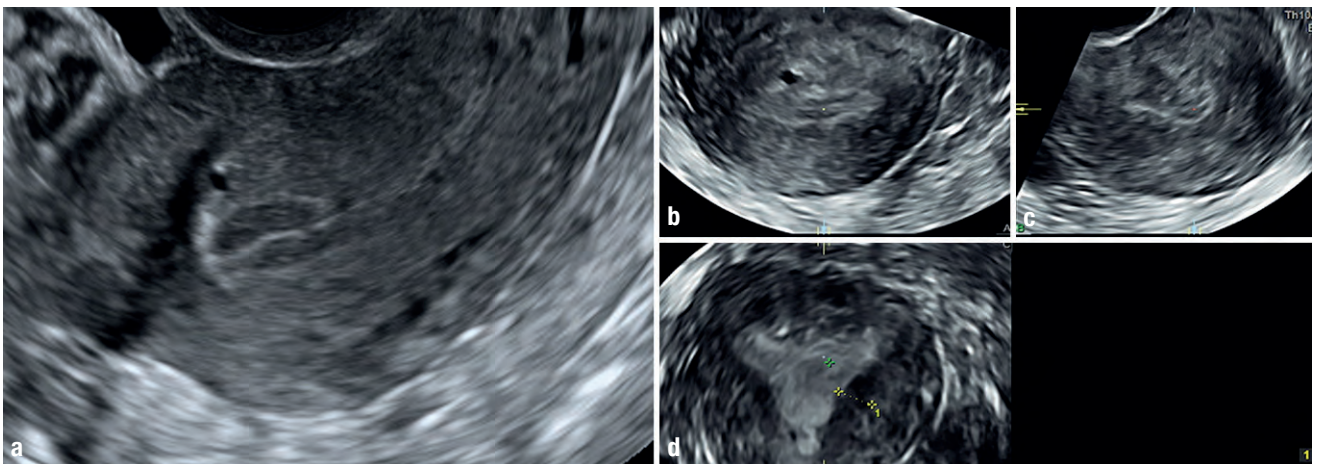
**Fig. 2.103a, b** Ultrasound images of an uterus with adenomyosis. Gray scale image showing a globally enlarged uterus unrelated to leiomyoma, with irregular myometrial echotexture, with hyperechoic irregular myometrial areas, and small anechoic areas. Note the ill-defined endometrial stripe (a). The power Doppler image shows diffusely spread vessels without a circular flow along a capsule, typical for leiomyoma (b).



**Fig. 2.104** Ultrasound image of an uterus with adenomyosis showing asymmetrical thickening. The posterior uterine wall is thicker than the anterior part and shows inhomogeneous, irregular myometrial echotexture due to hyperechoic and small cystic anechoic areas.

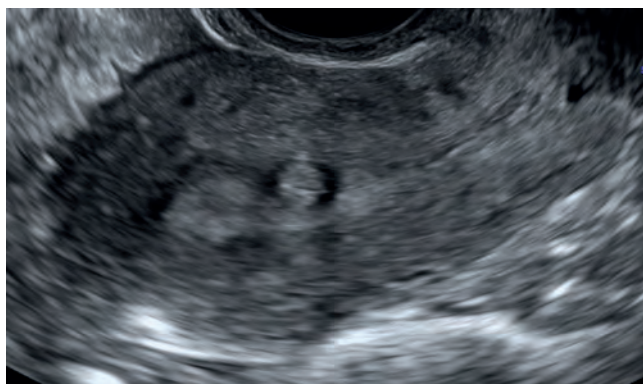

**Fig. 2.105** Ultrasound image of uterus with focal adenomyosis. Note the round cystic anechoic areas in the myometrium and hypoechoic linear striation.

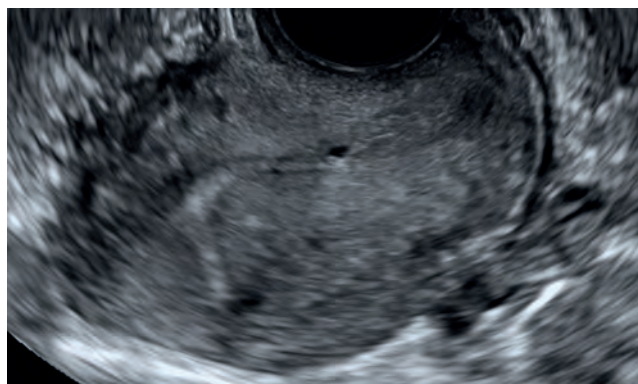

**Fig. 2.106a, b** Ultrasound images of uterus with focal cystic adenomyosis of the anterior wall (a–d). 2D gray scale image showing a cystic anechoic area in the myometrium of the anterior wall (a). 3D multiplanar view of the same patient (b–d). Transverse and coronal sections of the uterus are shown on (b) and (c), a longitudinal section is shown on (d). The thickened junctional zone appears as a hypoechoic zone surrounding the endometrium. The junctional zone appears irregular, thicker than normal and infiltrated by adenomyosis at the fundus.

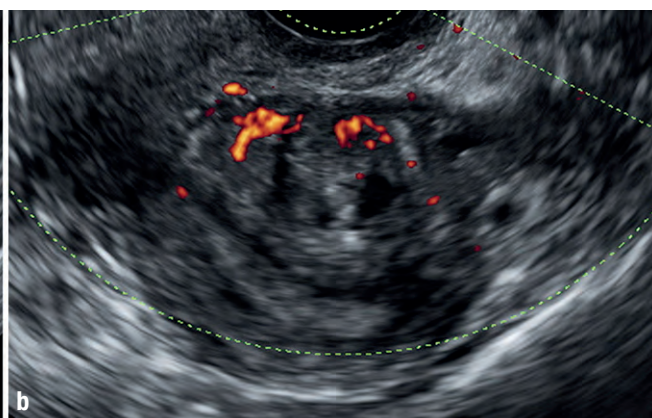
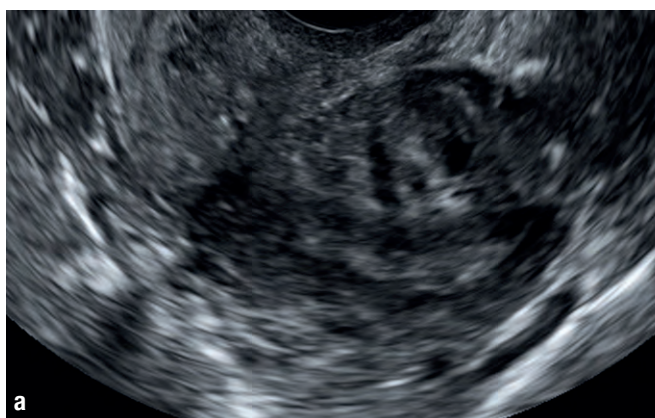


**Fig. 2.107** Ultrasound image of uterus. Note the hyperechoic buds in the myometrium below the endometrium.



**Fig. 2.108** Ultrasound image of uterus with adenomyosis exhibiting the typical 'question mark' sign.



**Fig. 2.109a, b** Ultrasound images of a retroverted uterus with posterior cystic adenomyoma. Gray scale image (a) showing inhomogeneous, irregular myometrial echotexture with cystic areas. Power Doppler image (b) showing more circular vessels in the hypertrophic myometrium surrounding the cystic areas.

Myometrial involvement of adenomyosis typically manifests with the following major phenotypes (Table 2.10):

- A tentative diagnosis of focal or localized adenomyosis can be made in the presence of solitary findings detected only in one part of the myometrium, or at single/multiple sites within the uterine wall forming a circumscribed lesion that assumes less than 50% of the total uterine volume (Fig. 2.105).
- Diffuse adenomyosis should be suspected if most part of the myometrium, i.e., at least 50% or more of the volume of the entire corpus is involved (Figs. 2.103, 2.104).
- An adenomyoma is typically characterized by a focal area of increased density of endometrial glands and/or endometrial stroma located within the myometrium with additional compensatory hypertrophy of the surrounding myometrium (Fig. 2.109).

It is often difficult to draw a clear distinction between adenomyoma and focal adenomyosis (Table 2.10). Compared to both localized and diffuse adenomyosis, adenomyomas are relatively uncommon.<sup>6,14,33,83</sup> A rare cystic form of adenomyoma may be seen in the younger age group.<sup>14</sup>

Power Doppler can be used to distinguish myometrial cysts from blood vessels and to tell apart leiomyomas from focal adenomyosis (Fig. 2.103). Uterine leiomyomas manifest with a circular flow noticeable along the myoma capsule, while localized adenomyosis and adenomyomas are characterized by diffusely spread vessels inside the lesions (Fig. 2.109). In the diagnosis of diffuse adenomyosis, *Reinhold and colleagues*<sup>83</sup> reported that 2D ultrasound has a sensitivity of 80–86%, specificity of 50–96%, and overall accuracy of 68–86%. However, 2D ultrasound can yield equivocal results in the case of focal adenomyosis, with or without concomitant fibroids.<sup>6,24</sup> In a meta-analysis comprising 14 trials and 1,985 participants, *Meredith et al.* reported the sensitivity and specificity of ultrasound in the diagnosis of adenomyosis to be as high as 82.5 and 84.6%, respectively.<sup>66</sup>

Most commonly, definitive diagnosis of adenomyosis is made by histological examination of an uterus specimen obtained through hysterectomy. The majority of past studies investigating the diagnostic accuracy of 2D-TVS in the identification of adenomyosis, are based on patient cohorts of women who underwent hysterectomy.<sup>10,24,66</sup> The cohorts were mainly composed of women with severe symptoms, who were more likely to have adenomyosis than the general population, which is why it can be suggested that prevalence of adenomyosis in these studies was overestimated.

Summary of Features of the Junctional Zone (JZ) in the Presence of Adenomyosis	
Features of the JZ	Adenomyosis
JZ Thickness	<ul style="list-style-type: none"> <li>■ Thickened               <ul style="list-style-type: none"> <li>– Maximum JZ thickness (JZ max) &gt; 6–8 mm;</li> <li>– Ratio of JZ (JZ max/total myometrial wall thickness) <math>\geq</math> 50 %;</li> <li>– Difference (JZmax) – (JZmin) = JZdif. <math>\geq</math> 4 mm</li> </ul> </li> </ul>
JZ Regularity	<ul style="list-style-type: none"> <li>■ Irregular or ill-defined;</li> <li>■ Distorted</li> </ul>
JZ Boundary	<ul style="list-style-type: none"> <li>■ Interrupted;</li> <li>■ Infiltration of the JZ by hyperechoic endometrial tissue</li> </ul>

**Table 2.11** Summary of features of the junctional zone (JZ) – detected on 3D-TVS – and correlated with a diagnosis of adenomyosis.

Furthermore, 2D transvaginal sonographic findings are more likely to be detected in advanced stages of the disease, and most of the studies investigating the validity of TVS in the diagnosis of adenomyosis, are based on at least one or three of the ultrasound features described above.<sup>23,28,61,68–70,78</sup> The presence of only one of the typical TVS features of adenomyosis may actually give rise to some concern, especially in young women. The presence of ultrasound features suggestive of adenomyosis has been reported in 20–22 % of young women, who did not undergo hysterectomy. However, the number of features included in the diagnosis, the mean age of patient cohorts included in the study, and the presence/absence of symptoms and pelvic endometriosis are often variable, which is why the incidence of adenomyosis cannot be compared.

A correlation between ultrasound findings suggestive of adenomyosis and symptoms like menorrhagia or dysmenorrhea, infertility and multiparity has been shown in the literature.<sup>7,68,68,70,87,93</sup> Taking into account the number of various morphological features detected in an individual woman, it has been proposed that these may be used as an indirect measure for the severity of disease.<sup>68–70</sup>

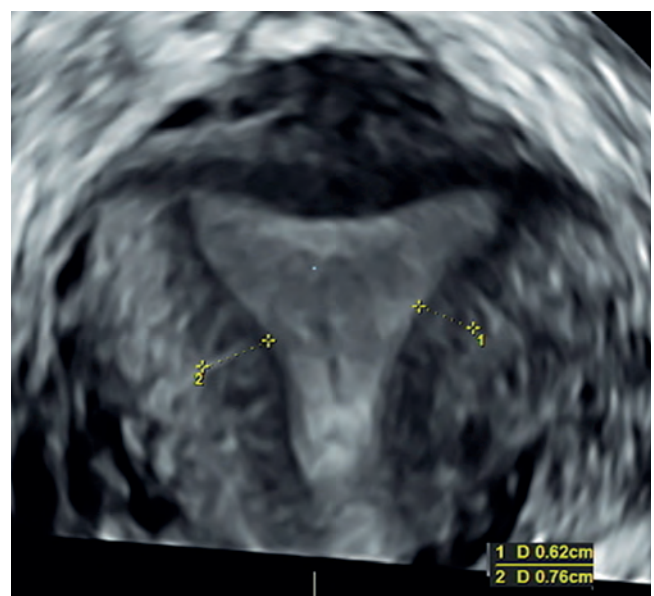
Adenomyosis, also seems to be associated with endometriosis.<sup>23,59,61,62,70</sup> The special value that accrues from a confirmed diagnosis of adenomyosis, lies in the opportunity to evaluate how many of these women are likely to have adenomyosis contributing to their pain symptoms as well as to any other form of pelvic endometriosis. A strong association was found between adenomyosis diagnosed by transvaginal ultrasound and concomitant presence of endometriosis, with an incidence of adenomyosis ranging between 48–50 % in patients affected by DIE.<sup>23,61</sup>

2D transvaginal sonography has reached a high level of accuracy and many authors have reported a high level of conformity between sonographic diagnosis of adenomyosis and histological findings. A recent review<sup>24</sup> concluded that TVS should be the primary tool in the diagnosis of adenomyosis, with MRI being used when TVS is inconclusive or in cases of large fibroids.

#### 2.6.4.2 3D Transvaginal Sonographic Features of Adenomyosis

Even though the *junctional zone* (JZ) can be visualized on 2D ultrasound, acquisition of a 3D-volume offers the advantage of a more complete assessment in the sagittal, transverse and coronal plane, which is demonstrated in a standardized multi-planar view.<sup>28,71,92</sup> 3D transvaginal sonographic signs of adenomyosis are used to evaluate the junctional zone on the acquired uterine volume in order to specifically investigate the coronal view. On coronal view, the junctional zone appears as hypoechoic zone around the endometrium. Using a *volume contrast imaging* (VCI) modality with 2–4 mm slices, the JZ is more clearly noticeable using all planes of the multiplanar view, including the longitudinal and transverse uterine section where the anterior and posterior JZ can be evaluated.<sup>28,70,92</sup>

The JZ may be regular, irregular, interrupted, not visible, and not amenable to evaluation or it may manifest with more than one feature (e.g., irregular and interrupted). Any irregularity in the JZ should be noted (e.g., cystic areas, hyperechoic dots, hyperechoic buds and lines) for each location of the uterus (anterior, posterior, lateral left, lateral right, fundus)<sup>28,70,92</sup> (Table 2.11) (Fig. 2.110).



**Fig. 2.110** Coronal section of an uterus obtained using three-dimensional ultrasound. Note the diffusely thickened junctional zone.



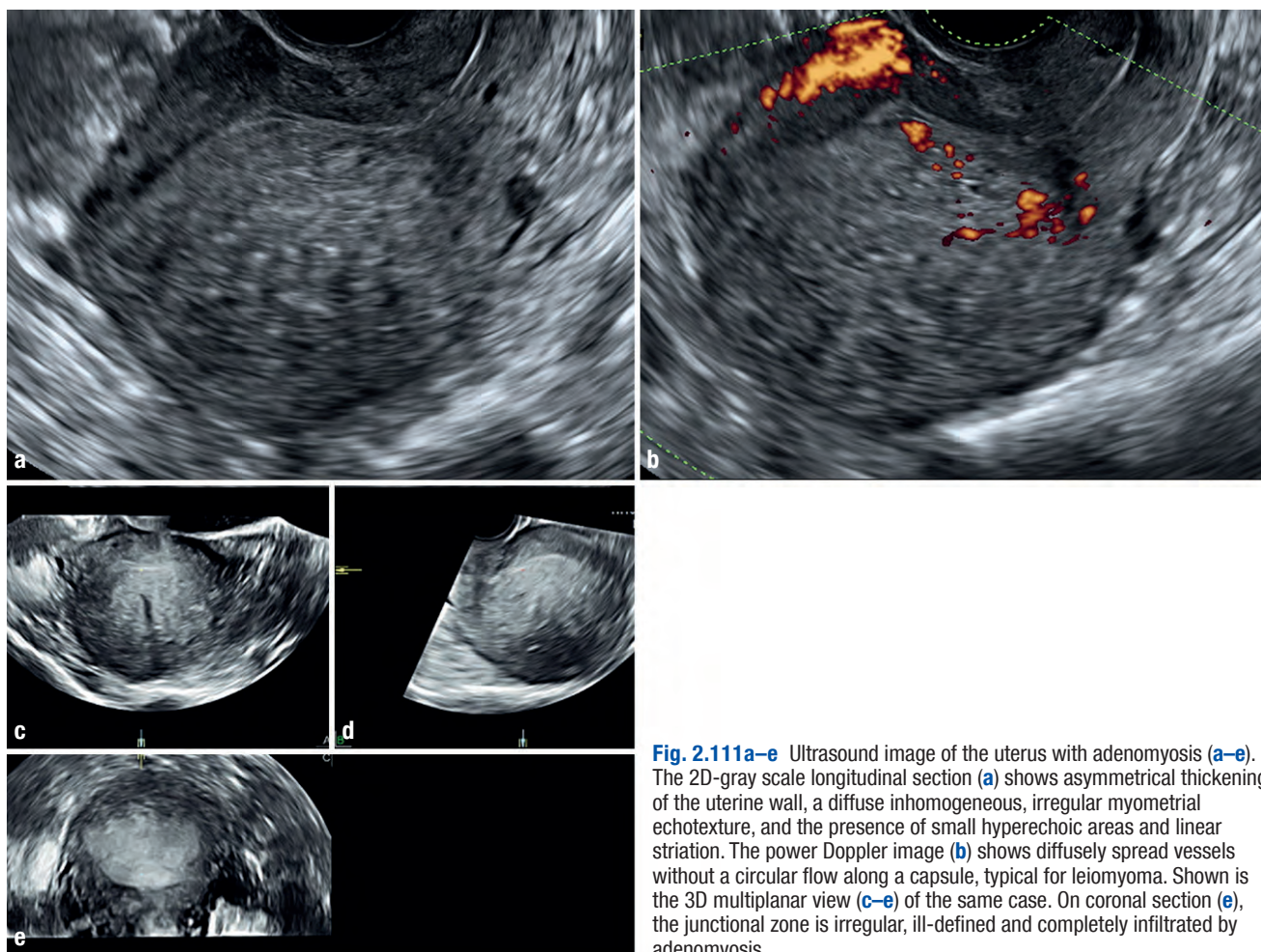
In an attempt to prevent a biased or subjective morphological evaluation of the junctional zone – as in terms of ‘irregularity’ and ‘infiltration’ – the use of objective parameters for the measurement of JZ thickness, which is commonly used by radiologists on MRI, has also been proposed for the assessment of the 3D-TVS appearance of the junctional zone.<sup>28,30,63</sup> The JZ and the total myometrial wall thickness can be measured perpendicular to the endometrium on the same section through the uterus. The maximum thickness of the junctional zone ( $JZ_{max}$ ) is measured at the area where the JZ appears to be at its thickest (Fig. 2.110), and the minimum thickness  $JZ_{min}$  is measured where it appears to be at its thinnest, after evaluation of the total three-dimensional volume of the uterus. The magnitude of a JZ irregularity is expressed as the difference between the maximal and minimal JZ thickness:  $(JZ_{max}) - (JZ_{min}) = JZ_{dif}$ . The extent of JZ irregularity is defined as the subjective estimation of the percentage of the JZ that shows an irregular appearance (< 50% or > 50%).<sup>28,63,92</sup> Detailed morphological measurement of the JZ is currently relevant only in the context of research protocols.

Interruption of the JZ may be caused by focal infiltration of the JZ by endometrial tissue, but contractions and changes within the JZ may also give rise to apparent JZ irregularities or may have an effect on JZ thickness. The extent of interruption is recorded as a subjective estimation of the percentage of the JZ that is affected (< 50% or > 50%)<sup>92</sup> (Figs. 2.106, 2.111).

When comparing transvaginal sonographic features with outcomes of histology of the uterus specimen after hysterectomy, it was shown that junctional zone thickness – ( $JZ_{max} = 6\text{--}8\text{mm}$  and  $[JZ_{max}] - [JZ_{min}] = 4\text{ mm}$ ) – demonstrated a more significant correlation with adenomyosis than that of other 2D-TVS features.<sup>28,63</sup> Apart from that, the subjective evaluation of ‘infiltration’ and ‘interruption’ caused by endometrial tissue in the junctional zone, is an accurate tool for the diagnosis of adenomyosis.<sup>28,63,71</sup>

Thickening and interrupted appearance of the junctional zone are a typical feature that is strongly associated with uterine adenomyosis.<sup>28,63,71,92</sup> The junctional zone, if altered, is correlated to adenomyosis, and seems to be involved in the pathogenetic process that leads to the development of pelvic endometriosis.<sup>11,59,60,62</sup>

With the use of 3-D ultrasound, adenomyosis, junctional zone hyperplasia and adenomyotic cysts can now be detected in younger patients during their reproductive years.<sup>35</sup> The use of 3-D vaginal ultrasound for the diagnosis of junctional zone abnormality or adenomyotic pathology has been extensively described by *Exacoustos et al.*<sup>28,30,63</sup> and can now be implemented in patients seeking fertility treatment. As there is a distinct trend for women to put off giving birth to a child until some later time in their reproductive years, we can expect an increasing incidence of adenomyotic pathology in patients with fertility problems.<sup>93</sup>



**Fig. 2.111a–e** Ultrasound image of the uterus with adenomyosis (a–e). The 2D-gray scale longitudinal section (a) shows asymmetrical thickening of the uterine wall, a diffuse inhomogeneous, irregular myometrial echotexture, and the presence of small hyperechoic areas and linear striation. The power Doppler image (b) shows diffusely spread vessels without a circular flow along a capsule, typical for leiomyoma. Shown is the 3D multiplanar view (c–e) of the same case. On coronal section (e), the junctional zone is irregular, ill-defined and completely infiltrated by adenomyosis.



### 2.6.5 Conclusions

Deep infiltrating endometriosis (DIE) is the most severe form of endometriosis, associated with infertility or pain symptoms, including chronic pelvic pain, dysmenorrhea, dyspareunia, dysuria, and dyschezia.<sup>57</sup> It is therefore recommended, that information, as detailed as possible, be obtained on disease spread and localization, which can be extremely useful to the surgeon and other health care professionals involved in the diagnosis and management of the disease. Careful evaluation of findings obtained through clinical and diagnostic imaging modalities offers the opportunity

- to choose the best medical or surgical approach,
- to decide whether there is need to draw on the knowledge and skills of additional surgical specialists other than a gynaecologic surgeon (e.g. colorectal surgeon or urologist),
- to establish a sophisticated management plan tailored to the patient's individual condition, and
- to properly inform patients on the extent of disease and the therapeutic options currently available.

The reported diagnostic accuracy of the sonographic detection of DIE varies between different studies, which may be due to variation in the examination technique, quality of ultrasound equipment and experience of operators. The prevalence of disease is also variable in different studies, which may bias the findings.

These days, 2D TVS has reached a high level of accuracy and a clear clinicopathological correlation between sonographic diagnosis of adenomyosis and histological findings has been demonstrated. In this context, it is suggested that the number of various morphological features observed in an individual be used as an indirect measure of the severity of disease. 3D ultrasound evaluation of the junctional zone and its alterations seems to be of paramount importance, especially in patients with suspected pelvic endometriosis and adenomyosis. The correlation of more than two 2D-3D ultrasound features of adenomyosis with symptoms (menometrorrhagia dysmenorrhea, dyspareunia, abnormal uterine bleeding), multiparity and endometriosis has been demonstrated. Further studies need to be conducted in young and asymptomatic or infertile patients diagnosed with only a few 2D/3D ultrasound features suggestive of adenomyosis.

Despite the high level of sensitivity and specificity of TVS in the prediction of DIE and adenomyosis, TVS-based diagnostic assessment of these conditions is a challenging task and requires a great deal of expertise. When carried out by experienced sonographers, the use of TVS for detection of DIE and adenomyosis is a highly valuable option.<sup>8,29,40,41,47,48</sup>

In the time waiting for a new classification and staging scheme for endometriosis that considers all manifestations of the disease in terms of site and pelvic extension, an accurate mapping system for use in diagnostic imaging procedures should be used to evaluate each endometriotic lesion according to anatomical localization. In the end, this should be aimed at improving the management, medical or surgical treatment and counselling of patients.

### 2.6.6 References

1. ABRAO MS, GONCALVES MO, DIAS JA JR, PODGAEC S, CHAMIE LP, BLASBALG R. Comparison between clinical examination, transvaginal sonography and magnetic resonance imaging for the diagnosis of deep endometriosis. *Hum Reprod* 2007;22(12):3092–7. doi:10.1093/humrep/dem187.
2. ABRAO MS, PETRAGLIA F, FALCONE T, KECKSTEIN J, OSUGA Y, CHAPRON C. Deep endometriosis infiltrating the recto-sigmoid: critical factors to consider before management. *Hum Reprod Update* 2015;21(3):329–39. doi:10.1093/humupd/dmv003.
3. ADAMSON GD. Endometriosis classification: an update. *Curr Opin Obstet Gynecol* 2011;23(4):213–20. doi:10.1097/GCO.0b013e328348a3ba.
4. ALABISO G, ALIO L, ARENA S, DI PRUN AB, BERGAMINI V, BERLANDA N et al. How to Manage Bowel Endometriosis: The ETIC Approach. *J Minim Invasive Gynecol* 2015;22(4):517–29. doi:10.1016/j.jmig.2015.01.021.
5. AMERICAN FERTILITY SOCIETY. Revised American Fertility Society classification of endometriosis: 1985. *Fertil Steril* 1985;43(3):351–2.
6. BAZOT M, CORTEZ A, DARAI E, ROUGER J, CHAPIER J, ANTOINE JM et al. Ultrasonography compared with magnetic resonance imaging for the diagnosis of adenomyosis: correlation with histopathology. *Hum Reprod* 2001;16(11):2427–33.
7. BAZOT M, DARAI E, ROUGER J, DETCHEV R, CORTEZ A, UZAN S. Limitations of transvaginal sonography for the diagnosis of adenomyosis, with histopathological correlation. *Ultrasound Obstet Gynecol* 2002;20(6):605–11. doi:10.1046/j.1469-0705.2002.00852.x.
8. BAZOT M, THOMASSIN I, HOURANI R, CORTEZ A, DARAI E. Diagnostic accuracy of transvaginal sonography for deep pelvic endometriosis. *Ultrasound Obstet Gynecol* 2004;24(2):180–5. doi:10.1002/uog.1108.
9. BELGHITI J, THOMASSIN-NAGGARA I, ZACHAROPOULOU C, ZILBERMAN S, JARBOUI L, BAZOT M et al. Contribution of Computed Tomography Enema and Magnetic Resonance Imaging to Diagnose Multifocal and Multicentric Bowel Lesions in Patients With Colorectal Endometriosis. *J Minim Invasive Gynecol* 2015;22(5):776–84. doi:10.1016/j.jmig.2015.02.019.
10. BENAGIANO G, BROSENS I. History of adenomyosis. *Best Pract Res Clin Obstet Gynaecol* 2006;20(4):449–63. doi:10.1016/j.bpobgyn.2006.01.007.
11. BENAGIANO G, HABIBA M, BROSENS I. The pathophysiology of uterine adenomyosis: an update. *Fertil Steril* 2012;98(3):572–9. doi:10.1016/j.fertnstert.2012.06.044.
12. BIGNARDI T, CONDOUS G. Sonorectovaginography: a new sonographic technique for imaging of the posterior compartment of the pelvis. *J Ultrasound Med* 2008;27(10):1479–83.
13. BROMLEY B, SHIPP TD, BENACERRAF B. Adenomyosis: sonographic findings and diagnostic accuracy. *J Ultrasound Med* 2000;19(8):529–34; quiz 535–6.
14. BROSENS I, GORDTS S, HABIBA M, BENAGIANO G. Uterine Cystic Adenomyosis: A Disease of Younger Women. *J Pediatr Adolesc Gynecol* 2015;28(6):420–6. doi:10.1016/j.jpog.2014.05.008.
15. CARMIGNANI L, VERCELLINI P, SPINELLI M, FONTANA E, FRONTINO G, FEDELE L. Pelvic endometriosis and hydronephrosis. *Fertil Steril* 2010;93(6):1741–4. doi:10.1016/j.fertnstert.2008.12.038.
16. CHAMIE LP, PEREIRA RM, ZANATTA A, SERAFINI PC. Transvaginal US after bowel preparation for deeply infiltrating endometriosis: protocol, imaging appearances, and laparoscopic correlation. *Radiographics* 2010;30(5):1235–49. doi:10.1148/rg.305095221.


17. CHAMPANERIA R, ABEDIN P, DANIELS J, BALOGUN M, KHAN KS. Ultrasound scan and magnetic resonance imaging for the diagnosis of adenomyosis: systematic review comparing test accuracy. *Acta Obstet Gynecol Scand* 2010;89(11):1374–84. doi:10.3109/00016349.2010.512061.
18. CHAPRON C, CHOPIN N, BORGHESE B, FOULOT H, DOUSSET B, VACHER-LAVENU MC et al. Deeply infiltrating endometriosis: pathogenetic implications of the anatomical distribution. *Hum Reprod* 2006;21(7):1839–45. doi:10.1093/humrep/del079.
19. CHAPRON C, FAUCONNIER A, VIEIRA M, BARAKAT H, DOUSSET B, PANSINI V et al. Anatomical distribution of deeply infiltrating endometriosis: surgical implications and proposition for a classification. *Hum Reprod* 2003;18(1):157–61.
20. CHAPRON C, PIETIN-VIALLE C, BORGHESE B, DAVY C, FOULOT H, CHOPIN N. Associated ovarian endometrioma is a marker for greater severity of deeply infiltrating endometriosis. *Fertil Steril* 2009;92(2):453–7. doi:10.1016/j.fertnstert.2008.06.003.
21. DESSOLE S, FARINA M, RUBATTU G, COSMI E, AMBROSINI G, NARDELLI GB. Sonovaginography is a new technique for assessing rectovaginal endometriosis. *Fertil Steril* 2003;79(4):1023–7.
22. DI DONATO N, BERTOLDO V, MONTANARI G, ZANNONI L, CAPRARA G, SERACCHIOLI R. Question mark form of uterus: a simple sonographic sign associated with the presence of adenomyosis. *Ultrasound Obstet Gynecol* 2015;46(1):126–7. doi:10.1002/uog.14750.
23. DI DONATO N, MONTANARI G, BENFENATI A, LEONARDI D, BERTOLDO V, MONTI G et al. Prevalence of adenomyosis in women undergoing surgery for endometriosis. *Eur J Obstet Gynecol Reprod Biol* 2014;181:289–93. doi:10.1016/j.ejogrb.2014.08.016.
24. DUEHOLM M. Transvaginal ultrasound for diagnosis of adenomyosis: a review. *Best Pract Res Clin Obstet Gynaecol* 2006;20(4):569–82. doi:10.1016/j.bpobgyn.2006.01.005.
25. DUEHOLM M, LUNDORF E. Transvaginal ultrasound or MRI for diagnosis of adenomyosis. *Curr Opin Obstet Gynecol* 2007;19(6):505–12. doi:10.1097/GCO.0b013e3282f1bf00.
26. DUEHOLM M, LUNDORF E, HANSEN ES, SORENSEN JS, LEDERTOUG S, OLESEN F. Magnetic resonance imaging and transvaginal ultrasonography for the diagnosis of adenomyosis. *Fertil Steril* 2001;76(3):588–94.
27. DUNSELMAN GA, VERMEULEN N, BECKER C, CALHAZ-JORGE C, D'HOOGHE T, BIE B DE et al. ESHRE guideline: management of women with endometriosis. <http://humrep.oxfordjournals.org/content/29/3/400.full.pdf+html>. *Hum Reprod* 2014;29(3):400–12. doi:10.1093/humrep/det457.
28. EXACOUSTOS C, BRIENZA L, DI GIOVANNI A, SZABOLCS B, ROMANINI ME, ZUPI E et al. Adenomyosis: three-dimensional sonographic findings of the junctional zone and correlation with histology. *Ultrasound Obstet Gynecol* 2011;37(4):471–9. doi:10.1002/uog.8900.
29. EXACOUSTOS C, MALZONI M, DI GIOVANNI A, LAZZERI L, TOSTI C, PETRAGLIA F et al. Ultrasound mapping system for the surgical management of deep infiltrating endometriosis. *Fertil Steril* 2014;102(1):143–150.e2. doi:10.1016/j.fertnstert.2014.03.043.
30. EXACOUSTOS C, MANGANARO L, ZUPI E. Imaging for the evaluation of endometriosis and adenomyosis. *Best Pract Res Clin Obstet Gynaecol* 2014;28(5):655–81. doi:10.1016/j.bpobgyn.2014.04.010.
31. EXACOUSTOS C, MIRK P, SPECA S, TESTA AC. Chapter 3, Gynecology,. In: Lutz H, Buscarini E, Mirk M, editors. *Manual of Diagnostic Ultrasound: World Health Organization*; 2013. p. 133–74. (ISBN No. 9789241548540).
32. EXACOUSTOS C, ZUPI E, CARUSOTTI C, RINALDO D, MARCONI D, LANZI G et al. Staging of pelvic endometriosis: role of sonographic appearance in determining extension of disease and modulating surgical approach. *J Am Assoc Gynecol Laparosc* 2003;10(3):378–82.
33. FEDELE L, BIANCHI S, DORTA M, ZANOTTI F, BRIOSCHI D, CARINELLI S. Transvaginal ultrasonography in the differential diagnosis of adenomyoma versus leiomyoma. *Am J Obstet Gynecol* 1992;167(3):603–6.
34. FEDELE L, BIANCHI S, RAFFAELLI R, PORTUESE A. Pre-operative assessment of bladder endometriosis. *Hum Reprod* 1997;12(11):2519–22.
35. GORDTS S, CAMPO R, BROSENS I. Hysteroscopic diagnosis and excision of myometrial cystic adenomyosis. *Gynecol Surg* 2014;11(4):273–8. doi:10.1007/s10397-014-0861-5.
36. GUERRIERO S, AJOSSA S, GARAU N, ALCAZAR JL, MAIS V, MELIS GB. Diagnosis of pelvic adhesions in patients with endometrioma: the role of transvaginal ultrasonography. *Fertil Steril* 2010;94(2):742–6. doi:10.1016/j.fertnstert.2009.03.035.
37. GUERRIERO S, AJOSSA S, GERADA M, D'AQUILA M, PIRAS B, MELIS GB. "Tenderness-guided" transvaginal ultrasonography: a new method for the detection of deep endometriosis in patients with chronic pelvic pain. *Fertil Steril* 2007;88(5):1293–7. doi:10.1016/j.fertnstert.2006.12.060.
38. GUERRIERO S, AJOSSA S, GERADA M, VIRGILIO B, ANGIIONI S, MELIS GB. Diagnostic value of transvaginal 'tenderness-guided' ultrasonography for the prediction of location of deep endometriosis. *Hum Reprod* 2008;23(11):2452–7. doi:10.1093/humrep/den293.
39. GUERRIERO S, AJOSSA S, LAI MP, MAIS V, AM PAOLETTI, MELIS GB. Transvaginal ultrasonography in the diagnosis of pelvic adhesions. *Hum Reprod* 1997;12(12):2649–53.
40. GUERRIERO S, AJOSSA S, MINGUEZ JA, JURADO M, MAIS V, MELIS GB et al. Accuracy of transvaginal ultrasound for diagnosis of deep endometriosis in uterosacral ligaments, rectovaginal septum, vagina and bladder: systematic review and meta-analysis. *Ultrasound Obstet Gynecol* 2015;46(5):534–45. doi:10.1002/uog.15667.
41. GUERRIERO S, AJOSSA S, OROZCO R, PERNICIANO M, JURADO M, MELIS GB et al. Accuracy of transvaginal ultrasound for diagnosis of deep endometriosis in the rectosigmoid: systematic review and meta-analysis. *Ultrasound Obstet Gynecol* 2016;47(3):281–9. doi:10.1002/uog.15662.
42. GUERRIERO S, ALCAZAR JL, AJOSSA S, PILLONI M, MELIS GB. Three-dimensional sonographic characteristics of deep endometriosis. *J Ultrasound Med* 2009;28(8):1061–6.
43. GUERRIERO S, SABA L, AJOSSA S, PEDDES C, ANGIOLUCCI M, PERNICIANO M et al. Three-dimensional ultrasonography in the diagnosis of deep endometriosis. *Hum Reprod* 2014;29(6):1189–98. doi:10.1093/humrep/deu054.
44. HAAS D, OPPELT P, SHEBL O, SHAMIYEH A, SCHIMETTA W, MAYER R. Enzian classification: does it correlate with clinical symptoms and the rASRM score? *Acta Obstet Gynecol Scand* 2013;92(5):562–6. doi:10.1111/aogs.12118.
45. HAAS D, SHEBL O, SHAMIYEH A, OPPELT P. The rASRM score and the Enzian classification for endometriosis: their strengths and weaknesses. *Acta Obstet Gynecol Scand* 2013;92(1):3–7. doi:10.1111/aogs.12026.

46. HOLLAND TK, YAZBEK J, CUTNER A, SARIDOGAN E, HOO WL, JURKOVIC D. Value of transvaginal ultrasound in assessing severity of pelvic endometriosis. *Ultrasound Obstet Gynecol* 2010;36(2):241–8. doi:10.1002/uog.7689.
47. HUDELIST G, BALLARD K, ENGLISH J, WRIGHT J, BANERJEE S, MASTOROUDES H et al. Transvaginal sonography vs. clinical examination in the preoperative diagnosis of deep infiltrating endometriosis. *Ultrasound Obstet Gynecol* 2011;37(4):480–7. doi:10.1002/uog.8935.
48. HUDELIST G, ENGLISH J, THOMAS AE, TINELLI A, SINGER CF, KECKSTEIN J. Diagnostic accuracy of transvaginal ultrasound for non-invasive diagnosis of bowel endometriosis: systematic review and meta-analysis. *Ultrasound Obstet Gynecol* 2011;37(3):257–63. doi:10.1002/uog.8858.
49. HUDELIST G, FRITZER N, STAETTNER S, TAMMAA A, TINELLI A, SPARIC R et al. Uterine sliding sign: a simple sonographic predictor for presence of deep infiltrating endometriosis of the rectum. *Ultrasound Obstet Gynecol* 2013;41(6):692–5. doi:10.1002/uog.12431.
50. HUDELIST G, OBERWINKLER KH, SINGER CF, TUTTLIES F, RAUTER G, RITTER O et al. Combination of transvaginal sonography and clinical examination for preoperative diagnosis of pelvic endometriosis. *Hum Reprod* 2009;24(5):1018–24. doi:10.1093/humrep/dep013.
51. HUDELIST G, TUTTLIES F, RAUTER G, PUCHER S, KECKSTEIN J. Can transvaginal sonography predict infiltration depth in patients with deep infiltrating endometriosis of the rectum? *Hum Reprod* 2009;24(5):1012–7. doi:10.1093/humrep/dep014.
52. JOHNSON N, VAN VOORST S, SOWTER MC, STRANDELL A, MOL BW. Surgical treatment for tubal disease in women due to undergo in vitro fertilisation. *Cochrane Database Syst Rev* 2010(1):CD002125. doi:10.1002/14651858.CD002125.pub3.
53. KEPKEP K, TUNCAY YA, GOYNUMER G, TUTAL E. Transvaginal sonography in the diagnosis of adenomyosis: which findings are most accurate? *Ultrasound Obstet Gynecol* 2007;30(3):341–5. doi:10.1002/uog.3985.
54. KHONG SY, BIGNARDI T, LUSCOMBE G, LAM A. Is pouch of Douglas obliteration a marker of bowel endometriosis? *J Minim Invasive Gynecol* 2011;18(3):333–7. doi:10.1016/j.jmig.2011.01.011.
55. KNABBen L, IMBODEN S, FELLMANN B, NIRGIANAKIS K, KUHN A, MUELLER MD. Urinary tract endometriosis in patients with deep infiltrating endometriosis: prevalence, symptoms, management, and proposal for a new clinical classification. *Fertil Steril* 2015;103(1):147–52. doi:10.1016/j.fertnstert.2014.09.028.
56. KONINCKX PR, MARTIN DC. Deep endometriosis: a consequence of infiltration or retraction or possibly adenomyosis externa? *Fertil Steril* 1992;58(5):924–8.
57. KONINCKX PR, USSIA A, ADAMYAN L, WATTIEZ A, DONNEZ J. Deep endometriosis: definition, diagnosis, and treatment. *Fertil Steril* 2012;98(3):564–71. doi:10.1016/j.fertnstert.2012.07.1061.
58. KRALIK R, TRNOVSKY P, KOPACOVA M. Transabdominal ultrasonography of the small bowel. *Gastroenterol Res Pract* 2013;2013:896704. doi:10.1155/2013/896704.
59. KUNZ G, BEIL D, HUPPERT P, NOE M, KISSLER S, LEYENDECKER G. Adenomyosis in endometriosis – prevalence and impact on fertility. Evidence from magnetic resonance imaging. *Hum Reprod* 2005;20(8):2309–16. doi:10.1093/humrep/dei021.
60. LARSEN SB, LUNDORF E, FORMAN A, DUEHOLM M. Adenomyosis and junctional zone changes in patients with endometriosis. *Eur J Obstet Gynecol Reprod Biol* 2011;157(2):206–11. doi:10.1016/j.ejogrb.2011.03.003.
61. LAZZERI L, DI GIOVANNI A, EXACOUSTOS C, TOSTI C, PINZAUTI S, MALZONI M et al. Preoperative and Postoperative Clinical and Transvaginal Ultrasound Findings of Adenomyosis in Patients With Deep Infiltrating Endometriosis. *Reprod Sci* 2014;21(8):1027–33. doi:10.1177/1933719114522520.
62. LEYENDECKER G, WILDT L, MALL G. The pathophysiology of endometriosis and adenomyosis: tissue injury and repair. *Arch Gynecol Obstet* 2009;280(4):529–38. doi:10.1007/s00404-009-1191-0.
63. LUCIANO DE, EXACOUSTOS C, ALBRECHT L, LAMONICA R, PROFFER A, ZUPI E et al. Three-dimensional ultrasound in diagnosis of adenomyosis: histologic correlation with ultrasound targeted biopsies of the uterus. *J Minim Invasive Gynecol* 2013;20(6):803–10. doi:10.1016/j.jmig.2013.05.002.
64. MACCAGNANO C, PELLUCCHI F, ROCCHINI L, GHEZZI M, SCATTONI V, MONTORSI F et al. Ureteral endometriosis: proposal for a diagnostic and therapeutic algorithm with a review of the literature. *Urol Int* 2013;91(1):1–9. doi:10.1159/000345140.
65. MENAKAYA U, CONDOUS G. The retroverted uterus: Refining the description of the real time dynamic ‘sliding sign’. *Australasian Journal of Ultrasound in Medicine* 2013;16(3):97. doi:10.1002/j.2205-0140.2013.tb00105.x.
66. MEREDITH SM, SANCHEZ-RAMOS L, KAUNITZ AM. Diagnostic accuracy of transvaginal sonography for the diagnosis of adenomyosis: systematic review and metaanalysis. *Am J Obstet Gynecol* 2009;201(1):107.e1-6. doi:10.1016/j.ajog.2009.03.021.
67. MOROTTI M, FERRERO S, BOGLIOLO S, VENTURINI PL, REMORGIDA V, VALENZANO MM. Transvaginal ultrasonography with water-contrast in the rectum in the diagnosis of bowel endometriosis. *Minerva Ginecol* 2010;62(3):179–85.
68. NAFTALIN J, HOO W, NUNES N, HOLLAND T, MAVRELOS D, JURKOVIC D. The association between ultrasound features of adenomyosis and severity of menstrual pain. *Ultrasound Obstet Gynecol* 2015;n/a-n/a. doi:10.1002/uog.15798.
69. NAFTALIN J, HOO W, PATEMAN K, MAVRELOS D, FOO X, JURKOVIC D. Is adenomyosis associated with menorrhagia? *Hum Reprod* 2014;29(3):473–9. doi:10.1093/humrep/det451.
70. NAFTALIN J, HOO W, PATEMAN K, MAVRELOS D, HOLLAND T, JURKOVIC D. How common is adenomyosis? A prospective study of prevalence using transvaginal ultrasound in a gynaecology clinic. *Hum Reprod* 2012;27(12):3432–9. doi:10.1093/humrep/des332.
71. NAFTALIN J, JURKOVIC D. The endometrial-myometrial junction: a fresh look at a busy crossing. *Ultrasound Obstet Gynecol* 2009;34(1):1–11. doi:10.1002/uog.6432.
72. NEZHAT CR, NEZHAT FR, NEZHAT CH, ADMON D. Treatment of ovarian endometriosis. In: Nezhat CR, Berger GS, Nezhat F, Buttram V, Nezhat CH, editors. *Endometriosis: Advanced Management and Surgical Techniques*. New York, NY: Springer New York; 1995. p. 95–106. (ISBN No. 1461384044).
73. OKARO E, CONDOUS G, KHALID A, TIMMERMAN D, AMEYE L, HUFFEL SV et al. The use of ultrasound-based ‘soft markers’ for the prediction of pelvic pathology in women with chronic pelvic pain – can we reduce the need for laparoscopy? *BJOG* 2006;113(3):251–6. doi:10.1111/j.1471-0528.2006.00849.x.
74. PASCUAL MA, GUERRIERO S, HERETER L, BARRI-SOLDEVILA P, AJOSSA S, GRAUPERA B et al. Diagnosis of endometriosis of the rectovaginal septum using introital three-dimensional ultrasonography. *Fertil Steril* 2010;94(7):2761–5. doi:10.1016/j.fertnstert.2010.02.050.



75. PATEMAN K, HOLLAND TK, KNEZ J, DERDELIS G, CUTNER A, SARIDOGAN E et al. Should a detailed ultrasound examination of the complete urinary tract be routinely performed in women with suspected pelvic endometriosis? *Hum Reprod* 2015;30(12):2802–7. doi:10.1093/humrep/dev246.
76. PATEMAN K, MAVRELOS D, HOO WL, HOLLAND T, NAFTALIN J, JURKOVIC D. Visualization of ureters on standard gynecological transvaginal scan: a feasibility study. *Ultrasound Obstet Gynecol* 2013;41(6):696–701. doi:10.1002/uog.12468.
77. PIKETTY M, CHOPIN N, DOUSSET B, MILLISCHER-BELLAISCHE AE, ROSEAU G, LECONTE M et al. Preoperative work-up for patients with deeply infiltrating endometriosis: transvaginal ultrasonography must definitely be the first-line imaging examination. *Hum Reprod* 2009;24(3):602–7. doi:10.1093/humrep/den405.
78. PINZAUTI S, LAZZERI L, TOSTI C, CENTINI G, ORLANDINI C, LUISI S et al. Transvaginal sonographic features of diffuse adenomyosis in 18–30-year-old nulligravid women without endometriosis: association with symptoms. *Ultrasound Obstet Gynecol* 2015;46(6):730–6. doi:10.1002/uog.14834.
79. REDWINE DB. Ovarian endometriosis: a marker for more extensive pelvic and intestinal disease. *Fertil Steril* 1999;72(2):310–5.
80. REID S, CONDOUS G. Should ureteric assessment be included in the transvaginal ultrasound assessment for women with suspected endometriosis? *Australasian Journal of Ultrasound in Medicine* 2015;18(1):2. doi:10.1002/j.2205-0140.2015.tb00021.x.
81. REID S, LU C, CASIKAR I, MEIN B, MAGOTTI R, LUDLOW J et al. The prediction of pouch of Douglas obliteration using offline analysis of the transvaginal ultrasound ‘sliding sign’ technique: inter- and intra-observer reproducibility. *Hum Reprod* 2013;28(5):1237–46. doi:10.1093/humrep/det044.
82. REID S, LU C, CASIKAR I, REID G, ABBOTT J, CARIO G et al. Prediction of pouch of Douglas obliteration in women with suspected endometriosis using a new real-time dynamic transvaginal ultrasound technique: the sliding sign. *Ultrasound Obstet Gynecol* 2013;41(6):685–91. doi:10.1002/uog.12305.
83. REINHOLD C, TAFAZOLI F, MEHIO A, WANG L, ATRI M, SIEGELMAN ES et al. Uterine adenomyosis: endovaginal US and MR imaging features with histopathologic correlation. *Radiographics* 1999;19 Spec No:S147–60. doi:10.1148/radiographics.19.suppl\_1.g99oc13s147.
84. REINHOLD C, TAFAZOLI F, WANG L. Imaging features of adenomyosis. *Hum Reprod Update* 1998;4(4):337–49.
85. ROSSI L, PALAZZO L, YAZBECK C, WALKER F, CHIS C, LUTON D et al. Can rectal endoscopic sonography be used to predict infiltration depth in patients with deep infiltrating endometriosis of the rectum? *Ultrasound Obstet Gynecol* 2014;43(3):322–7. doi:10.1002/uog.12535.
86. SAVELLI L, MANUZZI L, POLLASTRI P, MABROUK M, SERACCHIOLI R, VENTUROLI S. Diagnostic accuracy and potential limitations of transvaginal sonography for bladder endometriosis. *Ultrasound Obstet Gynecol* 2009;34(5):595–600. doi:10.1002/uog.7356.
87. SHRESTHA A. Risk factors for adenomyosis. *J Nepal Health Res Counc* 2012;10(22):229–33.
88. SOKOL AI, SHVEIKY D. Clinical Anatomy of the Vulva, Vagina, Lower Pelvis, and Perineum. GLOWM 2009. doi:10.3843/GLOWM.10000.
89. TIMOR-TRITSCH IE, LERNER JP, MONTEAGUDO A, MURPHY KE, HELLER DS. Transvaginal sonographic markers of tubal inflammatory disease. *Ultrasound Obstet Gynecol* 1998;12(1):56–66. doi:10.1046/j.1469-0705.1998.12010056.x.
90. TUTTLIES F, KECKSTEIN J, ULRICH U, POSSOVER M, SCHWEPPE KW, WUSTLICH M et al. ENZIAN-score, a classification of deep infiltrating endometriosis. *Zentralbl Gynakol* 2005;127(5):275–81. doi:10.1055/s-2005-836904.
91. VALENZANO MM, REMORGIDA V, ABBAMONTE LH, NICOLETTI A, RAGNI N, FERRERO S. Does transvaginal ultrasonography combined with water-contrast in the rectum aid in the diagnosis of rectovaginal endometriosis infiltrating the bowel? *Hum Reprod* 2008;23(5):1069–75. doi:10.1093/humrep/den057.
92. VAN DEN BOSCH T, DUEHOLM M, LEONE FP, VALENTIN L, RASMUSSEN CK, VOTINO A et al. Terms, definitions and measurements to describe sonographic features of myometrium and uterine masses: a consensus opinion from the Morphological Uterus Sonographic Assessment (MUSA) group. *Ultrasound Obstet Gynecol* 2015;46(3):284–98. doi:10.1002/uog.14806.
93. VERCELLINI P, CONSONNI D, DRIDI D, BRACCO B, FRATTARUOLO MP, SOMIGLIANA E. Uterine adenomyosis and in vitro fertilization outcome: a systematic review and meta-analysis. *Hum Reprod* 2014;29(5):964–77. doi:10.1093/humrep/deu041.

# 3 Surgical Techniques for Different Manifestations of Endometriosis



3.1	Peritoneal Endometriosis .....	180
3.2	General Remarks on Ovarian Endometriosis .....	184
3.3	Ovarian Endometriosis and Endometriomas .....	187
3.4	Deep Infiltrating Endometriosis (DIE) .....	200
3.5	Uterine Adenomyosis .....	221
3.6	Extragenital Endometriosis .....	257
3.7	Laparoscopic Diagnosis and Treatment of Superficial Pelvic Endometriosis .....	263
3.8	Robotic Laparoscopic Surgery for Endometriosis .....	268
3.9	Robotic-Assisted Laparoscopic Surgery for Deeply Infiltrating Endometriosis .....	275
3.10	Robotic Assistance in Endometriosis Surgery – Is this Technology a Game Changer? .....	286

## 3.1

## Peritoneal Endometriosis

Maurice K. Chung<sup>a</sup>**3.1.1 Introduction**

Endometriosis is one of the more prevalent gynecologic diagnoses among women with chronic pelvic pain, affecting more than half of those patients who receive a diagnosis for their chronic pelvic pain.<sup>4,6,8,11,13,14,18</sup> Symptoms include dyspareunia, cyclic perimenstrual low abdominal pelvic pain, symptom flares after sexual intimacy, and irritable voiding in the case of urinary tract involvement.<sup>9</sup> A definitive diagnosis of endometriosis requires visual confirmation of the lesion during laparoscopy, and histological confirmation of the presence of both ectopic endometrial glands and stroma.<sup>9</sup>

**3.1.2 Appearances and Morphology**

There are three types of endometriotic lesions: peritoneal, ovarian and rectovaginal. Morphologic and morphometric data show similarities between eutopic endometrium and red peritoneal lesions, suggesting that these lesions are the first stage of early implantation of endometrial glands and stroma.

After partial shedding, the red lesions re-grow constantly. The shedding induces an inflammatory reaction, provoking scarification, and the lesions become black. The subsequent fibrosis leads to areas of white opacification that are inactive.<sup>16</sup> In this chapter, we will focus on only peritoneal lesions.

Diagnosis of endometriosis lesion is established on the basis of a biopsy specimen sampled during laparoscopy.

The biopsied specimen needs to confirm the presence of hemosiderin-laden macrophages and endometrial glands (Fig. 3.1).

The appearances of endometriosis lesions can be divided into classical pigmented lesions and non-classical lesions.

---

<sup>a</sup> | RPh, MD, Clinical Professor; Department of Ob/Gyn, University of Toledo School of Medicine, Toledo, Ohio, USA  
 Director, Midwest Center of Excellence for Endometriosis, Pelvic Pain and Bladder Control, Lima, Ohio, USA  
 Women's Center of Excellence for Pelvic Pain, Organ Prolapse and Bladder Control,  
 Van Wert County Hospital, Van Wert, Ohio, USA

**Corresponding author:**

**Maurice K. Chung**, RPh, MD

Clinical Professor, Department of Ob/Gyn,  
 University of Toledo School of Medicine, Toledo, Ohio, USA  
 Midwest Regional Center for Chronic Pelvic Pain and Bladder Control  
 310 S Cable Rd  
 Lima, OH 45805, USA



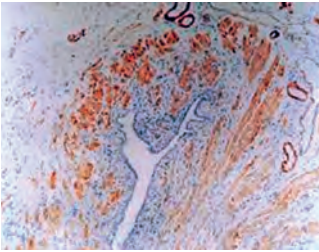


Fig. 3.1

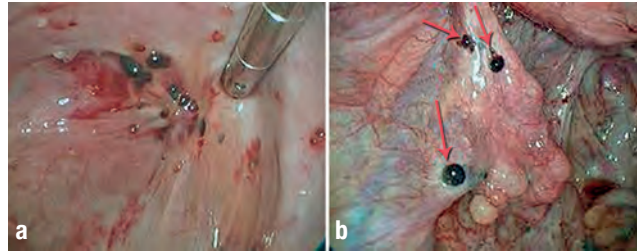


Fig. 3.2a, b

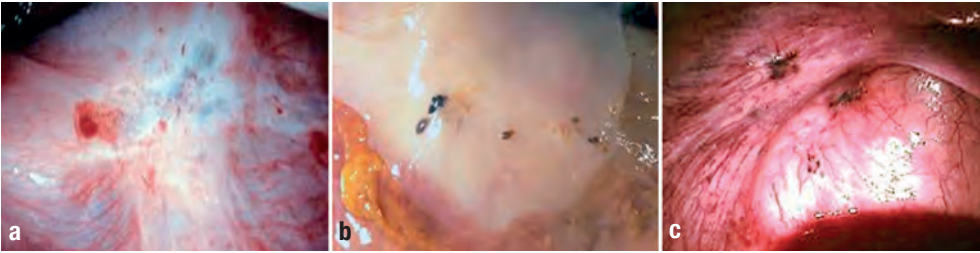


Fig. 3.3a–c “Powder burn”-like black lesions.

### 3.1.2.1 Classical Lesions

Classical pigmented lesions include red lesions, shown in the following pictures, and also “powder burn”-like black lesions (Figs. 3.2, 3.3).

### 3.1.2.2 Non-Classical Lesions

In Fig. 3.4, there is an invagination of yellow patchy endometriosis lesion in the pseudopocket, along with some red and clear lesions.

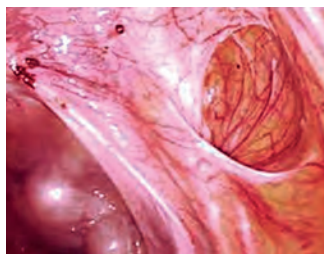


Fig. 3.4

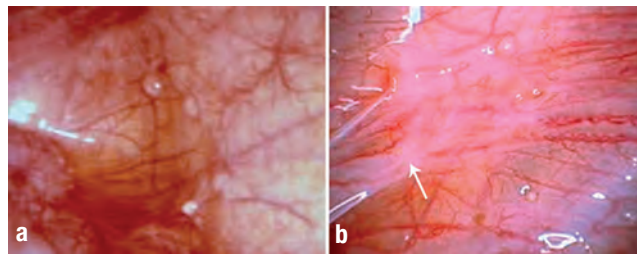


Fig. 3.5

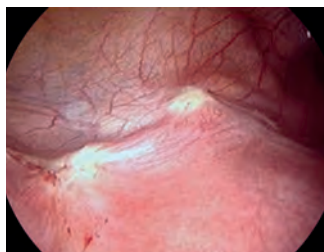

Fig. 3.6

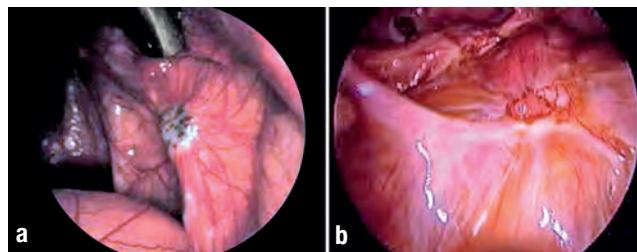


Fig. 3.7a, b

Figs. 3.5a, b show clear blister lesions of endometriosis.

Fig. 3.6 shows fibrotic endometriosis lesions.

Figs. 3.7a, b show black and red endometriosis and fibrotic endometriosis.

### 3.1.3 Surgical Techniques

In general, there are two methods in surgically treating peritoneal endometriosis. It is done by surgical excision or ablation of the endometriosis implants. Surgical procedures are usually carried out by using some form of energy, such as monopolar or bipolar electrocauterization. Some

techniques involve the use of laser technology, such as YAG, KTP or CO<sub>2</sub> laser to vaporize or excise endometriosis lesions whereas some other approaches are simply based on a cold scissor technique to excise the lesions. There are pros and cons for every technique. Of course, risks and complications are related to the different forms of energy used.

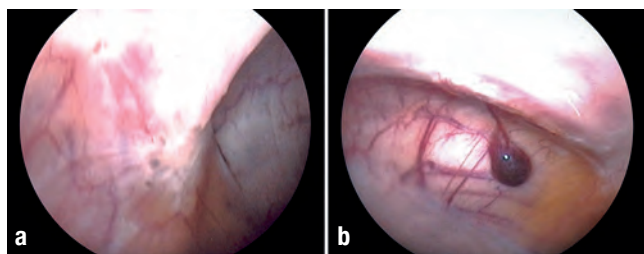


Fig. 3.8a, b

Figures 3.8a, b show left and right uterine sacral endometriosis.

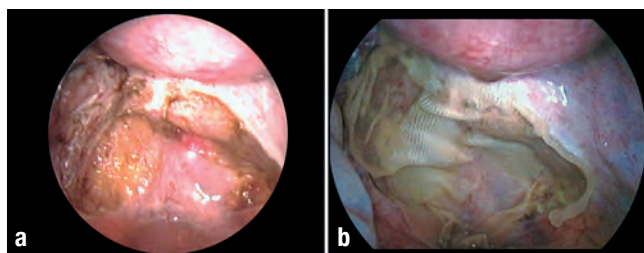


Fig. 3.9a,b Condition after CO<sub>2</sub> laser excision of endometriotic lesion: peritonectomy (a). Intercede<sup>®</sup> mesh was placed on the raw surface after endometriotic lesion (same patient as Fig. 3.9a) was excised to decrease adhesion formation (b).

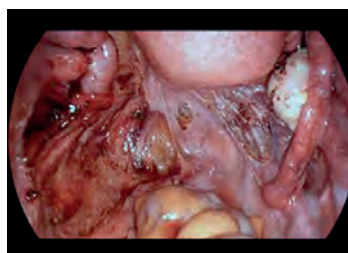

Fig. 3.10 Still image captured after laser excisional surgery of endometriosis in the cul-de-sac.

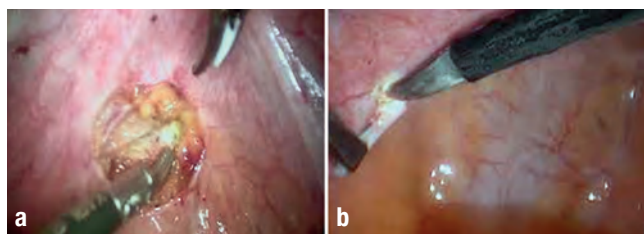


Fig. 3.11a, b Use of a monopolar instrument to ablate and excise the endometriotic lesion.

Figures 3.11a, b show the use of a monopolar instrument to ablate and excise the endometriosis.

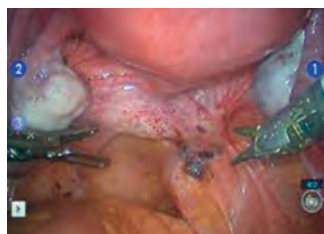

Fig. 3.12 Intraoperative view during robotic excision of the endometriosis lesion in the right uterine sacral ligament.

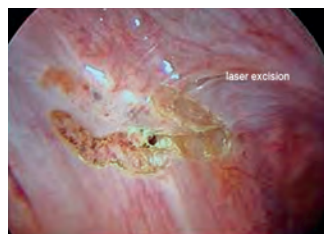

Fig. 3.13 CO<sub>2</sub> laser excision for fenestration and ablation of the peritoneal endometriosis.

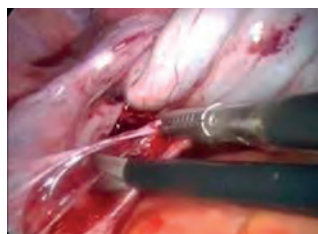

Fig. 3.14 Endometriotic lesion is excised by scissors.

### 3.1.4 Discussion

Endometriosis has been regarded as one of the most common causes of chronic pelvic pain which affects an estimated 5 million U.S. women.<sup>1</sup> Definitive diagnosis of endometriosis requires laparoscopic evaluation. Even though several new advances have been made in the treatment of this disease, the recurrent rate remains as high as 50%.<sup>7</sup> To exacerbate the issue, endometriosis is considered a progressive disease in more than 60% of patients.<sup>12</sup> This often leads to many reoperations, including laparoscopies and even hysterectomies. Treatment of endometriosis-related chronic pelvic pain remains challenging to the clinicians and the results have not been satisfactory. Diagnosing endometriosis sometimes can be difficult and also surgeon-dependent. At least 80% of chronic pelvic pain is associated with endometriosis.<sup>6,10,11,14,18</sup> On the other hand, support for laparoscopic diagnosis comes from data demonstrating that endometriosis can be found in 60% of asymptomatic patients,<sup>15</sup> and that progressive disease exists in close to 60% of patients overall.<sup>12</sup> Treating endometriosis is likewise challenging and similarly highly dependent on the surgeon. Surgeons are urged to obtain confirmed biopsy and it will often remain unclear whether the implants or adhesions found at surgery are the specific causes of the patients' pain. Therefore, even in the presence of endometriosis, suspicion of other chronic pelvic pain etiologies is warranted, particular in patients who do not respond adequately to treatment.

Although laparoscopic excisional surgery offers better success rate in treating endometriosis,<sup>17,19</sup> it also requires a higher level of operating skills. It is unfortunate that many patients are found to receive inadequate surgical treatment which often leads to persistent and recurrent disease. All these variables make the disease difficult to manage. Many patients have gone through numerous laparoscopies, and even after hysterectomy, a lot of them still suffer from chronic pelvic pain. Gynecologists are not primarily instructed in treating chronic pelvic pain patients. Many more recent studies suggest that chronic pelvic pain can have multiple pain generators such as interstitial cystitis, pudendal neuralgia and pelvic tension myofascial syndrome, among others. Therefore, even in the presence of endometriosis, surgeons are nonetheless advised to find out the co-existing pain generator.<sup>2,3,5</sup>

### 3.1.5 References

1. BALLWEG, ML. Public testimony to the U.S: Senate Committee on Labor and Resources Subcommittee on Aging 1993(May 5).
2. BENSON JT, GRIFFIS K. Pudendal neuralgia, a severe pain syndrome. *Am J Obstet Gynecol* 2005;192(5):1663–8. doi:10.1016/j.ajog.2005.01.051.
3. BUTRICK CW. Chronic pelvic pain: how many surgeries are enough? *Clin Obstet Gynecol* 2007;50(2):412–24. doi:10.1097/GRF.0b013e31804b195f.
4. CARTER JE. Combined hysteroscopic and laparoscopic findings in patients with chronic pelvic pain. *J Am Assoc Gynecol Laparosc* 1994;2(1):43–7.
5. CHUNG MK, CHUNG RP, GORDON D. Interstitial cystitis and endometriosis in patients with chronic pelvic pain: The “Evil Twins” syndrome. *JLS* 2005;9(1):25–9.
6. CHUNG MK, CHUNG RR, GORDON D, JENNINGS C. The evil twins of chronic pelvic pain syndrome: endometriosis and interstitial cystitis. *JLS* 2002;6(4):311–4.
7. GIOVANNI, B. Recurrent endometriosis. In: Nezhat CR, Buttram Jr VC, editors. *Endometriosis. Advanced Management and Surgical Techniques*. New York: Springer Verlag; 1994. p. 159–71.
8. HOWARD FM. The role of laparoscopy in chronic pelvic pain: promise and pitfalls. *Obstet Gynecol Surv* 1993;48(6):357–87.
9. HOWARD FM, EL-MINAWI AM, LI R. Endometriosis and endosalpingiosis. In: Howard FM, Perry CP, Carter JE, El-Minawi AM, editors. *Pelvic pain: Diagnosis and management*. Philadelphia: Lippincott Williams & Wilkins; 2000. p. 125–49. (ISBN No. 9780781717243).
10. HOWARD FM, EL-MINAWI AM, LI R. Endometriosis and endosalpingiosis. In: Howard, FM P, CP C, JE et al, editors. *Pelvic Pain Diagnosis & Management*. Philadelphia, PA: Lippincott Williams & Wilkins; 2000. p. 125–49.
11. KONINCKX PR, MEULEMAN C, DEMEYERE S, LESAFFRE E, CORNILLIE FJ. Suggestive evidence that pelvic endometriosis is a progressive disease, whereas deeply infiltrating endometriosis is associated with pelvic pain. *Fertil Steril* 1991;55(4):759–65.
12. MAHMOOD TA, TEMPLETON A. The impact of treatment on the natural history of endometriosis. *Hum Reprod* 1990;5(8):965–70.
13. MATHIAS SD, KUPPERMANN M, LIBERMAN RF, LIPSCHUTZ RC, STEEGE JF. Chronic pelvic pain: prevalence, health-related quality of life, and economic correlates. *Obstet Gynecol* 1996;87(3):321–7.
14. METTLER L, SCHOLLMAYER T, LEHMANN-WILLENBROCK E, SCHUPPLER U, SCHMUTZLER A, SHUKLA D et al. Accuracy of laparoscopic diagnosis of endometriosis. *JLS* 2003;7(1):15–8.
15. MOEN MH. Why do women develop endometriosis and why is it diagnosed? *Hum Reprod* 1995;10(1):8–11.
16. NISOLLE M, DONNEZ J. Peritoneal endometriosis, ovarian endometriosis, and adenomyotic nodules of the rectovaginal septum are three different entities. *Fertil Steril* 1997;68(4):585–96.
17. REDWINE DB. Aggressive laparoscopic excision of endometriosis of the cul-de-sac and uterosacral ligaments. *J Am Assoc Gynecol Laparosc* 1997;4(4):540–1.
18. RIPPS BA, MARTIN DC. Focal pelvic tenderness, pelvic pain and dysmenorrhea in endometriosis. *J Reprod Med* 1991;36(7):470–2.
19. WINKEL CA. Combined medical and surgical treatment of women with endometriosis. *Clin Obstet Gynecol* 1999;42(3):645–63.



## 3.2

## General Remarks on Ovarian Endometriosis

Thiers Soares Raymundo<sup>a</sup>**3.2.1 Introduction**

Endometrioma is defined as the formation of a cyst with ectopic endometriotic lining within the ovary. The origin of ovarian endometrioma is unknown; however, most authors believe that they result initially from a deposit of endometrium passed through the Fallopian tube,<sup>8,15,16</sup> causing adherence of the ovary to the pelvic peritoneum and progressive invagination of the ovarian cortex and metaplasia of the coelomic epithelium of the ovary.<sup>13</sup> Endometriomas are the third most common manifestation of endometriosis after Douglas peritoneum and uterosacral ligament endometriosis, and represent 35% of benign ovarian cysts requiring surgery. They are associated with advanced stage of endometriosis and increased morbidity.<sup>3</sup>

In many cases, operative laparoscopy – in contrast to laparotomy – is used as the current gold standard surgical approach in the treatment of endometriomas since it offers the potential of reduced postoperative pain, less analgesic requirement, shorter duration of hospital stay, and lower incidence of de novo adhesion formation.<sup>14</sup> There are two main risks associated with the surgical treatment of endometriomas:<sup>1</sup>

- The risk of excessive surgery (removal or destruction of normal ovarian cortex together with the endometrioma).<sup>2</sup>
- The risk of incomplete surgery (with subsequent early recurrence of endometriomas).<sup>13</sup>

Depending on the anticipated risk, one of two techniques is currently used, with both advantages and disadvantages: either cystectomy involving removal of the endometrioma wall or ablative surgery that entails opening the endometrioma and destroying the internal cyst wall by laser vaporization or bipolar coagulation.

Surgery of the ovarian endometrioma should in the first place address preservation of ovarian function by removal of the endometriotic pathology, which in most cases may affect the outside of the ovary, but progressively directly or indirectly affects the cortical layer.<sup>7</sup>

<sup>a</sup> | Professor, MD; Head of Department of Gynecological Endoscopy, Federal Hospital Cardoso Fontes; Director of the Postgraduate Program in Gynecological Endoscopy at the Supreme University; Consultant, Department of Gynecological Endoscopy, Pedro Ernesto University Hospital (UERJ), Rio de Janeiro, Brazil

**Corresponding author:**

**Thiers Soares Raymundo, MD**  
Avenida João Cabral de Mello Neto  
350 Apt 1407 Bloco 01  
Barra da Tijuca  
Rio de Janeiro 22775-05  
RJ, Brazil

Many authors have described several alternative laparoscopic techniques that may be used to treat the ovary compromised by the endometrioma. We will describe the initial steps in common of the procedures and then the specific features of each one:

Surgery starts with inspection of pelvic and peritoneal organs, peritoneal washings, staging of endometriosis, and adhesiolysis to fully release the adhesive ovaries from the surrounding structures. Ureterolysis may be necessary in some cases to release the ovary from its fossa due to dense adhesions.

**3.2.2 Ovarian Cystectomy**

Once the ovary is mobilized, the cortex is grasped with forceps, and is incised using laser, scissors, monopolar needle hook or harmonic scalpel. The incision must be made on the antimesenteric surface, as far as possible from the ovarian hilus to avoid unnecessary bleeding. The incision is extended and hydrodissection can be used to separate the cyst wall from the ovarian stroma. If the cyst is opened and spillage occurs, peritoneal irrigation must be performed to remove the chocolate-colored fluid although it cannot cause peritoneal implantations. The cyst is then decompressed by suction drainage and washed, and its wall is exposed and inspected to confirm the diagnosis of an endometrioma. The wall of the endometrioma is then excised or 'stripped away' from the underlying cortex using a combination of scissors (or monopolar hook or harmonic scalpel) and 5-mm grasping forceps. During the removal of the endometrioma, we apply a slight traction using the grasper to facilitate identification of the plane between the cyst wall and the ovarian stroma and then dissect this space, reducing the force required to remove the endometrioma capsule, thereby minimizing trauma to the ovarian tissue. The bed of the cyst needs to be carefully inspected to detect possible bleeding zones and hemostasis can be achieved with application of a 30-W current using bipolar forceps on the cyst bed. The endometrioma is removed through a 10-mm trocar or by using an endobag. Depending on the size of the remaining ovary, suture closure may be required.

**3.2.3 Ablation**

If the ovarian cyst remains unruptured despite the surgical manipulations required during adhesiolysis, it is punctured to drain and aspirate the cyst's chocolate-like content. We also can excise a 3- to 4-mm portion of the top of the cyst. Further extension of the incision into the antimesenteric edge facilitates meticulous inspection of the inner wall of the cyst for exclusion of possible suspicious areas followed by destruction of the cyst using either cutting or coagulating current, or using a form of laser energy. Vaporization continues until no further pigment can be seen. The depth of vaporization is shallow, as only the glandular epithelium and subjacent stroma need to be vaporized.

### 3.2.4 Mixed Techniques

Several surgeons have used mixed techniques to treat endometrioma. Some use laparoscopy, GnRH agonists and a second-look laparoscopy. It is called two-stage or even three-stage technique (if we consider GnRH-agonist therapy as a stage), which was first described by *Donnez et al.*<sup>5</sup> Others use combined excisional and ablative techniques.

#### 3.2.4.1 Two-Stage/Three-Stage Approach

The first laparoscopic procedure comprises only drainage of the cyst content, irrigation, and inspection of its inner wall. Finally, given the presence of suspicious or atypical lesions, a biopsy from the cyst's wall is sent for routine histologic examination or for frozen section analysis in order to confirm the diagnosis of endometriosis. Subsequently, GnRH agonists are administered for 3 months to reduce the cyst diameter, the stromal vascularization, and the rate of glandular mitotic activity of endometriosis. Three months after the first laparoscopic procedure, second-look laparoscopy is performed to vaporize the internal wall by using a CO<sub>2</sub> laser. The endometrioma is opened, and the interior wall of the cyst is vaporized with the CO<sub>2</sub> laser. After 12 weeks of GnRH-agonist therapy, the thickness of the endometrial cyst will be dramatically reduced, and the epithelial lining will be atrophic and white. Vaporization with the CO<sub>2</sub> laser allows very quick and easy vaporization of the internal wall, with minimal thermal damage to the normal ovarian cortex. The other areas of superficial active endometriosis involving the other ovary or the pelvic peritoneum are also treated. Reapproximation of the edges of the ovarian tissue can be achieved by a low power density CO<sub>2</sub> laser applied in defocused mode.

#### 3.2.4.2 Excisional and Ablative Technique

This procedure starts according to the cystectomy technique (described above). The difference is the approach to the hilus. When we reach the hilus, where the ovarian tissue is more functional and the cleavage plane is less discernible, resection of the dissected tissue (partial cystectomy) is performed. The stripping technique allows removal of 80% to 90% of the cyst. Upon completion of the first step of the procedure (partial cystectomy), the CO<sub>2</sub> laser is used to vaporize the remaining 10% to 20% of the endometrioma close to the hilus. Care must be taken to vaporize the entire residual cyst wall to avoid recurrence.

### 3.2.5 Discussion

Surgery plays a fundamental role in the treatment of endometriomas. Despite concerns about the effects of this surgery on the ovarian reserve, the benefits in terms of pain relief and spontaneous pregnancy rates favor this approach.<sup>9</sup> *Brosens et al.* (2014)<sup>7</sup> suggested that the pathology of small endometriomas depends not on the size but largely on the inflammatory disease resulting in smooth muscle cell metaplasia, fibrosis of the ovarian cortex and loss of follicles. For this reason, the ectopic endometrial tissue should be eliminated, the sooner the better and irrespective of the size of the cyst. A prospective randomized trial – analysing the outcomes of laparotomic versus laparoscopic ovarian cystectomy for management of endometrioma – has shown that the laparoscopic approach offers clear benefits to the patient in terms of reduced analgesic requirement, earlier discharge and a shorter post-operative recovery.<sup>10</sup> Several alternative laparoscopic techniques have been described for the treatment of ovarian endometriomata: cyst wall laser vaporization preceded or not by the use of GnRH<sup>6,17</sup> drainage and coagulation, and stripping.<sup>4</sup> As far as the ideal surgical technique is concerned, there is a great lack of well-conducted comparative studies. More studies are needed to compare excisional, laser ablation, and combined techniques and to evaluate the utility of GnRH agonists and a two-stage surgical approach.<sup>9</sup> *Donnez et al.* (2010)<sup>5</sup> reported on a study using the combined stripping-coagulation technique to avoid coagulation of bleeding, which commonly occurs after stripping of the pseudocapsule. The authors found out that it allows preservation of normal ovarian volume, as well as a normal AFC (antral follicular count) due to the preservation of the vascular blood supply to the ovary. They had a high pregnancy rate (40% at 8 months), and low recurrence rate (<2%). Two randomized controlled trials showed that excisional surgery for endometrioma provides a more favorable outcome than drainage and ablation using bipolar coagulation, with regard to the recurrence of the endometrioma, recurrence of symptoms and subsequent spontaneous pregnancy in women who were previously infertile.<sup>1,2</sup> According to *Muzii et al.* (2005),<sup>11</sup> recognizable ovarian tissue was inadvertently excised together with the endometriotic cyst wall in most cases during stripping for endometrioma excision. Close to the ovarian hilus, ovarian tissue removed along the endometrioma wall contained primordial, primary, and secondary follicles in 69% of cases. In cases of recurrent endometriomas or decreased ovarian reserve, the risks of repeated surgery should be taken into account. It is clear that considerable surgical expertise is required to decrease the risk of iatrogenic ovarian damage and avoid incomplete surgery. The level of expertise in endometriosis surgery inversely correlates with the amount of ovarian tissue inadvertently removed together with the endometrioma wall.<sup>12</sup>

### 3.2.6 References

1. ALBORZI S, MOMTAHAN M, PARSANEZHAD ME, DEHBASHI S, ZOLGHADRI J. A prospective, randomized study comparing laparoscopic ovarian cystectomy versus fenestration and coagulation in patients with endometriomas. *Fertil Steril* 2004;82(6):1633–7. doi:10.1016/j.fertnstert.2004.04.067.
2. BERETTA P, FRANCHI M, GHEZZI F, BUSACCA M, ZUPI E, BOLIS P. Randomized clinical trial of two laparoscopic treatments of endometriomas: cystectomy versus drainage and coagulation. *Fertil Steril* 1998;70(6):1176–80.
3. BUSACCA M, VIGNALI M. Ovarian endometriosis: from pathogenesis to surgical treatment. *Curr Opin Obstet Gynecol* 2003;15(4):321–6. doi:10.1097/01.gco.0000084247.09900.4f.
4. CANIS M, MAGE G, WATTIEZ A, CHAPRON C, POULY JL, BASSIL S. Second-look laparoscopy after laparoscopic cystectomy of large ovarian endometriomas. *Fertil Steril* 1992;58(3):617–9.
5. DONNEZ J, LOUSSE JC, JADOUL P, DONNEZ O, SQUIFFLET J. Laparoscopic management of endometriomas using a combined technique of excisional (cystectomy) and ablative surgery. *Fertil Steril* 2010;94(1):28–32. doi:10.1016/j.fertnstert.2009.02.065.
6. DONNEZ J, NISOLLE M, GILLET N, SMETS M, BASSIL S, CASANAS-ROUX F. Large ovarian endometriomas. *Hum Reprod* 1996;11(3):641–6.
7. GORDTS S, PUTTEMANS P, VALKENBURG M, BROSENS I, CAMPO R. Transvaginal endoscopy and small ovarian endometriomas: unravelling the missing link? *Gynecol Surg* 2014;11:3–7. doi:10.1007/s10397-013-0817-1.
8. HART R, HICKEY M, MAOURIS P, BUCKETT W, GARRY R. Excisional surgery versus ablative surgery for ovarian endometriomata: a Cochrane Review. *Hum Reprod* 2005;20(11):3000–7. doi:10.1093/humrep/dei207.
9. JADOUL P, KITAJIMA M, DONNEZ O, SQUIFFLET J, DONNEZ J. Surgical treatment of ovarian endometriomas: state of the art? *Fertil Steril* 2012;98(3):556–63. doi:10.1016/j.fertnstert.2012.06.023.
10. MAIS V, AJOSSA S, GUERRIERO S, PIRAS B, FLORIS M, PALOMBA M et al. Laparoscopic Management of Endometriomas: A Randomized Trial Versus Laparotomy. *Journal of Gynecologic Surgery* 1996;12(1):41–6. doi:10.1089/gyn.1996.12.41.
11. MUZII L, BELLATI F, BIANCHI A, PALAIA I, MANCI N, ZULLO MA et al. Laparoscopic stripping of endometriomas: a randomized trial on different surgical techniques. Part II: pathological results. *Hum Reprod* 2005;20(7):1987–92. doi:10.1093/humrep/deh851.
12. MUZII L, MARANA R, ANGIOLI R, BIANCHI A, CUCINELLA G, VIGNALI M et al. Histologic analysis of specimens from laparoscopic endometrioma excision performed by different surgeons: does the surgeon matter? *Fertil Steril* 2011;95(6):2116–9. doi:10.1016/j.fertnstert.2011.02.034.
13. NISOLLE M, DONNEZ J. Peritoneal endometriosis, ovarian endometriosis, and adenomyotic nodules of the rectovaginal septum are three different entities. *Fertil Steril* 1997;68(4):585–96.
14. PADOS G, TSOLAKIDIS D, BONTIS J. Laparoscopic management of the adnexal mass. *Ann N Y Acad Sci* 2006;1092:211–28. doi:10.1196/annals.1365.018.
15. SAMPSON JA. Heterotopic or misplaced endometrial tissue. *American Journal of Obstetrics and Gynecology* 1925;10(5):730–8. doi:10.1016/S0002-9378(25)90646-1.
16. SAMPSON JA. Peritoneal endometriosis due to the menstrual dissemination of endometrial tissue into the peritoneal cavity. *American Journal of Obstetrics and Gynecology* 1927;14(4):422–69. doi:10.1016/S0002-9378(15)30003-X.
17. SUTTON CJ, EWEN SP, JACOBS SA, WHITELAW NL. Laser laparoscopic surgery in the treatment of ovarian endometriomas. *J Am Assoc Gynecol Laparosc* 1997;4(3):319–23.



## 3.3

## Ovarian Endometriosis and Endometriomas

Ivo Meinhold-Heerlein<sup>a</sup> | Liselotte Mettler<sup>b</sup>

## 3.3.1 Introduction

Ovarian endometriomas are a common manifestation of endometriosis that are found in 17–44% of endometriosis patients.<sup>3</sup> They may reach up to 15 cm in size, and up to 50% are bilateral.<sup>49</sup>

While endometriosis patients may also have simple or functional cysts filled with hematoma, endometriosis cysts are characterized and classified by a distinct histopathologic pattern. This includes a broad range of stromal tissue, endometrioid cells, and collagenous fibers. Diagnosis requires the detection of pigmented macrophages, which are pseudoxanthoma cells containing lipofuscin and hemofuscin. The inner surface of the cyst presents a cuboidal or columnar epithelial layer; older cysts often show collagenous fibers only. Like the endometrial tissue, the epithelial layers of the cyst may undergo metaplastic changes.<sup>49</sup> In fact, the new WHO classification of ovarian, tubal, and primary peritoneal cancers distinguishes among endometriosis cysts, endometrioid cystadenomas, and endometrioid cystadenofibromas, placing endometriomas within the context of some types of ovarian cancer.<sup>27,33</sup> This connection is based on the fact that ovarian cancer, especially of the endometrioid and clear-cell type, may be associated with an ‘atypical ovarian endometriosis’ characterized by specific mutations (e.g., ARID 1a mutations) that may coexist in ovarian endometriosis and ovarian cancer in the same patient.<sup>49</sup> On the whole, endometriosis patients have a 50% greater risk of developing ovarian cancer.<sup>55</sup>

Apart from the latter findings, the origin and pathogenesis of endometriomas are not yet fully understood. Three main theories have been advanced. *Hughesdon* suggested that an invagination of the ovarian cortex results in a pseudocyst that collects menstrual debris from endometrial implants.<sup>19</sup>

*Brosens et al.* shared the invagination theory but believed that active implants must be located at the site of invagination.<sup>9</sup> *Donnez et al.* suggested that the coelomic epithelial layer of the ovarian surface undergoes a metaplastic change.<sup>14,38</sup> Finally, *Nezhat et al.* believed that endometrial implants within functional ovarian cysts may form endometriomas.<sup>37</sup>

Since endometriomas respond poorly to systemic therapy, surgical excision is still the most widely accepted treatment option. The indications for treatment may include pain, infertility, or sonographic evidence of a malignancy or premalignant lesion such as a borderline tumor. If further research confirms an association between atypical endometriosis and ovarian cancer, it may eventually provide an oncologic indication for surgical removal (see reviews<sup>22,49</sup>).

## 3.3.2 Indications for Surgery

The surgical removal of endometriomas in symptomatic patients is one of the standard therapeutic procedures for ovarian endometriosis recommended in national and international guidelines, such as those reported by *Dunselman et al.*<sup>15</sup> The most frequent indications for surgery are cyst-related symptoms, especially pain. Despite a lack of extensive data from prospective randomized trials, there is clear evidence that surgical removal or even ablation of an endometriosis cyst leads to pain reduction.<sup>10,18</sup> In addition, it has been shown that complete removal of endometriosis, including ovarian endometriosis, may lead to an increased fertility rate for up to 12 months after surgery. On the other hand, a recent Cochrane analysis comparing aspiration, cyst enucleation, and expectant management did not show a significant difference in pregnancy rates when these different strategies were followed by *assisted reproductive technology* (ART).<sup>7</sup>

Although the sensitivity and specificity of (transvaginal) ultrasound and tumor-marker analysis are both insufficient to classify an ovarian tumor as benign, premalignant, or even malignant, there are still morphologic criteria that can support the decision for surgical removal in order to achieve histopathologic certainty and avoid missing a malignancy.

Finally, ovarian endometriosis and other forms of deep infiltrating endometriosis are associated with a 50% increase in the risk for developing ovarian cancer. Thus, it may become important to reduce cancer risk by removing the endometriosis at a later time.<sup>17,28,40,45,46</sup>

There is always a potential for recurrence, however, even after a complete second-line cyst enucleation. The recurrence risk increases over time, rising to as much as 37% by 5 years after surgery.<sup>24</sup>

<sup>a</sup> | Professor, Hon. Professor, MD; Vice Director, Department of Gynecology and Obstetrics, Medical University of the RWTH Aachen, Germany

<sup>b</sup> | Professor Emerita, Department of Obstetrics and Gynecology, Kiel School of Gynecological Endoscopy, University Hospitals of Schleswig-Holstein, Kiel Campus, Kiel, Germany

## Corresponding authors:

Prof. h.c., Prof. Dr. med. habil. **Ivo Meinhold-Heerlein**  
Uniklinik RWTH Aachen  
Klinik für Gynäkologie und Geburtsmedizin  
Pauwelsstr. 30  
52074 Aachen, Germany  
E-mail: imeinhold@ukaachen.de

Prof. Dr. med. Dr. h.c. mult. **Liselotte Mettler**  
Universitätsklinikum Schleswig-Holstein – Campus Kiel  
Klinik für Gynäkologie und Geburtshilfe  
Arnold Heller-Str. 3/24  
24105 Kiel, Germany  
E-mail: lmettler@email.uni-kiel.de

### 3.3.3 Controversies in Surgical Removal

There are compelling arguments for and against the surgical removal of endometriomas. The removal of an endometrioma, while reducing pain, may also compromise the integrity of primordial and antral follicles. Studies have shown that primordial follicles are lost and the density of cells is decreased in proximity to an endometrioma.<sup>30,47,48</sup> Some authors blame this on an increased oxidative stress outside the cyst and the presence of free iron inside the cyst.<sup>31,47,48</sup> Additionally, a focal inflammation may incite fibrosis in the cortex-specific stroma. The coexisting oxidative stress and inflammation may lead to the increased recruitment and atresia of follicles.<sup>25</sup> Ovulation may be impaired<sup>6</sup> and the response to stimulation reduced. Interestingly, *Barri et al.* reported a 12% pregnancy rate after spontaneous conception with endometrioma in situ, compared with a 54% pregnancy rate after surgical removal.<sup>5</sup> It is clear that the risk of adnexal torsion, cyst growth and rupture, and malignant progression tend to favor surgical removal.<sup>41</sup>

Another important issue is ‘relapsed endometriosis.’ From a surgical standpoint, neither the stripping technique nor the ablative technique (opening and coagulating an endometriosis cyst without removing it) leads to a significantly different recurrence rate. In a study by *Muzii et al.* comparing the two techniques in 51 patients with bilateral endometriomas, the recurrence rate was 6% after stripping and 2% after coagulation. Thus, even if available data conflict in different studies, it may be preferable to perform an ablation in patients who desire future pregnancy.<sup>10,36</sup> But in infertile women with a recurrence of ovarian endometrioma, secondary surgery appears to impair the ovarian reserve and worsen reproductive performance. The pregnancy outcome in these cases may be better after direct ART, as shown by *Park et al.*<sup>39</sup>

Two parameters can pose major obstacles for endometriosis patients trying to conceive: the ‘ovarian reserve’ and the quality of the germ cells. While the germ cells tend to undergo a more rapid ageing process than in women without endometriosis, the ovarian reserve is decreased even further due to the endometrioma-related effects noted above. The ovarian reserve can be measured (indirectly) in terms of the antral follicle count or the level of *anti-Müllerian hormone* (AMH). These different aspects – a decreased ovarian reserve in endometriosis patients in general, further impairment due to endometrioma formation, and damage from a surgical procedure such as stripping or coagulation – must be taken into account when counseling a patient about surgery for ovarian endometriosis.<sup>51</sup>

Despite conflicting data in the literature, many studies have demonstrated that surgical excision can decrease the ovarian reserve. This may result from the removal of healthy ovarian tissue, damage due to coagulation, or local inflammation after surgery. Indeed, it has been shown that endometrioma removal is more likely to remove ovarian tissue than the removal of another benign cyst such as a dermoid or functional cyst.<sup>42</sup> This is particularly true in reoperations. Hormonal stimulation of an ovary appears to be more difficult after surgery. However, neither the pregnancy rate with IVF alone nor the sequence of surgery and IVF leads to a statistically significant difference.<sup>22</sup>

### 3.3.4 Strategy

In counseling a patient about surgery, it is essential to consider the motivation for surgery. We recommend a differentiated approach:

- For pain or other endometriosis-related symptoms: surgical removal of the cyst (by stripping or coagulation).
- For infertility: surgical removal before or after fertility treatment. We recommend surgery for patients with a unilateral endometrioma and no prior surgical treatment. For patients with recurrent endometrioma, we recommend direct fertility treatment without surgery.
- For patients with an ovarian cancer risk (atypical endometriosis): surgical removal of the cyst.

### 3.3.5 Technique

**Trocar placement and surgical site:** Two working trocars are usually sufficient for the enucleation of an ovarian cyst. A third working trocar may be helpful in more challenging situations such as the presence of dense adhesions, obesity, or intestinal involvement. Additionally, it may be helpful to antevert the uterus using a uterine manipulator. The pattern of trocar placement depends on the surgeon’s preference. We place the two standard working trocars in the lower abdomen lateral to the inferior epigastric artery (e.g., lateral umbilical ligament).

For the third working trocar, we prefer a paraumbilical site in the midclavicular line. Another option is to place the trocar in the midline cranial to the symphysis.

**Salpingoovariolysis:** Endometriosis causes dense adhesions to form between the ovary and its surroundings. Thus the ovary may be adherent to the pelvic sidewall, uterus, bowel, and even the contralateral ovary depending on size and bilaterality. In removing any cyst, it is important to free the ovary completely without damaging either the ovary or adjacent structures. If the bowel is adherent, gentle traction should be placed on the bowel to expose the plane of dissection between the bowel and ovary. The adhesions should be cut with scissors rather than an energy device to prevent thermal injury to the tissues. In the case of a ‘frozen pelvis,’ it may be helpful to open the retroperitoneal space at the level of the sacral promontory so that the ureter can be identified. Then the ureter is followed and the bowel, ureter, and ovary are separated from one another. The next step may be to detach the ovary from the uterus. This may require applying traction to the ovary with a grasper. The adhesion can then be identified and divided with scissors or an energy device (i.e., using monopolar or bipolar current or ultrasound). The last step is to free the ovary from the pelvic sidewall. The ovary is held anteriorly with a grasper, which may be held by the surgeon or by an assistant. The suction-irrigation device can then be used for blunt dissection, carefully freeing the ovary from the endometriosis-affected peritoneal tissue of the pelvic sidewall. The suction-irrigation tube is swiped between the ovary and pelvic wall in a parallel direction, rather than perpendicular.

Frequently the cyst will rupture at this stage, and the chocolate cyst can be confirmed. The fluid is evacuated and dissection

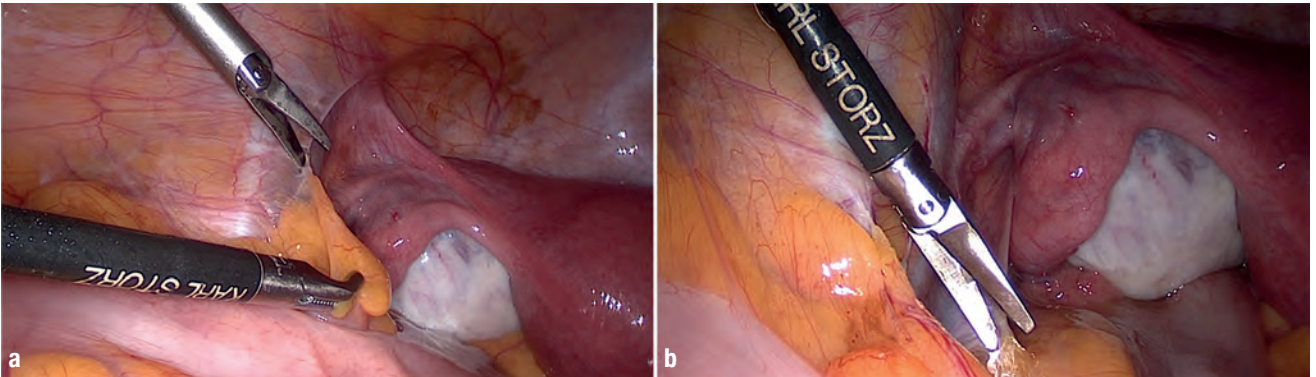


is continued in the same fashion until the ovary is completely freed. Any bleeding sites can be carefully coagulated with bipolar current. In most cases the anatomic structures of the ovarian ligament, infundibulopelvic ligament, fallopian tube, ovary, and pelvic wall can be identified. Do not coagulate the pelvic wall before identifying the ureter! This is because the ureter is always close to the surgery site and is vulnerable to thermal injury.

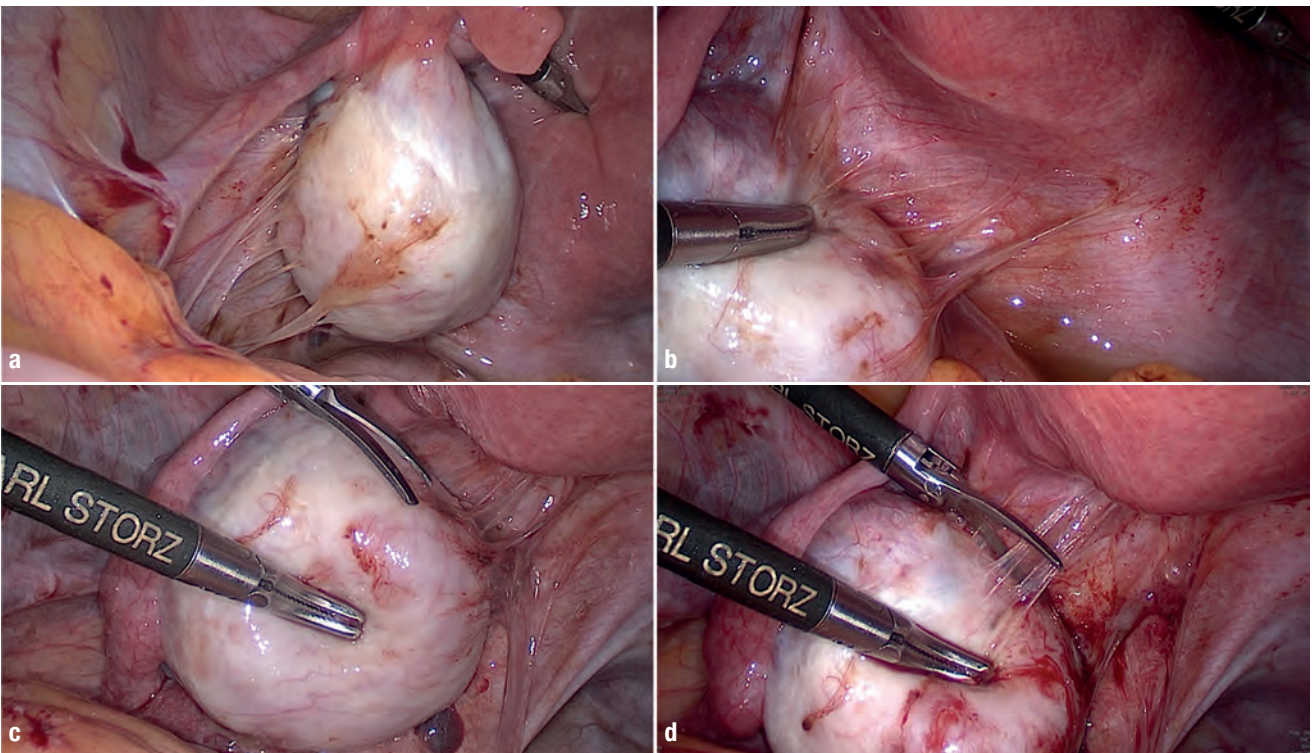
**Cyst enucleation:** Most endometriomas will rupture during ovariolysis. If that occurs, the rupture site on the ovary can serve as the starting point for cyst enucleation. The opening should be enlarged along the ovarian axis or equatorially so that the ovary is divided into two equal parts.

It is important at this stage to identify the proper plane of dissection. This may be difficult because endometriomas adhere to the ovarian tissue. This is especially true for lesions

with a fibroblastic rather than fibrocystic histology. All dissection should proceed very slowly and carefully so that normal ovarian tissue is damaged as little as possible. If the layers cannot be separated at one site, another should be tried. Always start the dissection at the easiest site, leaving the more difficult part for the end. The graspers should always be placed close to each other; otherwise if the surgeon ends up pulling a long piece of tissue, the normal tissue may tear, or the cyst itself may tear, and this will make the dissection more difficult. Coagulation should be used sparingly so that germ cells are prevented from thermal damage. Most bleeders will stop by themselves; only heavier bleeders should be selectively cauterized. If the endometrioma measures 5 cm or less, the ovary will shrink after cyst enucleation and there is no need for reapproximating sutures. If the defect approaches the ovarian ligament, an (intracorporeal) suture may be used, taking care to avoid stitching the vessels (Figs. 3.15–3.21).

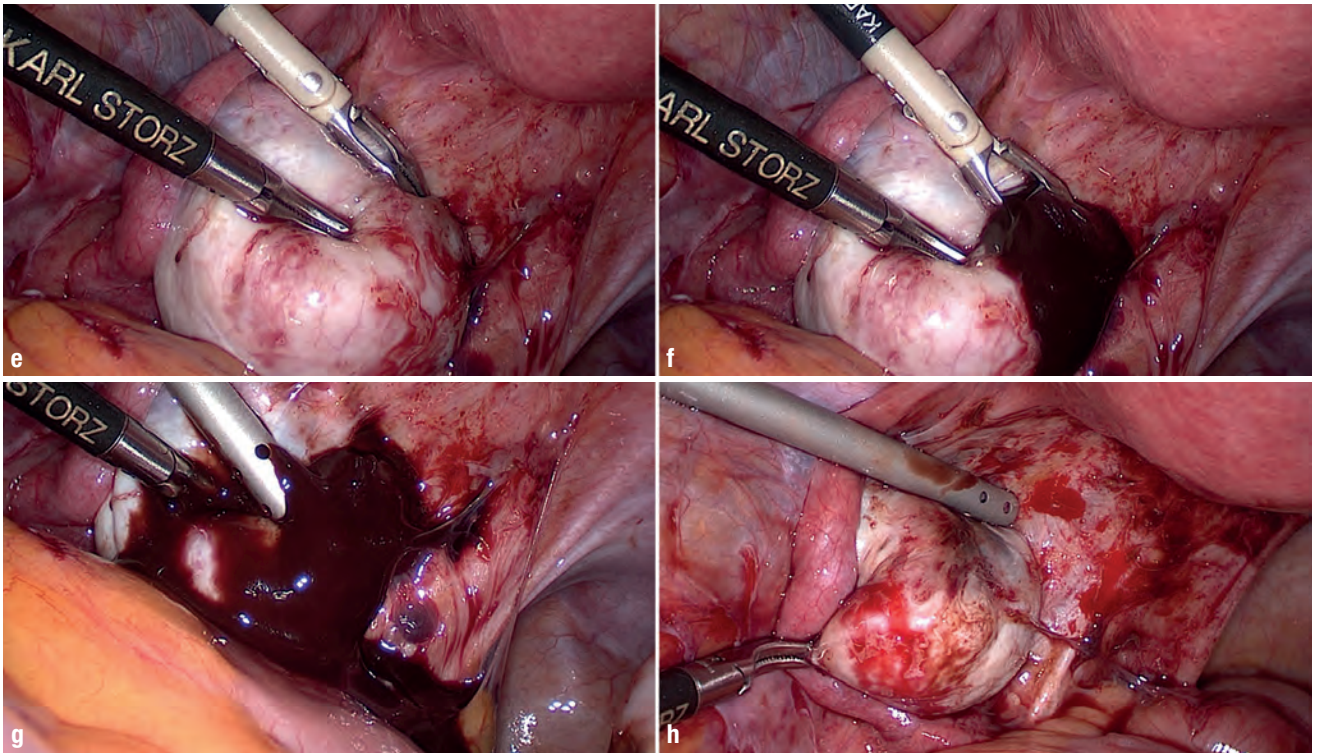


**Fig. 3.15a, b Adhesiolysis.** Gentle traction on the mesosigmoid exposes an avascular plane, which is cut with scissors (a). The adhesion is divided until the sigmoid colon is completely freed (b).

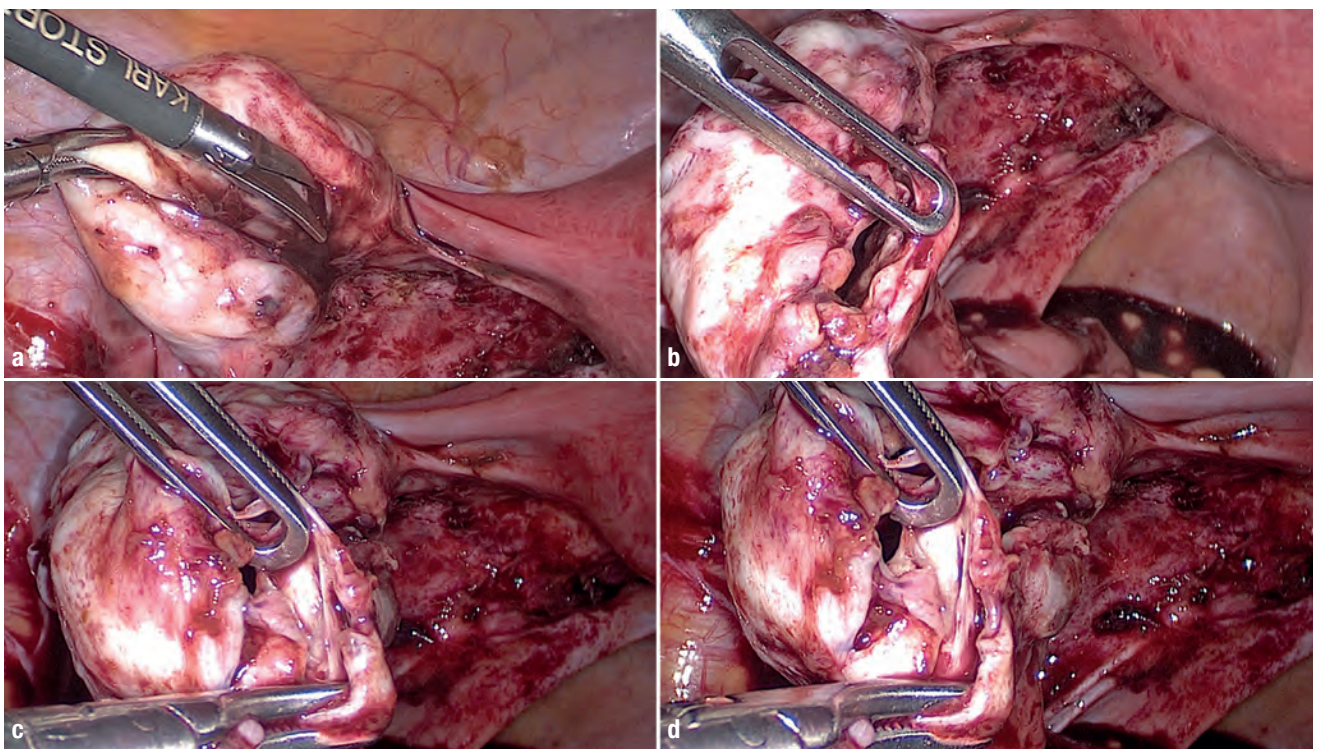


**Fig. 3.16a–d Ovariolysis.** The uterus is anteverted, exposing adhesions between the ovary and pelvic wall (a). The ovary is freed by blunt dissection between the ovary and uterus (b). Indentation of the ovary exposes filmy adhesions between the ovary and uterus close to the ovarian ligament (c, d).



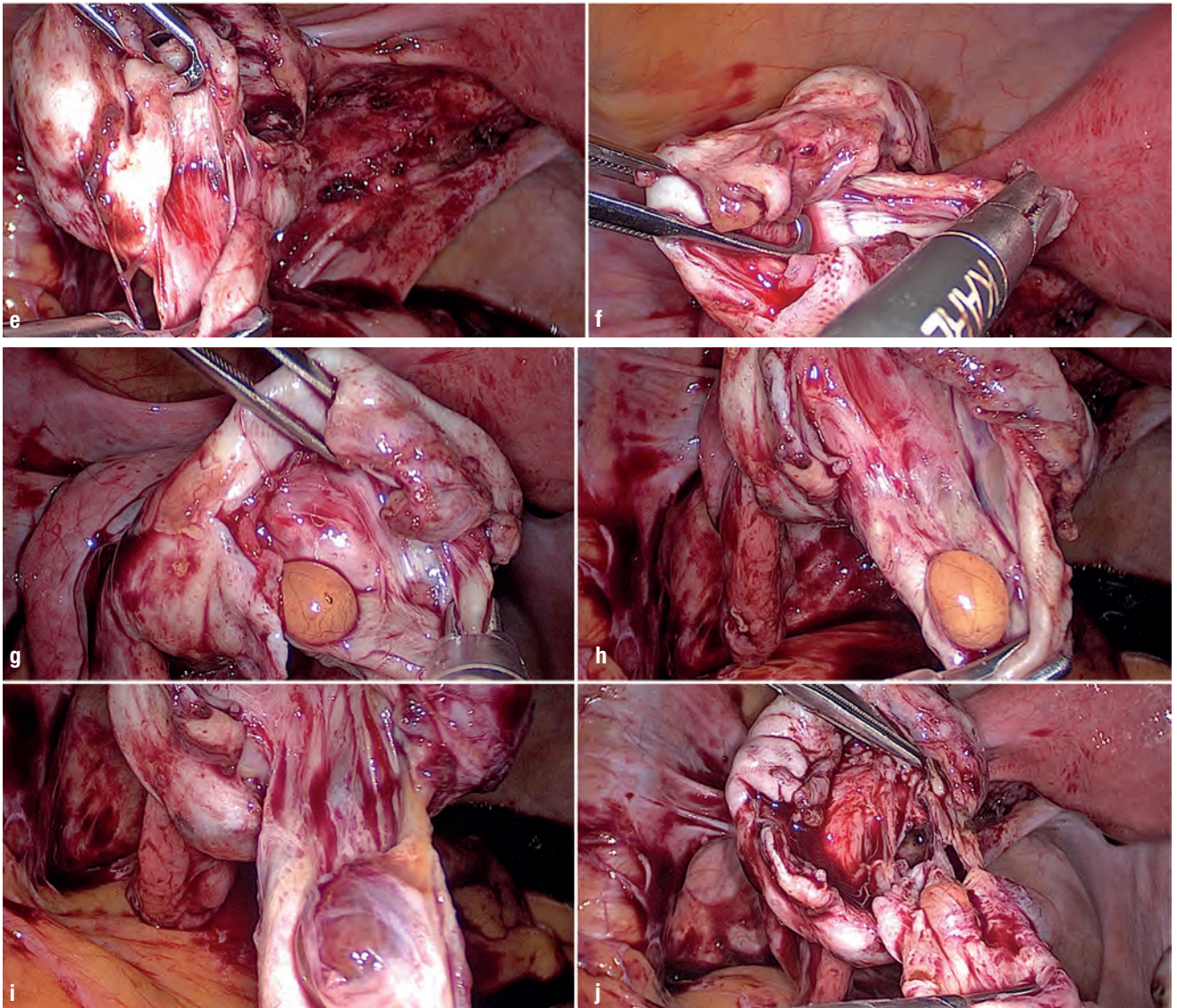


**Fig. 3.16e–h** The ovary and uterus are gently forced apart, using a bipolar Kelly grasper without current (e). The cyst will often rupture during dissection, and a chocolate-like fluid is seen (f). The fluid is evacuated (g). Blunt dissection with the suction-irrigation tube is performed parallel to the cleavage line between the ovary and adjacent tissue of the pelvic wall (h).

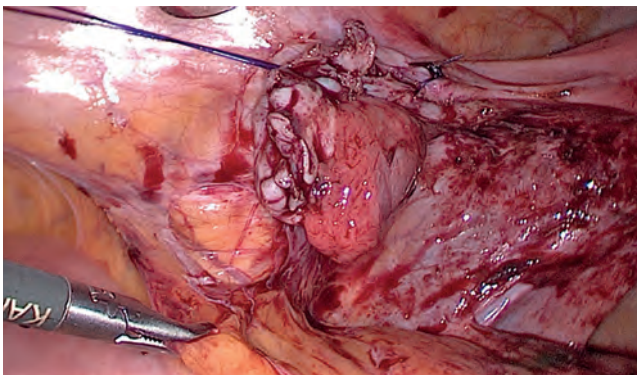


**Fig. 3.17a–d Cyst enucleation (stripping).** The ovary is pulled anterolaterally. The rupture site is exposed and enlarged with scissors (a). Normal ovary and cyst are identified and grasped separately (b–d).



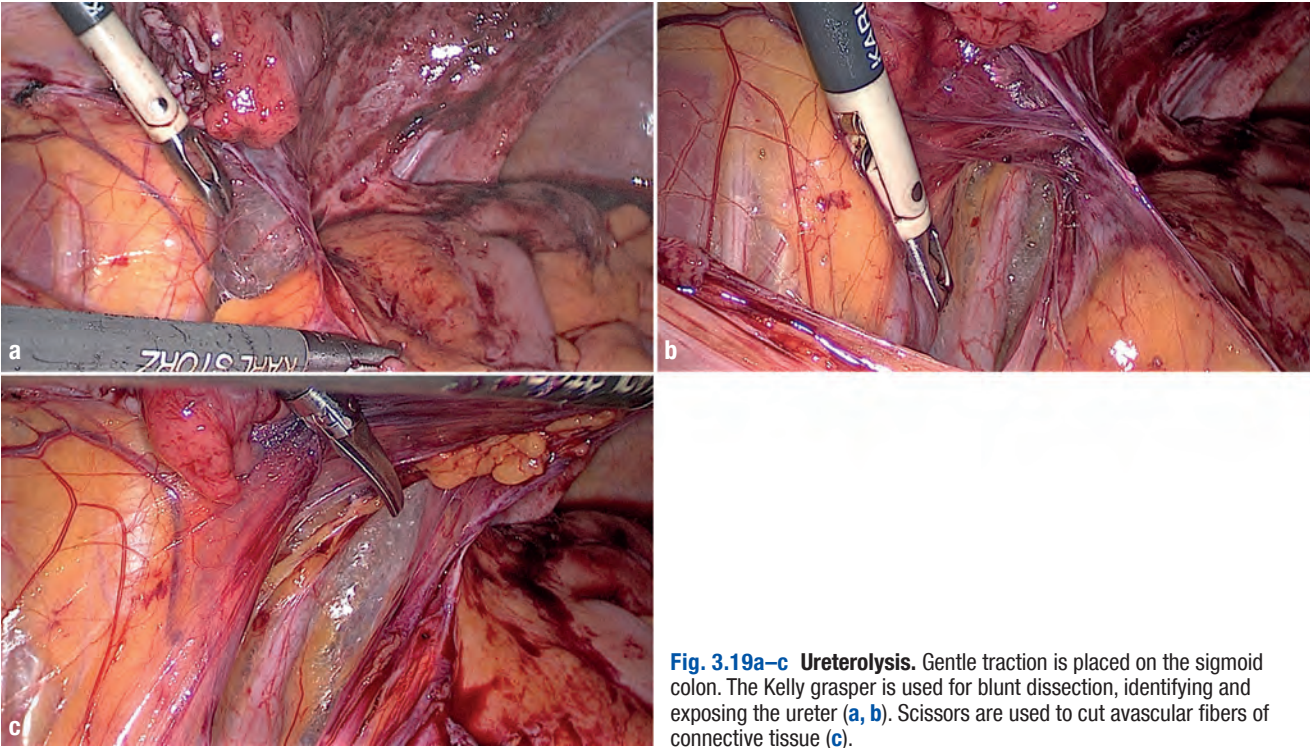


**Fig. 3.17e–j** The line (plane) between the ovary and cyst is visualized, and gentle traction is applied in perpendicular fashion to gradually separate the cyst from normal ovarian tissue. There should be little or no bleeding when this is done in the correct plane. The two graspers should be placed fairly close together for stripping the cyst (**e**). Even if the dissection is performed very carefully, normal tissue (e.g., a small functional cyst) is removed with the endometrioma. After the endometriosis cyst has been removed, bleeding vessels are sparingly coagulated (**g–j**).

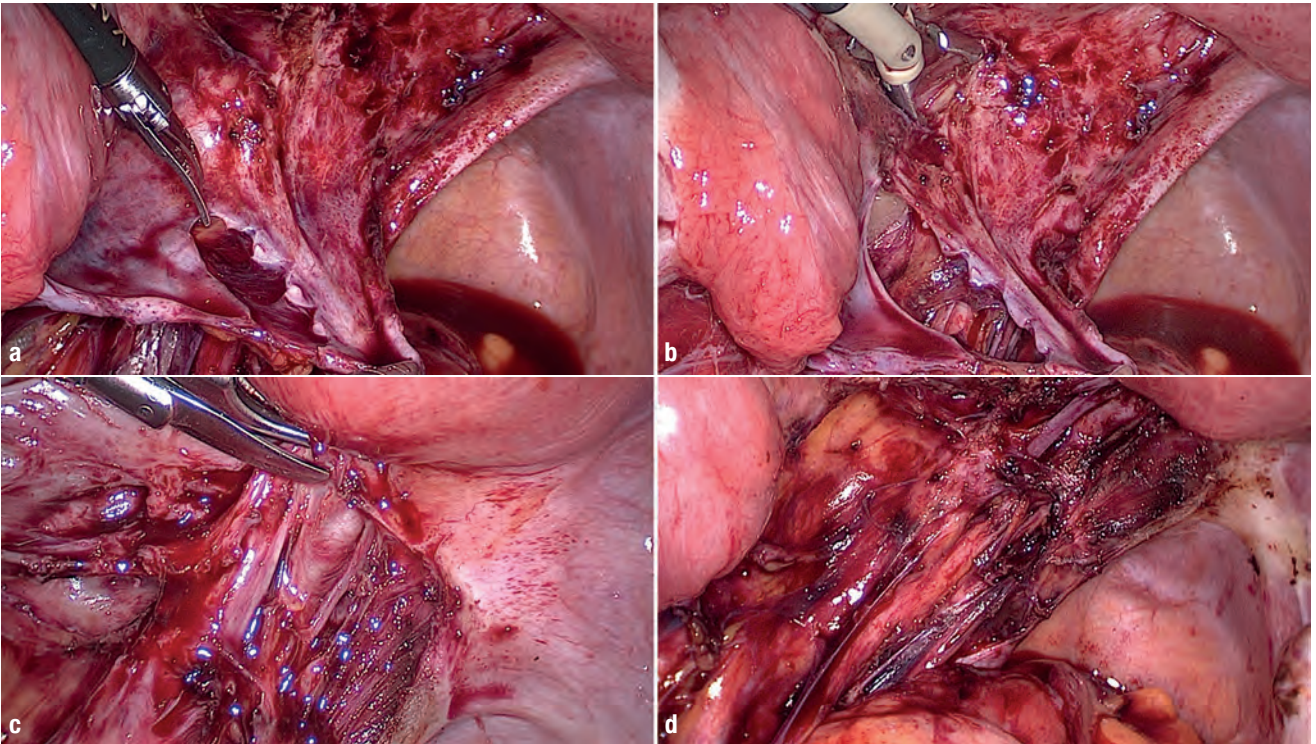


**Fig. 3.18 Ovariopexy.** An ovariopexy helps to expose the ovarian fossa.



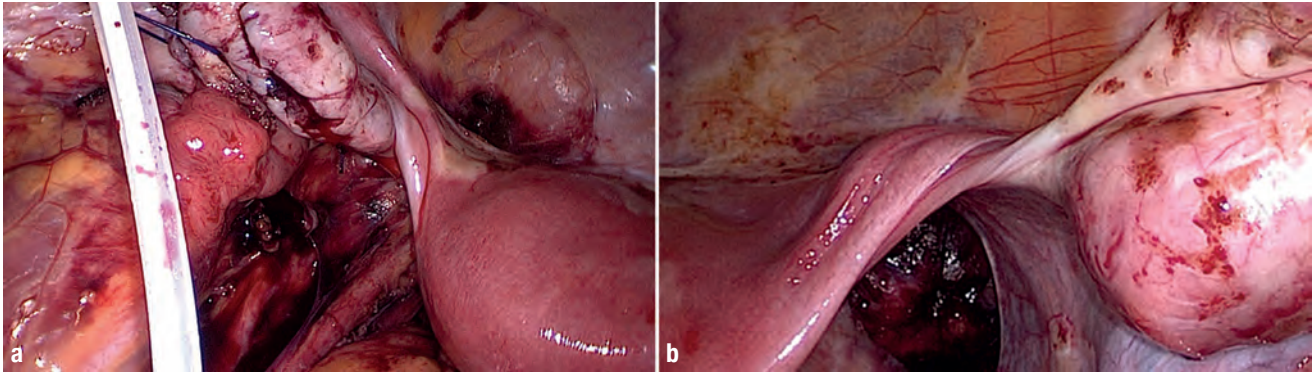


**Fig. 3.19a–c Ureterolysis.** Gentle traction is placed on the sigmoid colon. The Kelly grasper is used for blunt dissection, identifying and exposing the ureter (**a, b**). Scissors are used to cut avascular fibers of connective tissue (**c**).



**Fig. 3.20a–d Deperitonealization of the ovarian fossa.** While traction is placed on the peritoneum, the endometriosis-affected peritoneal tissue is excised with a scissors (**a**). The Kelly grasper may help to force apart healthy and affected peritoneal tissue (**b**). The peritoneum is excised with scissors close the uterus (**c**). Final view after deperitonealization of the ovarian fossa (**d**).





**Fig. 3.21a, b** Final view at the conclusion of surgery. The ovariopexy remains in place for two days. The drain is removed as output diminishes.

**Ovariopexy:** In almost all cases of ovarian endometriosis, the ovary is involved by peritoneal endometriosis of the pelvic wall. This makes it necessary to remove the peritoneal and deep infiltrating endometriosis involving adjacent tissues, i.e., the peritoneal tissue of the ovarian fossa and the uterosacral ligament. A temporary ovariopexy is helpful in exposing the field for this part of the procedure. There are many ways to fix the ovary temporarily. We prefer an extracorporeal suture on a straight needle introduced into the abdominal cavity under vision at a site lateral to the lower working portal. The needle is then passed through the ovary and returned through the abdominal wall. The suture is tied outside the abdomen. The ovary may be kept in that position for up to 1–2 days postoperatively to prevent immediate postoperative adhesions between the ovary and the pelvic wall or bowel. Alternatively, an assistant can lift the ovary with a grasper to expose the field for deperitonealization and ureterolysis.

**Deperitonealization of the ovarian fossa and ureterolysis:**

The peritoneum adjacent to the ureter is often involved by endometriosis. Since deep infiltrating endometriosis can lead to hydronephrosis and hydroureter, and because complete excision is the best way to prevent recurrence and yields the highest pregnancy rates, deperitonealization of the ovarian fossa and, if necessary, of the uterosacral ligament is recommended. To spare the ureter, the ureter should be identified and ureterolysis performed, carefully preserving the vessels and nerve fibers accompanying the ureter.

The ureter should be visualized where it crosses the iliac vessels, approximately at the level of the sacral promontory. The retroperitoneal space is then opened parallel to the ureter. This can be accomplished by blunt dissection with a Kelly grasper. Look for unaffected peritoneum to start the

dissection. The ureter is traced distally until the uterine artery is seen crossing the ureter medially to reach the uterus. It may even be necessary to dissect the ureter as far as the parametrial tissue. The peritoneum is stripped to ensure the removal of all endometriosis-affected tissue.

The following tips may be helpful in freeing the ureter safely:

- Dissect parallel to the ureter.
- Place no traction on the ureter.
- Use bipolar current carefully and sparingly.
- Thin the peritoneum.
- Keep the ureter in the ‘web’ of the cardinal ligament.
- Expect endometriosis where the uterine artery crosses the ureter.
- Use double J stents if necessary.
- Be aware that if you operate endometriosis as radically as you would a cancer, you can expect the same side effects.

**Adhesion prophylaxis:** Surgeons may use any preferred barrier method to prevent adhesions, such as oxidized regenerated cellulose (Interceed®), expanded polytetrafluoroethylene (Gore-Tex®), or sodium hyaluronate with carboxymethylcellulose (Septrafilm®). There is no clear evidence, however, that any barrier method can prevent adhesion formation or lead to improved pregnancy rates.<sup>2</sup>

**Drain:** Since coagulation is used sparingly on the ovary, the cyst bed may still ooze at the end of surgery. A drain should be inserted and remain in place until its output is less than 100 mL/24 h.

### 3.3.6 Statistical Analysis of Endometrioma Surgery

#### 3.3.6.1 Material and Methods

From 1995 to 2004, we retrospectively analyzed 3057 patient medical records and surgical reports at the Department of Obstetrics and Gynecology of Kiel University Hospital in Kiel, Germany. Based on these records and reports, we histologically verified 550 cases of ovarian endometriotic cysts that underwent conservative excision via laparoscopy or laparotomy. Data on general patient characteristics, endometrioma symptoms, and diagnostic and surgical findings were collected from clinical records and reviewed (Fig. 3.22). Patient characteristics are summarized in Table 3.1. Letters were sent to the patients asking them to fill in and return a questionnaire. With a final return rate of 52.5%, there were 289 patients in the follow-up study. The questionnaire asked about the possible postoperative occurrence of another endometriosis cyst, timing of occurrence, possible malignancy, as well as reoperation rate, type of operation, and recurrent pain symptoms (pain lasting > 1 week, dysmenorrhea, and dyspareunia). Patients were surveyed about their preoperative and postoperative fertility, whether they had had a planned spontaneous pregnancy with or without complications and, in infertile patients, whether artificial insemination had been successful. The recurrence of ovarian endometrioma was defined as a positive response to the presence of an endometriosis cyst as reported by the patient on the questionnaire. The average follow-up period was 12.9 years, with a range from 7.0 years to 16.9 years between surgery and follow-up.

Data for analysis were recorded using Microsoft Access software (Redmond, Washington). Statistical analysis was performed using Microsoft Excel and SPSS software (IBM Corporation, Armonk, New York). Patient identification numbers were assigned to ensure confidentiality. The percentage data are based primarily on total case numbers; but in the absence of information, the corrected probability is given. The chi-squared test was used in the analysis of categorical values. The statistical significance level was set at 5% ( $P < 0.05$ ). The recurrence-free interval probabilities were estimated using the Kaplan-Meier method. The log-rank test (Mantel-Cox) was used to compare the survival times of two groups. Postmenopausal women were not considered in the postoperative analysis of dysmenorrhea.<sup>32</sup>

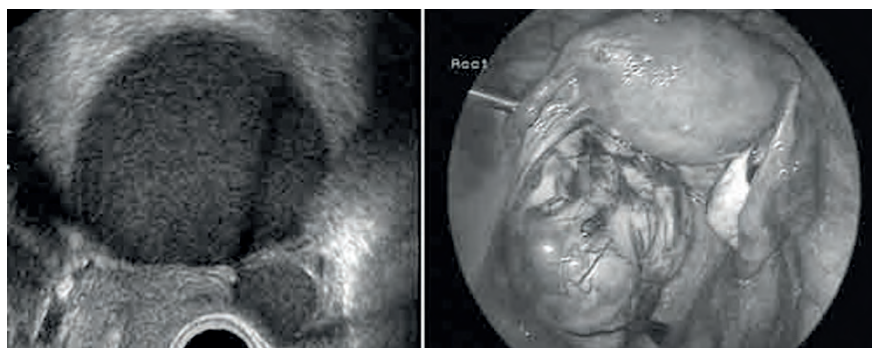
#### 3.3.6.2 Results

At the time of surgery, the mean age of all endometrioma patients was 37.2 ( $\pm 9.0$ ) years. Their mean age at follow-up was 50.5 ( $\pm 9.3$ ) years (Table 3.1). Younger preoperative age, nulliparity, and prior laparoscopic surgery for ovarian endometrioma positively predicted the presence of pain and dysmenorrhea. Larger cyst size (> 8 cm) was also associated with occurrence of pain, while primary or secondary sterility was associated with a higher rate of dysmenorrhea.

Factors associated with recurrence of dysmenorrhea were younger age ( $P < 0.01$ ), nulliparity ( $P < 0.05$ ), and larger cyst size ( $P < 0.05$ ). Prior laparoscopic surgery for ovarian endometrioma ( $P < 0.05$ ) was the only significant risk factor relating to the recurrence of pain (Table 3.2).

One hundred ninety-seven patients were initially diagnosed with endometriomas at the time of surgery. Forty-seven of these patients (23.9%) had a recurrent ovarian endometrioma in the follow-up period. 68.1% of the same subset of patients (32 of 47) had undergone a reoperation in the follow-up period (Table 3.1). Of those 32 patients, 17 (53.1%) required 1 reoperation, 9 patients (28.1%) required 2 reoperations, and 6 patients (18.8%) required 3 or more reoperations due to new endometriosis cysts. The probability of a recurrence-free interval was 76.1% for all primarily diagnosed endometriomas over our study period.

Patients with preoperative pain showed a significantly higher recurrence rate (log-rank test  $P = 0.013$ ). The Kaplan-Meier graph shows that patients without preoperative pain had a significantly higher recurrence-free interval of 84.7% when compared with patients who had a history of preoperative pain. The latter group were only 69.4% recurrence-free by the end of the follow-up period (Fig. 3.23). Another statistically significant risk factor for endometrioma recurrence was preoperative dysmenorrhea (log-rank test  $P = 0.013$ ). The Kaplan-Meier curve (Fig. 3.24) shows that women without preoperative dysmenorrhea have a recurrence-free interval of 81.4% compared with a recurrence-free interval of only 66.2% in women with preoperative dysmenorrhea.



**Fig. 3.22** Transvaginal sonogram of a 6-cm (diameter) endometrioma of the left ovary and corresponding laparoscopic image.

Patient Characteristics (n = 550) (Factors)		Cases n (%)
Age (years)		37.2 ± 9.0 <sup>a</sup>
BMI (kg/m <sup>2</sup> )	< 19	43 (7.8)
	19–24	344 (62.5)
	25–30	123 (22.4)
	> 30	40 (7.3)
Sterility	primary	261 (47.5)
	secondary	52 (9.5)
Parity ≥ 1		194 (35.3)
Abortion or miscarriage ≥ 1		72 (13.1)
Pain		338 (61.5)
Dysmenorrhea		214 (38.9)
Recurrence of previous endometrioma		153 (27.8)
Previous laparoscopic surgery of endometrioma		226 (41.1)
Presence of uterine myoma		105 (19.1)
CA-125 <sup>b</sup> (U/ml)	increased (> 35 U/ml)	147 (47.6)
Cyst size (cm)	2–4	316 (57.5)
	5–8	209 (38.0)
	> 8	25 (4.5)
Cyst rupture	preoperative	23 (4.2)
	intraoperative	281 (51.1)
Follow-up Patient Characteristics (n = 289)		Cases n (%)
Age (years)		50,5 ± 9,3 <sup>b</sup>
Postoperative medical treatment		162 (56.1)
Postoperative pain		96 (33.2)
Postoperative dysmenorrhea <sup>b</sup>		93 (34.8)
Recurrence of first diagnosed ovarian endometrioma <sup>b</sup>		47 (23.9)
Re-operation rate of first diagnosed ovarian endometrioma <sup>b</sup>		32 (68.1)
Postoperative pregnancy desire		111 (38.4)
Postoperative pregnancy <sup>b</sup>		60 (54.1)

**Table 3.1** Patient characteristics.<sup>a</sup> Mean ± SD<sup>b</sup> The sum does not add up to the total because of missing values or because of a new subtotal. Body Mass Index (BMI).

Analysis of Factors Related to the Occurrence / Recurrence of Pain and Dysmenorrhea <sup>32</sup>				
Factors	Preoperative	Postoperative	Preoperative	Postoperative
	Pain		Dysmenorrhea	
	P-value (n = 550)	P-value (n = 289)	P-value (n = 550)	P-value (n = 267)
Younger age (years)	< 0.01	NS	< 0.01	< 0.01
BMI (kg/m <sup>2</sup> )	NS	NS	NS	NS
Sterility	NS	NS	< 0.01	NS
Nulliparity	< 0.05	NS	< 0.05	< 0.05
Abortion/miscarriage	NS	NS	NS	NS
Previous laparoscopy of endometrioma	< 0.01	< 0.05	< 0.05	NS
Larger cyst size (> 8 cm)	< 0.05	NS	NS	< 0.05
Cyst rupture	NS	NS	NS	NS

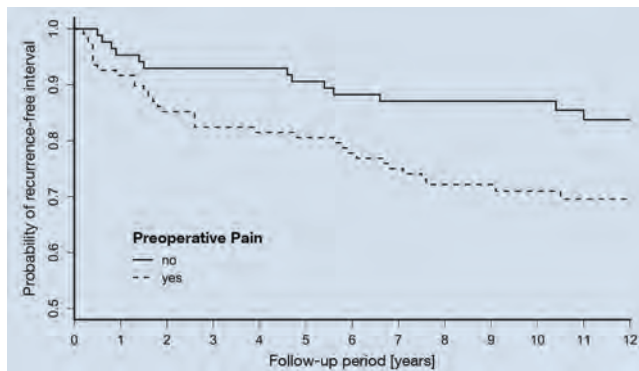
**Table 3.2** Analysis of factors related to the occurrence and recurrence of pain and dysmenorrhea.<sup>32</sup> Key to acronyms: not significant (NS). Body Mass Index (BMI).



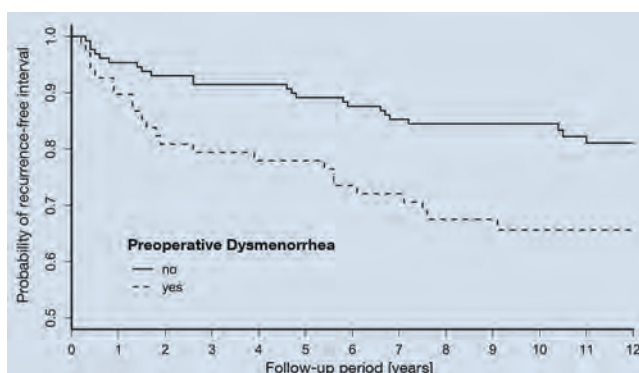
Other risk factors that were not significant, but showed an association with a higher recurrence rate were larger cyst size (> 8 cm: recurrence rate of 33.3% [5 of 15] versus 16.3% [15 of 92] for cyst size 5–8 cm and 16.8% [24 of 143] for cyst size < 5 cm), younger age at surgery (< 25 years: 6.4% [3 of 47] in the recurrence cohort versus 2.8% [8 of 289] in the follow-up cohort), and preoperative cyst rupture (recurrence rate of 28.6% [2 of 7] versus 20.5%).

As for the efficacy of endometrioma surgery, laparoscopy yielded the best results in terms of freedom from symptoms in the postoperative period: 49.0% of the patients were symptom-free after laparoscopic surgery, compared with only 33.3% after laparotomy. Only 43.7% of patients were asymptomatic following conversion from laparoscopy to laparotomy.

Postoperative medical treatment was given in 56.1% of the cases (162 of 289). Additional postoperative hormone therapy (gonadotropin-releasing hormone agonist, oral contraceptive, medroxyprogesterone acetate, or danazol) led to a higher recurrence of endometrioma, with a recurrence-free interval rate of only 70.5% versus 82.6% in patients who did not receive hormonal therapy (log-rank test  $P = 0.050$ ) (Fig. 3.25). The recurrence rates in both groups increased steadily with time from diagnostic surgery. When combined surgical and hormonal treatment was compared with surgical treatment alone, the following differences were found: postoperative pain in 36.4% versus 29.1%, dysmenorrhea in 37.8% versus 26.0%, and dyspareunia in 19.1% versus 18.1%.



**Fig. 3.23** Probability of recurrence-free interval within the follow-up period in patients with and without preoperative **pain**. Courtesy of Maul *et al.* (2014).<sup>32</sup>



**Fig. 3.24** Probability of recurrence-free interval within the follow-up period in patients with and without preoperative **dysmenorrhea**. Courtesy of Maul *et al.* (2014).<sup>32</sup>

One hundred eleven of 289 patients expressed a desire to become pregnant in the postoperative period (38.4%). Combined surgical and hormonal treatment was given to 61 of 111 patients (55.0%), whereas surgery alone was performed in 50 of 111 patients (45.0%). Among these patients, the postoperative spontaneous pregnancy rate was 54.1% (60 of 111). Of the 60 patients who conceived, 46 of 111 (41.4%) had received surgery plus medical treatment, and 14 of 111 (12.6%) had had surgery alone. A statistically significant difference ( $P < 0.001$ ) was noted between combined surgical and hormonal therapy and surgery alone.

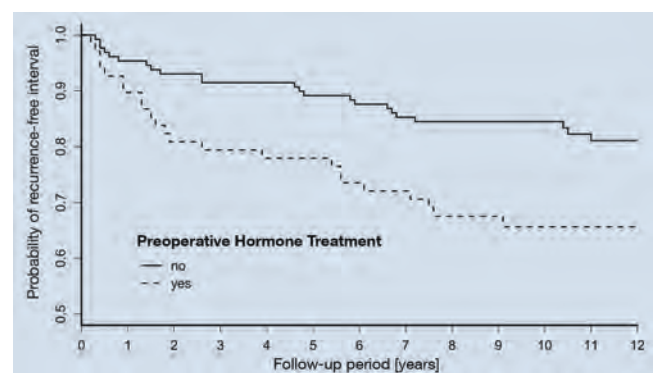
### 3.3.6.3 Discussion

Our retrospective cohort study investigated risk factors, the efficacy of endometrioma surgery comparing laparoscopy versus laparotomy, and the effect of additional medical treatment on the recurrence of endometrioma and on pregnancy rates.

Preoperative risk factors found to have significant predictive value for pain and dysmenorrhea were younger age at surgery, prior laparoscopic surgery for ovarian endometrioma, and nulliparity. Pain complaints appeared to be significantly associated with larger cyst size (> 8 cm), while primary or secondary sterility was associated with a higher rate of dysmenorrhea. As for recurrent symptoms, younger age, nulliparity, and larger cyst diameter significantly influenced the recurrence of dysmenorrhea, while only prior laparoscopic surgery for ovarian endometrioma was found to be a significant risk factor for the recurrence of pain as reported by Bussacca *et al.* and Porpora *et al.*<sup>11,32,43</sup>

In agreement with Vercellini *et al.*, a lower incidence of dysmenorrhea in older patients is attributable to postmenopausal changes.<sup>54</sup> Other studies have suggested that adhesions have causal importance in pain associated with endometriosis, whereas no significant correlation has been found between cyst diameter and pain symptoms.<sup>16,21</sup> Like earlier studies that described pregnancy as a protective factor against pain associated with endometriosis, more recent studies have also identified nulliparity as having predictive value for pain symptoms.<sup>26,43</sup>

Many studies have analyzed the recurrence rate of endometriomas after laparoscopic surgery and found a



**Fig. 3.25** Probability of recurrence-free interval within the follow-up period in patients with and without postoperative **hormone treatment**. Courtesy of Maul *et al.* (2014).<sup>32</sup>

recurrence rate between 11.0% and 30.4% after 2 or more years of observation.<sup>26,54</sup> As recurrence is among the most significant challenges of endometriosis, reoperation is often considered the best treatment option at present, although the extent and duration of benefits from second-line surgery remain unclear.<sup>53</sup> In the present follow-up, a reoperation rate of 68.1% was noted in 32 of 47 patients with recurrent endometrioma who had ovarian endometriomas initially diagnosed at surgery. These observations agree with those of *Cheong et al.* but not with the lower reoperation rates reported by other authors.<sup>1,13,53</sup>

A history of preoperative pain or preoperative dysmenorrhea was shown to be a significant factor associated with higher recurrence rates, which agrees with a study by *Renner et al.*<sup>44</sup> Our study found significantly lower recurrence-free intervals for those preoperative complaints. In the present study larger cyst size, as also reported by *Kikuchi et al.* and *Koga et al.*, younger age at surgery, and preoperative cyst rupture appeared to increase the risk for recurrence of ovarian endometrioma.<sup>23,26</sup>

Laparoscopy yielded the best results regarding the efficacy of endometrioma surgery. Efficacy was assessed in terms of uneventful postoperative course and pain reduction. In fact, because of its good tolerance, low morbidity, and low total cost of treatment, laparoscopy with sampling for histologic analysis has become the gold standard for the evaluation of endometriosis patients with persistent complaints.<sup>35,43</sup>

The impact of postoperative hormone therapy on ovarian endometriosis is not yet fully understood. To determine the effect of additional postoperative medical treatment in the present follow-up, patients on hormonal therapy (56.1%) were compared with patients not receiving hormones (43.9%). Our findings were consistent with previous observations that patients do not significantly benefit from additional postoperative hormone therapy (gonadotropin-releasing hormone agonist, oral contraceptive, medroxyprogesterone acetate, or danazol) in terms of reduced risk of disease and pain recurrence.<sup>8,43,50,52,53</sup> We observed even lower probabilities for a recurrence-free interval based on an average follow-up of 12.9 years in patients receiving hormone therapy versus those who received surgical treatment only. A retrospective study found that previous medical treatment of endometriosis was a significant risk factor ( $P = .009$ ) for higher recurrence.<sup>26</sup> *Yap et al.* found a significant improvement in recurrence rates after postoperative hormone therapy, noting also that there were no recorded beneficial effects on pain and pregnancy rates relative to surgery alone.<sup>56</sup>

Among the 111 patients who wished to conceive, the postoperative spontaneous pregnancy rate was 54.1%, which corresponds to fertility rates reported by *Vercellini et al.* and *Jones and Sutton*.<sup>20,54</sup> As the present study analyzes only the outcomes of total endometrioma excision, we were unable to draw comparisons with other surgical techniques such as fenestration or ablation.<sup>3,18</sup> The present study indicates that additional medical treatment positively impacts the postoperative spontaneous pregnancy rate, which is in line with previous observations.<sup>4,34</sup> This contrasts with

other studies, however, which did not observe a hormonal impact on fertility rates after surgery.<sup>12,29</sup> Further studies are needed to determine the most effective treatment for ovarian endometrioma.

One limitation of this study is that its study model, a retrospective cohort study, does not provide the same level of evidence or validity as a prospective randomized controlled study. The definition of 'recurrence' varies in the literature. Some studies define recurrence as a typical morphologic change depicted in a vaginal sonogram, while others define it as a recurring or worsening subjective perception of pain. Although the general definition of 'recurrent endometriosis' remains to be determined, our definition represents a limitation because it is based on a questionnaire.

Biases in this study include differences in surgeons' experience, the low return rate of questionnaires, and developments in the field of hormonal therapy over the period of data collection and observation. (For example, danazol, despite its interesting immunosuppressive effects, has been superseded by drugs with fewer side effects, such as GnRH analogues and progestin-only pills.)

Among the strengths of the study are the long follow-up period, large sample size, and the fact that all patients underwent surgery at the same hospital.

Our study identifies risk factors for recurrent ovarian endometrioma in our patient population as preoperative pain, preoperative dysmenorrhea, and larger cyst size.

The present study also indicates that patients with ovarian endometriomas who wish to conceive seem to benefit from additional postoperative medical therapy. For patients who do not desire future pregnancy, the need for additional postoperative medical therapy should be carefully assessed based on individual patient preferences.

### 3.3.7 Summary

Endometriosis cysts of the ovary occur in up to 44% of all endometriosis patients. Half of those patients suffer from bilateral endometriomas. Surgical treatments, which usually involve enucleating (stripping) or coagulating the cyst, have become the first-line option because it has been shown that the complete removal of endometriosis is most effective in alleviating symptoms and improving pregnancy rates. Apart from endometriosis-related symptoms, endometriosis cysts may impair fertility. The removal of endometriosis cysts is a controversial issue, however, as other studies have shown that any kind of manipulation may worsen the outcome of fertility treatment by decreasing the ovarian reserve. Translational research has revealed that endometriosis is associated with endometrioid, clear-cell, and low-grade serous ovarian cancer. However, ovarian endometriosis is frequently removed to resolve symptoms related to the disease and to improve the fertility potential of the patient. This chapter provides an introduction to the controversial debate and explores the indications and techniques of surgical treatment.

### 3.3.8 References

- ABBOTT JA, HAWE J, CLAYTON RD, GARRY R. The effects and effectiveness of laparoscopic excision of endometriosis: a prospective study with 2–5 year follow-up. *Hum Reprod* 2003;18(9):1922–7.
- AHMAD G, O'FLYNN H, HINDOCHA A, WATSON A. Barrier agents for adhesion prevention after gynaecological surgery. *Cochrane Database Syst Rev* 2015;4:CD000475. doi:10.1002/14651858.CD000475.pub3.
- ALBORZI S, MOMTAHAN M, PARSANEZHAD ME, DEHBASHI S, ZOLGHADRI J. A prospective, randomized study comparing laparoscopic ovarian cystectomy versus fenestration and coagulation in patients with endometriomas. *Fertil Steril* 2004;82(6):1633–7. doi:10.1016/j.fertnstert.2004.04.067.
- ALKATOUT I, METTLER L, BETETA C, HEDDERICH J, JONAT W, SCHOLLMEYER T et al. Combined surgical and hormone therapy for endometriosis is the most effective treatment: prospective, randomized, controlled trial. *J Minim Invasive Gynecol* 2013;20(4):473–81. doi:10.1016/j.jmig.2013.01.019.
- BARRI PN, COROLEU B, TUR R, BARRI-SOLDEVILA PN, RODRIGUEZ I. Endometriosis-associated infertility: surgery and IVF, a comprehensive therapeutic approach. *Reprod Biomed Online* 2010;21(2):179–85. doi:10.1016/j.rbmo.2010.04.026.
- BENAGLIA L, SOMIGLIANA E, VERCELLINI P, ABBIATI A, RAGNI G, FEDELE L. Endometriotic ovarian cysts negatively affect the rate of spontaneous ovulation. *Hum Reprod* 2009;24(9):2183–6. doi:10.1093/humrep/dep202.
- BENSCHOP L, FARQUHAR C, VAN DER POEL N, HEINEMAN MJ. Interventions for women with endometrioma prior to assisted reproductive technology. *Cochrane Database Syst Rev* 2010(11):CD008571. doi:10.1002/14651858.CD008571.pub2.
- BIANCHI S, BUSACCA M, AGNOLI B, CANDIANI M, CALIA C, VIGNALI M. Effects of 3 month therapy with danazol after laparoscopic surgery for stage III/IV endometriosis: a randomized study. *Hum Reprod* 1999;14(5):1335–7.
- BROSENS IA, PUTTEMANS PJ, DEPREST J. The endoscopic localization of endometrial implants in the ovarian chocolate cyst. *Fertil Steril* 1994;61(6):1034–8.
- BROWN J, FARQUHAR C. Endometriosis: an overview of Cochrane Reviews. *Cochrane Database Syst Rev* 2014;3:CD009590. doi:10.1002/14651858.CD009590.pub2.
- BUSACCA M, MARANA R, CARUANA P, CANDIANI M, MUZIL L, CALIA C et al. Recurrence of ovarian endometrioma after laparoscopic excision. *Am J Obstet Gynecol* 1999;180(3 Pt 1):519–23.
- BUSACCA M, SOMIGLIANA E, BIANCHI S, MARINIS S DE, CALIA C, CANDIANI M et al. Post-operative GnRH analogue treatment after conservative surgery for symptomatic endometriosis stage III–IV: a randomized controlled trial. *Hum Reprod* 2001;16(11):2399–402.
- CHEONG Y, TAY P, LUK F, GAN HC, LI TC, COOKE I. Laparoscopic surgery for endometriosis: How often do we need to re-operate? *J Obstet Gynaecol* 2008;28(1):82–5. doi:10.1080/01443610701811761.
- DONNEZ J, NISOLLE M, GILLET N, SMETS M, BASSIL S, CASANAS-ROUX F. Large ovarian endometriomas. *Hum Reprod* 1996;11(3):641–6.
- DUNSELMAN GA, VERMEULEN N, BECKER C, CALHAZ-JORGE C, D'HOOGE T, BIE B DE et al. ESHRE guideline: management of women with endometriosis. *Hum Reprod* 2014;29(3):400–12. doi:10.1093/humrep/det457.
- FAUCONNIER A, CHAPRON C, DUBUISSON JB, VIEIRA M, DOUSSET B, BREART G. Relation between pain symptoms and the anatomic location of deep infiltrating endometriosis. *Fertil Steril* 2002;78(4):719–26.
- FORTE A, CIPOLLARO M, GALDERISI U. Genetic, epigenetic and stem cell alterations in endometriosis: new insights and potential therapeutic perspectives. *Clin Sci (Lond)* 2014;126(2):123–38. doi:10.1042/CS20130099.
- HART RJ, HICKEY M, MAOURIS P, BUCKETT W. Excisional surgery versus ablative surgery for ovarian endometriomata. *Cochrane Database Syst Rev* 2008(2):CD004992. doi:10.1002/14651858.CD004992.pub3.
- HUGHESDON PE. The structure of endometrial cysts of the ovary. *J Obstet Gynaecol Br Emp* 1957;64(4):481–7.
- JONES KD, SUTTON CJ. Pregnancy rates following ablative laparoscopic surgery for endometriomas. *Hum Reprod* 2002;17(3):782–5.
- KAYA H, SEZIK M, OZKAYA O, SAHINER H, OZBASAR D. Does the diameter of an endometrioma predict the extent of pelvic adhesions associated with endometriosis? *J Reprod Med* 2005;50(3):198–202.
- KEYHAN S, HUGHES C, PRICE T, MUASHER S. An Update on Surgical versus Expectant Management of Ovarian Endometriomas in Infertile Women. *Biomed Res Int* 2015;2015:204792. doi:10.1155/2015/204792.
- KIKUCHI I, TAKEUCHI H, KITADE M, SHIMANUKI H, KUMAKIRI J, KINOSHITA K. Recurrence rate of endometriomas following a laparoscopic cystectomy. *Acta Obstet Gynecol Scand* 2006;85(9):1120–4. doi:10.1080/00016340600627154.
- KIM ML, KIM JM, SEONG SJ, LEE SY, HAN M, CHO YJ. Recurrence of ovarian endometrioma after second-line, conservative, laparoscopic cyst enucleation. *Am J Obstet Gynecol* 2014;210(3):216.e1–6. doi:10.1016/j.ajog.2013.11.007.
- KITAJIMA M, DOLMANS MM, DONNEZ O, MASUZAKI H, SOARES M, DONNEZ J. Enhanced follicular recruitment and atresia in cortex derived from ovaries with endometriomas. *Fertil Steril* 2014;101(4):1031–7. doi:10.1016/j.fertnstert.2013.12.049.
- KOGA K, TAKEMURA Y, OSUGA Y, YOSHINO O, HIROTA Y, HIRATA T et al. Recurrence of ovarian endometrioma after laparoscopic excision. *Hum Reprod* 2006;21(8):2171–4. doi:10.1093/humrep/del125.
- KURMAN RJ (ED.). WHO classification of tumours of female reproductive organs. 4th ed. Lyon: Internat. Agency for Research on Cancer; 2014. (ISBN No. 978-92-832-2435-8).
- LA BRINTON, SAKODA LC, SHERMAN ME, FREDERIKSEN K, KJAER SK, GRAUBARD BI et al. Relationship of benign gynecologic diseases to subsequent risk of ovarian and uterine tumors. *Cancer Epidemiol Biomarkers Prev* 2005;14(12):2929–35. doi:10.1158/1055-9965.EPI-05-0394.
- LOVERRO G, CARRIERO C, ROSSI AC, PUTIGNANO G, NICOLARDI V, SELVAGGI L. A randomized study comparing triptorelin or expectant management following conservative laparoscopic surgery for symptomatic stage III–IV endometriosis. *Eur J Obstet Gynecol Reprod Biol* 2008;136(2):194–8. doi:10.1016/j.ejogrb.2006.10.034.
- MANESCHI F, MARASA L, INCANDELA S, MAZZARESE M, ZUPI E. Ovarian cortex surrounding benign neoplasms: a histologic study. *Am J Obstet Gynecol* 1993;169(2 Pt 1):388–93.



31. MATSUZAKI S, HOULLE C, DARCHA C, POULY JL, MAGE G, CANIS M. Analysis of risk factors for the removal of normal ovarian tissue during laparoscopic cystectomy for ovarian endometriosis. *Hum Reprod* 2009;24(6):1402–6. doi:10.1093/humrep/dep043.
32. MAUL LV, MORRISON JE, SCHOLLMAYER T, ALKATOUT I, METTLER L. Surgical therapy of ovarian endometrioma: recurrence and pregnancy rates. *JSLs* 2014;18(3). doi:10.4293/JSLs.2014.00223.
33. MEINHOLD-HEERLEIN I, FOTOPOULOU C, HARTER P, KURZEDER C, MUSTEA A, WIMBERGER P et al. Statement by the Kommission Ovar of the AGO: The New FIGO and WHO Classifications of Ovarian, Fallopian Tube and Primary Peritoneal Cancer. *Geburtshilfe Frauenheilkd* 2015;75(10):1021–7. doi:10.1055/s-0035-1558079.
34. METTLER L. Pathogenesis, diagnosis and treatment of genital endometriosis. *Acta Obstet Gynecol Scand Suppl* 1989;150:31–7.
35. METTLER L, SCHOLLMAYER T, LEHMANN-WILLENBROCK E, SCHUPPLER U, SCHMUTZLER A, SHUKLA D et al. Accuracy of laparoscopic diagnosis of endometriosis. *JSLs* 2003;7(1):15–8.
36. MUZII L, ACHILLI C, BERGAMINI V, CANDIANI M, GARAVAGLIA E, LAZZERI L et al. Comparison between the stripping technique and the combined excisional/ablative technique for the treatment of bilateral ovarian endometriomas: a multicentre RCT. *Hum Reprod* 2016;31(2):339–44. doi:10.1093/humrep/dev313.
37. NEZHAT F, NEZHAT C, ALLAN CJ, METZGER DA, SEARS DL. Clinical and histologic classification of endometriomas. Implications for a mechanism of pathogenesis. *J Reprod Med* 1992;37(9):771–6.
38. NISOLLE M, DONNEZ J. Peritoneal endometriosis, ovarian endometriosis, and adenomyotic nodules of the rectovaginal septum are three different entities. *Fertil Steril* 1997;68(4):585–96.
39. PARK H, KIM CH, KIM EY, MOON JW, KIM SH, CHAE HD et al. Effect of second-line surgery on in vitro fertilization outcome in infertile women with ovarian endometrioma recurrence after primary conservative surgery for moderate to severe endometriosis. *Obstet Gynecol Sci* 2015;58(6):481–6. doi:10.5468/ogs.2015.58.6.481.
40. PAVONE ME, LYTTLE BM. Endometriosis and ovarian cancer: links, risks, and challenges faced. *Int J Womens Health* 2015;7:663–72. doi:10.2147/IJWH.S66824.
41. PEARCE CL, TEMPLEMAN C, ROSSING MA, LEE A, AM NEAR, WEBB PM et al. Association between endometriosis and risk of histological subtypes of ovarian cancer: a pooled analysis of case-control studies. *Lancet Oncol* 2012;13(4):385–94. doi:10.1016/S1470-2045(11)70404-1.
42. PERLMAN S, KJER JJ. Ovarian damage due to cyst removal: a comparison of endometriomas and dermoid cysts. *Acta Obstet Gynecol Scand* 2016;95(3):285–90. doi:10.1111/aogs.12841.
43. PORPORA MG, PALLANTE D, FERRO A, CRISAFI B, BELLATI F, BENEDETTI PP. Pain and ovarian endometrioma recurrence after laparoscopic treatment of endometriosis: a long-term prospective study. *Fertil Steril* 2010;93(3):716–21. doi:10.1016/j.fertnstert.2008.10.018.
44. RENNER SP, RIX S, BOOSZ A, LERMANN JH, STRISSEL PL, THIEL FC et al. Preoperative pain and recurrence risk in patients with peritoneal endometriosis. *Gynecol Endocrinol* 2010;26(3):230–5. doi:10.1080/09513590903159623.
45. ROSSING MA, CUSHING-HAUGEN KL, WICKLUND KG, DOHERTY JA, WEISS NS. Risk of epithelial ovarian cancer in relation to benign ovarian conditions and ovarian surgery. *Cancer Causes Control* 2008;19(10):1357–64. doi:10.1007/s10552-008-9207-9.
46. SAINZ DE LA CUESTA R, EICHHORN JH, RICE LW, FULLER AF JR, NIKRUI N, GOFF BA. Histologic transformation of benign endometriosis to early epithelial ovarian cancer. *Gynecol Oncol* 1996;60(2):238–44.
47. SANCHEZ AM, PAPALES E, CORTI L, SANTAMBROGIO P, LEVI S, VIGANO P et al. Iron availability is increased in individual human ovarian follicles in close proximity to an endometrioma compared with distal ones. *Hum Reprod* 2014;29(3):577–83. doi:10.1093/humrep/det466.
48. SANCHEZ AM, VIGANO P, SOMIGLIANA E, PANINA-BORDIGNON P, VERCELLINI P, CANDIANI M. The distinguishing cellular and molecular features of the endometriotic ovarian cyst: from pathophysiology to the potential endometrioma-mediated damage to the ovary. *Hum Reprod Update* 2014;20(2):217–30. doi:10.1093/humupd/dmt053.
49. SCHMIDT D, ULRICH U. Endometriosis-related ovarian tumors. *Pathologe* 2014;35(4):348–54. doi:10.1007/s00292-014-1949-4.
50. SESTI F, CAPOZZOLO T, PIETROPOLLI A, MARZIALI M, BOLLEA, PICCIONE E. Recurrence rate of endometrioma after laparoscopic cystectomy: a comparative randomized trial between post-operative hormonal suppression treatment or dietary therapy vs. placebo. *Eur J Obstet Gynecol Reprod Biol* 2009;147(1):72–7. doi:10.1016/j.ejogrb.2009.07.003.
51. SEYHAN A, ATA B, UNCU G. The Impact of Endometriosis and Its Treatment on Ovarian Reserve. *Semin Reprod Med* 2015;33(6):422–8. doi:10.1055/s-0035-1567820.
52. TSAI YL, HWANG JL, LOO TC, CHENG WC, CHUANG J, SEOW KM. Short-term postoperative GnRH analogue or danazol treatment after conservative surgery for stage III or IV endometriosis before ovarian stimulation: a prospective, randomized study. *J Reprod Med* 2004;49(12):955–9.
53. VERCELLINI P, BARBARA G, ABBIATI A, SOMIGLIANA E, VIGANO P, FEDELE L. Repetitive surgery for recurrent symptomatic endometriosis: what to do? *Eur J Obstet Gynecol Reprod Biol* 2009;146(1):15–21. doi:10.1016/j.ejogrb.2009.05.007.
54. VERCELLINI P, FEDELE L, AIMI G, GIORGI O DE, CONSONNI D, CROSIGNANI PG. Reproductive performance, pain recurrence and disease relapse after conservative surgical treatment for endometriosis: the predictive value of the current classification system. *Hum Reprod* 2006;21(10):2679–85. doi:10.1093/humrep/del230.
55. VERCELLINI P, VIGANO P, SOMIGLIANA E, FEDELE L. Endometriosis: pathogenesis and treatment. *Nat Rev Endocrinol* 2014;10(5):261–75. doi:10.1038/nrendo.2013.255.
56. YAP C, FURNESS S, FARQUHAR C. Pre and post operative medical therapy for endometriosis surgery. *Cochrane Database Syst Rev* 2004(3):CD003678. doi:10.1002/14651858.CD003678.pub2.

## 3.4

## Deep Infiltrating Endometriosis (DIE)

Ingo von Leffern<sup>a</sup>

## 3.4.1 Introduction

When speaking about *deep infiltrating endometriosis* (DIE) this means that more than one tissue has been infiltrated by disease, e.g., peritoneum and deeper retroperitoneal structures such as the muscularis or mucosa of the bowel, fatty tissue of the retroperitoneum, umbilicus, nerves, ureter, bladder, sacrouterine ligament, rectovaginal space and vagina, diaphragm or pericardium.

Deep infiltrating endometriosis of the peritoneum is defined as endometriosis penetrating more than 5 mm beneath the peritoneal surface.<sup>22</sup>

The decision-making as to the approach and modality of surgical treatment, is subject to the location of endometriotic lesions.

Respect the properties of different tissues!

Every anatomical space has its own problems and its own advantages and each organ has that too!

In this subsection, the author explains and illustrates how to deal with the various tissues, spaces and organs.

## 3.4.1.1 Basic Considerations

Considering that surgical treatment of DIE can pose some technical challenges and can be fraught with a multitude of potential complications,<sup>21,39</sup> the first question to be addressed is:

Why do we opt for a surgical approach and what is the goal to be achieved?

The criteria to be applied when defining the major therapeutic objective, are based on quality of life, severity, duration and frequency of symptoms, the patient's individual needs and the anticipated risk of severe complications.

Quality of life, among others, should include sexual function and its level of satisfaction.

In a comparative study conducted by *U. van den Broeck et al.*<sup>39</sup> it was shown, that at 6 months after surgery, the bowel resection group versus the no-bowel-resection group was found to have lower mean levels of the Beck Depression Inventory (BDI) (P, 0.05), a lower incidence of 'pain during sexual intercourse' and 'orgasm problems' (P, 0.05), and a lower proportion of patients with severe orgasm problems (P, 0.05), measured with the *Short Sexual Functioning Scale* (SSFS).

These data have demonstrated that radical but fertility-sparing surgery for the treatment of endometriosis – with or without bowel resection – results in comparable and good psychological outcomes concerning depression levels, relationship, satisfaction and sexual function.

A good quality of life also means to be free from pain. Radical resection of endometriosis can be an effective treatment for pelvic pain.<sup>14</sup>

Nevertheless, sometimes less is more, or in other words, less is even better!<sup>41</sup>

There are two options available for the surgical treatment of bowel or bladder endometriosis: a conservative approach (nodule excision with bowel or bladder shaving and preservation of the organ(s) involved) and a radical approach (segmental bowel resection or partial cystectomy).<sup>40</sup>

It is well-known that the surgical treatment options proposed and discussed in the current literature are subject to constant change. More aggressive approaches have been abandoned in favor of less invasive tissue-sparing surgical procedures. In recent years, the so-called shaving technique has increasingly gained in acceptance and is now frequently used in those cases where resection was proposed as first-line option for treating endometriosis involving the bowel and/or bladder. It has now become more common for surgeons to even consider medical treatment as an alternative option suited to achieve an effective resolution of the symptoms associated with the disease.<sup>40</sup>

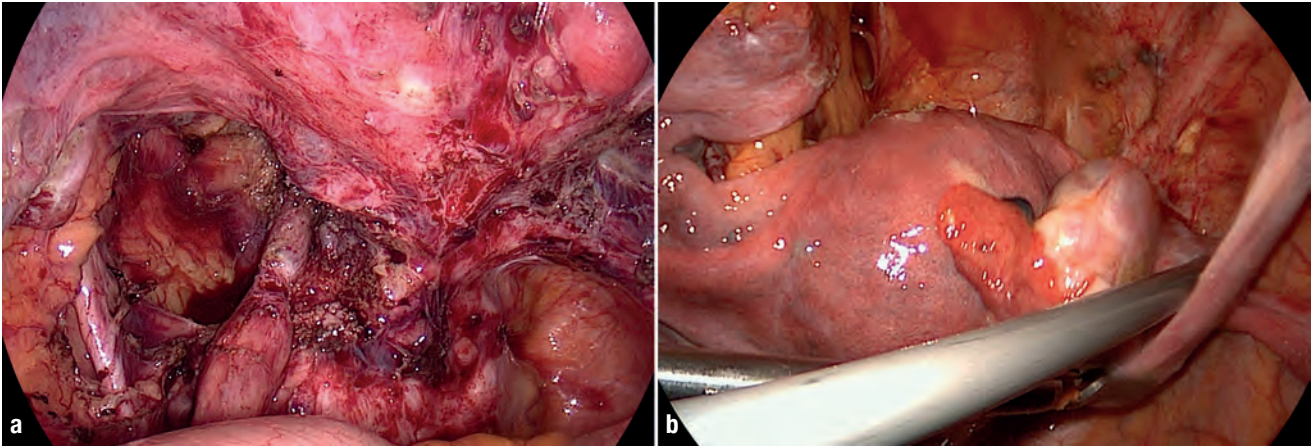
Endometriosis, especially in its more severe form, needs to be treated by highly skilled surgeons capable of coping with the challenges of difficult procedures in an accurate manner. Surgery must be performed by surgeons who are dedicated to endometriosis. It is mandatory, that complete treatment be achieved while respecting anatomical integrity and reducing the risk of iatrogenic fertility impairment.

Unlike most other operative procedures, the surgical treatment of DIE should be based on a collaborative multidisciplinary approach. In this way, patients are offered the optimal treatment that should be provided by a team of highly skilled experts.

<sup>a</sup> MD, MIC III; Director of Albertinen Women's Clinics; Head of Department of Gynecology and Obstetrics, Albertinen Hospital, Hamburg, Germany

**Corresponding author:**

Dr. med. **Ingo von Leffern**, MIC III  
Leitung Brustzentrum, Direktor der Albertinen-Frauenkliniken  
Chefarzt Klinik für Gynäkologie und Geburtshilfe,  
Albertinen-Krankenhaus  
Süntelstrasse 11a  
22457 Hamburg, Germany  
E-mail: Ingo.vonLeffern@albertinen.de



**Fig. 3.26a,b** Situs after primary surgery (a). Situs at second-look surgery (b).

In patients who wish to have children, a well-adapted treatment strategy should be chosen. In order to preserve integrity of the reproductive organs, in these cases, surgery has to be accomplished in a more conservative and extremely cautious way, that is based on a staged approach in order to prevent postoperative adhesion formation.

In these special cases, we perform a second-look laparoscopy 6 to 8 weeks after primary surgery and carry out adhesiolysis, chromopertubation and prophylaxis for prevention of recurrent adhesions.

Fig. 3.26a, b show the operative situs after primary and secondary surgery in a woman who became pregnant within about 6 months after second-look surgery.

It must be kept in mind that DIE is a benign disease! There is no scientific evidence that 100% surgical removal of disease should be considered the major goal to be achieved in any case.

Is there a need for complete resection?

Moreover, it is virtually impossible to identify and remove every single endometriosis cell.

In a large number of cases lymph nodes are found to harbor endometriotic lesions.<sup>26</sup> To the best of my knowledge these lesions do not cause any disorders or pain which is why the author advises against attempting a systematic removal.

It is still unclear whether nodules of deep infiltrating endometriosis that do not cause pain should in fact be excised. Another clinical question yet to be answered is whether remnants of endometriosis are a possible cause of relapse.

Conversely, however, it is indisputable that almost complete removal should be attempted to the extent feasible if the patient presents with symptomatic endometriosis. Infertility can be one of these symptoms.

Lacking clear data, the author recommends eradication of visible endometriotic lesions, however care should be taken in the area of the intestine. The rate of severe complications has led us to exercise due restraint at this site during radical surgery. Occasionally, the need may arise that endometriosis lesions are shaved off the bowel leaving behind a layer of fibrosis that encloses the nodules.

Taking into account that evidence of recurrent disease is most frequently found in the posterior fornix of the vagina<sup>23</sup> and considering that the vaginal cuff commonly heals well, it is important to ensure a complete resection in this region.

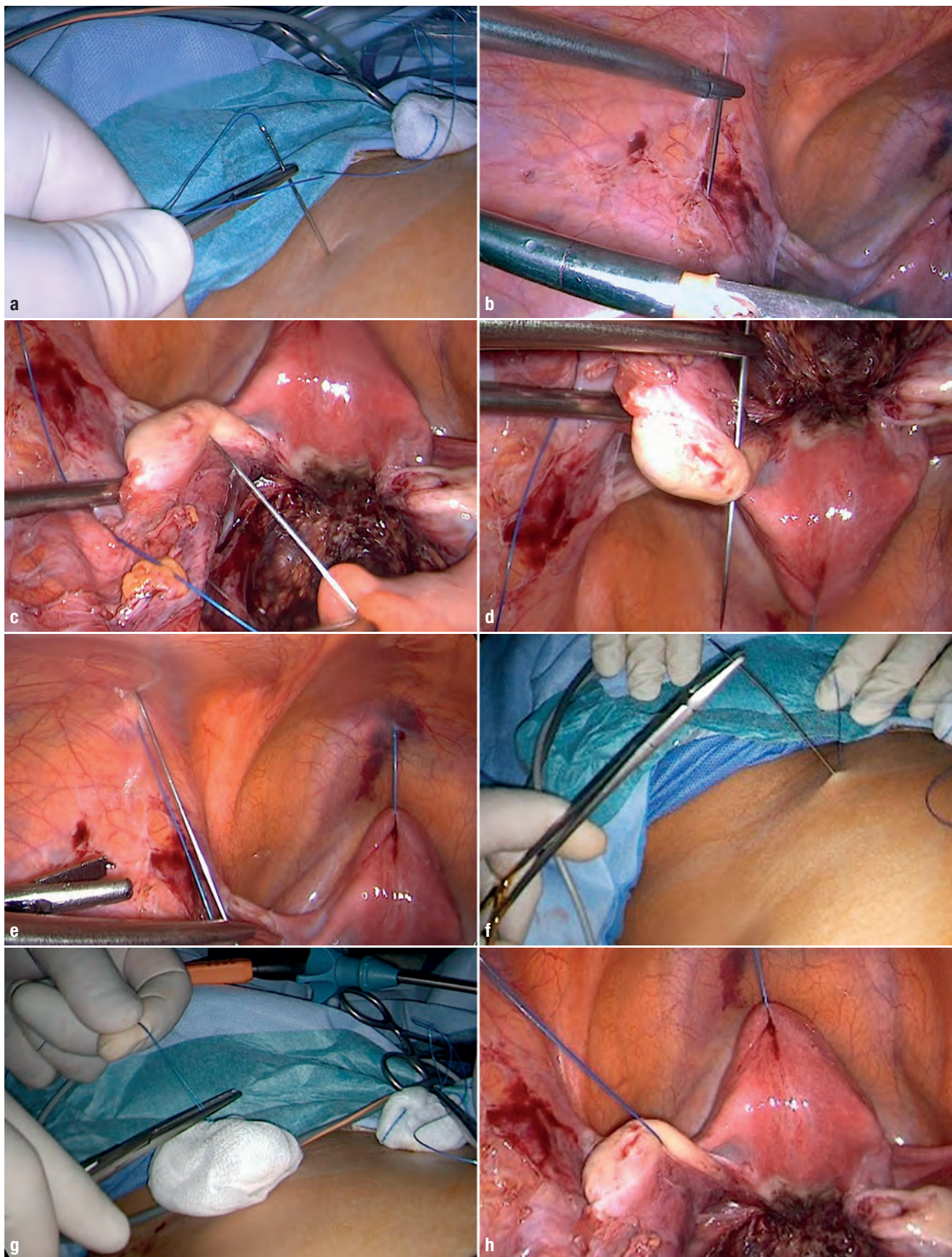
### 3.4.2 Surgical Approaches and Instruments

A minimally invasive, laparoscopic approach should be selected, whenever possible

In the hands of experts, use of the laparoscopic route is less invasive and enables a targeted and accurate surgical treatment of deep infiltrating endometriosis.

Do not hesitate to use an open access, if laparoscopy is not feasible or if the intraoperative situation suggests that conversion to laparotomy seems to be a better option.





**Fig. 3.27a–h** The needle is passed through the abdominal wall (a). The needle is grasped from inside the abdomen (b). The needle is placed at the ovary (c). The needle is passed through the ovary (d). The needle is passed through the abdomen from inside (e). Pulling out the thread (f). Both ends of the suture are held by a Kocher clamp (g). Final aspect following completion of suspension of the uterus and left ovary (h).

### 3.4.2.1 Uteropexy and Ovariopexy

In order to facilitate laparoscopic access to rectum, pouch of Douglas or to the rectovaginal space, an uterine manipulator (e.g. Valtchev adapter) can be of great help.

From the author's perspective, the use of a temporary ventral uteropexy<sup>15</sup> with a thick, monofilament suture has also proven helpful. The thread is passed through the abdominal wall with a long, straight needle, then guided through the uterine fundus and again withdrawn through the abdominal wall, where the threads are held with a Kocher clamp.

The temporary uteropexy allows a very effective elevation of the uterus without the need for fixing cervix or vagina. This option offers the advantage that no further assistance is needed as is the case with a uterine manipulator.

The same method can also be used for temporary suspension of ovaries for keeping them out of the surgical site. This measure is used by some surgeons for adhesion prevention and involves that the stitches are left in situ for 48–72 hours after surgery. So far, there is no authoritative evidence supporting the efficiency of this method in preventing the formation of adhesions. Derived from anecdotal experience of a few surgeons only non-representative samples of cases have been reported so far. Fig. 3.27a–h shows the technique of ventro-lateral ovariopexy.

### 3.4.2.2 Instruments

The vast number of different laparoscopic instruments for the surgical treatment of deep infiltrating endometriosis makes it impossible to mention all of them in this chapter.

In the following, the author focuses on the monopolar hook / monopolar needle electrode (Fig. 3.28), an instrument, that has always been the subject of controversy among physicians. It is loved by some surgeons and totally rejected by others.

The advantage of this instrument lies in the fact, that it allows the surgeon to concurrently cut and coagulate, to cut without coagulation – provided the energy device is adjusted to pure cutting mode, and to cut and coagulate very precisely and millimeter by millimeter – provided an interrupted cutting current is used with very short intervals.

In high-frequency electrosurgery, a cutting current is used to cut through tissue almost without necrosis and without inducing collateral coagulation, offering similar features as those made advantage of in laser surgery.

Another advantage of the monopolar hook/needle is that you can cut without exerting pressure on the tissue. In order to cut and coagulate, the electrode only has to be in near contact with the target tissue. When using “spray coagulation mode”, no contact between the instrument tip and the tissue to be treated, is needed at all.

The mass of the electrode is so minimal, that it cools immediately in fractions of a second. Iatrogenic burns to adjacent tissue, upon inadvertent contact after shut-down of the current, do not occur.

However, a few disadvantages of monopolar electrodes should also be mentioned. First of all, monopolar current may spread well beyond the target site into tissue. The direction, in which it spreads, cannot be controlled by the surgeon and is subject to the varying electric conductivity of different tissues.

The use of monopolar current also carries the risk of stimulating distant nerves which may result in spontaneous muscle jerks or twitches of the body. This is particularly risky while operating close to large blood vessels.

**Caveat:** Monopolar current must not be used in close proximity to any nerves since this can result in iatrogenic damage!

Provided these rules are adhered to, the instrument is ideally suited for both atraumatic and straightforward dissection, creating a cleavage plane that conforms with the targeted physiologic layer of tissue. Furthermore, it is very inexpensive.

### 3.4.3 DIE and Fertility

Endometriosis affects about 10 to 15% of women of child-bearing age and 20% of these patients even suffer from DIE.

Subfertility is a well-known and common problem in patients with endometriosis. Unfortunately, the underlying etiopathological mechanisms of the disease are not yet completely understood.

In endometriosis patients, the management of infertility encompasses surgery, medical treatment and the use of assisted reproduction techniques. In terms of infertility, the use of minimally invasive techniques have been shown to provide better results than those yielded by open surgery approaches.

Based on the current literature, the use of laparoscopic resection techniques has demonstrated a benefit in the treatment of both minimal and moderate endometriosis.

In cases of severe endometriosis, the data currently available are inadequate. Considering that an extensive surgical intervention is fraught with significant risks, it would not be reasonable to undertake this option in cases where the major objective of treatment is geared toward improving the patient's fertility status.<sup>4</sup>



**Fig. 3.28** Monopolar hook with a ceramic tip.



On the other hand, a literature review by *Cohen et al.*<sup>10</sup> demonstrated that surgery alone offers a high spontaneous pregnancy rate in cases of DIE without bowel involvement.

For those women with bowel involvement, the low spontaneous and relatively high overall pregnancy rate suggests that a benefit can be achieved by a combination of surgery and medically-assisted reproduction (MAR).

*Stepniewska et al.*<sup>38</sup> observed three groups of patients for about 4 years after surgery and analyzed the monthly fecundity rate (MFR) of each group.

Those patients who underwent surgery for endometriosis with colorectal segmental resection showed a MFR of 2.3%. In those patients with evidence of bowel endometriosis subjected to endometriosis removal, but without bowel resection, a MFR of only 0.84% was revealed. Finally, in the group of patients with DIE, but without any bowel involvement, the MFR was 3.95%. The differences were significant.

Concordant with the results and conclusions of *Cohen et al.*<sup>10</sup>, it was established, that in order to improve fertility, the affected bowel should better be removed. In a nutshell, DIE of the bowel seems to be associated with a decrease in fertility, which can be partly compensated by adequate surgical treatment.

#### 3.4.4 DIE of Sacrouterine Ligament

The sacrouterine ligament is among the anatomical regions most frequently involved by DIE. From this location, endometriosis spreads into the broad ligament, to rectovaginal space, to the pararectal space and to the area surrounding the ureter.

Radical resection of the sacrouterine ligament is complicated by close proximity of the ureter, bowel and the nerves of the pelvic plexus.

Integrity of these nerves, in particular, has to be preserved. Iatrogenic injury may result in urinary dysfunction and cannot be repaired.<sup>8</sup> Atony of the bladder and problems with defecation may result from radical resection of both ligaments.

Refractory neurogenic bladder atony may entail the need for permanent self-catheterization.

This serious complication can severely impair the patient's quality of life to a degree exceeding that of endometriosis itself.

Bladder dysfunction and neurogenic atony may occur even years after primary surgery.<sup>34</sup> In the immediate postoperative phase, these symptoms may sometimes remain occult leading to delayed notification of the doctor in charge of follow-up care.

Integrity of the tissue surrounding the ureter has to be preserved meticulously to prevent injury to the network of nerves forming the pelvic plexus! If possible, leave behind part of the sacrouterine ligament and some fatty tissue beside the rectum.

If both sacrouterine ligaments are affected by disease, it is sometimes prudent to leave some endometriotic lesions behind and refrain from radical resection on one side!<sup>36</sup>

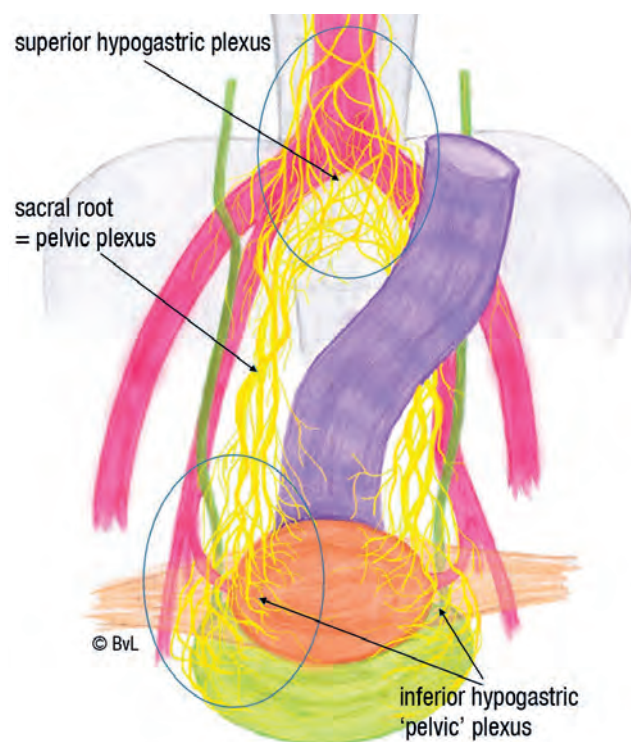
The vesical plexus is part of the sacral plexus and composed of very delicate nerves that can be difficult to locate. Sometimes, it may be necessary to first trace the larger portions of the pelvic plexus, the sacral roots (Figs. 3.29, 3.30a), and then follow them caudally to spot the thin branches of the vesical plexus. In order to identify the sacral roots, dissection is initiated medial to the ureter and lateral to the sacrouterine ligament (Fig. 3.30b).

In the broad ligament, it should be possible to visualize small nerve fibers (Fig. 3.30c) in the pars nervosa inferior to the pars vascularis, which is superior to the deep uterine vein.

Accordingly, the deep uterine vein constitutes the boundary between pars vascularis and pars nervosa of the broad uterine ligament.

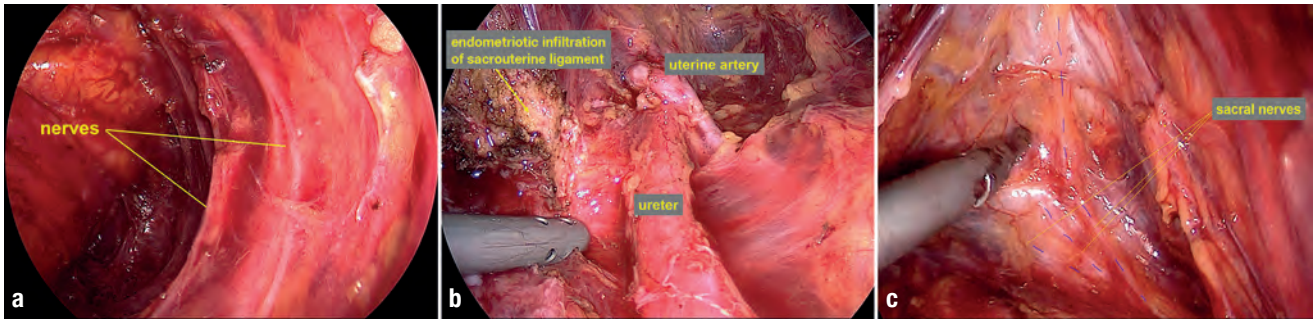
#### 3.4.5 DIE Involving Nerves

Occasionally, nerves are affected by endometriosis which may lead to muscular dysfunction if motor nerves are involved. Given the involvement of sensory nerves, pain symptoms or sensory discomfort may result from irritation of those nerves.



**Fig. 3.29** Schematic representation of the pelvic plexus and hypogastric plexus.





**Fig. 3.30a–c** Sacral roots (a). Anatomical landmarks (b). Sacral nerves of inferior hypogastric plexus (c).

Cyclical sciatica from intraneural endometriosis of sciatic nerve has been reported<sup>9</sup> as well as cases of DIE affecting a multitude of various other nerves.

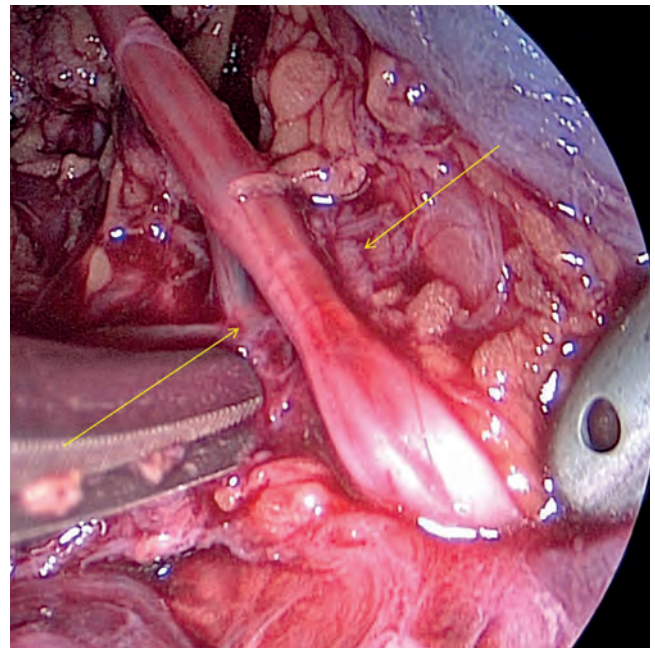
The literature provides some anecdotal evidence of perineural spread of endometriosis to the lumbosacral plexus along the autonomic nerves and then distally to the sciatic nerve and proximally to the spinal nerves.

Endometriosis may also affect femoral nerves<sup>3</sup> as well as the nerves of the pelvic side wall such as the obturator nerve (Fig. 3.31).

Shown on (Fig. 3.31) is the obturator nerve after dissection of DIE reaching from the peritoneum to the iliac bone. Intrinsic endometriosis of the ureter was noticeable as well as infiltration of the periosteal layer of the iliac bone, but without affecting the nerve.

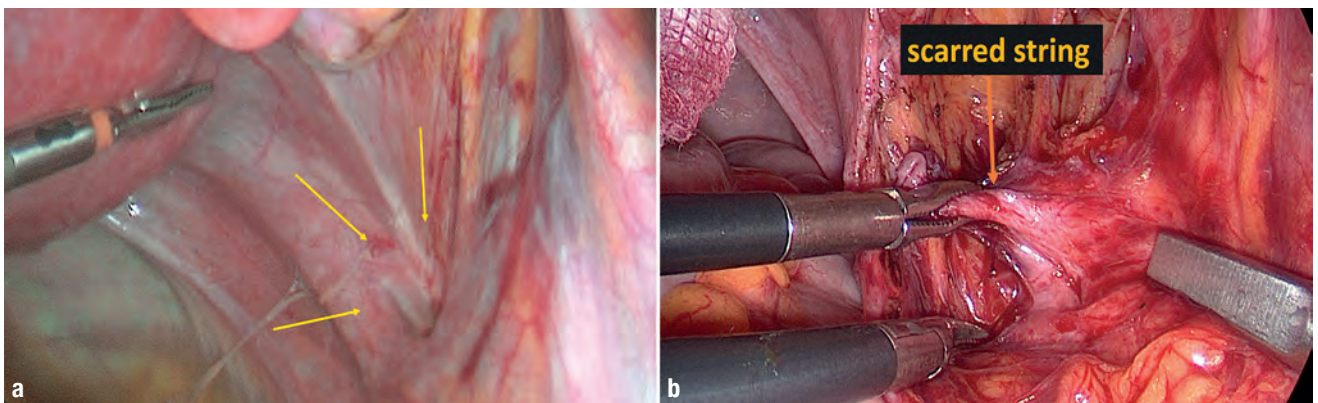
As shown in (Fig. 3.31), endometriosis-associated compression of the obturator nerve was treated by neurolysis carried out by creating a cleavage plane that conforms with the targeted physiologic tissue layers.

Deep retroperitoneal nerves can be involved without any prominent signs of DIE visible on the peritoneum. As shown in Fig. 3.32a, there is only a small fibrous retraction noticeable on the peritoneum of the ovarian fossa. The patient suffered from severe cyclic ischialgia. Based on MRI scans, endometriotic involvement was demonstrated in the area surrounding the superior gluteal nerve and the sciatic nerve. Once the



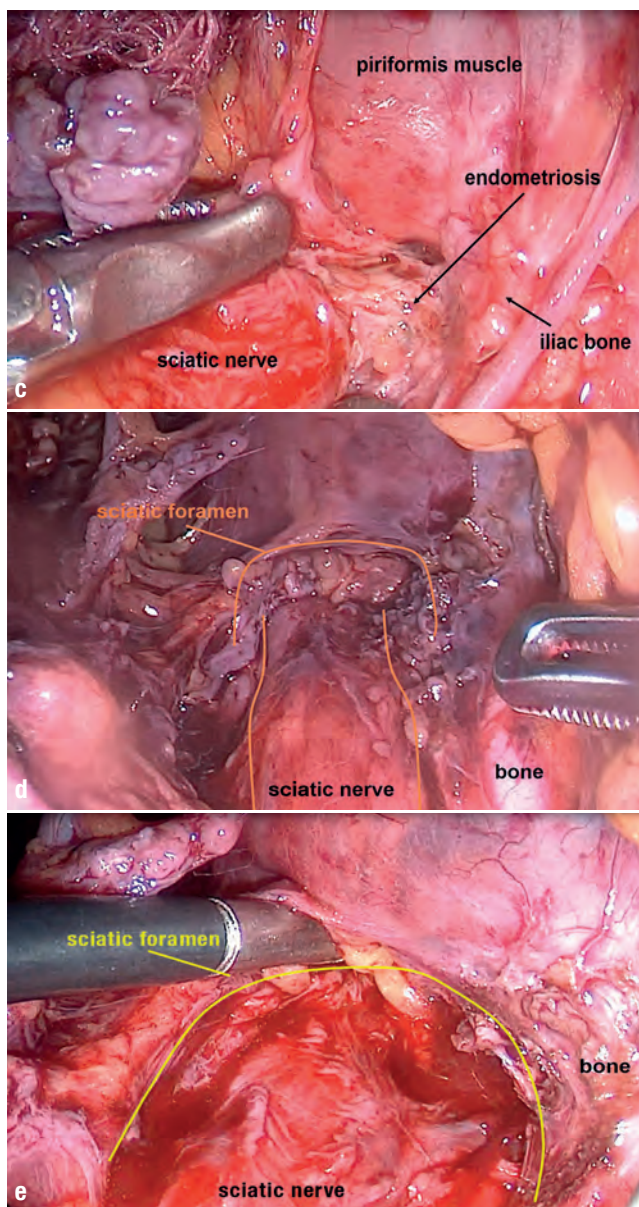
**Fig. 3.31** Right obturator nerve with signs of compression.

peritoneum was opened, a scarred string-shaped lesion (Fig. 3.32b) was revealed to adhere to the obturator foramen and the iliac bone, especially in the area of the greater sciatic notch. The obturator nerve was not involved.



**Fig. 3.32a,b** At the site of endometriotic lesions (pointers), the peritoneal wall exhibits signs of retraction (a). Note the presence of a scarred, string-shaped endometriotic lesion (b).





**Fig. 3.32c–e** Endometriosis compressing the sciatic nerve (c). Sciatic foramen completely infiltrated by endometriosis (d). View of the sciatic foramen freed from disease (e).

As shown in Fig. 3.32c, the sciatic nerve was encased and constricted by DIE. Once the nerve was partially skeletonized by excision of endometriotic lesions (Fig. 3.32d), marked entrapment of the sciatic nerve became apparent. Upon removal of the endometriotic lesions with cold scissors, the sciatic foramen was wide open and decompression of the nerve was confirmed (Fig. 3.32e). At follow-up, the patient reported to be free of cyclic sciatica symptoms.

While performing neurolysis, never use electro-surgery (neither monopolar nor bipolar) or any kind of heat-emitting

modality (e.g. ultrasound scissors). Dissection should either be performed bluntly or with cold scissors. Occasionally, the use of aqua-jet dissection is feasible.

### 3.4.6 DIE of the Ureter

Endometriotic involvement of the ureter is often associated with DIE of the peritoneum. The peritoneal portion in front of the ureter is a predilection area for endometriosis of the pelvic sidewall.

Anecdotal evidence suggests a predilection of endometriosis to develop on the ureter!

Endometriosis of the ureter may simply be superficial, but may also be more invasive in nature and totally enclose the ureter. As disease progresses, endometriosis can invade deeply into the ureter. This condition is described as ‘intrinsic ureteral endometriosis’.

Secondary to an ‘entrapped’ ureter or if the latter is affected by intrinsic disease, this may result in hydronephrosis, a sequela that constitutes an absolute indication for immediate surgery.

The aim of surgery is to free the ureter from constrictive tissue and to excise endometriosis radically in order to prevent recurrence of disease, especially in this region.

Utmost care must be taken during ureterolysis, particularly when coming close to the ureter’s blood supply. Whenever possible, integrity of the adventitial layer of the ureter should be preserved, while making sure to keep adequate distance from concomitant nerves.

Shown on (Fig. 3.33a, b) is an ureter affected by intrinsic endometriosis and exhibiting an abrupt change in calibre. Most noticeable is a pronounced dilatation proximally to a segment with severe stenosis.

The affected ureter even appears to be deflected despite the fact that a stent had been implanted prior to the operation.

The stenotic segment and the part of intrinsic endometriosis had to be removed completely.

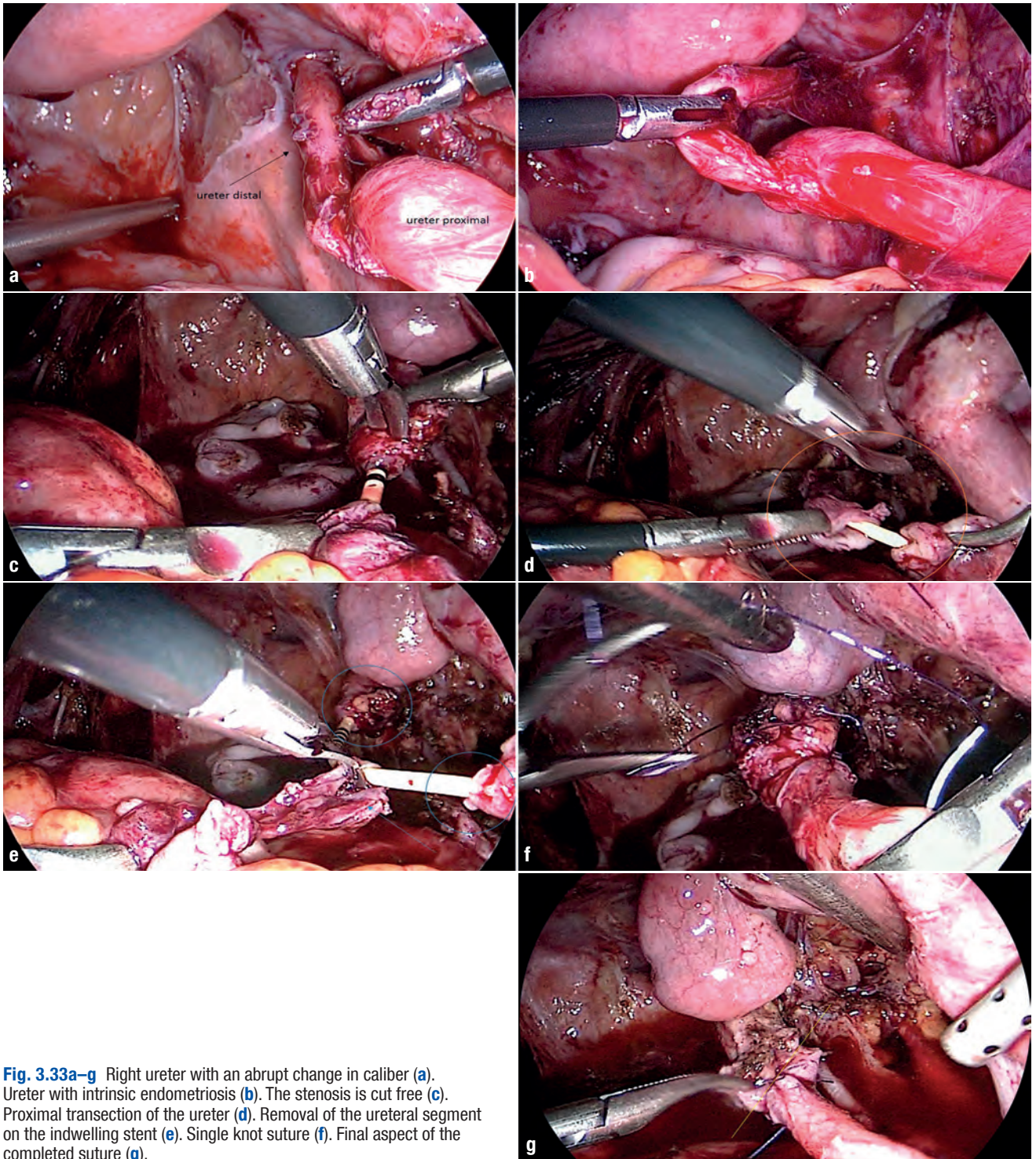
Stenting with a double-J-stent is imperative in cases of hydronephrosis or stenosis of the ureter. Some surgeons opt for stenting in all cases where ureterolysis is anticipated. **The author does not choose this option!**

Mostly, the ureter is identified and dissected with ease while obviating the need for stent placement. The use of a stent is often associated with pain and bleeding. Hence, this may result in a dead end situation in which it remains unclear where pain and bleeding have arisen from.

#### 3.4.6.1 Partial Resection of the Ureter

In a first step, about 3–4 cm of the ureter are excised and then ureteroureterostomy<sup>25</sup> with an end-to-end anastomosis is performed. It is important, that the anastomosis is free of tension! In order to achieve good results, the removed segment should not be too close to the bladder, since blood supply in this region is insufficient.





**Fig. 3.33a–g** Right ureter with an abrupt change in caliber (a). Ureter with intrinsic endometriosis (b). The stenosis is cut free (c). Proximal transection of the ureter (d). Removal of the ureteral segment on the indwelling stent (e). Single knot suture (f). Final aspect of the completed suture (g).

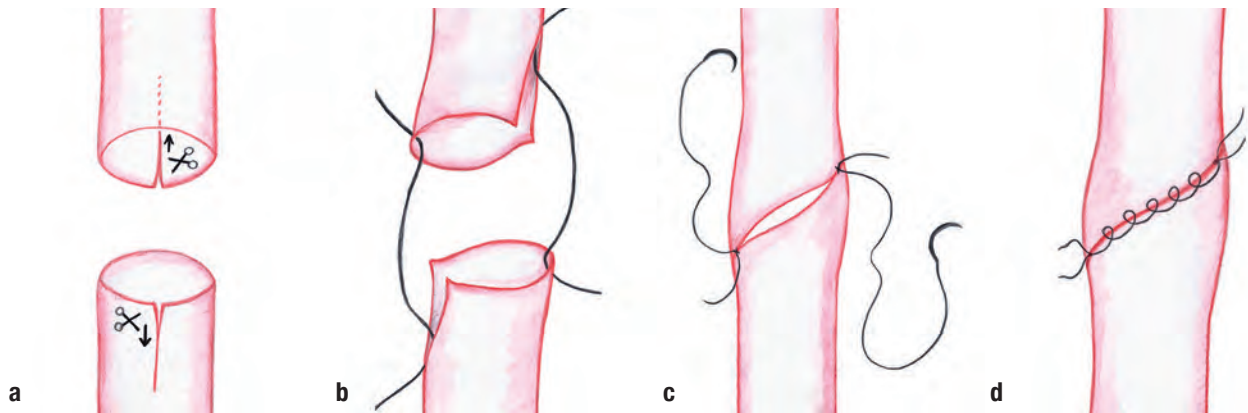
If end-to-end anastomosis is not feasible because of problems related to the length of the removed part or due to immobility of the ureter, it is recommended to switch to reimplantation of the ureter to the bladder, e.g., by ways of psoas hitch.

Given a lack of experience in urogynecology, it is highly recommended in these cases to call in the assistance of an urologist.

In the event of segmental resection, the surgical maneuver is initiated by transection of the ureter at distal (Fig. 3.33c) and proximal sites (Fig. 3.33d) using cold scissors to prevent the risk of necrosis.

Next, the middle part, that needs to be resected is removed (Fig. 3.33e). Make sure that both ends of the ureter are free of scarred tissue, without any signs of endometriosis and with good vascular supply.





**Fig. 3.34a–d** Both ends of the ureter are spatulated (a). The corner sutures are placed (b) and completed by knot tying (c). Running suture (d).

In the next step, the distal and proximal ends of the ureter are spatulated using longitudinal incisions that should measure about 7 – 10 mm in length and be offset by 180 degrees (Fig. 3.34a). Spatulating is necessary to prevent the risk of ureter constriction as a result of the shrinking scar.

Subsequently, the corner sutures are placed (Fig. 3.33f and Figs. 3.34b, c).

Use of a thin resorbable suture (e.g. USP 5-0) is recommended. Next, anastomosis of the ureter is completed. One may either use the corner sutures to perform a running suture or make a single knot suture (Fig. 3.33g and Figs. 3.34d).

The short tail of the corner suture is grasped to mobilize the ureter in any direction needed, which affords a good view of the entire circumference of the ureter.

A soft drain may be inserted in case of urine leakage and should be left in place for 1–2 days.

The bladder catheter should be left in place for 3 days and the stent should be removed in about 2–4 weeks. A single antibiotic injection is recommended.

#### 3.4.6.2 Risks and Complications

- Urinoma.
- Urinary infection.
- Recurrence of ureteral stricture.

#### 3.4.7 DIE of the Bladder

Most commonly, endometriosis of the urinary bladder may well be identified by ultrasound imaging (Fig. 3.35a). In view of its inherent dynamic properties, the vaginal ultrasound probe can be used to move the bladder wall, the uterus or even the endometriotic nodule to differentiate smooth and mobile layers from dense and adherent tissue.

Sometimes, an additional MRI exam has shown to be useful in order to yield additional information (Fig. 3.36).

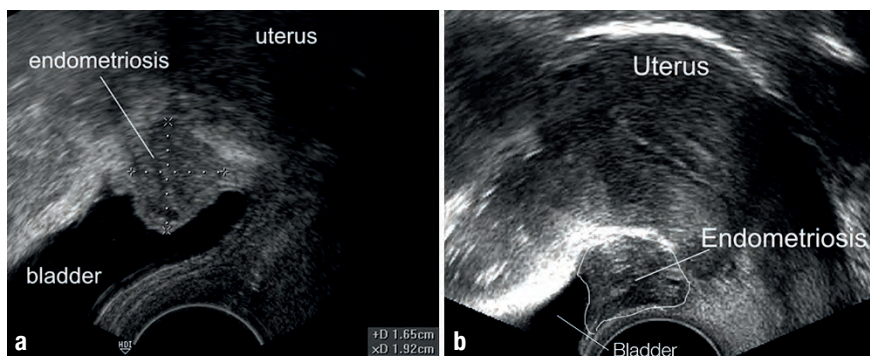
This can be particularly helpful in cases where sonographic density of endometriosis lesions, bladder wall and uterus is similar.

Deep infiltration of the bladder commonly results in bladder pain synchronous with the menstrual cycle and sometimes presenting with micro or macro hematuria.

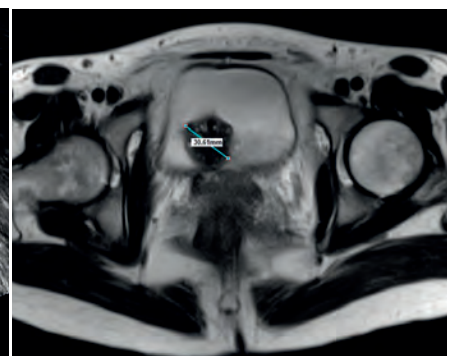
Occasionally, the presence of DIE is recognized during a cystoscopy, but not in all cases.

Often, deep infiltrating endometriotic implants are located at the peritoneal fold between uterus and bladder (Fig. 3.35b). Therefore, in most cases, the lesions may encroach on the ventral and cranial wall of the bladder. Depending on the extent of endometriotic growth, the immediate vicinity of the ureteral orifices or the ureters themselves can be involved.

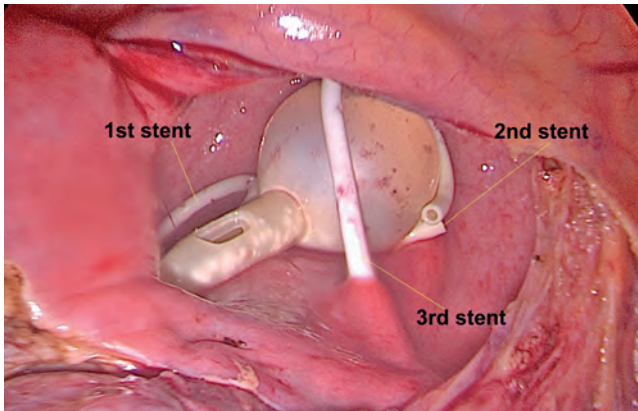
In order to maintain integrity of the ureter and their ostia, both ureters should be stented before surgery facilitating identification of the ostia.



**Fig. 3.35a,b** Sonographic image of endometriosis of the bladder wall (a). Sonographic appearance of endometriosis between uterus and bladder (b).



**Fig. 3.36** Transverse MRI scan showing an endometriosis nodule.



**Fig. 3.37** View into a bladder with three stented ureters. One is on the left side, two on the right.

It is vital to make sure that adequate information be obtained on possible abnormalities of the urinary tract.

The prevalence of these abnormalities is about 1:150. Cystoscopy and stenting of ureters can uncover the presence of unknown ureteral duplication. Shown on [Fig. 3.37](#) is an opened bladder with an urethral catheter, and one stent on the right and two stents on the left.

The third stent, and along with it, the proximal right ureter was very close to the removed lesion. The stent helped to identify the intramural part of the ureter.

Parts of the bladder wall may easily be resected laparoscopically.

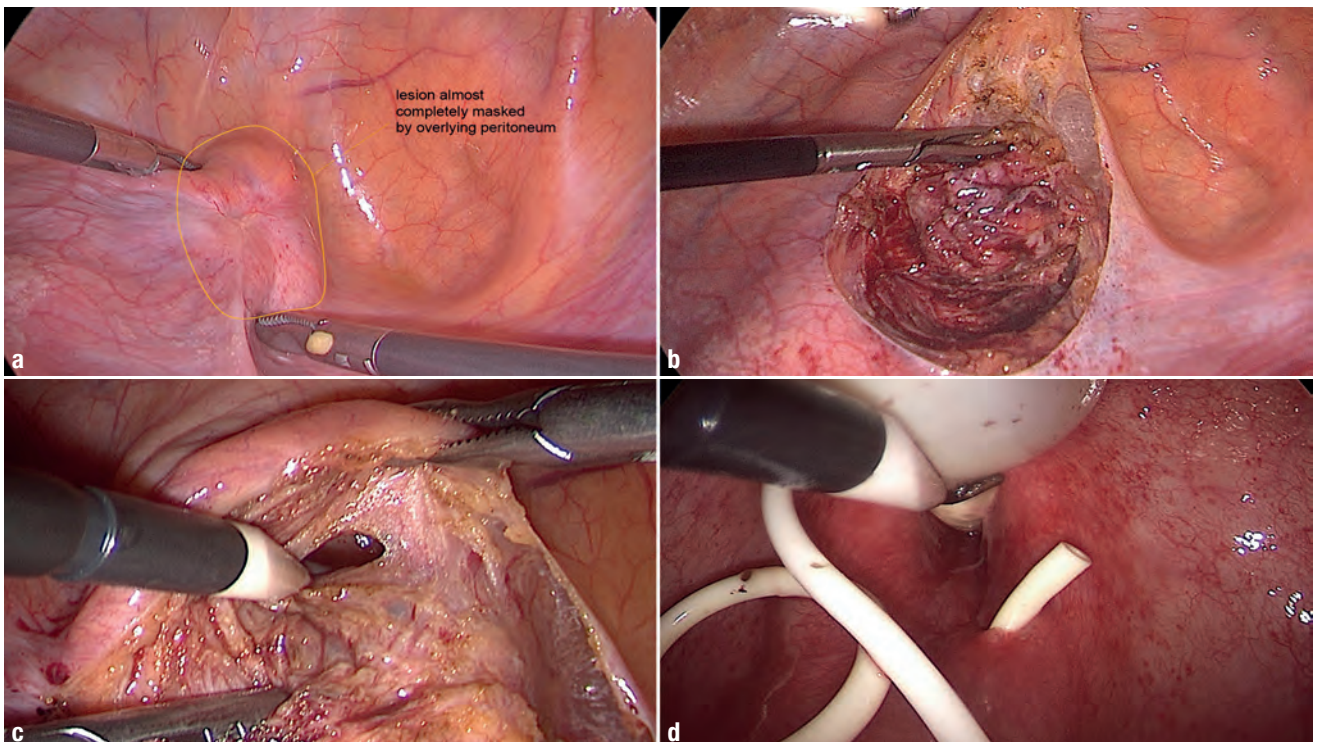
Prior to initiating resection, it has proven helpful to fill the bladder with 200–300 ml of water which allows for enhanced visualization of margins between the endometriotic lesion and the healthy bladder wall. One may either incise the bladder with a monopolar hook/needle or ultrasound scissors. Do not use undue coagulation and beware of producing wide zones of necrosis. Minor bleedings from the detrusor muscle are acceptable.

Wounds from bladder repair commonly heal very well provided the operating surgeon adheres to the principles of atraumatic dissection, tension-free approximation of wound margins and proper suture techniques.

Occasionally, the lesion can be difficult to identify when obscured by a healthy peritoneum ([Fig. 3.38a](#)). In this case, it has proven helpful to trace the site of the lesion by referring to ultrasound or MRI images taken in advance.

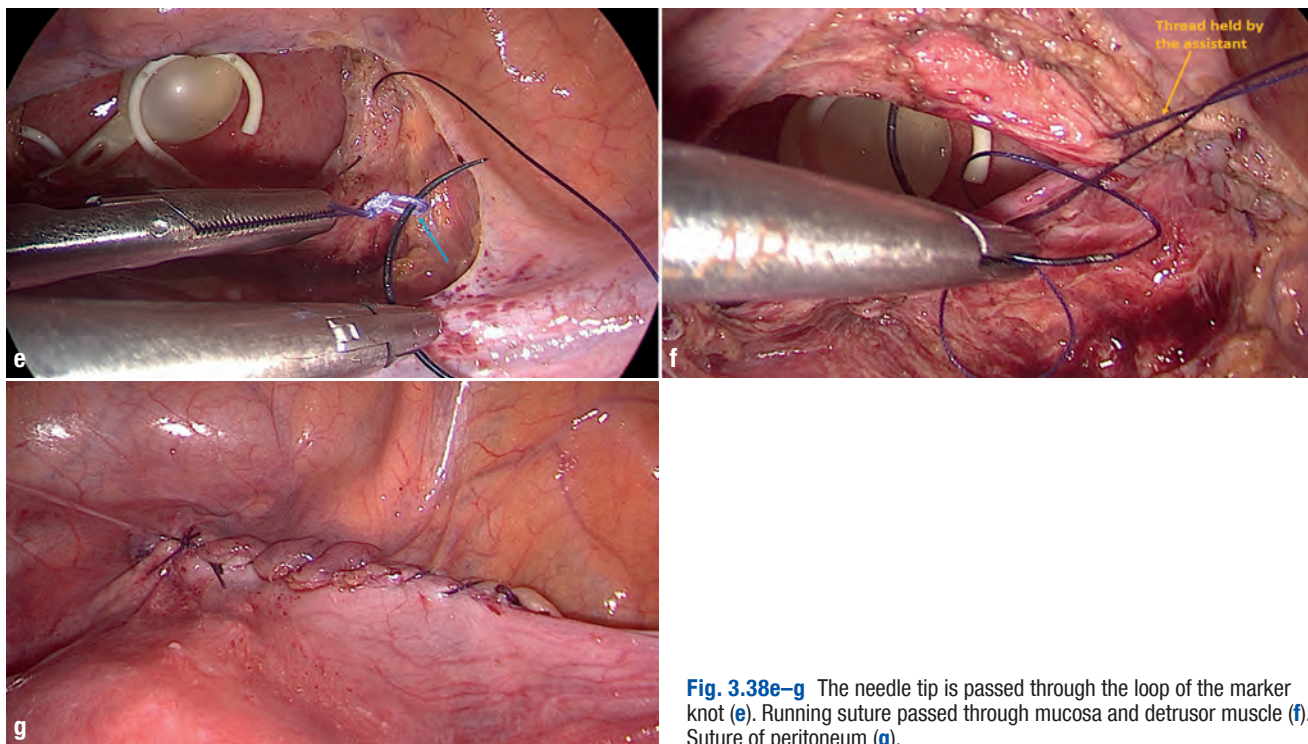
After opening the peritoneum, the margins of the lesion need to be circumscribed in order to prevent excessive removal of healthy bladder tissue ([Fig. 3.38b](#)). The lesion should be completely removed, but meticulous care is required at the trigone and ureteric orifices. For this purpose, a full-thickness fenestration is made in the bladder wall at a secure position ([Fig. 3.38c](#)), followed by aspiration of saline and insertion of the laparoscope into the bladder ([Fig. 3.38d](#)).

While resecting along the circumference of the lesion, constant care must be paid not to transgress the predefined margins. Undue removal of healthy tissue must be avoided in order to prevent build-up of tension to the suture line placed later on in the procedure and potentially resulting in a decrease of bladder capacity.



**Fig. 3.38a–d** DIE, barely noticeable (a). Dissection of the endometriotic nodule (b). The opening is made at a secure position (c). Localizing the trigone (d).





**Fig. 3.38e–g** The needle tip is passed through the loop of the marker knot (e). Running suture passed through mucosa and detrusor muscle (f). Suture of peritoneum (g).

After resection, the cystostomy is closed with a USP 3-0 resorbable, braided suture. In order to spare the first knot, it can be helpful to tie a small marker knot at the end of the thread (Fig. 3.38e).

Occasionally, it may be helpful to mobilize the bladder prior to suture closure of the cystostomy in order to achieve a tension-free tissue approximation. This can be accomplished by creating a wide peritoneal opening at the ventral fold and by freeing the bladder from the pubic bone.

The continuous suture is initiated from the right side of the cystostomy once the position of the trigone has been confirmed. A two-layer suture is applied for cystostomy closure. At first, the mucosa is closed. Care should be taken to include nearly equal portions of tissue in each bite which are spaced at similar intervals from each other.<sup>18</sup> The assistant is instructed to align the thread and keep the suture line under moderate tension while placing the running stitches (Fig. 3.38f).

The second-layer suture – of the same material as the first one – is used to reinforce and bury the first suture. Suturing is again started at the right edge, slightly lateral to the primary suture line forming the first layer. Grasp the full thickness of the muscle layer of the detrusor and avoid passing the stitches through the stitch channels made previously. Make sure that the first suture is covered completely in order to ensure leak tightness of wound closure.

Patency of the suture line is assessed by filling the bladder with 200 – 300 ml of saline. The use of Methylene blue is not needed for this purpose.

The peritoneum can be left open allowing blood and coagula to drain off. If the wound does not reveal any signs of

hemorrhage, the peritoneum can be closed with a running suture (Fig. 3.38g).

A Foley catheter is inserted and left in place for 7 days allowing any signs of secondary bleeding to be detected. This precautionary measure obviates the need for vesical tamponade and helps to prevent the occurrence of suture dehiscence.

The stents are removed 3–4 weeks later in the same session of the follow-up cystoscopy scheduled for monitoring the wound healing process.

#### 3.4.7.1 Risks and Complications

- Urinary tract infection.
- Bleeding.
- Wound infection.
- Urinoma.
- Vesical tamponade.
- Voiding dysfunction.

#### 3.4.8 DIE of the Bowel

DIE of the bowel can be asymptomatic or associated with dyschezia.

Particularly in cases where the colon is directly infested with endometriosis, e.g., in case of retro-cervical involvement, symptoms of dyschezia can be severe. Secondly, the condition may trigger symptoms of dyspareunia which can be correlated (or not) with the site of endometriotic lesions (with or without loss of libido).



Current Data on the Success and Improvement of Symptoms After Interdisciplinary Therapy of Deep Infiltrating Endometriosis								
Reference	Numbers	Procedure (segmental resection of bowel)	Preoperative pain	Postoperative pain	Significance	Infertility rate	Pregnancy rate	Significance
<i>Meuleman</i> <sup>30</sup>	203	yes (76)	72 (95%)	2 (3%)	p < 0.05	72 (95%)	48 (63%)	p > 0.05
		no (127)	104 (82%)	6 (5%)		117 (92%)	27 (21%)	
<i>Dousset</i> <sup>13</sup>	100	yes (100)	100 (100%)	6 (6%)	p < 0.05	70 (70%)	n.a.	n.a.
<i>Jelenc</i> <sup>19</sup>	52	yes (48)	dysmenorrhea 48 (92%)	15 (29%) asymptomatic	p < 0.05	15 (29%)	9 (17%)	p < 0.05
		no (4)	pelvic pain 30 (58%)	36 (70%) improvement				
				1 (1%) no improvement				
<i>Koh</i> <sup>20</sup>	92	25 (27%)	dysmenorrhea 57 (72%)	42 (46%) asymptomatic	n.a.	30 (33%)	13 (14%)	n.a.
			pelvic pain 12 (15%)	33 (36%) improvement				
				3 (3%) no improvement				
<i>Mabrouk</i> <sup>24</sup>	47	yes (47)	dysmenorrhea score 8	dysmenorrhea score 0	p < 0.05	14 (30%)	n.a.	n.a.
			dysmenorrhea score 2	pelvic pain score 0	p < 0.05			
<i>Nezhat</i> <sup>31</sup>	193	yes 3 (1.6%)	dysmenorrhea 101 (52%)	26 (13%)	p < 0.05	n.a.	n.a.	n.a.
		no 141 (73%)	pelvic pain 159 (82%)					
<i>Ercoli</i> <sup>16</sup> (robotic)	22	yes (12)	dysmenorrhea score 10	dysmenorrhea score 1	p < 0.05	n.a.	n.a.	n.a.
		no (10)	dyspareunia score 9	dyspareunia score 0	p < 0.05			
<i>Ruffo</i> <sup>37</sup>	900	yes (900)	900 (100%)	dysmenorrhea 114 (16%)	p < 0.05	n.a.	128 (16.5%)	p < 0.05
				pelvic pain 64 (8%)				

**Tab. 3.3** Current data on the success and improvement of symptoms after interdisciplinary therapy of deep infiltrating endometriosis. Key to acronyms: not available (n.a.); probability (p).

Severe endometriosis of the bowel can cause constipation, flatulence and constriction of intestinal lumen which can eventually lead to intestinal obstruction.

Patients afflicted with DIE of the bowel commonly suffer from chronic pelvic pain which can be cyclic or non-cyclic in nature.

Cyclic bleeding from the rectum is yet another symptom.

Surgical treatment of colorectal endometriosis is difficult and challenging. Complication rate is relatively high. The requirements to be met by the surgeon are on a high level, and in most cases, an interdisciplinary setting is necessary.

A literature review by *Meuleman et al.*<sup>29</sup> that was based on 49 studies and a total of 3,894 patients revealed that 71% received bowel resection anastomosis, 10% received discoid excision and only 18% were treated with superficial surgical removal (shaving). Based on these findings it was shown, that most patients with DIE of the bowel were treated by extended surgery which is fraught with significant inherent risks.

In a clinical, prospective cohort study based on 203 patients followed-up for 24 months after surgery,<sup>30</sup> 136 of them had a confirmed diagnosis of severe endometriosis. Patients were observed for quality of life, dysmenorrhea, chronic pelvic pain, deep dyspareunia, fertility outcome and complications. The

rAFS score was higher in the bowel resection group than in the non-resection group. The complication rate in the bowel resection group was 11%. In both groups, quality of life and pain scores improved significantly and remained stable for 24 months. The overall pregnancy rate during 24 months was 51%. The cumulative reintervention rate was 10% in the 3-year follow-up interval and recurrence rate was 8% in the same time.

Accordingly, it can be concluded, that complication rate increases with rising radicality of bowel surgery.

Nevertheless, the outcome regarding quality of life, chronic pain and sexual life is significantly improved by surgery<sup>2,27,28</sup> (Table 3.3).

As mentioned above, it can be stated that DIE involving the bowel should better be removed in order to improve fertility. In conclusion, DIE of the bowel seems to cause a decrease in fertility rates, which may partly be compensated by adequate surgery<sup>1,10</sup> (Table 3.3).

### 3.4.8.1 How to Practically Deal with DIE of the Bowel?

First of all, make sure to determine the major problems and cardinal symptoms of the patient. In the absence of major problems, there is no indication for extended surgery! If the level of distress associated with endometriosis is low, it would be unreasonable to opt for a surgical procedure and its inherent risks.

Nonetheless, it remains to be clarified how to deal with bowel endometriosis in the general context of extended endometriosis surgery. When faced with complete surgical removal of endometriosis by ways of extended surgery, the question arises whether it is a good idea to leave a lesion at the bowel behind, especially in the absence of specific bowel-related symptoms. In cases of endometriosis-associated infertility, it seems to be an advantage to remove all endometriotic nodules,<sup>5,10</sup> especially in the case of bowel involvement.

If infertility is not the problem and given the absence of specific bowel symptoms, the decision-making poses some challenges and should be guided by an assessment of the

anticipated difficulties associated with a staged approach, i.e., if definite treatment of endometriotic nodules of the bowel is postponed until secondary surgery. In the author's opinion, the presence of a deep rectum nodule with concomitant DIE of the rectovaginal space should prompt the surgeon to remove the nodule because the latter will be a starting point for recurrent rectovaginal DIE.

Given sole involvement of the higher rectum or sigmoid colon, the nodules can be left behind in order to adopt a wait-and-see strategy.

In cases where the preoperative workup does not allow to accurately elicit the anatomical structures infiltrated by endometriosis, a conflict needs to be managed that can only be resolved through good communication and a joint decision-making with the patient prior to surgery. Occasionally, the anatomical location of disease even remains unclear.

If the patient is suffering from dyschezia or symptoms of bowel constriction, resection is indicated.

Subject to the level of experience, the surgeon can choose among a multitude of different operative techniques. Commonly, a visceral surgeon should be called in<sup>24</sup> to play a key role in the decision-making as to which surgical procedure should be chosen.

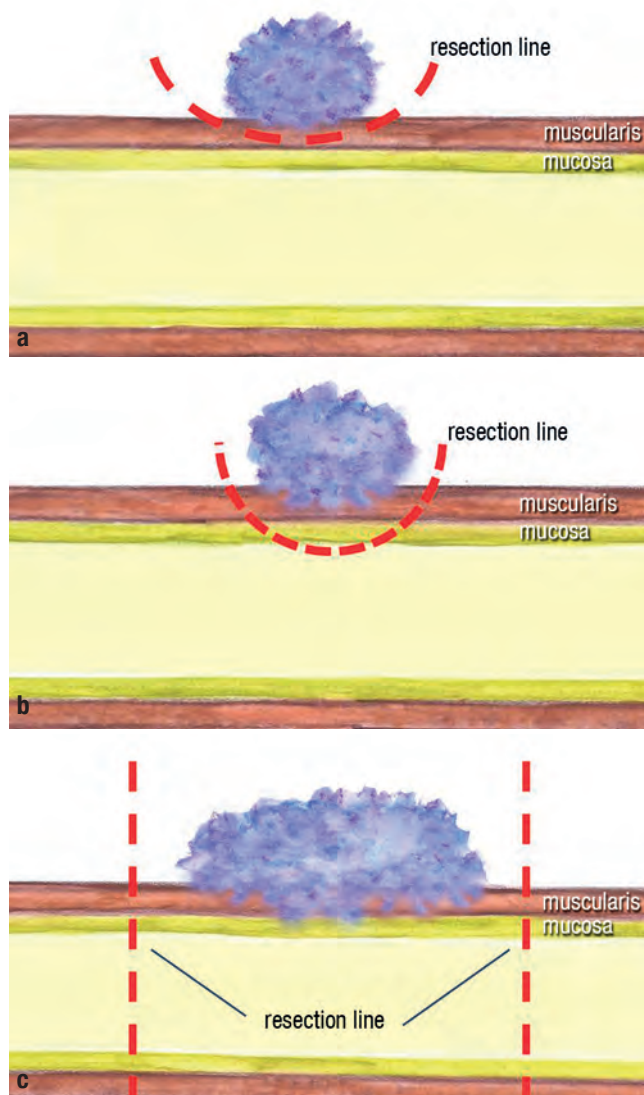
#### ■ Shaving Technique

Given the fact that deep infiltrating endometriosis is mostly limited to the serous membrane of the bowel, lesions may be removed by using a shaving technique (Fig. 3.39a). Following mobilization, the nodule is elevated and then removed sharply from the bowel wall by use of cold scissors.<sup>12</sup> In the author's experience, use of electrosurgery has proven helpful with a monopolar hook applied in intermittent cutting mode only and without coagulation while making sure that the tissue subjected to treatment is kept under adequate tension. Use of a CO<sub>2</sub> laser was also shown to be a viable modality that may be employed in that procedure. Proceeding in a step-by-step manner, it is possible to recognize the muscular tissue layer of the bowel that must not be penetrated. If you are uncertain about the actual plane of shaving, leave a thin layer of endometriosis behind. The resected tissue often includes a thin layer of external bowel muscle. The defect should be closed by continuous suture or single stitches (e.g. USP 3-0). Take care, not to constrict the bowel with this suture. Sometimes it is better only to cover the defect with loosely adapted para-rectal fat, if the lesion is at the rectum.

#### ■ Full-Thickness Discoid Dissection

Nodules up to 2 cm may be removed by use of a rectal circular stapler, e.g., 33 or 34 mm in size, with preinstalled anvil.

Before introducing the stapler, a purse-string suture is placed around the lesion in order to lower the lesion under the surface of the bowel. Therefore, it is advisable to first reduce the lesion by shaving. Following transanal insertion of the stapler, the anvil is advanced proximal to the lesion. The nodule is pulled into the stapler while slowly closing the device resulting in a full-thickness discoid excision of the lesion.



**Fig. 3.39a–c** Superficial infiltration of the bowel (a). Deep infiltration of the muscle layer (b). Deep infiltration of 2 cm or more (c).



Instead of using a purse-string suture, a suture can be placed on either sides of the lesion. In this manner, traction can be applied on the threads causing the intestinal ventral wall to be invaginated into the stapler. The result will be the same.

Full-thickness discoid resection can also be performed with a classical technique by cutting out the lesion and making a hand-sewn full-layer suture. In addition, some surgeons carry out an omentoplasty to protect the pelvic sutures. In the author's clinical practice, this is not performed on a routine basis.

The boundaries of discoid excision are determined by the size of the lesion (e.g. up to 2 cm), depth of infiltration, and location (Fig. 3.39b). Especially in cases where the lesion takes up more than 40% of the bowel circumference, dissection is prone to difficulties.

#### ■ Risks and Complications

The extent of resection is limited in this technique which is why the resulting free margins can be very narrow. Accordingly, microscopic endometriotic lesions may still be found on the margins in a number of patients treated by full-thickness discoid dissection. The following complications may occur:

- Anastomotic leakage.
- Rectovaginal fistula.
- Perirectal abscess.

#### 3.4.8.2 Segmental Resection of the Recto-Sigmoid

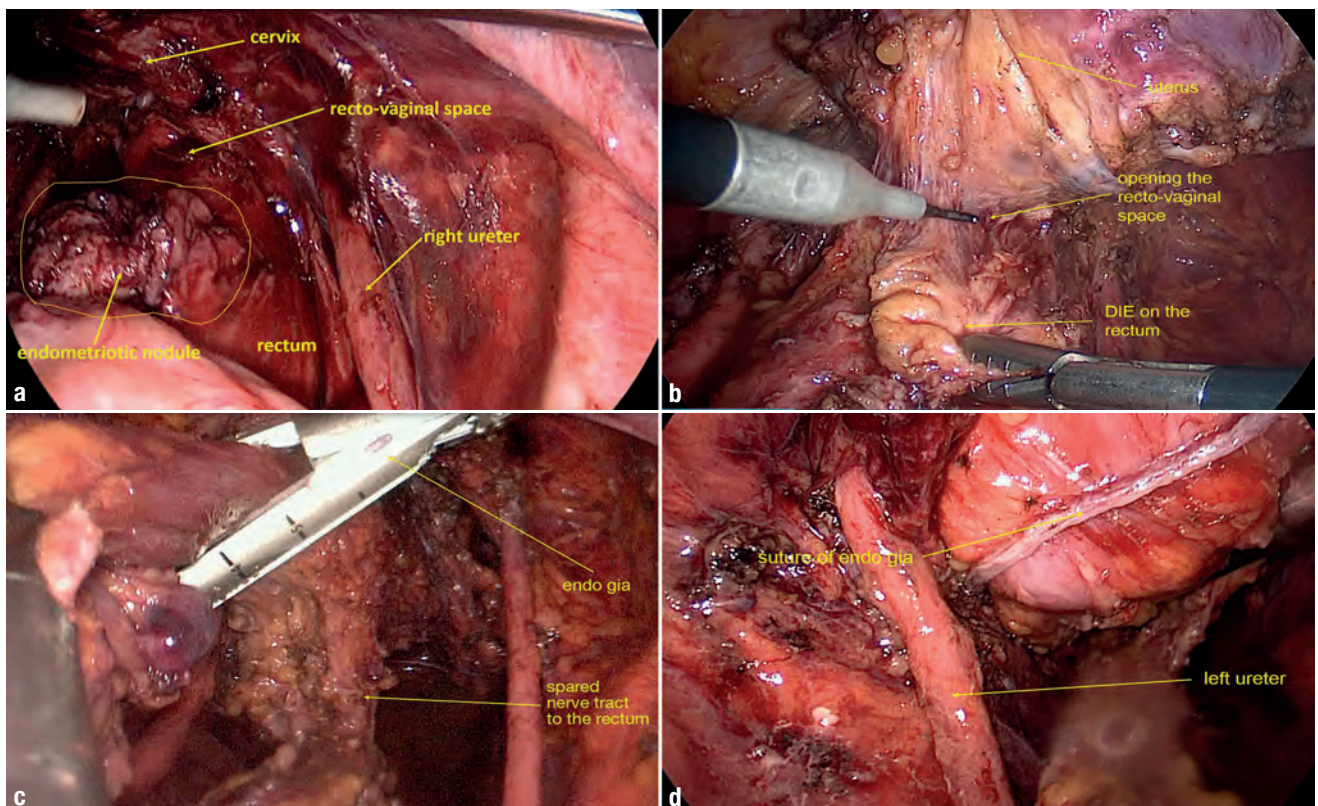
Invasion of more than 50% of the bowel circumference, multiple nodules, or nodules larger than 2 cm are indications for a segmental bowel resection (Fig. 3.39c, Fig. 3.40a,b).<sup>2</sup>

If resection of an intestinal segment is necessary, the decision-making on whether to perform nerve-sparing resection of the anterior rectum at a lower or higher level is determined by the site of the nodule. Innervation to and from the rectum should be spared (Fig. 3.40c) in order to prevent the occurrence of dysfunctional defecation and micturition.

Following mobilization of the sigmoid colon and rectum, the associated blood supply is coagulated and the bowel segment affected by disease is dissected. Resection is performed with a linear endo-stapler (Fig. 3.40c). The longer the distance to the internal sphincter the better the outcome in terms of function and healing. Therefore, it is recommended to leave behind as much as possible of healthy rectum!

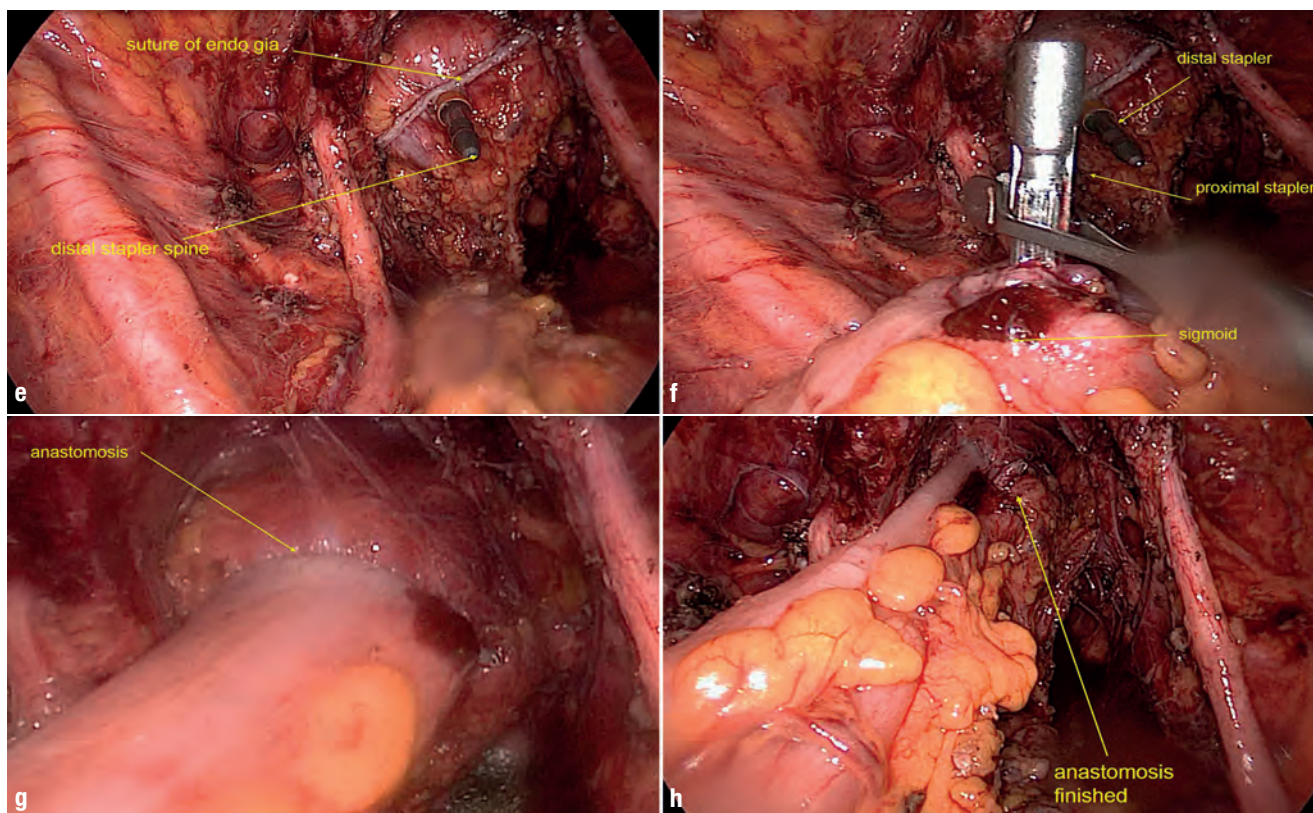
Once extended mobilization of the descending colon is accomplished, the sigmoid is passed through the abdominal wall through a small incision. At first, the bowel segment to be resected needs to be identified and a purse-string suture is placed proximal to the preselected segment.

The anvil of the circular endostapler is fixed in place and the exteriorized bowel is pushed back into the abdomen. Following deployment of the stapler, the spike is locked onto the anvil and the anastomosis is accomplished by closing and firing the stapler (Figs. 3.40d–g).



**Fig. 3.40a–d** Anatomical landmarks (a). Opening the recto-vaginal space (b). Positioning of the linear endostapler (c). Staple line of the linear Endo GIA™ (d).





**Fig. 3.40e–h** Perforating the rectum with the stapler spike (e). The proximal and distal components of the stapler are locked onto each other (f). Operative site after completion of anastomosis (g). Assessment for patency of the anastomosis (h).

Upon completion of anastomosis, patency should be confirmed either by using air or stained saline. Apart from that, a tension-free anastomosis must be ensured and, if necessary, improved by further mobilization of the colon (Fig. 3.40h).

#### ■ Risks and Complications

- Severe postoperative complications occur in 3–10% of cases. They include, among others,
  - urinary retention due to denervation of the bladder, rectovaginal fistula (0,7%), anastomotic leakage (1.5%) and abscess (0.3%).
- Some studies report anastomosis-related complications, such as
  - leakage, pelvic abscess, and rectovaginal fistula.
  - The incidence varies from 1% to 6% and a mean rate of 4.7%.<sup>10</sup>
  - A protective ileostomy is rarely necessary, but should always be discussed with the patient.

#### 3.4.9 DIE of the Recto-Vaginal Space and Vagina

Recto-vaginal endometriosis may extend from top of the posterior vaginal wall to the anterior rectal wall and laterally to the uterosacral ligaments.

Surgical treatment of DIE of the rectovaginal space is among the most challenging gynecologic operative procedures. This form of endometriosis has been found to become firmly adherent to the nerves that control function of bladder, bowel and sexuality. The area of infiltration is located nearest to the bowel, commonly involves the vagina and may even encroach on the uterine cervix. If the cervix is affected by invasive endometriosis, a complete surgical removal of 100% is not feasible without removing the cervix or uterus. Particularly with regard to fertility potential, pregnancy and sexual function, this seems to be a conflict of mutually incompatible goals.

Laparoscopic resection is the treatment of choice for DIE involving the rectovaginal septum, and several authors have reported good clinical outcomes with improvements in symptoms of dysmenorrhea, dyspareunia, and chronic pelvic pain.<sup>2,27,29,30</sup>

Nevertheless, damage to pelvic nerves can have a detrimental effect on the patient's quality of life.

In order to achieve clear resection margins, a combined access should be adopted given involvement of the vaginal wall. Small nodules are sometimes palpable or visible more readily via transvaginal access. Accordingly, it can be helpful

to mark the nodules preoperatively with knots (Fig. 3.41), placed during laparoscopic inspection at the beginning of the procedure.

Shown in Fig. 3.41 are the resection lines, that are defined to delineate the boundaries for complete surgical removal of DIE.

In cases where the vagina has been opened, the author recommends that wound closure be accomplished by placing a continuous suture with a monofilament absorbable thread (USP 0) which has proven to result in the lowest rate of suture line dehiscence.

There are no specific data available about suture line dehiscence, suture technique and postoperative management. Based on the author's experience, adequate wound healing can pose a problem, which is why all patients subjected to this type of operative procedure at the author's clinical center are counselled to abstain from sexual intercourse for 8 weeks after surgery. Apart from that, this precaution is aimed at preventing rupture of bowel or vagina, and therefore, women who become pregnant soon after surgery, are advised to preauthorize consent to caesarian delivery.

#### 3.4.9.1 Risks and Complications

Complications such as anastomotic leakage or rectovaginal fistula, can occur after bowel resection and anastomosis. There are reports in the literature on bowel resection and full-thickness discoid excision<sup>20</sup>, with incidence rates for anastomotic leakage, abscess formation, and rectovaginal fistula of 0.7%, 0.3%, and 0.7%, respectively.

From this, the author draws the conclusion that bowel resection is capable of yielding good operative outcomes with an acceptable major complication rate.

### 3.4.10 DIE of the Diaphragm and/or Pericardium

The presence of extra-pelvic endometrial deposits (diaphragm, umbilicus) is a rare finding.

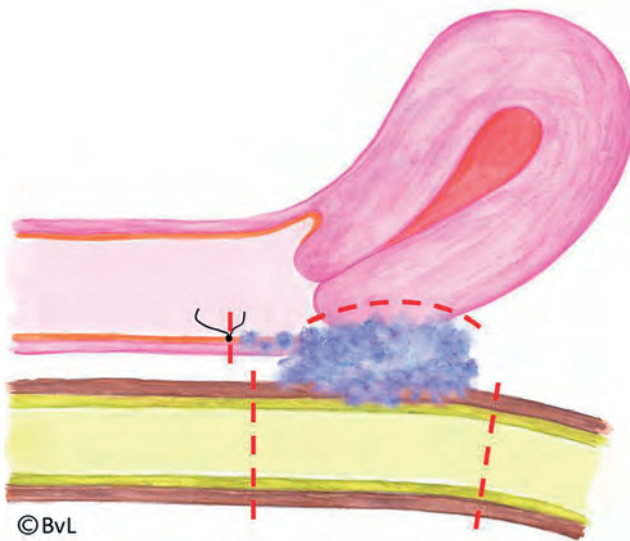


Fig. 3.41 DIE of the rectovaginal space.

While most implants are superficial and cause no discomfort, others can be deeply infiltrating.

Deep infiltrating endometriosis of the diaphragm can be associated with chest pain, upper quadrant pain and chronic shoulder tip pain.<sup>17</sup>

DIE may be found on and in the diaphragm. The main contributors to the phrenic nerve are the cervical nerves C3, C4 and C5. Considering the common innervation of C5, the presence of shoulder tip pain in young women without clinical findings is a valuable clue to differential diagnosis.

However, there are also two peripheral innervating sources. The intercostal nerves (T5-T11) and the subcostal nerve which is located at T12.

This makes us understand the most common symptoms of diaphragmatic endometriosis which can manifest as dyspnea, epigastric pain, pain in the chest (pleuritic), shoulder pain, and right or left upper abdomen pain. All of the symptoms may or may not be cyclic.

Diaphragmatic involvement sometimes causes recurrent catamenial pneumothorax as well.

There are some case reports about chronic right shoulder tip pain arising from diaphragmatic DIE.<sup>11,32</sup> The diagnosis of extra pelvic endometriosis is often missed, due to lack of knowledge about the mere existence of this disorder.

Malignant transformation of endometriosis is a rare event. There are very few case reports about transformation of endometriosis of the abdominal wall to either a clear cell carcinoma<sup>7</sup> or a papillary serous carcinoma.<sup>33</sup> On account of its rare occurrence, malignant transformation of abdominal wall endometriosis has not been elucidated.

#### 3.4.10.1 Surgical Therapy

*Redwine*<sup>35</sup> reports about a small study of eight patients with DIE of the right posterior diaphragm, which is not always visible from the umbilical port site. In all cases, laparoscopic detection of endometriotic lesions was feasible when using a port situated beneath the right costal margin.

In view of the posterior site of infiltration, obscured by the liver, and the presence of full-thickness invasion, laparoscopic treatment was not feasible in all eight patients.

Full-thickness resection of the diaphragm resulted in complete eradication of symptoms in seven of eight patients, and good symptomatic amelioration in one patient.

The good news about diaphragmatic endometriosis is that after sound surgical treatment, studies have shown that the condition is far less likely to recur than other forms of DIE.<sup>32</sup>

It seems to make no difference which technique of removal is used. Irrespective of whether vaporization, ablation, hydro dissection, excision with cold scissors or ultrasonic scissors was used, all of these modalities have proven to be similarly efficient.



Based on the experience that has been gained at the author's clinical center, a monopolar hook can be used without problems at the pars membranacea of the diaphragm (non-muscular part). Using monopolar current at the muscular part triggers jerky movements of the diaphragm which can lead to pleural rupture.

The occurrence of pleural rupture during laparoscopy is not a critical event because CO<sub>2</sub> gas will be resorbed rapidly because it is readily soluble in blood. A small defect can be closed by placing an absorbable running suture.

#### 3.4.10.2 Pericardium

Unlike capnopleura, the occurrence of a capnopericardium may result in severe complications!

Case reports are extremely rare. One of them was published by *Banks-Venegoni et al.*<sup>6</sup> reporting on a cardiac arrest arising from a tension capnopericardium that occurred during peroral endoscopic full-thickness myotomy.

In the following, a case report is presented on the occurrence of a capnopericardium encountered at the author's clinical center. Finally, a smart approach will be described explaining how to manage such a special complication successfully during laparoscopy.

A young patient about 30 years of age, presented one year after spontaneous delivery with severe pain in the right shoulder. A review of the patient's history revealed various orthopedic diagnoses as well as a multitude of various failed attempts of treatment including arthroscopy. Unfortunately, her gynecologist was not alerted to the presence of a clue, namely the finding that pain symptoms were synchronous with the patient's menstrual cycle.

A laparoscopic examination was scheduled to look for any findings suggestive of endometriosis.

At laparoscopy, a few superficial endometriotic lesions were detected in the pelvis, along with multiple nodules seen on both sides of the diaphragm. On the left side, two of them appeared to be of deeply infiltrating type and invaded the posterior diaphragm, next to the liver and adjacent to the falciform ligament (Fig. 3.42a).

Behind the diaphragm, the pulsating movements of the heart could be seen. Endometriosis was found to infiltrate the diaphragm in the area of the pars membranacea. The first nodule was resected by using ultrasonic scissors and intermittent application of a monopolar hook (Fig. 3.42b). During removal of the nodule, some small endometriotic cysts were opened (Fig. 3.42c). Nearly full-thickness resection was accomplished and the serous layer of the pericardium was locally exposed (Fig. 3.42d). In order to stabilize the thin pericardial membrane, the defect was closed with an U-stitch suture (Fig. 3.42e) and a sliding knot tied extra-corporeally.

For extra-corporeal knotting the author commonly uses a self-locking slip knot named "von Leffern Knot". A monofilament absorbable suture material is applied without undue tensile force allowing the thread to be passed through smoothly and without sawing into the tissue. The knot is tied down with a closed knot-pusher (Figs. 3.42f, g).

Once the first defect had been repaired and closed, the second lesion was excised, again with the aid of ultrasonic scissors. The nodule was also located in the membranous part of the pericardium. In this case, endometriosis had infiltrated all tissue layers including the parietal serous pericardium, which prompted us to create an opening giving access to the pericardial space.

It was just then when a capnopericardium occurred and the anesthesiologist was alerted to the presence of a significant decrease in blood pressure and a tachycardia accompanied by a low QRS complex voltage.

In order to give the anesthesiologist enough time to stabilize the patient, intra-abdominal CO<sub>2</sub> pressure was instantly decreased. All instruments as well as the laparoscope were removed, while making sure that all trocar valves were in an opened state. The patient was stable within a few minutes.

Subsequently, laparoscopy was continued and the lesion was removed completely by resecting all layers of the visceral pericardium. The defect had a size of approximately 1.5 cm in diameter (Fig. 3.42h). From the site of the defect the pulsating movements of the heart could be seen. The epicardium, forming the visceral serous layer of the pericardium, was inspected closely.

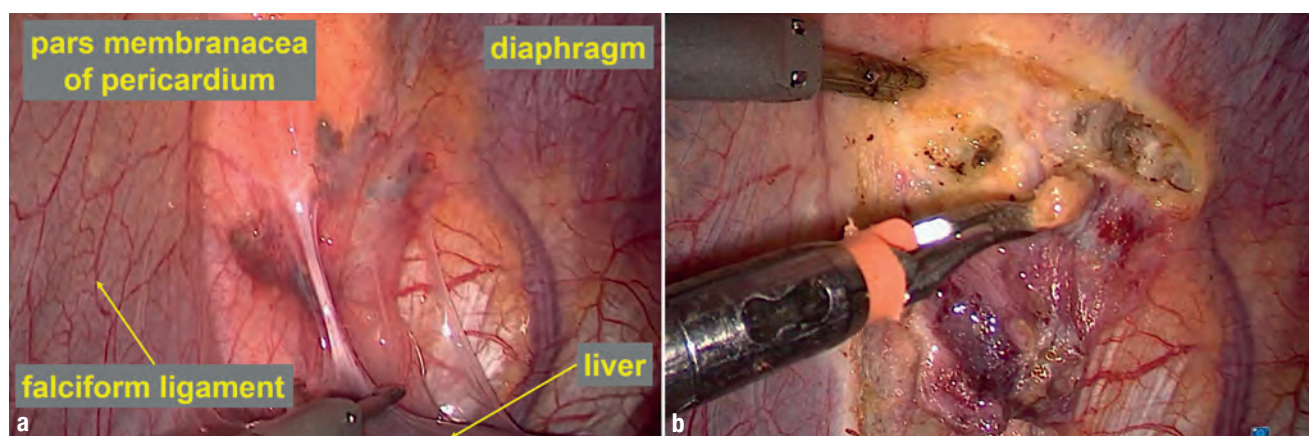
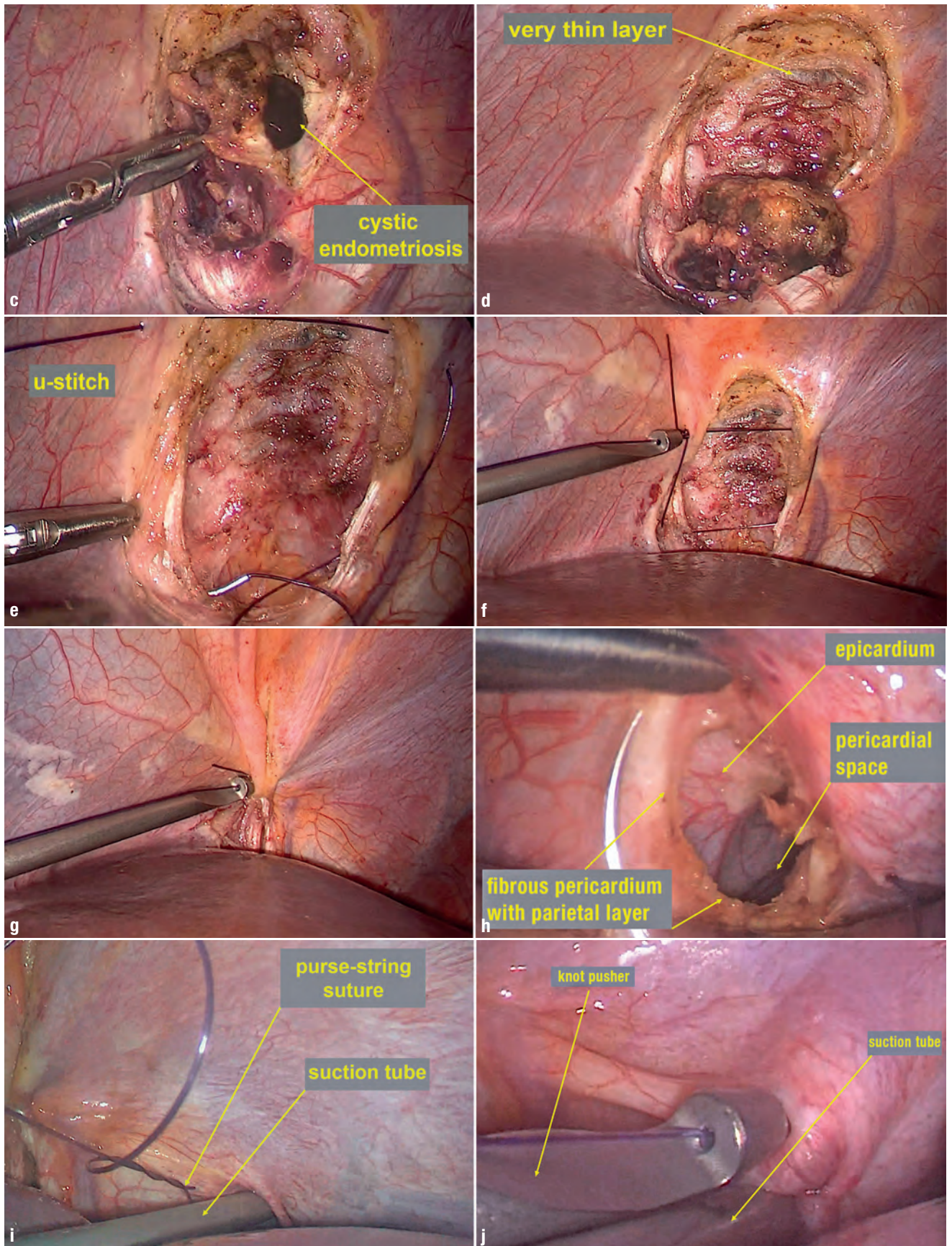


Fig. 3.42a,b Endometriosis of the diaphragm (a). Dissection of endometriotic nodule (b).





**Fig. 3.42c–j** Opening of a cystic nodule (c). The pulsating movements of the heart are noticeable (d). Placing an U-stitch suture (e). The slipknot is tied down with a knot pusher (f). Closure of the lesion (g). Pericardial defect and view into the pericardial space (h). The suction tube is inserted into the pericardial space after completion of extra-corporeal knot tying (i). The defect is closed while aspirating the remaining CO<sub>2</sub> gas from the pericardial space (j).



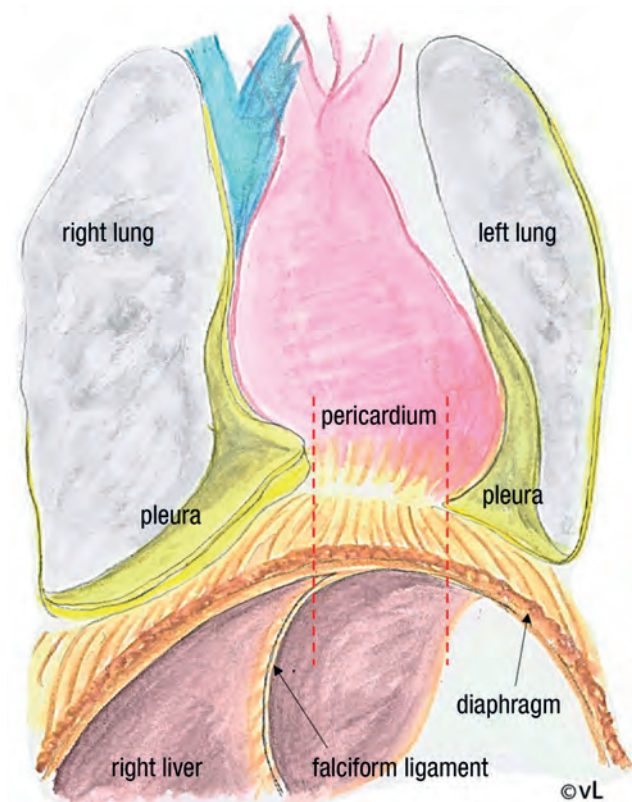
In order to provide for a sustained, long-lasting remission of disease, a purse-string suture was placed around the defect and tied down with an extra-corporeal slip knot. Next, a suction tube was inserted into the pericardial space to aspirate the remaining CO<sub>2</sub> gas (Fig. 3.42i).

While retracting the suction tube, the knot was pushed down resulting in closure of the defect (Fig. 3.42j). Again, monofilament suture material (USP 0) was used for extra-corporeal knot tying. For this purpose, the thread must measure at least 90 cm in length.

The patient's ECG instantly recovered to normal as well as blood pressure, pulse rate and all other vital parameters. The patient was discharged from hospital on day 3 post-surgery, and reported to feel fine all the time. At the follow-up examination 10 weeks later, she presented with normal menstruation, remission of dysmenorrhea, and above all, absence of shoulder pain!

#### 3.4.10.3 How to Deal with DIE of the Diaphragm

At first, it needs to be established whether the lesion belongs to the pleural or pericardial diaphragm. The latter can be identified by the pulsating movements of the heart. Apart from that, one should be cognizant of where to find the pericardium. Shown on Fig. 3.43 is the pericardium (area between the red interrupted lines) that is situated in close proximity to the falciform ligament and, in the posterior half of the diaphragm, next to the liver. A small pericardial portion is located above the level of the right liver close to the falciform ligament.



**Fig. 3.43** Frontal section demonstrating the topographic relationships between pericardium and adjacent organs.

Provided you are clear about the position of the lesion, do not try to open the pericardial space, if there is lack of evidence that this is truly necessary. A lot of endometriotic nodules can be removed by sparing the serous layer.

Considering that you can never be sure about what happens next, it is mandatory to keep in close communication with the anesthesiologist and to make clear what you are planning to do next and what might be the consequences.

Suturing in the angle between liver, falciform ligament and diaphragm is not an easy matter. If you do not have adequate skills in laparoscopic suturing techniques, it is safer to convert to an open surgery access.<sup>35</sup>

#### 3.4.11 Summary

Deep infiltrating endometrioses does not respect the borders of tissue layers.

Therefore, the principles of good surgical practice are similar to those applied in cancer surgery, however surgery for DIE can be even more difficult.

Unlike many other diseases, where there is a clear indication for radical surgery, surgeons who opt for surgical treatment of DIE are faced with the need for drawing into account all aspects that are linked to the patient's quality of life.

Radical surgery for deep infiltrating endometriosis has the potential of increasing quality of life and pregnancy rates, but the procedure can also be associated with a multitude of adverse side effects. In the light of this, it is paramount to speak openly to the patient prior to obtaining an informed consent.

All surgeons are required to have an adequate level of experience and skills not only with regard to operative techniques but also in terms of anatomic and functional knowledge. Surgical treatment of DIE often is an interdisciplinary project.

As mentioned before, every layer, every space, each tissue and each organ has its own specific problems and characteristics.

Surgeons should know this and respect the varying properties of tissues when affected by deep infiltrating endometriosis at various anatomical locations.

#### 3.4.12 Acknowledgment

I thank my beloved wife *Barbara von Leffern* for preparing the anatomical drawings according to my ideas!

### 3.4.13 References

- ALKATOUT I, MEINHOLD-HEERLEIN I, LEFFERN I VON, MAASS N, METTLER L. Operative Therapie der Endometriose: Radikal und schonend zugleich. *Gynäkologe* 2015;48(3):228–36. doi:10.1007/s00129-014-3419-8.
- AM WOLTHUIS, MEULEMAN C, TOMASSETTI C, D'HOOGHE T, DE BUCK VAN OVERSTRAETEN A, D'HOORE A. Bowel endometriosis: colorectal surgeon's perspective in a multidisciplinary surgical team. *World J Gastroenterol* 2014;20(42):15616–23. doi:10.3748/wjg.v20.i42.15616.
- ANDRADE C, BARATA S, ANTONIO F, ALHO C, CALHAZ-JORGE C, OSORIO F. Laparoscopic Neurolysis of Deep Endometriosis Infiltrating Left Femoral Nerve: Case Report. *Surg Technol Int* 2015;27:163–8.
- ANGIONI S, CELA V, SEDDA F, STOCHINO LE, COFELICE V, PONTIS A et al. Focusing on surgery results in infertile patients with deep endometriosis. *Gynecol Endocrinol* 2015;31(8):595–8. doi:10.3109/09513590.2015.1062868.
- BAGGIO S, POMINI P, ZECCHIN A, GARZON S, BONIN C, SANTI L et al. Delivery and pregnancy outcome in women with bowel resection for deep endometriosis: A retrospective cohort study. *Gynecol Surg* 2015;12(4):279–85. doi:10.1007/s10397-015-0901-9.
- BANKS-VENEGONI AL, DESILETS DJ, ROMANELLI JR, EARLE DB. Tension capnopericardium and cardiac arrest as an unexpected adverse event of peroral endoscopic myotomy (with video). *Gastrointest Endosc* 2015;82(6):1137–9. doi:10.1016/j.gie.2015.07.028.
- BATS AS, ZAFRANI Y, PAUTIER P, DUVILLARD P, MORICE P. Malignant transformation of abdominal wall endometriosis to clear cell carcinoma: case report and review of the literature. *Fertil Steril* 2008;90(4):1197.e13–6. doi:10.1016/j.fertnstert.2007.08.080.
- BOKOR A, CSIBI N, LUKOVICH P, BRUBEL R, JOO JG, RIGO J. Importance of nerve-sparing surgical technique in the treatment of deep infiltrating endometriosis. *Orv Hetil* 2015;156(48):1960–5. doi:10.1556/650.2015.30290.
- CAPEK S, AMRAMI KK, HOWE BM, COLLINS MS, SANDRONI P, CHEVILLE JC et al. Sequential imaging of intraneural sciatic nerve endometriosis provides insight into symptoms of cyclical sciatica. *Acta Neurochir (Wien)* 2016;158(3):507–12. doi:10.1007/s00701-015-2683-2.
- COHEN J, THOMIN A, MATHIEU DE, LAAS E, CANLORBE G, ZILBERMAN S et al. Fertility before and after surgery for deep infiltrating endometriosis with and without bowel involvement: a literature review. *Minerva Ginecol* 2014.
- COOPER MJ, RUSSELL P, GALLAGHER PJ. Diaphragmatic endometriosis. *Med J Aust* 1999;171(3):142–3.
- DONNEZ J, SQUIFFLET J. Complications, pregnancy and recurrence in a prospective series of 500 patients operated on by the shaving technique for deep rectovaginal endometriotic nodules. *Hum Reprod* 2010;25(8):1949–58. doi:10.1093/humrep/deq135.
- DOUSSET B, LCONTE M, BORGHESE B, MILLISCHER AE, ROSEAU G, ARKWRIGHT S et al. Complete surgery for low rectal endometriosis: long-term results of a 100-case prospective study. *Ann Surg* 2010;251(5):887–95. doi:10.1097/SLA.0b013e3181d9722d.
- DUFFY JM, ARAMBAGE K, CORREA FJ, OLIVE D, FARQUHAR C, GARRY R et al. Laparoscopic surgery for endometriosis. *Cochrane Database Syst Rev* 2014;4:CD011031. doi:10.1002/14651858.CD011031.pub2.
- EBERT AD. *Gynäkologische Laparoskopie: Ein Wegweiser für die Praxis ; inklusive der chirurgischen Anatomie des weiblichen Beckens*. 2nd ed. Berlin: De Gruyter; 2014.
- ERCOLI A, D'ASTA M, FAGOTTI A, FANFANI F, ROMANO F, BALDAZZI G et al. Robotic treatment of colorectal endometriosis: technique, feasibility and short-term results. *Hum Reprod* 2012;27(3):722–6. doi:10.1093/humrep/der444.
- FREESTON JE, GREEN MJ, KING DG, IVESON JM. Chronic shoulder pain and diaphragmatic endometriosis. *Rheumatology (Oxford)* 2006;45(12):1533. doi:10.1093/rheumatology/kel188.
- JAIN N. *State of the Art Atlas and Textbook of Laparoscopic Suturing*: Jaypee Brothers Medical Pub; 2006.
- JELENČ F, RIBIC-PUCELJ M, JUJUAN R, KOBAL B, SINKOVEC J, SALAMUN V. Laparoscopic rectal resection of deep infiltrating endometriosis. *J Laparoendosc Adv Surg Tech A* 2012;22(1):66–9. doi:10.1089/lap.2011.0307.
- KOH CE, JUSZCZYK K, COOPER MJ, SOLOMON MJ. Management of deeply infiltrating endometriosis involving the rectum. *Dis Colon Rectum* 2012;55(9):925–31. doi:10.1097/DCR.0b013e31825f3092.
- KONDO W, BOURDEL N, TAMBURRO S, CAVOLI D, JARDON K, RABISCHONG B et al. Complications after surgery for deeply infiltrating pelvic endometriosis. *BJOG* 2011;118(3):292–8. doi:10.1111/j.1471-0528.2010.02774.x.
- KONINCKX PR, MARTIN D. Treatment of deeply infiltrating endometriosis. *Curr Opin Obstet Gynecol* 1994;6(3):231–41.
- KONINCKX PR, USSIA A, ADAMYAN L, WATTIEZ A, DONNEZ J. Deep endometriosis: definition, diagnosis, and treatment. *Fertil Steril* 2012;98(3):564–71. doi:10.1016/j.fertnstert.2012.07.1061.
- MABROUK M, SPAGNOLO E, RAIMONDO D, D'ERRICO A, CAPRARA G, MALVI D et al. Segmental bowel resection for colorectal endometriosis: is there a correlation between histological pattern and clinical outcomes? *Hum Reprod* 2012;27(5):1314–9. doi:10.1093/humrep/des048.
- MANSKI D. Ureteroureterostomy: End-to-End Anastomosis of the Ureter. 2015; Available from: Available at: <http://www.urology-textbook.com/ureteroureterostomy.html>. Accessed January 24, 2016.
- MECHSNER S. Lymphatische Ausbreitungswege der Endometriose. *Gyn.* 2013;18(6):444–8.
- MEULEMAN C, TOMASSETTI C, D'HOOGHE TM. Clinical outcome after laparoscopic radical excision of endometriosis and laparoscopic segmental bowel resection. *Curr Opin Obstet Gynecol* 2012;24(4):245–52. doi:10.1097/GCO.0b013e3283556285.
- MEULEMAN C, TOMASSETTI C, D'HOORE A, BUYENS A, VAN CLEYNENBREUGEL B, FIEUWS S et al. Clinical outcome after CO(2) laser laparoscopic radical excision of endometriosis with colorectal wall invasion combined with laparoscopic segmental bowel resection and reanastomosis. *Hum Reprod* 2011;26(9):2336–43. doi:10.1093/humrep/der231.
- MEULEMAN C, TOMASSETTI C, D'HOORE A, VAN CLEYNENBREUGEL B, PENNINGCKX F, VERGOTE I et al. Surgical treatment of deeply infiltrating endometriosis with colorectal involvement. *Hum Reprod Update* 2011;17(3):311–26. doi:10.1093/humupd/dmq057.



30. MEULEMAN C, TOMASSETTI C, WOLTHUIS A, VAN CLEYNENBREUGEL B, LAENEN A, PENNINGCKX F et al. Clinical outcome after radical excision of moderate-severe endometriosis with or without bowel resection and reanastomosis: a prospective cohort study. *Ann Surg* 2014;259(3):522–31. doi:10.1097/SLA.0b013e31828dfc5c.
31. NEZHAT C, HAJHOSSEINI B, KING LP. Laparoscopic management of bowel endometriosis: predictors of severe disease and recurrence. *JSLs* 2011;15(4):431–8. doi:10.4293/108680811X13176785203752.
32. NEZHAT C, NEZHAT F. Protocols and Best Practices for Treating Diaphragmatic Endometriosis; Available from: Available at: [http://www.nezhat.org/file/Diaphragmatic\\_Endometriosis\\_Article.pdf](http://www.nezhat.org/file/Diaphragmatic_Endometriosis_Article.pdf). Accessed January 24, 2016.
33. OMRANIPOUR R, NAJAFI M. Papillary serous carcinoma arising in abdominal wall endometriosis treated with neoadjuvant chemotherapy and surgery. *Fertil Steril* 2010;93(4):1347.e17–8. doi:10.1016/j.fertnstert.2009.09.065.
34. POSSOVER M. Pathophysiologic explanation for bladder retention in patients after laparoscopic surgery for deeply infiltrating rectovaginal and/or parametric endometriosis. *Fertil Steril* 2014;101(3):754–8. doi:10.1016/j.fertnstert.2013.12.019.
35. REDWINE DB. Diaphragmatic endometriosis: diagnosis, surgical management, and long-term results of treatment. *Fertil Steril* 2002;77(2):288–96.
36. RENNER S, BURGHUIS S, WIMBERGER P, FEHM T, HEPP P, LEFFERN I VON et al. Veranstaltungsbericht. Operative Verfahren bei Patientinnen mit Endometriose – Ergebnisse eines Expertenworkshops. *Geburtshilfe Frauenheilkd* 2015;75(05):417–8. doi:10.1055/s-0035-1546033.
37. RUFFO G, SCOPELLITI F, MANZONI A, SARTORI A, ROSSINI R, CECCARONI M et al. Long-term outcome after laparoscopic bowel resections for deep infiltrating endometriosis: a single-center experience after 900 cases. *Biomed Res Int* 2014;2014:463058. doi:10.1155/2014/463058.
38. STEPNIEWSKA A, POMINI P, BRUNI F, MEREU L, RUFFO G, CECCARONI M et al. Laparoscopic treatment of bowel endometriosis in infertile women. *Hum Reprod* 2009;24(7):1619–25. doi:10.1093/humrep/dep083.
39. VAN DEN BROECK U, MEULEMAN C, TOMASSETTI C, D'HOORE A, WOLTHUIS A, VAN CLEYNENBREUGEL B et al. Effect of laparoscopic surgery for moderate and severe endometriosis on depression, relationship satisfaction and sexual functioning: comparison of patients with and without bowel resection. *Hum Reprod* 2013;28(9):2389–97. doi:10.1093/humrep/det260.
40. ZUPI E, LAZZERI L, CENTINI G. Deep endometriosis: Less is better. *JE* 2015;7(1):1–2. doi:10.5301/je.5000206.

## 3.5

## Uterine Adenomyosis

Ibrahim Alkatout<sup>a</sup>

## 3.5.1 Introduction

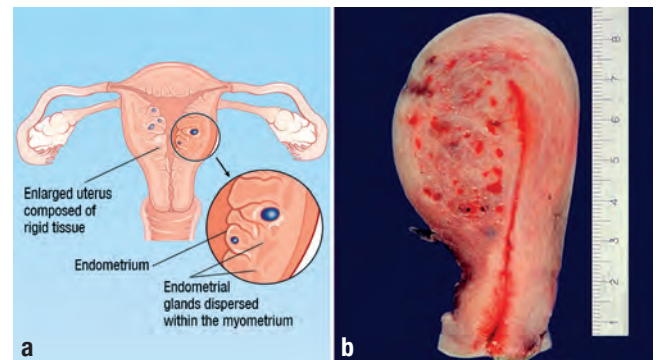
Endometriosis, the second most common benign genital disease in women after uterine myoma, has been defined as the presence of endometrial glands and stroma outside the epithelial lining of the uterine cavity. Possible signs and symptoms include chronic pelvic pain, dysmenorrhea, deep dyspareunia, cyclical bowel or bladder symptoms (such as dyschezia, bloating, constipation, rectal bleeding, diarrhea, and hematuria), subfertility, abnormal menstrual bleeding, chronic fatigue, and low back pain. The nonspecific symptoms are determined by the highly complex nature and location of pathology as well as the patient's individual response to the disease. All classifications proposed to date are limited in terms of their predictive value.<sup>41</sup>

A definitive diagnosis of endometriosis is established in approximately 50% of teenagers and 32% of women of reproductive age undergoing surgical treatment for chronic pelvic pain or dysmenorrhea. The percentage of women treated for endometriosis-associated infertility ranges from 9% to 50%. The exact prevalence of endometriosis in the overall female population is unknown because the associated symptoms are variable and nonspecific.<sup>31,52</sup>

The delay between the onset of nonspecific symptoms and the definitive diagnosis of endometriosis is approximately 7 years. An initial diagnosis is most commonly made in women 20–40 years of age. In cases of secondary infertility, the incidence rises in proportion to the time elapsed since the last pregnancy: less than 5 years: 7%; 5–10 years: 19%; and more than 10 years: 26%.<sup>20</sup>

Because the pathogenesis of endometriosis is unclear, causal treatment is not yet feasible. Current treatment options include expectant management, analgesia, hormone therapy, surgical intervention, and a combination of medical treatment and surgery. Since it has been shown that the growth of endometriosis is promoted by estrogen, the condition is amenable to various medical therapies.<sup>28,35</sup>

Uterine adenomyosis is distinguished from endometriosis in that the former is marked by the presence of endometrial glands and stroma within the myometrium. The spread of endometrial tissue induces hypertrophy and hyperplasia of the surrounding tissue leading to an enlarged uterus, that may have a soft or rigid consistency. Adenomyosis can be positively identified by the use of various imaging modalities. Nevertheless, focal adenomyosis may easily be mistaken for a leiomyoma (Figs. 3.44–3.48).



**Fig. 3.44** Diagrammatic representation of adenomyosis in an enlarged uterus (a). Endometrial glands are dispersed within the myometrium. Sagittal section of an anatomic specimen (b). The uterine wall is much thicker posteriorly than anteriorly, with endometrial glands distributed diffusely within the wall of the myometrium.

<sup>a</sup> Associate Professor, MD, PhD, MA; Department of Obstetrics and Gynecology, Head of the Kiel School of Gynecological Endoscopy, University Hospitals of Schleswig-Holstein, Kiel Campus Kiel, Germany

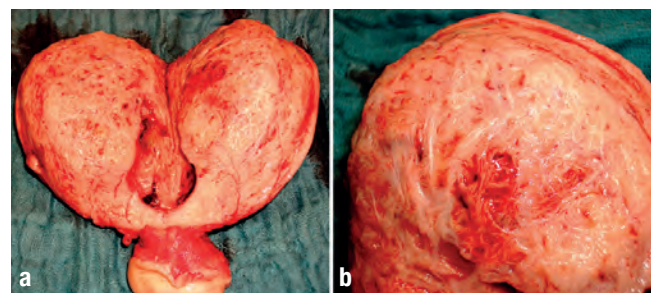
## Corresponding author:

Priv.-Doz. Dr. med. **Ibrahim Alkatout**, Oberarzt, Klinik für Gynäkologie und Geburtshilfe, Leiter der Kiel School of Gynaecological Endoscopy, Universitätsklinikum Schleswig-Holstein, Campus Kiel, Klinik für Gynäkologie und Geburtshilfe

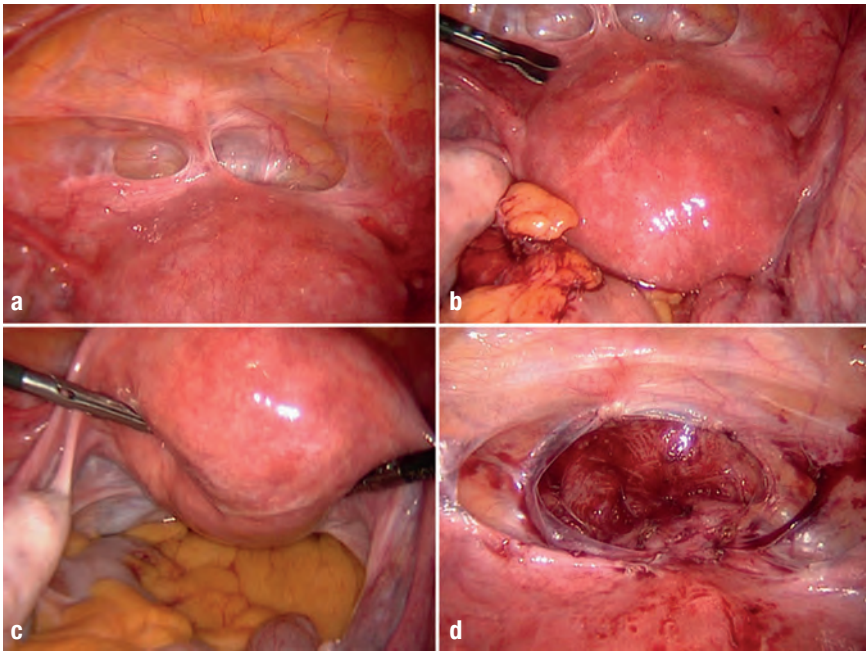
Arnold-Heller-Strasse 3/Haus 24, 24105 Kiel, Germany

E-mail: [ibrahim.alkatout@uksh.de](mailto:ibrahim.alkatout@uksh.de)

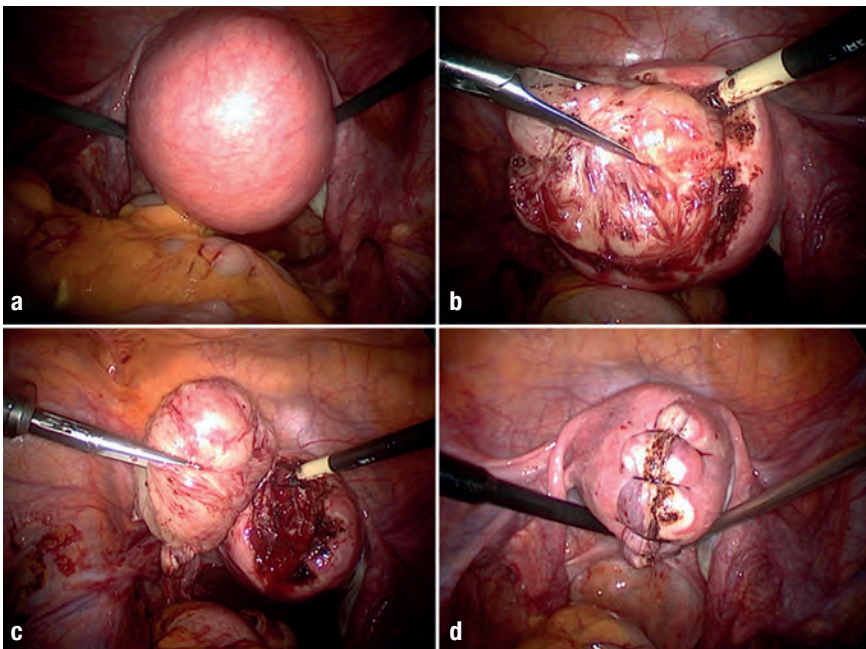
[kiel.school@uksh.de](mailto:kiel.school@uksh.de)



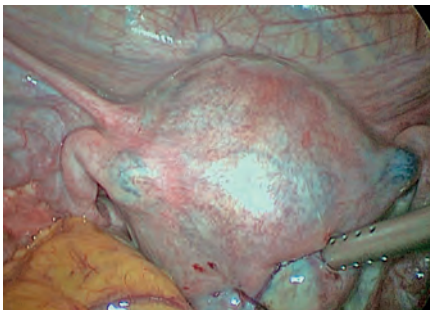**Fig. 3.45** Sagittal section of a pathology specimen (a). Magnification of panel (a) shows small islands of endometriosis infiltrating deeply into the myometrium (b).



**Fig. 3.46** Laparoscopic view in a patient with severe dysmenorrhea (a). The uterus is enlarged and soft (a–c). The anterior wall is fixed to the bladder peritoneum by multiple adhesions. After the completion of adhesiolysis (d), it appears that adenomyosis has penetrated the uterine wall and invaded the neighboring bladder.



**Fig. 3.47** Transmyometrial myoma (a) causing uterine enlargement. Treatment by laparoscopic enucleation of the myoma and reconstruction of the uterine wall (b–d). The uterine myometrium still appears dense and hypervascular. Clinically, adenomyosis may have a soft or tense, rigid consistency.



**Fig. 3.48** Same patient as in Fig. 3.47 after chromoperturbation. Blue dye injection defines the intramural vessels, which appear greatly increased. This also is a macroscopic feature of uterine adenomyosis.



### 3.5.2 Epidemiology and Pathology

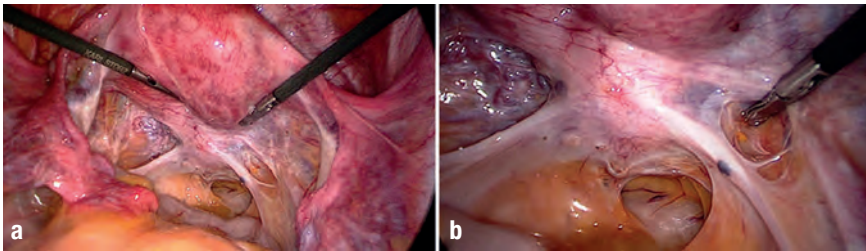
The estimated prevalence of adenomyosis in the general female population is approximately 20%. Data published to date are widely divergent, however (from 5% to 70%). In the majority of cases, a definitive diagnosis is established by histopathology workup of the hysterectomy specimen. In terms of epidemiology, our understanding of adenomyosis is limited by the fact that it tends to coexist with endometriosis and/or uterine fibroids. In some reviews, the histopathology findings in hysterectomy specimens are suggestive of adenomyosis, independent of symptoms, and independent of the reason for performing surgery. In other studies, women with adenomyosis were compared statistically with those suffering from endometriosis and were found to have higher parity, earlier menarche, and shorter menstrual cycles. On the other hand, there is no proof that women of higher parity are at increased risk for developing adenomyosis.<sup>57</sup> Another study found out that women with adenomyosis are more likely to suffer from dysmenorrhea, pelvic pain and depression, and their medical history shows a higher number of prior surgical procedures.<sup>55</sup>

Uterine adenomyosis is an estrogen-dependent disease. The endometrial-myometrial interface, also named uterine junctional zone, is very likely **involved** in the disease as an anatomical and functional entity.<sup>22</sup>

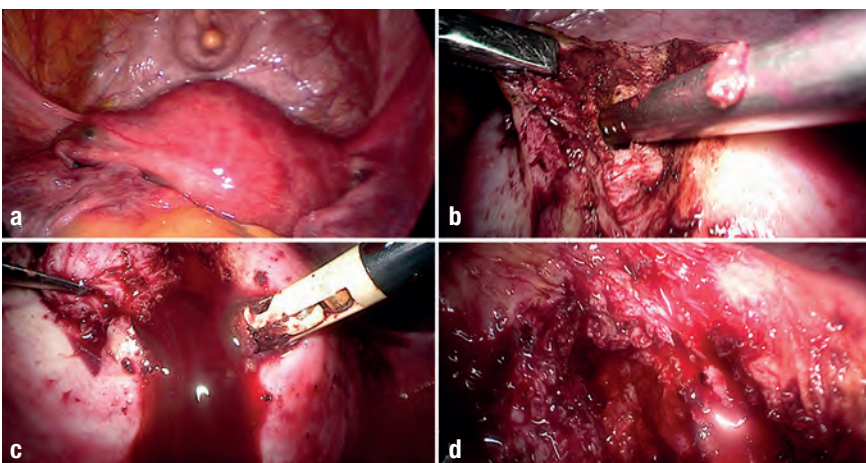
The pathogenesis of adenomyosis is similar to that of endometriosis. Three theories of pathogenesis have been proposed:

- Adenomyosis de novo is induced by metaplastic transformation of embryologic pluripotent Müllerian remnants.
- Adenomyosis develops by invagination of the basal endometrium into the myometrium through an altered or absent junctional zone.
- Adenomyosis is a consequence of tissue injury and repair, stimulated by hypersecretion of estrogen.<sup>22</sup>

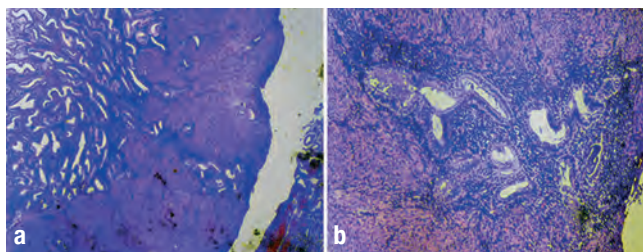
Adenomyosis may show a diffuse distribution pattern within the myometrium or may present as a focal nodule or adenomyoma. The pathology specimen may contain chocolate-colored areas that represent islands of endometriosis. Adenomyomas are difficult to distinguish from leiomyomas by clinical examination. They lack a distinct cleavage plane and cannot be excised as easily as fibroids. Closure of the uterine wall is made difficult by the fragile and unstable myometrium, and therefore suturing can be technically challenging. Adenomyosis is frequently accompanied by endometriosis (Figs. 3.49–3.50).



**Fig. 3.49** Patient with severe endometriosis and multiple signs of external genital endometriosis (a, b). Ultrasound suggested the presence of fibroid disease.



**Fig. 3.50** Same patient as in Fig 3.48. Asymmetry of the uterus suggests endometriosis of the left fallopian tube and a central space-occupying lesion (a). The central intramural lesion suspected of being a fibroid, is incised (b). Chocolate-like fluid oozes from the surgical opening in the adenomyoma (c). The middle layers of the endometrial wall are visible in the magnified view (d).

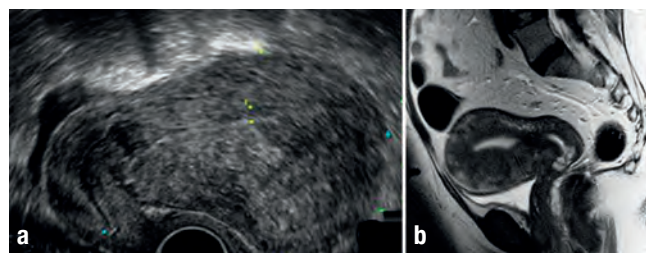


**Fig. 3.51** Low-magnification view of an endometrial tissue fragment obtained by ablation. The surrounding myometrial tissue is in the early secretory phase (a). Islets of endometrial glands are embedded in myometrial stroma and do not communicate with the uterine cavity (b). Note, that there are clear signs of endometrial involvement in the endocrine cycle. (Courtesy of Professor *Martin Anlauf*, Institute of Pathology and Cytology, Limburg, Germany).

On microscopic examination, multiple islands of endometriosis are dispersed within the myometrium without being clearly connected to the endometrium. Usually a zone of myometrial hypertrophy and hyperplasia surrounds the adenomatous tissue. The spread of endometrial tissue occurs in response to fluctuations of estrogen and progesterone levels during the menstrual cycle (Fig. 3.51).

### 3.5.3 Clinical Manifestations and Diagnosis

The principal symptoms of uterine adenomyosis are severe dysmenorrhea (25 %) and heavy menstrual bleeding (60 %). Chronic pelvic pain may also be present, as in endometriosis. Many of these symptoms may be absent before 40 or 50 years of age. One third of women tend to be asymptomatic. The impact of adenomyosis on infertility is still controversial



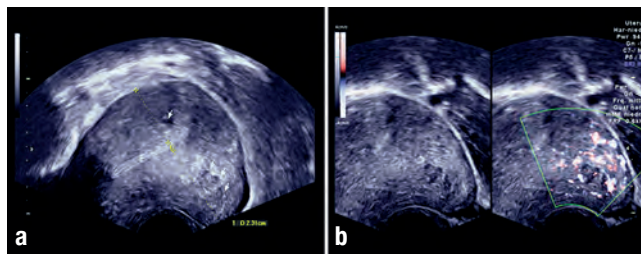
**Fig. 3.52** The anterior wall has irregular contours and a heterogeneous appearance at ultrasound (a). The wall is thickened, and the affected area is poorly circumscribed. Note that focal adenomyosis can easily be mistaken for a myoma. MRI confirms the clinical diagnosis of adenomyosis (b). The T2-weighted image shows irregular vasculature, which is an important differentiating feature from myoma (Courtesy of Dr. *Werner Dürr*, Nürtingen, Germany).

because most women diagnosed with adenomyosis have coexisting leiomyomas, endometriosis, and endometrial polyps.

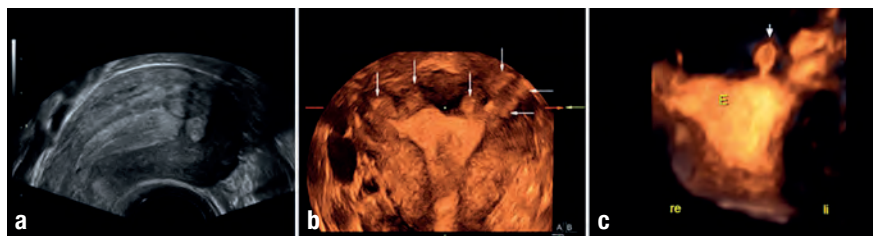
Histologic examination of a hysterectomy specimen is the key to establishing a definitive diagnosis of adenomyosis and instituting causal treatment. The preoperative diagnostic workup is based on the patient's medical history (menorrhagia, dysmenorrhea, dyspareunia), bimanual examination, transvaginal ultrasound, and MRI (especially T2-weighted scans). In a meta-analysis of 23 articles, the sensitivity and specificity of MRI in detecting adenomyosis were found to be 77 % and 89 %, respectively, as compared with 72 % and 81 % for ultrasound (Figs. 3.52–3.54).<sup>8</sup> Visible signs of adenomyosis include the following features:

- Asymmetrical myometrial thickening noticeable between the anterior and posterior uterine wall (most extensive in the posterior wall).
- Intramyometrial cysts.
- Linear striations extending from the endometrium.
- Loss of a clear endomyometrial junction.
- Greater myometrial heterogeneity.<sup>16,45</sup>

Dysmenorrhea is a major clue from the medical history that suggests adenomyosis. The specific etiology of dysmenorrhea must be established. Possible causes of secondary dysmenorrhea are listed in Table 3.5.



**Fig. 3.53** Ultrasound scans in a different patient show cystic structures surrounded by an echogenic endometrium-like rim (a). Color Doppler shows very pronounced and diffuse neovascularity in the cystic area consistent with the incipient progression of adenomyosis (b). Striated shadows are suggestive of an old inactive process, while cystic lesions are a more recent manifestation of adenomyosis (Courtesy of Dr. *Werner Dürr*, Nürtingen, Germany).



**Fig. 3.54** Ultrasound in this patient reveals focal, somewhat homogeneous intramural areas (a). The area of adenomyosis shows a pronounced, irregular vascular pattern that contrasts with the more regular pattern of preexisting vessels, demonstrable only by 3D and power Doppler ultrasound (b, c). (Courtesy of Dr. *Werner Dürr*, Nürtingen, Germany).



Differential Diagnosis of Adenomyosis	
Differential diagnosis	<ul style="list-style-type: none"> <li>■ Pregnancy</li> <li>■ Polyps</li> <li>■ Submucosal myoma</li> <li>■ Endometrial hyperplasia</li> <li>■ Synechiae</li> <li>■ Adenocarcinoma</li> <li>■ Infection (endometritis)</li> </ul>

**Table 3.4** Differential diagnosis of uterine adenomyosis.

Causes of Secondary Dysmenorrhea	
Gynecologic causes	<ul style="list-style-type: none"> <li>■ Endometriosis</li> <li>■ Adenomyosis</li> <li>■ Fibroids</li> <li>■ Ovarian cysts</li> <li>■ Intrauterine or pelvic adhesions</li> <li>■ Chronic pelvic inflammatory disease</li> <li>■ Obstructive endometrial polyps</li> <li>■ Congenital obstructive Müllerian anomalies</li> <li>■ Cervical stenosis</li> <li>■ Use of a contraceptive intrauterine device</li> <li>■ Pelvic congestion syndrome</li> </ul>
Nongynecologic causes	<ul style="list-style-type: none"> <li>■ Inflammatory bowel disease</li> <li>■ Irritable bowel syndrome</li> <li>■ Ureteropelvic junction obstruction</li> <li>■ Psychogenic disorders</li> </ul>

**Table 3.5** Causes of secondary dysmenorrhea.

### 3.5.4 Adenomyosis and Infertility

General endometriosis is associated with infertility, which is amenable to treatment by medical therapy, surgery, or a combination of both. Surgical treatment has been shown to improve the chances for natural conception.

It has been postulated that adenomyosis compromises fertility by impairing sperm transport and causing hyperperistaltic or dysperistaltic uterotubal transport. The eutopic and heterotopic endometrium of adenomyosis patients may undergo biochemical and functional alterations, leading to poor receptivity. The high spontaneous abortion rate is believed to

be due to a dysfunctional junction zone. Adenomyosis has also been identified as a risk factor contributing to failure of in vitro fertilization (IVF) and intracytoplasmic sperm injection (ICSI). Lower rates of clinical pregnancy and implantation as well as higher rates of early pregnancy loss have been reported. The ‘long protocol’ of downregulation appears to have a protective effect (Figs. 3.55a, b, adapted from *Vercellini et al.*, 2014).<sup>12,62</sup>

#### 3.5.4.1 Treatment Options

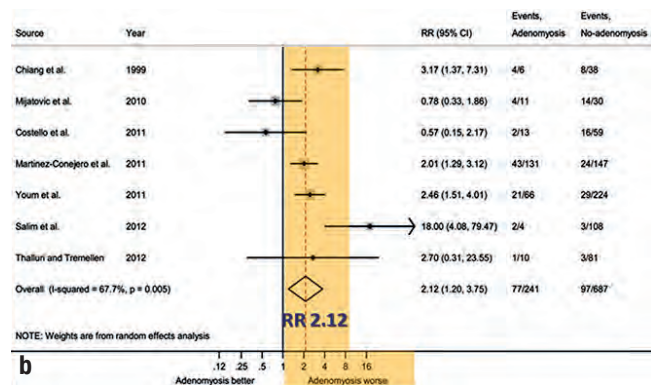
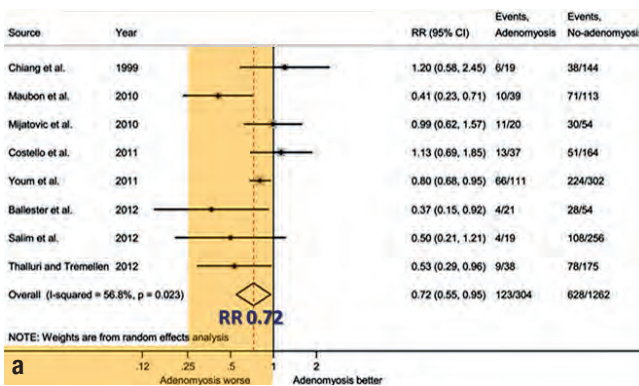
The causal treatment of adenomyosis has proven to be a challenge. Conservative medical therapy is identical to that used for endometriosis. Many patients have coexisting uterine adenomyosis and endometriosis.<sup>4</sup>

The general management strategy for endometriosis consists of a combined approach that includes concurrent treatment for uterine adenomyosis.

Because pathogenesis of endometriosis is not yet fully understood, there is no curative treatment other than hysterectomy. Current treatment options are as follows:

- Expectant management
- Analgesia
- Hormonal medical therapy
- Surgery
- Combination of medical treatment and surgery.

Available therapeutic procedures can be divided into three groups: medical, surgical, and combined. The finding that the growth of endometriosis is estrogen-responsive has led to a variety of medical therapies.<sup>28,35,43</sup> The first well-structured treatment regimen was introduced by *Mettler and Semm*. It involves diagnostic laparoscopy, removal of all detectable foci of endometriosis to the extent feasible, 3 to 6 months of endocrine therapy, and subsequent second-look laparoscopy with resection of residual foci, removal of adhesions, and reconstruction of organs. In patients with an explicit desire to preserve fertility, the gynecologist is advised to use assisted reproductive technology (ART).<sup>47</sup>



**Fig. 3.55a,b** Forest plot showing individual and combined effect size estimates and 95% confidence intervals (CI) in studies analyzing the likelihood of clinical pregnancy in infertile women with or without adenomyosis undergoing IVF/ICSI. Horizontal lines indicate 95% CI, boxes indicate study-specific weight, the diamond represents the combined effect size, and the dashed line indicates the overall estimate (a). Forest plot showing individual and combined effect size estimates and 95% confidence intervals (CI) in studies analyzing the risk of miscarriage in clinical pregnancies achieved after IVF/ICSI in women with or without adenomyosis. Horizontal lines indicate 95% CI, boxes indicate study-specific weight, the diamond represents the combined effect size, and the dashed line indicates the overall estimate (b).



**Medical treatment:** In the past, the mainstay strategy consisted of inducing a state of pseudopregnancy, the administration of progestins and, more recently, the use of danazol and GnRH analogs.<sup>28</sup> This approach was long considered the gold standard, but has now been supplemented by add-back therapy with a synthetic progestin (Dienogest).<sup>67</sup> A serum estradiol level of approximately 60 pg/mL is needed to prevent side effects from the GnRH agonist such as bone demineralization, vasomotor symptoms and mood swings.<sup>19,28,64,67</sup> Levonogestrel-releasing IUDs may be effective in reducing menorrhagia and dysmenorrhea, although there is evidence that symptoms recur within 6 months after this type of medical treatment is withdrawn.<sup>51</sup>

**Targeted treatment:** Research has focused on inhibiting the interaction of various mediating substances that maintain the disease through inflammatory processes, vascularization and cell proliferation. Specific aromatase inhibitors (such as letrozole, anastrozole or exemestane) or selective COX-2 inhibitors (such as celecoxib or rofecoxib) are of major interest and have been investigated in clinical trials.<sup>5,21,38</sup> We still lack conclusive evidence that one medical treatment is superior to any other in resolving clinical symptoms of endometriosis or infertility.

**Surgical treatment:** Considering that endometriosis – often indistinguishable from adenomyosis before surgery – runs a progressive course and can ultimately compromise or disrupt integrity of reproductive organs, surgical treatment has a major role in the management of the disease. Laparoscopy is the sole means by which a clinical diagnosis can be made to confirm or exclude endometriosis with or without associated adenomyosis. Endometriosis has a variable phenotype and may present as elevated flame-like patches, whitish opacifications, yellowish-brown discolorations, translucent blebs, or reddish spots of irregular shape.<sup>17,31</sup> In advanced stages, pain and sterility are caused predominantly by organ damage, fibrosis and adhesions, thus providing a clear indication for surgical treatment. Early laparoscopy can be helpful in the timely detection of disease and offers the benefit of delaying symptom progression. The value of a combined approach – consisting of laparoscopic assessment, biopsy sampling and/or resection – is underscored by the fact that visual evaluation alone is a potential source of error. However, the laparoscopic or hysteroscopic extraction of endometrial/myometrial ‘chips’ has been abandoned because the potential benefit from this method does not justify the associated tissue trauma.<sup>54,65</sup> Among the potential risk factors and disadvantages inherent in laparoscopy are damage to adjacent organs, and postoperative complications such as adhesion formation or infection. Similar caveats apply to hysteroscopy, which is fraught with the risks of iatrogenic perforation, intraabdominal seeding of endometrial tissue (implantation hypothesis), scar formation, and secondary adhesions.<sup>9,14,16,36,43</sup> Symptom relief can be achieved in most patients after successful ablation/resection of endometriosis and adhesiolysis, but a recurrence rate as high as 40% has been documented after 10-year follow-up.<sup>1,26,30,36</sup>

**Combined treatment:** This strategy involves a combination of diagnostic laparoscopy, the removal of all visible endometriotic

foci to the extent feasible, 3 to 6 months of endocrine therapy, and subsequent second-look laparoscopy with the resection of residual foci, adhesiolysis and organ reconstruction. In patients suffering from endometriosis and/or adenomyosis of the uterus, who wish to conceive, the gynecologist employs downregulation with GnRH-agonists and subsequent stimulation over a long-time period in conjunction with in-vitro fertilization.<sup>6,18,26,30,56,66</sup>

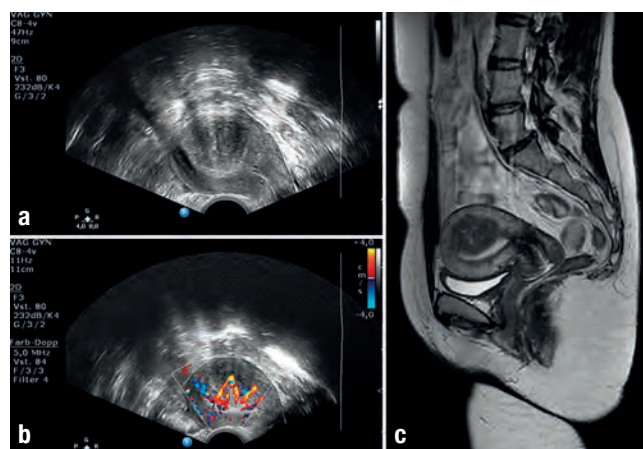
#### 3.5.4.2 Surgical Treatment of Uterine Adenomyosis

The primary advantage of endoscopic treatment for uterine adenomyosis is that it allows intraabdominal comorbidity such as endometriosis, severe adenomyosis of adjacent organs (sacroterine ligaments, cardinal ligament, bladder and/or bowel), and adhesions to be managed in the same session. Even though uterus-preserving surgical strategies are still a matter of lively debate and considering that the outcomes are not consistently promising, the only conclusive treatment option currently available for adenomyosis is total hysterectomy. Since the disease is confined to the uterus, the ovaries can be preserved.

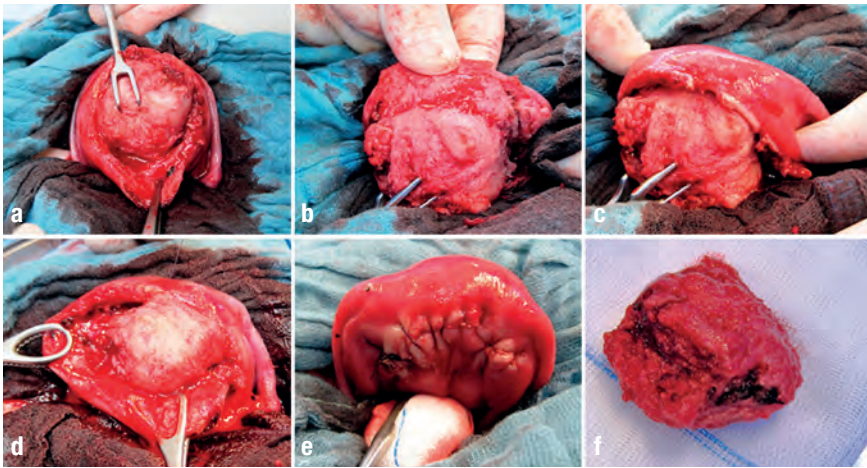
##### ■ Organ-Preserving Surgical Management of Uterine Adenomyosis

The inherent drawback of organ-preserving surgery for severe adenomyosis is lack of a clear demarcation line between normal and affected tissue. The myometrial wound defect that requires surgical repair is vulnerable and fragile in consistency, which is why the resulting tensile strength of the reconstructed uterine wall is low. Many techniques have been devised for this purpose. The triple-flap technique of Osada has received greatest attention.<sup>42</sup> Compared with medical therapy, surgical treatment has been reported to provide symptom relief while also having a positive effect on reproductive capacity.<sup>60</sup>

Figs. 3.56, 3.57 were obtained during the diagnostic workup of a patient with focal adenomyosis before and during surgical treatment which resulted in a successful childbirth one year after surgery.



**Fig. 3.56** Vaginal ultrasound scans (a, b) and sagittal MRI (c) of focal adenomyosis, located in the posterior uterine wall. Note the diffuse vascularization pattern revealed by the color Doppler scan (b).



**Fig. 3.57** Intraoperative views taken during organ-preserving enucleation of focal adenomyosis (a–d). The uterus is reconstructed in multiple layers (e). The specimen has a stony consistency with a pitted or porous texture (f).

#### ■ Definitive Surgical Management of Uterine Adenomyosis

Hysterectomy is among the most commonly performed surgical procedures in gynecology. Based on guidelines issued by international gynecologic societies, the transvaginal approach is the most widely accepted technique used for this purpose. In the past two decades, however, the use of endoscopic surgical techniques has grown in importance and become the first-line standard of care, preferred over traditional abdominal and vaginal hysterectomy. In hysterectomies performed for benign disease, the proportion of abdominal approaches has been declining. The rate of vaginal hysterectomies is variable, whereas the number of laparoscopic and robot-assisted laparoscopic procedures is on the rise.<sup>32</sup> This trend has become apparent on a global scale.<sup>48</sup> The inherent drawback of vaginal hysterectomy – compared with abdominal hysterectomy – is the fact that a complete removal of lesions is virtually impossible. The use of endoscopic techniques, including conventional laparoscopic and robot-assisted approaches, offers the benefit of a more complete and accurate resection of disease.

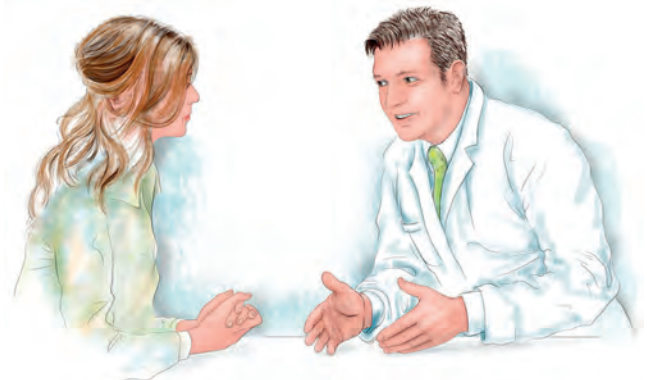At present, the indications most frequently reported for hysterectomy are uterine leiomyomas, adenomyosis, diffuse endometriosis, uterine prolapse, and refractory idiopathic bleeding. These conditions constitute up to 60 % or more of the indications for hysterectomy.<sup>33</sup> In the past decade, alternative treatment options such as uterine artery embolization and high-intensity focused ultrasound treatment have been developed in Germany<sup>53</sup> and other countries.<sup>13</sup> Conservative surgical management and the introduction of ulipristal acetate for preoperative treatment of myoma have contributed to a reduced number of hysterectomies. Hysterectomy rates are determined not only by indications, but also by age group, family planning, and the centers at which patients are treated. The range of indications and clinical protocols for implementation of hysterectomy in general have been updated. In current practice, the decision as to whether hysterectomy is the best treatment option in any given case, should be guided by the patient's desire to preserve future fertility potential.<sup>15,25</sup> Hysterectomy is also performed for malignant diseases of the internal genital organs (endometrium, cervix, ovary, fallopian tubes). Endoscopic surgery is performed only for the

treatment of endometrial and cervical cancer. The indications for hysterectomy are listed in Table 3.6.

- Uterine leiomyomas.
- Endometriosis and adenomyosis of the uterus.
- Pelvic organ prolapse.
- Pelvic pain or infection (other than endometriosis): pelvic inflammatory disease, adhesions.
- Abnormal uterine bleeding of known and unknown origin.
- Malignant and premalignant disease.

**Table 3.6** Current indications for hysterectomy.

Once the recommendation for hysterectomy has been decided upon, the physician and patient must determine whether the procedure will be conducted using an abdominal, vaginal, laparoscopic or robot-assisted approach.<sup>3,9,28</sup> Each of these options has its advantages and disadvantages, which should be weighed against one another during individual patient counseling (Fig. 3.58). The level of experience that a surgeon has gained with the particular technique and the economic resources of the hospital are additional factors that may need to be considered.<sup>39</sup>



**Fig. 3.58** The physician should communicate an attitude of empathy and respect during preoperative counseling. Efforts should be geared towards enhancing patient compliance with the anticipated treatment plan.

In many patients, conservative medical therapy or conservative surgical treatment would be tantamount to undertreatment and could result in an eventual need for reoperation.<sup>60</sup> Subtotal hysterectomy, the least invasive form of hysterectomy, is a compromise that meets the requirements of patients, doctors, and society. However, once the patient has been appropriately counseled and informed about the drawbacks associated with a retained cervix, it is imperative that informed consent be obtained and properly documented prior to surgery. Laparoscopic total hysterectomy (LTH) is the only treatment option that provides complete protection from recurrence of fibroids, eventual cervical cancer or sarcoma, spillage of cells during tissue incision or morcellation, uncontrolled menstrual bleeding, and other problems that may stem from the uterus. The persistence or recurrence of adenomyosis-related symptoms after subtotal hysterectomy is still a subject of debate.

#### ■ Total Versus Subtotal (Supracervical) Hysterectomy

Regardless of which surgical technique (subtotal or total hysterectomy) is employed, endoscopic surgery is considered the first-line treatment option currently available. Some women wish to retain a cervical stump, assuming that its removal may adversely affect sexual satisfaction. Removal of the cervix is believed to cause excessive neurologic and anatomic disruption, thereby increasing the likelihood of operative and postoperative morbidity, vaginal shortening, subsequent vault prolapse, abnormal cuff granulations, and fallopian tube prolapse. These issues were addressed in a systematic review of three randomized trials on total versus subtotal hysterectomy for benign gynecologic conditions.<sup>34</sup>

- No difference was found in the rates of incontinence, constipation or measures of sexual function (sexual satisfaction, dyspareunia).
- The duration of surgery and average blood loss during surgery were significantly lower for subtotal hysterectomy than total hysterectomy, but there was no difference in the need for transfusion.
- Febrile morbidity was less likely and ongoing cyclical vaginal bleeding one year after surgery more likely after subtotal hysterectomy.
- The rates of other complications, recovery from surgery and readmission rates did not differ.

In the short-term follow up, randomized trials have shown that preservation or removal of the cervix does not affect the rate of subsequent pelvic organ prolapse.

The anatomical and functional advantage of retaining a cervical stump lies in the fact that the cardinal and uterosacral ligaments are preserved.

The advantages of supracervical hysterectomy include shorter operating times compared with total abdominal hysterectomy, and a shorter hospital stay, provided a laparoscopic approach is used. Furthermore, women who undergo subtotal hysterectomy are able to tolerate physical stresses earlier because there is no risk of vaginal cuff dehiscence.<sup>58</sup>

Some authors have reported a shorter recovery period after subtotal hysterectomy, but randomized trials do not support this statement. In a prospective cohort study, supracervical hysterectomy was associated with greater improvement in short-term quality of life scores as compared with those of total hysterectomy, but no differences were found in postoperative pain or resumption of activities of daily living.<sup>24</sup> There may also be fewer urinary tract injuries because dissection is not carried as close to the cervix or as deep into the pelvis as in a total hysterectomy. To date, however, there have been no clinical trials designed to validate this observation.

Other differences include posthysterectomy body image and general health status. Women who had undergone subtotal versus total hysterectomy reported a significantly better body image and health-related quality of life. Both groups experienced greater sexual satisfaction.<sup>45</sup>

The only absolute contraindication to subtotal hysterectomy is a malignant or premalignant condition of the uterine corpus or cervix.

Extensive endometriosis is a relative contraindication because the patient may experience persistent dyspareunia when the cervix is retained.

To this day, the repercussions of adenomyosis have been underestimated. The uterus is morcellated in the abdomen and, unless the morcellated uterus is collected in a bag prior to extraction, adenomyosis may spread due to intraabdominal seeding. Patients may also experience persistent pain in the lower midabdomen. Laparoscopic supracervical hysterectomy (LSH) is a technique that disregards possible involvement of the cervix or the retrocervical/precervical space. Very often, the sacrouterine ligaments or the lateral cardinal ligaments leading to the ovarian fossa are also affected by disease. In these cases, adenomyosis may have penetrated the uterine wall and spread to adjacent organs, or possibly, the presence of concomitant endometriosis should be suspected. To eliminate the potential causes of symptoms as a whole, it would be advisable to remove all visible endometriosis-associated pathology. LTH, when performed correctly, is associated with very few secondary risks or side effects. Therefore, in cases of uterine adenomyosis, therefore, we recommend the LTH procedure after first explaining the situation to the patient in detail. Arguments in favor of LTH include a lower risk of urinary incontinence, prolapse, and cervical stump problems. However, subtotal hysterectomy is technically easier in most cases and appears to be associated with fewer intraoperative and postoperative complications. There is still a lack of conclusive data regarding the benefits to be derived from concurrent removal of the cervix. Very rarely, the cervix is involved by disease. This, for instance, also holds true for the risk of cervical intraepithelial neoplasia (CIN) or cervical cancer developing from the cervical stump. On the other hand, fibroids seldom occur in the cervix or deep infiltrating endometriosis can be symptomatic in the cervical region.<sup>11,23,46</sup>

Elective supracervical hysterectomy should be preceded by cervical cytology (PAP smear) to confirm the absence of cervical intraepithelial neoplasia (CIN). Patients with a medical



history of supracervical hysterectomy should be screened for cervical cancer based on standardized guidelines as determined by age and risk status. In women with abnormal uterine bleeding (especially metrorrhagia), endometrial cancer or any type of sarcoma should be excluded before proceeding with supracervical hysterectomy.

Occasionally, the cervix needs to be removed during a second-look procedure at a later time. This second-look approach has been shown to be associated with frequent iatrogenic damage to the bowel and bladder because adhesions are common and anatomical planes cannot be clearly visualized. However, the surgical approach is more widely accepted because secondary surgery has higher inherent risks than primary surgery. Patients who wish to minimize the likelihood of subsequent surgery may preferably choose a laparoscopic total hysterectomy (LTH).<sup>2</sup>

Laparoscopic total hysterectomy involves removal of the uterus and cervix. The whole procedure is performed laparoscopically. Commonly, the specimen can be retrieved through the vaginal vault. Laparoscopic-assisted vaginal hysterectomy (LAVH) has been abandoned and replaced by the endoscopic technique, which has become a standard procedure owing to the favorable learning curve for laparoscopic suturing. Given the advantages of endoscopic surgery (shorter hospital stay, faster recovery, fewer infections, better cosmetic result), it should be asked whether the risk of posthysterectomy prolapse following LSH can be reduced by preserving integrity of the supportive structures in the middle compartment of the pelvic floor or by surgical repair. In patients with preexisting defects, LTH provides suitable fixation of the pelvic floor and thus minimizes the risk of posthysterectomy prolapse. Mesh implants like those used for sacrocolpopexy may be employed in both procedures.

Our multimodal concept of laparoscopic intrafascial hysterectomy for the treatment of adenomyosis is aimed at removing all visible sites of endometriosis and reducing the risk of posthysterectomy prolapse:

- Removal of all endometriotic foci and demarcating the extent of adenomyosis.
- Intrafascial hysterectomy with preservation of existing ligaments, but opening the medial compartment when performing total laparoscopic hysterectomy.
- A technique for stable fixation of the vaginal stump.

### 3.5.5 Development of Laparoscopic Hysterectomy Techniques and Instruments

The popularity of laparoscopic hysterectomy rose gradually after the initial publication of the procedure by *Harry Reich*.<sup>37,44</sup> A number of approaches evolved, such as laparoscopic-assisted vaginal hysterectomy (LAVH), laparoscopic supracervical hysterectomy (LSH), laparoscopic total hysterectomy (LTH), and laparoscopic total intrafascial hysterectomy (LTIH). LTIH had a steep learning curve and was initially associated with rather high complication rates.<sup>13</sup> The development of new instruments and consistent training helped to improve the

situation. The introduction of the intrauterine manipulator helped to develop the classic intrafascial concept, which has now become the aim of every gynecologic surgeon performing laparoscopic total hysterectomy. It was *Michael K. Hohl*, who adopted the method of classic intrafascial hysterectomy from *Kurt Semm's* classic intrafascial supracervical hysterectomy (CISH)<sup>50</sup> and developed an advanced version based on the use of a manipulator.<sup>27</sup> Most current manipulators are widely accepted because they are easy to operate, reusable, and durable. The uterus can be moved in all directions while the long, elliptical tip of the manipulator eases out vaginal and paravaginal tissue intraabdominally. The manipulator can be pushed straight toward the surgical field, especially when cutting the uterus off the vagina with the monopolar hook, while targeting the tip of the manipulator.

The great majority of uterine manipulators are equipped with a ceramic cap that provides a flat working surface. Consequently, there is little or no need for dissection of the bladder. It should be noted that the use of the manipulator for bladder dissection is safe and effective even after a cesarean section. The working technique with the uterine manipulator imitates the classic maneuvers of an abdominal hysterectomy, allowing the ureters to be kept out of the surgical field. The cap is designed to enable intrafascial hysterectomy, which preserves the ligaments and avoids vaginal shortening. The smooth cutting edge is useful for vaginal closure.

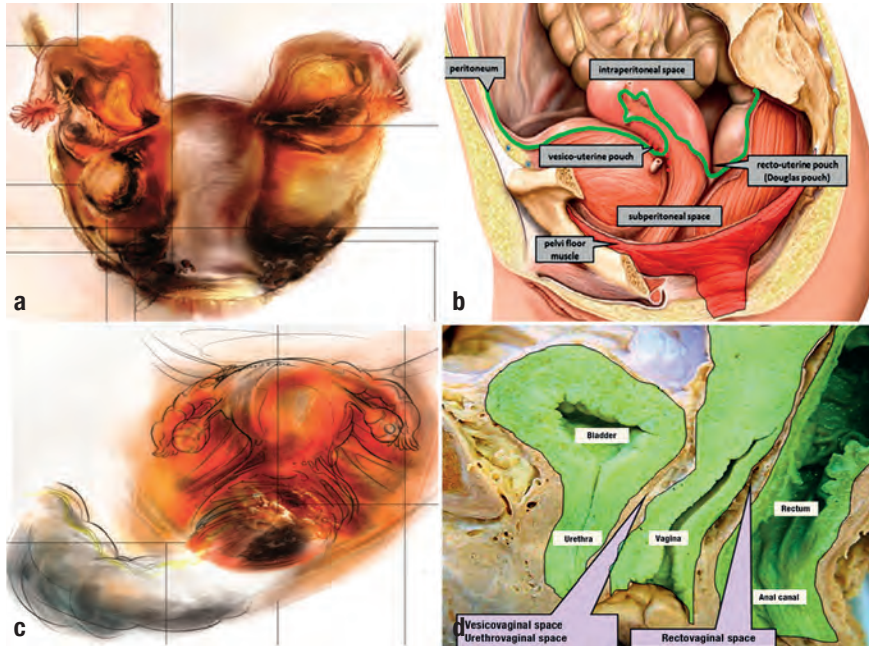
Points to be considered:

- Monopolar electricity can be used on the ceramic cap. The use of bipolar current results in a larger defect, which carries the risk of postoperative complications related to impaired wound healing and vaginal cuff dehiscence. Due care must be exercised when using ultrasound for dissection during hysterectomy because this source of energy is capable of destroying the manipulator.
- Intrafascial hysterectomy is associated with a marked reduction in the size of the vaginal opening and spares the circular ligaments. A large uterus may have to be morcellated prior to extraction. Extensive endometriosis or adenomyosis may involve the circular ligaments, which should then be removed.<sup>27</sup>

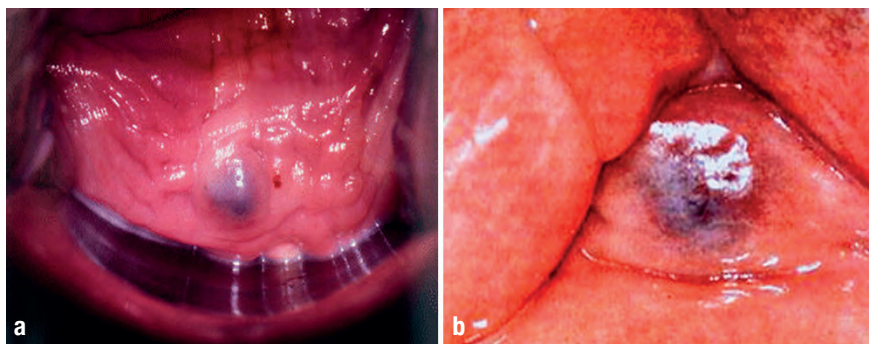
Other instruments may have a disposable or reusable product design. Disposable tissue sealing instruments are wielded more rapidly and obviate the need for frequent instrument changes. These instruments are costly, however, and provide only indistinct visual cues about anatomical details once the tissue layers have been fused. Bipolar forceps are essential. Extracorporeal sutures (1-0 PDS) are helpful, although intracorporeal sutures (Vicryl) are sufficient for vaginal closure. The monopolar hook facilitates the removal of endometriotic foci from the uterus which is held in a stable position by the manipulator. However bipolar forceps and scissors may also be used for this purpose. In the case of a large uterus, the tenaculum can be used to elevate the uterus. The use of a morcellator avoids troublesome comminution of the uterine tissue.

### 3.5.6 Preoperative Considerations and Preparations

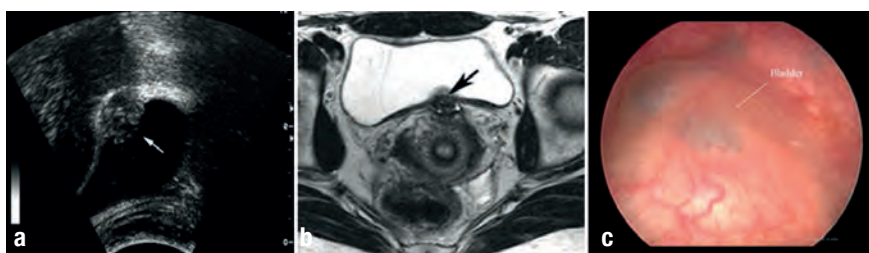
In cases where vaginal examination (Fig. 3.61) arouses suspicion of severe endometriosis (Fig. 3.60), assessment of clinical findings – obtained from ultrasound images that are correlated with the medical history – may prompt the use of additional diagnostic imaging modalities such as MRI, cystoscopy, rectoscopy or endosonography (Figs. 3.61, 3.62). Radical interdisciplinary surgery can then be planned and carried out (Figs. 3.63–3.65).



**Fig. 3.59** Schematic representation of female reproductive tract (a, c) with severe endometriosis. Relevant anatomical landmarks (b, d).

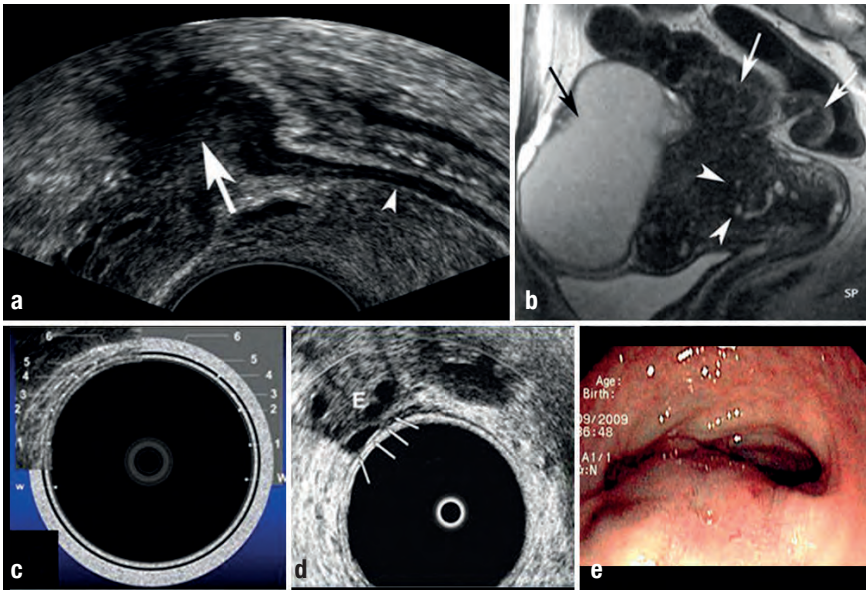


**Fig. 3.60** Vaginal macroscopic view of a small endometriotic nodule in the posterior vaginal wall (a). Vaginal involvement by severe deep infiltrating endometriosis of the vagina in another patient (b).

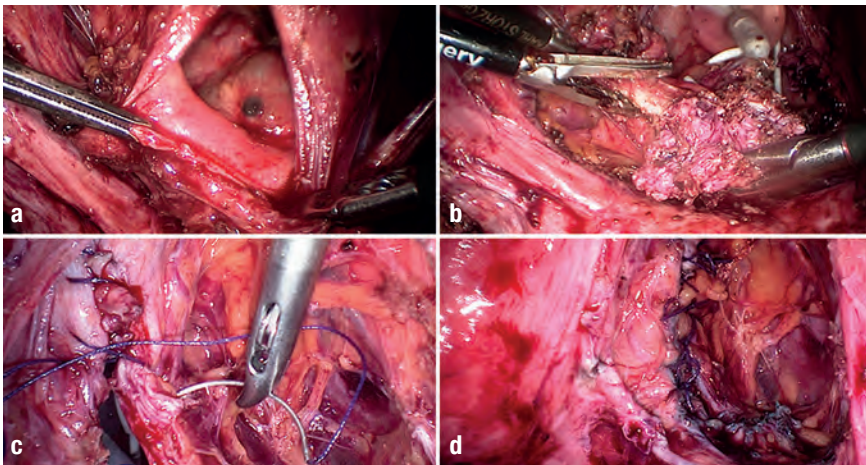


**Fig. 3.61a–c** Vaginal ultrasound scan (a) of a solitary nodule between the anterior uterine wall and the bladder (vesicovaginal space). MR image (b) and cystoscopic view (c) in the same patient.

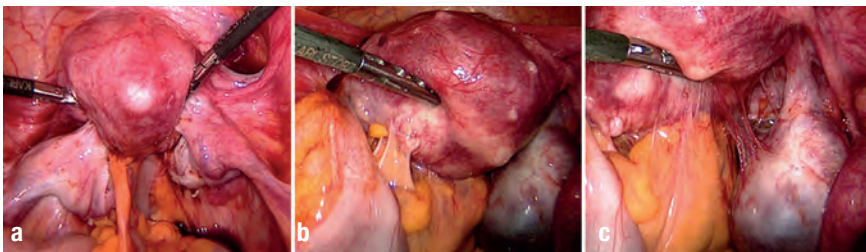




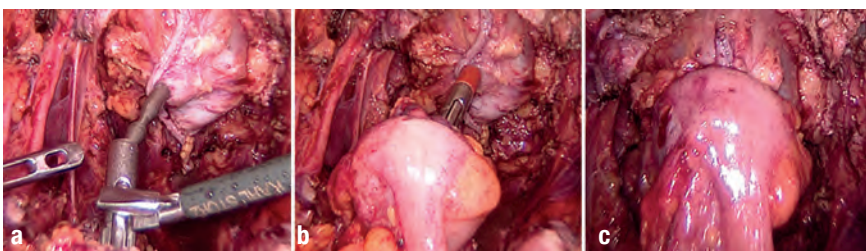**Fig. 3.62** Vaginal ultrasound scan (a) of a solitary nodule between the lower posterior wall of the uterus/cervix and the rectum (rectovaginal space). MR image (b), endosonography (c–d) and rectoscopy (e).



**Fig. 3.63** Resection of a solitary endometriotic nodule of the bladder. The bladder is opened, exposing the bladder (a). Two double-J catheters are placed in both ureters allowing the nodule (b) to be excised with an energy device. The bladder is closed in two layers (c, d).



**Fig. 3.64** Severe form of deep infiltrating endometriosis with concomitant uterine adenomyosis and involvement of the lower sigmoid colon and rectum.



**Fig. 3.65** Partial bowel resection is followed by endoscopic re-anastomosis.



A hysterectomy always requires adequate antibiotic coverage, e.g., with a second-generation cephalosporin. In cases with suspected bowel involvement, a single injection of metronidazole is also essential. The antibiotic should be administered approximately 30 minutes before the start of the operation.

The set of instruments comprises trocars, the uterine manipulator (for LTH only), needle holders and sutures. The set should also include an instrument for electrocoagulation, graspers, scissors, fenestrated forceps and a suction-irrigation unit. If a robotic surgical system is available, the set of instruments should be provided accordingly. The use of a thermofusion device with integrated knife is considered an optional extra.

### 3.5.6.1 Prerequisites

Obesity or comorbid conditions, a large uterus or multiple uterine fibroids, all of these conditions are not considered contra-indications to a laparoscopic approach. However, in these cases, any details related to the preoperative assessment and the anesthesia technique that will be applied, must be explained and discussed with the patient in advance. The trocars may need to be placed at a higher level in the abdominal wall, and more than two ancillary trocars, commonly used for the procedure, may be required. In patients with a large uterus, the need for morcellation and associated risks should be explained to the patient prior to surgery.

### 3.5.6.2 Intrafascial Hysterectomy with Preservation of Existing Structures Operative Steps of Laparoscopic Total Hysterectomy (LTH)

#### ■ Step 1

A vaginal examination under anesthesia is performed before the manipulator is used. If no additional vaginal or rectal pathology is detected, the manipulator is introduced.

#### ■ Step 2

##### Port Placement

The first step in the operation is placement of the uterine manipulator.<sup>49</sup>

The trocar sites are selected according to the size of the uterus and the size/location of fibroid elements, if present.

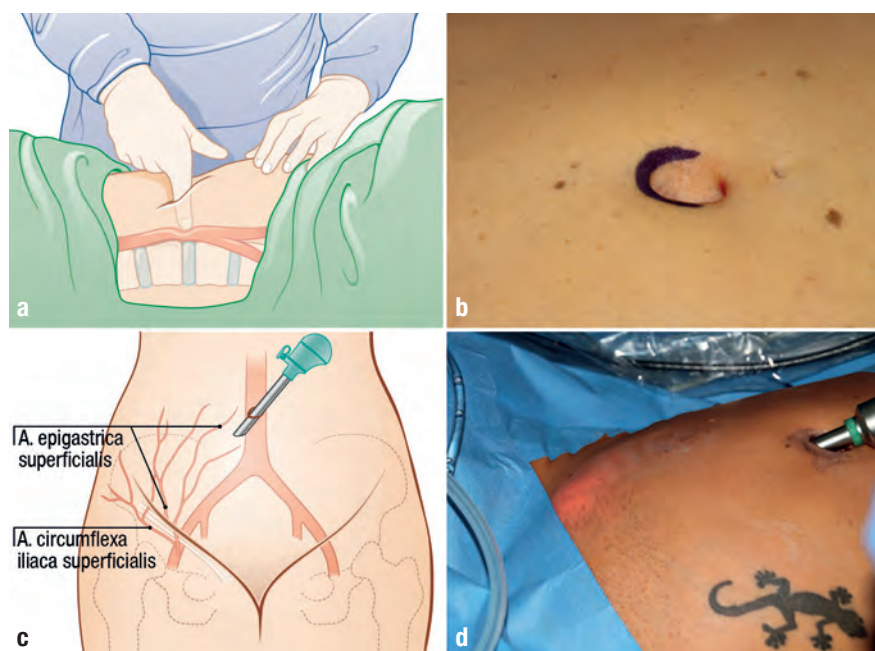
There is a multitude of entry techniques. The use of a direct entry technique under visual control has become very popular in the past few years. Nevertheless, the traditional entry technique – as described in the 1980s by *Kurt Semm* and *Liselotte Mettler* – is still used at the *Kiel School of Gynecologic Endoscopy* as shown here.

##### Optical Trocar

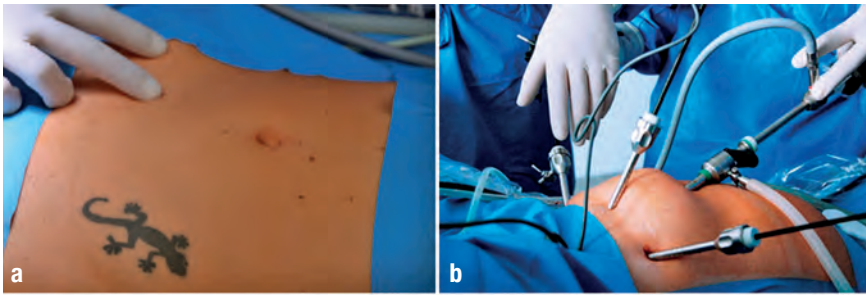
##### *Veress Needle Technique and CO<sub>2</sub> Gas Insufflation*

In order to insert the Veress needle, the operating table should be in horizontal position. The pneumoperitoneum is established, and then the table is moved to a Trendelenburg tilt. The most common site for inserting the Veress needle is the umbilical area. As the wall layers are thinnest at that level, a deep incision will afford access to the peritoneal cavity. Prior to making the initial skin incision, it is recommended to palpate the course of the aorta and identify the iliac bifurcation. This will enable inspection and palpation of the abdomen in order to detect any uncommon masses (Figs. 3.66–3.68).<sup>63</sup>

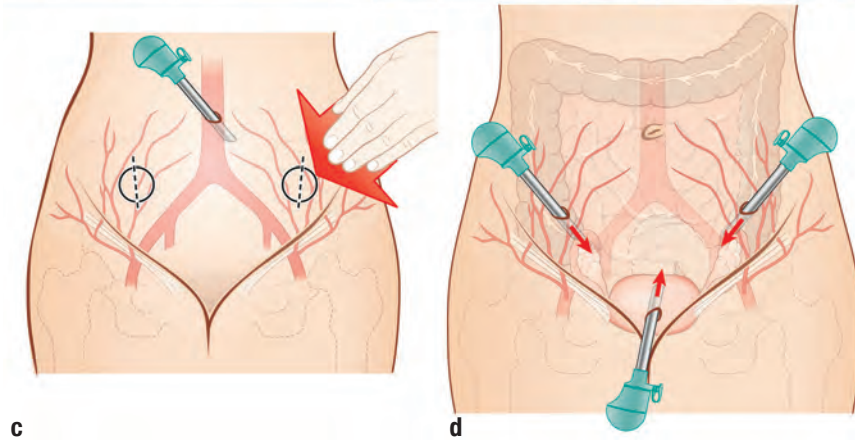
Proper function of the Veress needle must be checked to make sure that the spring-action of the safety mechanism is fully operational, and that gas flow is between 6 and 8 mmHg. Once the initial skin incision has been placed, the Veress needle is angled at 45° to the abdominal wall and advanced toward the uterus. If performed as described, the maneuver involves the least risk of iatrogenic damage to



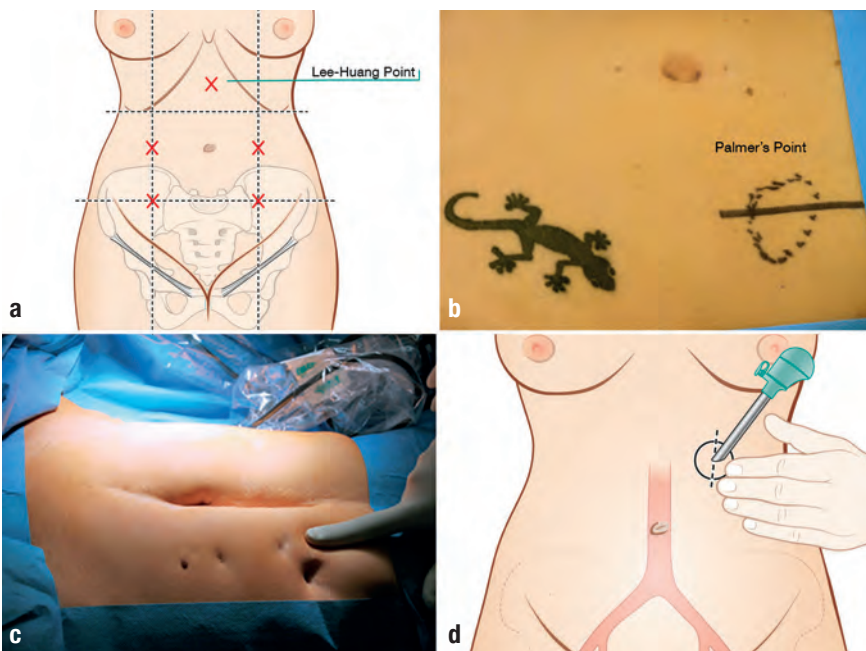
**Fig. 3.66** Typical palpation point in the subumbilical region (a). The fingertip is pointing to the sacral promontory. Subumbilical incision and local palpation demonstrate the short distance from the skin to the spine. Transillumination (b–d) can be useful to explore the anticipated area of insertion of ancillary trocars by defining the superficial epigastric artery and superficial circumflex iliac artery.



**Fig. 3.67** Point of insertion viewed from the outside (a, c) (two thumb breadths medial to the anterior superior iliac spine). The trocar is introduced at an angle of 90° to the abdominal wall plane, penetrating all layers of the wall. The site of trocar insertion is lateral to the lateral umbilical plica. Overview after placement of the laparoscope and 3 ancillary trocars (b, d).



**Fig. 3.68** Alternative entry sites. In the case of a large uterus, especially one extending to or past the umbilicus, the Lee-Huang point (a) is recommended for video-assisted laparoscopy. If adhesions are anticipated in the area of Palmer's point (c), the latter should be used (b-d). Palmer's point is located in the midclavicular line, approximately 3 cm below the costal margin.



major descending retroperitoneal vessels. The abdominal wall should be lifted before inserting the instrument. In obese patients, the insertion angle is close to 90°, whereas in thin patients, it is closer to 45°. If the first attempt fails, one repeat attempt should be made before choosing an alternative entry site. Prior to inserting the Veress needle, a few safety checks should be completed to minimize the risk of complications.

Usually, two clicks will be heard, the first one occurs when perforating the muscle fascia, and the second when perforating the peritoneum. Proper needle placement is ensured by holding the Veress needle like a pencil between the thumb and

index finger. **Aspiration test:** Following injection of 5 to 10 ml of normal saline solution, no fluid should return on reaspiration if the Veress needle has been placed correctly. Reaspiration of blood-tinged fluid, or intestinal contents suggests bowel or vascular penetration. **Hanging drop test** and **'fluid in-flow':** Once the Veress needle is inserted in the abdominal cavity, a drop of water is placed on the hub of the Veress needle, making sure that the stopcock is open. Next, the abdominal wall is elevated which results in a negative intra-abdominal pressure. If the needle is correctly positioned, the drop should flow readily downward through the lumen of the needle.

Any movement of the needle after placement of the Veress needle should be avoided, as this may convert a small needlepoint injury into a complex and hazardous tear. When correct placement of the Veress needle has been confirmed, insufflation is started. Once adequate gas flow and pressure have been achieved, the flow rate may be raised to 2 to 3 liters of CO<sub>2</sub> gas per minute until a total of 3–6 liters are insufflated, depending on the patient's body habitus and obesity. When reaching an insufflation volume of approximately 300 ml, loss of dullness to percussion over the liver region provides a reliable clue for proper positioning of the needle and allows to confirm that an adequate pneumoperitoneum has been established. Prior to insertion of the primary trocar, abdominal pressure is raised to 20–25 mmHg, which, as a result of distension, increases the distance between the abdominal wall and vulnerable intraabdominal structures (Fig. 3.69).<sup>50</sup>

The optical trocar is inserted in two steps. First, a 5-mm optical trocar and the laparoscope are inserted to make sure that the pneumoperitoneum has been established properly and to check for local adhesions. In a second step, the tract is dilated to 10 mm, either blindly or under vision, to ensure optimal visibility during the operation.

#### ■ Step 1

Entry into the abdominal cavity is obtained by employing a 'Z'-technique in the following manner: After advancing the trocar horizontally for approximately 1.5 cm, the tip is moved approximately 1.5 cm to the right at a 90° angle. The abdominal wall is lifted in the same manner as when inserting the Veress needle and, with a twisting motion of the dominant hand, the trocar is pushed through the abdominal wall at a 90° angle, aiming toward the hollow of the sacrum.

Correct placement of the trocar is indicated by a hissing sound which is produced when gas escapes through the open trocar valve. The obturator is then removed and the trocar sleeve kept in place. Before dilating to a port size of 10 mm, a 5-mm

laparoscope is introduced and rotated through 360° to visually check for any signs of bleeding, intraabdominal abnormalities and adherent bowel loops. If bowel adhesion is suspected in the umbilical region, the primary trocar site should be scrutinized by introducing a 5-mm laparoscope through a secondary port, such as the lower abdominal wall.

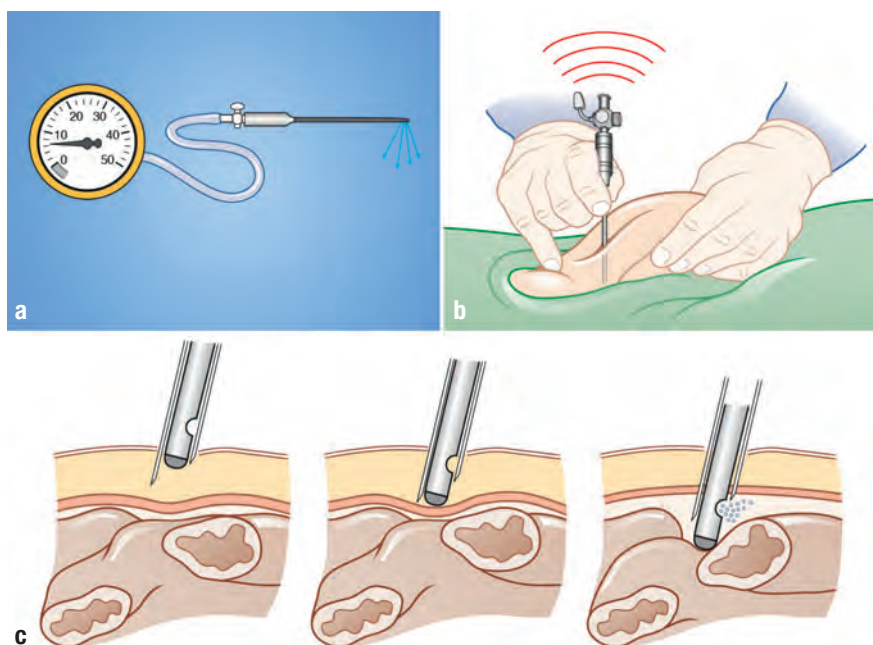
#### ■ Step 2

A blunt palpation probe is placed in the 5-mm trocar; the sleeve is withdrawn over the probe and withdrawn. Next, a 10-mm trocar is placed in the abdominal cavity by use of a twisting motion.<sup>50</sup>

#### Subcostal Insufflation Technique (Palmer's Point or Lee Huang Point)

No entry technique can entirely eliminate the risk of gas embolism or accidental injury to vessels, bowel, or the urinary tract. Palmer's point is the safest laparoscopic entry point because it is least likely to be affected by adhesions.

In 1974, *Palmer* described the use of an abdominal entry point in the midclavicular line, approximately 3 cm below the costal margin. This entry site should be considered in all patients with a significantly higher risk of adhesion formation, a history of abdominal surgery including cesarean section, a large fibroid uterus, umbilical hernia, large ovarian cysts, preperitoneal gas insufflation or failed umbilical entry. Palmer's point can be used for insertion of the Veress needle as well as for small trocars. If adhesions are suspected in the subcostal region on the left side, the Lee Huang point in the midline is a suitable alternative option (Fig. 3.69).<sup>50</sup>



**Fig. 3.69** Veress needle and its insertion. The spring-loaded safety mechanism of the needle helps prevent injury to the bowel and vessels.



### Ancillary Trocars

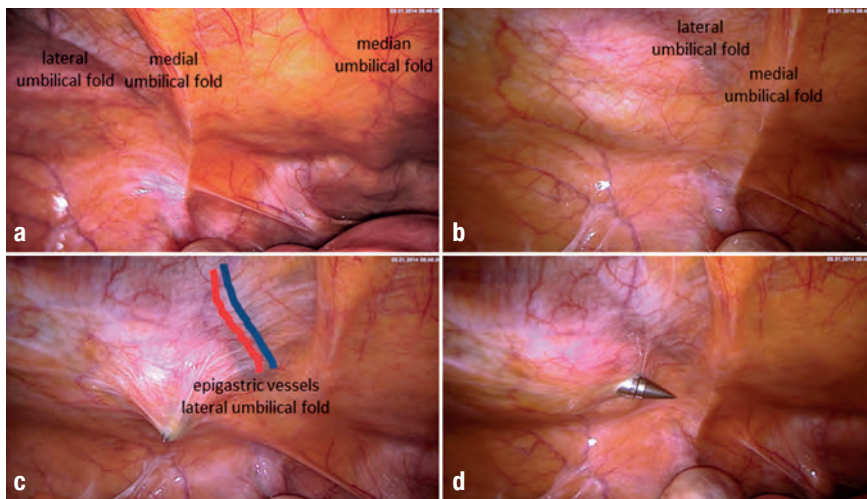
All ancillary trocars are inserted under direct vision using an intraabdominal pressure of 15–20 mmHg. The inferior epigastric vessels are visualized laparoscopically, while transillumination can be helpful to identify the superficial vessels (Figs. 3.70, 3.71).

When the trocar tip has pierced the peritoneum, it should be angled toward the uterine fundus under visual control until the port is correctly placed and the sharp tip can be removed.

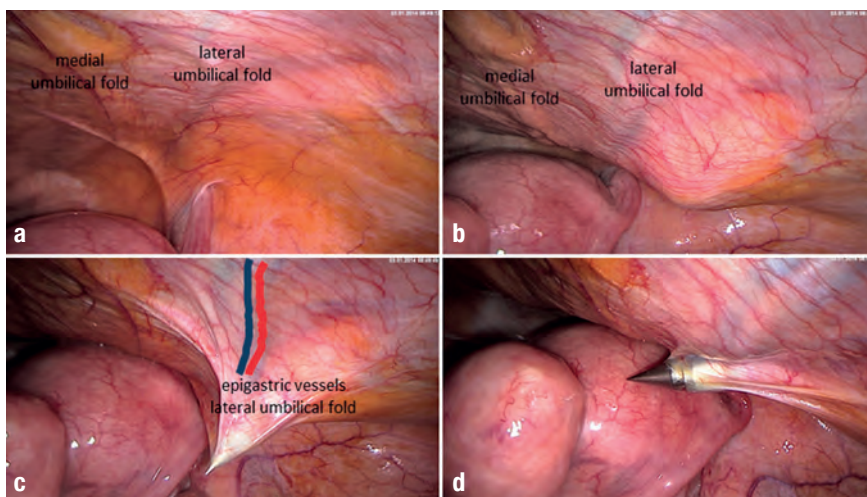
The patient is placed in Trendelenburg position before any ancillary trocars are introduced. Premature Trendelenburg positioning may increase the risk of retroperitoneal vascular injury, because the iliac vessels are exactly on-axis with the proposed insertion angle of 45°, especially in thin patients with minimal retroperitoneal fat. The number of ancillary trocars needed for a specific surgical procedure is variable, and all of them are inserted under direct visual control. If two working trocars are needed, they should be placed in

the lower quadrant above the pubic hairline lateral to the deep epigastric vessels when viewed from below. Viewed externally, the trocars are placed two finger breadths medial to the anterior superior iliac spine. Care is taken to protect two major superficial vessels – the superficial epigastric artery and the superficial circumflex iliac artery. These vessels can be visualized with the aid of transillumination. Provided a third ancillary trocar is required, a suprapubic midline port is most commonly used. Transillumination cannot be relied upon to locate deep vessels, especially in obese patients (Figs. 3.66, 3.67).

Finger-tapping on the outer abdominal wall may be used to verify correct positioning of the trocar. A small skin incision is made to facilitate trocar insertion. The trocars should be inserted along the shortest route at an angle of 90° to the skin surface in order to minimize the risk of iatrogenic injury to vital structures. When a trocar is inserted in the midline, the Foley catheter should be identified to avoid accidental bladder perforation.<sup>7,50</sup>



**Fig. 3.70** Placement of a secondary trocar in the left lower abdominal quadrant. The three different plicae are visualized (a). The palpating finger indicates the area lateral to the lateral umbilical fold (b). The sharp ancillary trocar is inserted lateral to the lateral umbilical fold (c). After penetrating the peritoneum, the trocar is directed towards the uterine fundus to avoid injury to major vessels and bowel (d).



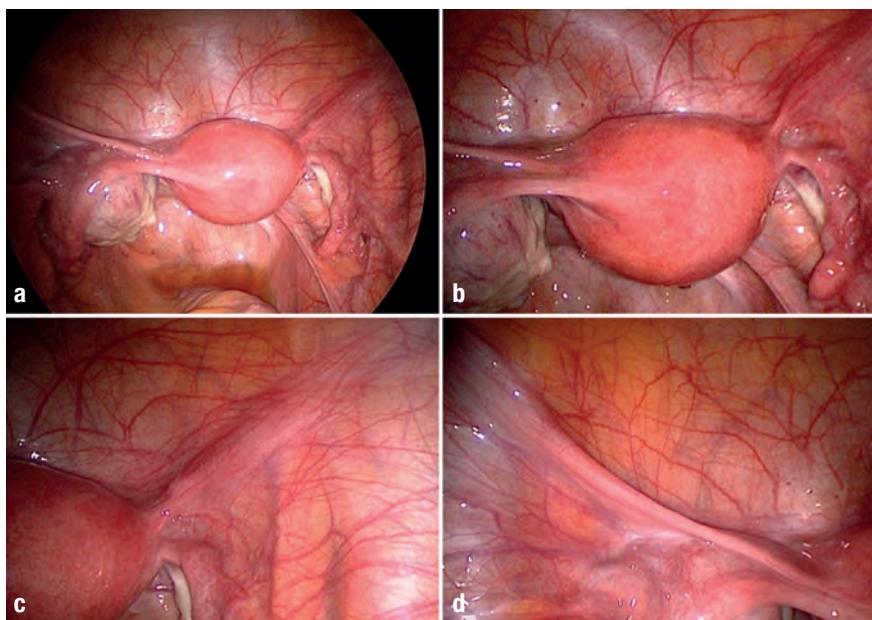
**Fig. 3.71** Placement of a secondary trocar in the right lower abdominal quadrant. The three different plicae are visualized (a). The palpating finger indicates the area lateral to the lateral umbilical fold (b). The sharp ancillary trocar is inserted lateral to the lateral umbilical fold (c). After penetrating the peritoneum, the trocar is directed towards the uterine fundus to avoid injury to major vessels and bowel (d).

### ■ Step 3

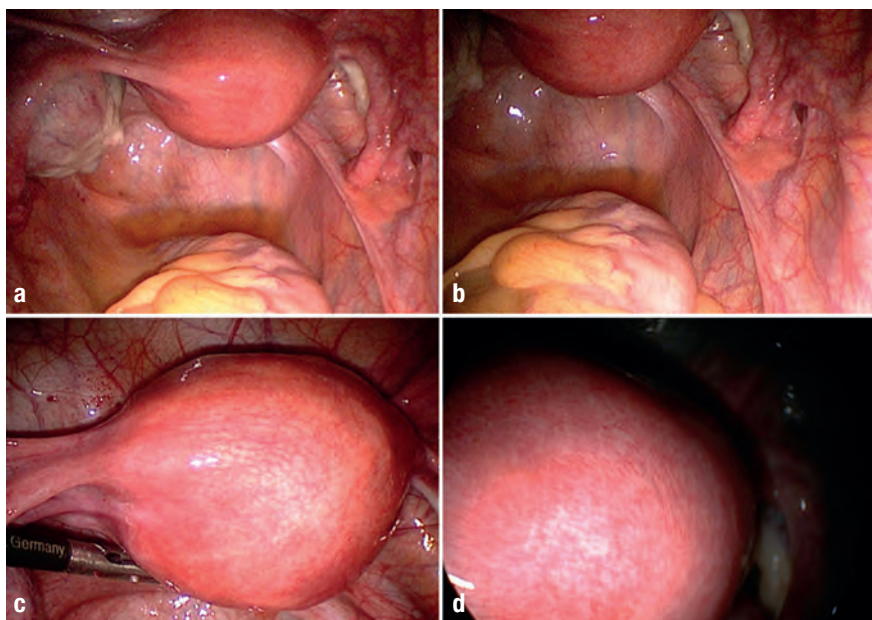
#### Surgical Steps

##### *Resection of Endometriosis*

The primary step in hysterectomy is the removal of all visible foci of endometriosis. These may be superficial implants which are easy to excise (Figs. 3.72–3.75), or they may be adherent to delicate structures and thus are more difficult to remove (Figs. 3.76, 3.77).

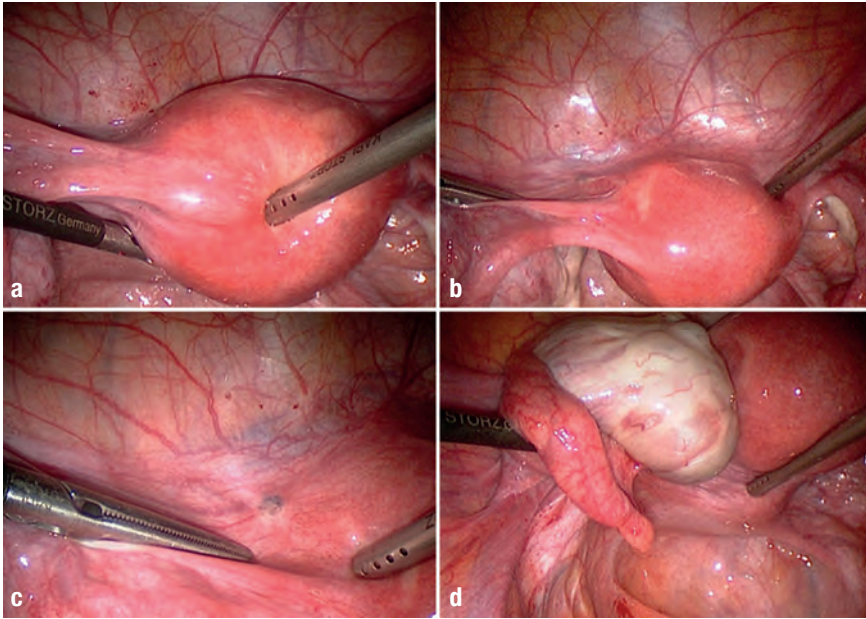


**Fig. 3.72** Laparoscopic panoramic view in a patient with dysmenorrhea (a). Inspection reveals an enlarged uterus of irregular shape and a hypervascular serosa (a, b). The chronic course of disease has resulted in asymmetry of the round ligaments (c). The right side is much shorter than the left side (d).

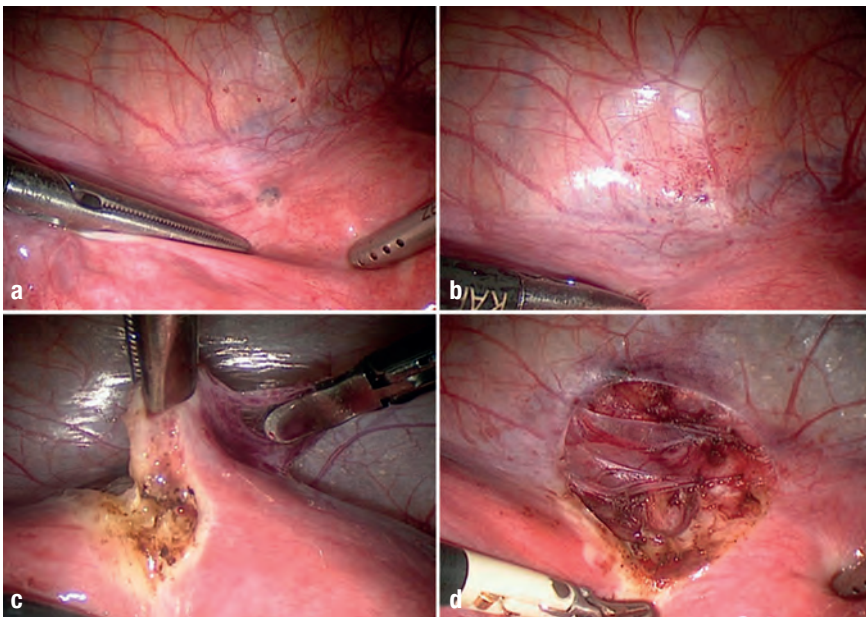


**Fig. 3.73** The uterus appears to be less mobile and is fixed in the pelvis (a, c). The ureteral portion of the peritoneum is under tension in its course to the bladder and is clearly demarcated from the sacrouterine ligament (b). The uterine surface is hypervascular and the proximal portion of the tubes appears to be steep (c, d).



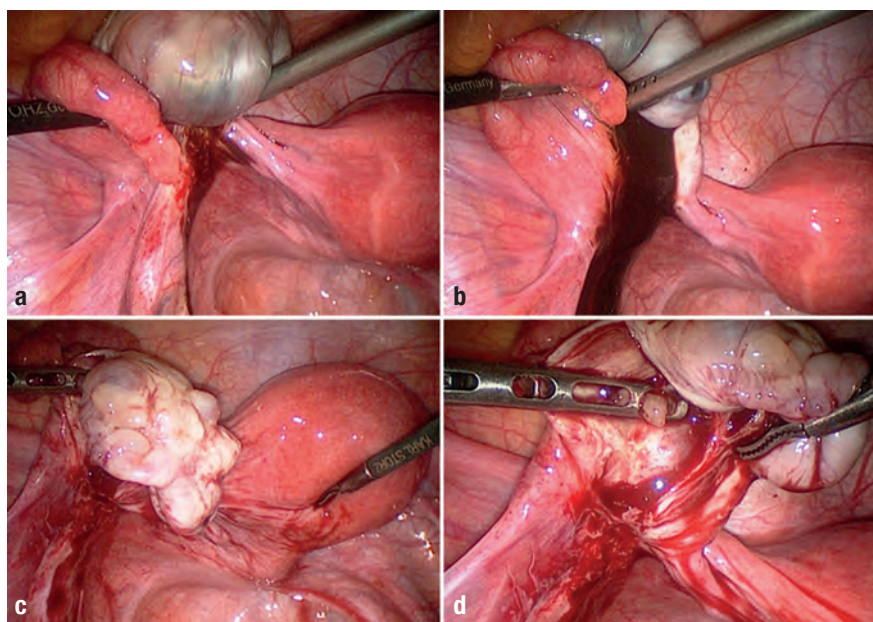


**Fig. 3.74** Probing the uterus with a blunt instrument shows that it is not as soft as in **Fig. 3.45**, but rather tense and hypervascular (**a, b**). An endometriotic nodule is noted on the lower anterior uterine wall (**c**). An enlarged cystic left ovary is fixed to the ovarian fossa (**d**). The ureter is clearly noticeable behind the peritoneum and is lifted toward the immobile area.

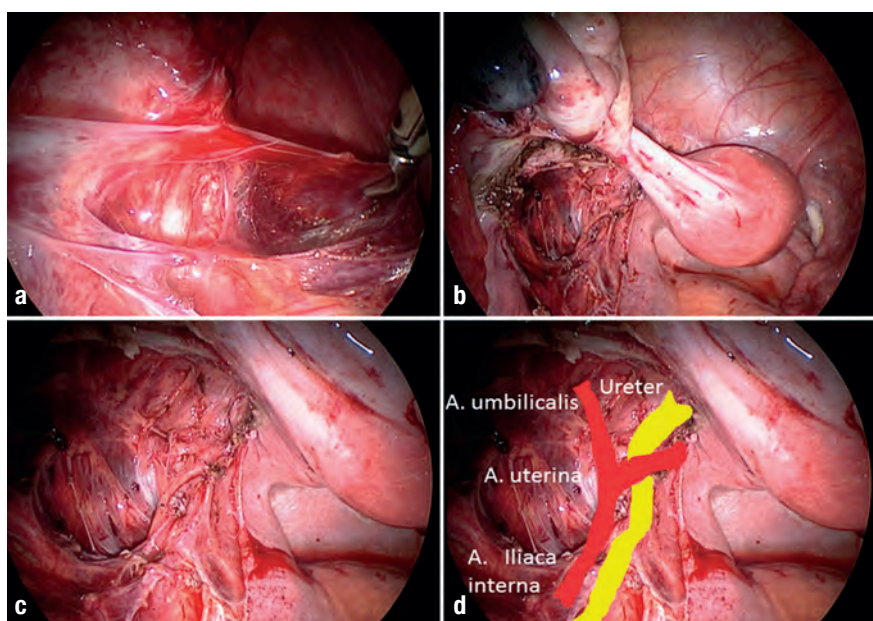


**Fig. 3.75** Excision of the endometriotic nodule in the lower anterior uterine wall (**a-d**). The adjacent bladder also appears to be affected superficially as it is hypervascular and fragile (**b**).



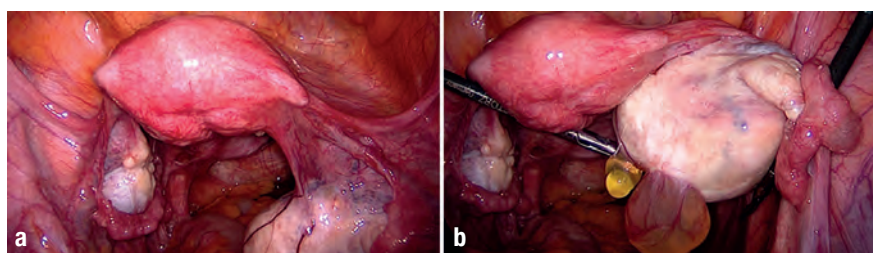


**Fig. 3.76** The ovary is lifted out of the ovarian fossa and released from its peritoneal adhesion, thereby opening the endometrioma (a, b). The deep portion of the ovarian fossa is affected by disease and the boundaries of the peritoneal nodule are clearly noticeable (c, d). In most cases, the nodules are implanted on the cardinal ligament or sacrouterine ligament.



**Fig. 3.77** The peritoneal wall is opened for resection of the symptomatic endometriotic nodule.

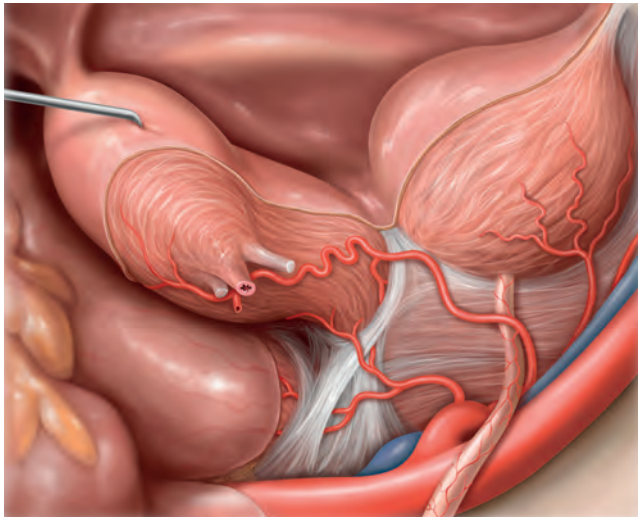
The ureter and pelvic wall vessels are bluntly separated from the affected peritoneum and the endometriotic nodule (a–d). Involvement of the ureter or its accompanying vessels is very rare and when present, will require a specific surgical technique.



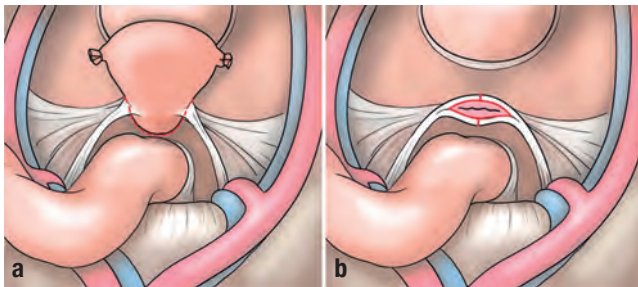
**Fig. 3.78** Symptomatic uterine adenomyosis in a patient who has completed her family planning (post-sterilization) (a, b). Fresh endometriotic lesions are found on the posterior uterine wall and on the right ovary. The patient's symptoms worsened after sterilization because she discontinued hormonal contraceptive medication. The patient is scheduled for LTH.

*Laparoscopic Total Hysterectomy (LTH)*

In patients who require surgical staging, the surgeon performing LTH will be able to assess the abdomen and pelvis, perform pelvic washings/obtain samples from the fluid, perform salpingo-oophorectomy, lymph node dissection, biopsy sampling and omentectomy in addition to laparoscopic hysterectomy (Fig. 3.78).



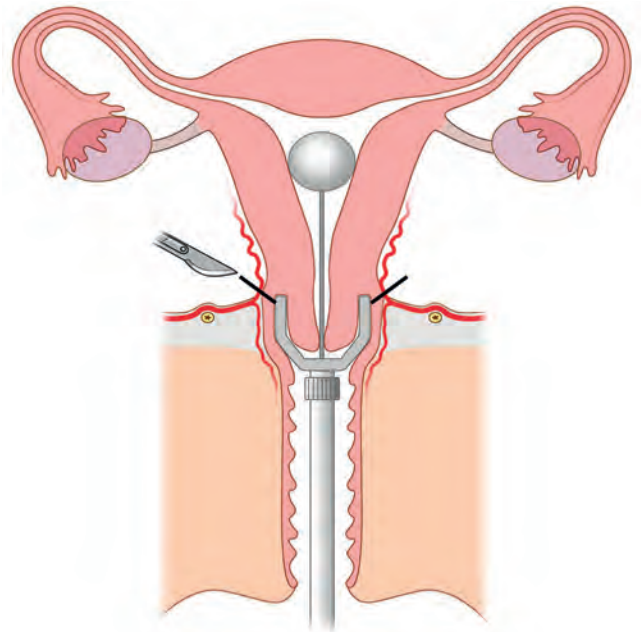
**Fig. 3.79** Anatomical illustration shows the relationship of the uterine vessels to the ureter in the pelvic wall, as compared with its location close to the uterus. The tortuous course of the ascending branch of the uterine artery is clearly appreciated. The uterus, bladder and rectum are embedded in a ligament-based pelvic floor.



**Fig. 3.80** Diagrammatic representation of laparoscopic total hysterectomy (a) and the residual vaginal stump (b).

*Classic Intrafascial Hysterectomy*Surgical Steps

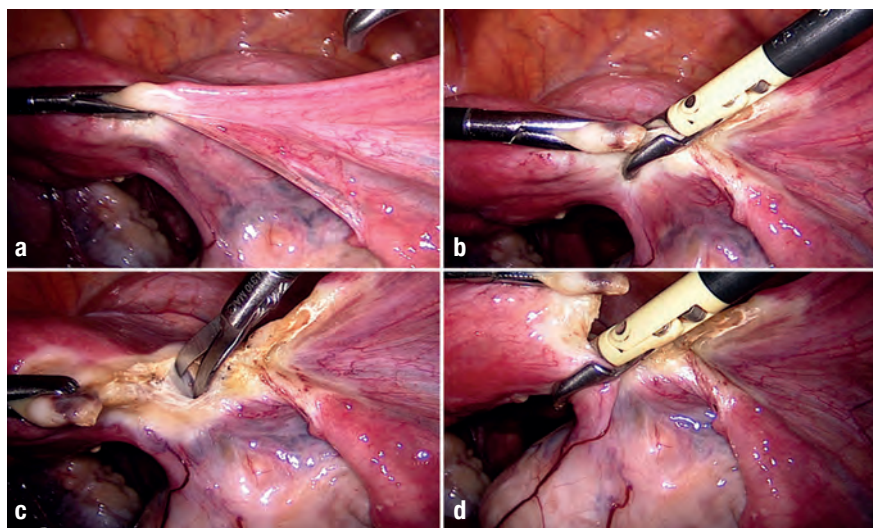
- Initial steps consist of inspecting the pelvis, tracing the course of the ureters, and planning the operation (Figs. 3.72, 3.73, 3.79–3.81).



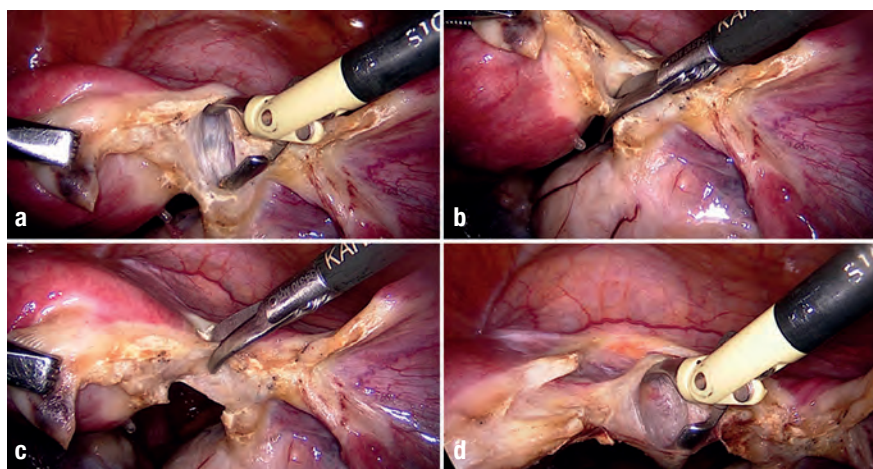
**Fig. 3.81** Diagrammatic representation of the resection line in LTH. Only the ascending branch of the uterine artery needs to be coagulated and cut with the uterine manipulator. Good surgical practice requires that a safety margin of approximately 2 cm is maintained from the coagulation zone.



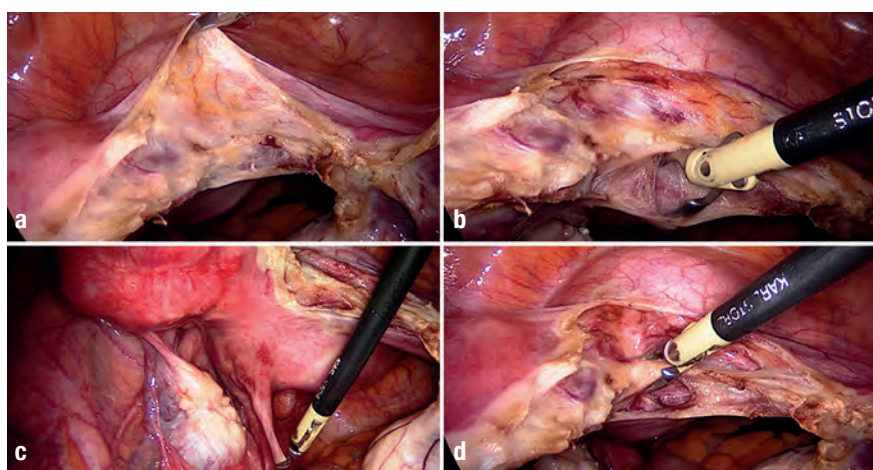
- Start on the right side. Push the uterus in the opposite direction when separating the adnexa or ligaments from the pelvic sidewall, aided by traction or use of the intrauterine manipulator (Fig. 3.82).
- The infundibulopelvic ligament and round ligament are separated from the pelvic sidewall. Alternatively, the adnexa are separated from the uterus, if they are to be preserved (Fig. 3.83).
- Dissection of the broad ligament: The broad ligament is opened and each leaf is coagulated separately (Fig. 3.84). This is not possible when a sealing and cutting instrument is used, as it will fuse together the two leaves of the broad ligament. The boundary of exposure should be as close as possible to the uterus, but as far from it as necessary to avoid injury to the pelvic sidewall and ureter (Fig. 3.79).



**Fig. 3.82** Stepwise coagulation and dissection of the right round ligament (a–c) and utero-ovarian ligament (d).



**Fig. 3.83** The anterior and posterior leaves of the broad ligament are opened. By mobilizing the uterus upward (c), the surgical plane down to the bladder fat can be opened bluntly (d).

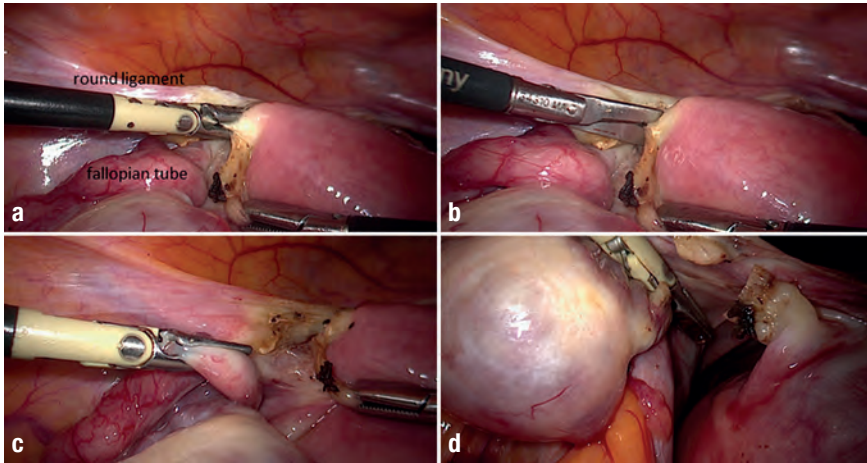


**Fig. 3.84** The bladder peritoneum is incised (a). The bladder is kept at a safe distance; only the bladder fat and portions of the bladder pillar are seen. The ascending branch of the uterine artery can be identified and selectively coagulated (b–d). Pulling the uterus upward while mobilizing it upward with the uterine manipulator are important steps. In benign conditions, the cutting line should be located above the cardinal ligament (c). Hysterectomy is then performed via the intrafascial route.

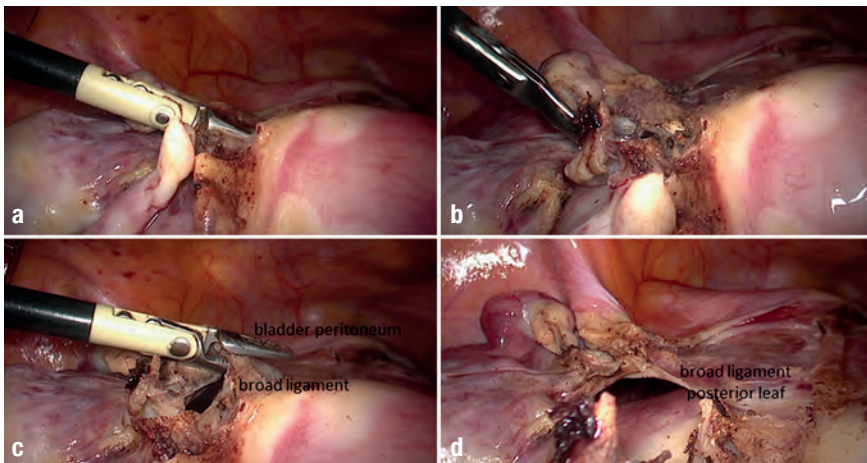


- The bladder is separated from the uterus by opening the vesicouterine ligament and pushing the bladder downward approximately 1–2 cm (Fig. 3.84).
- The ascending branch of the uterine artery is identified and the uterine pedicles are separated (Fig. 3.84).
- The left adnexa are progressively dissected in the same way (Figs. 3.85, 3.86). The bladder peritoneum and broad ligament

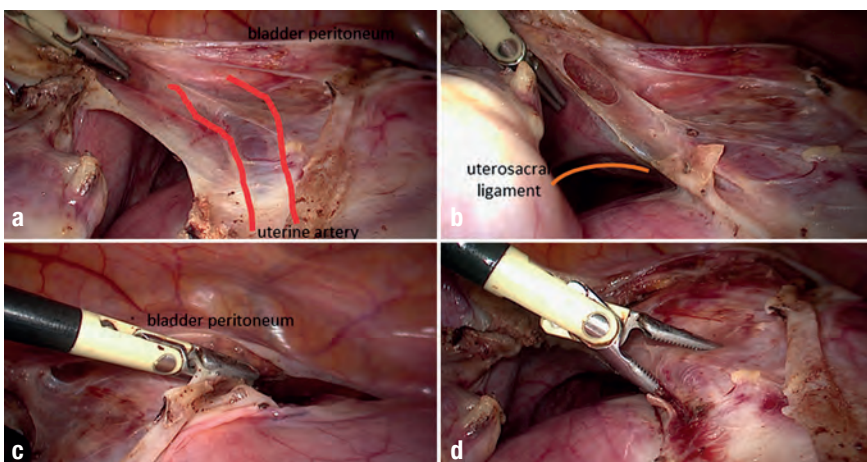
are opened (Fig. 3.87) and the uterine vessels are dissected (Figs. 3.88, 3.89) on the left side. The cervix is thoroughly inspected.



**Fig. 3.85** Stepwise coagulation and dissection of the left round ligament and fallopian tube (a–c), as well as the ovarian ligament (d). The curved scissors is held such that the tip points away from the uterine wall (a, b). After dissection of the fallopian tube, the vessels running beneath it should be coagulated before proceeding with cutting (c, d). Given the presence of coexisting myomas in the lateral region, the course of the sacrouterine ligament and the uterus can be defined and visualized by blunt manipulation. Care must be taken to make sure that the coagulation line spares this region.



**Fig. 3.86** Dissection of the bladder peritoneum and the anterior and posterior leaves of the broad ligament on the left side. Note that the bladder peritoneum has already been opened from the right side (d). The posterior leaf of the broad ligament serves as an anatomic landmark to identify the uterine vessels.



**Fig. 3.87** The opening made in the bladder peritoneum and the broad ligament is enlarged (a–c), and coagulation of the left uterine vessels is initiated (d). The uterine artery provides an anatomic landmark in its descending course (a). A view toward the back of the uterus confirms that the cutting edge is above the junction of the sacrouterine ligaments.

■ After the bladder has been separated from the uterus, the bladder is mobilized and dissected 2–3 cm downward to expose the rim of the cervical cap. In cases of post-caesarean section, will require a careful, gentle and mostly blunt dissection technique (Figs. 3.90, 3.91).

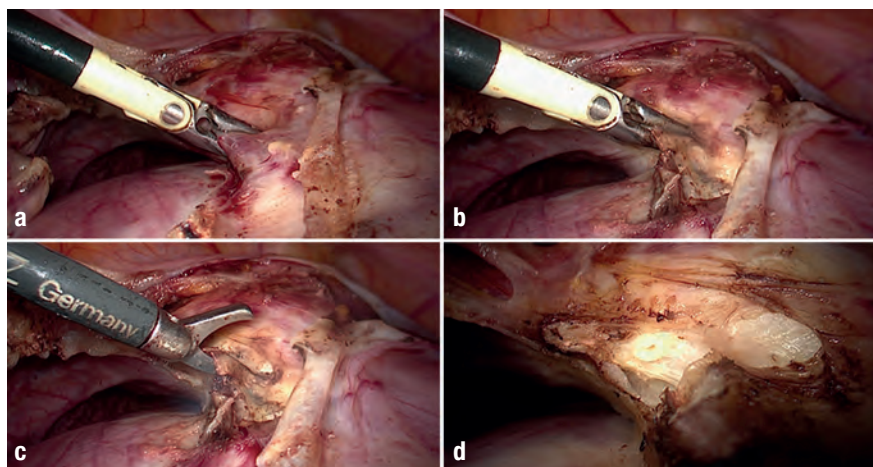
■ While the ureter is lateralized by pushing the manipulator upward, the uterine artery and vein along with its collaterals are fully coagulated close to the cervix and dissected.

The key steps of pushing the bladder downward from the anterior vaginal fornix prior to making the incision and obtaining safe clearance of the ureters and uterine vessels at

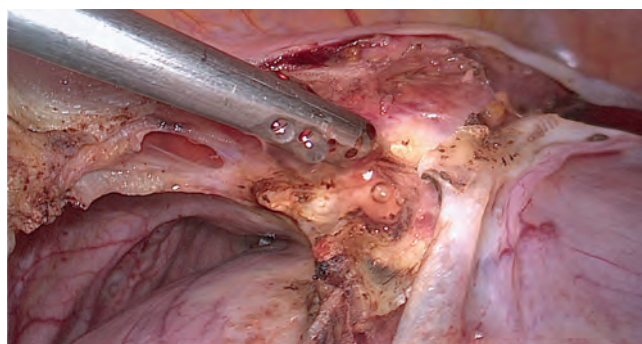
the cervical/vaginal level can be safely achieved by guiding the manipulator firmly upward toward the side opposite the exposure (Fig. 3.92).

#### ■ Step 4

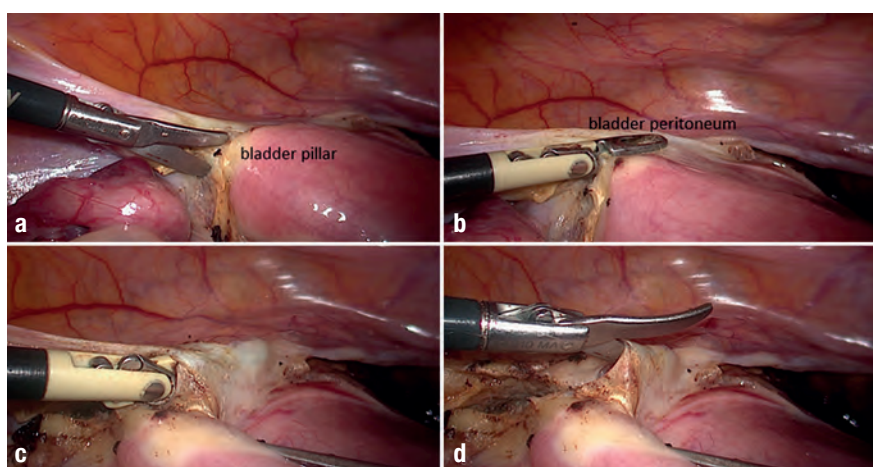
The vagina is resected from the cervix with a monopolar hook while extending the uterine manipulator firmly upward. An infrafascial dissection is performed, leaving the sacrouterine ligaments almost entirely in place (Figs. 3.93, 3.94).



**Fig. 3.88** Bipolar coagulation and separation of the uterine vessels on the left side. The coagulation zone should include the upper portions of the artery to avoid any retrograde bleeding after dissection of the vessel (b). The uterus is blanched to a grayish-white color. A deep cut can be avoided by using hook scissors (c–d). The uterine artery is dissected in two steps. This allows to proceed with coagulation of the tissue just behind the artery, while at the same time preventing venous bleeding.

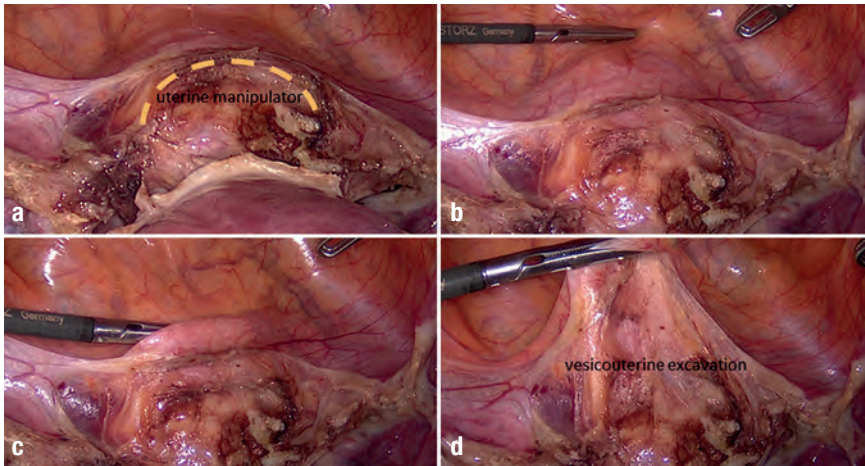


**Fig. 3.89** Visualization of the detached left uterine pedicles. Adding a few drops of physiological saline solution facilitates to achieve a more effective bipolar coagulation through the flow of electrolytes, especially if the surgical site is very dry.

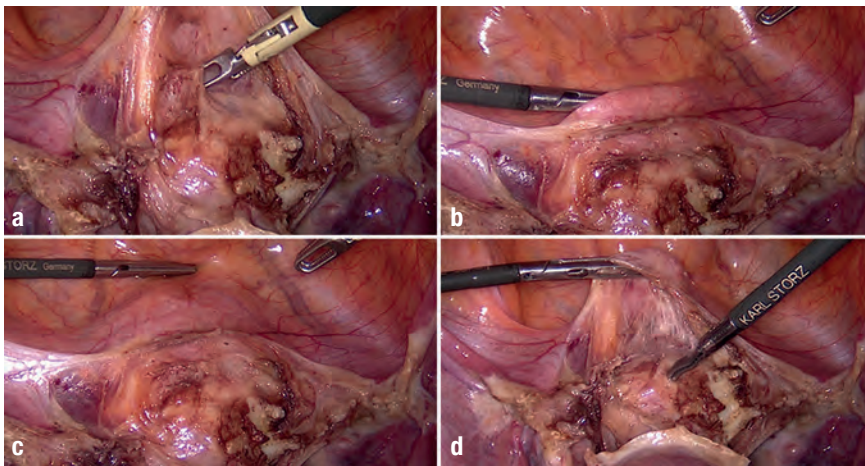


**Fig. 3.90** The bladder pillar and bladder peritoneum are finally dissected from left to right, allowing the CO<sub>2</sub> distension medium to 'show the way'. The bladder is pushed safely downward out of the surgical field, and the peritoneal line of the vesicouterine fold is easily identified.

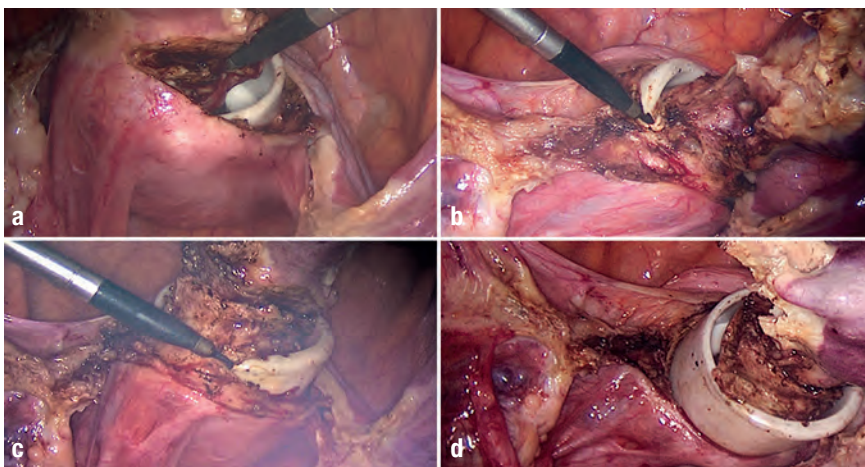




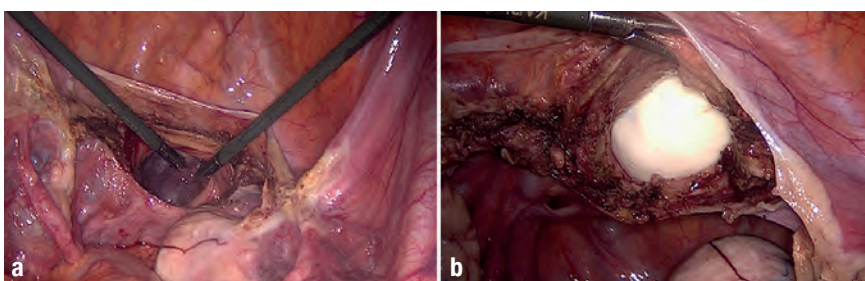
**Fig. 3.91** View of the area that will be taken up by the intrauterine manipulator (broken line) (a). The bladder cannot always be readily identified and safely avoided (b, c). Accurate localization of the bladder is achieved with a blunt instrument which is used to push the presumed bladder toward the cervix and away from the balloon of the Foley catheter. Once the bladder has been elevated, the vesicouterine pouch can be opened to continue mobilizing the bladder further downward.



**Fig. 3.92** Minimal dissection of the bladder peritoneum, approximately 1 cm for LSH and 2–3 cm for LTH, by opening the vesicouterine pouch. This is facilitated by placing the uterine manipulator inside the vagina while pushing the cervix upward, but may also be accomplished by using traction alone. Once the vesicouterine space has been opened, exposure is achieved in a straightforward and bloodless manner using a blunt instrument.



**Fig. 3.93** Completion of dissection of the vagina from the cervix (a–d) and initial transvaginal retraction of the uterine cervix, still held in place with the manipulator forceps. Meticulous exposure under good laparoscopic vision is essential, considering that monopolar resection with the very sharp monopolar hook is accompanied by fogging of the distal lens. Exposure is accomplished under laparoscopic vision (30° scope) with simultaneous retraction and manipulation. The surgeon must be alerted to the possibility that vision may abruptly deteriorate when CO<sub>2</sub> gas escapes through the colpotomy. In this case, blind application of monopolar energy involves the risk of iatrogenic injury.



**Fig. 3.94** Retraction of the uterus through the vagina (a). A surgical glove packed with cotton swabs is introduced transvaginally to prevent loss of the CO<sub>2</sub> pneumoperitoneum (b).



The uterus is now extracted transvaginally or is positioned within the vagina to prevent loss of intraabdominal pressure while it is still fixed to the manipulator. A large uterus should be morcellated either intraabdominally or transvaginally. In case of a large benign uterus, myomas that can be readily identified, may be enucleated. As an alternative option, the large uterus may be cut into small pieces for transvaginal retrieval. Accordingly, the length of the low abdominal incision does not need to exceed 5 mm, which minimizes postoperative pain and prevents the risk of hernia formation. Another option is to strip off the surgical specimen by use of a powered morcellator (10 to 12 mm in diameter) and to extract the dissected material through the abdominal wall. While activating the device, the surgeon must make sure that the morcellator's cutting edge is under constant visual surveillance. The absence of any malignancy should be previously confirmed in the course of the preoperative diagnostic workup. As part of the informed consent process and documentation, the patient should be informed in advance that morcellation of the uterus may be necessary, depending on the uterine volume.

#### ■ Step 5: Closure Technique for Prevention of Prolapse

##### A Technique for Stable Fixation of the Vaginal or Cervical Stump

##### *Vaginal Closure with the Schollmeyer Modification of the Te Linde Suturing Technique*

Hysterectomy is known to be associated with the risk of pelvic organ prolapse, which is particularly high among multiparous women, and may entail the need for surgical management. Given the fact that mean life expectancy (at birth) for women is quite high (Germany, 83.2 yrs; 2014),<sup>40</sup> organ prolapse can pose a problem later in life and may give rise to complications that are associated with surgical repair (thrombosis, embolism, and infection).<sup>10</sup>

The suturing technique of *Te Linde*, used in abdominal hysterectomy for closure of the vagina, was modified for laparoscopic use by *Bruno van Herendael* and was further modified by *Thoralf Schollmeyer*.<sup>59,61</sup>

- The vagina is sutured following meticulous coagulation of its margin.<sup>29</sup> Coagulation should proceed very carefully to avoid postoperative necrosis of the vaginal stump. Minor residual bleeding is managed with sutures incorporating the full thickness of the vaginal wall. The uterus may either be placed temporarily in the vagina or a sterile glove packed with swabs is placed in the vagina to maintain the pneumoperitoneum. In most cases, simple interrupted sutures (PDS 1-0) are placed with a curved needle using extracorporeal knots and intracorporeal safety knots. Alternatively, ski needles or even straight needles can be used to facilitate insertion and withdrawal of the 5-mm trocars.

PDS 1-0 extracorporeal knots are used for the following reasons:

- The monofilament suture material is gently passed through the tissue without causing added trauma ('sawing').
- Use of monofilament PDS material minimizes the risk of vaginal stump infection.
- The long half-life of the suture material minimizes the risk of vaginal stump dehiscence.<sup>29,29</sup>
- Extracorporeal knots provide additional tensile strength.

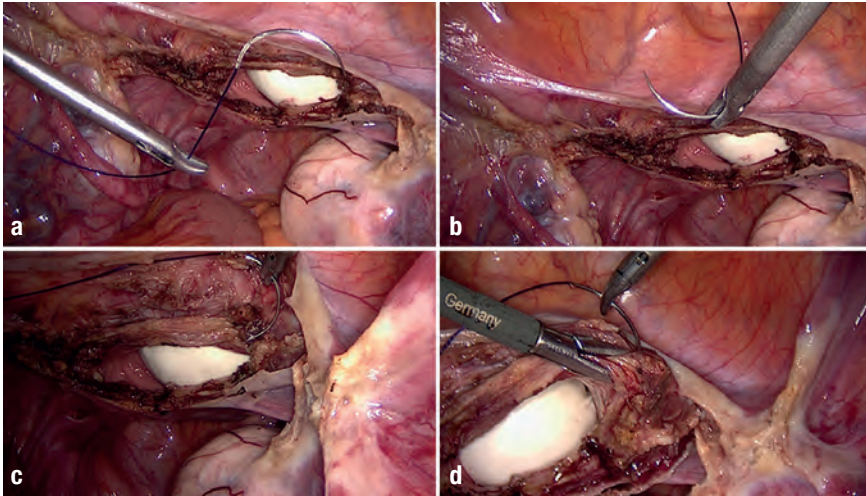
A further surgical option is to suture both sacrouterine ligaments to the posterior vaginal wall to prevent the occurrence of a vaginal prolapse (*McCall* culdoplasty).

##### *Corner Sutures*

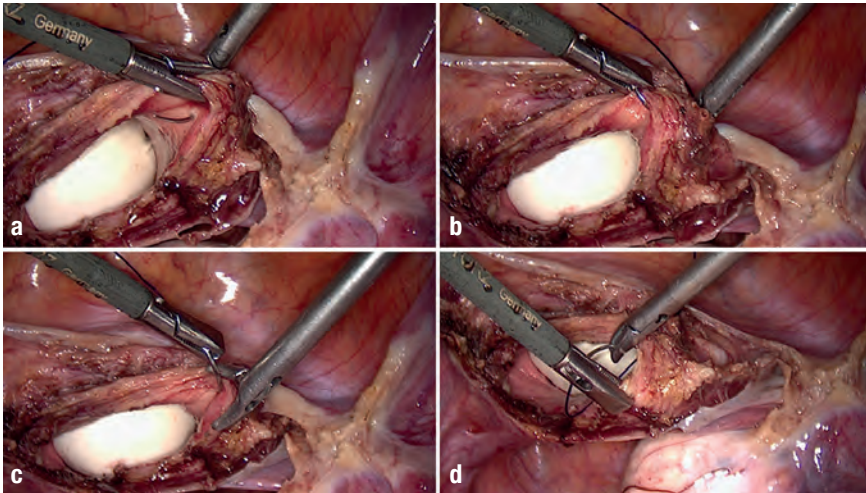
The suture is started in the right vaginal corner, passing the needle through the pericervical ring, and is followed by another stitch that is placed in the corresponding vaginal epithelium. The sutures should be placed at a safe distance away from the urinary bladder to minimize the risk of bladder laceration.

- Subsequently, the needle is passed through the medial aspect of the cardinal ligament in front of the uterine vessels and is aimed at reinforcing the supportive structures involved in vaginal wall suspension. Extracorporeal knotting is performed with deep placement of a strong monofilament suture, allowing the surgeon to incorporate a large amount of tissue and to gently pull the suture through the tissue without causing any iatrogenic trauma.
- Once the suture has been brought back out of the vagina, the next step is to pass the needle through the vaginal epithelium and, successively, through the sacrouterine ligament. The preceding maneuver may be omitted if the suture through the ligament is repeated once or twice in order to shorten it. This step is absolutely essential in patients with an already existing descensus.

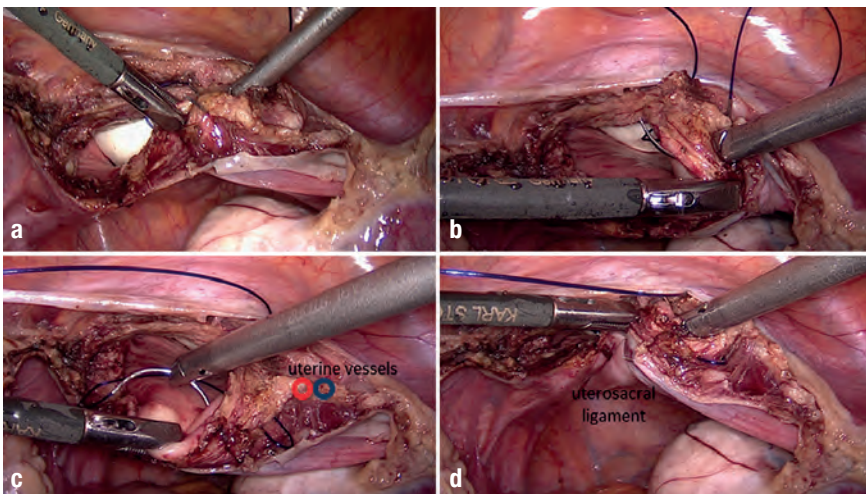
The needle can now be withdrawn, and the suture completed with an extracorporeal Roeder knot, which is secured by two or three intracorporeal knots (Figs. 3.95–3.100). This technique is repeated on the contralateral side to make sure that all parts of the endopelvic fascia (vesicouterine, cardinal and sacrouterine ligaments) have been incorporated (Figs. 3.101–3.103).



**Fig. 3.95** LTH: Right corner suture coalescing the anterior and posterior vaginal wall, the posterior peritoneum and the right sacrouterine ligament. The bladder is identified and spared. A sharp forceps is needed to permit a secure grip on the vaginal epithelium. If the suture incorporates the vaginal wall while excluding the epithelium, there is a high susceptibility to postoperative granuloma formation.

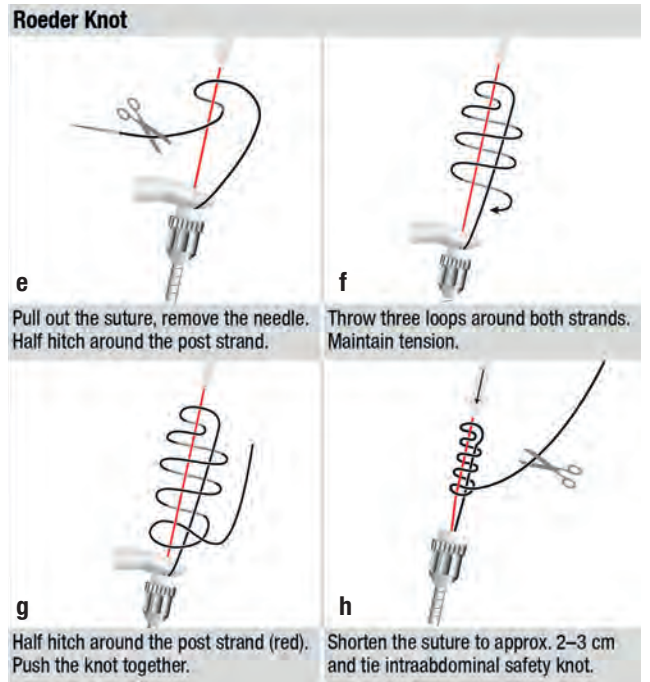
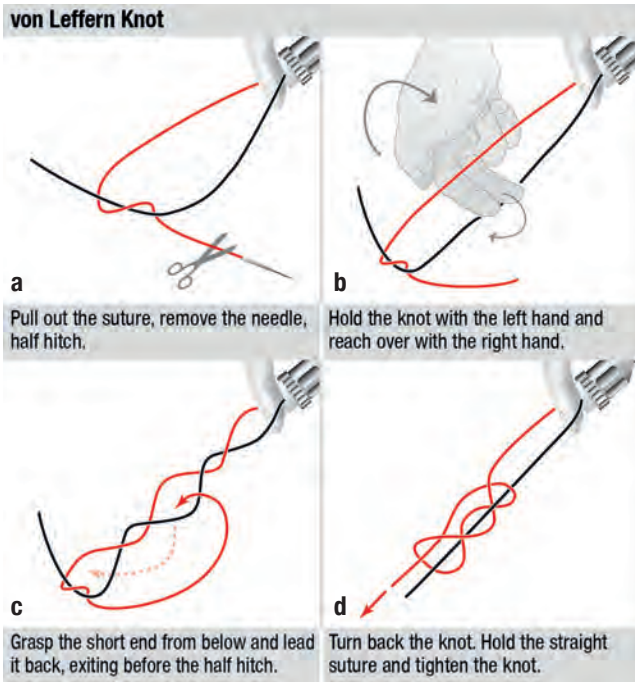


**Fig. 3.96** LTH: Right corner suture (continued from Fig. 3.95). The 30°-scope allows to view from below and above into the vagina. The suture should encompass large portions of the strong paravaginal tissue.



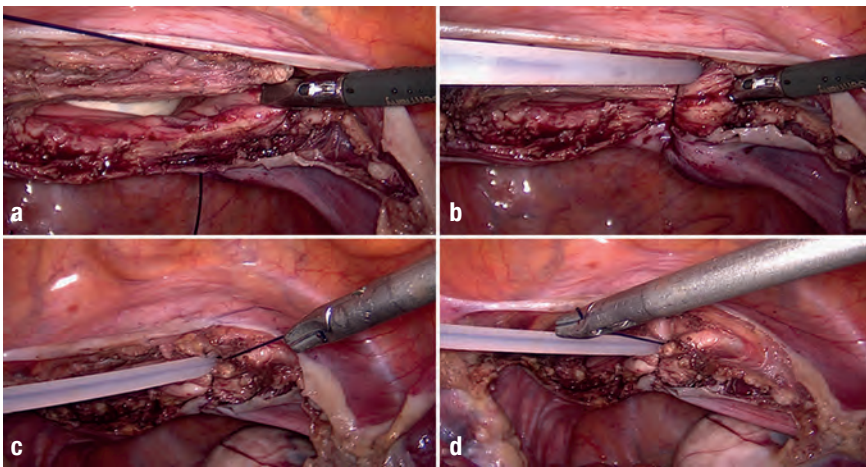
**Fig. 3.97** LTH: Right corner suture (continued from Fig. 3.96). The right sacrouterine ligament is grasped. The vessel stumps are lateralized and excluded from the suture bites. Vessels are mechanically compressed when this type of suture is used.



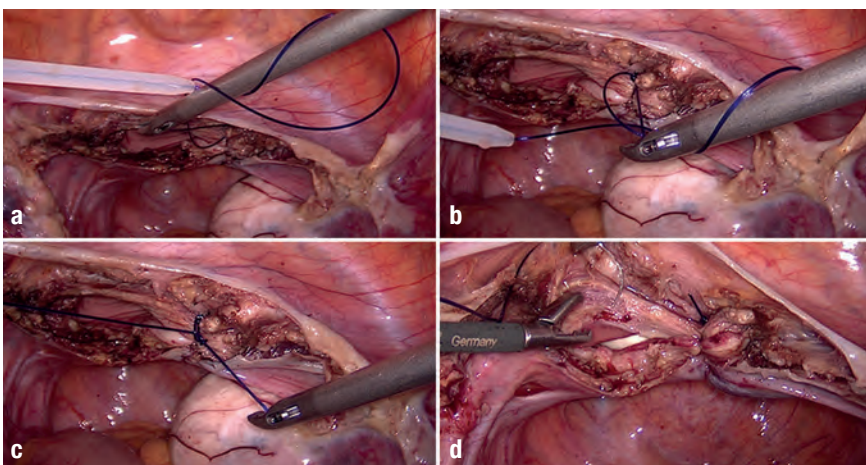


**Fig. 3.98a–d** LSH: The PDS suture is tied extracorporeally using either the ‘von Leffern knot’ or ...

**Fig. 3.98e–h** ... the ‘Roeder knot’.

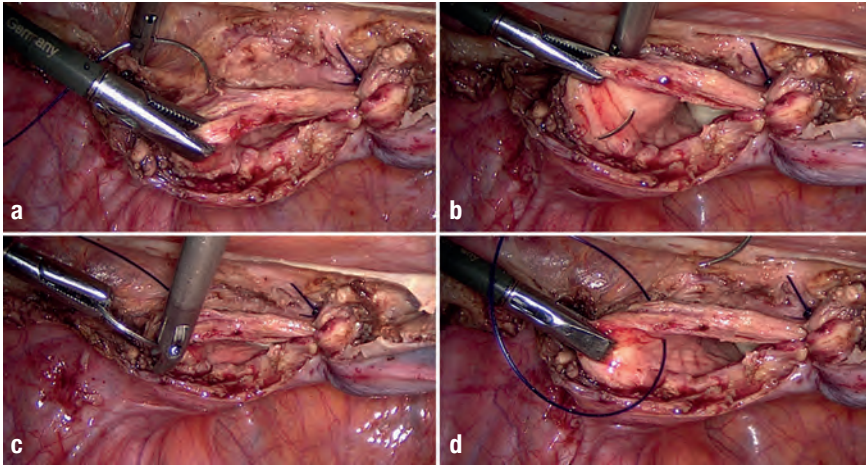


**Fig. 3.99** LTH: The extracorporeal ‘Roeder knot’ or ‘von Leffern knot’ is completed by sliding it downward with a plastic knot pusher (b–d). The edge is pulled into the abdomen to preserve intravaginal sensitivity.

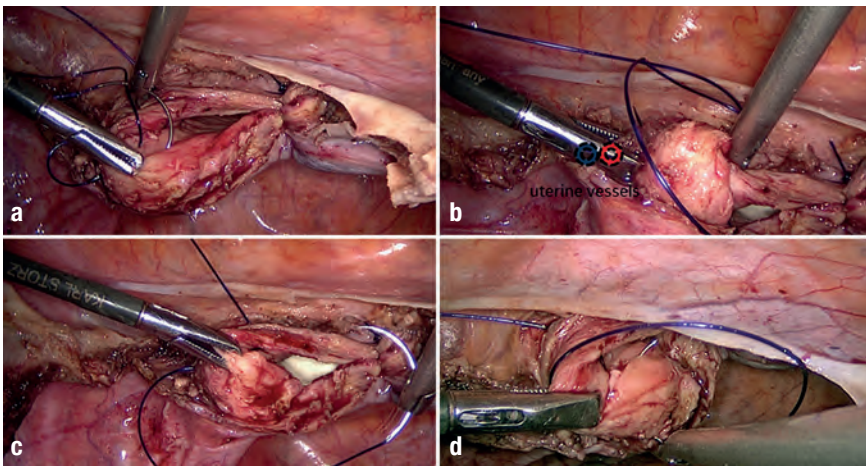


**Fig. 3.100** LTH: The right corner suture is tied intracorporeally and the tail is cut.

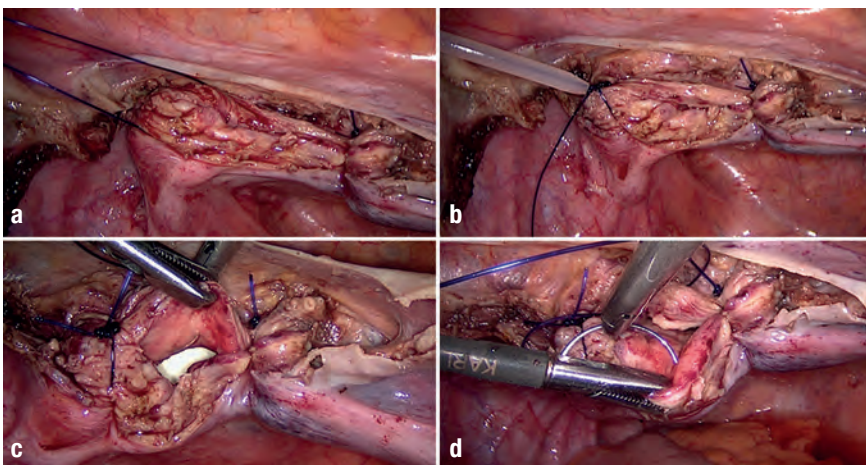




**Fig. 3.101** LTH: Left corner suture coalescing the anterior and posterior vaginal wall, the posterior peritoneum and the left sacrouterine ligament. The bladder is identified and spared under vision. A sharp forceps is needed to securely grip the vaginal epithelium. If the suture incorporates the vaginal wall while excluding the epithelium, there is a high susceptibility to postoperative granuloma formation.



**Fig. 3.102** LTH: Left corner suture (continued from Fig. 3.101). Vessels are mechanically compressed when this type of suture is used. The suture should encompass approximately 1 cm of the vaginal wall.



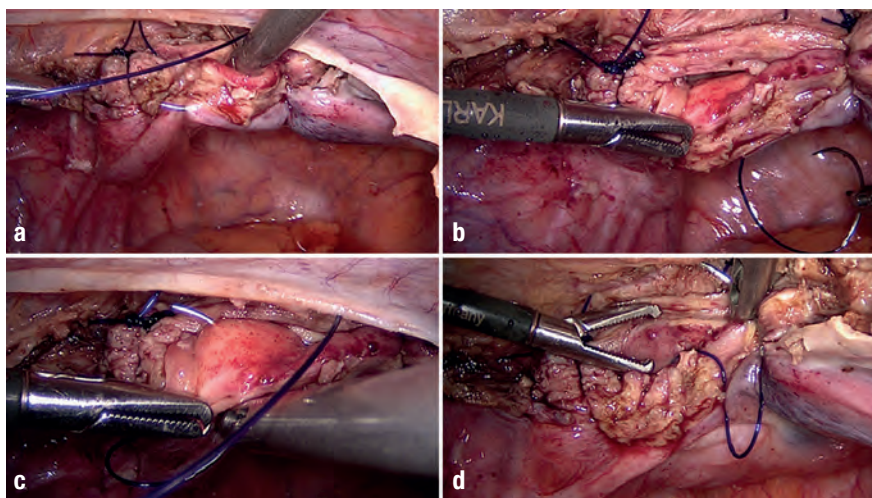
**Fig. 3.103** LTH: Completion of the left corner suture. The extracorporeal knot is slid downward using a knot pusher (a–c). A U-shaped stitch (mattress suture) or Z-closure is started at the center (d). Approximation of the margins and closure is facilitated if the vaginal cuff is not completely dry. Most bleeding will stop spontaneously, eliminating the need for any further electrocoagulation. When applied heavily to the vaginal wall, electrocoagulation entails an increased risk of vaginal stump infection or dehiscence.

### ■ Step 6

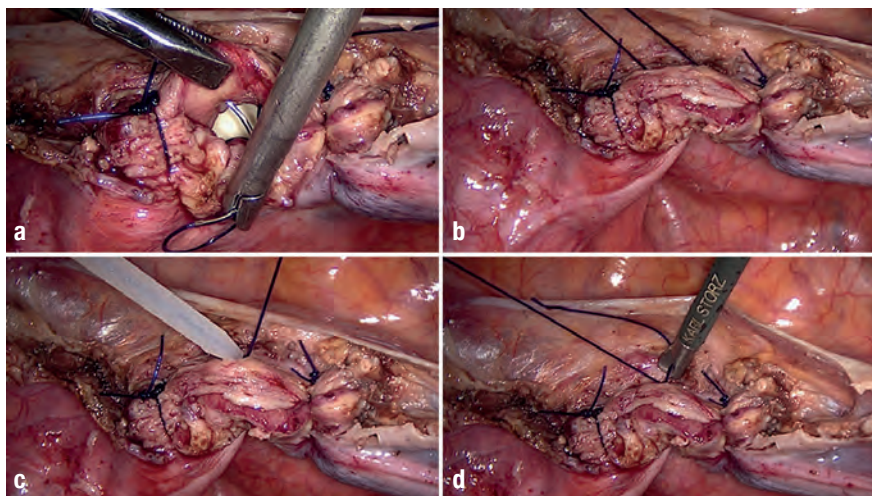
#### Vaginal Closure

The residual vaginal opening at the center can now be closed with two mattress or Z-sutures, which provides for both vertical and horizontal tissue compression, and minimizes the risk of a vaginal stump hematoma. There is no need for peritonealization or drain insertion (Figs. 3.104–3.106). Physiologic reperitonealization will occur during the first two postoperative weeks. Any additional peritoneal suturing may

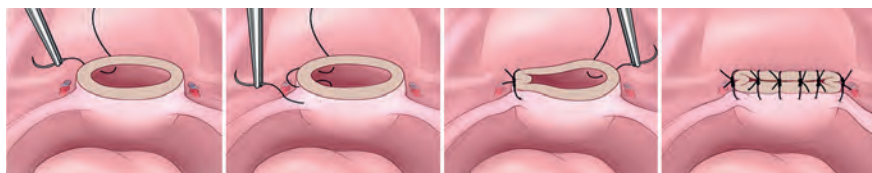
entail the formation of encapsulated seroma or hematoma and is associated with an elevated risk of postoperative infection and pain sensations. If still inside, the uterus or the glove packed with swabs is now removed from the vagina. Fig. 3.107 illustrates the surgical outcomes of supracervical and total hysterectomy.



**Fig. 3.104** LTH: Closure of the residual vaginal opening with a mattress or Z-suture. When a mattress suture is used, it should be carried as far as the bladder in order to prevent damage to the bowel.

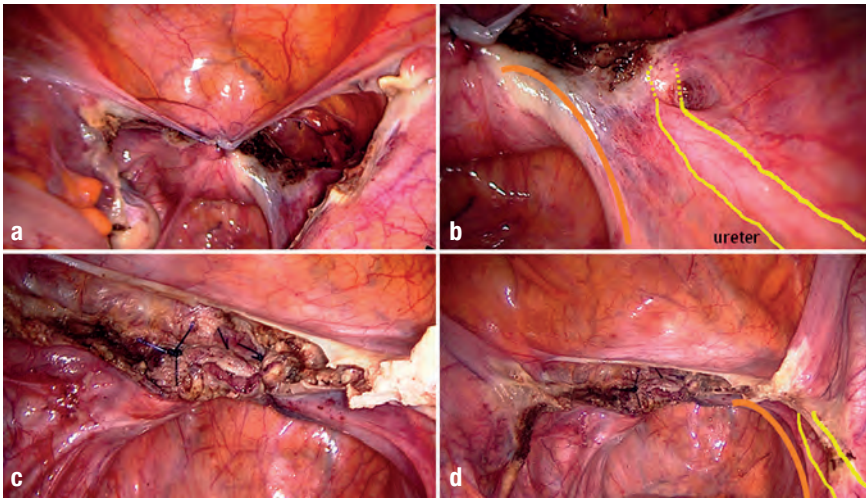


**Fig. 3.105** LTH: Completion of the central suture with a mattress or Z-suture technique. Extracorporeal suturing is unnecessary because the suture is placed properly and the amount of tissue incorporated, is sufficient.



**Fig. 3.106** Diagrammatic representation of vaginal closure after LTH, as modified by *Schollmeyer*. A suture is passed through the endopelvic fascia, 1 cm below the cephalad edge of the vaginal epithelium. The needle is directed from the vaginal lumen through the vaginal wall, passed between the uterine vessels (median part of the broad ligament), and brought back through the vaginal lumen. The sacrouterine ligament is identified before passing the suture through. The needle is directed from the vaginal lumen through the vaginal wall and rectovaginal septum, and finally through the sacrouterine ligament. The vaginal vault is closed with interrupted sutures, mattress sutures, or Z-sutures. The stitch is passed through the endopelvic fascia and vaginal wall, then out of the vaginal wall and endopelvic fascia.



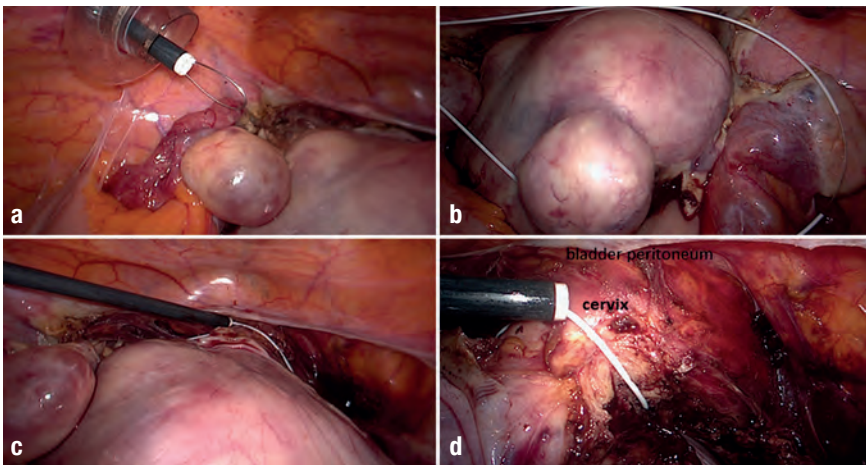


**Fig. 3.107** Final view of the surgical site upon completion of laparoscopic subtotal hysterectomy (**a, b**). The cervical canal is covered with peritoneum and both sacrouterine ligaments are under slight tension in order to reinforce the middle compartment and the cervical ring. Final view of the surgical site upon completion of LTH (**c, d**). The vaginal stump is closed and the sacrouterine ligaments are elevated using two corner sutures. The peritoneum covers the cervical canal and drainage may be applied to both sides. Both sacrouterine ligaments are under slight tension, maintaining the colposuspension. Reperitonealization will occur approximately two weeks after surgery. The PDS suture provides for secure closure and healing of the vaginal cuff because it takes approximately 6 months to be resorbed. The sacrouterine ligaments and ureter can be clearly identified. Since the anatomy of the ureter is not altered, there is no need to open or inspect the retroperitoneal space.

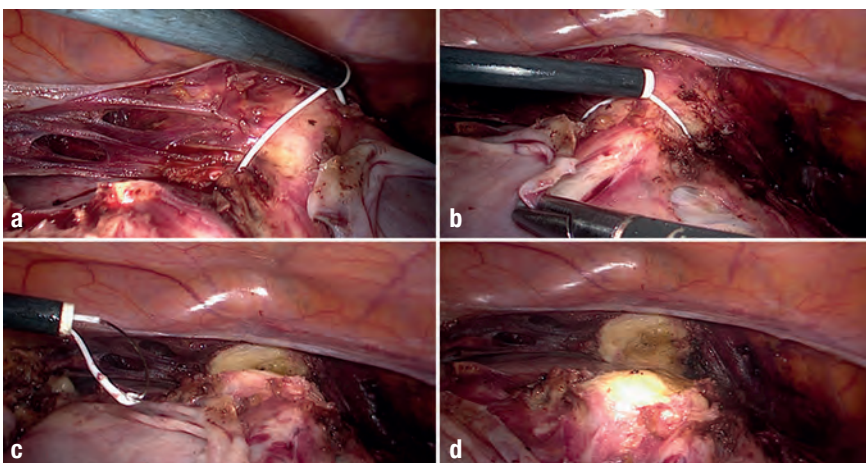
### Laparoscopic Subtotal Hysterectomy (LSH)

In laparoscopic subtotal or supracervical hysterectomy (LSH/LASH), resection of the uterine corpus is performed at the stage of surgery shown in [Fig. 3.108](#). The preceding steps are very similar except that the uterus is elevated by traction instead of using a manipulator. The uterine corpus is cut with a monopolar loop and the cervical canal is coagulated to minimize the

risk of cyclical spotting. The cervical canal should be closed considering the high risk of ascending infection. Concurrently, the cervix may be suspended with a strong monofilament suture, and tied extracorporeally. The residual uterine corpus requires intraabdominal morcellation prior to extraction ([Figs. 3.108–3.114](#)).

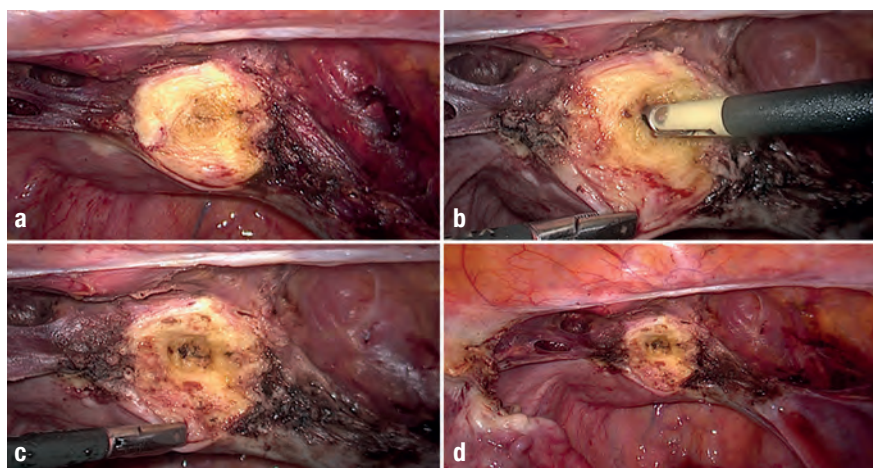


**Fig. 3.108** Introduction of a monopolar cutting loop for use on the cervix and visual confirmation of its proper position prior to initiating electrosurgery (**a**). The whitish uterus is passed through the loop which then is gently tightened (**b, c**). The loop is checked for correct placement between the stumps of the uterine artery and above the junction of the sacrouterine ligaments.

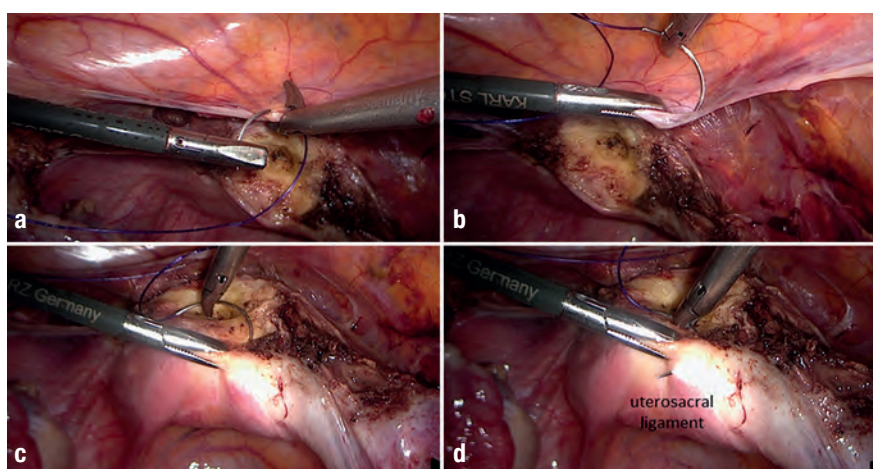


**Fig. 3.109** The loop is placed with the cutting point on the posterior cervix, and the uterine corpus is resected from the cervix (**a, b**). Prior to initiating dissection, correct placement is confirmed to make sure that the loop is between the stumps of the uterine artery and above the junction of the sacrouterine ligaments. Dissection of the cervix and uterus is performed (**c, d**) (in this case: LSH) by applying the monopolar current only in the non-insulated field. The uterine corpus is pulled upward while activating the cutting current in order to obtain an inverted cone (**b, d**).

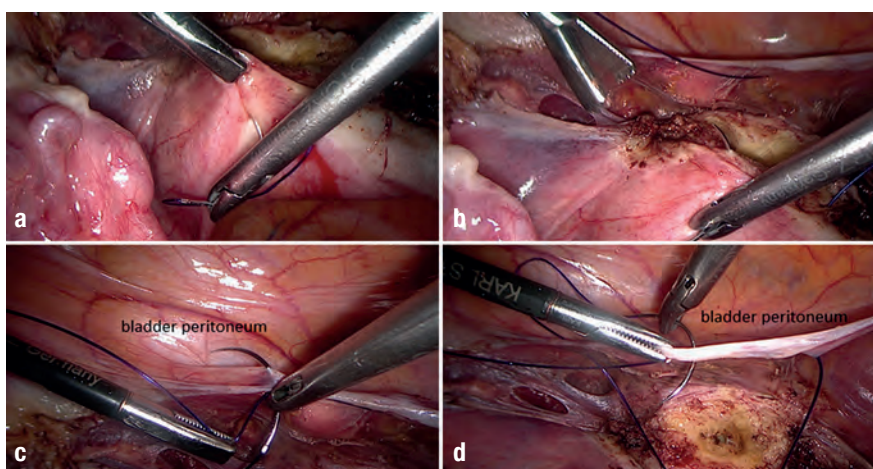




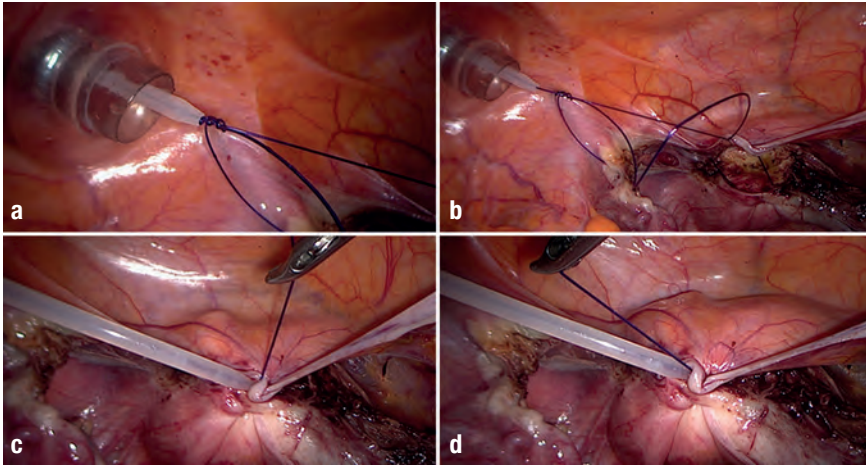
**Fig. 3.110** The residual cervical stump. Extended coagulation should be performed in patients with bleeding disorders, uterine adenomyosis, or endometriosis (a–c). By pulling the uterus upward while activating the cutting current for resection, an inverted cervical cone is created (d).



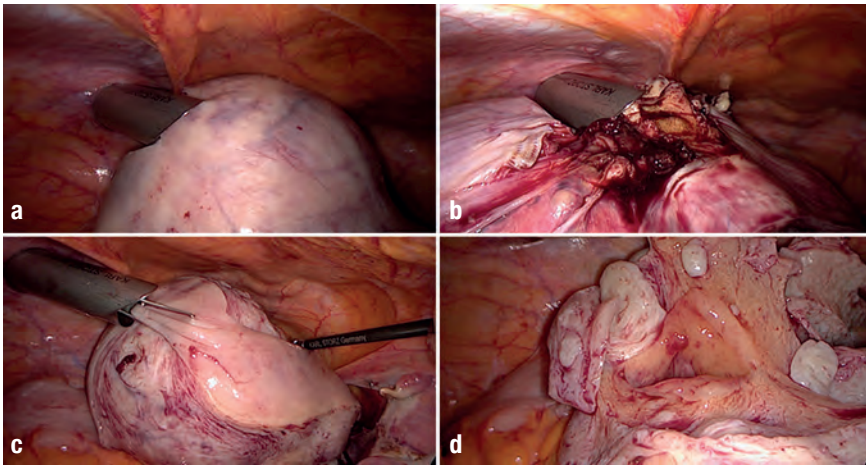
**Fig. 3.111** LSH: (a–d) The junction of the sacrouterine ligaments has been spared. The two ligaments are gripped and incorporated in the suture to provide cervical suspension (a). The bladder peritoneum is attached to the posterior peritoneum with a purse-string suture.



**Fig. 3.112** The sacrouterine ligaments are identified and included in the closure of the cervical stump (a, b). Since the bladder has been exposed only moderately in the course of the procedure, there is enough tissue to close the cervical canal (c, d) and prevent the occurrence of cuff dehiscence.



**Fig. 3.113** Extracorporeal knot tying is used to functionally seal off the cervical canal with peritoneum and provide for cervical suspension. The sides that have been left out still permit drainage, if necessary.



**Fig. 3.114** LSH: The myomatous uterus (850 g) is morcellated, making sure that the rotating cutting edge and the protective shield of the morcellator are meticulously kept in view at all times. The protective shield is directed upward toward the abdominal wall in order to prevent division of abdominal wall vessels. However, the lower part of the field – especially the small bowel – must be exposed and kept out of the surgical area. The surgeon must be patient and prevent injury to the bowel; the latter being one of the major complications of the LSH procedure.

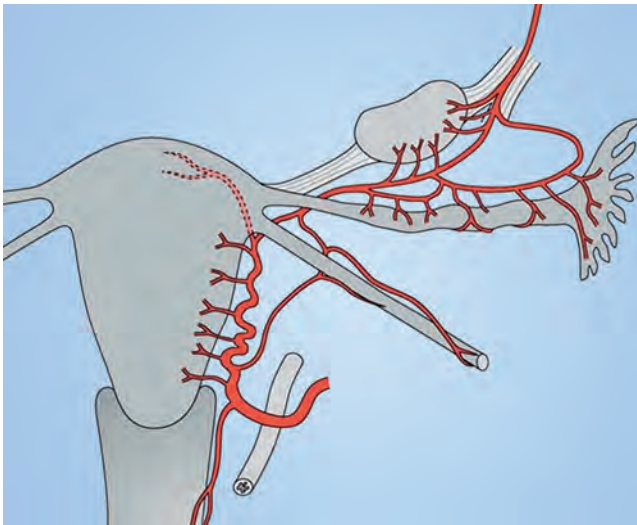


### Special Situations

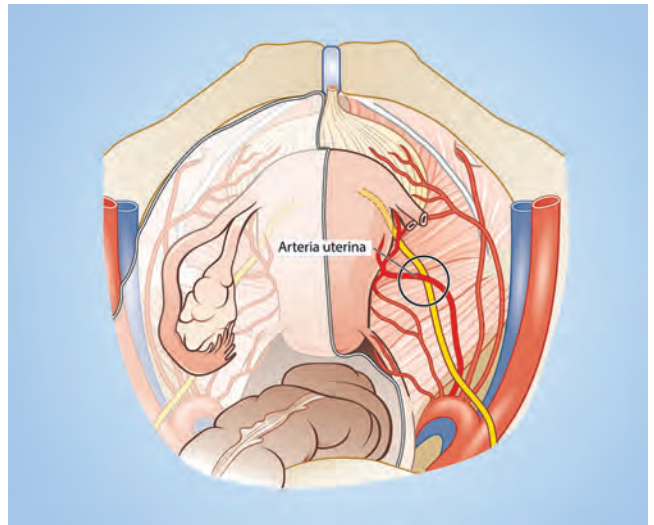
The traditional technique of laparoscopic hysterectomy should be modified in patients with severe adhesions or concomitant deep infiltrating endometriosis. The surgical steps are quite similar to those of oncologic surgery and radical pelvic exposure is essential (Figs. 3.49, 3.76, 3.77, 3.79). Following completion of adhesiolysis, which may be very extensive in case of severe endometriosis or adenomyosis, the retroperitoneum is opened (Figs. 3.115–3.117). The ureter and major vessels are identified, and the crossing point of the uterine artery is exposed (Fig. 3.118). In some cases, clipping of the uterine artery just past its origin from the internal iliac artery (Figs. 3.119–3.122) has proven useful for the following reasons:

- Dissecting and skeletonizing the uterine artery at a more distal level may be difficult or impossible.
- Endometriotic scars and nodules may distort the regional anatomy. This may lead to unexpected bleeding, especially in the case of a large uterus. Proximal clipping of the uterine artery helps to minimize intraoperative bleeding.
- Taking into account that the uterine artery is in close proximity to the ureter, thermal effects from application of bipolar instruments carries the risk of iatrogenic injury to the ureter, which can be prevented by using vascular clips.

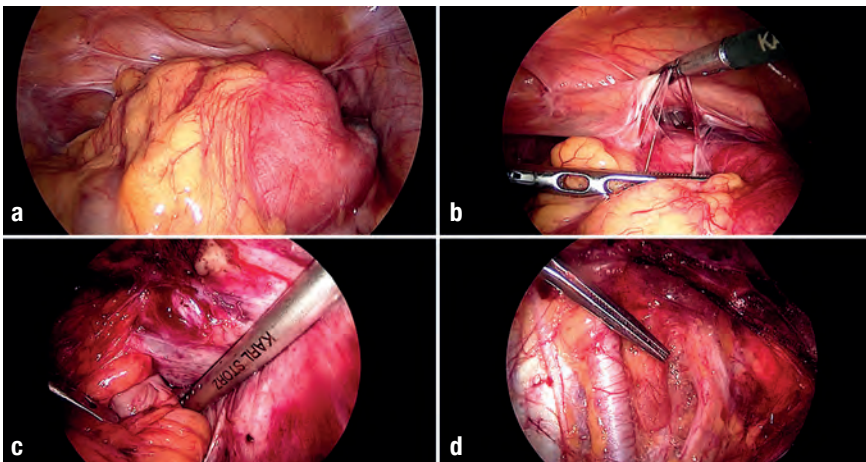
At the end of the procedure, the abdominal cavity is irrigated with physiological saline solution and drained. Usually no drains are left indwelling (Fig. 3.107).



**Fig. 3.115** Diagrammatic representation of the typical course of the uterine artery. The safest area to coagulate the uterine artery is the ascending branch close to the uterus. The distance from the ureter in that area is approximately 2 cm.

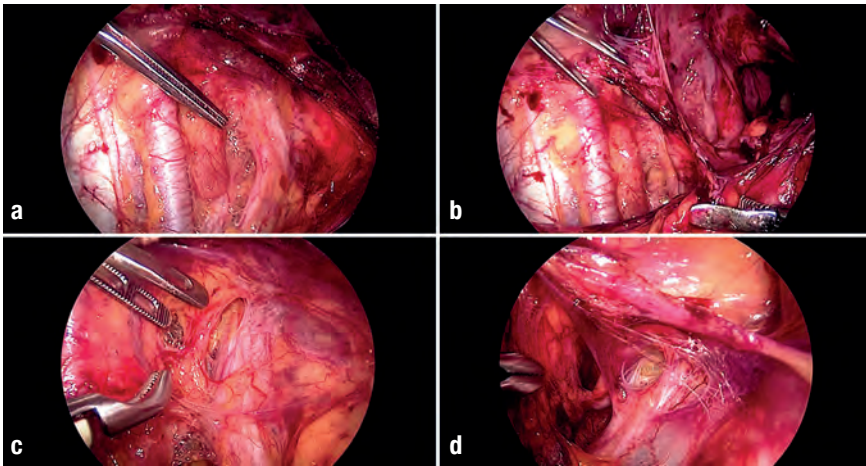


**Fig. 3.116** Any uterine pathology will hinder exposure of the lateral uterine wall and the ascending branch of the uterine artery. Furthermore, a radical hysterectomy must include the parametrium and involves a distal resection margin. This may require exposing the retroperitoneum and identifying the origin of the uterine artery from the internal iliac artery.

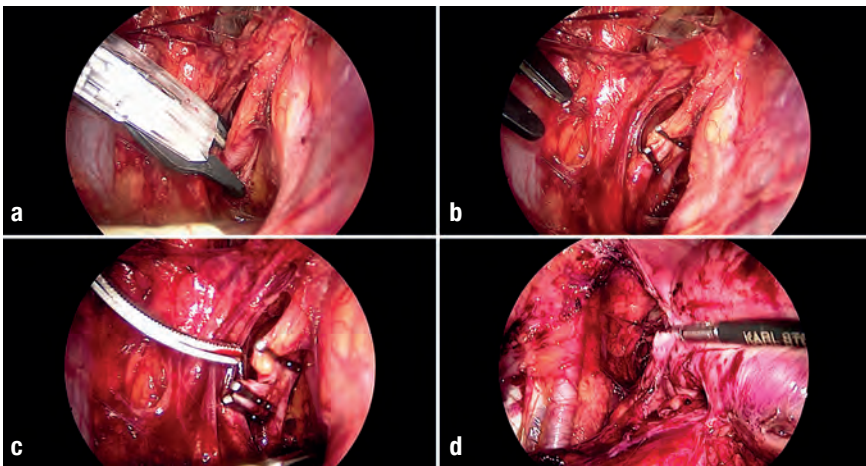


**Fig. 3.117** A case of severe uterine adenomyosis with adhesions of the bowel (a) and bladder peritoneum (b). Access to the lateral aspect of the uterus is obstructed (c). Retroperitoneal access is required (d).

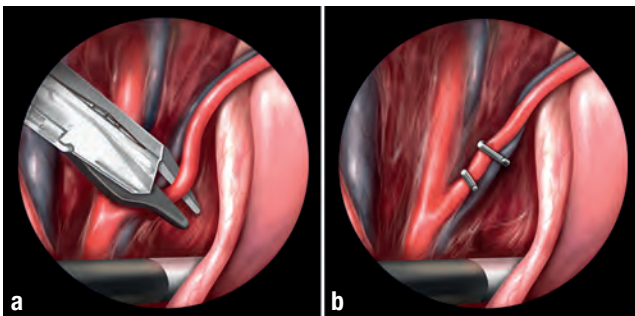




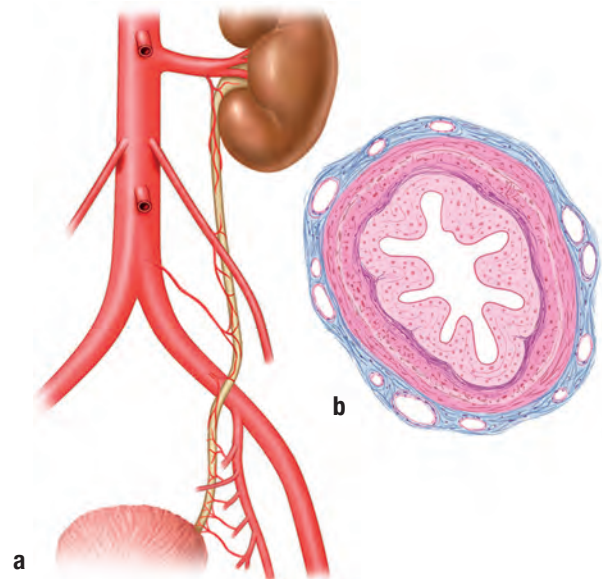
**Fig. 3.118** Once the external iliac artery has been identified, the ureter is usually found adherent to the peritoneum (**a**). A large lymph node is found in the intervening area. (**b**) Access to the pararectal space and paravesical fossa is obtained (**c**). The crossing point of the uterine artery is identified (**d**). The ureter is left in its adventitia to avoid skeletonizing and denudation.



**Fig. 3.119** Clips can be placed for occluding and dividing the artery (**a, b**). The uterine vein (deep) is just beneath the cut artery (**c**). Overview of the exposed region (**d**). The uncolored uterus is seen on the right, after occlusion of both arteries.



**Fig. 3.120** Diagrammatic representation of the retroperitoneal area where the ureter crosses below the uterine artery (**a, b**). The uterine vein is divided into a superficial part and deep part. Clips can be placed after the ureter is medialized.



**Fig. 3.121** Ureteral anatomy provides crucial information (**a, b**). The upper part of the ureter is supplied chiefly by the renal artery, ovarian artery, and aorta (**a**). The lower part is supplied by the iliac vessels and uterine artery (**a**). Blunt dissection causes minor bleeding at the respective levels. Histologic cross-section of the ureter demonstrates the location of the vessels in the adventitia (**b**). Because of this arrangement, electrosurgery or any manipulation that destroys the adventitia may eventually result in secondary fistulation and/or leakage.

The suture technique described above was established because it provides for a stable fixation of the vaginal stump and has other advantages in terms of safety:

- As the suture is placed parallel to the urethra, kinking of the ureters is avoided. The suture is passed through the medial part of the cardinal ligament, along the anteroposterior access route.
- Compression of small vessels between the vaginal wall and uterine artery within the cardinal ligament minimizes the risk of bleeding.
- Despite good suspension there is no significant anatomical displacement of the vaginal approach posteriorly, which could increase the risk of a cystocele.

#### Post-Hysterectomy Inspection

The pedicles, bladder, ureters and bowel should be inspected under continuous irrigation with Ringer lactate or Adept (Baxter). Ureteral movement should not be interpreted as a proof of integrity. If there is suspected injury to or kinking of the ureter during closure of the vagina, the ureter should be exposed by opening the retroperitoneum and freeing the ureter to the site of its junction with the parametria (Fig. 3.121). An alternative test is the injection of methylene blue dye. If the dye does not appear within the abdomen, it is unlikely that significant ureteral damage has occurred. In critical cases, an intravenous pyelogram should be obtained 2–3 days after the operation to assess ureteral integrity.

#### Postoperative Management

Generally, the urinary catheter is removed. It is left indwelling only in selected cases. Postoperative cystoscopy is performed in patients with severe endometriosis or adhesions in the upper part of the bladder. It is good practice to ambulate the patient from bed a few hours after surgery. Clear fluids can be taken 6 hours after surgery, followed by a light diet. Thromboprophylaxis (mechanical and medical) should be used in appropriate cases. The patient can be discharged 8–12 hours after surgery. A postoperative ultrasound scan of the renal pelvis should be obtained. Ordinary light activities are permitted and the patient may return to work in 4–5 days. The patient should be advised to refrain from sexual activity, sports and strenuous work for approximately 6–8 weeks.

Adjuvant medical therapy will depend on the patient's intraoperative condition and level of discomfort.

#### Anticipated Problems

Vital signs, pain, and body temperature should be closely monitored for the first 8 hours. A patient who is discharged early should be given a phone number she can call in the event of pain or discomfort. Drain insertion is not required. Fever, early pain, abdominal distension, delirium, decreased urine output, hypotension or other shock symptoms must be immediately recognized and responded to, as they may signify complications.

#### Summary and Conclusions

In addition to well-known laparoscopic techniques for endometriosis surgery and hysteroscopic techniques for bleeding disorders, laparoscopic subtotal and total hysterectomy are surgical options for the definitive treatment of uterine adenomyosis. The surgical procedure is decided upon jointly by the patient and her doctor. The specific steps described in this chapter will help gynecologic surgeons to perform successful surgery to relieve the clinical symptoms of adenomyosis in women who have completed their family planning.

#### **3.5.7 Conclusions**

- Adenomyosis is a disorder in which endometrial glands and stroma are present within the uterine myometrium. The endometrial glands induce hyperplasia and hypertrophy of the surrounding myometrium, leading to an enlarged and soft uterus.
- Adenomyosis is characterized by menorrhagia and dysmenorrhea. Coexisting endometriosis is also a frequent finding.
- MRI has a high sensitivity and specificity, but vaginal ultrasound is still the diagnostic tool of choice. The final diagnosis is established by histologic examination of the uterine specimen.
- Hysterectomy remains the first-line surgical treatment for women with severe symptoms who have completed their family planning. For those who desire future pregnancy, the treatment of adenomyosis is similar to that of general endometriosis and may consist of medical therapy, surgery, or a combination of both modalities.

#### **3.5.8 References**

1. ABBOTT J, HAWE J, HUNTER D, HOLMES M, FINN P, GARRY R. Laparoscopic excision of endometriosis: a randomized, placebo-controlled trial. *Fertil Steril* 2004;82(4):878–84. doi:10.1016/j.fertnstert.2004.03.046.
2. ALKATOUT I. Communicative and ethical aspects of physician-patient relationship in extreme situations. *Wien Med Wochenschr* 2015;165(23–24):491–8. doi:10.1007/s10354-015-0385-2.
3. ALKATOUT I, BOJAHN B, DITTMANN L, WARNEKE V, METTLER L, JONAT W et al. Precarious preoperative diagnostics and hints for the laparoscopic excision of uterine adenomatoid tumors: two exemplary cases and literature review. *Fertil Steril* 2011;95(3):1119. e5-8. doi:10.1016/j.fertnstert.2010.10.017.
4. ALKATOUT I, EGBERTS JH, METTLER L, DONIEC M, WEDEL T, JUNEMANN KP et al. Interdisciplinary Diagnosis and Treatment of Deep Infiltrating Endometriosis. *Zentralbl Chir* 2015. doi:10.1055/s-0034-1383272.
5. ALKATOUT I, MAASS N, JONAT W, MUNDHENKE C, SCHEM C. Rolle der Angiogenese und ihrer Inhibitoren in der Gynäkologie. *Gynäkologe* 2013;46(1):56–62. doi:10.1007/s00129-012-3091-9.
6. ALKATOUT I, METTLER L, BETETA C, HEDDERICH J, JONAT W, SCHOLLMEYER T et al. Combined surgical and hormone therapy for endometriosis is the most effective treatment: prospective, randomized, controlled trial. *J Minim Invasive Gynecol* 2013;20(4):473–81. doi:10.1016/j.jmig.2013.01.019.
7. ALKATOUT I, METTLER L, MAASS N, NOE GK, ELESSAWY M. Abdominal anatomy in the context of port placement and trocars. *J Turk Ger Gynecol Assoc* 2015;16(4):241–51. doi:10.5152/jtga.2015.0148.

8. ALKATOUT I, METTLER L, MEINHOLD-HEERLEIN I (EDS.). *Hysterectomy – A Practical Guide*. Heidelberg: Springer; in preparation; 2017.
9. ALKATOUT I, SCHOLLMEYER T, HAWALDAR NA, SHARMA N, METTLER L. Principles and safety measures of electrosurgery in laparoscopy. *JLS* 2012;16(1):130–9. doi:10.4293/108680812X13291597716348.
10. ALTMAN D, FALCONER C, CNATTINGIUS S, GRANATH F. Pelvic organ prolapse surgery following hysterectomy on benign indications. *Am J Obstet Gynecol* 2008;198(5):572.e1–6. doi:10.1016/j.ajog.2008.01.012.
11. ASCHER-WALSH CJ, TU JL, DU Y, BLANCO JS. Location of adenomyosis in total hysterectomy specimens. *J Am Assoc Gynecol Laparosc* 2003;10(3):360–2.
12. BENAGIANO G, BROSENS I, HABIBA M. Adenomyosis: a life-cycle approach. *Reprod Biomed Online* 2015;30(3):220–32. doi:10.1016/j.rbmo.2014.11.005.
13. BRUMMER TH, SEPPALA TT, HARKKI PS. National learning curve for laparoscopic hysterectomy and trends in hysterectomy in Finland 2000–2005. *Hum Reprod* 2008;23(4):840–5. doi:10.1093/humrep/den006.
14. BUCHWEITZ O, POEL T, DIEDRICH K, MALIK E. The diagnostic dilemma of minimal and mild endometriosis under routine conditions. *J Am Assoc Gynecol Laparosc* 2003;10(1):85–9.
15. CENTERS FOR DISEASE CONTROL AND PREVENTION OF WOMEN'S REPRODUCTIVE HEALTH. *Hysterectomy Fact Sheet*. Dept. of Reproductive Health 2009;1600 Clifton Rd. Atlanta, GA 30333, USA.
16. CHRISTENSEN B, FREIE HM, SCHINDLER AE. Endometriosis – diagnosis and therapy. Results of a current survey of 6,700 gynecologists. *Geburtshilfe Frauenheilkd* 1995;55(12):674–9. doi:10.1055/s-2007-1022312.
17. CLEMENT PB. The pathology of endometriosis: a survey of the many faces of a common disease emphasizing diagnostic pitfalls and unusual and newly appreciated aspects. *Adv Anat Pathol* 2007;14(4):241–60. doi:10.1097/PAP.0b013e3180ca7d7b.
18. CROSIGNANI PG, VERCELLINI P, BIFFIGNANDI F, COSTANTINI W, CORTESI I, IMPARATO E. Laparoscopy versus laparotomy in conservative surgical treatment for severe endometriosis. *Fertil Steril* 1996;66(5):706–11.
19. DAVIS L, KENNEDY SS, MOORE J, PRENTICE A. Oral contraceptives for pain associated with endometriosis. *Cochrane Database Syst Rev* 2007(3):CD001019. doi:10.1002/14651858.CD001019.pub2.
20. ENGEMISE S, GORDON C, KONJE JC. Endometriosis. *BMJ* 2010;340:c2168. doi:10.1136/bmj.c2168.
21. FERRERO S, CAMERINI G, SERACCHIOLI R, RAGNI N, VENTURINI PL, REMORGIDA V. Letrozole combined with norethisterone acetate compared with norethisterone acetate alone in the treatment of pain symptoms caused by endometriosis. *Hum Reprod* 2009;24(12):3033–41. doi:10.1093/humrep/dep302.
22. GARAVAGLIA E, AUDREY S, ANNALISA I, STEFANO F, IACOPO T, LAURA C et al. Adenomyosis and its impact on women fertility. *Iran J Reprod Med* 2015;13(6):327–36.
23. GIMBEL H. Total or subtotal hysterectomy for benign uterine diseases? A meta-analysis. *Acta Obstet Gynecol Scand* 2007;86(2):133–44. doi:10.1080/00016340601024716.
24. GORLERO F, LIJOI D, BIAMONTI M, LORENZI P, PULLE A, DELLACASA I et al. Hysterectomy and women satisfaction: total versus subtotal technique. *Arch Gynecol Obstet* 2008;278(5):405–10. doi:10.1007/s00404-008-0615-6.
25. HANSTEDDE MM, BURGER MJ, TIMMERMANS A, BURGER MP. Regional and temporal variation in hysterectomy rates and surgical routes for benign diseases in the Netherlands. *Acta Obstet Gynecol Scand* 2012;91(2):220–5. doi:10.1111/j.1600-0412.2011.01309.x.
26. HEALEY M, ANG WC, CHENG C. Surgical treatment of endometriosis: a prospective randomized double-blinded trial comparing excision and ablation. *Fertil Steril* 2010;94(7):2536–40. doi:10.1016/j.fertnstert.2010.02.044.
27. HOHL MK, HAUSER N. Safe total intrafascial laparoscopic (TAIL) hysterectomy: a prospective cohort study. *Gynecol Surg* 2010;7(3):231–9. doi:10.1007/s10397-010-0569-0.
28. HUGHES E, BROWN J, COLLINS JJ, FARQUHAR C, FEDORKOW DM, VANDEKERCKHOVE P. Ovulation suppression for endometriosis. *Cochrane Database Syst Rev* 2007(3):CD000155. doi:10.1002/14651858.CD000155.pub2.
29. HUR HC, GUIDO RS, MANSURIA SM, HACKER, SANFILIPPO JS, LEE TT. Incidence and patient characteristics of vaginal cuff dehiscence after different modes of hysterectomies. *J Minim Invasive Gynecol* 2007;14(3):311–7. doi:10.1016/j.jmig.2006.11.005.
30. JACOBSON TZ, BARLOW DH, GARRY R, KONINCKX P. Laparoscopic surgery for pelvic pain associated with endometriosis. *Cochrane Database Syst Rev* 2001(4):CD001300. doi:10.1002/14651858.CD001300.
31. KENNEDY S, BERGQVIST A, CHAPRON C, D'HOOGHE T, DUNSELMAN G, GREB R et al.ESHRE guideline for the diagnosis and treatment of endometriosis. *Hum Reprod* 2005;20(10):2698–704. doi:10.1093/humrep/dei135.
32. KOVAC SR. Route of hysterectomy: an evidence-based approach. *Clin Obstet Gynecol* 2014;57(1):58–71. doi:10.1097/GRF.0000000000000009.
33. LEFEBVRE G, ALLAIRE C, JEFFREY J, VILOS G, ARNEJA J, BIRCH C et al. SOGC clinical guidelines. Hysterectomy. *J Obstet Gynaecol Can* 2002;24(1):37–61; quiz 74–6.
34. LETHABY A, IVANOVA V, JOHNSON NP. Total versus subtotal hysterectomy for benign gynaecological conditions. *Cochrane Database Syst Rev* 2006(2):CD004993. doi:10.1002/14651858.CD004993.pub2.
35. MAHMOOD TA, TEMPLETON A. The impact of treatment on the natural history of endometriosis. *Hum Reprod* 1990;5(8):965–70.
36. METTLER L, SCHOLLMEYER T, ALKATOUT I. Adhesions during and after surgical procedures, their prevention and impact on women's health. *Womens Health (Lond Engl)* 2012;8(5):495–8. doi:10.2217/whe.12.34.
37. METTLER L, SEMM K, LEHMANN-WILLENBROCK L, SHAH A, SHAH P, SHARMA R. Comparative evaluation of classical intrafascial-supracervical hysterectomy (CISH) with transuterine mucosal resection as performed by pelviscopy and laparotomy – our first 200 cases. *Surg Endosc* 1995;9(4):418–23.
38. MOUSA NA, BEDAIWY MA, CASPER RF. Aromatase inhibitors in the treatment of severe endometriosis. *Obstet Gynecol* 2007;109(6):1421–3. doi:10.1097/01.AOG.0000265807.19397.6d.
39. NIEBOER TE, JOHNSON N, LETHABY A, TAVENDER E, CURR E, GARRY R et al. Surgical approach to hysterectomy for benign gynaecological disease. *Cochrane Database Syst Rev* 2009(3):CD003677. doi:10.1002/14651858.CD003677.pub4.
40. OECD DATA. Life expectancy at birth. [accessed 25, August 2016]; Available from: <https://data.oecd.org/healthstat/life-expectancy-at-birth.htm>.
41. OLIVE DL, SCHWARTZ LB. Endometriosis. *N Engl J Med* 1993;328(24):1759–69. doi:10.1056/NEJM199306173282407.



42. OSADA H, SILBER S, KAKINUMA T, NAGAISHI M, KATO K, KATO O. Surgical procedure to conserve the uterus for future pregnancy in patients suffering from massive adenomyosis. *Reprod Biomed Online* 2011;22(1):94–9. doi:10.1016/j.rbmo.2010.09.014.
43. PRACTICE COMMITTEE OF AMERICAN SOCIETY FOR REPRODUCTIVE MEDICINE. Treatment of pelvic pain associated with endometriosis. *Fertil Steril* 2008;90(5 Suppl):S260–9. doi:10.1016/j.fertnstert.2008.08.057.
44. REICH H. Laparoscopic oophorectomy and salpingo-oophorectomy in the treatment of benign tubo-ovarian disease. *Int J Fertil* 1987;32(3):233–6.
45. ROOVERS JP, VAN DER BOM JG, VAN DER VAART CH, HEINTZ AP. Hysterectomy and sexual wellbeing: prospective observational study of vaginal hysterectomy, subtotal abdominal hysterectomy, and total abdominal hysterectomy. *BMJ* 2003;327(7418):774–8. doi:10.1136/bmj.327.7418.774.
46. SARMINI OR, LEFHOLZ K, FROESCHKE HP. A comparison of laparoscopic supracervical hysterectomy and total abdominal hysterectomy outcomes. *J Minim Invasive Gynecol* 2005;12(2):121–4. doi:10.1016/j.jmig.2005.01.019.
47. SCHINDLER AE. Kombiniertes chirurgisch-hormonelles Management der Endometriose. Langzeit Follow-up. *Zentralbl Gynakol* 1999;121(7):325–9.
48. SCHOLLMEYER T, ELESSAWY M, CHASTAMOURATIDHS B, ALKATOUT I, MEINHOLD-HEERLEIN I, METTLER L et al. Hysterectomy trends over a 9-year period in an endoscopic teaching center. *Int J Gynaecol Obstet* 2014;126(1):45–9. doi:10.1016/j.ijgo.2013.12.017.
49. SCHÜSSLER, B., Scheidel, P., Hohl, MK. Hysterektomie Update. *Frauenheilkunde aktuell* 2008;3:4–12.
50. SEMM K. Hysterectomy via laparotomy or pelviscopy. A new CASH method without colpotomy. *Geburtshilfe Frauenheilkd* 1991;51(12):996–1003. doi:10.1055/s-2008-1026252.
51. SHENG J, ZHANG WY, ZHANG JP, LU D. The LNG-IUS study on adenomyosis: a 3-year follow-up study on the efficacy and side effects of the use of levonorgestrel intrauterine system for the treatment of dysmenorrhea associated with adenomyosis. *Contraception* 2009;79(3):189–93. doi:10.1016/j.contraception.2008.11.004.
52. SINAII N, PLUMB K, COTTON L, LAMBERT A, KENNEDY S, ZONDERVAN K et al. Differences in characteristics among 1,000 women with endometriosis based on extent of disease. *Fertil Steril* 2008;89(3):538–45. doi:10.1016/j.fertnstert.2007.03.069.
53. STANG A, MERRILL RM, KUSS O. Hysterectomy in Germany: a DRG-based nationwide analysis, 2005–2006. *Dtsch Arztebl* 2011;108(30):508–14. doi:10.3238/arztebl.2011.0508.
54. STEGMANN BJ, SINAII N, LIU S, SEGARS J, MERINO M, NIEMAN LK et al. Using location, color, size, and depth to characterize and identify endometriosis lesions in a cohort of 133 women. *Fertil Steril* 2008;89(6):1632–6. doi:10.1016/j.fertnstert.2007.05.042.
55. TARAN FA, WEAVER AL, CODDINGTON CC, STEWART EA. Understanding adenomyosis: a case control study. *Fertil Steril* 2010;94(4):1223–8. doi:10.1016/j.fertnstert.2009.06.049.
56. TAYLOR E, WILLIAMS C. Surgical treatment of endometriosis: location and patterns of disease at reoperation. *Fertil Steril* 2010;93(1):57–61. doi:10.1016/j.fertnstert.2008.09.085.
57. TEMPLEMAN C, MARSHALL SF, URSIN G, HORN-ROSS PL, CLARKE CA, ALLEN M et al. Adenomyosis and endometriosis in the California Teachers Study. *Fertil Steril* 2008;90(2):415–24. doi:10.1016/j.fertnstert.2007.06.027.
58. THAKAR R, AYERS S, CLARKSON P, STANTON S, MANYONDA I. Outcomes after total versus subtotal abdominal hysterectomy. *N Engl J Med* 2002;347(17):1318–25. doi:10.1056/NEJMoa013336.
59. THOMPSON, J.D. and J. Warshaw. Hysterectomy. In: Rock JA, Thompson JD, editors. *Te Linde's Operative Gynecology*. Philadelphia-New York: Lippincott Raven; 1996. p. 771–854.
60. TSUI KH, LEE FK, SEOW KM, CHANG WC, WANG JW, CHEN SU et al. Conservative surgical treatment of adenomyosis to improve fertility: Controversial values, indications, complications, and pregnancy outcomes. *Taiwan J Obstet Gynecol* 2015;54(6):635–40. doi:10.1016/j.tjog.2015.05.003.
61. VAN HERENDAEL B. Strategies to prevent vaginal vault descent during hysterectomy. In: Mettler L, editor. *Manual of New Hysterectomy Techniques*. New Delhi: Jaypee Brothers Medical Publishers; 2007. p. 82–5.
62. VERCELLINI P, CONSONNI D, DRIDI D, BRACCO B, FRATTARUOLO MP, SOMIGLIANA E. Uterine adenomyosis and in vitro fertilization outcome: a systematic review and meta-analysis. *Hum Reprod* 2014;29(5):964–77. doi:10.1093/humrep/deu041.
63. VERESS J. Neues Instrument zur Ausführung von Brust- und Bauchpunktionen und Pneumothoraxbehandlung. *Deutsche medizinische Wochenschrift* 1938;64:1480–1.
64. WONG CL, FARQUHAR C, ROBERTS H, PROCTOR M. Oral contraceptive pill as treatment for primary dysmenorrhoea. *Cochrane Database Syst Rev* 2009(2):CD002120. doi:10.1002/14651858.CD002120.pub2.
65. WYKES CB, CLARK TJ, KHAN KS. Accuracy of laparoscopy in the diagnosis of endometriosis: a systematic quantitative review. *BJOG* 2004;111(11):1204–12. doi:10.1111/j.1471-0528.2004.00433.x.
66. YEUNG PP JR, SHWAYDER J, PASIC RP. Laparoscopic management of endometriosis: comprehensive review of best evidence. *J Minim Invasive Gynecol* 2009;16(3):269–81. doi:10.1016/j.jmig.2009.02.007.
67. ZUPI E, MARCONI D, SBRACIA M, ZULLO F, VIVO B DE, EXACUSTOS C et al. Add-back therapy in the treatment of endometriosis-associated pain. *Fertil Steril* 2004;82(5):1303–8. doi:10.1016/j.fertnstert.2004.03.062.

## 3.6

## Extragenital Endometriosis

Daniela Hornung<sup>a, b</sup>

## 3.6.1 Introduction

Endometriosis is a very common gynecological disease defined as the presence of functional endometrial-like tissue outside the uterus. Although generally confined to the pelvis, ectopic endometrium may also be detected at extrapelvic sites, such as umbilicus, abdominal scars, respiratory system, and even in the brain and eyes. Apart from the spleen, the disease can be found in virtually any tissue of the body. The true incidence of extrapelvic disease is still unknown and its frequency seems to decrease with the distance from pelvis.<sup>31</sup> *Nisolle et al.* (2007) report a frequency of approximately 5%.<sup>22</sup> Endometriosis-related symptoms may include cyclic pain, at least in early stages of the disease, but may also present as bleeding and chronic pain. In patients with extragenital endometriotic lesions, the mean age for diagnosis (35–40 years) is approximately 5 years older than that reported for genital endometriotic lesions.<sup>11</sup> The treatment of choice is complete excision, whenever possible; otherwise, long-term medical therapy with gestagens, continuous regimens of oral contraceptives (OC) or GnRH analogues may be offered to the patient.<sup>10</sup>

Since extragenital endometriosis is a very rare condition, mainly collections of anecdotal case reports or case series are available so far, but no comparative studies. Several reviews about extragenital endometriosis have been published in the pertinent literature.<sup>5,16,17,22</sup>

The diagnosis is difficult, since the physicians consulted (f.e. general practitioner, neurologist, pulmonologist, etc.) are not familiar with the specific challenges inherent to the disease. Imaging modalities like CT or MRI can be helpful, which particularly applies to brain endometriosis. The use of thorascopy or bronchoscopy is capable of detecting pulmonary endometriosis, whereas only histopathological examination can finally confirm the presence of disease at extragenital sites.

a | University of Lübeck, Department of Obstetrics and Gynecology, Lübeck, Germany

b | Professor, MD; Head of Department of Gynecology and Obstetrics, Diakonissenkrankenhaus, Karlsruhe-Rüppurr, Germany

**Corresponding author:**

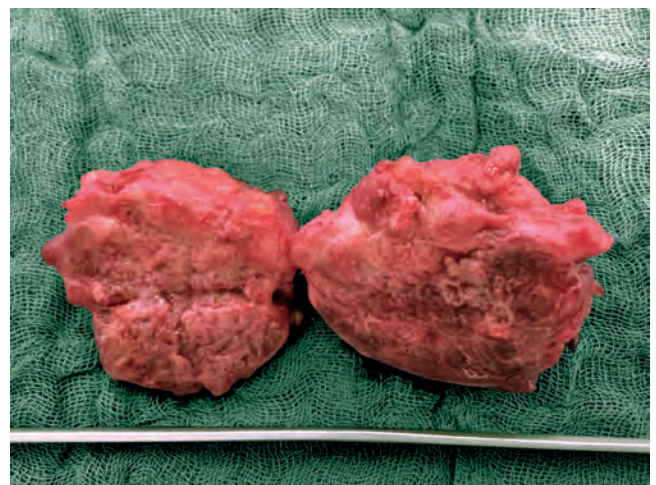
Klinik für Gynäkologie und Geburtshilfe mit Hebammenschule  
Leitung: Prof. Dr. med. **Daniela Hornung**  
Ev. Diakonissenkrankenhaus Karlsruhe-Rüppurr  
Diakonissenstraße 28  
76199 Karlsruhe, Germany  
E-mail: D.Hornung@gmx.de

**Locations of extragenital endometriosis**

- Abdominal wall, umbilical, (cesarean) scar endometriosis.
- Appendiceal endometriosis.
- Diaphragmatic, thoracic and pulmonal endometriosis.
- Renal endometriosis.
- Cerebral and cerebellar endometriosis
- Nasolacrimal endometriosis.

**3.6.2 Endometriosis of the Abdominal Wall, Umbilicus and Surgical (Cesarean) Scar**

Functional endometrial tissue can be found in the abdominal wall, especially, but not exclusively in surgical incisions, umbilicus or inguinal canal. In women with a medical history of gynecological surgery, the lesions can appear in scars after previous myomectomies, caesarean sections (Fig. 3.122) or episiotomies,<sup>12</sup> even though such findings may also be encountered in patients who lack a specific surgical history.<sup>24</sup> The varying appearance of endometriosis can be appreciated as dark red-blue or brown, tender nodules. Among the characteristics of symptoms are pain episodes or even bleeding synchronous with the menstrual cycle. Surgical therapy includes complete resection. In rare cases of endometriotic infiltration of the aponeurosis, extensive mobilization of its remnant is required in order to accomplish a tension-free closure. Occasionally, the need may arise to cover the defect with a synthetic patch, which is essential for successful closure of the abdominal wall. In case of extensive umbilical endometriosis, the formation of a 'neo-umbilicus' can become necessary.



**Fig. 3.122** Endometriosis of the abdominal scar after cesarean section (endometriotic tissue sample, 5 cm in diameter). The fascia was completely infiltrated by disease, so extensive dissection of the residual fascia was required to close the defect at the end of surgery. In other cases, placement of a synthetic patch can be indicated.



### 3.6.2.1 Endometriosis of the Appendix

The first description of appendiceal endometriosis was published by *von Rokitansky* in 1860.<sup>25</sup> Usually, the diagnosis is made incidentally during laparoscopy performed for other reasons. Only in rare cases, patients present with acute abdominal pain mimicking acute appendicitis. Other clinical appearances may be lower gastrointestinal bleeding, intestinal perforation or intestinal obstruction.<sup>32</sup> In a study published by *Chandrasegaram et al.* in 2012, 14 out of 4670 (0.3%), patients had their appendices removed on the basis of a confirmed diagnosis of endometriosis.<sup>7</sup> In a different retrospective study of *Yoon et al.* (2014), only 5 out of 2173 (0.2%) women underwent appendectomy for appendiceal endometriosis, but in the latter study – unlike that of *Chandrasegaram et al.* – patients, who had been treated for intra-abdominal endometriosis other than that of the appendix, were excluded.<sup>32</sup>

Accordingly, it can be concluded that appendiceal endometriosis is of rare occurrence. In any case, irrespective of whether the patient is identified as symptomatic or not, the appendix should be removed laparoscopically, which commonly involves the use of a stapling technique. In most cases, however, appendiceal endometriosis is detected in patients with other forms of peritoneal endometriosis and especially in those with bowel endometriosis, which is why careful inspection of the appendix should be an integral part of any endometriosis surgery.

### 3.6.2.2 Diaphragmatic, Thoracic and Pulmonary Endometriosis

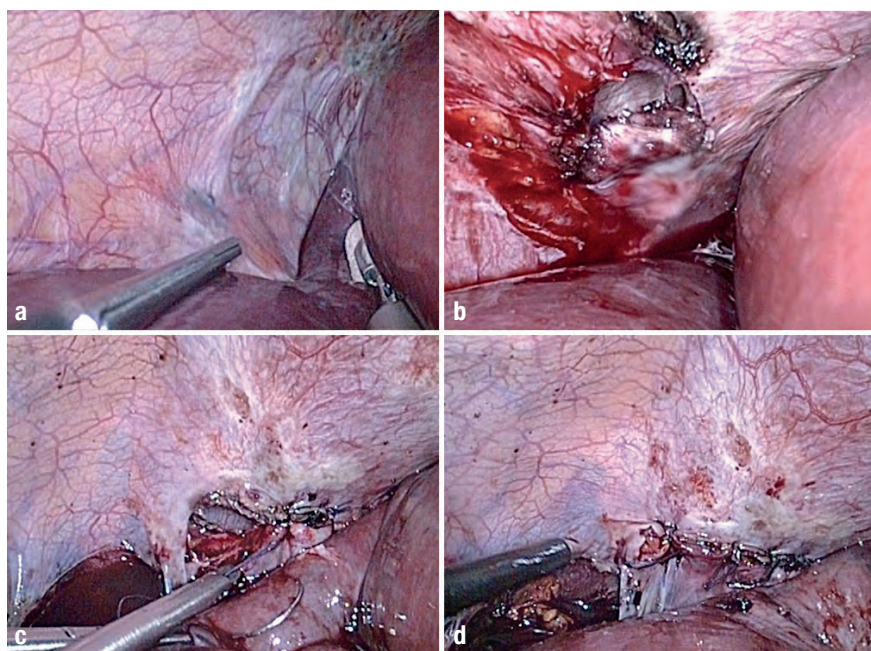
Particularly the thorax is an uncommon site for manifestation of endometriosis. This rare condition is characterized by the presence of endometrial tissue in the diaphragm, the lung parenchyma or the airways. It mainly affects women of reproductive age, often nulliparas, and long-standing symptoms are usually related to menses.<sup>3</sup> About 80% of women with thoracic endometriosis have concomitant abdominopelvic endometriosis.<sup>20</sup> The first case of pulmonary endometriosis was described by *Barnes* in 1953.<sup>4</sup>

Diaphragmatic endometriosis is often associated with cyclic right sided shoulder pain (40%), whereas lung endometriosis can be suspected if cyclic haemoptysis (12%), catamenial pneumothorax (24%) and catamenial chest pain (80%) is reported. Other symptoms include shortness of breath, pain with inspiration and bloody taste of sputum. Sputum cytology is capable of confirming the presence of endometrial cells.

In 90–95% of cases, the right hemi-thorax is involved.<sup>14</sup>

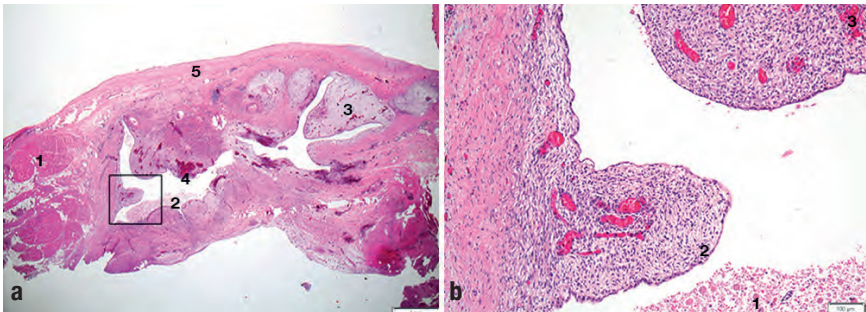
Among the operative treatment options available for pulmonic endometriosis, video-assisted thoracoscopic surgery (VATS) with fulguration of lesions by use of bipolar electrocautery is recommended. Occasionally, a pleurodesis may be required at the end of the procedure. In case of recurrence, pleural abrasion or pleurectomy can be helpful. Persistent haemoptysis can be treated by lobectomy, segmentectomy or tracheobronchoscopic laser ablation.<sup>22</sup>

In cases of diaphragmatic endometriosis, large endometriotic nodules infiltrate from the peritoneum into the diaphragmatic tissue (Fig. 3.123, from *Silveira et al.*, 2011).<sup>27</sup> The implants should be resected completely and the defect closed by multiple single sutures. In most cases, only a small pneumothorax is encountered, so there is no need for placing an indwelling chest drain. In order to check for signs of possible pulmonary complications, a thorax radiograph should be taken in the immediate postoperative period and a few days after surgery (Fig. 3.124, from *Silveira et al.*, 2011).<sup>27</sup> In the tissue samples obtained in the course of the procedure, endometrial glands are surrounded by a wide stroma containing small mesenchymal cells and fibrosis. In the clinical case presented herein, multiple hemosiderin-laden macrophages and hemorrhagic foci are clearly visible in the luminal region (Fig. 3.125, from *Silveira et al.*, 2011).<sup>27</sup>

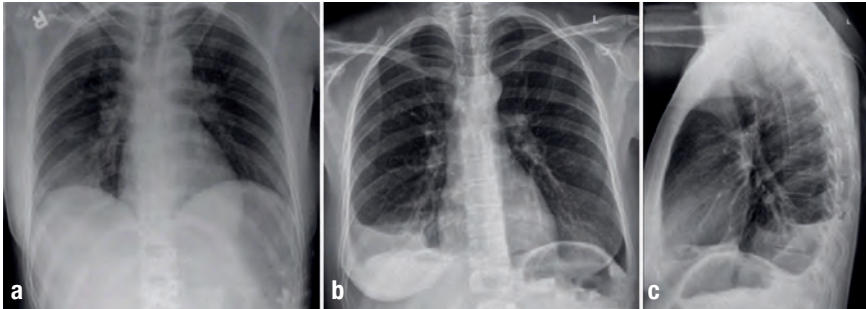


**Fig. 3.123** Intraoperative inspection of the upper right abdominal quadrant (a) shows endometriotic foci infiltrating the diaphragm. After laparoscopic resection of the endometriotic implant (b), the resulting surgical defect was closed with five single sutures (c, d). No indwelling pleural drain was needed (Courtesy of *Silveira et al.*, 2011).<sup>27</sup>





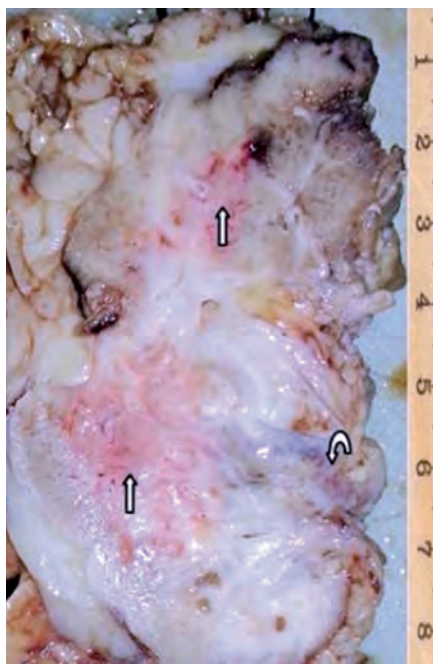
**Fig. 3.124** Endometrial tissue infiltrating from peritoneum into the diaphragm. Shown in panel (a) are endometrial cysts (2) that are in close proximity to the striated diaphragm muscle (1). Note the dilated vessels (3) in the endometrial stroma. Extravasated erythrocytes (4) are surrounded by peritoneal serosa (5). The close-up view in panel (b) (see square in panel a) shows in greater detail the cellular debris and macrophages (1), endometrial stroma (2), and hemorrhagic foci (3) (Courtesy of *Silveira et al.*, 2011).<sup>27</sup>



**Fig. 3.125** Thoracic radiographs taken immediately (a) and three days (b, c) after surgery confirming regression of pleural effusion as a result of the surgical procedure (Courtesy of *Silveira et al.*, 2011).<sup>27</sup>

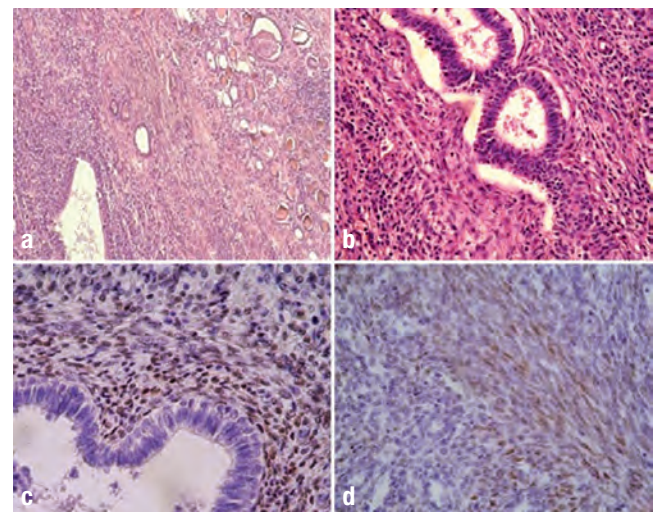
### 3.6.2.3 Renal Endometriosis

Only a small proportion of cases of endometriosis are detected in the urinary tract (0.1–1%) and the potential presence of subclinical disease seems to be under-appreciated.<sup>2</sup> The predilection sites and relative frequencies of urinary tract endometriosis are bladder (80–84%), ureter (14%), kidney (4%), and urethra (2%), at an approximate ratio of 40:5:1:1, respectively.<sup>9,18</sup>



**Fig. 3.126** Macroscopic appearance of a bisected kidney. The cortical surface is irregular and contracted. The renal parenchyma appears with multiple erythematous patches (straight arrows). The curved arrow marks the renal pelvic urothelium (Courtesy of *Cheng et al.*, 2015).<sup>8</sup>

The presence of endometriosis in the kidney is extremely rare (Figs. 3.126, 3.127, from *Cheng et al.*, 2015).<sup>8</sup> Among the cases of urinary tract endometriosis, only a few involve the kidney. Renal endometriosis can be difficult to diagnose and definitive diagnosis is based on histopathological findings. Medical therapy with gestagens or oral contraceptives may be indicated or even a hysterectomy with bilateral

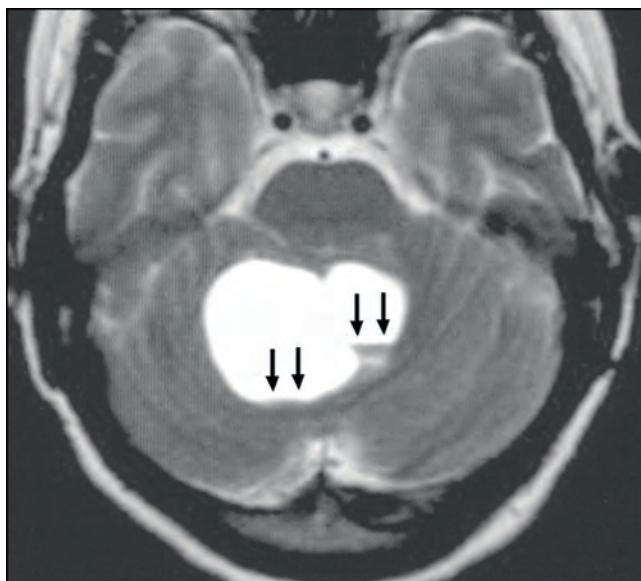


**Fig. 3.127** Photomicrographs of sections of kidney. Shown in panel (a) are endometrial glands and stroma with thyroidization of adjacent tubules and chronic inflammatory infiltrates in the interstitium; hematoxylin and eosin stain (H&E), ×100 magnification. In panel (b), note there are endometrial glands, stromal cells and spiral arterioles; H&E, ×200 magnification. Panel (c) shows positive staining for estrogen receptors in stromal cell nuclei; immunohistochemical method (IHC), ×200 magnification. In panel (d), there is positive staining for progesterone receptors in stromal cell nuclei; IHC, ×200 magnification (Courtesy of *Cheng et al.*, 2015).<sup>8</sup>

salpingo-oophorectomy. The decision on whether to perform nephrectomy is determined by the level of renal function. Although extremely rare, renal endometriosis should be included in the range of differential diagnosis when faced with the presence of a contracted, non-functioning kidney. Early diagnosis can prevent the need for nephrectomies in cases of uncomplicated renal endometriosis.

Common manifestations of renal endometriosis are local pain and, rarely, cyclical hematuria, which is more common if the ureter and/or bladder are affected by disease. Most patients have normal findings on physical examination, unless other pathologic conditions are encountered. Renal endometriosis typically develops unobtrusively and remains inappreciable for many years before the diagnosis is made. Occasionally, the lesion may be completely asymptomatic and diagnosed incidentally after nephrectomy for other indications, such as cancer. Imaging techniques may be used to confirm a clinical diagnosis, but evidence is rarely conclusive enough to suggest the presence of endometriosis. Definitive diagnosis is commonly established as a result of histopathological examination, which provides proof of endometrial glands and stroma in the specimen.

Treatment of renal endometriosis is determined by the state of the kidney, severity of symptoms, extent of the disease, age of the patient, and by whether pregnancy is planned or desired. Hormone therapy involves the use of GnRH agonists, estrogen-progestin combinations, and progestin alone. Hormone therapy is optimal for patients of child-bearing age, who wish to retain reproductive capability and for those with normal renal function. If the patient does not want to become pregnant, a total abdominal hysterectomy with bilateral salpingo-oophorectomy can be performed with or without adjuvant hormone therapy. Whether a nephrectomy is required should be determined according to the level of renal function.



**Fig. 3.128** Axial T2-weighted fast spin-echo MR image shows fluid-fluid levels in cystic mass, dependent fluid being hypointense on this sequence (**arrows**). These features are suggestive of previous intracystic hemorrhage, and their MRI appearance is similar to that described for pelvic endometriomas ('shading' sign) (By courtesy of *Sarma et al.*, 2003).<sup>26</sup>

#### 3.6.2.4 Cerebral and Cerebellar Endometriosis

With regard to endometriosis of the brain and cerebellum, based on the author's current knowledge, only three case reports have been published so far in the English literature.<sup>15,26,29</sup> Patients most commonly present with headaches and seizures. MRI scans show hypointense fluid levels in the dependent layer, with shading sign or evidence of hemorrhage in cystic lesions, the latter being hyperintense on T1-weighted and hypointense on T2-weighted images (**Fig. 3.128**, from *Sarma et al.*, 2003).<sup>26</sup>

Surgical treatment of cerebral and cerebellar endometriosis is undertaken by neurosurgeons and includes complete resection of the mass.

#### 3.6.2.5 Nasolacrimal Endometriosis

Cyclic bleeding from the inferior punctum of the eye synchronous with menstruation and coexisting crusted hemorrhage in the tear meniscus and inferior to the caruncle, may be interpreted as signs and symptoms suggestive of nasolacrimal endometriosis. MRI scans should allow to delineate the extent of disease before proceeding with a complete surgical excision of the lesion which is performed by an otorhinolaryngologist.<sup>30</sup>

### 3.6.3 Discussion

Endometriosis of surgical scars should always be considered in surgical practice when faced with extensive formation of scar tissue of the abdominal wall. The major goal of therapy is to excise the mass as completely as possible. Patients should be alerted to the risk of malignancy that may arise from the scar if surgical excision is declined.

The clockwise flow of peritoneal fluid in the abdomen (down the left peritoneal gutter over the pelvic floor and up the right peritoneal gutter to the subdiaphragmatic space) together with the piston-like effect of the liver is believed to account for the mainly right-sided location of a catamenial pneumothorax. As in the case of right sided catamenial pneumothorax, the right diaphragm and pleura seem to be sites of predilection for endometriotic lesions. The right-sided predominance has also been confirmed in a paper of *Nezhat et al.* (1998)<sup>21</sup>: 'Lesions were bilateral in 8 patients, limited to the right hemidiaphragm in 14 patients, and limited to the left hemidiaphragm in 2 patients.'

On the other hand, the potential hematogenous or lymphatic spread of viable endometrial cells has also been widely considered as a pathogenetic mechanism underlying the development of these distant lesions, mainly in patients with previous history of surgery or childbirth.<sup>23,28</sup> Even though symptomatology of extrapelvic endometriosis (including thoracic disease) is usually associated with menstrual cycle and the site of manifestation, this does not necessarily mean that such correlation exists in all patients.<sup>17</sup> Moreover, the related symptoms can also overlap with other pathologies, making diagnosis a challenging task.<sup>3</sup> Particularly, pleural endometriosis is usually suspected when patients frequently report on cyclic symptoms of chest pain and dyspnea, accompanied by concomitant pulmonary complications such



as pneumothorax or hemothorax. A chest radiograph of the lung or a chest CT scan may reveal pulmonary opacities and nodular lesions, however, the use of these imaging modalities is mainly indicated in the presence of pulmonary symptoms.<sup>13</sup> Apart from that, considering the large variety of possible morphologic appearances of endometriotic implants, there are no pathognomonic findings that would allow to reliably distinguish either pelvic or extrapelvic endometriosis from other processes. Therefore, in order to establish a definitive diagnosis of the disease, a detailed clinical history in conjunction with surgical inspection and histological confirmation may often be needed.<sup>3</sup>

In fact, surgical intervention still remains the gold standard for the diagnosis of thoracic endometriosis, and a systematic and accurate inspection of the abdominal cavity should always be an integral part of laparoscopic evaluation, especially in women with pain symptoms and a previous history of endometriosis.<sup>21</sup> According to our experience, a systematic surgical approach is critical in that it allows to identify any suspicious findings on diaphragmatic tissue, which otherwise may be missed when using imaging analysis alone.

Both detailed anamnesis and accurate surgical inspection are the gold standard in the diagnosis of endometriosis. Occasionally, deep implants may only be identified and treated accordingly when the patient's position at laparoscopy has changed from head-down to head-up and she has been turned to the left side.

A lively debate is currently going on with regard to optimal management of thoracic endometriosis, including pleural and diaphragmatic disease. Medical therapy has long been considered as the first-line option in case of pulmonary complications (such as pneumothorax) achieving long-term amenorrhea by the use of medical hormonal regimens, however, these modalities have not been shown to prevent subsequent recurrence of disease.<sup>16</sup> Accordingly, surgical treatment is currently recommended mainly in cases refractory to medical therapy, intolerable adverse effects, symptom recurrence after cessation of treatment, or in patients who wish to conceive.<sup>1</sup>

Undoubtedly, diaphragmatic endometriosis is often difficult to manage surgically, and a multidisciplinary approach is of key importance to remove all clinically suspicious foci of endometriosis as well as to treat the associated symptoms. Patients suffering from pleural involvement may exhibit pneumothorax or pleural effusion, and therefore, surgical excision of endometriotic foci is usually performed in combination with placement of an indwelling chest tube or by use of pleurodesis.<sup>6,19</sup> However, conservative surgery by laparoscopy alone may also be used successfully in patients with pleural endometriosis to prevent the need for additional procedures and to avoid the occurrence of postoperative pulmonary complications.

Diagnosis of renal endometriosis is a challenging task. Final diagnosis should be established on the basis of histopathologic findings. Treatment may include hormone therapy or hysterectomy with bilateral salpingo-oophorectomy.

The decision as to whether a nephrectomy is required depends on the level of renal function. Although extremely rare, renal endometriosis should be included in the range of differential diagnosis when faced with a contracted, non-functioning kidney. Early diagnosis can prevent the need for nephrectomies in patients who have an uncomplicated form of renal endometriosis.

Endometriosis of the brain is a rare condition that can occur without cyclical symptoms related to menstruation. The shading sign on MRI or any other evidence of hemorrhage in a cystic lesion in a female patient should alert the radiologist to the possibility of endometriosis, even at unusual sites. The final diagnosis in such rare locations can, of course, only be obtained by histopathological examination.

### 3.6.4 Conclusion

In conclusion, great care should be paid to take a thorough anamnesis, particularly in patients who suffer from recurrent, unusual endometriosis-related symptoms and a known history of endometriosis. However, a tentative diagnosis of extragenital endometriosis should be considered even in the absence of a known history of pelvic endometriosis. Management should include a systematic investigation, geared toward detecting endometriotic implants at extrapelvic sites.

Extrapelvic endometriosis is an uncommon condition typically associated with a host of varying symptoms and a complex diagnostic workup.

Treatment includes excision of the implants, wherever possible, and usual medical long-term treatment with COCs, gestagens or GnRH analogues.

### 3.6.5 References

- ALIFANO M, TRISOLINI R, CANCELLIERI A, REGNARD JF. Thoracic endometriosis: current knowledge. *The Annals of thoracic surgery* 2006;81(2):761–9. doi:10.1016/j.athoracsur.2005.07.044.
- AL-KHAWAJA M, TAN PH, MACLENNAN GT, LOPEZ-BELTRAN A, MONTIRONI R, CHENG L. Uteral endometriosis: clinicopathological and immunohistochemical study of 7 cases. *Human pathology* 2008;39(6):954–9. doi:10.1016/j.humpath.2007.11.011.
- AUGOULEA A, LAMBRINOUDAKI I, CHRISTODOULAKOS G. Thoracic endometriosis syndrome. *Respiration; international review of thoracic diseases* 2008;75(1):113–9. doi:10.1159/000105102.
- BARNES J. Endometriosis of the pleura and ovaries. *The Journal of obstetrics and gynaecology of the British Empire* 1953;60(6):823–4.
- BERGQVIST A. Different types of extragenital endometriosis: a review. *Gynecological endocrinology the official journal of the International Society of Gynecological Endocrinology* 1993;7(3):207–21.
- BHOJAWALA J, HELLER DS, CRACCHIOLO B, SAMA J. Endometriosis presenting as bloody pleural effusion and ascites—report of a case and review of the literature. *Archives of gynecology and obstetrics* 2000;264(1):39–41.
- CHANDRASEGARAM MD, ROTHWELL LA, AN EI, MILLER RJ. Pathologies of the appendix: a 10-year review of 4670 appendectomy specimens. *ANZ journal of surgery* 2012;82(11):844–7. doi:10.1111/j.1445-2197.2012.06185.x.



8. CHENG CH, KUO HC, SU B. Endometriosis in a kidney with focal xanthogranulomatous pyelonephritis and a perinephric abscess. *BMC research notes* 2015;8:591. doi:10.1186/s13104-015-1574-1.
9. DIRIM A, CELIKKAYA S, AYGUN C, CAYLAK B. Renal endometriosis presenting with a giant subcapsular hematoma: case report. *Fertility and sterility* 2009;92(1):391.e5-7. doi:10.1016/j.fertnstert.2009.04.013.
10. DUNSELMAN GA, VERMEULEN N, BECKER C, CALHAZ-JORGE C, D'HOOGHE T, BIE B DE et al. ESHRE guideline: management of women with endometriosis. *Human reproduction (Oxford, England)* 2014;29(3):400–12. doi:10.1093/humrep/det457.
11. DUTTA P, BHAT MH, BHANSALI A, KUMAR V. A young woman with endometriosis of kidney. *Saudi medical journal* 2006;27(2):244–6.
12. ECKER AM, DONNELLAN NM, SHEPHERD JP, LEE TT. Abdominal wall endometriosis: 12 years of experience at a large academic institution. *American journal of obstetrics and gynecology* 2014;211(4):363.e1-5. doi:10.1016/j.ajog.2014.04.011.
13. FOSTER DC, STERN JL, BUSCEMA J, ROCK JA, WOODRUFF JD. Pleural and parenchymal pulmonary endometriosis. *Obstetrics and gynecology* 1981;58(5):552–6.
14. HILARIS GE, PAYNE CK, OSIAS J, CANNON W, NEZHAT CR. Synchronous rectovaginal, urinary bladder, and pulmonary endometriosis. *JSLs Journal of the Society of Laparoendoscopic Surgeons/Society of Laparoendoscopic Surgeons* 2005;9(1):78–82.
15. ICHIDA M, GOMI A, HIRANOUCHE N, FUJIMOTO K, SUZUKI K, YOSHIDA M et al. A case of cerebral endometriosis causing catamenial epilepsy. *Neurology* 1993;43(12):2708–9.
16. JOSEPH J, SAHN SA. Thoracic endometriosis syndrome: new observations from an analysis of 110 cases. *The American journal of medicine* 1996;100(2):164–70.
17. JUBANYIK KJ, COMITE F. Extrapelvic endometriosis. *Obstetrics and gynecology clinics of North America* 1997;24(2):411–40.
18. MACCAGNANO C, PELLUCCHI F, ROCCHINI L, GHEZZI M, SCATTONI V, MONTORSI F et al. Ureteral endometriosis: proposal for a diagnostic and therapeutic algorithm with a review of the literature. *Urologia internationalis* 2013;91(1):1–9. doi:10.1159/000345140.
19. MOFFATT SD, MITCHELL JD. Massive pleural endometriosis. *European journal of cardio-thoracic surgery official journal of the European Association for Cardio-thoracic Surgery* 2002;22(2):321–3.
20. NEZHAT C, MAIN J, PAKA C, NEZHAT A, BEYGUI RE. Multidisciplinary treatment for thoracic and abdominopelvic endometriosis. *JSLs Journal of the Society of Laparoendoscopic Surgeons/Society of Laparoendoscopic Surgeons* 2014;18(3). doi:10.4293/jsls.2014.00312.
21. NEZHAT C, SEIDMAN DS, NEZHAT F. Laparoscopic surgical management of diaphragmatic endometriosis. *Fertility and sterility* 1998;69(6):1048–55.
22. NISOLLE M, PASLEAU F, FOIDART JM. [Extragenital endometriosis]. *Journal de gynécologie, obstétrique et biologie de la reproduction* 2007;36(2):173–8. doi:10.1016/j.jgyn.2006.12.010.
23. PARK WW. The occurrence of decidual tissue within the lung; report of a case. *The Journal of pathology and bacteriology* 1954;67(2):563–70.
24. PRAMANIK SR, MONDAL S, PAUL S, JOYCERANI D. Primary umbilical endometriosis: A rarity. *Journal of human reproductive sciences* 2014;7(4):269–71. doi:10.4103/0974-1208.147495.
25. ROKITANSKY CV. Über Uterusdrüsen-Neubildung in Uterus- und Ovarial-Sarcomen. *Zeitschrift der Gesellschaft der Aerzte* 1860(16):577–81.
26. SARMA D, IYENGAR P, MAROTTA TR, TERBRUGGE KG, GENTILI F, HALLIDAY W. Cerebellar endometriosis. *AJR. American journal of roentgenology* 2004;182(6):1543–6. doi:10.2214/ajr.182.6.1821543.
27. SILVEIRA CGT, AGIC A, KLEEMANN M, MERZ H, HORNUNG D. Laparoscopic management of phrenic endometriosis. *Journal of Endometriosis* 2011;3(4):213–7.
28. TERADA Y, CHEN F, SHOJI T, ITOH H, WADA H, HITOMI S. A case of endobronchial endometriosis treated by subsegmentectomy. *Chest* 1999;115(5):1475–8.
29. THIBODEAU LL, PRIOLEAU GR, MANUELIDIS EE, MERINO MJ, HEAFNER MD. Cerebral endometriosis. Case report. *Journal of neurosurgery* 1987;66(4):609–10. doi:10.3171/jns.1987.66.4.0609.
30. TURKCUOGLU I, TURKCUOGLU P, KURT J, YILDIRIM H. Presumed nasolacrimal endometriosis. *Ophthalmic plastic and reconstructive surgery* 2008;24(1):47–8. doi:10.1097/IOP.0b013e31815c9053.
31. WILLIAMS TJ, PRATT JH. Endometriosis in 1,000 consecutive celiotomies: incidence and management. *American journal of obstetrics and gynecology* 1977;129(3):245–50.
32. YOON J, LEE YS, CHANG HS, PARK CS. Endometriosis of the appendix. *Annals of surgical treatment and research* 2014;87(3):144–7. doi:10.4174/astr.2014.87.3.144.

## 3.7

## Laparoscopic Diagnosis and Treatment of Superficial Pelvic Endometriosis

Joseph Nassif<sup>a</sup> | Joe Eid<sup>a</sup> | Sally Khoury<sup>a</sup>

### 3.7.1 Introduction

In this chapter we will review the surgical steps involved in the laparoscopic diagnosis and treatment of pelvic endometriosis, excluding deep infiltrating endometriosis (DIE).

Guidelines issued by the European Society of Human Reproduction and Embryology (ESHRE) have defined laparoscopy as the modality of choice for the diagnosis of peritoneal endometriosis.<sup>6</sup> Though little has been published on its diagnostic value, laparoscopy enables the physician to make a more confident diagnosis based on biopsy samples and histology results. A systematic review published in 2004 showed that in women presenting with symptoms of endometriosis, a negative laparoscopic examination was very reliable for the exclusion of endometriosis.<sup>23</sup> Additionally, laparoscopy is the treatment modality of choice for the removal of peritoneal implants. When endometriosis is detected at diagnostic laparoscopy, it is recommended that the surgeon proceed with surgical treatment of the lesions. This will have a positive impact on long-term pain associated with endometriosis.<sup>11</sup> Three surgical treatment options are available: coagulation, laser vaporization, and surgical excision.

Unlike peritoneal endometriosis, ovarian endometriosis can be diagnosed by transvaginal ultrasound scanning, which can reveal all lesions except a small endometrioma.<sup>6,16</sup> The diagnosis in premenopausal women is based on features described as ground-glass echogenicity of the cyst fluid, one to four locules, and no solid parts.<sup>9</sup> Laparoscopy is necessary for the treatment of ovarian endometriomas. Laparoscopic cystectomy has been shown to be superior to other modalities such as drainage and coagulation.<sup>8,17</sup> Cystectomy is associated with lower rates of pain and other recurrent symptoms.

Laparoscopy is also used to increase pregnancy rates in infertile women suffering from endometriosis. Specifically, women with minimal or mild endometriosis will benefit from laparoscopic surgery with lysis of adhesions.<sup>10</sup> Pregnancy and live birth rates have been found to increase in these women. As stated previously, there is good evidence that excisional endometrioma surgery yields better outcomes than drainage and ablation in terms of disease recurrence, pain recurrence,

and subsequent spontaneous pregnancy rate in women who were previously subfertile.<sup>8</sup> However, several studies have shown that when compared with other techniques, the treatment of endometrioma by excision/stripping is associated with a decrease in ovarian reserve. This is true when compared with vaporization/coagulation<sup>21</sup> and with plasma energy ablation techniques.<sup>19</sup>

Furthermore, although single-port access laparoscopy (SPAL) ovarian cystectomy is comparable to conventional laparoscopy in terms of surgical outcomes, a recent study showed that single-port cystectomy is associated with a decrease in ovarian reserve and is not recommended for women who want to preserve their fertility.<sup>2</sup>

### 3.7.2 Laparoscopic Surgical Technique

#### 3.7.2.1 Diagnostic Assessment and Patient Preparation

Whether superficial endometriosis is treated for the purpose of relieving pain or improving fertility, laparoscopy is always necessary for an accurate diagnosis. Superficial endometriosis may be missed on physical examination and in many preoperative studies including ultrasound and pelvic MRI. Both diagnostic and therapeutic laparoscopy require adequate preparation. A fiber-free diet should be maintained for 3–5 days prior to laparoscopy to facilitate exposure. Bowel preparation with laxative macromolecules is unnecessary in most cases and may cause the adverse effect of bowel distention in some patients, which could hamper exposure during the surgical procedure. It may be necessary when a bowel resection is proposed, but this option is rarely indicated for superficial disease.

#### 3.7.2.2 Technique of Laparoscopic Entry

Following induction of general anesthesia, the patient is prepped and draped from the nipple line to the mid-thigh level. A direct access technique (with 5-mm or 10-mm trocars) or Veress needle can be used to create the pneumoperitoneum in an abdomen with no prior surgeries. If the patient has had previous open or laparoscopic surgery, it is best to start with a Veress needle introduced at Palmer's left subcostal point, where adhesions are less dense due to lung movements during respiration. Contraindications to this access point are as follows:

- Absence of an orogastric or nasogastric tube.
- Splenomegaly.
- Prior gastric surgery.
- Any incision in the left subcostal area.

<sup>a</sup> MD; Department of Obstetrics and Gynecology, American University of Beirut Medical Center, Beirut, Lebanon

#### Corresponding author:

Joseph A. Nassif, MD

American University of Beirut

Faculty of Medicine and Medical Center, Beirut, Lebanon

7 Dag Hammarskjöld Plaza

New York, NY, USA 10017

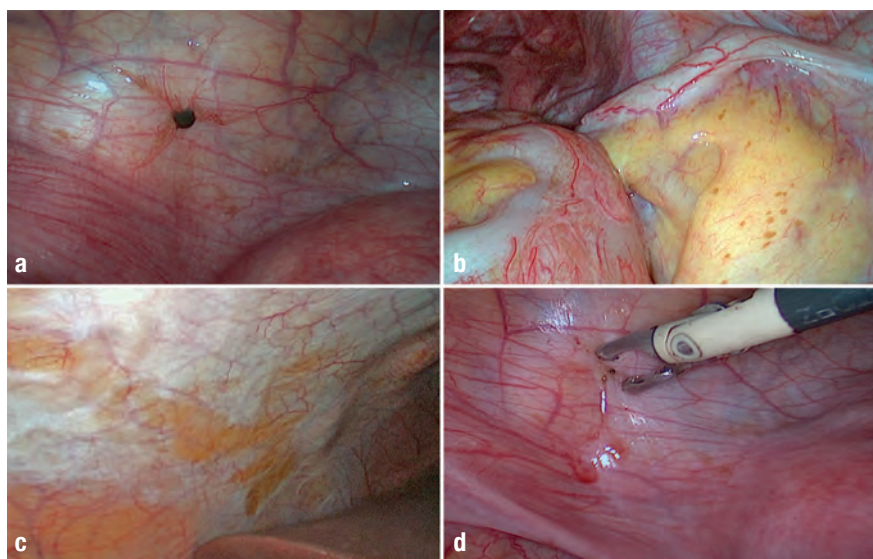
E-mail: jn25@aub.edu.lb

### 3.7.2.3 Safety Precautions and Initial Laparoscopic Inspection

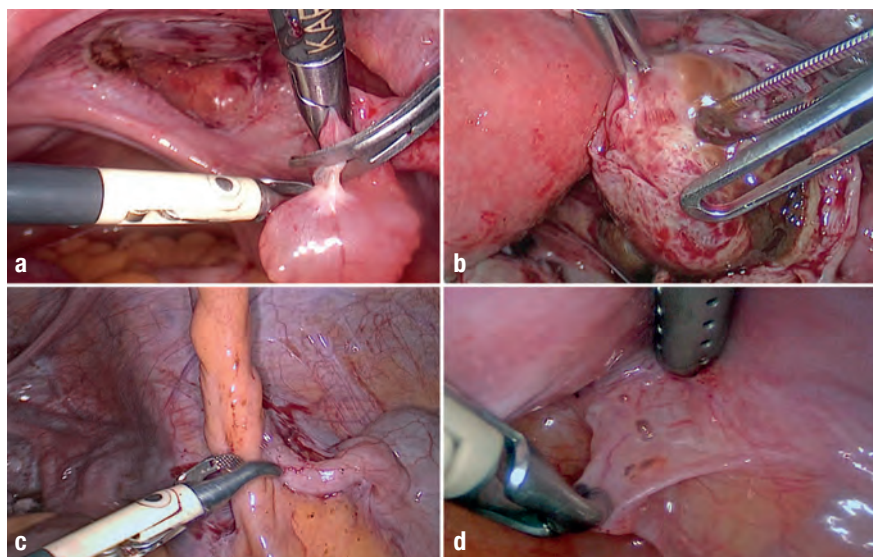
A safety check should be done when a Veress needle is used. The authors connect a 10-cc syringe to the Veress needle and raise the plunger. No fluid or gas should be aspirated at this time. Then, the syringe is disconnected, filled with air, and reconnected to the Veress needle. The air is pushed forcibly into the abdominal cavity while the other hand is placed on the abdominal wall to detect the thrill that confirms intraperitoneal placement of the needle tip. If needle insertion fails in two or three attempts, it is best to use a different access technique or different insertion site. Insufflation is done at a maximum flow rate until a steady state pressure of 12–14 mmHg is established within the abdominal cavity.

The normal pattern of insufflation starts with a low pressure (less than 10 mm Hg), a high insufflation rate and no volume of injected CO<sub>2</sub> until a pressure of 12 to 14 mmHg is reached, then final insufflation volume to 3–5 L as indicated on the insufflation monitor. At that point, the scope is introduced and the peritoneal cavity is fully explored. The patient can

be moved to the Trendelenburg position after insertion of the optical trocar to facilitate exposure. Meticulous inspection of the abdominal cavity and good documentation with still images, video sequences and/or a detailed description in the operative report are necessary for mapping the lesions in the event that reoperation is needed. The uterus, fallopian tubes, and ovaries should be closely inspected for the presence of implants or adhesions. The exploration should cover the ovarian fossae, uterosacral ligaments, cul-de-sac, vesicovaginal peritoneal fold, pelvic sidewalls, paracolic gutters, omentum, small bowel, colon, liver, and diaphragm. Superficial implants are variable in their shape, size, color, and location (Figs. 3.129–3.130). The nodules may be subcentimeter in scale, but it is not uncommon to find lesions up to several centimeters in diameter. Morphologically they may appear as fibrotic nodules, 'powder burns', or as filmy adhesions in the case of florid endometriosis on the bowel. Implants can vary in color from white (fibrotic implants) or pale red (resembling petechiae) to dark red, purple, or black.



**Fig. 3.129a–d** Florid peritoneal endometriotic lesion (a). Superficial endometriosis with multiple peritoneal lesions (b). Superficial patchy implants (c). Excision of superficial endometriotic lesion (d).



**Fig. 3.130a–d** Laparoscopic cystectomy of ovarian endometrioma (a). Laparoscopic drainage of ovarian endometrioma due to 'kissing' ovaries (b). Appendectomy with appendiceal peritoneum showing multiple superficial endometriotic lesions (c). Endometriosis in the cul de sac (d).



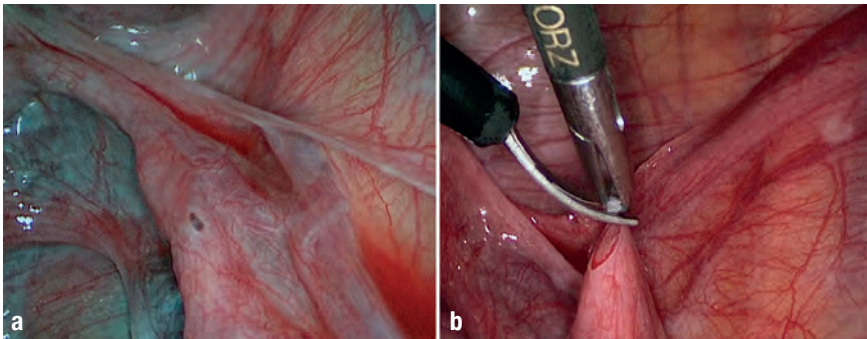
#### 3.7.2.4 Trocar Positioning and Operative Technique

After introducing the optical trocar, the authors recommend placing three additional 5-mm trocars in the right and left iliac areas and in the suprapubic region. The surgeon and assistant will use these ancillary trocars to facilitate intraoperative exposure and manipulations. The surgical procedure begins with adhesiolysis in an attempt to restore local anatomy. Whenever possible, it is always preferable to excise adhesive bands and not just divide them. In the case of ‘kissing ovaries,’ the endometriomas should be drained and the ovaries suspended to the abdominal wall or the round ligament to free the assistant’s hand for other manipulations. This can be done with sutures on a straight needle or with special devices. As stated earlier, excision of the endometrial implants is the best way to achieve pain control and reduce the recurrence rate. Since histopathologic confirmation of endometriosis is required, small implants should be carefully excised; the use of electrocautery should be minimized to reduce damage to the endometriosis implants and aid histologic interpretation of the slides (Figs. 3.131a, b). For this purpose, the authors recommend having the assistant hold and stabilize the implant with a grasping forceps. The surgeon then uses a bipolar forceps to define the resection margins, which should widely encompass the implant. Then, a cold laparoscopic scissors or monopolar hooks are used to cut the peritoneum or serosal surface while the assistant places traction on the nodule. In the case of very small nodules that do not abut vital structures (see below), the nodule can be stabilized and excised with

a cold scissors, followed by hemostasis, as another way to preserve the histologic architecture of the nodule for better pathology readings. Generally speaking, abnormal tissue can be positively distinguished from normal tissue when the resection margins are defined. The endometriotic nodules have the appearance described above, while surrounding tissues will generally consist of fat (yellow) or peritoneum (white or transparent). This makes it possible to dissect and resect the lesions with an adequate margin of healthy tissue.

Superficial endometriotic nodules that overlie vital structures like the ureter, nerves, bladder, or bowel require special attention. With implants overlying the ureter, the first step is to identify the trajectory of the ureter. Then, the peritoneum is incised at a site 1 cm from the ureter. Next, the nodule is grasped and bluntly dissected from the ureter. A bipolar forceps has a collateral damage zone of 5–10 mm, so care is taken to achieve good hemostasis without exposing the ureter to undue heat. This will help to preserve the ureteral blood vessels in the adventitia.

Implants close to hypogastric nerves should be dissected from the nerves. Superficial implants on the bladder or bowel serosa should be excised with cold scissors and minimal use of electrocautery. When the serosa has been deeply excised and the muscularis layer breached, reapproximation with simple interrupted or continuous sutures is advised. The use of absorbable suture material is recommended.



**Fig. 3.131a,b** Endometriosis on the serosa of the Fallopian tube (a). The endometriotic implant is excised without prior electrocautery to preserve the histologic architecture in the small nodule (b).

Agent	Mechanism of action	Advantages/Disadvantages	Reference
Hyaluronic acid / carboxy-methylcellulose (HA/CMC) membrane	Site-specific barrier. Mechanically separates tissue surfaces. Forms hydrophilic gel after placement.	Reduces adhesions and early small bowel obstruction. Not well studied in prevention of late small bowel obstruction. Absorbed within 7 days and excreted in 28 days.	3,20,22,18
Oxidized regenerated cellulose	Mechanical barrier (mesh). Placed over and between raw surfaces. Forms a gelatinous protective lining.	Reduces adhesions. Hemostasis is necessary prior to application. Absorbed within 2 weeks.	12,13,18,20
Expanded polytetrafluoroethylene	Nonabsorbable synthetic material that must be sutured in place. Inhibits tissue adherence and cellular migration.	Reduces adhesions. Difficult to use in laparoscopy. Needs to be removed surgically.	1,15,18
Polyethylene glycol	Sprayed gel. Remains over applied area for 1 week, then is degraded and absorbed.	Reduces adhesions. Limited evidence to support its use.	7,14,18
Crystalloid solutions (lactated Ringer, NaCl 0.9%)	Instilled into the peritoneal cavity. Absorbed within 24 h.	Cover more potential sites of adhesions. Commonly used. Lack of evidence for efficacy in reducing adhesion formation.	4,18
Icodextrin 4% solution	Isomolar solution. Absorbed by lymphatic system. Separates peritoneal surfaces by hydroflotation and maintains a fluid reservoir up to 4 days.	Effective in reducing adhesions. Suitable for laparoscopic surgery. Contraindicated in cases that include repair of gastrointestinal tract structures.	4,5,20

**Table 3.4** Agents used for the prevention of postoperative adhesions.

### 3.7.2.5 Completion of Surgery

The excision or coagulation of most implants is followed by copious suction-irrigation. Surgical specimens are retrieved in protective bags and sent to pathology. Fluids like crystalloid solutions or antiadhesive barriers (Table 3.4) are left in the abdominal cavity at the end of the procedure to inhibit the formation of postoperative adhesions. The accessory trocars are removed under direct vision to check for any bleeding at the insertion sites. The abdomen should be deflated in the Trendelenburg position. A Valsalva maneuver, performed by exhaling against a closed airway, can help minimize the amount of residual CO<sub>2</sub> in the peritoneal cavity. The optical trocar and laparoscope are kept in the abdominal cavity until CO<sub>2</sub> deflation is complete. This is to keep bowel from being entrapped in the trocar prior to its removal. Skin incisions are closed with absorbable or nonabsorbable sutures. The patient can leave the hospital the same day if the procedure and anesthesia have been well tolerated. Otherwise, an overnight stay should be sufficient for most patients.

### 3.7.3 Conclusion

Laparoscopy is the minimally invasive modality of choice for the diagnosis and treatment of superficial or deep infiltrating endometriosis. A high level of surgeon expertise is crucial for the proper visualization and accurate excision of endometriotic lesions. This is supported by proper preparation and positioning of the patient and by following a systematic routine during the procedure. Selecting the proper entry sites, adequate insufflation of the abdomen, and thorough inspection of the peritoneal and pelvic cavities are of utmost importance and give the surgeon optimal conditions for operating. A thorough knowledge of pelvic anatomy is also crucial for preventing inadvertent injuries to vital structures, nerves, blood vessels, and the ureters. While suspected lesions are excised, it is important to identify and respect the margins between normal and abnormal tissues. Surgical specimens should be removed in a retrieval bag to preserve them for pathology. Finally, concluding the procedure in a proficient manner is as important as starting it in a proficient manner. Suction-irrigation, careful retrieval of surgical instruments, deflation of the abdomen, and closure of the skin are all integral parts of a successful procedure.

### 3.7.4 References

- AHMAD G, DUFFY JM, FARQUHAR C, VAIL A, VANDEKERCKHOVE P, WATSON A et al. Barrier agents for adhesion prevention after gynaecological surgery. *Cochrane Database Syst Rev* 2008(2):CD000475. doi:10.1002/14651858.CD000475.pub2.
- ANGIONI S, PONTIS A, CELA V, SEDDA F, GENAZZANI AD, NAPPI L. Surgical technique of endometrioma excision impacts on the ovarian reserve. Single-port access laparoscopy versus multiport access laparoscopy: a case control study. *Gynecol Endocrinol* 2015;31(6):454–7. doi:10.3109/09513590.2015.1017812.
- BRISTOW RE, MONTZ FJ. Prevention of adhesion formation after radical oophorectomy using a sodium hyaluronate-carboxymethylcellulose (HA-CMC) barrier. *Gynecol Oncol* 2005;99(2):301–8. doi:10.1016/j.ygyno.2005.06.057.
- BROWN CB, LUCIANO AA, MARTIN D, PEERS E, SCRIMGEOUR A, DIZEREGA GS. Adept (icodextrin 4 % solution) reduces adhesions after laparoscopic surgery for adhesiolysis: a double-blind, randomized, controlled study. *Fertil Steril* 2007;88(5):1413–26. doi:10.1016/j.fertnstert.2006.12.084.
- DIZEREGA GS, VERCO SJ, YOUNG P, KETTEL M, KOBAK W, MARTIN D et al. A randomized, controlled pilot study of the safety and efficacy of 4 % icodextrin solution in the reduction of adhesions following laparoscopic gynaecological surgery. *Hum Reprod* 2002;17(4):1031–8.
- DUNSELMAN GA, VERMEULEN N, BECKER C, CALHAZ-JORGE C, D'HOOGHE T, BIE B DE et al. ESHRE guideline: management of women with endometriosis. *Hum Reprod* 2014;29(3):400–12. doi:10.1093/humrep/det457.
- FERLAND R, CAMPBELL PK. Pre-clinical evaluation of a next-generation spray adhesion barrier for multiple site adhesion protection. *Surg Technol Int* 2009;18:137–43.
- HART RJ, HICKEY M, MAOURIS P, BUCKETT W. Excisional surgery versus ablative surgery for ovarian endometriomata. *Cochrane Database Syst Rev* 2008(2):CD004992. doi:10.1002/14651858.CD004992.pub3.
- HOLSBEKE VAN C, CALSTER VAN B, GUERRIERO S, SAVELLI L, PALADINI D, LISSONI AA et al. Endometriomas: their ultrasound characteristics. *Ultrasound Obstet Gynecol* 2010;35(6):730–40. doi:10.1002/uog.7668.
- JACOBSON TZ, DUFFY JM, BARLOW D, FARQUHAR C, KONINCKX PR, OLIVE D. Laparoscopic surgery for subfertility associated with endometriosis. *Cochrane Database Syst Rev* 2010(1):CD001398. doi:10.1002/14651858.CD001398.pub2.
- JACOBSON TZ, DUFFY JM, BARLOW D, KONINCKX PR, GARRY R. Laparoscopic surgery for pelvic pain associated with endometriosis. *Cochrane Database Syst Rev* 2009(4):CD001300. doi:10.1002/14651858.CD001300.pub2.
- KECKSTEIN J, ULRICH U, SASSE V, ROTH A, TUTTLIES F, KARAGEORGIEVA E. Reduction of postoperative adhesion formation after laparoscopic ovarian cystectomy. *Hum Reprod* 1996;11(3):579–82.
- MAIS V, AJOSSA S, MARONGIU D, PEIRETTI RF, GUERRIERO S, MELIS GB. Reduction of adhesion reformation after laparoscopic endometriosis surgery: a randomized trial with an oxidized regenerated cellulose absorbable barrier. *Obstet Gynecol* 1995;86(4 Pt 1):512–5.
- METTLER L, AUDEBERT A, LEHMANN-WILLENBROCK E, SCHIVE-PETERHANSL K, JACOBS VR. A randomized, prospective, controlled, multicenter clinical trial of a sprayable, site-specific adhesion barrier system in patients undergoing myomectomy. *Fertil Steril* 2004;82(2):398–404. doi:10.1016/j.fertnstert.2003.12.046.
- MONTZ FJ, MONK BJ, LACY SM. The Gore-Tex Surgical Membrane: effectiveness as a barrier to inhibit postradical pelvic surgery adhesions in a porcine model. *Gynecol Oncol* 1992;45(3):290–3.
- MOORE J, COPLEY S, MORRIS J, LINDSELL D, GOLDING S, KENNEDY S. A systematic review of the accuracy of ultrasound in the diagnosis of endometriosis. *Ultrasound Obstet Gynecol* 2002;20(6):630–4. doi:10.1046/j.1469-0705.2002.00862.x.
- MOURALI M, MEKKI D, FITOUHI L, MKAOUAR L, HMLA F, BINOUS N et al. Management of ovarian endometriomas: intraperitoneal cystectomy versus fenestration and coagulation. *Tunis Med* 2013;91(12):709–14.
- PADOS G, VENETIS CA, ALMLOGLOU K, TARLATZIS BC. Prevention of intra-peritoneal adhesions in gynaecological surgery: theory and evidence. *Reprod Biomed Online* 2010;21(3):290–303. doi:10.1016/j.rbmo.2010.04.021.
- ROMAN H, AUBER M, MOKDAD C, MARTIN C, DIGUET A, MARPEAU L et al. Ovarian endometrioma ablation using plasma energy versus cystectomy: a step toward better preservation of the ovarian parenchyma in women wishing to conceive. *Fertil Steril* 2011;96(6):1396–400. doi:10.1016/j.fertnstert.2011.09.045.
- SCHNURIGER B, BARMPPARAS G, BRANCO BC, LUSTENBERGER T, INABA K, DEMETRIADES D. Prevention of postoperative peritoneal adhesions: a review of the literature. *Am J Surg* 2011;201(1):111–21. doi:10.1016/j.amjsurg.2010.02.008.
- SOMIGLIANA E, BENAGLIA L, VIGANO' P, CANDIANI M, VERCELLINI P, FEDELE L. Surgical measures for endometriosis-related infertility: a plea for research. *Placenta* 2011;32 Suppl 3:S238–42. doi:10.1016/j.placenta.2011.06.011.
- VRIJLAND WW, TSENG LN, EIJKMAN HJ, HOP WC, JAKIMOWICZ JJ, LEGUIT P et al. Fewer intraperitoneal adhesions with use of hyaluronic acid-carboxymethylcellulose membrane: a randomized clinical trial. *Ann Surg* 2002;235(2):193–9.
- WYKES CB, CLARK TJ, KHAN KS. Accuracy of laparoscopy in the diagnosis of endometriosis: a systematic quantitative review. *BJOG* 2004;111(11):1204–12. doi:10.1111/j.1471-0528.2004.00433.x.



## 3.8

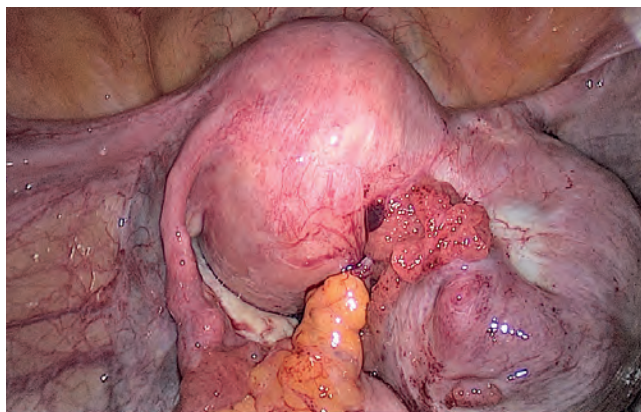
## Robotic Laparoscopic Surgery for Endometriosis

Joao Siufi Neto<sup>a</sup> | Daniela Freitas Santos Siufi<sup>a</sup> | Javier F. Magrina<sup>b</sup>

### 3.8.1 Introduction

Endometriosis is associated with chronic inflammatory response with consequent fibrosis, adhesion formation, neural infiltration and distortion of pelvic anatomy (Fig. 3.132), leading to pain and infertility.<sup>8,27</sup> The disease is usually divided into superficial (peritoneum and/or ovary), ovarian endometriomas and a deep infiltrative form (lesions > 5 mm in depth). Deep endometriosis can affect the bowel (rectum, appendix, ileum, cecum), posterior vaginal wall, uterosacral ligaments and urinary tract (bladder and ureter), requiring more complex surgical procedures.<sup>3</sup> If any viscera are invaded by disease, the condition is also classified as extrinsic or intrinsic, depending on whether the mucosa is unaffected or infiltrated, respectively.

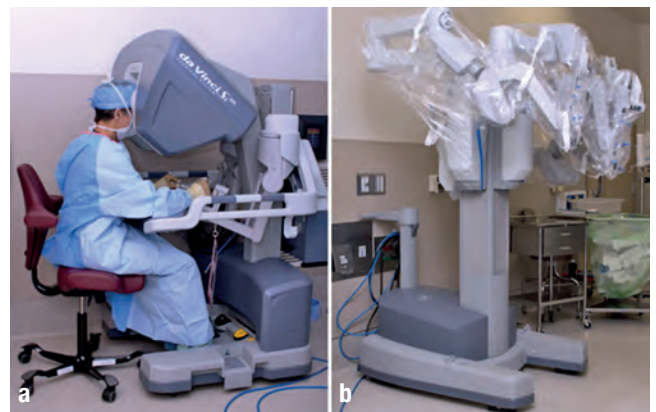
The benefits of laparoscopic surgery for complex gynecologic conditions such as endometriosis have been demonstrated, especially in relation to faster recovery, less blood loss, better intraoperative visualization, shorter hospital stay, cosmetics and reduced postoperative pain.<sup>16,23</sup>



**Fig. 3.132** Frozen pelvis with total cul-de-sac obliteration and a large right ovarian endometrioma.

A great advance in laparoscopic surgery was the emergence of robotic-assisted laparoscopy, a platform that consists of a surgeon console that controls articulated robotic arms attached to the patient (Fig. 3.133), with a three-dimensional camera system and energy (bipolar or monopolar) connected to the instruments.<sup>30</sup> Besides decreasing surgeon's fatigue, robotic-assisted surgery allows better coordinated movements, tremor reduction and shorter learning curve when compared to conventional laparoscopy.<sup>21</sup>

The present chapter discusses the benefits of robotic-assisted laparoscopy for the treatment of endometriosis.



**Fig. 3.133a, b** Robotic platform (a, b). Surgeon console of the *da Vinci Surgical System*. (a). Patient-side cart with robotic arms (b).

<sup>a</sup> | MD; Surgical Oncologist, Sírio-Libanês Hospital, São Paulo, SP, Brazil

<sup>b</sup> | MD; Department of Gynecologic Surgery, Mayo Clinic Arizona, Phoenix, AZ, USA

**Corresponding author:**

**Joao Siufi Neto, MD**

Rua Prof. Daher Cutait, 69

Bairro Bela Vista – CEP 01308-060

São Paulo, SP, Brazil

E-mails of authors: joaosiufi@me.com

danielafrasantos@me.com

jmagrina@mayo.edu

### 3.8.2 Robotic-Assisted Laparoscopy Set Up

For all pelvic procedures, we recommend a dorsal semi-lithotomy position with the legs supported in Allen stirrups. To prevent sliding during Trendelenburg position, the patient's torso rests on convoluted foam pad (Fig. 3.134a). Special attention should be paid to prevent neural injuries, protecting legs and arms with surgical drapes and foam pads.

The open entry Hasson technique is our preference to initiate the procedure. After pelvic and upper abdomen inspection with the scope, two 8 mm additional robotic trocars are placed to the right and left of the umbilicus and about 10 cm from it, respectively. One 10 mm assistant trocar is placed 3 cm cranial and equidistant in between the umbilical and the left robotic trocars; one robotic 8 mm trocar is placed at the level of the cecum in the right lower quadrant (Fig. 3.134b). The robotic arms are side-docked to the patient's right leg in 3 minutes (Fig. 3.134c), on average.<sup>11</sup> Being dependent on the surgeons preference, a monopolar spatula electrode or scissors is inserted through the right trocar and a plasmakinetic bipolar grasper is inserted through the left trocar. At the right lower quadrant trocar, a ProGrasp forceps is inserted and used as the fourth arm for retraction. The assistant uses the left upper quadrant trocar (Table 3.5 summarizes the practical points of the robotic-laparoscopic setup).

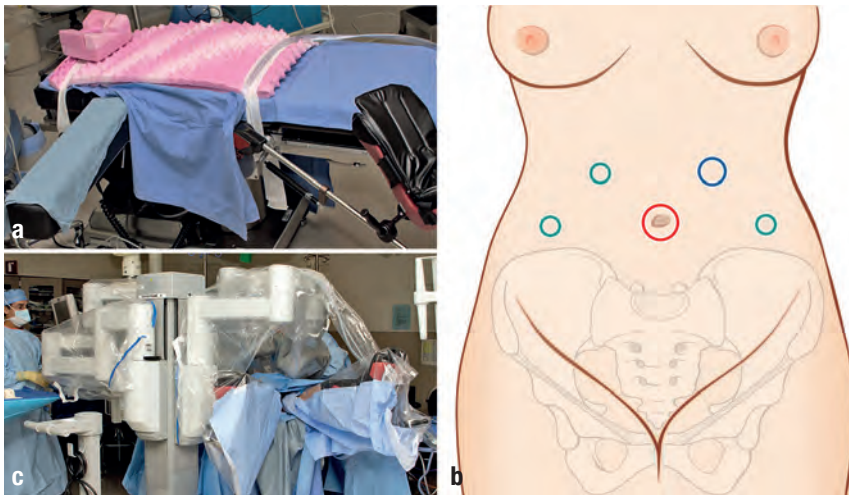
### 3.8.3 Surgical Excision

Extensive evidence has shown excision is preferable to cautery of lesions for two reasons. Recurrence rate is lower with excision<sup>26</sup> and many peritoneal lesions which resemble endometriosis are not. In a study evaluating 480 peritoneal lesions suspicious for endometriosis, only 51% were confirmed to be endometriosis on histological examination.<sup>29</sup>

Endometriosis shows different appearances and patterns of involvement of intrapelvic organs, ranging from superficial or deep peritoneal foci, ovarian endometriomas, and up to bladder, ureter and intestinal infiltrating lesions. Except from peritoneal lesions that can be easily resected, endometriosis affecting other structures requires an individualized surgical planning, as outlined below.

#### 3.8.3.1 Intestinal Endometriosis

Deep endometriosis is usually associated with chronic pelvic cyclic and non-cyclic pain, dysmenorrhea and intestinal symptoms including dyschezia, rectal bleeding and serious impairment in quality of life.<sup>4,25</sup> Symptomatic patients obtain most benefit from surgical treatment, especially those with significant pain, signs of bowel obstruction and previous IVF failure.<sup>1,4,14</sup>



**Fig. 3.134a–c** Operating table configuration with convoluted foam pad to prevent the patient from sliding off the operating table (a). Illustration of trocar configuration for pelvic robotic surgeries (red circle = camera trocar; blue circle = assistant 10-mm trocar; green circles = robotic 8-mm trocars (b). Robotic platform docked to the patients right leg (c).

Robotic-Laparoscopic Setup – Practical Points	
<b>Patient Preparation</b>	<ul style="list-style-type: none"> <li>■ Semi-lithotomy.</li> <li>■ Arms and legs protected.</li> <li>■ Convoluted foam pad to prevent patient from sliding off the operating table.</li> <li>■ First entry (umbilical trocar): open Hasson technique.</li> </ul>
<b>Laparoscopic Steps</b>	<p><b>Additional Trocars</b></p> <ul style="list-style-type: none"> <li>■ 8-mm right robotic trocar, 10 cm from the umbilicus.</li> <li>■ 8-mm left robotic trocar, 10 cm from the umbilicus.</li> <li>■ 8-mm right upper robotic trocar, 3 cm cranial in between umbilical and right robotic trocar.</li> <li>■ 10-mm left upper assistant trocar, 3 cm cranial in between umbilical and left robotic trocar.</li> </ul>

**Table 3.5** Practical points of the robotic-laparoscopic setup.

The surgical management of rectal endometriosis includes three main techniques:

- lesion shaving,
- nodule resection, or
- segmental resection with end-to-end anastomosis.

Minimally invasive techniques are the gold standard and a multidisciplinary team or a gynecologist with intestinal surgery skills is required. The decision on which technique to be used depends on size, depth of lesions, and whether stricture is present (Table 3.6 summarizes the surgical approach based on the size and characteristics of the lesion).

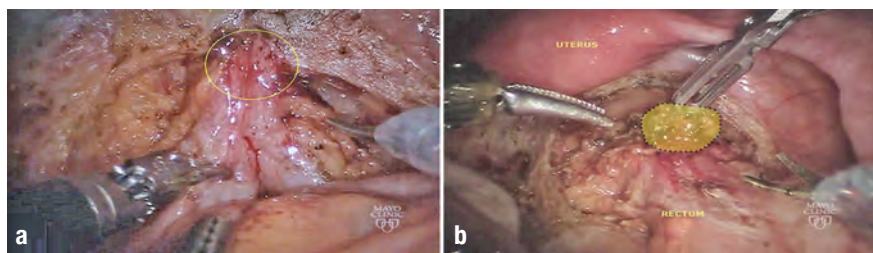
#### Intestinal Endometriosis Approach (Symptomatic Patients)

Size and Characteristics of Lesion	Surgical Approach
> 3 cm or 40% of bowel circumference.	Segmental resection with anastomosis (end-to-end; side-to-end; side-to-side). Local excision with two layer closure.
< 3 cm, no stricture.	Shaving technique with single-layer closure of defect (if bowel lumen is entered, two layer closure).

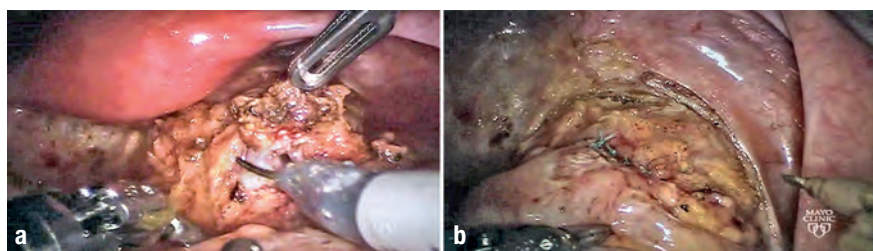
**Table 3.6** Intestinal endometriosis approach according to the size and characteristics of the lesion.

#### ■ Shaving Technique

The shaving technique consists of removing an infiltrating rectosigmoid nodule to the deepest layer of involvement (Figs. 3.135a, b), which can be appreciated only with endoscopic surgery (Fig. 3.136a). The defect is then closed with absorbable sutures or nonabsorbable sutures (Fig. 3.136b). In a prospective series including 500 patients submitted to the shaving technique, *Donnez and Squifflet (2010)*<sup>7</sup> reported rectal perforation in seven cases (1.4%); ureteral injury in four cases (0.8%); blood loss > 300 ml in one case (0.2%); and urinary retention in four cases (0.8%). The authors concluded that this technique preserves blood supply, organs and nerves, and can be considered a less aggressive alternative to segmental resection.



**Fig. 3.135a,b** Rectal endometriotic nodule attached to the retrocervical region (a). Rectal endometriotic nodule aspect after dissection (dashed line) (b).



**Fig. 3.136a,b** Nodule shaving using cold scissors to avoid thermal injury (a). Rectal wall defect closed, final aspect (b).

In a series of 25 patients submitted to robotic shaving, *Pellegrino et al. (2015)*,<sup>24</sup> reported complete free margins in all cases, with a median large axis of endometriotic excised nodule of 21 mm (range, 10–60 mm). The median operative time was 174 minutes (range, 75–300 minutes), and estimated blood loss was less than 100 mL. The authors concluded that the robotic platform is equally effective for the treatment of deep endometriotic nodules involving the rectosigmoidal wall.

#### ■ Discoid Resection with Circular Stapler

Another technique widely used to resect rectal endometriotic nodules is the use of a circular stapler, and was firstly described as an option to avoid ultra-low segmental resection.<sup>9</sup> This technique is applicable to lesions < 3 cm since the maximum diameter of a circular stapler is 33 mm. Once the lesion is dissected and clearly outlined, one absorbable suture is placed at the 3 o'clock and another at the 9 o'clock position of the nodule to place it in the open circular stapler introduced transanally. Once the lesion is inserted into the opened stapler with the use of the anchoring sutures, the stapler is closed and before firing, a last verification is performed to ensure that the entire lesion is enclosed into the stapler jaws. The final result consists of a discoid resection of the anterior rectal wall including the entire lesion.

#### ■ Local Excision and Segmental Resection

Endometriotic nodules larger than 3 cm, or involving > 40% of circumference, or associated with stricture should be approached through a local excision or segmental resection with end-to-end anastomosis. Local excision is always preferred due to a lower morbidity rate. Because endometriosis does not involve the mesentery of the small bowel, colon, sigmoid or rectum, there is no need for mesenteric resection in any of these locations.



### Local Excision

For local excision, a rectal probe or dilator is introduced transanally and the limits of the lesion are demarcated with the cautery. A full-thickness resection of the bowel wall is then performed. The defect is always closed in a transverse fashion in two layers. An inner layer of 3-0 PDS continuous suture is placed first including the full thickness of the bowel wall followed by interrupted inverting sutures with nonabsorbable suture such as Ethibond 3-0. The integrity of the closure is checked with the bubble test and methylene blue enema. Another, but more expensive option, is the use of a linear endoscopic stapler to close the defect. Three holding sutures are placed, one in the middle and at each end to elevate the edges of the bowel defect and to facilitate the application of the linear endoscopic stapler.

### Segmental Resection

For segmental resection of the rectosigmoid, there is no need to mobilize the rectosigmoid from the presacral area. Typically, the rectosigmoid is fixed to the posterior cervical wall and must be separated first. If the uterus is preserved, the fourth robotic arm keeps the uterus in maximum anteversion. The rectovaginal space is dissected to the lower half of the vagina. The Prograsp or plasmakinetic instrument is passed through the mesenteric border immediately below the bowel wall creating a space to pass the stapling device. The bowel is transected proximal and distal to the lesion with an endoscopic linear stapler. A suprapubic mini-laparotomy incision is performed for removal of the specimen and exteriorization

of the proximal end of the bowel. The circular stapler anvil is secured with a purse suture to the proximal end of the bowel which is reintroduced into the cavity. After closure of the incision an end-to-end anastomosis is completed with an end-to-end anastomotic (EEA) device introduced transanally. A bubble test and transanal injection of methylene blue are performed to check for anastomotic leakage.<sup>19,20</sup>

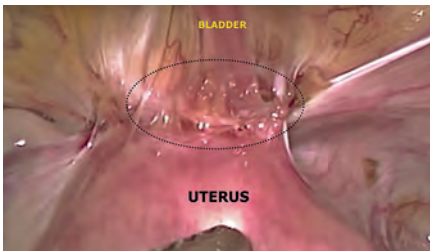
### 3.8.4 Bladder and Ureteral Endometriosis

Genitourinary tract endometriosis is a rare manifestation of the disease, but with potential complications related to its treatment, in particular with ureteral resection.<sup>6</sup> About 14% of patients with advanced endometriosis have urinary involvement.<sup>18</sup>

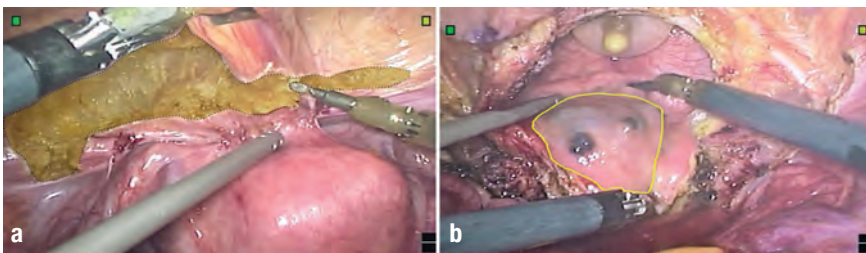
#### 3.8.4.1 Bladder Endometriosis

If bladder endometriosis is suspected, a cystoscopy is recommended. Based on preoperative imaging and endoscopic findings, a proper surgical approach can be planned, with local excision (partial cystectomy) indicated in cases of infiltration of the urothelium. Ureteral stents are helpful in particular if the lesions are near the ureteral meatus.<sup>12</sup>

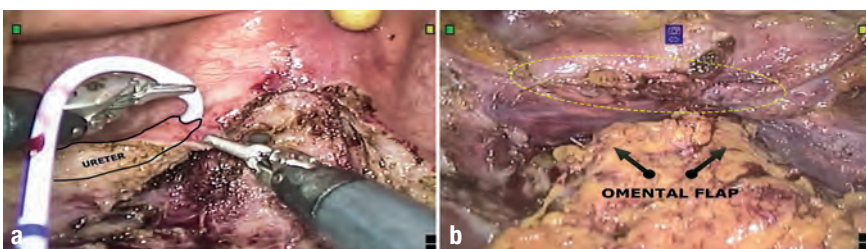
Robotic-assisted laparoscopy is a feasible approach for partial cystectomy. After intraoperative inventory, the bladder lesion is identified (Fig. 3.137) and resected with free margins using surgical scissors or spatula and bipolar forceps (Figs. 3.138a, b). The bladder defect can be easily closed with the robotic articulated needle holders in a double-layer closure (Figs. 3.139a, b).



**Fig. 3.137** Large endometriotic lesion infiltrating the bladder.



**Fig. 3.138a, b** Extensive bladder dissection as first step for partial cystectomy (a). Intravesical aspect of the endometriotic nodule after cystotomy (yellow line) (b).



**Fig. 3.139a, b** Ureteral stenting after complete nodule resection before bladder closure (a). Final aspect after double-layer closure of the bladder (b).

The first is a continuous layer including the full thickness of the bladder wall using 3-0 PDS suture. A second running layer is placed incorporating the bladder wall but only to the submucosa and imbricating the previous layer. The bladder is then distended with water or diluted methylene blue to confirm a watertight closure.<sup>15</sup>

#### 3.8.4.2 Ureteral Endometriosis

Endometriosis of the ureter can be accompanied by renal impairment if associated with ureteral obstruction due to extrinsic or intrinsic disease. During laparoscopy, the first step consists of freeing and exposing the ureter above the area of the involvement, followed by separation of the ureter from any loose endometriosis lesions (ureterolysis). In the presence of obstruction, ureterolysis is always preferable to segmental resection<sup>18</sup> and if resection is needed reimplantation (uretero-neocystostomy) is always preferable to end-to-end anastomosis (uretero-ureterostomy). A double J stent is always used to facilitate a dry environment for healing, prevent urine leak, and stricture, although the latter can occur after the stent is removed. The robotic articulation facilitates precise suturing for ureteral surgery.<sup>13</sup>

#### 3.8.5 Ovarian Endometriosis (Cystectomy)

Laparoscopic surgery is the gold standard technique for the treatment of ovarian endometriomas. Ovarian cystectomy is associated with low recurrence rates, however it decreases the ovarian reserve and fertility rates. With the endometrioma and ovary stabilized between two graspers, an incision is made on the antimesenteric aspect of the cyst, avoiding damage to the hilus. After identification of the correct cleavage plane, the cyst is removed from the ovarian cortex by traction and counter-traction, followed by gentle cautery hemostasis which if excessive may further compromise ovarian reserve.<sup>10</sup>

#### 3.8.6 Discussion

The benefits of using a robotic platform are more evident in cases of severe pelvic endometriosis. Based on the authors' experience, the crucial component in this context is the 3D camera system, allowing better identification, dissection and resection of lesions. In a cohort of 43 women with stage III and IV endometriosis submitted to hysterectomy, robotic-assisted laparoscopy resulted in a median operative time of 145 min (67–325 min,  $p = 0.882$ ), and median blood loss of 100 mL (20–400 mL,  $p = 0.503$ ). As expected, 95% of the patients (41 of 43) stayed less than one day at the hospital, with only one reported complication, a vaginal cuff abscess.<sup>2</sup>

In another retrospective series,<sup>5</sup> 164 women with stage IV endometriosis underwent robotic-assisted laparoscopic excision and were followed for 10.2 months for outcomes. Dysmenorrhea was the most frequent symptom noted in 58.3% of the patients. A variety of procedures were performed, ranging from unilateral oophorectomy to intestinal resection. The average operative time was  $180 \pm 77.2$  min and according to the procedure complexity, different complications were reported. The highest complications were noted in patients with rectal or ureteral involvement. In the former, increased blood loss, conversion to laparotomy, and hemorrhage (2,300 mL)

were noted. In the latter group, a ureteric fistula and a ureteral were observed. A recurrence rate of 10.2% was noted on follow up, and out of 42 patients who tried pregnancy, 28.2% of them succeeded.

In a comparison with conventional laparoscopy, robotic-assisted laparoscopy showed to be a feasible alternative for the treatment of advanced endometriosis. In a retrospective cohort including 118 patients (86 conventional and 32 robotic-assisted) with stage III and IV endometriosis, the median operative room time was 250.50 minutes with the robot compared to 173.50 minutes with conventional laparoscopy ( $p < 0.0005$ ). In relation to blood loss, length of hospital stay, intra and perioperative complications, no statistical difference were observed. The authors reported no conversions to laparotomy and recommended the use of the robotic platform for complex surgeries, requiring fine dissection and lengthy procedures.<sup>22</sup>

The largest series in literature comparing robotic-assisted laparoscopic surgery (RALS) and conventional laparoscopic surgery (CLS) was reported in a study from the Mayo Clinic in Arizona, including 493 women with histologically proven stage III ( $n = 225$ ) or stage IV ( $n = 268$ ) endometriosis.<sup>17</sup> RALS was the method of choice in 331 patients (135 stage III and 196 stage IV), while 162 patients (79 stage III and 83 stage IV) had CLS. The evaluation of perioperative outcomes between both techniques was the main objective.

The operative time increased by 5.3% for every 10-year in age ( $p = .008$ ), by 10% for every 100 mL of blood loss ( $p < .001$ ), by 32% with 4 or more procedures per patient ( $p < .001$ ), and by 16.2% when the operation was performed using conventional laparoscopic instead of robotics ( $p < .001$ ). The length of hospital stay (LOS) was significantly influenced by age, blood loss and operating time. For every 10-year increase in age, LOS increased by 45% (adjusted odds ratio [OR], 1.45; 95% confidence interval [CI], 1.18–1.77;  $p < .001$ ). The type of surgical approach, either robotics or laparoscopy, did not affect LOS ( $p = .30$ ) or postoperative complications.

These results demonstrated that operating time was the unique variable significantly associated with complications. It was noticed a 57% increased odds of having postoperative complications for every 60 minutes of additional operating time (adjusted OR, 1.57; 95% CI, 1.21–2.02;  $p < .001$ ). The number of procedures performed per patient and specific procedures such as radical hysterectomy, pelvic peritonectomy and adhesiolysis were associated with increased risk of postoperative complications ( $p = .04$ ). This study showed a 16% reduced operating time for patients operated by robotics as compared to laparoscopy.

Only three patients (0.6%) needed conversion to laparotomy, one because of dense obliteration of cul-de-sac and two requiring rectosigmoid resection. Minor postoperative complications were observed in fourteen patients (2.8%), including fever ( $n = 1$ ), urinary tract infection ( $n = 7$ ), trocar site cellulitis ( $n = 3$ ), vaginal bleeding ( $n = 1$ ) and Clostridium difficile colitis ( $n = 2$ ).

A prospective randomized controlled trial (**Laparoscopy vs. Robotic Surgery for Endometriosis**; LAROSE- NCT01556204) was conducted comparing robotic-assisted surgery and conventional laparoscopy for the excision of endometriosis.<sup>28</sup> This trial will add relevant information about both surgical approaches, especially related to intra and postoperative outcomes.

### 3.8.6.1 Conclusion

Robotic-assisted laparoscopy has become very popular among gynecologic surgeons, not only for radical oncological procedures but also for the complex procedures needed for the excision of severe endometriosis. The combination of a 3D camera system with surgeon's ergonomics and articulated instruments makes robotics a preferable approach for patients with advanced endometriosis stage III and IV.

## 3.8.7 References

- ANAF V, SIMON P, EL NAKADI I, FAYT I, BUXANT F, SIMONART T et al. Relationship between endometriotic foci and nerves in rectovaginal endometriotic nodules. *Hum Reprod* 2000;15(8):1744–50.
- BEDAIWY MA, RAHMAN MYA, CHAPMAN M, FRASURE H, MAHAJAN S, GRUENIGEN VE VON et al. Robotic-assisted hysterectomy for the management of severe endometriosis: a retrospective review of short-term surgical outcomes. *JLS* 2013;17(1):95–9. doi:10.4293/108680812X13517013317275.
- CHAPRON C, CHOPIN N, BORGHESE B, FOULOT H, DOUSSET B, VACHER-LAVENU MC et al. Deeply infiltrating endometriosis: pathogenetic implications of the anatomical distribution. *Hum Reprod* 2006;21(7):1839–45. doi:10.1093/humrep/del079.
- CHAPRON C, SANTULLI P, ZIEGLER D DE, NOEL J, ANAF V, STREULI I et al. Ovarian endometrioma: severe pelvic pain is associated with deeply infiltrating endometriosis. *Hum Reprod* 2012;27(3):702–11. doi:10.1093/humrep/der462.
- COLLINET P, LEGUEVAQUE P, NEME RM, CELA V, BARTON-SMITH P, HEBERT T et al. Robot-assisted laparoscopy for deep infiltrating endometriosis: international multicentric retrospective study. *Surg Endosc* 2014;28(8):2474–9. doi:10.1007/s00464-014-3480-3.
- COMITER CV. Endometriosis of the urinary tract. *Urol Clin North Am* 2002;29(3):625–35.
- DONNEZ J, SQUIFFLET J. Complications, pregnancy and recurrence in a prospective series of 500 patients operated on by the shaving technique for deep rectovaginal endometriotic nodules. *Hum Reprod* 2010;25(8):1949–58. doi:10.1093/humrep/deq135.
- GIUDICE LC. Clinical practice. Endometriosis. *N Engl J Med* 2010;362(25):2389–98. doi:10.1056/NEJMcp1000274.
- GORDON SJ, MAHER PJ, WOODS R. Use of the CEEA stapler to avoid ultra-low segmental resection of a full-thickness rectal endometriotic nodule. *J Am Assoc Gynecol Laparosc* 2001;8(2):312–6.
- KAPONIS A, TANIGUCHI F, AZUMA Y, DEURA I, VITSAS C, DECAVALAS GO et al. Current treatment of endometrioma. *Obstet Gynecol Surv* 2015;70(3):183–95. doi:10.1097/OGX.000000000000157.
- KHO RM, HILGER WS, HENTZ JG, MAGTIBAY PM, MAGRINA JF. Robotic hysterectomy: technique and initial outcomes. *Am J Obstet Gynecol* 2007;197(1):113.e1–4. doi:10.1016/j.ajog.2007.05.005.
- KNABBen L, IMBODEN S, FELLMANN B, NIRGIANAKIS K, KUHN A, MUELLER MD. Urinary tract endometriosis in patients with deep infiltrating endometriosis: prevalence, symptoms, management, and proposal for a new clinical classification. *Fertil Steril* 2015;103(1):147–52. doi:10.1016/j.fertnstert.2014.09.028.
- KOLODZIEJ A, KRAJEWSKI W, DOLOWY L, HIRNLE L. Urinary Tract Endometriosis. *Urol J* 2015;12(4):2213–7.
- LITTMAN E, GIUDICE L, LATHI R, BERKER B, MILKI A, NEZHAT C. Role of laparoscopic treatment of endometriosis in patients with failed in vitro fertilization cycles. *Fertil Steril* 2005;84(6):1574–8. doi:10.1016/j.fertnstert.2005.02.059.
- LIU C, PERISIC D, SAMADI D, NEZHAT F. Robotic-assisted laparoscopic partial bladder resection for the treatment of infiltrating endometriosis. *J Minim Invasive Gynecol* 2008;15(6):745–8. doi:10.1016/j.jmig.2008.07.002.
- LU D, LIU Z, SHI G, LIU D, ZHOU X. Robotic assisted surgery for gynaecological cancer. *Cochrane Database Syst Rev* 2012;1:CD008640. doi:10.1002/14651858.CD008640.pub2.
- MAGRINA JF, ESPADA M, KHO RM, CETTA R, CHANG YH, MAGTIBAY PM. Surgical Excision of Advanced Endometriosis: Perioperative Outcomes and Impacting Factors. *J Minim Invasive Gynecol* 2015;22(6):944–50. doi:10.1016/j.jmig.2015.04.016.
- MAGRINA JF, Cornella J.L., Nygaard I.E. et al. Endometriosis involving the lower urinary tract, part I: clinical presentation. *J Pelvic Surg* 1996;2:172–5.
- MALZONI M, DI GIOVANNI A, EXACOUSTOS C, LANNINO G, CAPECE R, PERONE C et al. Feasibility and Safety of Laparoscopic-Assisted Bowel Segmental Resection for Deep Infiltrating Endometriosis: A Retrospective Cohort Study With Description of Technique. *J Minim Invasive Gynecol* 2015. doi:10.1016/j.jmig.2015.09.024.
- NEME RM, SCHRAIBMAN V, OKAZAKI S, MACCAPANI G, CHEN WJ, DOMIT CD et al. Deep infiltrating colorectal endometriosis treated with robotic-assisted rectosigmoidectomy. *JLS* 2013;17(2):227–34. doi:10.4293/108680813X13693422521836.
- NEZHAT C, LAVIE O, LEMYRE M, UNAL E, NEZHAT CH, NEZHAT F. Robot-assisted laparoscopic surgery in gynecology: scientific dream or reality? *Fertil Steril* 2009;91(6):2620–2. doi:10.1016/j.fertnstert.2008.03.070.
- NEZHAT FR, SIROTA I. Perioperative outcomes of robotic assisted laparoscopic surgery versus conventional laparoscopy surgery for advanced-stage endometriosis. *JLS* 2014;18(4). doi:10.4293/JLS.2014.00094.
- PARAISO MFR, WALTERS MD, RACKLEY RR, MELEK S, HUGNEY C. Laparoscopic and abdominal sacral colpopexies: a comparative cohort study. *Am J Obstet Gynecol* 2005;192(5):1752–8. doi:10.1016/j.ajog.2004.11.051.
- PELLEGRINO A, DAMIANI GR, TRIO C, FACCIOLI P, CROCE P, TAGLIABUE F et al. Robotic Shaving Technique in 25 Patients Affected by Deep Infiltrating Endometriosis of the Rectovaginal Space. *J Minim Invasive Gynecol* 2015;22(7):1287–92. doi:10.1016/j.jmig.2015.06.002.
- REMORGIDA V, FERRERO S, FULCHERI E, RAGNI N, MARTIN DC. Bowel endometriosis: presentation, diagnosis, and treatment. *Obstet Gynecol Surv* 2007;62(7):461–70. doi:10.1097/01.ogx.0000268688.55653.5c.
- RIZK B, FISCHER AS, LOTFY HA, TURKI R, ZAHED HA, MALIK R et al. Recurrence of endometriosis after hysterectomy. *Facts Views Vis Obgyn* 2014;6(4):219–27.



27. STRATHY JH, MOLGAARD CA, COULAM CB, MELTON LJ3. Endometriosis and infertility: a laparoscopic study of endometriosis among fertile and infertile women. *Fertil Steril* 1982;38(6):667–72.
28. U.S. National Institutes of Health. Laparoscopy vs. Robotic Surgery for Endometriosis (LAROSE): a Prospective Randomized Controlled Trial (LAROSE). Sponsor: The Cleveland Clinic; Available from: <https://clinicaltrials.gov/ct2/show/results/NCT01556204>.
29. WALTER AJ, HENTZ JG, MAGTIBAY PM, CORNELLA JL, MAGRINA JF. Endometriosis: correlation between histologic and visual findings at laparoscopy. *Am J Obstet Gynecol* 2001;184(7):1407–11; discussion 1411-3.
30. WEINBERG L, RAO S, ESCOBAR PF. Robotic surgery in gynecology: an updated systematic review. *Obstet Gynecol Int* 2011;2011:852061. doi:10.1155/2011/852061.

## 3.9

## Robotic-Assisted Laparoscopic Surgery for Deeply Infiltrating Endometriosis

Nisha Lakhi<sup>a</sup> | Farr Nezhat<sup>b</sup>

### 3.9.1 Introduction

Endometriosis is a common condition that affects up to 10–15% of women in their reproductive years.<sup>24</sup> There are three distinct types of endometriosis: superficial endometriosis, ovarian endometriomas, and deeply infiltrating endometriosis (DIE). DIE is characterized by endometriotic implants that penetrate more than 5 mm into the affected tissue and is responsible for painful symptoms whose severity is strongly correlated with the depth of the DIE lesions.<sup>15</sup> In addition to pelvic structures, DIE may involve several other sites such as the uterosacral ligaments (USL), the rectovaginal septum (RVS), the posterior vaginal wall, the bowel and the urinary tract.<sup>15,30,50,61</sup> The estimated incidence of bowel endometriosis is between 3% and 36%, and the rectal and recto-sigmoid junction involvement together account for 70%–93% of all intestinal endometriotic lesions.<sup>30,61</sup> Urinary tract DIE, found in up to 6% of women with pelvic endometriosis, may involve either the bladder or ureters.<sup>50</sup> Deeply infiltrating endometriosis of the diaphragm has been described. In severe cases, the entire thickness of the diaphragm may be involved by endometriosis, with extension into the pleural space, resulting in pneumo- or hemothorax.<sup>52</sup>

### 3.9.2 Treatment of Deeply Infiltrating Endometriosis

Patients who have DIE present with different clinical complaints based on the location and extent of the disease. Treatment depends on the age of the patient, the location of the disease, the severity of the symptoms, and the desire for future fertility. Intervention usually is indicated for pain, infertility, or impaired function of the involved organ, such as the bladder, ureter, or bowel. Medical and surgical forms of management are available. Because of the limited efficacy of medical therapy, and due to symptom recurrence rates as high as 76%, surgical excision is frequently advocated as the treatment of choice.<sup>63</sup>

#### 3.9.2.1 Pioneering a Minimally Invasive Approach

In the 1980s, the *Nezhats* were the first to successfully perform video-assisted laparoscopic management of extensive endometriosis.<sup>43</sup> This included laparoscopic treatment of endometriosis of the bowel, bladder, and ureter.<sup>47</sup> Diagnosis and excision of all forms of endometriosis by a minimally invasive approach may now be considered the ‘gold standard’ of clinical care for women with endometriosis-related pain and infertility. A minimally invasive approach compared to laparotomy has several known advantages, including minimal trauma, superb visualization, low incidence of complications, reduction of adhesion formation, and favorable postoperative course along with rapid recovery and cosmetic effect.<sup>38</sup>

Although the benefits of laparoscopy have been well documented, laparoscopic management of advanced endometriosis and deeply infiltrating lesions can be technically challenging.<sup>53,64</sup> Several attributes of conventional laparoscopy, including the two-dimensional view, gradual learning curve, tremor amplification, may impede the uptake of this technology by the less experienced surgeon.<sup>41,65</sup> In addition, patients with DIE lesions can be difficult surgical candidates. Depending on the pervasiveness of the disease, some patients may have had multiple prior surgical interventions for symptom management. The disease itself is multifocal. Evidence has shown that for symptom relief complete surgical removal is necessary.<sup>18</sup> Incomplete excision of DIE is the biggest risk factor for future recurrence.<sup>66</sup> The long learning curve associated with traditional laparoscopy and limited surgical skills leads to inadequate surgery or conversion to laparotomy. For these reasons, the majority of procedures for DIE are still being performed by an open approach.<sup>53</sup>

#### 3.9.2.2 Robotic Assisted Laparoscopic Surgery

Robotic Assisted Laparoscopic Surgery (RALS) represents the latest development in minimally invasive surgery. This platform offers improved ergonomics, 3-dimensional visualization of the operating field, fine instrumentation, and increased maneuverability of the instruments.<sup>53,64,65</sup> These key features allow complex minimally invasive procedures to be performed more easily than with conventional laparoscopic surgery. The advantages given by the robotic system are amplified in the most complex procedures, and should be greatly enhanced in the setting of management of DIE.<sup>41</sup>

There are limited data comparing outcomes of RALS versus conventional laparoscopy for treatment of DIE and advanced endometriosis. A large retrospective study by *Nezhat et al.* compared RALS (n = 223) versus conventional laparoscopy (n = 147) for fertility-sparing treatment with advanced stage endometriosis.<sup>53</sup> It was found that RALS and conventional laparoscopic treatment of endometriosis showed no statistically significant differences in outcomes, except for a longer operating time and slightly longer hospital stay in the

<sup>a</sup> MD; Department of Obstetrics and Gynecology, Richmond University Medical Center, Staten Island, New York, USA

<sup>b</sup> MD; Department of Obstetrics and Gynecology, Division Gynecologic Oncology, Weill Cornell Medicine, NY, New York, USA  
Department of Obstetrics, Gynecology and Reproductive Medicine, State University of New York at Stony Brook School of Medicine, Stony Brook, NY, USA  
Department of Obstetrics and Gynecology, Winthrop University Hospital, Mineola, NY, USA

#### Corresponding author:

Farr Nezhat, MD

E-mail: fnezhat@chpnet.org.

RALS group.<sup>53</sup> Table 3.7 summarizes the demographic and intraoperative outcomes among the two groups.

Other authors have demonstrated the safety and feasibility of RALS for management of DIE. *Bedaiwy et al.* reviewed a series of 43 women with stage III or IV endometriosis treated with robot-assisted laparoscopy and found it to be a reasonably safe and feasible method for definitive surgical management of this condition.<sup>7</sup> Intraoperative complication rates were low and only one patient required conversion to laparotomy.<sup>7</sup> *Siesto et al.* published a retrospective cohort study of 43 patients with deep infiltrating endometriosis (DIE) treated by RALS, including 19 bowel resections, 23 removals of nodules from the rectovaginal septum, and 5 bladder resections. They found the robotic approach to be a safe and allowed for a comprehensive surgical treatment of DIE lesions.<sup>64</sup> *Collinet et al.* retrospectively analyzed the largest international multi-center series of women that underwent RALS for treatment of DIE.<sup>19</sup> The study included 164 patients, of which 88 had DIE involving the rectum, 23 the bladder, and 155 the ureter or uterosacral ligaments. The average operative time was 180 min. Conversion to laparotomy only occurred in one case. After a mean follow-up of 10.2 months, only 1.8% of patients required re-operation.<sup>19</sup>

Several smaller reports demonstrating the use of RALS in cases of DIE have been documented. *Chammas et al.* published a case report about a 23-year-old woman with rectal and bladder endometriosis that underwent robotic-assisted laparoscopic partial cystectomy with excision of

rectal nodules for endometriosis.<sup>12</sup> Another case report of bladder endometriosis successfully removed by RALS, was published by *Liu et al.*<sup>34</sup> In Brazil, *Averbach et al.* published a case report in which a 35-year-old woman with DIE with rectal involvement underwent colorectal resection by a RALS.<sup>3</sup> A case series published by *Nezhat et al.* demonstrated the feasibility of the RALS approach in treating 5 patients with multi-organ endometriosis, including bowel, bladder, and ureteral endometriosis.<sup>39</sup>

### 3.9.2.3 Firefly™ Fluorescence Imaging

Firefly™ fluorescence imaging is integrated in the Si and Xi systems and provides real-time, image-guided identification of anatomical landmarks using near-infrared technology. This Firefly™ technology may help in detecting endometriotic lesions not easily visible to the naked eye. Indocyanine green (ICG) is a water-soluble fluorescent dye that binds to plasma proteins and aids in identifying increased vascularity of tissue. A laser light source at 803 nm from the Da Vinci Firefly™ adapted endoscope allows for visualization of the dye that has accumulated in vascular structures. This method is useful for the detection of endometriosis because endometriotic lesions are associated with increased neovascularization. ICG accumulates within these endometriotic lesions and illumination with the robotic Firefly™ technology turns the lesions dark green, enabling their detection (Fig. 3.140). As endometriotic lesions can be subtle and difficult to identify, illumination using the robotic Firefly™ technology can aid in complete targeted resection of the affected tissue.

**Comparative Study of Conventional Laparoscopy vs RALS**

	Conventional Laparoscopy n = 273	RALS n = 147	P Value
Age	31	30	0.21
BMI	23	23	0.81
Estimated blood loss (ml)	25	40	0.86
Mean operative time (min.)	135	196	< 0.001
Intraoperative complications	0	0	NA
Postoperative complications	0	0	NA
Number with length of stay > 24 hours	63	147*	< 0.001
Conversion	0	3**	

**Table 3.7** Comparative study of conventional laparoscopy vs RALS by *Nezhat et al.*<sup>53</sup> Key to legend: \*All 147 patients were discharged on postoperative day #1, \*\* 3 patients converted from RALS to conventional laparoscopy.

Author	Number of Patients	Inclusion	Mean Operating Time (min)	Mean Estimated Blood Loss (ml)	Conversion	Mean Length of Stay (days)	Complications
<i>Bedaiwy</i> 2013 <sup>7</sup>	43	DIE stage 3 and 4	145	100	2.3%	1	1 vaginal cuff abscess
<i>Siesto</i> 2014 <sup>64</sup>	54	Colorectal or urinary DIE	200	120	0	3	1 bowel anastomotic leak
<i>Collinet</i> 2014 <sup>19</sup>	164	DIE stage 4	180	85	0.6%	4	1 bowel sutured bowel injury; 1 ureter-bladder anastomotic leak; 1 transfusion for EBL 2,300 ml; 1 ureteral fistula; 1 prolonged urinary catheterization

**Table 3.8** Summary of advanced endometriosis case series managed by RALS.



### 3.9.3 Preoperative Evaluation

Preoperative planning is an important first step prior to surgery to assess the extent and severity of the disease. In some instances, formation of a multi-disciplinary team may be necessary for obtaining optimal surgical results, especially when the disease involves multiple organ systems. Preoperative evaluation begins with a history and physical examination. Clinical presentation can be variable, with some women experiencing severe symptoms while others remain asymptomatic.<sup>63</sup> Pain symptoms can be elusive, as the degree of pain can be dependent on a multitude of factors.<sup>13,16,17,33</sup>

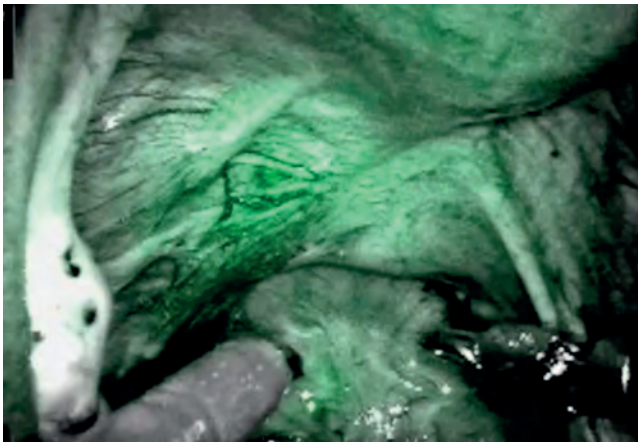
As DIE affects multiple organ-systems, obtaining a meticulous review of symptoms is necessary. Recently, *Ballester et al.* demonstrated that there is an increased incidence of urinary symptoms in women with posterior DIE. In particular parametrial involvement with endometriosis was associated with changes in urinary function.<sup>5</sup> In the case of intestinal DIE, there is a greater likelihood of the presence of symptoms such as cyclic painful defecation, cyclical constipation, and longer evacuation time.<sup>33</sup> Dysmenorrhea is also common, and has been shown by *Nezhat et al.* to be directly proportional to the number of endometriotic implants.<sup>57</sup>

The physical examination is an important step in the preoperative evaluation of deeply infiltrating endometriosis lesions. On vaginal examination, tenderness or nodularity in the posterior fornix of the vagina and utero-sarcal ligaments

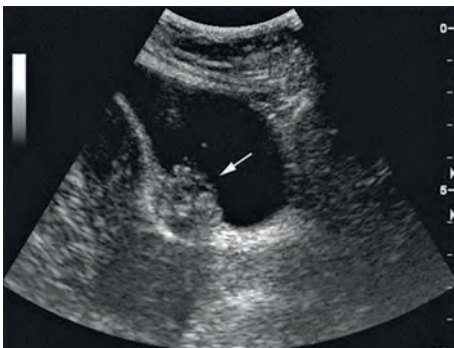are common. On rectal examination, one must determine the relationship between the lesions and the wall of the rectum, assessing the mobility of the rectal wall, and degree of disease affecting the utero-sacral ligaments. Although the decision to perform surgery for deep endometriosis is mainly clinical, ultrasonography and other imaging techniques such as magnetic resonance image (MRI) can be useful tools to allow preoperative assessment of lesions.

The objective of preoperative imaging is to map more precisely the areas affected by the disease, identifying especially those lesions that affect the gastrointestinal and urinary tracts.<sup>32</sup> The use of transvaginal pelvic ultrasound, improves the diagnostic accuracy of the examination, especially detection of ovarian endometrioma or DIE involving the uterosacral ligaments, the bladder, or the rectosigmoid (*Fig. 3.141*).<sup>2,11,28,29</sup> Ultrasound evaluation of the urinary tract is also important during the preoperative evaluation of bulky retrocervical DIE lesions and of lateral DIE lesions to exclude ureteral involvement.<sup>31</sup>

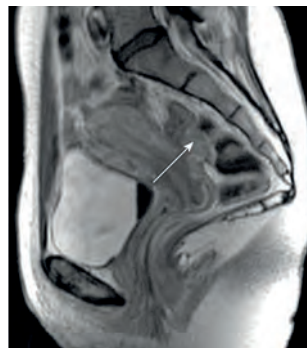Other diagnostic modalities such as rectal endoscopic sonography (RES), three dimensional ultrasound, and magnetic resonance imaging (MRI) for the assessment of DIE have also been used with good results (*Fig. 3.142*).<sup>6,58</sup> Although MRI is important for assessing ovarian endometriomas and multifocal intestinal DIE lesions, it does not replace a basic transvaginal ultrasound.



**Fig. 3.140** ICG dye in endometriotic lesion illuminated by Firefly™ technology demonstrating the lesions in dark green.



**Fig. 3.141** Ultrasound scan of endometriotic nodule within the bladder (**white arrow**).



**Fig. 3.142** The MRI image demonstrates an endometriotic nodule in the large intestine (**white arrow**).

### 3.9.4 Patient Positioning and Port Placement

The operating room table should be configured for gynecological procedures, with the ability to lower the bottom of the bed. A gel pad or another non-slip device should be placed between the operating room table and the patient. This will prevent the patient from sliding down after adequate Trendelenburg has been established. Shoulder braces should be avoided because of the risk of brachial plexus nerve injuries. We tuck the patient's arms as shown in the Fig. 3.143a. Obese patients are especially prone to shift on the operating room table during surgery. This movement can be problematic for both uterine manipulation and surgical field optimization.

A multi-port robotic technique is utilized. A 12-mm or 8.5-mm optical port is usually placed at the umbilicus or higher, depending on the size of the uterus if it is present. Two 8-mm robotic ports are placed 1 to 2 cm below the optical port and 8 cm lateral to it. Five- to 10-mm accessory ports can be placed according to the surgeon's preference. A fourth robotic arm can be placed at the discretion of the surgeon. Our port position is shown in Fig. 3.143b.

The operating room table is lowered, and the patient is placed in steep Trendelenburg (defined as 30–40 degrees 'head-down tilt') to allow optimal visualization with the bowel falling away from the pelvis into the upper abdomen (Fig. 3.143c). When the pelvis is cleared of bowel, the operating room table can be reversed until the bowel starts to fall back into the pelvis. This is typically between 15–20 degrees.

The traditional docking of the robot cart for gynecological procedures is between the patient's legs. The advantage of this docking position is that the camera and working arms are placed in the same axis as the patient's torso. However, this position poses challenges as access to the vagina is limited. An alternative to docking between the legs is side docking at an angle of 45 degrees from the midline with the central column of the robot cart and the camera arm in line with the patient's contralateral shoulder. This configuration offers the advantage that the bedside assistant, who is positioned between the patient's legs, can access the vagina more easily. Once the patient-side robotic cart is docked, the robot arms can be attached to the cannulas and robotic endoscope and instruments can be inserted.

### 3.9.5 General Surgical Approach

Diagnostic laparoscopy is performed initially. The surgeon explores the pelvic cavity to assess the extent of disease and identify abnormalities or distortions of the pelvic organs. The location and boundaries of the bladder, ureter, colon, rectum, pelvic gutters, uterosacral ligaments, and major blood vessels are noted. The upper abdominal organs, abdominal walls, liver, and diaphragm should be evaluated for endometriosis or any other condition that may contribute to the patient's symptoms. The omentum and the small bowel are evaluated for disease, and to ensure that they were not injured during insertion of the Veress needle or trocar. A rectovaginal examination is accomplished to evaluate deep and retroperitoneal endometriosis found in the lower pelvis at the rectovaginal septum, uterosacral ligament, lower colon, and pararectal area. In 15% of patients with endometriosis, the appendix is involved and should be examined.<sup>59</sup> Deep retroperitoneal endometriosis is rare without a connection to the surface peritoneum.

Once the initial survey is complete, the surgical robot is docked using a three or four arm technique. Limited instrumentation is available in the robotic platform as compared to conventional laparoscopy. However instrumentation that allows for cauterization and removal of endometriotic implants include cautery hook, spatula, scissors, and bipolar coagulation. We tend to use an atraumatic grasper in the left robotic arm and either a monopolar hook, spatula or scissors in the right robotic arm.

#### 3.9.5.1 Lysis of Adhesions

The methods used to restore normal anatomy and divide adhesions can vary according to bulk, vascularity, extent, and anatomical location. Filmy adhesions can be separated by blunt dissection. More dense adhesions require electro-surgical dissection at points of attachment to pelvic organs or the abdominal wall. This can be accomplished by use of the monopolar hook or scissors and the atraumatic grasping forceps. Structures requiring separation are teased apart along their cleavage plane. Hydro-dissection may be useful to help facilitate such planes. A safe area is sought, and a small incision is made with a scissors or electrocautery. The suction-irrigator is then introduced from the assistant port. Care must be taken with electro-surgery near the bowel, bladder, and vessels. If concern exists as to proximity to such organs, then cold scissors should be employed.

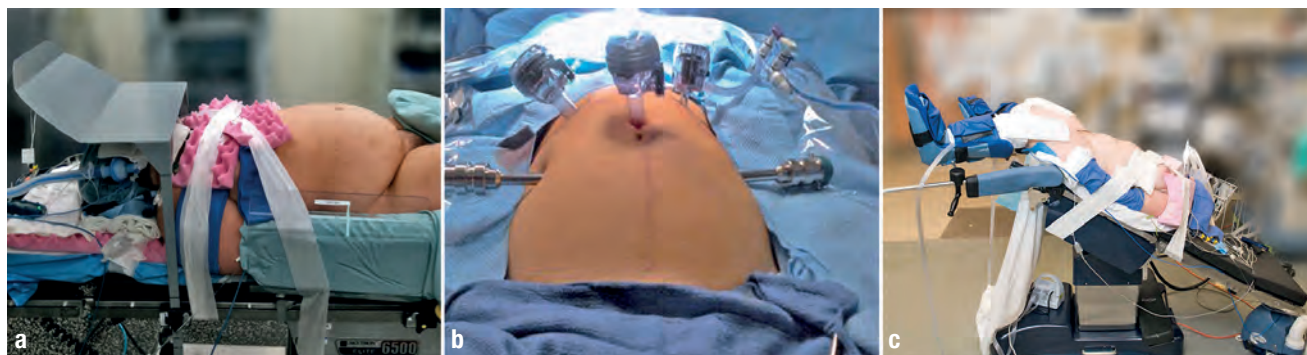

Fig. 3.143a–c Patient positioned with arms tucked at side (a). Port placement (b). Patient positioned in steep Trendelenburg (c).

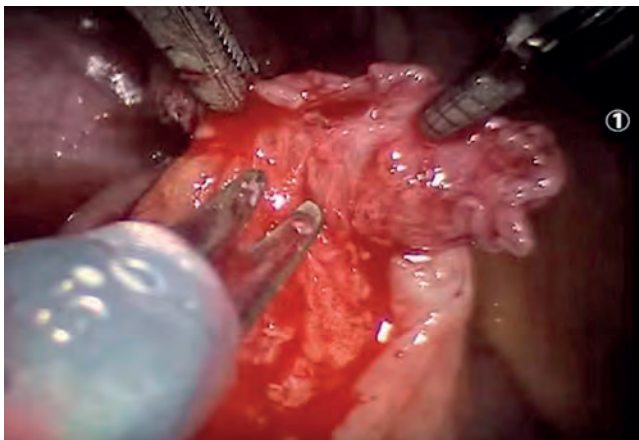
### 3.9.5.2 Gastrointestinal DIE

Intestinal endometriosis should be suspected in women of childbearing age who present with gastrointestinal symptoms and a history of endometriosis. Often we see that these patients have been previously misdiagnosed with irritable bowel syndrome. There appears to be intestinal involvement in about 45% to 56% of patients with DIE and in about 57.1% of women with ovarian endometriomas.<sup>59,61</sup>

Surgical intervention is necessary to dissect and resect infiltrating bowel endometriosis. Large bowel resection for obstructing endometriosis of the sigmoid colon was reported in 1909 by *Mackenrodt*.<sup>35</sup> Some surgeons still recommend it as primary treatment for bowel endometriosis. Although we previously advocated the use of bowel resection for patients with bowel endometriosis, over the last decade we have become more conservative in our use of bowel resection. Techniques used for excision of gastrointestinal DIE lesions include rectal shaving, disc excision, and segmental resection.<sup>45</sup>

### 3.9.5.3 Rectal Shaving

Rectal Shaving does not require the use of a stapling device. It can be used if the lesion is not circumferential and does not constrict the lumen of the bowel. Successful rectal shaving requires one important clinical finding: a clean plane beyond which there are no more endometriotic lesions. The extent of the lesion is evaluated visually and by palpation, using the tip of the suction-irrigator probe introduced through an assistant port. A sigmoidoscope may be used to further delineate the lesion and guide the surgeon. After the ureters are identified to avoid inadvertent injury, the lower colon is mobilized in all aspects except posteriorly. The pararectal space is entered, and the colon is separated from the adjacent organs. Full-thickness shaving is carried out beginning above the area of visible disease. Traditionally, gynecologists first separate the posterior surface of the nodule from the anterior wall of the rectum and then perform the separation of the lesion from the posterior vaginal fornix and from the retrocervical region.<sup>57</sup> The surgeon should follow the contour of the rectum around the endometriotic nodule (Fig. 3.144). The goal is to free the nodule completely from the bowel wall and to identify the healthy tissue distal to the nodule.



**Fig. 3.144** Endometriotic nodule on the large bowel is being separated using the shaving technique.

After separating the posterior surface of the nodule from the colon, further division from surrounding structure should be undertaken. Alternatively, one may use a surgical approach called a “reverse”.<sup>57</sup> In this technique, the anterior surface of the nodule is initially separated from the posterior surface of the uterus and vagina. This may allow for better mobility of the nodule when attempting to dissect it from the rectum.

Studies of laparoscopic rectal shaving techniques have demonstrated a significantly lower overall complication rate (6%) compared with disc excision (23%;  $p = 007$ ) and segmental resection.<sup>36</sup> Limited data exists for the robotic platform. *Pellegrino et al.* performed robotic assisted rectal shaving in a series of 25 women with DIE.<sup>56</sup> The subjects were well selected and shaving was only performed in patients where the lesion was superficial or had partially involved the muscular layer. There were no intra-operative complications in this series. The fertility outcome in patients with a history of infertility was 27%, which is comparable with estimates in the literature.<sup>56</sup> Complete or significant pain relief was reported in all cases at the third month of follow-up. Risk of recurrence has been noted to be high with rectal shaving,<sup>56,57</sup> and surgeons should be prepared for the risk of possibly entering the bowel during resection.<sup>57</sup>

### 3.9.5.4 Discoid Resection

Discoid resection entails wedge resection of the anterior wall of the rectum.<sup>56</sup> Two techniques have been described in the literature:

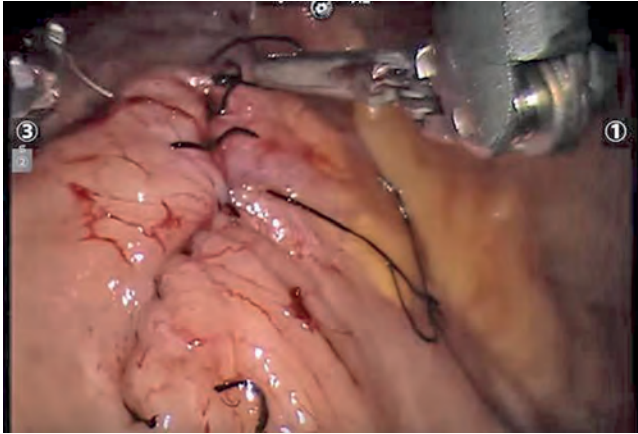
- resection of the endometrial nodule with the cold scissors, followed by rectal repair by manual suturing and
- resection of the endometrial nodule using a circular stapler inserted transanally.<sup>46,57</sup>

For the robotic platform, the first technique is primarily utilized. Discoid resection is most useful for single lesions of DIE. Those that are located on the anterior wall of the rectosigmoid colon with evidence of deep infiltration beyond the muscle layer, smaller lesions (less than 3 cm) or those that occupy less than one-third of the intestinal circumference are appropriate candidates.<sup>67</sup>

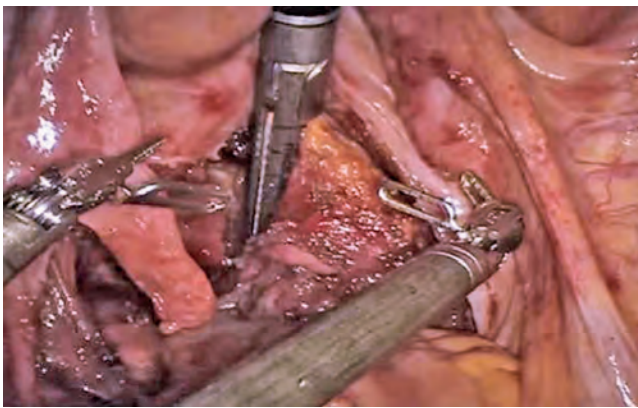
We first evaluate the extent of the lesion both visually and by palpation, using the tip of the suction irrigator probe introduced from the assistant port. A sigmoidoscope is used to further delineate the lesion and guide the surgeon. After the ureters are identified to avoid inadvertent injury, the lower colon is mobilized in all aspects except posteriorly. The pararectal space is entered, and the colon is separated from the adjacent organs. Full-thickness excision is carried out, beginning above the area of visible disease. After the normal tissue is identified, the lesion is held at its proximal end with grasping forceps. An incision is then made through the bowel serosa and muscularis in order to enter the lumen. The lesion is excised entirely from the anterior rectal wall. After complete excision of the lesion, the pelvic cavity is irrigated and suctioned. The bowel is repaired transversely in one layer. We approximate the edges of the bowel defect by placing several interrupted through-and-through polyglactin or polydioxanone sutures in 0.4 to 0.6 cm increments until the defect is completely closed



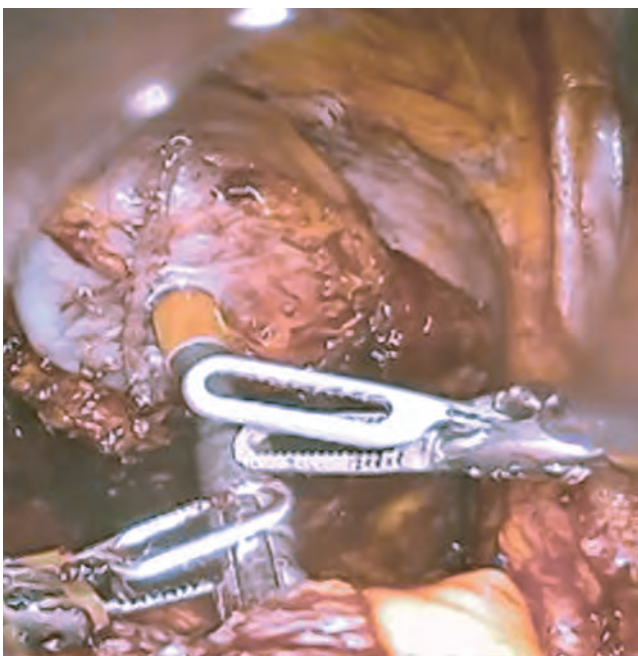(Fig. 3.145). At the end of the procedure, sigmoidoscopy is performed to ensure that the closure is water-tight and that there are no bowel strictures.



**Fig. 3.145** Edges of the bowel re-approximated with suture.



**Fig. 3.146** Rectum being transected with linear stapler.



**Fig. 3.147** End-to-end bowel anastomosis being performed with a robotic approach. The anvil was placed transanally.

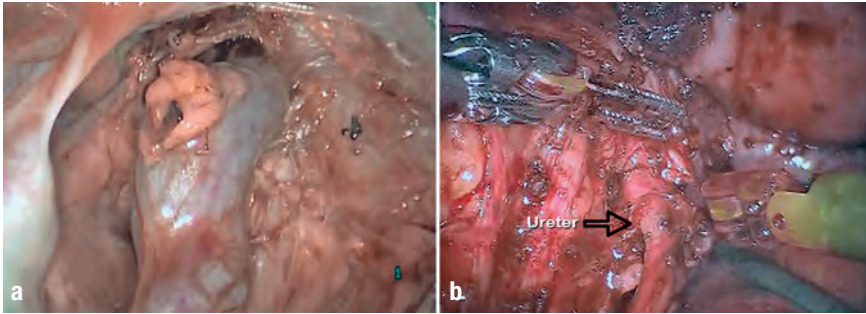
### 3.9.5.5 Segmental Resection

In patients who have severe disease of the bowel wall, with circumferential involvement, resection may be necessary. This requires full mobilization of the entire rectum. First the lateral rectal pedicles are electrocoagulated and the presacral space is entered up to the level of the levator ani muscles. The branches of the inferior mesenteric vessels of the bowel segment to be resected are coagulated and divided. The rectum is transected proximal to the lesion. A 2-0 nylon purse-string suture is placed at the end of the proximal bowel to secure the opposing anvil of the stapler. The anvil may be introduced abdominally transvaginally or transanally. The rectal stump, containing the endometriotic lesion, is transected proximal to the lesion using linear stapler (Fig. 3.146).

A circular EEA stapler is placed into the rectum, and the anvil in the proximal limb of the bowel is positioned into the stapling device by using the two robotic fenestrated graspers in each arm (Fig. 3.147). The device is fired, creating an end-to-end anastomosis. A proctoscope is used to examine the anastomosis for structural integrity and bleeding. The pelvis is filled with Ringer's lactate solution and observed with the camera as the rectum is insufflated with air to check for leakage. Air leaks can be corrected with 2-0 polyglactin sutures.

There is little data comparing the efficacy and outcomes of these techniques on a robotic platform. Advincula and colleagues demonstrated the feasibility of robotic assisted recto-sigmoidectomy in a series of 10 women.<sup>37</sup> *Diguisto et al.* compared robotic-assisted segmental resection (n = 6) versus rectal shaving (n = 21) in a small series of women.<sup>21</sup> The study found increased short and long term morbidity associated with segmental resection, with similar resolution of pain symptoms at 2 months follow-up. Other laparoscopic studies have demonstrated a higher pregnancy rate for less invasive procedures (shaving and discoid excision) compared with segmental resection.<sup>25</sup> A case-control study of laparoscopic discoid versus segmental resection for management of pain symptoms associated with DIE demonstrated similar results.<sup>36</sup> The authors concluded that discoid resection was more appropriate if the maximum diameter did not exceed 3 cm, with maximum involvement of less than one-half of the bowel circumference.<sup>36</sup>

The management of intestinal endometriosis depends on the depth of the bowel wall invasion (superficial, partial, or full-thickness invasion), leading to different surgical options (shaving, discoid excision, segmental resection). Surgery should strive to restore anatomy and be as conservative as possible, with the aim to excise all disease. Many authors have suggested that the incidence of recurrent endometriosis was higher if the endometriotic lesions of the bowel were not completely excised.<sup>1,23,26,60</sup> For complex cases of colorectal DIE, a well-trained multidisciplinary team may improve outcomes.<sup>4</sup>



**Fig. 3.148a,b** Intrinsic endometriosis of left ureter (a). Extrinsic endometriosis of left ureter (b).

### 3.9.6 Genitourinary DIE

#### 3.9.6.1 Ureteral Endometriosis

Urinary tract DIE may be found in about 6% of women presenting with pelvic endometriosis and may involve either the bladder or ureters.<sup>62</sup> Endometriosis of the ureter is rare, and occurs in 0.1–0.4% of cases.<sup>9</sup> Ureteral endometriosis is most commonly unilateral, involving a small segment of distal left ureter and often represented by a ureteric ring.<sup>9</sup> It is classified as intrinsic or extrinsic, depending on whether the uroepithelium and submucosal layer of the ureteral wall are infiltrated (Figs. 3.148a, b). In extrinsic lesions, endometrial glands and stroma only involve the adventitia, whereas intrinsic lesions, they involve the muscularis propria, lamina propria, or ureteral lumen.<sup>14</sup> Extrinsic compression of the ureter appears to be more common than intrinsic disease.<sup>14</sup> It most commonly affects the distal ureter, less commonly the mid-ureter, and rarely the proximal ureter.<sup>14</sup> Ureteral involvement may be due to the lateral spreading of deep endometriosis that infiltrates the rectovaginal space or uterosacral ligaments.<sup>22</sup> Progressive ureteral stenosis may be responsible for the destruction of the renal parenchyma and gradual renal loss of function.<sup>62</sup> Silent obstruction with loss of renal function occurs in 5–30% of women with urinary tract endometriosis; thus, early disease recognition is crucial.<sup>62</sup>

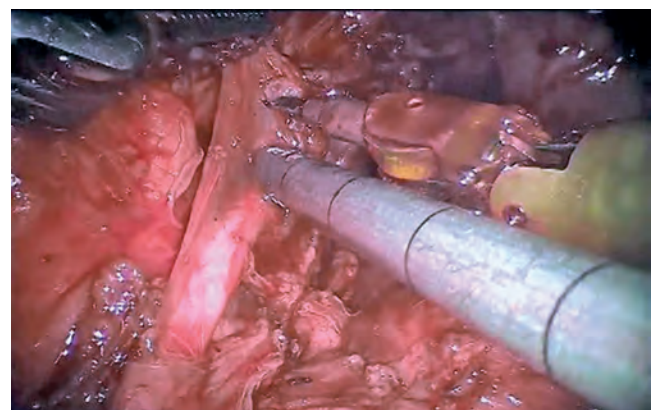
Ureteral endometriosis can be managed either medically or surgically, though medical management is generally considered palliative, until a more definitive surgical procedure can be performed. Ureterolysis is performed in cases of extrinsic non-obstructive disease. In cases of intrinsic disease, with obstruction or stenosis of the ureter, the diseased segment should be excised followed by either uretero-ureterostomy or uretero-neocystostomy.<sup>51</sup> In cases of renal compromise secondary to obstruction, a nephrectomy may be necessary.<sup>62</sup>

*Frick et al.* demonstrated the feasibility of RALS for treatment of ureter DIE in a case study of two patients.<sup>27</sup> The group described 2 cases of ureteral obstruction secondary to endometriosis managed with robotic-assisted laparoscopic partial ureterectomy and ureteroneocystostomy. Similarly *Nezhat et al.* published a report of 2 patients with endometriosis of the ureter, and 1 patient with endometriosis of the bladder managed my RALS with good surgical outcomes.<sup>40</sup>

RALS is an excellent modality for performing delicate procedure involving the ureter, and can facilitate the delicate suturing required for partial ureterectomy and ureteroneocystostomy. When we perform robotic assisted ureterolysis, a monopolar scissor or spatula (Fig. 3.149) is placed in the right robotic arm and an atraumatic grasper is used in the left robotic arm.

Due to the injury that may be caused from monopolar current, minimization of electrical current is advised. Hydro-dissection with a suction irrigator introduced from the assistant port can facilitate defining tissue planes. During robotic-assisted ureterolysis, care is taken to preserve the peri-ureteral vascular supply if the ureter is not directly affected by endometriosis, fibrosis, or inflammation. The blood supply to the distal ureter typically comes laterally from the iliac artery, whereas the mid- and proximal ureter's blood supply comes medially from the aorta. There is also a fine network of vessels that travel along the length of the ureter. Thus, ureterolysis should preserve the peri-ureteral tissue and adventitia of the ureter. In cases in which extrinsic ureteral involvement is minimal, ureterolysis alone may be all that is needed. The principles of success include atraumatic handling of the ureter and when feasible, interposition of normal tissue, such as omentum if necessary.<sup>44</sup> Based on extent and localization of lesion, a decision is made if ureterolysis alone is sufficient to manage the disease and its associated symptoms.

If stenosis is evident but limited to the ovarian fossa, and the distal ureter can be preserved, ureteral resection and end-to-end anastomosis can be performed over a ureteral stent. The surgical approach is modified if stenosis or lesion is observed in close proximity to the vesico-ureteral junction. In this case, the ureter is resected before the area of disease, and the proximal end is re-implanted into the bladder. Surgical principles of robotic ureteral surgery are the same as in laparoscopy. The ureter should be spatulated, and fine interrupted absorbable sutures such as 5-0 or 4-0 vicryl are used. Use of RALS greatly facilitates the required suturing.



**Fig. 3.149** Robotic ureterolysis using monopolar spatula and suction irrigator.



### 3.9.6.2 Bladder Endometriosis

Bladder DIE may be responsible for urinary symptoms including suprapubic pain, dysuria, cyclic hematuria, and urgency. Bladder endometriosis usually presents as an adenomyotic nodule.<sup>20</sup> These nodules are typically solitary and most frequently involve the dome and posterior wall of the bladder. The lesions tend to invade the detrusor musculature in an extrinsic fashion and often remain submucosal.<sup>8,20</sup> Using cystoscopy, these lesions appear as solitary submucosal lesions that are slightly raised, with little surrounding mucosal edema in the absence of concomitant cystitis or infection (Fig. 3.150).

Transurethral biopsy or resection may be inadequate for histologic diagnosis because of the submucosal nature of the lesion. Extravesically, the lesions can be identified by laparoscopy, and direct biopsy remains the gold standard of disease diagnosis and staging (Fig. 3.151). However, the actual extent of bladder involvement may be difficult to completely visualize with laparoscopy. Thus, a combined cystoscopic and laparoscopic approach is needed during definitive surgical resection.

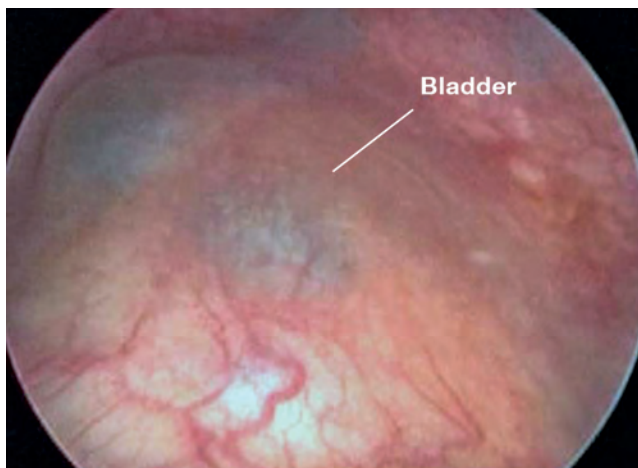
For cases of DIE involving the bladder, resection of the lesion with repair of the bladder is required. The surgical technique for all such cases begins with a cystoscopy and placement of bilateral ureteral stents. A laparoscopic assessment is then made from above, and the robot is brought in via a side docking or parallel docking technique to allow for easier access to the vaginal area. An atraumatic grasping forceps is used from the left robotic arm and monopolar scissors in the right robotic arm. The bladder is identified and careful dissection is carried out to separate bladder from the uterus and cervix. We first enter the vesicovaginal space and mobilize the bladder posteriorly. We then enter the right and left paravesical spaces as well as the space of Retzius to mobilize the bladder anteriorly. Once this is accomplished, a simultaneous cystoscopy is performed by an assistant. In this manner, the bladder incision can be performed under direct visualization, allowing for clear margins and assurance of integrity of the ureteral orifices. The bladder dome is held near the midline with the robotic grasper, and the endometriotic

nodule along with partial resection of the bladder wall is removed 5 mm beyond the lesion. After excision of the lesion, the bladder is repaired with a continuous running stitch and then with multiple interrupted sutures of 4-0 vicryl using the robotic suturing instruments. Once the cystostomy is closed, the bladder is tested for leaks with retrograde filling using methylene blue mixed with saline (Figs. 3.152a–d).

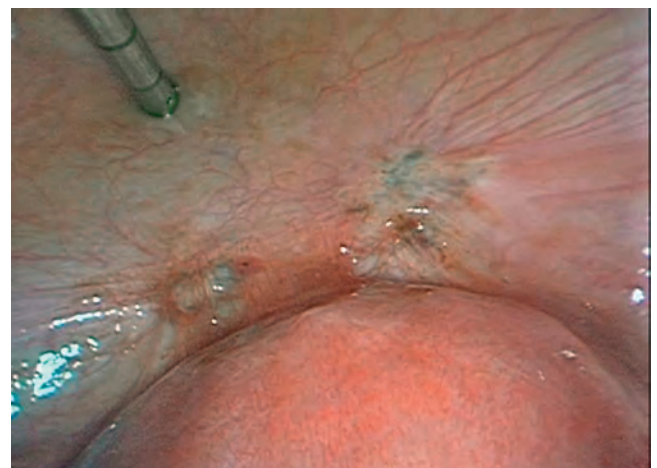### 3.9.6.3 Diaphragmatic DIE

Diaphragmatic endometriosis is rare and usually associated with severe pelvic involvement.<sup>49</sup> The treatment of abdominal diaphragmatic endometriosis by a conventional laparoscopic approach was first described by *Nezhat et al.* in 1992.<sup>49</sup> Superficial endometriosis on the abdominal surface of the diaphragm can be treated with cold scissors, monopolar energy, or bipolar energy. However, deeply infiltrating implants, or small perforations, are best treated by resection and reanastomosis with an endoscopic stapler device or by suturing the defect.<sup>49</sup> Larger diaphragmatic perforations can be sutured, but the recurrence rate is high.<sup>42</sup> Since both surfaces of the diaphragm can be involved with disease, a multi-disciplinary approach with concomitant thoracoscopy should be considered for all patients, especially those with history of catamenial hemothorax, catamenial pneumothorax, cyclic chest or shoulder pain, or cyclic dyspnea.<sup>48</sup>

RALS was first used for excision of a diaphragmatic endometriosis by *Cela et al.* in Italy.<sup>10</sup> For a robotic approach, we first make a laparoscopic assessment of the abdominal surface of the diaphragm and upper abdomen. For upper abdominal procedures, we generally dock the robot over the patient's right shoulder and the case is approached similar to an oncological operation. However, the advent of the Da Vinci Xi system (*Intuitive Surgical, Inc.*, Sunnyvale, CA) has afforded more flexibility in docking positions allowing the surgeon to access the upper abdomen. Currently, there is limited data on outcomes regarding the use of RALS for diaphragmatic endometriosis.

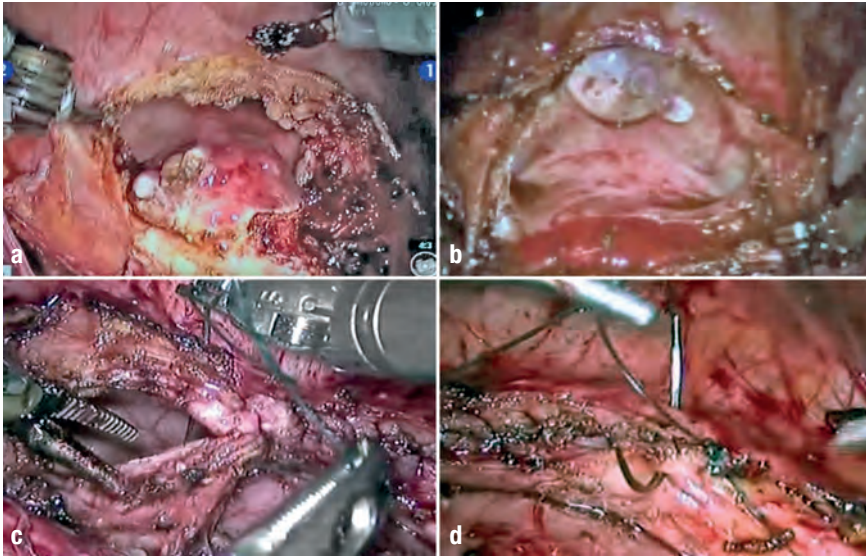


**Fig. 3.150** DIE lesions located within the bladder wall visualized by cystoscopy.



**Fig. 3.151** DIE lesions located within the bladder wall visualized by laparoscopy.





**Fig. 3.152a–d** Large nodule being excised from the bladder (a). View of bladder after partial excision of bladder wall (b). First layer bladder closure. Continuous running stitch with 4-0 vicryl suture (c). Second layer bladder closure. Interrupted imbricating stitch with 4-0 vicryl suture (d).

### 3.9.7 Limitations to the Robotic Platform

Robotic surgery has several disadvantages compared with traditional laparoscopy. These include increased cost; the lack of tactile feedback to the surgeon; the presence of bulky robotic arms, the inability to move the surgical table once the robot arms are attached; and a limited range of motion with respect to operating in different quadrants in the same case.

DIE can be found in multiple quadrants, including the upper abdomen, around the liver and the diaphragm, and on the appendix. In robotic-assisted laparoscopic cases of extensive intra-abdominal endometriosis, there is limited flexibility in changing camera locations and instrumentation. For difficult dissections via conventional laparoscopy, the surgeon is able to move the camera to different ports much more readily. This can only be accomplished robotically using a laparoscopy-robotic hybrid technique.<sup>54</sup> Although the limitation of approaching multiple quadrants has been overcome by the newer generation Da Vinci Xi system (*Intuitive Surgical, Inc.*, Sunnyvale, CA), it is costly and of limited availability to most surgeons.

When comparing laparoscopy to robotic surgery, *Nezhat et al.* found conventional laparoscopy and RALS to be excellent methods for treatment of advanced stages of endometriosis with comparable peri-operative outcomes.<sup>55</sup> The robotic platform however, may increase operative time and may be associated with longer hospital stay.<sup>53</sup> They attributed the increase in surgical time secondary to the difficulty of approaching multiple quadrants with a fixed camera. Furthermore, the instrumentation available for the robot is still in its infancy. Limited opportunity to utilize the carbon dioxide (CO<sub>2</sub>) laser with the Da Vinci robot is another factor that may have contributed to the increased operative time in the RALS procedures.<sup>53</sup> As noted by *Berker et al.*, the use of the CO<sub>2</sub> laser can be beneficial for precisely and safely excising DIE lesions with minimal bleeding and tissue damage. The robotic scissors and monopolar hook require extra care and time to prevent injury to surrounding structures. This leads to longer operative time, which, in combination with the increased

number of incisions and associated pain, may be the reason why hospital stay was longer in the robotic group.<sup>53</sup>

### 3.9.8 Conclusion

As technology advances, the present limitations of the robotic surgical system can be overcome, and surgeons will be able to perform more minimally invasive surgical procedures for treatment of DIE. Conventional laparoscopy, with and without robotic assistance, is associated with excellent results. The robotic platform may be a useful tool for surgeons who do not have an advanced skill set in conventional laparoscopy, so that a minimally invasive approach can still be offered. Treatment of DIE can be challenging as it is multi-focal and involves different organ-systems. Use of RALS may have potential to improve patient outcomes. At present, there are limited well-designed trials comparing outcomes of conventional and robotic-assisted laparoscopic surgery. Further studies are needed in this area. At present, RALS has demonstrated safety and efficacy and offers a minimally invasive alternative to open surgery.

### 3.9.9 References

1. ABBOTT JA, HAWE J, CLAYTON RD, GARRY R. The effects and effectiveness of laparoscopic excision of endometriosis: a prospective study with 2-5 year follow-up. *Hum Reprod* 2003;18(9):1922–7.
2. ABRAO MS, GONCALVES MO, DIAS JA JR, PODGAEC S, CHAMIE LP, BLASBALG R. Comparison between clinical examination, transvaginal sonography and magnetic resonance imaging for the diagnosis of deep endometriosis. *Hum Reprod* 2007;22(12):3092–7. doi:10.1093/humrep/dem187.
3. AVERBACH M, POPOUTCHI P, MARQUES OW JR, ABDALLA RZ, PODGAEC S, ABRAO MS. Robotic rectosigmoidectomy – pioneer case report in Brazil. *Current scene in colorectal robotic surgery. Arq Gastroenterol* 2010;47(1):116–8.
4. BACHMANN R, BACHMANN C, LANGE J, KRAMER B, BRUCKER SY, WALLWIENER D et al. Surgical outcome of deep infiltrating colorectal endometriosis in a multidisciplinary setting. *Arch Gynecol Obstet* 2014;290(5):919–24. doi:10.1007/s00404-014-3257-x.

5. BALLESTER M, SANTULLI P, BAZOT M, COUTANT C, ROUZIER R, DARAI E. Preoperative evaluation of posterior deep-infiltrating endometriosis demonstrates a relationship with urinary dysfunction and parametrial involvement. *J Minim Invasive Gynecol* 2011;18(1):36–42. doi:10.1016/j.jmig.2010.08.692.
6. BAZOT M, LAFONT C, ROUZIER R, ROSEAU G, THOMASSIN-NAGGARA I, DARAI E. Diagnostic accuracy of physical examination, transvaginal sonography, rectal endoscopic sonography, and magnetic resonance imaging to diagnose deep infiltrating endometriosis. *Fertil Steril* 2009;92(6):1825–33. doi:10.1016/j.fertnstert.2008.09.005.
7. BEDAIWY MA, RAHMAN MY, CHAPMAN M, FRASURE H, MAHAJAN S, GRUENIGEN VE VON et al. Robotic-assisted hysterectomy for the management of severe endometriosis: a retrospective review of short-term surgical outcomes. *JSLs* 2013;17(1):95–9. doi:10.4293/108680812X13517013317275.
8. BERKES E, BOKOR A, RIGO J JR. Current treatment of endometriosis with laparoscopic surgery. *Orv Hetil* 2010;151(28):1137–44. doi:10.1556/OH.2010.28904.
9. BOSEV D, NICOLL LM, BHAGAN L, LEMYRE M, PAYNE CK, GILL H et al. Laparoscopic management of ureteral endometriosis: the Stanford University hospital experience with 96 consecutive cases. *J Urol* 2009;182(6):2748–52. doi:10.1016/j.juro.2009.08.019.
10. CELA V, SIMI G, OBINO M, UCCELLI A, D'ISIDORO C, MORELLI L et al. Diaphragmatic endometriosis: review of the literature and first case of robot-assisted laparoscopic treatment. *Journal of Endometriosis* 2014;6(4):219–24.
11. CHAMIE LP, PEREIRA RM, ZANATTA A, SERAFINI PC. Transvaginal US after bowel preparation for deeply infiltrating endometriosis: protocol, imaging appearances, and laparoscopic correlation. *Radiographics* 2010;30(5):1235–49. doi:10.1148/rg.305095221.
12. CHAMMAS MF JR, KIM FJ, BARBARINO A, HUBERT N, FEUILLU B, COISSARD A et al. Asymptomatic rectal and bladder endometriosis: a case for robotic-assisted surgery. *Can J Urol* 2008;15(3):4097–100.
13. CHAPRON C, BARAKAT H, FRITEL X, DUBUISSON JB, BREART G, FAUCONNIER A. Presurgical diagnosis of posterior deep infiltrating endometriosis based on a standardized questionnaire. *Hum Reprod* 2005;20(2):507–13. doi:10.1093/humrep/deh627.
14. CHAPRON C, CHIODO I, LECONTE M, AMSELLEM-OUAZANA D, CHOPIN N, BORGHESE B et al. Severe ureteral endometriosis: the intrinsic type is not so rare after complete surgical exeresis of deep endometriotic lesions. *Fertil Steril* 2010;93(7):2115–20. doi:10.1016/j.fertnstert.2009.01.102.
15. CHAPRON C, CHOPIN N, BORGHESE B, FOULOT H, DOUSSET B, VACHER-LAVENU MC et al. Deeply infiltrating endometriosis: pathogenetic implications of the anatomical distribution. *Hum Reprod* 2006;21(7):1839–45. doi:10.1093/humrep/del079.
16. CHAPRON C, FAUCONNIER A, DUBUISSON JB, BARAKAT H, VIEIRA M, BREART G. Deep infiltrating endometriosis: relation between severity of dysmenorrhoea and extent of disease. *Hum Reprod* 2003;18(4):760–6.
17. CHOPIN N, BALLESTER M, BORGHESE B, FAUCONNIER A, FOULOT H, MALARTIC C et al. Relation between severity of dysmenorrhea and endometrioma. *Acta Obstet Gynecol Scand* 2006;85(11):1375–80. doi:10.1080/00016340600935490.
18. CHOPIN N, VIEIRA M, BORGHESE B, FOULOT H, DOUSSET B, COSTE J et al. Operative management of deeply infiltrating endometriosis: results on pelvic pain symptoms according to a surgical classification. *J Minim Invasive Gynecol* 2005;12(2):106–12. doi:10.1016/j.jmig.2005.01.015.
19. COLLINET P, LEGUEVAQUE P, NEME RM, CELA V, BARTON-SMITH P, HEBERT T et al. Robot-assisted laparoscopy for deep infiltrating endometriosis: international multicentric retrospective study. *Surg Endosc* 2014;28(8):2474–9. doi:10.1007/s00464-014-3480-3.
20. COMITER CV. Endometriosis of the urinary tract. *Urol Clin North Am* 2002;29(3):625–35.
21. DIGUISTO C, HEBERT T, PATERNOTTE J, KELLAL I, MARRET H, OULDAMER L et al. Robotic assisted laparoscopy: comparison of segmentary colorectal resection and shaving for colorectal endometriosis. *Gynecol Obstet Fertil* 2015;43(4):266–70. doi:10.1016/j.gyobfe.2015.02.006.
22. DONNEZ J, NISOLLE M, SQUIFFLET J. Ureteral endometriosis: a complication of rectovaginal endometriotic (adenomyotic) nodules. *Fertil Steril* 2002;77(1):32–7.
23. DUBERNARD G, PIKETTY M, ROUZIER R, HOURY S, BAZOT M, DARAI E. Quality of life after laparoscopic colorectal resection for endometriosis. *Hum Reprod* 2006;21(5):1243–7. doi:10.1093/humrep/dei491.
24. EMMANUEL KR, DAVIS C. Outcomes and treatment options in rectovaginal endometriosis. *Curr Opin Obstet Gynecol* 2005;17(4):399–402.
25. FANFANI F, FAGOTTI A, GAGLIARDI ML, RUFFO G, CECCARONI M, SCAMBIA G et al. Discoid or segmental rectosigmoid resection for deep infiltrating endometriosis: a case-control study. *Fertil Steril* 2010;94(2):444–9. doi:10.1016/j.fertnstert.2009.03.066.
26. FLEISCH MC, XAFIS D, BRUYNE F DE, HUCKE J, BENDER HG, DALL P. Radical resection of invasive endometriosis with bowel or bladder involvement – long-term results. *Eur J Obstet Gynecol Reprod Biol* 2005;123(2):224–9. doi:10.1016/j.ejogrb.2005.04.007.
27. FRICK AC, BARAKAT EE, STEIN RJ, MORA M, FALCONE T. Robotic-assisted laparoscopic management of ureteral endometriosis. *JSLs* 2011;15(3):396–9. doi:10.4293/108680811X13125733356314.
28. GONCALVES MO, PODGAEC S, DIAS JA JR, GONZALEZ M, ABRAO MS. Transvaginal ultrasonography with bowel preparation is able to predict the number of lesions and rectosigmoid layers affected in cases of deep endometriosis, defining surgical strategy. *Hum Reprod* 2010;25(3):665–71. doi:10.1093/humrep/dep433.
29. HUDELIST G, BALLARD K, ENGLISH J, WRIGHT J, BANERJEE S, MASTOROUDES H et al. Transvaginal sonography vs. clinical examination in the preoperative diagnosis of deep infiltrating endometriosis. *Ultrasound Obstet Gynecol* 2011;37(4):480–7. doi:10.1002/uog.8935.
30. JERBY BL, KESSLER H, FALCONE T, MILSOM JW. Laparoscopic management of colorectal endometriosis. *Surg Endosc* 1999;13(11):1125–8.
31. KONDO W, BRANCO AW, TRIPPIA CH, RIBEIRO R, ZOMER MT. Retrocervical deep infiltrating endometriotic lesions larger than thirty millimeters are associated with an increased rate of ureteral involvement. *J Minim Invasive Gynecol* 2013;20(1):100–3. doi:10.1016/j.jmig.2012.09.012.
32. KONDO W, ZOMER M, RIBERIO R, TRIPPIA C, OLIVERA M, CRISP C. Laparoscopic Treatment of Deep Infiltrating Endometriosis of the Intestine – Technical Aspects. *Braz. J. Video-Sur* 2012;2(5):23–39.
33. LAFAY PMC, HUCHON C, SANTULLI P, BORGHESE B, CHAPRON C, FAUCONNIER A. A clinical score can predict associated deep infiltrating endometriosis before surgery for an endometrioma. *Hum Reprod* 2014;29(8):1666–76. doi:10.1093/humrep/deu128.

34. LIU C, PERISIC D, SAMADI D, NEZHAT F. Robotic-assisted laparoscopic partial bladder resection for the treatment of infiltrating endometriosis. *J Minim Invasive Gynecol* 2008;15(6):745–8. doi:10.1016/j.jmig.2008.07.002.
35. MEYER R. Über entzündliche heterotope Epithelwucherungen im weiblichen Genitalgebiete und über eine bis in die Wurzel des Mesocolon ausgedehnte benigne Wucherung des Darmepithels. *Virchows Arch. path Anat.* 1909;195(3):487–537. doi:10.1007/bf02088858.
36. MOHR C, NEZHAT FR, NEZHAT CH, SEIDMAN DS, NEZHAT CR. Fertility considerations in laparoscopic treatment of infiltrative bowel endometriosis. *JLS* 2005;9(1):16–24.
37. NEME RM, SCHRAIBMAN V, OKAZAKI S, MACCAPANI G, CHEN WJ, DOMIT CD et al. Deep infiltrating colorectal endometriosis treated with robotic-assisted rectosigmoidectomy. *JLS* 2013;17(2):227–34. doi:10.4293/108680813X13693422521836.
38. NEZHAT C, CROWGEY S, NEZHAT F. Videolaseroscopy for the treatment of endometriosis associated with infertility. *Fertil Steril* 1989;51(2):237–40.
39. NEZHAT C, HAJHOSSEINI B, KING LP. Robotic-assisted laparoscopic treatment of bowel, bladder, and ureteral endometriosis. *JLS* 2011;15(3):387–92. doi:10.4293/108680811X13125733356396.
40. NEZHAT C, HAJHOSSEINI B, KING LP. Robotic-assisted laparoscopic treatment of bowel, bladder, and ureteral endometriosis. *JLS* 2011;15(3):387–92. doi:10.4293/108680811X13125733356396.
41. NEZHAT C, LAVIE O, LEMYRE M, UNAL E, NEZHAT CH, NEZHAT F. Robot-assisted laparoscopic surgery in gynecology: scientific dream or reality? *Fertil Steril* 2009;91(6):2620–2. doi:10.1016/j.fertnstert.2008.03.070.
42. NEZHAT C, MAIN J, PAKA C, NEZHAT A, BEYGUI RE. Multidisciplinary treatment for thoracic and abdominopelvic endometriosis. *JLS* 2014;18(3). doi:10.4293/JLS.2014.00312.
43. NEZHAT C, NEZHAT F. Operative laparoscopy (minimally invasive surgery): state of the art. *J Gynecol Surg* 1992;8(3):111–41. doi:10.1089/gyn.1992.8.111.
44. NEZHAT C, NEZHAT F (EDS.). *Nezhat's Video-Assisted and Robotic-Assisted Laparoscopy and Hysteroscopy*. 4th ed. New York: Cambridge University Press; 2013.
45. NEZHAT C, NEZHAT F, PENNINGTON E. Laparoscopic treatment of infiltrative rectosigmoid colon and rectovaginal septum endometriosis by the technique of videolaparoscopy and the CO2 laser. *Br J Obstet Gynaecol* 1992;99(8):664–7.
46. NEZHAT C, NEZHAT F, PENNINGTON E, NEZHAT CH, AMBROZE W. Laparoscopic disk excision and primary repair of the anterior rectal wall for the treatment of full-thickness bowel endometriosis. *Surg Endosc* 1994;8(6):682–5.
47. NEZHAT C, NEZHAT FR. Safe laser endoscopic excision or vaporization of peritoneal endometriosis. *Fertil Steril* 1989;52(1):149–51.
48. NEZHAT C, NICOLL LM, BHAGAN L, HUANG JQ, BOSEV D, HAJHOSSEINI B et al. Endometriosis of the diaphragm: four cases treated with a combination of laparoscopy and thoracoscopy. *J Minim Invasive Gynecol* 2009;16(5):573–80. doi:10.1016/j.jmig.2009.06.012.
49. NEZHAT C, SEIDMAN DS, NEZHAT F. Laparoscopic surgical management of diaphragmatic endometriosis. *Fertil Steril* 1998;69(6):1048–55.
50. NEZHAT CH, MALIK S, OSIAS J, NEZHAT F, NEZHAT C. Laparoscopic management of 15 patients with infiltrating endometriosis of the bladder and a case of primary intravesical endometrioid adenocarcinoma. *Fertil Steril* 2002;78(4):872–5.
51. NEZHAT CH, NEZHAT F, SEIDMAN D, NEZHAT C. Laparoscopic ureteroureterostomy: a prospective follow-up of 9 patients. *Prim Care Update Ob Gyns* 1998;5(4):200.
52. NEZHAT CR, NEZHAT F, ADMON D, SEIDMAN D, NEZHAT CH. Laparoscopic Management of Genitourinary Endometriosis. *J Am Assoc Gynecol Laparosc* 1994;1(4, Part 2):S25.
53. NEZHAT CR, STEVENS A, BALASSIANO E, SOLIEMANNJAD R. Robotic-assisted laparoscopy vs conventional laparoscopy for the treatment of advanced stage endometriosis. *J Minim Invasive Gynecol* 2015;22(1):40–4. doi:10.1016/j.jmig.2014.06.002.
54. NEZHAT F, KHALIL S, FINGER T, VETERE P. Combined conventional and robotic-assisted laparoscopy for staging and debulking of early, advanced and recurrent ovarian, fallopian tube and primary peritoneal cancer. A hybrid technique. *Gynecol Surg* 2013;11(05).
55. NEZHAT FR, SIROTA I. Perioperative outcomes of robotic assisted laparoscopic surgery versus conventional laparoscopy surgery for advanced-stage endometriosis. *JLS* 2014;18(4). doi:10.4293/JLS.2014.00094.
56. PELLEGRINO A, DAMIANI GR, TRIO C, FACCIOLI P, CROCE P, TAGLIABUE F et al. Robotic Shaving Technique in 25 Patients Affected by Deep Infiltrating Endometriosis of the Rectovaginal Space. *J Minim Invasive Gynecol* 2015;22(7):1287–92. doi:10.1016/j.jmig.2015.06.002.
57. PERPER MM, NEZHAT F, GOLDSTEIN H, NEZHAT CH, NEZHAT C. Dysmenorrhea is related to the number of implants in endometriosis patients. *Fertil Steril* 1995;63(3):500–3.
58. PHILIP CA, BISCH C, COULON A, SAINT-HILAIRE P DE, RUDIGOZ RC, DUBERNARD G. Correlation between three-dimensional rectosonography and magnetic resonance imaging in the diagnosis of rectosigmoid endometriosis: a preliminary study on the first fifty cases. *Eur J Obstet Gynecol Reprod Biol* 2015;187:35–40. doi:10.1016/j.ejogrb.2015.02.006.
59. PRYSTOWSKY JB, STRYKER SJ, UJIKI GT, POTICHA SM. Gastrointestinal endometriosis. Incidence and indications for resection. *Arch Surg* 1988;123(7):855–8.
60. REDWINE DB, WRIGHT JT. Laparoscopic treatment of complete obliteration of the cul-de-sac associated with endometriosis: long-term follow-up of en bloc resection. *Fertil Steril* 2001;76(2):358–65.
61. REMORGIDA V, FERRERO S, FULCHERI E, RAGNI N, MARTIN DC. Bowel endometriosis: presentation, diagnosis, and treatment. *Obstet Gynecol Surv* 2007;62(7):461–70. doi:10.1097/01.ogx.0000268688.55653.5c.
62. ROZSNYAI F, ROMAN H, RESCH B, DUGARDIN F, BERROCAL J, DESCARGUES G et al. Outcomes of surgical management of deep infiltrating endometriosis of the ureter and urinary bladder. *JLS* 2011;15(4):439–47. doi:10.4293/108680811X13176785203798.
63. SHAW RW. Treatment of endometriosis. *Lancet* 1992;340(8830):1267–71.
64. SIESTO G, IEDA N, ROSATI R, VITOBELLO D. Robotic surgery for deep endometriosis: a paradigm shift. *Int J Med Robot* 2014;10(2):140–6. doi:10.1002/rcs.1518.
65. STYLOPOULOS N, RATTNER D. Robotics and ergonomics. *Surg Clin North Am* 2003;83(6):1321–37. doi:10.1016/S0039-6109(03)00161-0.
66. VIGNALI M, BIANCHI S, CANDIANI M, SPADACCINI G, OGGIONI G, BUSACCA M. Surgical treatment of deep endometriosis and risk of recurrence. *J Minim Invasive Gynecol* 2005;12(6):508–13. doi:10.1016/j.jmig.2005.06.016.
67. WOODS RJ, HERIOT AG, CHEN FC. Anterior rectal wall excision for endometriosis using the circular stapler. *ANZ J Surg* 2003;73(8):647–8.



## 3.10

## Robotic Assistance in Endometriosis Surgery – Is this Technology a Game Changer?

R. Sinha<sup>a</sup> | S. Madhumathi<sup>b</sup> | B. Rupa<sup>c</sup> | K. Samita<sup>d</sup>

### 3.10.1 Introduction

Endometriosis is a chronic gynecologic disorder that affects more than 70 million women and adolescents worldwide, who may even suffer a life time from the disease.<sup>15</sup> The estimated prevalence of endometriosis is 5%–15% among women of child-bearing age, 20% to 48% among women suffering from infertility and 70% of women with chronic pelvic pain not responding to hormone therapy or to other types of medication regimens.<sup>3</sup>

Chronic pelvic pain and infertility are the most debilitating symptoms that often distress the patients and their treating physicians alike. At present, there are no clinical biomarkers that may be used in diagnosing the condition at an early stage. Considering that endometriosis is a slow and progressive disease, it takes years to develop lesions which are amenable to detection by traditional diagnostic modalities such as ultrasonography (USG) or magnetic resonance imaging (MRI). Accordingly, by the time of definitive diagnosis, these women require surgical therapy for overt clinical symptoms suggestive of advanced-stage disease, like dysmenorrhoea, chronic non-cyclical pelvic pain, subfertility, heavy menstrual bleeding or abdominal symptoms. Early diagnosis and diligent management by use of medical and/or surgical treatment can give hope to these women. Recurrent disease with persistence of symptoms is frustrating and often arises from inadequate surgical clearance.

Performance-limiting factors for the outcome of laparoscopic treatment in advanced-stage endometriosis are the surgeons' skills and experience of the team. The use of a robotic platform is a logical step forward to advanced laparoscopy and, provided the per-procedure costs are adequately addressed in

the future, this innovative technology may become more widely accepted among gynecological surgeons all over the world.<sup>14</sup> The authors hold the opinion, that it would be appropriate to compare robotic-assisted surgery with laparotomy rather than laparoscopy done by skilled and experienced surgeons.

### 3.10.2 Why Robotic Assistance?

In the therapeutic armamentarium used in today's operative gynecology, minimal access surgery (laparoscopy) is the gold standard for diagnosis of endometriosis. Surgical treatment can be accomplished either in a laparoscopic setting primarily adopted for diagnostic purposes, or later on, upon failure of conservative therapy. In the past decades, laparoscopy, to a large degree, has replaced laparotomy for the treatment of endometriosis on account of obvious advantages.<sup>9</sup> However, still a large proportion of women is suffering from endometriosis while not receiving adequate surgical clearance via minimal access surgery for relief of pain symptoms and/or improvement of fecundity. This is either due to inadequate surgery as a result of poor surgical skills, or may arise from procedures, initiated as minimal access surgery, that are eventually converted to open surgery. Minimal access surgery for endometriosis is still universally elusive.

In an attempt to fill this gap and to offer minimal access surgery to all patients identified as candidates for this type of treatment, a new technology of robotic-assisted laparoscopic surgery is slowly gaining ground. The use of a 3D console allows for enhanced depth perception, which is of tremendous advantage when dissecting along tissue planes during endometriosis surgery. The inherent benefits of robotic assistance are its intuitive movements and articulating instruments which provide greater range of motion and complete filtration of physiologic tremor.<sup>10</sup> The *da Vinci Surgical System* (Intuitive Surgical, Inc., Sunnyvale, CA, USA) with EndoWrist™ technology offers an increased motion range with regard to instruments (7 degrees of freedom) and enables the surgeon to adopt the same techniques as in open surgery. The latter is particularly helpful when coping with technical challenges of surgical maneuvers that require a high level of proficiency in a conventional laparoscopic setting, such as adhesiolysis in endometriosis patients and in those who need restoration of pelvic anatomy. However, robotic technology alone is not capable of simplifying the challenges of advanced cases of endometriosis. Even though endoscopic techniques for managing endometriosis stage III and/or IV are in fact facilitated by the use of a *da Vinci Surgical System*, an operative-gynecologic endoscopist with a good level of knowledge of surgical anatomy and experience in endometriosis surgery is still a key factor for the successful outcome of surgery. Described in a simplistic way, one might go as far as to say that robotic assistance is capable of making a good surgeon excellent. The realistic prospects of performing complete surgery while minimizing the risk of conversion to

<sup>a</sup> MBBS, MD, DNB, MICOG, PGDMLS, MNAMS; Senior Consultant, Minimal Access and Robotic Surgeon, Department of Gynecology, Minimal Access and Robotic Surgery, Apollo Health City, Hyderabad, Telangana, India

<sup>b</sup> Senior Consultant; Department of Gynecology, Minimal Access and Robotic Surgery, Apollo Health City, Hyderabad, Telangana, India

<sup>c</sup> MD, Senior Registrar; Department of Gynecology, Minimal Access and Robotic Surgery, Apollo Health City, Hyderabad, Telangana, India

<sup>d</sup> Resident (DNB); Department of Gynecology, Minimal Access and Robotic Surgery, Apollo Health City, Hyderabad, Telangana, India


#### Corresponding author:

**Sinha Rooma**, MBBS; MD; DNB; MICOG; PGDMLS; MNAMS  
Senior Consultant, Department of Gynecology,  
Minimal Access and Robotic Surgery,  
Apollo Health City  
A 402, Aparna Towers, Kondapur, Hyderabad  
500084, Telangana, India  
E-mail: drroomasinha@hotmail.com

laparotomy in endometriosis management is where robotic-assisted surgery stands a good chance of emerging as a game changer in women's health care.

The *da Vinci Surgical System* provides enhanced 3D visualization with 10x magnification and typically comes with EndoWrist™ instruments offering seven degrees of freedom. The cumulative benefits derived from the use of this system facilitate a precise and careful dissection. The basic system configuration has three components. The first component is the vision cart (Fig. 3.153a), which provides two-dimensional viewing conditions through a 12-mm bi-channeled endoscope. The bi-channeled scope offers a 3D vision to the surgeon who operates while sitting at the console. The second component is the patient-side cart (Fig. 3.153b) with robotic arms and EndoWrist™ instruments. Whether to use two or three instruments commonly depends on surgeon's preferences and the case profile. The third component is the surgeon console which is located away from the operating table, but in

the same operating room. The surgeon is comfortably seated at the console while viewing the high-definition 3D image on the integrated stereo display (Fig. 3.153c). With the aid of the master controls located below the display, the movements of the surgeon's hands, wrist, and fingers are translated into real-time actions of the EndoWrist™ instruments positioned in the operative field via 8-mm ports. Beneath the console are various foot pedals for control of energy devices, camera adjustment, and a quick-change mechanism for seamlessly swapping between instruments. Once a good level of familiarity with all functions of the *da Vinci Surgical System* has been reached, the surgeon can exercise near-total control over the surgical field without being dependent on an assistant, as is the case with standard laparoscopy. A comparison of the benefits and drawbacks of standard laparoscopy with those offered by robotic-assisted laparoscopy (with focus on endometriosis) is shown in Table 3.9.



**Figs. 3.153a–c** Vision cart of the *da Vinci Surgical System* (a). Patient-side cart with robotic arms (b). Surgeon console of the *da Vinci Surgical System* (Intuitive Surgical, Inc., Sunnyvale, CA, USA) (c).

Drawbacks of Conventional Laparoscopy	Benefits of Robotic Assistance
2D vision.	3D vision.
5x magnification.	10x magnification.
Physiological tremor of surgeon	Tremor filtration by robotic platform.
Camera controlled by assistant resulting in an <b>unsteady image</b>	Camera controlled by surgeon at console. <b>Steady image</b>
Fixed axis of instruments with fulcrum at the level of abdominal wall	Fulcrum at the wrist of instruments. Seven degrees of freedom allowing micro-movements of instruments.
Dissecting along tissue planes is difficult, especially in cases of advanced endometriosis.	Dissecting along tissue planes is facilitated due to 3D vision and 7 degrees of freedom. Particularly useful in advanced cases of endometriosis.
Limited access to deep pelvic structures	Unlimited access to deep pelvic structures
Operating in an unergonomic working posture for prolonged periods of time can result in physical discomfort and early fatigue for the surgeon and assistant.	Improved ergonomics, comfortable working posture.
Intracorporeal suturing is difficult.	Suturing facilitated due to wristed instruments.
Prolonged learning curve	Reduced learning curve

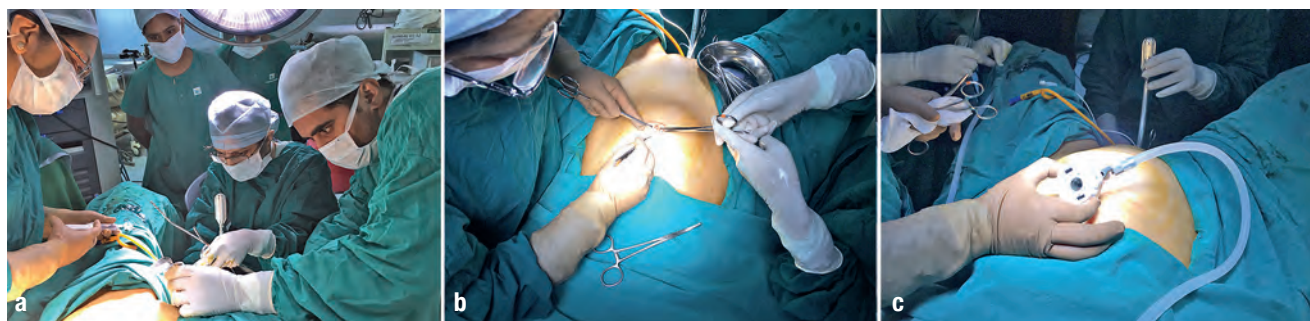**Table 3.9** Inherent drawbacks of standard laparoscopy compared to the benefits of robotic-assisted laparoscopy.



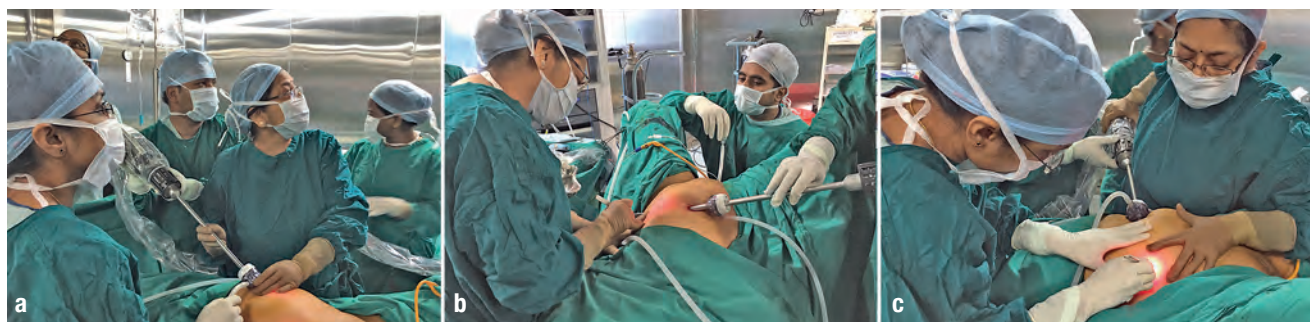### 3.10.3 Sequential Steps of Robotic-Assisted Endometriosis Surgery

- 1. Preoperative Preparation.** Liquid diet for 24 hours prior to surgery and fasting for the last 6 hours before surgery. The authors do not recommend mechanical bowel preparation even in patients with stage 3 or 4 endometriosis. Antibiotic prophylaxis is given as 1 gm cefotaxime one hour before induction of anesthesia.
- 2. Anesthesia.** General anesthesia is required in all patients undergoing robotic surgery. A Foley catheter is placed intraoperatively and removed either immediately after surgery or as soon as the patient can independently get out of bed to go to the lavatory.
- 3. Patient Positioning and Port Placement.** The patient is put in a dorsal lithotomy position and an uterine manipulator is placed in the uterine cavity (Fig. 3.154a). The primary 12-mm camera port is placed at the umbilicus. The authors

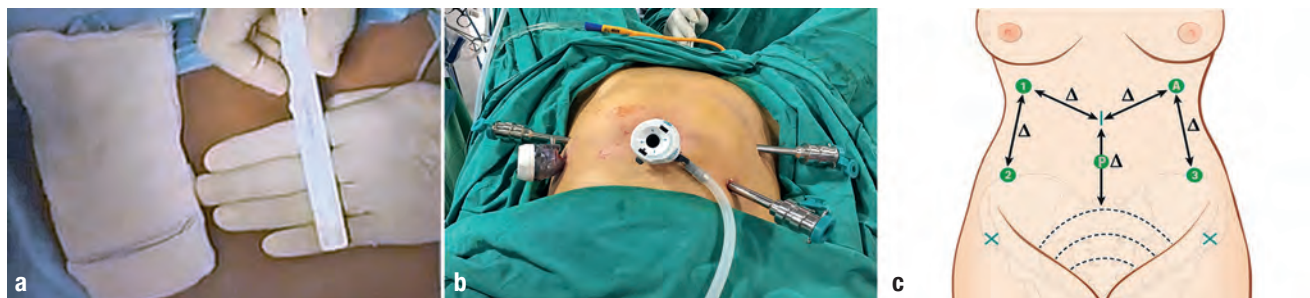prefer to establish the primary port using the open entry method (Fig. 3.154b). In the presence of a large pelvic mass, the primary port site may be shifted caudally in the midline. Once the pneumoperitoneum has been created via the primary port (Fig. 3.154c), the patient is moved to Trendelenburg position with 15–20 degrees tilt. At this point, a panoramic view of the pelvis is taken first, followed by mapping of the endometriotic lesions for planning of the next surgical steps (Fig. 3.155a). Accessory port sites should be chosen according to surgeon's preferences and the type of surgery to be performed (Figs. 3.155b, c). The distance between the ports should measure at least a palm's breadth (Fig. 3.156a) (approx. 10 cm) to avoid clashing of the robotic arms. The final port configuration is shown in (Figs. 3.156b, c and Fig. 3.158), with the primary port located at the umbilicus, two 8-mm ports on the right lateral side, one 8-mm port on the left side, and one 5-mm port for the assistant in the left upper quadrant.



**Figs. 3.154a–c** The RUMI uterine manipulator is placed in the uterine cavity (a). The incision for the primary port is made at the umbilicus (b). The 12-mm port for the robotic camera is completed at the umbilicus (c).



**Figs. 3.155a–c** First, a panoramic view of the pelvis is obtained (a). Superficial skin markings are made for the lateral ports (b). The 8-mm lateral ports are established, once the respective incisions have been safely placed with the aid of transillumination (c).




**Figs. 3.156a–c** The minimum distance between the ports should measure approximately a palm's breadth (a). External view of the final port configuration (b); camera port (P) at the umbilicus; two 8-mm lateral ports (1 and 2) are placed on the right side; one 8-mm (3) port and one 5-mm port (A) are placed on the left lateral side (b, c). Schematic representation of the port configuration for robotic-assisted endometriosis surgery. The 'Δ'-sign denotes the minimum distance of approx. 10 cm that should be maintained between the ports (c).



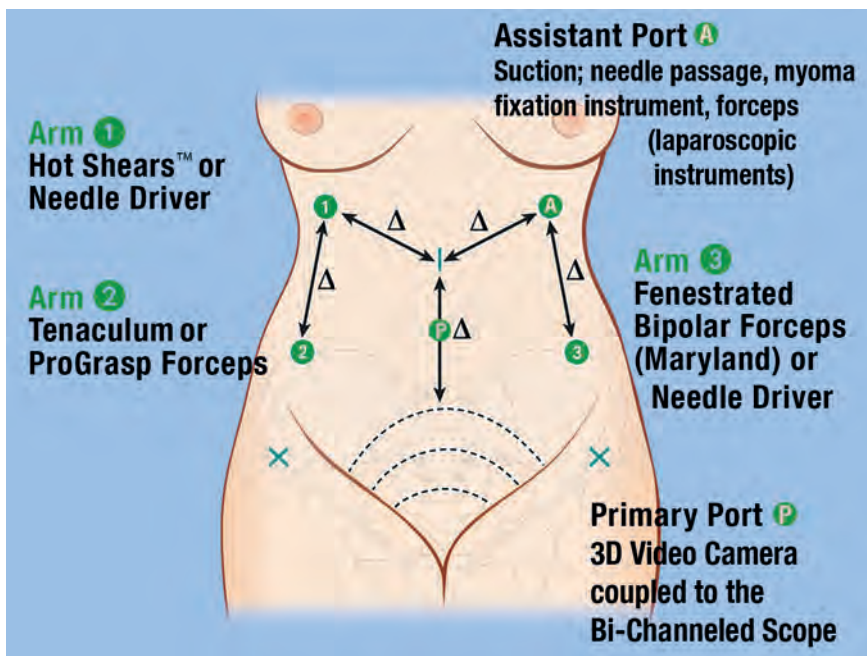
**4. Movement of Patient-Side Surgical Cart.** The patient-side surgical cart is then moved to the right side parallel to the operating table (Figs. 3.157a, b).

**5. Docking of Robotic Arms and Introduction of Instruments.** Once the robotic arms are positioned properly (Fig. 3.157c), the preselected instruments are mounted to the arms and docked to the ports. The authors prefer the bipolar forceps to be mounted to arm ③ and docked to the left lower port. The ProGrasp forceps is mounted to arm ② and docked to the left lower port. Hot Shears™ (monopolar curved scissors) are mounted to arm ① and docked to the right upper port (Fig. 3.158).

**6. Surgeon Console.** Upon completion of the preparatory steps, the surgeon takes a seated position at the console to exercise near-total control over the surgical field. Once proper docking of all robotic arms has been checked, the first step of the surgical procedure can be initiated (Fig. 3.153c).



**Figs. 3.157a–c** The patient-side surgical cart is placed on the right side of patient parallel to the operating table (a). Alignment of the mobile patient-side cart in parallel to the operating table, a configuration also named ‘parallel docking’ (b). The robotic arms are being docked onto the trocar ports. (c).

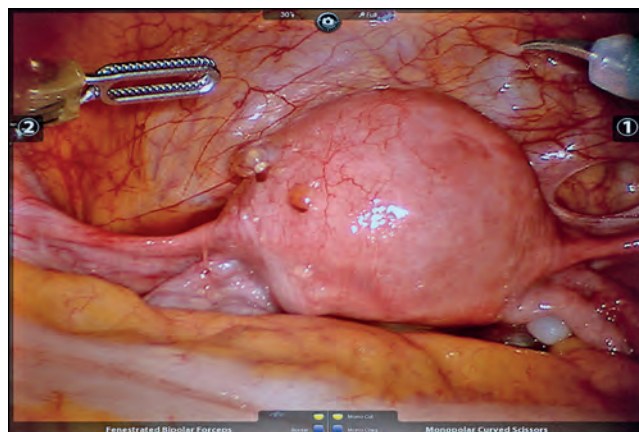


**Fig. 3.158** Schematic diagram showing the various instruments typically used through the ports in robotic-assisted endometriosis surgery.

### 3.10.4 The Role of Robotics in the Management of Endometriosis – A Game Changer in Three Application Fields

#### Major Application Fields of Robotic-Assisted Management of Endometriosis

- Visual inspection for diagnosis of endometriosis.
- Surgical treatment of advanced cases of both genital and extra-genital forms of endometriosis.
- Enhancement of surgical skills, particularly when preparing for the surgical management of severe forms of endometriosis, which can be challenging because of the inherently higher level of complexity.



**Fig. 3.159** Early endometriosis on uterine surface.

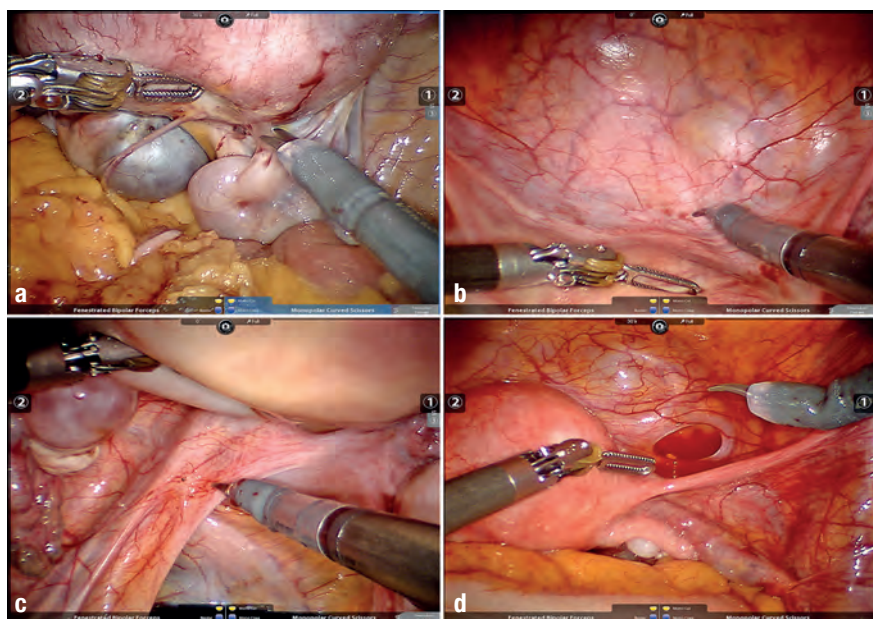
#### 3.10.4.1 Diagnosis of Endometriosis

Early manifestations of endometriotic lesions are amenable to visual detection only on the basis of detailed inspection of the pelvic cavity. Taking an intrapelvic stereoscopic view through the advanced 3D console with up to 10x magnification at HD quality allows to scrutinize all areas of interest and to appreciate even the faintest details which may serve as visual cues to suggest the presence of early lesions. The higher the image quality, the better the chances for the gynecologist to arrive at an accurate diagnosis on which surgical treatment in cases of endometriosis can be based.<sup>11</sup> The following are images of representative clinical cases subjected to robotic-assisted surgery. **Fig. 3.160a** shows an intrapelvic view in a patient who underwent robotic-assisted treatment of endometriosis. In a different clinical case, the presence of early endometriotic lesions was confirmed in the uterovesical fold (**Fig. 3.160b**) and uterosacral ligaments (**Fig. 3.160c**). The peritoneal defect demonstrated in (**Fig. 3.160d**) was detected in a patient with Allen Masters syndrome.

The chances of diagnosing the disease at an early stage are increased if the surgeon has adequate knowledge, experience and awareness about the clinical manifestations of early-stage

endometriosis which can be revealed by videoendoscopic exploration (**Fig. 3.159**). This is of major importance since imaging modalities like ultrasound or MR imaging are of limited value in the diagnosis of early-stage endometriosis, the latter being particularly relevant to adolescent patients. If the dual goal of early detection and appropriate treatment is met successfully, young women are among those who can benefit greatly from minimally invasive ablative surgery, both in terms of reduced trauma to ovarian tissue and enhanced quality of life.

The integrated use of FireFly™ imaging technology in a robotic platform has opened up new prospects to detect and surgically remove endometriotic lesions that cannot be visualized with standard white-light illumination. This is of particular importance, taking into account that full pain relief is not feasible without complete resection of endometriosis. Several authors have reported on their experience with the use of FireFly™ technology during robotic single-incision laparoscopy. When integrated in a robotic surgical system, FireFly™ technology is used for targeted excitation of fluorescence, a phenomenon that can be induced by exposure of a specific fluorochrome (indocyanine green, ICG) to near-infrared (NIR) light.



**Figs. 3.160a–d** Videoendoscopic pelvic view in a patient undergoing robotic-assisted treatment of endometriosis (**a**). Early diagnosis of endometriotic spots in the uterovesical fold (**b**). Puckered endometriotic lesion near the left uterosacral ligament (**c**). Peritoneal defect in a patient with Allen Masters syndrome (**d**).

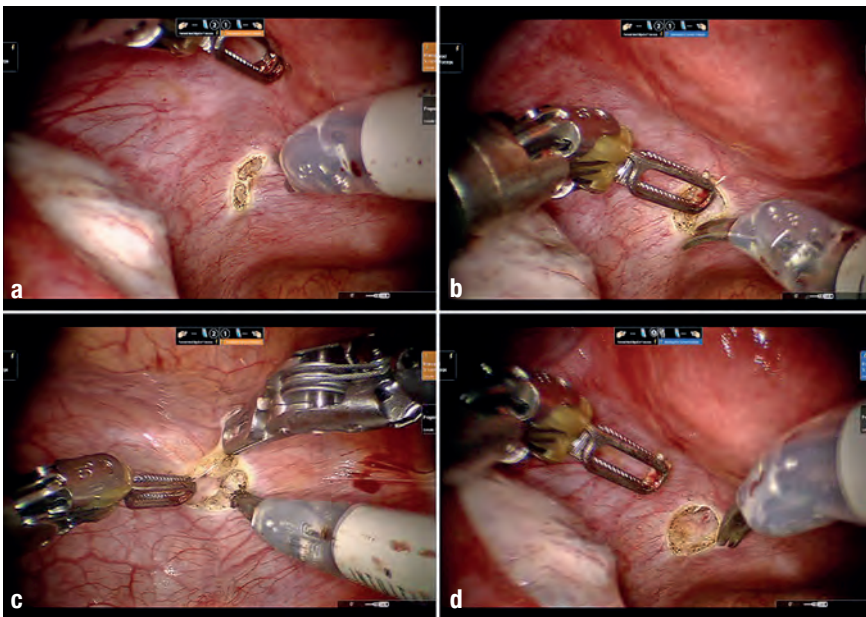


Indocyanine green is a medical-grade, water-soluble dye that binds to plasma proteins. After injection, the fluorescent property of the dye is used effectively to determine tissue perfusion and to enable visualization of the vasculature. Guan *et al.* (2016) stated that application of FireFly™ technology for NIR/ICG-induced fluorescence facilitates identification of endometriosis and allows to successfully perform single-site laparoscopic treatment of advanced-stage disease by resection of endometriotic nodules overlying the ureter and rectum. The authors reported on complete resolution of pelvic pain symptoms and excellent cosmetic results.<sup>5</sup> FireFly™ technology is currently used in many centers to treat endometriosis. Considering that areas of disease are characterized by increased neovascularization, NIR/ICG-induced fluorescence allows to readily detect endometriotic lesions which appear in dark green.<sup>12</sup> Frequently, the lesions are subtle in appearance and cannot be appreciated with the naked eye under standard white-light endoscopy. However, when exposed to near-infrared light using FireFly™ technology, targeted resection of the affected tissue allows to remove endometriosis to the maximum extent feasible. This promising novel technique could become a game changer in that it allows to identify small endometriotic lesions, that were previously missed, and enables complete excision, thus providing full pain relief.

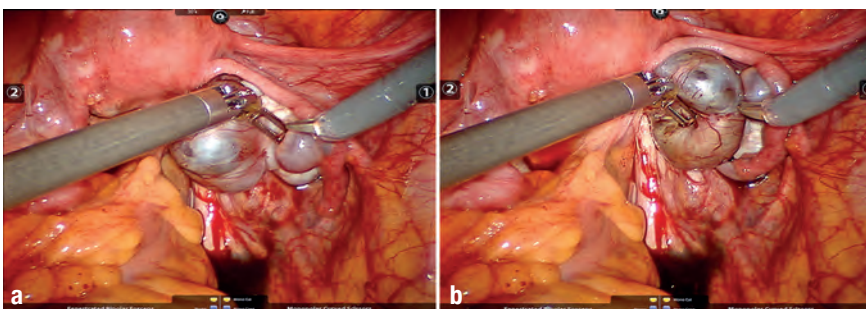
#### 3.10.4.2 Surgical Therapy of Endometriosis

It is well known that complete removal of all visible endometriotic implants is often not feasible by standard laparoscopic surgery. This holds true even more so for early-stage endometriotic lesions, where precise excision with standard laparoscopic instruments can be tricky at times, especially when close to the ureter and the bladder surface. These lesions may be either left alone or managed by minimal coagulation in the same operative session. Yet, with the help of multi-articulated small robotic instruments, endometriotic implants can be removed easily to prevent postoperative recurrence. Precise surgical removal also offers the opportunity to subject the sampled tissue specimens to histopathological examination for the purpose of definitive diagnosis. The following are images of a representative clinical case demonstrating step-by-step excision of an early-stage endometriotic implant by robotic-assisted surgery (Figs. 3.161a–d) with articulated harmonic shears and ProGrasp forceps.

Adherence of the ovary to the ovarian fossa has been identified as a source of chronic pelvic pain and dysmenorrhoea. Lysis of ovarian adhesions by application of traction is commonly achieved with the laparoscopic technique. The following images are taken from a representative clinical case, showing robotic-assisted lysis of ovarian adhesions using harmonic shears with unipolar current (Fig. 3.162a, b).



**Figs. 3.161a–d** Harmonic shears are used to delineate the boundary of the endometriotic implant (a). View of the endometriotic implant while it is being excised (b). Excision of the endometriotic implant is completed (c). View of the surgical defect upon excision of the endometriotic implant (d).



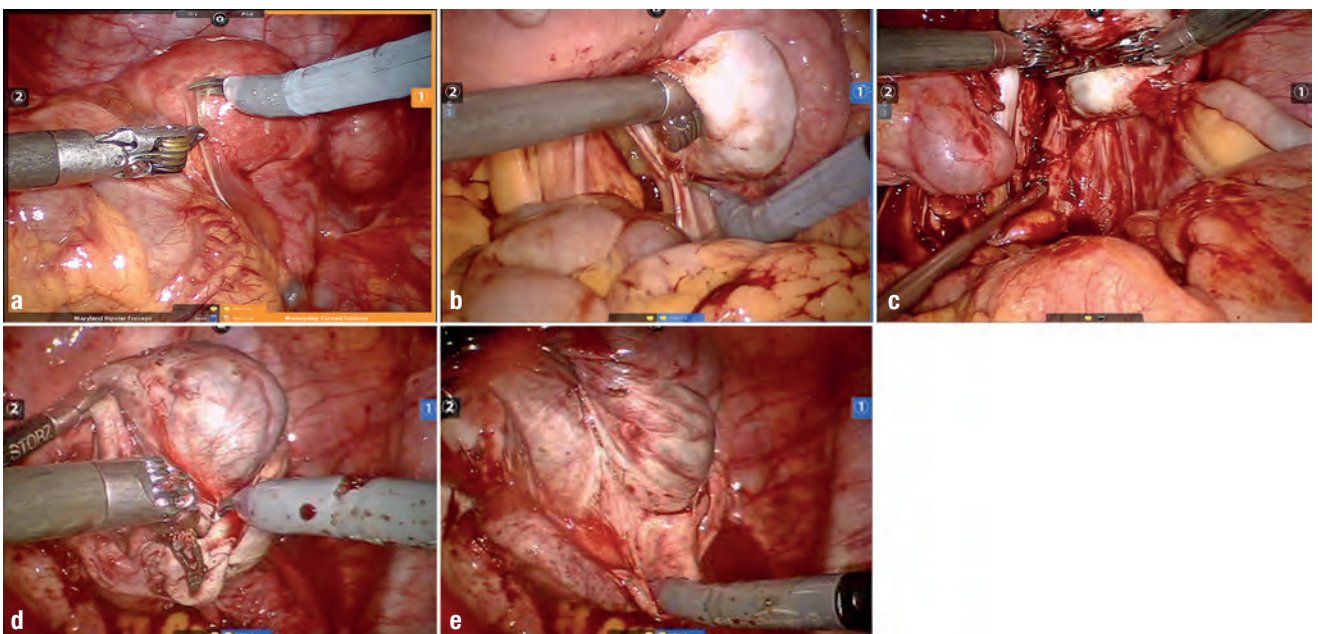
**Figs. 3.162a, b** Right ovary adherent to the ovarian fossa due to endometriosis (a). Lysis of endometriosis-related adhesions between the right ovary and the ovarian fossa using harmonic shears with unipolar current (b).



In cases where endometriomas have already developed, clinicians should rather opt to proceed with cystectomy instead of choosing drainage and coagulation, as cystectomy reduces endometriosis-associated pain.<sup>7</sup> Even though a standard laparoscopic approach is commonly advised for cyst excision in cases of endometriosis, the authors hold the opinion that the use of articulated robotic instruments allows this type of surgery to be performed more precisely. Apart from that, directing the instruments in the correct plane of dissection is achieved more easily under robotic assistance. The general method adopted in a laparoscopic approach is either by using a rolling technique or by applying traction and counter-traction. In robotic-assisted surgery, excision of the cyst wall proceeds in a stepwise fashion and requires that the fibers between the cyst and ovarian tissue be identified first. Subsequently, the cyst wall is removed by precise dissection following the principles of microsurgery which is in stark contrast to a forceful peeling of the tissues by traction and counter-traction commonly applied in laparoscopic technique. We believe that such precise dissection has two advantages. Firstly, adherence to microsurgical principles using delicate robotic instruments offers the benefit of less postoperative adhesions. *Gomel et al.* also emphasizes the value of a robotic platform in facilitating microsurgery for the purpose of reducing postoperative adhesion formation which is so essential to postoperative fertility outcomes.<sup>4</sup> Secondly, there is a chance that the loss of normal ovarian tissue is as minimal as possible, thus preserving the residual follicular reserve. However, this needs to be corroborated by trials comparing laparoscopic and robotic techniques in order to determine their effect on future fertility. The following are images of a representative clinical case demonstrating the various steps of ovarian cystectomy for endometrioma using robotic technology (Figs. 3.163a–e). Adhesion of sigmoid to lateral pelvic wall is a common finding in women with endometriosis.

Such adhesions are thought to be responsible for abdominal discomfort and bloating. Fig. 3.164a–c show dissection and detachment of the sigmoid from the lateral pelvic wall.

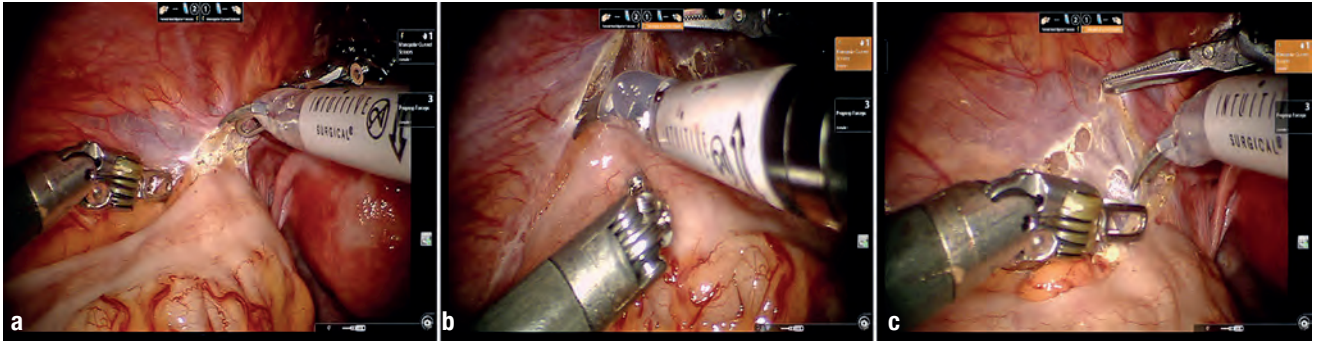
Surgical management of advanced stages (III and IV) of endometriosis poses a challenge to any surgeon. Complete removal of all endometriotic implants has direct correlation to improvement of symptoms and fertility outcome as well as to recurrence of disease. The results obtained from laparoscopic surgery, which is used by the majority of surgeons, leaves a lot to be desired. In women suffering from endometriosis, the goal of adequate surgical clearance – which is key to improving surgical outcomes – poses the major challenge today. The authors believe that it should be possible to achieve this in the years to come. Robotic surgery with all its advantages offers the potential of performing complex resections for the management of infiltrating forms of endometriosis including those affecting the rectovaginal septum, bladder and bowel. In studies that compare the robotic versus laparoscopic approach, no special differences were found, except those related to mean duration of surgery, which is longer in the robotic-assisted procedure. However, it is important to notice that no conversions are necessary, and the robotic approach may be more effective in cases of complex resections that are associated with a significant compromise of the affected organ.<sup>1,2</sup> The largest series published in the literature on robotic-assisted laparoscopy for deep infiltrating endometriosis concludes that this type of surgery seems to be promising in the treatment of deep infiltrating endometriosis, showing no increase in surgical time, blood loss, and intra- and postoperative complications.<sup>6</sup> The results of a prospective cohort study of 25 consecutive patients with deep infiltrating endometriosis (DIE) by *Pellegrino et al.* recommends the use of robotics as a safe and attractive alternative option for comprehensive surgical treatment of the disease. The authors



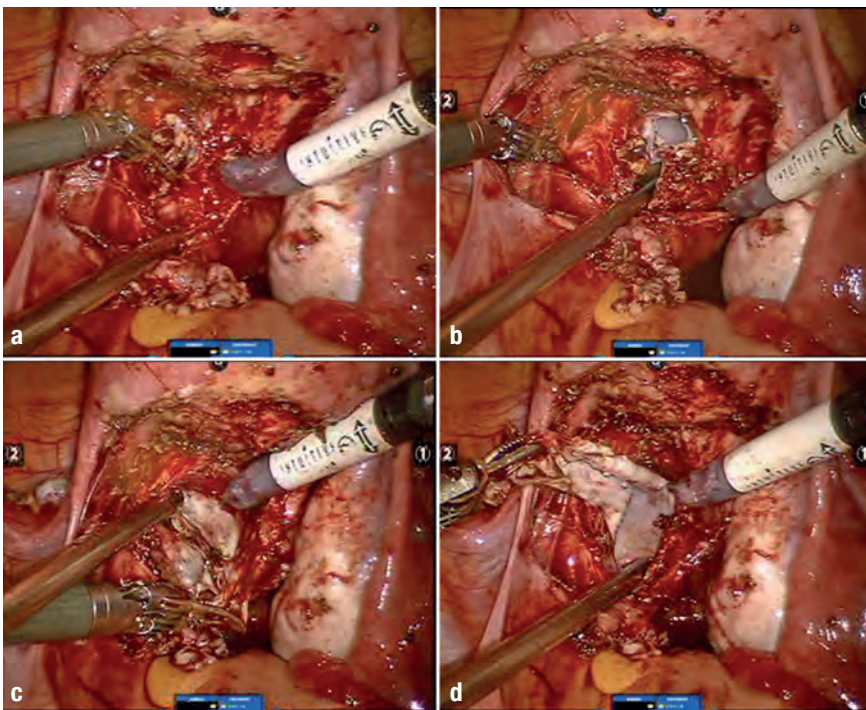
**Figs. 3.163a–e** Ovarian cystectomy begins with adhesiolysis and exposure of endometrioma (a). Ovarian cyst being lifted up from the ovarian fossa with the aid of articulated scissors and forceps (b). Endometrioma is free from adhesion to the ovarian fossa and anatomy is exposed further (c). Ovarian cystectomy is continued with precise dissection of fibers between the cyst wall and the normal ovarian tissue (d). Ovarian cystectomy is almost complete exposing the cyst base from the ovarian pedicle.

reported on the successful removal of endometriotic nodules from the rectovaginal septum using rectal shaving alone or in combination with accessory procedures in stage-IV disease and confirmed the same on histopathology. This series has a median long-term follow up of 22 months with an optimal operative time, demonstrating good long-term outcomes.<sup>13</sup> However, one must remember that surgery for DIE – even with robotic-assisted laparoscopy – is commonly associated with a significant morbidity rate, which is why a team approach with a colorectal surgeon is highly advised. Robotic surgery

for endometriosis was found to be successful in stage-IV endometriosis without conversion to laparotomy and in many scientific reports, the conversion rate was reported to be approximately 10%. The use of robotic-assisted technology in the management of endometriosis should be reserved to more severe cases such as those involving segmental bladder, bowel and ureteral resection.<sup>8</sup> The following images (Figs. 3.165a–d) are taken from a representative clinical case showing dissection of an endometriotic cyst in the rectovaginal septum.



**Figs. 3.164a–c** Robotic-assisted dissection and detachment of the sigmoid from the lateral pelvic wall.



**Figs. 3.165a–d** After clearing the obliterated pouch of Douglas, the endometrioma is exposed in the rectovaginal septum (a). The endometriotic cyst is opened and drained (b). The wall of the endometriotic cyst is identified and excision continues (c). Complete excision of the endometriosis cyst wall in the rectovaginal septum (d).

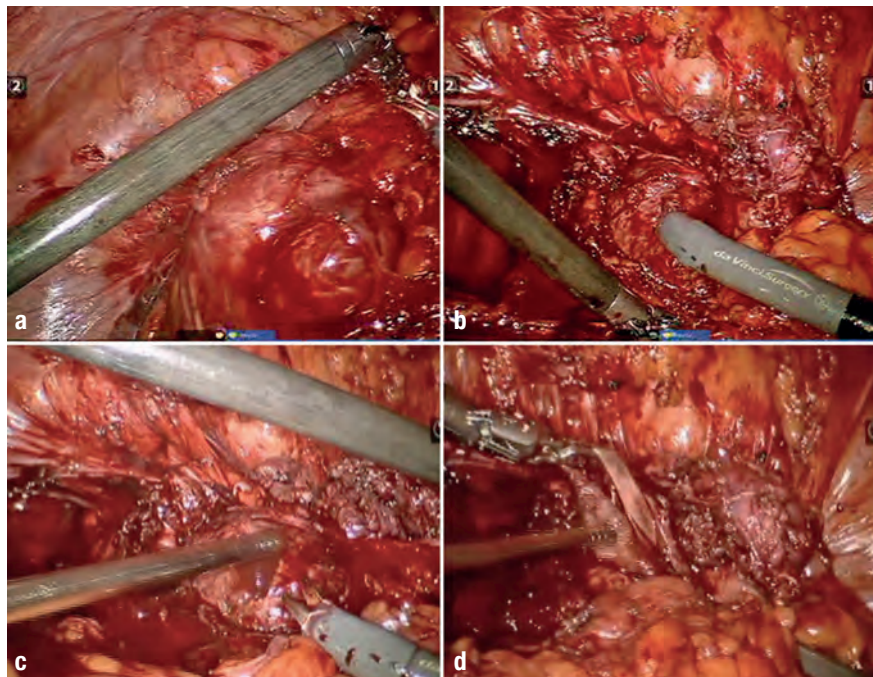


The recurrence rate reported in the literature for advanced stages of endometriosis where ovaries are preserved during hysterectomy is as high as approximately 60% with patients having a 6-fold risk of recurrent pain and an 8-fold risk of repeat surgery. This is directly correlated to the surgical precision and removal of peritoneal and deeply infiltrating disease accomplished by primary surgery. Authors feel that robotic-assisted hysterectomy is particularly useful to prevent residual disease in patients diagnosed with endometriosis stage III or IV. They also reported on their experience with managing post-hysterectomy recurrence of endometrioma. The need for conversion to laparotomy was minimal. The following is a case of complete excision of a post-hysterectomy endometrioma measuring 6 cm in size, and complete resolution of symptoms confirmed at 6-month follow-up examination (Figs. 3.166a–d).

#### 3.10.4.3 Enhancement of Surgeon's Proficiency in Complex Endometriosis Surgery

The most significant advantage that can be derived from the use of a robotic surgical system as compared to a standard laparoscopic approach is a shorter learning curve. The simulation modules integrated in the console of the *da Vinci Surgical System* can help younger surgeons to hone their skills before starting surgery on patients. Even amongst the most skilled laparoscopic surgeons, there is growing consensus that ease of instrument manipulation is a distinct feature of robotic assistance which makes it most suitable for use in endometriosis surgery and restoration of pelvic anatomy to provide fertility-enhancing therapy in advanced stages of disease. The 3D console offers improved spectral depth perception of pelvic structures, which is of tremendous advantage in dissecting along tissue planes during endometriosis surgery. Because of the intuitive hand control and articulating instruments, surgeons can mimic

the familiar movements commonly applied in open surgery. Owing to their greater range of motion with seven degrees of freedom, robotic instruments can be controlled similarly to the human wrist, which is in stark contrast to 'straight-stick' laparoscopy.<sup>10</sup> Moreover, the surgeon can assume a comfortable seated position throughout the procedure, which aids in reducing fatigue, especially during long operations, and should therefore be regarded as a distinct feature that enhances the surgeon's ability to perform better. The *da Vinci Surgical System* allows for telestration. This feature is helpful in that it enables the instructing surgeon to write on a touch screen with a finger or an electronic pen. Written instructions can be seen by both the surgeon at the console and the other members of the operating room staff. When it comes to supervising a surgical step and guiding dissection through difficult planes the instructing surgeon can give clues on when and how a specific robotic instrument should be used. The instructing surgeon can also assist with suturing and knot tying or can help to identify any vital structures that should be avoided. The TilePro™ multi-input display of the *da Vinci Si HD System* (Intuitive Surgical, Inc., Sunnyvale, CA) is an extended feature that allows two additional video sources to be superimposed on the console during surgery, (e.g., radiologic data, ultrasonography, computed tomography, or magnetic resonance imaging), which can be very helpful in the early phase of the learning curve. In the authors' point of view, it is of no doubt that the use of a computer-assisted robotic platform will enable more surgeons to perform complex gynecological procedures and convert open procedures to minimally invasive surgery in the years to come. The ability of the robotic platform to filter and reduce physiologic tremor and to transform a surgeon's hand movements into more precise micro-movements can be a game changer in fertility-enhancing surgeries, especially in the treatment of endometriosis and fibroid uterus.



**Figs. 3.166a–d** Excision of post-hysterectomy endometrioma at the vaginal vault (a–d). Dissection at the vaginal vault and exposure of the cyst (a). Dissection is carried along the anterior bladder and posterior sigmoid until reaching the endometriotic cyst at the vaginal vault (b). Once the cyst is exposed, its content is drained to identify the cyst wall which is then separated from bladder and bowel (c). The cyst wall is identified and excised completely (d).



### 3.10.5 Conclusion

Since the introduction of computer-enhanced technology (robotics) to gynecological surgery in 2005, attention has been focused on its advantages and disadvantages. Most centers using this technology believe that it enables more surgeons to convert laparotomies to minimally invasive surgeries. Thus, the utility of robotic platform lies in the management of severe cases of endometriosis and opens up the chance to further reduce the number of laparotomies. In the coming years, this technology will find its place in the clinical practice of minimally invasive gynecology, as a complementary means to the current standard of laparoscopic surgery. However, we need to critically examine the long-term benefits especially in benign conditions. As more surgeons are trained and utilize this enabling technology, one thing is certain; as the number of minimally invasive surgeries for endometriosis will increase, the incidence rate of open surgery procedures in gynecology is expected to decline. Addressing the cost of equipment and surgeon credentialing in the future stands a good chance of making this technology more widely accepted among surgeons and patients alike.

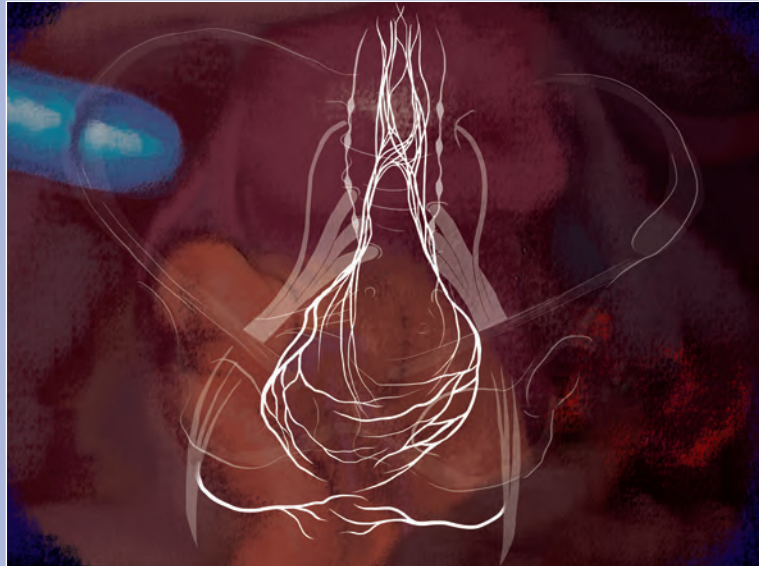
### 3.10.6 References

1. ADVANCING MINIMALLY INVASIVE GYNECOLOGY WORLDWIDE (AAGL). Position Statement: Robotic-Assisted Laparoscopic Surgery in Benign Gynecology. *Journal of minimally invasive gynecology* 2013;20(1):2–9. doi:10.1016/j.jmig.2012.12.007.
2. AYALA YANEZ R, OLAYA GUZMAN EJ, HAGHENBECK ALTAMIRANO FJ. [Robotics in gynecology. Background, feasibility and applicability]. *Ginecologia y obstetricia de Mexico* 2012;80(6):409–16.
3. BULUN SE. Endometriosis. *The New England journal of medicine* 2009;360(3):268–79. doi:10.1056/NEJMra0804690.
4. GOMEL V. The impact of microsurgery in gynecology. *Clinical obstetrics and gynecology* 1980;23(4):1301–10.
5. GUAN X, NGUYEN MT, WALSH TM, KELLY B. Robotic Single-Site Endometriosis Resection Using Firefly Technology. *Journal of minimally invasive gynecology* 2016;23(1):10–1. doi:10.1016/j.jmig.2015.08.001.
6. HANSSSENS S, NISOLLE M, LEGUEVAQUE P, NEME RM, CELA V, BARTON-SMITH P et al. [Robotic-assisted laparoscopy for deep infiltrating endometriosis: the Register of the Society of European Robotic Gynaecological Surgery]. *Gynecologie, obstetrique & fertilité* 2014;42(11):744–8. doi:10.1016/j.gyobfe.2014.09.005.
7. HART RJ, HICKEY M, MAOURIS P, BUCKETT W. Excisional surgery versus ablative surgery for ovarian endometriomata. *The Cochrane database of systematic reviews* 2008(2):Cd004992. doi:10.1002/14651858.CD004992.pub3.
8. LIU C, PERISIC D, SAMADI D, NEZHAT F. Robotic-assisted laparoscopic partial bladder resection for the treatment of infiltrating endometriosis. *Journal of minimally invasive gynecology* 2008;15(6):745–8. doi:10.1016/j.jmig.2008.07.002.
9. NEZHAT C, CROWGEY SR, GARRISON CP. Surgical treatment of endometriosis via laser laparoscopy. *Fertility and sterility* 1986;45(6):778–83.
10. NEZHAT C, LAVIE O, LEMYRE M, UNAL E, NEZHAT CH, NEZHAT F. Robot-assisted laparoscopic surgery in gynecology: scientific dream or reality? *Fertility and sterility* 2009;91(6):2620–2. doi:10.1016/j.fertnstert.2008.03.070.
11. NEZHAT C, NEZHAT F, NEZHAT C. Operative laparoscopy (minimally invasive surgery): state of the art. *Journal of gynecologic surgery* 1992;8(3):111–41.
12. NEZHAT FR, SIROTA I. Perioperative outcomes of robotic assisted laparoscopic surgery versus conventional laparoscopy surgery for advanced-stage endometriosis. *JSLs Journal of the Society of Laparoendoscopic Surgeons/Society of Laparoendoscopic Surgeons* 2014;18(4). doi:10.4293/jsls.2014.00094.
13. PELLEGRINO A, DAMIANI GR, TRIO C, FACCIOLI P, CROCE P, TAGLIABUE F et al. Robotic Shaving Technique in 25 Patients Affected by Deep Infiltrating Endometriosis of the Rectovaginal Space. *Journal of minimally invasive gynecology* 2015;22(7):1287–92. doi:10.1016/j.jmig.2015.06.002.
14. SINHA R, SANJAY M, RUPA B, KUMARI S. Robotic surgery in gynecology. *Journal of minimal access surgery* 2015;11(1):50–9. doi:10.4103/0972-9941.147690.
15. The National Women's Health Information Council. Understanding Endometriosis: Past, Present and Future. Available from: <http://www.4woman.gov/HealthPro/healtharticle/march.htm>.



# 4

## Special Conditions



4.1	The Management of Endometriosis in Infertility . . . . .	298
4.2	Endometriosis and Pain . . . . .	303
4.3	Laparoscopic Surgery for Treatment of Endometriosis-Associated Pelvic Pain Including the Role of Presacral Neurectomy . . . . .	312
4.4	Postoperative Management of Endometriosis . . . . .	317
4.5	Nerve-Sparing Surgery in Endometriosis . . . . .	324
4.6	Neuropelveology . . . . .	332
4.7	Recurrent Endometriosis . . . . .	346
4.8	Definitive Surgery for Endometriosis after Completion of Family Planning .	351
4.9	Robotic Assistance for Deep Infiltrating Endometriosis Surgery . . . . .	360
4.10	Endometriosis-Associated Malignant Neoplasms . . . . .	367
4.11	Controversies in Surgical Treatment of Adenomyosis . . . . .	374



## 4.1

## The Management of Endometriosis in Infertility

Carlos Alberto Petta<sup>a</sup> | Alessandra Peloggia<sup>b</sup>

## 4.1.1 Introduction

Infertility affects approximately 10–15% of the population of reproductive age and is considered an issue of substantial socioeconomic magnitude. Since the 1950s, sociodemographic studies have reported a reduction in birthrates in Europe irrespective of region or social class. In developed countries, approximately 15% of the population is infertile, and this proportion is even higher in less developed countries where infertility affects around 9–30% of couples,<sup>22, 23</sup> (see Fig. 4.1).

Between 25% and 50% of infertile women have endometriosis and 30–50% of women with endometriosis are infertile. In fertile couples, fertility rates are around 0.15 to 0.20 per month and decrease with age. In infertile women with untreated endometriosis, the fertility rate decreases substantially to values as low as approx. 0.02 to 0.10.<sup>19</sup>

Since fertility rates vary considerably according to variables such as age and duration of infertility, it is difficult to quantify the true prevalence of endometriosis in infertile women. The prevalence of endometriosis is high, approximately 48%, in women with infertility compared to 5% in women submitted to

tubal ligation.<sup>33</sup> The hypothesis that all stages of endometriosis cause infertility or a decrease in fertility still requires further reflection and more comprehensive studies. Based on the core assumption that endometriosis is indeed a major cause of infertility, it would be permissible to conclude that eradicating the disease should improve fertility rates; however, data in the literature have failed to confirm this hypothesis.

In this context, among the unresolved major issues of today is the question on how to manage the treatment of endometriosis in infertile patients, principally with respect to defining the right point in time at which it may be indicated – or not – to perform a surgical procedure or assisted reproductive technique. In this chapter, we will discuss the various treatment options currently available and presented in the literature for cases of endometriosis and infertility. This literature review was conducted using the PubMed/MEDLINE database to search for articles published in English, using the following keywords: *endometriosis, infertility, surgical treatment, surgery, clinical treatment, IVF and ICSI*. The articles were selected based on their methodology, relevance and clinical applicability.

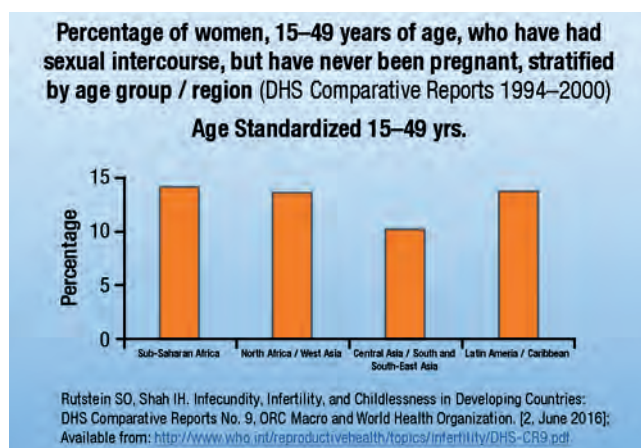
## 4.1.2 Clinical Treatment of Infertility in Patients with Endometriosis

Even though the effectiveness of pharmacological treatment for the relief of endometriosis-associated pain has been well established, there is no conclusive evidence of positive results when the issue is infertility. On the contrary, fertility is essentially eliminated during therapy, since all drugs used for treating endometriosis inhibit ovulation.

Various randomized studies have shown that drugs such as progestogens or GnRH analogs are ineffective in treating infertility associated with mild or minimal endometriosis.<sup>13</sup> In one randomized study involving 71 infertile women with mild or minimal endometriosis, the cumulative pregnancy rates were similar in the group of women who received GnRH analogs for 6 months when compared with the control group submitted to expectant management.<sup>9</sup> Likewise, pregnancy rates were similar in a study based on 37 infertile women with mild or minimal endometriosis who were treated with progestogens or by expectant management.<sup>28</sup>

The use of pharmacological therapy prior to or following surgery has resulted in no benefits insofar as fertility is concerned. In patients with more extensive endometriosis, medical therapy following surgery may be an important means of eradicating residual endometriotic implants, however, it is not a suitable option for improving fertility outcome.

There is insufficient evidence that any benefit accrues from pharmacological treatment, which also applies to the administration of analogs prior to intrauterine insemination procedures.<sup>15</sup> In addition, data in the literature are inappropriate to warrant recommending the use of oral contraceptives prior



**Fig. 4.1** Percentage of women aged between 15–49 yrs., who have had sexual intercourse, but have never been pregnant, stratified by age group / region.

<sup>a</sup> | MD PhD; Fertility and Assisted Reproduction Center, Campinas, SP, Brazil; Sirio Libanês Hospital, São Paulo, SP, Brazil

<sup>b</sup> | MD PhD; Fertility and Assisted Reproduction Center, Campinas, SP, Brazil; Sirio Libanês Hospital, São Paulo, SP, Brazil

**Corresponding author:**

Dr. Carlos Alberto Petta

Rua Joaquim Floriano, 533

12<sup>o</sup> andar

CEP 04534-011, Itaim Bibi, São Paulo/SP

República Federativa do Brasil

E-mail: contato@drpetta.med.br

to assisted fertilization. On the other hand, the use of GnRH analogs has been found to be effective in improving the likelihood of success when used for 3–6 months prior to in vitro fertilization.<sup>35</sup> Nevertheless, there is always a concern when inhibiting ovulation for prolonged periods of time in women with endometriosis, since in many cases their ovarian reserve is already reduced and prolonged ovulation inhibition may diminish response in terms of oocyte quantity. With the advances and improvements achieved in the techniques used to freeze embryos and gametes, one option would be to transfer frozen embryos from a cycle during which ovulation was not inhibited and then inhibit ovulation in the cycles following follicular aspiration.

### 4.1.3 Surgical Treatment of Infertility in Patients with Endometriosis

The principles adopted with respect to laparoscopic surgery for infertility are similar to those applied in the surgical treatment of other endometriosis-related symptoms. If diagnosis has been made in compliance with principles of good clinical practice, and given that the surgical team has been adequately trained, then surgery becomes a possible means of achieving optimal results.

Prior to the decision-making on whether there is an indication for surgical treatment, the ovarian reserve of infertile women is assessed by measuring anti-Müllerian hormone levels. This evaluation constitutes a relevant step, principally in view of the increasing evidence that surgical treatment of endometriomas may contribute to a decline of ovarian reserve.<sup>24</sup>

#### 4.1.3.1 Surgical Treatment for Peritoneal Disease (ASRM stage I/II)

A Cochrane review revealed laparoscopic surgery to be more effective in improving pregnancy rates than simple diagnostic laparoscopy, with laparoscopic ablation of endometriotic implants being associated with a slight but significant improvement in fertility rates.<sup>14</sup>

Two randomized trials evaluated the efficacy of laparoscopic surgery when used in initial stages of endometriosis-related infertility. In the first one, a Canadian study, conception occurred in 36.6% of women treated with laparoscopic ablation or resection, as compared to 21.9% of patients of the control group, who were submitted to diagnostic laparoscopy alone.<sup>17</sup> In the second study, conducted in Italy, pregnancy occurred in 19.6% of the treated women and in 22.2% of the untreated women.<sup>21</sup>

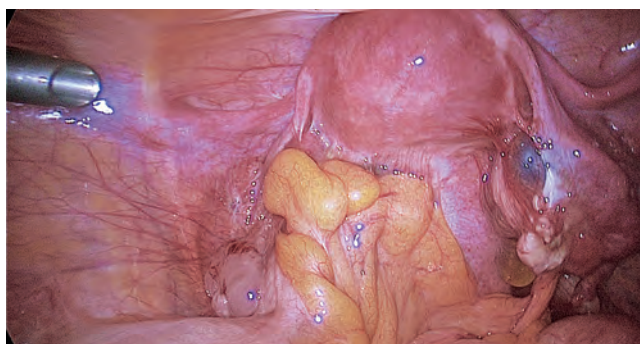

Fig. 4.2 Peritoneal disease.

When combining the data obtained from the two studies above, no statistically significant difference is found between the two groups, with a total absolute difference of 8.6% in favor of treating endometrial lesions. In terms of statistics, the minimum number of patients that must be treated to meet the therapeutic goal in one patient is 12. In other words, this means that pregnancy will occur in 1 out of 12 patients with a laparoscopically confirmed diagnosis of incipient endometriosis, who were treated by ablation or resection rather than expectant management with laparoscopic diagnosis alone.

#### 4.1.3.2 Surgical Treatment for Ovarian Disease

Ovarian endometriomas are among the most severe forms of endometriosis. Commonly, they do not respond satisfactorily to medical treatment,<sup>16</sup> which indeed is capable of improving endometriosis-related pain and reducing the size of cysts, whereas no therapeutic benefit has been demonstrated with regard to the treatment of infertility.<sup>10</sup> The risks of surgery and the associated potential damage to ovarian function need to be thoroughly examined, principally prior to initiating assisted fertilization procedures.

Treatment options include cystectomy and ovarian vaporization/coagulation. For the purpose of improving fertility in the presence of cysts of more than 4 cm in diameter, laparoscopic cystectomy offers better results than drainage and coagulation, which is associated with higher recurrence rates.<sup>4,12</sup> According to *Brosens et al.*, the accompanying intense inflammatory process demands that ectopic endometrial tissue be removed as soon as it is diagnosed, irrespective of the size of the lesion. The group of *Brosens* developed a technique referred to as *transvaginal hydrolaparoscopy*, which permits not only diagnosis of the endometrioma at initial stages but also its ablation.<sup>3</sup>

Therefore, if conservative surgery is indicated, patients must be informed that excision of the endometrioma capsule incurs a notable risk of reduced ovarian function and may even result

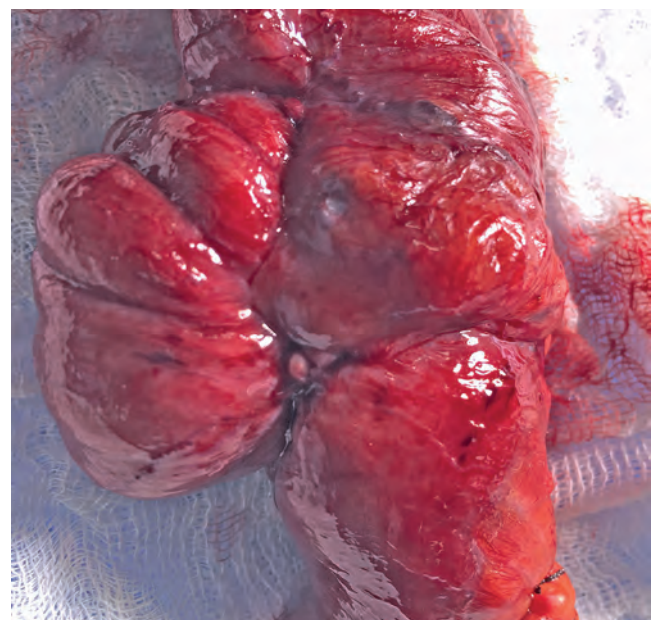


Fig. 4.3 Ovarian endometrioma.



in loss of the ovary. In patients with a medical history of ovarian surgery, the need to adopt a second-look procedure should be determined with caution.<sup>7</sup> Freezing gametes/embryos prior to surgery should be discussed with the patient whenever the presence of endometriomas is considered an indication for surgical removal.

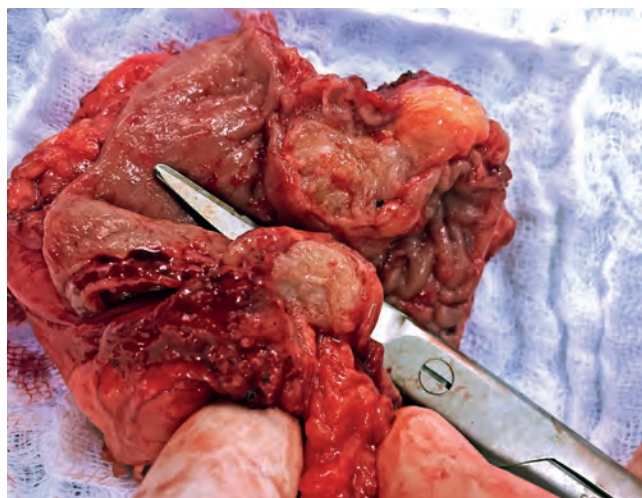
#### 4.1.3.3 Surgical Treatment for Deep Infiltrating Lesions

The impact of surgery on fertility in cases of deep endometriosis is the subject of ongoing controversy in the literature. *Vercellini et al.* evaluated 150 infertile women with rectovaginal endometriosis and no other coexisting infertility factors, who had been presented with the option of choosing between expectant management and surgical treatment. After two years of follow-up, no statistically significant differences were observed between both groups, with a pregnancy rate of 36% in the expectant management group versus 34% in the surgical treatment group.<sup>31</sup>

These results contrast with the findings of other studies in the literature, which have emphasized that the principal reason constituting an indication for surgical treatment in cases of deep endometriosis would be the conclusive and statistically significant evidence of successful outcomes in terms of pregnancy rates.<sup>25</sup> According to three systematic reviews, the pregnancy rates of around 42–44% following surgical treatment were considered satisfactory.<sup>18,32,34</sup> Nevertheless, according to an evaluation made by *Vercellini et al.*, the benefits of surgery are over-estimated and therefore, successful pregnancy rates cannot be attributed to surgical treatment alone.<sup>18</sup>

When opting for surgical treatment, there is still no consensus on which of the current techniques is the best, because studies have indicated good pregnancy rates in patients treated with laparoscopic colorectal resection as well as in those subjected to discoid resection. Up to the present time, these surgical techniques have yet to be evaluated in randomized studies, principally due to the fact that they are associated with high complication rates.<sup>6,30</sup>

The major objective of surgery in the treatment of deep infiltrating endometriosis is to restore the anatomy and improve the likelihood of spontaneous pregnancy. However, prior to



**Fig. 4.4** Deep infiltrating endometriosis.

suggesting an indication for surgical treatment, it is imperative to conduct a thorough diagnostic workup that yields the full clinical image of a patient's infertility status, which must include an adequate evaluation of ovarian reserve as well as a comprehensive assessment of potentially contributing male factors. Following surgical treatment, a period of six months should be allowed to pass before attempting conception. If pregnancy does not occur during this period, in vitro fertilization is then recommended.<sup>26</sup>

#### 4.1.3.4 Combined Use of Pharmaceutical and Surgical Treatment

Even though from a theoretical point of view this combination should be a promising option, there is no evidence in the literature in support of improved pregnancy rates, which is why this strategy cannot be recommended. The use of pharmaceutical medication following surgery is believed to delay pregnancy at the very moment when the likelihood of fertility is higher as a result of the surgical procedure.<sup>7,22</sup>

#### 4.1.3.5 Ovulation Induction and Intrauterine Insemination

There is evidence of favorable results with ovarian induction alone or in conjunction with intrauterine insemination in women with incipient stages (stage I/II) of endometriosis, particularly if they were diagnosed surgically and provided there are no signs of distorted pelvic anatomy.<sup>22</sup>

A randomized study showed more favorable results employing a combined therapeutic regimen of ovulation induction with four cycles of clomiphene citrate and intrauterine insemination compared to four cycles of programmed coitus alone.<sup>5</sup>

In a randomized clinical trial conducted in 1997, *Tummon et al.* reported a 5.6 times higher live birth rate in women with stage I/II endometriosis, who were subjected to ovulation induction with gonadotropins followed by intrauterine insemination compared to a control group treated by expectant management.<sup>29</sup> The adjunctive use of ovulation induction with gonadotropins followed by intrauterine insemination yielded higher pregnancy rates than those observed after intrauterine insemination alone.<sup>20</sup> Unfortunately, more recent studies on this topic are not available in the current literature.

#### 4.1.3.6 Assisted Reproductive Technology (ART)

Among the armamentarium of ART modalities, in vitro fertilization (IVF) is considered the most effective treatment option for women with endometriosis-related infertility. While endometriosis is known to adversely affect the outcomes of ART, IVF appears to improve fertility rates in women with endometriosis. This holds particularly true in cases where pelvic anatomy has been distorted as a sequela of more severe forms of disease. The rationale underlying the surgical resection of peritoneal endometriosis is to minimize any adverse effects that peritoneal implants and their secretion products can have on the quality of the oocyte, embryogenesis, and implantation.<sup>27</sup> At present, there is major doubt whether any benefit is derived from performing surgery prior to in vitro fertilization. In a prospective study conducted in 2009, women with deep endometriosis were given the option of choosing between IVF alone or laparoscopic excision of the lesions followed by IVF.



At the end of the study, a significantly lower pregnancy rate (24 %) was found in the 'IVF-alone group' compared to the 'excision-prior-to-IVF' group (44 %).<sup>2</sup> To date, this study is the only evidence providing support of the possible benefits that are derived from surgical treatment prior to in vitro fertilization. Apart from that, the study also reflects the impaired prognosis a patient suffering from deep infiltrating endometriosis can be faced with when attempting assisted reproduction treatment.<sup>25</sup>

The impact of ovarian endometriomas on the outcomes of assisted reproduction techniques remains controversial. The inherent risks of surgery and its potential harm to ovarian reserve should be weighed against the associated complications that may arise from a persisting endometrioma in the course of assisted reproductive technology procedures.<sup>11</sup>

In fact, the only indication for removing endometriomas of more than 3 cm in diameter prior to IVF would be pain relief or improved ovarian access.<sup>8</sup> Nevertheless, *Benaglia et al.* reported a 53 % lower response to gonadotropins in patients whose ovaries had been submitted to surgery, irrespective of the size of the cysts, with an absence of follicular development in 13 % of cases following excision of unilateral endometriomas.<sup>1</sup>

In a recent systematic review and meta-analysis in which live birth rates, pregnancy rates and miscarriage rates were evaluated, results were similar in women with non-operated endometriomas and in those without endometriomas. However, in endometrioma patients, fewer oocytes were captured and high doses of FSH were required for ovarian stimulation. Apart from that, endometrioma patients had a three-fold greater likelihood of experiencing an abrupt cessation of menstrual cycle as compared to women without the disease.<sup>2</sup>

Among the possible benefits of prior surgical treatment are prevention of rupture of large endometriomas, facilitated oocyte capture, no contamination of follicular fluid with the contents of the endometrioma and cessation of disease progression. Nevertheless, the inherent drawbacks of surgery include surgical trauma, intra- and postoperative complications such as bleeding and infection, and the potential of impaired ovarian response.<sup>11</sup>

#### 4.1.4 Key Points in the Treatment of Infertile Women with Endometriosis

When establishing a therapeutic strategy, a variety of factors need to be taken into account, which are the patient's age, the duration of infertility, symptomatology and endometriosis staging.

There is a natural decrease in fertility after 35 years of age, and the endometriosis-related decline of a woman's fecundability in association with advanced age decreases the probability of conception even more. In women under 35 years of age with mild/minimal endometriosis, the benefits of surgery are insufficient and expectant treatment, or ovulation induction/uterine insemination, is considered as first-line therapy. In women over 35 years of age, more aggressive treatment

is required that includes ovulation induction/intrauterine insemination or in vitro fertilization. Such a candidate should be informed in advance that in vitro fertilization in her case has a reduced probability of success as compared to that of a woman receiving the same type of treatment but for another indication such as, for example, tubal factor infertility.

There is no evidence that removing endometriomas from asymptomatic women scheduled for in vitro fertilization or intracytoplasmic sperm injection (ICSI) will increase success rates with these procedures. Patients should be counseled on the increased risk of the cycle having to be cancelled and, most importantly, since there is still no consensus on this issue, treatment should be individualized.

Finally, it is generally known that infertility is a condition mediated by both male and female factors and that it is not only related to endometriosis. A complete diagnostic workup of both the ovarian reserve and the male factor is needed to determine whether there is in fact an indication for surgical treatment. This should allow the gynecologist to assess the reproductive prognosis of a couple with greater assurance.

#### 4.1.5 References

1. BENAGLIA L, SOMIGLIANA E, VIGHI V, RAGNI G, VERCELLINI P, FEDELE L. Rate of severe ovarian damage following surgery for endometriomas. *Hum Reprod* 2010;25(3):678–82. doi:10.1093/humrep/dep464.
2. BIANCHI PH, PEREIRA RM, ZANATTA A, ALEGRETTI JR, MOTTA EL, SERAFINI PC. Extensive excision of deep infiltrative endometriosis before in vitro fertilization significantly improves pregnancy rates. *J Minim Invasive Gynecol* 2009;16(2):174–80. doi:10.1016/j.jmig.2008.12.009.
3. BROSENS I, GORDTS S, PUTTEMANS P, BENAGIANO G. Pathophysiology proposed as the basis for modern management of the ovarian endometrioma. *Reprod Biomed Online* 2014;28(2):232–8. doi:10.1016/j.rbmo.2013.09.024.
4. CHAPRON C, VERCELLINI P, BARAKAT H, VIEIRA M, DUBUISSON JB. Management of ovarian endometriomas. *Hum Reprod Update* 2002;8(6):591–7.
5. DEATON JL, GIBSON M, BLACKMER KM, NAKAJIMA ST, BADGER GJ, BRUMSTED JR. A randomized, controlled trial of clomiphene citrate and intrauterine insemination in couples with unexplained infertility or surgically corrected endometriosis. *Fertil Steril* 1990;54(6):1083–8.
6. DONNEZ J, SQUIFFLET J. Complications, pregnancy and recurrence in a prospective series of 500 patients operated on by the shaving technique for deep rectovaginal endometriotic nodules. *Hum Reprod* 2010;25(8):1949–58. doi:10.1093/humrep/deq135.
7. DUNSELMAN GA, VERMEULEN N, BECKER C, CALHAZ-JORGE C, D'HOOOGHE T, BIE B DE et al. ESHRE guideline: management of women with endometriosis. *Hum Reprod* 2014;29(3):400–12. doi:10.1093/humrep/det457.
8. ELTER K, ORAL E. Surgical treatment before assisted reproductive technologies. *Semin Reprod Med* 2014;32(4):253–61. doi:10.1055/s-0034-1375177.

9. FEDELE L, PARAZZINI F, RADICI E, BOCCIOLONE L, BIANCHI S, BIANCHI C et al. Buserelin acetate versus expectant management in the treatment of infertility associated with minimal or mild endometriosis: a randomized clinical trial. *Am J Obstet Gynecol* 1992;166(5):1345–50.
10. GARCIA-VELASCO JA, SOMIGLIANA E. Management of endometriomas in women requiring IVF: to touch or not to touch. *Hum Reprod* 2009;24(3):496–501. doi:10.1093/humrep/den398.
11. HAMDAN M, DUNSELMAN G, LI TC, CHEONG Y. The impact of endometrioma on IVF/ICSI outcomes: a systematic review and meta-analysis. *Hum Reprod Update* 2015;21(6):809–25. doi:10.1093/humupd/dmv035.
12. HART RJ, HICKEY M, MAOURIS P, BUCKETT W. Excisional surgery versus ablative surgery for ovarian endometriomata. *Cochrane Database Syst Rev* 2008(2):CD004992. doi:10.1002/14651858.CD004992.pub3.
13. HUGHES E, BROWN J, COLLINS JJ, FARQUHAR C, FEDORKOW DM, VANDEKERCKHOVE P. Ovulation suppression for endometriosis. *Cochrane Database Syst Rev* 2007(3):CD000155. doi:10.1002/14651858.CD000155.pub2.
14. JACOBSON TZ, DUFFY JM, BARLOW D, FARQUHAR C, KONINCKX PR, OLIVE D. Laparoscopic surgery for subfertility associated with endometriosis. *Cochrane Database Syst Rev* 2010(1):CD001398. doi:10.1002/14651858.CD001398.pub2.
15. JOHNSON NP, HUMMELSHOJ L. Consensus on current management of endometriosis. *Hum Reprod* 2013;28(6):1552–68. doi:10.1093/humrep/det050.
16. KEYHAN S, HUGHES C, PRICE T, MUASHER S. An Update on Surgical versus Expectant Management of Ovarian Endometriomas in Infertile Women. *Biomed Res Int* 2015;2015:204792. doi:10.1155/2015/204792.
17. MARCOUX S, MAHEUX R, BERUBE S. Laparoscopic surgery in infertile women with minimal or mild endometriosis. Canadian Collaborative Group on Endometriosis. *N Engl J Med* 1997;337(4):217–22. doi:10.1056/NEJM199707243370401.
18. MEULEMAN C, TOMASSETTI C, D'HOORE A, VAN CLEYNENBREUGEL B, PENNINGCKX F, VERGOTE I et al. Surgical treatment of deeply infiltrating endometriosis with colorectal involvement. *Hum Reprod Update* 2011;17(3):311–26. doi:10.1093/humupd/dmq057.
19. MISSMER SA, HANKINSON SE, SPIEGELMAN D, BARBIERI RL, MARSHALL LM, HUNTER DJ. Incidence of laparoscopically confirmed endometriosis by demographic, anthropometric, and lifestyle factors. *Am J Epidemiol* 2004;160(8):784–96. doi:10.1093/aje/kwh275.
20. NULSEN JC, WALSH S, DUMEZ S, METZGER DA. A randomized and longitudinal study of human menopausal gonadotropin with intrauterine insemination in the treatment of infertility. *Obstet Gynecol* 1993;82(5):780–6.
21. PARAZZINI F. Ablation of lesions or no treatment in minimal-mild endometriosis in infertile women: a randomized trial. Gruppo Italiano per lo Studio dell'Endometriosi. *Hum Reprod* 1999;14(5):1332–4.
22. PRACTICE COMMITTEE OF THE AMERICAN SOCIETY FOR REPRODUCTIVE MEDICINE. Endometriosis and Infertility: A Committee Opinion. *Fertil Steril* 2012;98(3):591–8. doi:10.1016/j.fertnstert.2012.05.031.
23. RUTSTEIN S, IQBAL S, IQBAL SH. Infecundity, Infertility, and Childlessness in developing Countries. In: DHS Comparative Reports n° 9 Calverton, editor. ORC Macro and the WHO. Calverton, Maryland, USA; 2004.
24. SOMIGLIANA E, BERLANDA N, BENAGLIA L, VIGANO P, VERCELLINI P, FEDELE L. Surgical excision of endometriomas and ovarian reserve: a systematic review on serum antimullerian hormone level modifications. *Fertil Steril* 2012;98(6):1531–8. doi:10.1016/j.fertnstert.2012.08.009.
25. SOMIGLIANA E, GARCIA-VELASCO JA. Treatment of infertility associated with deep endometriosis: definition of therapeutic balances. *Fertil Steril* 2015;104(4):764–70. doi:10.1016/j.fertnstert.2015.08.003.
26. STEPNIIEWSKA A, POMINI P, SCIOSCIA M, MEREU L, RUFFO G, MINELLI L. Fertility and clinical outcome after bowel resection in infertile women with endometriosis. *Reprod Biomed Online* 2010;20(5):602–9. doi:10.1016/j.rbmo.2009.12.029.
27. SURREY ES. Endometriosis-Related Infertility: The Role of the Assisted Reproductive Technologies. *Biomed Res Int* 2015;2015:482959. doi:10.1155/2015/482959.
28. THOMAS EJ, COOKE ID. Successful treatment of asymptomatic endometriosis: does it benefit infertile women? *Br Med J (Clin Res Ed)* 1987;294(6580):1117–9.
29. TUMMON IS, ASHER LJ, MARTIN JS, TULANDI T. Randomized controlled trial of superovulation and insemination for infertility associated with minimal or mild endometriosis. *Fertil Steril* 1997;68(1):8–12.
30. VERCELLINI P, BARBARA G, BUGGIO L, FRATTARUOLO MP, SOMIGLIANA E, FEDELE L. Effect of patient selection on estimate of reproductive success after surgery for rectovaginal endometriosis: literature review. *Reprod Biomed Online* 2012;24(4):389–95. doi:10.1016/j.rbmo.2012.01.003.
31. VERCELLINI P, PIETROPAOLO G, GIORGI O DE, DAGUATI R, PASIN R, CROSIGNANI PG. Reproductive performance in infertile women with rectovaginal endometriosis: is surgery worthwhile? *Am J Obstet Gynecol* 2006;195(5):1303–10. doi:10.1016/j.ajog.2006.03.068.
32. VERCELLINI P, SOMIGLIANA E, VIGANO P, ABBIATI A, BARBARA G, CROSIGNANI PG. Surgery for endometriosis-associated infertility: a pragmatic approach. *Hum Reprod* 2009;24(2):254–69. doi:10.1093/humrep/den379.
33. VERKAUF BS. Incidence, symptoms, and signs of endometriosis in fertile and infertile women. *J Fla Med Assoc* 1987;74(9):671–5.
34. ZIEGLER D DE, BORGHESE B, CHAPRON C. Endometriosis and infertility: pathophysiology and management. *Lancet* 2010;376(9742):730–8. doi:10.1016/S0140-6736(10)60490-4.
35. ZIEGLER D DE, GAYET V, AUBRIOT FX, FAUQUE P, STREULI I, WOLF JP et al. Use of oral contraceptives in women with endometriosis before assisted reproduction treatment improves outcomes. *Fertil Steril* 2010;94(7):2796–9. doi:10.1016/j.fertnstert.2010.05.056.

## 4.2

## Endometriosis and Pain

Sylvia Mechsner<sup>a</sup>

## 4.2.1 Introduction

## 4.2.1.1 Endometriosis-Associated Pain

Endometriosis is a disease that affects women of reproductive age and presents with symptoms of dysmenorrhea, dyspareunia, dyschezia, dysuria, cyclic and acyclic pelvic pain, menstrual disorders, and infertility. All these effects have a profound negative impact not only on clinical status but also on the broader human and economic toll taken by the disease.<sup>25,38</sup>

While the above symptoms are relatively specific for endometriosis – there is no other diagnostic entity that presents with such a typical, cyclic pattern of complaints –, endometriosis should also be suspected in cases where there is a significant delay between symptom onset and the time of definitive diagnosis. Many patients have to visit more than 10 different doctors until an eventual diagnosis of endometriosis is established.<sup>41</sup> Based on current data, the mean elapsed time between symptom onset and definitive diagnosis ranges from 7 to 11 years.<sup>30</sup> This finding can be explained by a wide range of many other nonspecific features such as bowel and bladder complaints, pain radiating to the legs, concomitant autonomic symptoms like nausea and vomiting, gastric disorders, headache, dizziness, painful ovulation (intermenstrual pain), irregular pelvic pain, low back pain, and chronic fatigue syndrome (Table 4.1). The complex and multifactorial nature of disease may give rise to misconceptions that often lead to a misdiagnosis.

**Nonspecific symptoms**

- Nonspecific bladder disorder.
- Nonspecific bowel dysfunction.
- Spotting, heavy menstrual bleeding.
- Concomitant autonomic symptoms: nausea, vomiting, gastric disorders.
- Headache, dizziness.
- Painful ovulation (intermenstrual pain).
- Irregular pelvic pain.

<sup>a</sup> | Professor, MD, PhD; Head of the Charité Center for Endometriosis Care; Department of Gynaecology and Breast Centre of the Charité University Medicine, Campus Benjamin Franklin, Berlin, Germany

**Corresponding author:**Prof. Dr. med. **Sylvia Mechsner**

Leiterin Endometriose- und Myomzentrum Charité  
Charité Centrum Frauen-, Kinder- und Jugendmedizin mit  
Perinatalzentrum und Humangenetik CC 17  
Klinik für Gynäkologie mit Brustzentrum der Charité  
Campus Benjamin Franklin  
Hindenburgdamm 30, 12200 Berlin, Germany  
E-mail: sylvia.mechsner@charite.de

- Low back pain.
- Pain radiating to the legs.
- Chronic fatigue syndrome.
- Combinations of the above symptoms.

**Table 4.1**

These diagnostic problems stem mainly from a lack of knowledge about the etiopathogenesis and mechanisms of pain generation in endometriosis. The presence of ‘unremarkable’ physical findings in many patients makes it difficult to establish a diagnosis.

However, the details of a patient’s history appear to be linked to the varying manifestations of endometriosis that occur in different types of the disease and at varying sites. The main area of predilection for endometriosis is the pelvis. Lesions affecting the pelvic organs (uterus, bladder, bowel) usually present with visceral pain, whereas lesions on the pelvic wall tend to cause somatic pain. The characteristics of these two types of pain are quite different and are linked to a wide range of symptoms. On the other hand, most patients present with a combined pattern of endometriotic lesions that are capable of inducing various types of pain.

Thus, more than 84 % of patients suffer from dysmenorrhea and pelvic pain while over 72 % report additional complaints. More than 70 % of endometriosis patients are affected by dyspareunia, and up to 50 % suffer from dyschezia.<sup>64</sup>

## 4.2.1.2 Definition and Classification of Endometriosis

Endometriosis is an inflammatory disease in which endometrium-like tissue grows outside the uterine cavity. Endometriosis can occur at a variety of sites. By definition, *endometriosis genitalis externa* is characterized by the presence of endometriotic lesions on the visceral and parietal peritoneum of the female internal genital organs (peritoneum of the uterus, fallopian tubes and ovaries, also the bladder, ovarian fossa, cul-de-sac, ligaments, and pelvic wall) and by the presence of endometriotic ovarian cysts (*endometriomas*). According to the revised classification system of the *American Society for Reproductive Medicine* (rASRM), endometriosis externa is divided into four stages from minimal to severe (rASRM I–IV)<sup>6</sup> based on the size and number of lesions and bilaterality, as well as associated adhesion formation noted at the time of surgery. On the other hand, the presence of epithelial and stromal cells in the myometrium and fallopian tubes is termed *adenomyosis*, known also as *endometriosis interna*. The presence of endometriotic lesions outside the female reproductive tract (in the bladder, bowel, diaphragm, abdominal wall, or even the lung) is called *extragenital endometriosis*. Endometriotic lesions exhibit a superficial and/or deep infiltrating growth pattern and may cause the destruction of adjacent tissues like the bowel, bladder,



and ureter. The most common form of deep infiltrating endometriosis is *rectovaginal endometriosis*, which is typically located in the rectovaginal septum and classified according to the ENZIAN scoring system.<sup>81</sup> This system has been shown to be helpful in assessing the degree to which endometriotic tissue has infiltrated adjacent organs or anatomic structures such as the sacrouterine ligaments, vagina, ureter, or bowel wall. Destructive changes at different sites may lead to various complaints such as severe pain and functional disorders, and bowel-wall infiltration may even cause stenosis. The ectopic endometrium-like tissue incites a local, chronic inflammatory response that promotes the formation of adhesions, leading to the progression of disease and to structural changes in internal genitalia, with associated functional complaints.

As a result, endometriosis is frequently associated with complex symptoms, although the severity of pain is disproportionate to the stage of disease.<sup>7,33,42,83</sup> Conclusions can indeed be drawn regarding the nature of pain in symptomatic patients,<sup>31,32,48</sup> bearing in mind that the symptoms of various manifestations may overlap. Patients with adenomyosis, for example, usually have dysmenorrhea but may also suffer from cyclic pelvic pain.<sup>71</sup> The same symptoms may occur in endometriosis externa. All manifestations of endometriosis can lead to dysmenorrhea, and intralesional microbleeds may be a contributing factor.<sup>82</sup> Dyspareunia is a typical feature of uterine adenomyosis, endometriosis externa, and in some patients with rectovaginal endometriosis, whereas infiltration of the bladder or bowel tends to cause dyschezia or dysuria (Table 4.2).

## 4.2.2 Pathophysiology of Endometriosis-Associated Pain

### 4.2.2.1 Complexity of Endometriosis-Associated Pain

It is very difficult to explore and understand the various forms of endometriosis-related pain (pelvic pain, dysmenorrhea, dysuria, dyschezia). The sites of lesion involvement will usually determine the character of the pain.

Endometriosis may be associated with both somatic and visceral pain. In most cases, somatic pain originating from the

pelvic wall, muscles, or joints can be identified by its location and is typically described as sharp or stabbing. Visceral pain originates from intraperitoneal organs, which have a sympathetic nerve supply. This type of pain is often poorly localized and is described as dull and cramping. It may be spread over several dermatomes. Pain, in most cases, is associated with nausea and vomiting. Moreover, there is a complex interaction among the reproductive organs, urogenital tract, and bowel so that differentiation is often difficult, especially if the pain becomes chronic.<sup>85</sup> It is important to remember that visceral organs have no somatic innervation, only autonomic innervation. This is a dual innervation system that involves both sympathetic and parasympathetic neurons. The sympathetic source originates from the inferior hypogastric plexus. Visceral organs also have sensory innervation, however. The whole bowel wall and uterus are supplied by myelinated A-delta fibers and nonmyelinated C fibers. The cell bodies of the visceral afferent neurons are located in the dorsal root ganglia. However, the route of the visceral afferents to the spinal cord typically involves passage through or near prevertebral ganglia, where they can distribute collateral axons to autonomic ganglia with associated secretory and motor functions and autonomic activation. With afferent fibers arising from somatic structures, on the other hand, the number of visceral afferent fibers is estimated to be less than 10 % of the total spinal afferent input from all sources. This may explain why visceral pain tends to be poorly localized. It is interesting to note that visceral pain is not a necessary consequence of tissue injury and can result from stretching and mechanical stimulation.

On the other hand, the parietal peritoneum has a rich nerve supply, is sensitive to pain, temperature, touch and pressure, and receives the same somatic nerve supply as the region of the abdominal wall that it lines. Thus, the parietal peritoneum lining the anterior abdominal wall is supplied by the lower six thoracic and first lumbar nerves. It should be kept in mind that these are the same nerves that innervate the muscles and skin of the anterior abdominal wall. The surface of the diaphragm has a different nerve supply. The central part of the diaphragmatic peritoneum is supplied by phrenic nerves, while the peripheral part is supplied by the lower six thoracic

Symptoms	Lesion sites
Dysmenorrhea	<ul style="list-style-type: none"> <li>■ Adenomyosis.</li> <li>■ Peritoneal lesions.</li> <li>■ Deep infiltrating endometriosis.</li> </ul>
Pelvic pain	<ul style="list-style-type: none"> <li>■ Peritoneal und ovarian lesions.</li> <li>■ Adhesions, adenomyosis.</li> </ul>
Dyspareunia	<ul style="list-style-type: none"> <li>■ Rectovaginal endometriosis.</li> <li>■ Lesions of the cul-de-sac and sacrouterine ligaments.</li> </ul>
Dyschezia, dysuria hematochezia, hematuria	<ul style="list-style-type: none"> <li>■ Bowel and bladder involvement.</li> </ul>
Infertility	<ul style="list-style-type: none"> <li>■ Adenomyosis, endometriosis.</li> <li>■ Endometriomas.</li> <li>■ Adhesions.</li> <li>■ Tubal obstruction.</li> </ul>

Table 4.2

nerves. In the pelvic region, the parietal peritoneum is supplied chiefly by the obturator nerve, which is a branch of the lumbar plexus. Somatic nerves that innervate the parietal peritoneum also supply the corresponding segmental areas of skin and muscles. Irritation of the parietal peritoneum incites a reflex muscular contraction with localized hypercontractility, which explains the frequent reports of pelvic floor tenderness.

Other complications result from adhesion-related pain, which is often characterized by a transition from cyclic to acyclic pelvic pain.

Chronic pain in endometriosis patients commonly leads to a reactive depression over time and is associated with somatoform pain symptoms, making the disease even more complex.<sup>73</sup> This calls for a broad differential diagnosis that may include postoperative adhesions (not endometriosis-related), *pelvic inflammatory disease* (PID), pelvic varicosity, interstitial cystitis, nonspecific intestinal disorders such as irritable bowel syndrome, and prior physical and/or sexual abuse.

Ultimately, it is a difficult task to characterize and evaluate pelvic pain due to the difficulty most patients have in accurately describing the location of their pain.<sup>58</sup>

#### 4.2.2.2 Pelvic Pain

Pelvic pain is generally experienced as abdominal pain located below the level of the umbilicus. This pain may be acute or chronic. Pelvic pain that occurs during the menstrual cycle and relates to hormonal causes is known as '*chronic cyclic pelvic pain*' (CCPP). CCPP also includes pelvic pain occurring in a cyclic pattern but not related to menstrual bleeding, as illustrated by the German term '*Mittelschmerz*' or intermenstrual pain.<sup>90</sup> Moreover, pelvic pain may follow no cyclic pattern and is therefore unrelated to hormonal fluctuations.<sup>1</sup>

Other specific forms of pelvic pain are dyspareunia and dysmenorrhea. Dyspareunia is pelvic pain associated with sexual intercourse. Dysmenorrhea, defined as painful menstruation, can be classified as primary or secondary based on the absence or presence of an underlying cause. Painful menstruation without pelvic pathology was formerly described as primary dysmenorrhea, while secondary dysmenorrhea stems from an underlying condition such as endometriosis.<sup>35</sup> However, more than 80% of patients diagnosed with endometriosis report severe dysmenorrhea starting from their first menstrual bleed. Clinical surveillance has shown that the occurrence of primary dysmenorrhea (painful menstruation starting from the first menstrual period) appears to be typical in patients with endometriosis, even though the lesions themselves develop at a later time.<sup>57</sup>

Pathophysiologic aspects of dysmenorrhea, pelvic pain, and dyspareunia will be explored below in greater detail.

#### ■ Dysmenorrhea

Dysmenorrhea is described as an intermittent cramping discomfort in the lower abdomen and pelvis. This may be associated with a bearing-down sensation, backache, and epigastric discomfort with nausea and vomiting. Pain radiating to the legs is not uncommon.

Although dysmenorrhea is considered a major social and economic problem in patients with endometriosis and adenomyosis,<sup>3,38</sup> there is still a lack of knowledge and experience in understanding the pathophysiology of adenomyosis and endometriosis-associated dysmenorrhea.

#### Primary Dysmenorrhea

An established phenomenon in women with primary dysmenorrhea is ischemic pain due to myometrial hyperactivity and a consequent reduction of uterine blood flow.<sup>3</sup> Potential etiological factors in primary dysmenorrhea are substances that increase myometrial contractility such as oxytocin (OT), vasopressin (VP), and prostaglandin (PG) F<sub>2α</sub>.<sup>57</sup> Plasma levels of both VP and OT are elevated in women with dysmenorrhea.<sup>2,4,29,78</sup> Oxytocin receptor (OTR) and vasopressin receptor (VPR) have been detected in the myometrium of nonpregnant women.<sup>51,61</sup> Uterotonic peptides like OT, VP, endothelin, norepinephrine, and/or endoperoxides can promote the vasoconstriction that occurs in dysmenorrhea. They act directly on the resistance of the uterine arteries. The endometrial synthesis of PGF<sub>2α</sub> would be regulated under the influence of OT, estradiol and progesterone, and so PGF<sub>2α</sub> can activate pain by the stimulation of uterine contractions and afferent nerve fibers, leading to a pain sensation.<sup>52</sup>

A therapeutic benefit of competitive OT and VP receptor antagonists in primary dysmenorrhea<sup>1,5,76,77</sup> is supported by the therapeutic use of oral contraceptives in women with primary dysmenorrhea. This therapy works by lowering the plasma levels of OT, VP, and estrogen receptors (ER).<sup>1,2,29</sup> The administration of ethanol inhibits the release of the posterior pituitary hormones VP and OT. It also causes a complete suppression of uterine contractility in nonpregnant women.<sup>36</sup>

#### Endometriosis and Adenomyosis-Associated Dysmenorrhea

Adenomyosis and endometriosis coexist in 90% of cases.<sup>50</sup> The most common symptoms of adenomyosis are dysmenorrhea (30–50%), menorrhagia (50%), metrorrhagia (20%), and occasional dyspareunia, pelvic pain, and infertility.<sup>72</sup> Adenomyosis may be considered a major cause of dysmenorrhea, therefore. The frequency and severity of symptoms correlate with the extent<sup>17</sup> and depth of adenomyotic foci in the myometrium.<sup>68</sup>

#### *Hyper- and Dysperistalsis*

Researchers have found that a model of abnormal myometrial contractility in patients with adenomyosis and endometriosis is similar to that seen in the hyperperistalsis and dysperistalsis of myometrial cells.<sup>22,55</sup> Myometrial contractions in the nonpregnant uterus originate exclusively from the junctional zone.<sup>19,22,60,88</sup> The expression of OTR and VPR has also been established in patients with adenomyosis.<sup>65</sup>

The myometrium consists of at least two functionally and structurally distinct zones: the subendometrial or junctional zone and the outer myometrium.<sup>19-21,26,37,54</sup>

Significant morphologic changes have been noted in the myometrial architecture of adenomyosis patients. The junctional zone in the uteri of patients with adenomyosis

was often found to be significantly more fissured than in women without adenomyosis.<sup>65</sup> Adenomyosis-associated myometrium was also found to be more compact than unaffected myometrium. Overexpression of OTR, which is present in 50% of cases, and metaplastic activity of adenomyotic cells give rise to myometrial hyperplasticity and metaplasia.<sup>34,37,47,49,54,56,66,75</sup> The structural changes promote peristalsis, leading to pain.

#### *Deep Infiltrating Endometriosis of the Rectovaginal Septum*

In deep infiltrating endometriosis of the rectovaginal septum, with bowel and/or vaginal infiltration, the extent of disease usually correlates with the severity of dysmenorrhea and dyspareunia. Significant improvement of these symptoms was reported after excision of the infiltrated rectovaginal lesions.<sup>24</sup>

#### ■ *Pathogenesis of Endometriosis-Associated Cyclic and Acyclic Pelvic Pain*

As noted earlier, the character and pathogenesis of endometriosis-associated chronic pelvic pain are not yet fully understood. The source of the pain may be peritoneal lesions, adhesions, and the uterus itself. Moreover, chronic pelvic pain leads to functional disorders of the pelvic floor, with associated muscle spasms and pain.

#### *Pain from Peritoneal Endometriotic Lesions*

The question as to why patients with peritoneal endometriosis have such severe pain, while other peritoneal diseases such as malignancies are often asymptomatic, is still far from clear. Normal peritoneum has a very rich nerve supply. Most notably, the parietal peritoneum is a mediator of pain in diseases such as acute peritonitis secondary to appendicitis or PID. Possible contributing factors for severe pain expression in peritoneal endometriosis could be the activity of the lesion in producing pain and inflammatory mediators, as well as the growth of nerve fibers and the suspected contractions of isolated muscle fibers in the peritoneum. The ovary, unlike the peritoneum, is quite insensitive to pain. It may assume enormous proportions (e.g., due to ovarian cancer or endometrioma) before significant pain develops, usually as a result of peritoneal irritation.

#### *Inflammatory Nociceptive Pain*

The synthesis of pain mediators occurs in the peritoneal lesions themselves and is the main determinant of peritoneal pain. The number, activity, and infiltration depth of the lesions appear to correlate with pain severity.<sup>24,82,87</sup> Pain mediators such as prostaglandins (PG), histamine, kinins, and interleukins are secreted by peritoneal endometriotic lesions and are known to activate nociceptors.<sup>28,67,87</sup> Consistent with the behavior of ectopic endometrium, peritoneal implants are subject to cyclic changes and therefore secrete mediators in a cyclic fashion. Despite a relative lack of current study data on this issue, recent studies have shown that PG synthesis, with an up-regulation of cyclooxygenase-2 (COX-2) expression, is indirectly increased in peritoneal endometriosis-associated macrophages<sup>89</sup> and in ectopic endometriotic implants.<sup>69</sup> The COX-2 expression correlates with the concentration of secreted PGE<sub>2</sub> in the peritoneal fluid and with the severity of endometriosis.<sup>89</sup>

This mechanism underlies the inflammatory nociceptive pain component and validates the use of PG synthesis inhibitors such as NSAIDs in the treatment of endometriosis. It also explains the target of hormonal therapy with combined oral contraceptives (COCs), progesterone-only pill (POP), and gonadotropin releasing hormone agonists (GnRHa) for the deregulation of ovarian function. Interrupting the cyclic activity of the lesions in this way can significantly improve symptoms.

Unfortunately, despite the well-documented results of surgical and hormonal therapy, pain continues to be an everyday fact of life for a great many patients, with a reported failure rate of 20–25%.<sup>7</sup> It is also remarkable that only half of patients complain of 'typical' endometriosis pain that is intermittent and related to the menstrual cycle, while the remaining half suffer from chronic pain.<sup>7</sup>

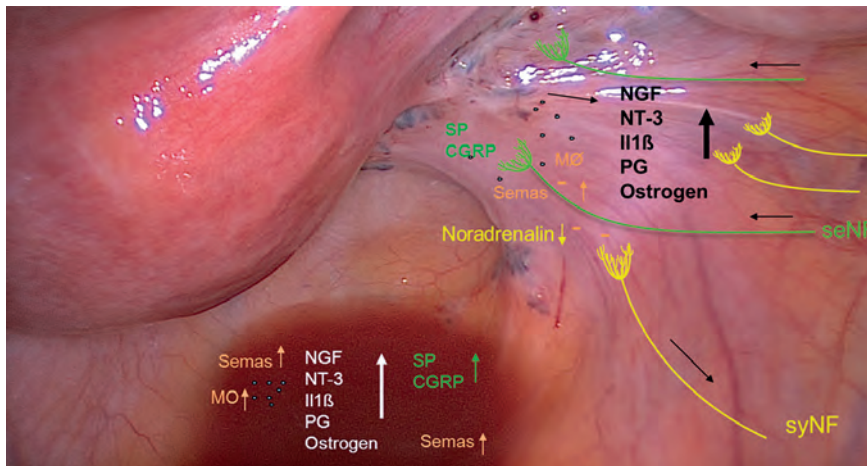
Because its nature is poorly understood, this chronic pain has often prompted psychosomatic therapy trials undertaken in the belief that cognitive distortions, negative conditioning, depressive disorders, or 'social stress' (based on the biopsychosocial concept of chronic pain) may be the principal source of complaints. The quality of chronic pain is often described as burning or stabbing. To date, there have been no published data on endometriosis-associated pain qualities. It could also be interpreted as neuropathic pain, and a neural invasion theory has been proposed.<sup>7</sup>

#### *Neurogenic Inflammation*

The dissemination of nerve fibers in close contact with endometriotic lesions is an established observation<sup>8,63,80</sup> and suggests that nerve fibers are involved in pain generation, especially the development of neuropathic pain and neurogenic inflammation. More specifically, it has been suggested that the co-localization of nerve fibers with immature blood vessels and the expression and release of nerve growth factor (NGF) is related to the ingrowth of new nerve fibers into endometriotic lesions.<sup>62</sup>

The nervous system plays a key role in other chronic inflammatory diseases. Normally, in unaffected tissue, more sympathetic nerve fibers are expressed than sensory nerve fibers. Sympathetic neurotransmitters such as epinephrine and norepinephrine have a concentration-dependent anti-inflammatory action, while the neurotransmitter substance P, released from sensory nerve fibers, is more pro-inflammatory. Tissue that has undergone inflammatory changes, as in rheumatoid arthritis, shows a significant increase in sensory nerve fibers with an associated loss of sympathetic fibers. The result is an imbalance of pro- and anti-inflammatory neurotransmitters in inflammatory tissue.<sup>35</sup> This phenomenon appears to be a major factor in the persistence of chronic inflammation and pain generation. When the distribution of sensory and sympathetic nerve fibers is analyzed in peritoneal endometriotic lesions, a definite imbalance of sensory and sympathetic nerve fibers can be confirmed.<sup>3</sup> These changes in peritoneal innervation seem to account for the neurotrophic properties found in endometriotic lesions, with the expression and release of NGF as well as estrogen.<sup>13,18,63</sup> The expression of NGF and estrogen leads to a proliferation of sensory nerve fibers and a depletion of sympathetic nerve fibers.<sup>14</sup>





**Fig. 4.5** The process of a neurogenic inflammatory response in tissue affected by endometriosis: The expression of NGF and estrogen induces the proliferation of sensory nerve fibers (seNF) and depletion of sympathetic nerve fibers (syNF). Sensory nerve fibers secrete neuropeptides, triggering a neurogenic inflammatory response, while increasing numbers of immune cells and macrophages release pain-mediating substances and semaphorins.

The sensory nerve fibers secrete neuropeptides, inciting a neurogenic inflammatory response with increasing numbers of immune cells and macrophages. These cells, in turn, release pain-mediating substances as well as semaphorins. Semaphorins are nerve-repellent factors for sympathetic nerve fibers, leading to the repulsion and loss of sympathetic fibers.<sup>10</sup> Thus, we can see how the process of a neurogenic inflammatory response can be initiated and how ongoing neuroimmune modulation could alter and cause microinjury to the mesothelial cells of the peritoneum (Fig. 4.5).<sup>53</sup>

#### Endometriosis-Associated Smooth Muscle Cells

Endometriosis-associated smooth muscle cells are another important component of peritoneal endometriotic lesions.<sup>62</sup> Endometriosis-associated smooth muscle cells occupy a significant portion (40%) of the lesion.<sup>15</sup> These cells express oxytocin and vasopressin receptor, both estrogen receptors, and progesterone receptor, which are all components that characterize uterine myometrial cells.<sup>40</sup> It is possible that peritoneal nociceptors leading to pain generation are stimulated and incite contractions of these endometriosis-associated smooth muscle cells.<sup>23,40</sup>

#### Adhesions

Adhesions are believed to be one of the mechanisms involved in the pathogenesis of pelvic pain. The evolution of endometriosis is associated with the development of adhesions, which may underlie the transition from cyclic pain to acyclic chronic pain. For many years, researchers have recognized the importance of inflammatory and postoperative adhesions as the principal sources of chronic pelvic pain. One prospective study found that pain reduction by adhesiolysis was not significantly improved when compared with diagnostic laparoscopy alone.<sup>79</sup> Only a more specific analysis of the lysis of very dense, well-vascularized and innervated adhesions showed a significant reduction in pain. Data regarding the etiology of adhesion-related pain are still unclear, however. There is a theory that endometriosis is a chronic inflammatory disease associated with pelvic adhesions<sup>27</sup> and with reformation of adhesions following laparoscopic excision and adhesiolysis of endometriotic lesions.<sup>43,59,70</sup>

#### Uterus

Parker *et al.* found that peritoneal lesions were not the only factor involved in the development of pain. Pelvic pain could still persist after optimal excision of all endometriotic lesions in the pelvis, usually as a result of comorbid adenomyosis. This shows that the uterus itself is involved in the sensation of lower abdominal pain. Accordingly, it is difficult to differentiate uterine and pelvic pain.<sup>70</sup>

#### Musculoskeletal System

Pelvic pain can develop from the pelvic floor muscles as well as the muscles of the abdominal wall. Today, these muscles are considered to be primary or secondary causes of pelvic pain. Up to 85% of patients with chronic pelvic pain are found to have musculoskeletal dysfunction such as spasticity of the pelvic floor muscles.<sup>12,74</sup> Pelvic floor spasms are a common finding in endometriosis patients with chronic pain.

#### Deep Dyspareunia

Dyspareunia is a distressful condition that can significantly impact relationship satisfaction, family planning, and quality of life. Position-dependent pain and pain on deep penetration are common complaints in endometriosis patients. The pathogenesis of endometriosis-associated dyspareunia is still unclear, except in cases where deep infiltrating nodules are found in the rectovaginal septum. Rectovaginal nodules may reach several centimeters in diameter and often have a dense nerve supply, with some nerve fibers infiltrated by stromal cells.<sup>9</sup> An increase in nerve fiber density correlates with increasing hyperalgesia.<sup>9</sup> Pain also results from traction on the inelastic parametrium by the compression of fibrotic tissue embedded in endometriotic implants.<sup>86</sup>

#### Central Sensitization

Apart from peripheral pain sensitization, central sensitization can be an important mechanism of pain generation and perception. Central sensitization can act on various levels of the spinal cord to create a condition in which normal input evokes an exaggerated response. This phenomenon, while well explored in other conditions (toothache, headache, fibromyalgia), has been poorly investigated in endometriosis. It is probably one of the factors that leads to chronic pain in some women, independent of the lesions themselves.

He *et al.* reported on a very important finding in endometriosis patients. They discovered that the pain threshold in patients with symptomatic endometriosis was significantly lower than in healthy women. More importantly, the excision of endometriotic lesions was not only capable of lowering the level of pain but even caused the pain threshold to return to a normal level similar to that in healthy controls.<sup>45</sup> This suggests that the surgical treatment of endometriotic lesions can have a positive impact on central hyperalgesia.

Another interesting aspect of chronic pelvic pain is a possible effect of brain morphology on changes. A morphometric study of the brain was conducted in four groups: patients with endometriosis and chronic pelvic pain (CPP), patients with endometriosis but without CPP, patients with CPP but without endometriosis, and healthy controls. The study showed that, relative to the controls, women with endometriosis-associated CPP and women with CPP and no endometriosis had decreased gray-matter volume in brain areas involved in pain perception, including the left thalamus, left cingulate gyrus, right putamen, and right insula. The same pattern was not observed in patients with endometriosis and no CPP. The authors concluded that CPP was associated with changes in regional gray-matter volume within the central pain system. At the same time, endometriosis itself can be an important risk factor for developing CPP, acting as a cyclic source of peripheral nociceptive input. Recent data prove that changes in the central pain system also play an important role in the evolution of chronic pain, regardless of the presence of endometriosis. The authors propose a conceptual approach for understanding possible mechanisms of pain chronification in patients with dysmenorrhea and/or endometriosis.<sup>11</sup>

#### 4.2.2.3 Management of Endometriosis-Associated Pain in Patients Without a Current Desire for Pregnancy

First it is essential to take an accurate and meticulous patient history that includes a detailed, chronological pain history. The pain history should cover timing, onset, location, radiation, precipitating and relieving factors, and the nature of the pain. In particular, the physician should ask specifically about dysmenorrhea, pelvic pain (cyclic and acyclic), deep dyspareunia, dyschezia, and dysuria. History taking should include attention to cyclic pain relating to the patient's menstrual cycle. The onset of associated symptoms such as dysuria or a change in bowel habits relative to the menstrual cycle should also be determined. The severity of symptoms should be rated in a questionnaire with a visual analog scale, and associated symptoms such as nonspecific bowel complaints should be assessed. A meticulous review of the 'typical endometriosis history' will avoid overlap with symptoms of other gynecologic and nongynecologic conditions that involve dysmenorrhea or pelvic pain. The clinical examination should include a pelvic examination and transvaginal ultrasound. Focal tenderness on pelvic examination is strongly associated with endometriosis. A pelvic mass, immobile pelvic organs, and rectovaginal nodules are also suggestive of endometriosis.

If endometriosis is suspected, a diagnostic laparoscopy should be performed and should include the removal of all visible endometriotic implants.

Initial clinical staging should also be done during this procedure.<sup>6</sup> In order to achieve significant pain reduction and quality-of-life improvement, it is essential to remove all visible implants and endometriotic nodules, lyse adhesions, and restore physiologic anatomy. Several studies have documented the efficacy of this approach,<sup>39,44,46</sup> especially in patients with deep infiltrating endometriosis.<sup>24</sup>

Endometriosis, of course, is characterized by a high recurrence rate of symptoms and implants following surgical treatment.<sup>84</sup> Most patients will require hormonal therapy due to persistent complaints. Medical treatment with the various forms of COCs and POPs is considered to be the best approach in patients who desire pregnancy. This type of therapy is appropriate if it can be continued on a long-term basis at reasonable cost with an acceptable profile of side effects. The use of COCP on a continuous basis is effective in suppressing menstruation and preventing dysmenorrhea and cyclic pelvic pain. Progestins act upon various processes, including the suppression of ovarian activity, and are acknowledged to be highly effective in endometriosis patients.<sup>82</sup> Recently, a levonorgestrel-releasing intrauterine device was tested as a new approach to the treatment of dysmenorrhea.<sup>16</sup> GnRH analogues can be used to suppress ovarian function for pain relief in endometriosis patients. Symptomatic treatment can be modeled with painkillers such as prostaglandin inhibitors (ibuprofen) in good responders. Pain recurrence after surgery with a normal pelvic examination would be a definite indication for hormonal therapy. No accurate data are available on the quality and duration of benefit yielded from secondary surgery, so the need for reoperation is a difficult decision.<sup>85</sup> It should be decided only after reviewing the efficacy of initial surgery, the presence of a visible or palpable endometriotic mass, and evaluation of issues related to family planning (in patients with a normal pelvic examination). Moreover, reoperation should be postponed for as long as possible.

Osteopathic therapy has been shown to be very beneficial for pelvic pain, adhesions, myofascial pain, and myalgia as a complementary treatment option. Interdisciplinary observation of these patients is also desirable (counseling, treatment at a pain management center). Considering the severity of endometriosis-associated chronic pelvic pain and quality-of-life reduction, a long-term program of individualized management is advised. The most important message of this chapter is the need to educate patients about the chronic, biological nature of their disease. They should understand that the disease can result in a chronic pelvic pain syndrome. Open discussion is essential so that patients can better adapt to their condition and learn new lifestyle strategies. Once a chronic pain syndrome has become established, it is difficult to break the cycle.

#### 4.2.3 Conclusion

Pain is a distressing, complex process related to various pain stimuli, signal transmission, and central processing, which are influenced by subjective variables of pain perception (Fig. 4.5). These mechanisms are mediated by various peptides. It is important to gain a fuller understanding of pain generation, as the results of surgical, hormonal, and analgesic therapies

are often unsatisfactory. On the other hand, hormonal and surgical treatments are beneficial in a great many patients, resulting in a complete resolution of symptoms.

Commonly accepted inflammatory processes, including the nociceptive pain component of neuropathic pain, neurogenic inflammatory processes, and myogenic pain are recognized aspects of the complex pathology that underlies endometriosis-associated pelvic pain.

#### 4.2.4 References

- AKERLUND M. Can primary dysmenorrhea be alleviated by a vasopressin antagonist? Results of a pilot study. *Acta obstetrica et gynecologica Scandinavica* 1987; 66(5): 459-61.
- AKERLUND M. The role of oxytocin and vasopressin in the initiation of preterm and term labour as well as primary dysmenorrhoea. *Regulatory peptides* 1993; 45(1-2): 187-91.
- AKERLUND M, ANDERSSON KE. Effects of terbutaline on human myometrial activity and endometrial blood flow. *Obstetrics and gynecology* 1976; 47(5): 529-35.
- AKERLUND M, STROMBERG P, FORSLING ML. Primary dysmenorrhoea and vasopressin. *British journal of obstetrics and gynaecology* 1979; 86(6): 484-7.
- AKERLUND M, MELIN P, MAGGI M. Potential use of oxytocin and vasopressin V1a antagonists in the treatment of preterm labour and primary dysmenorrhoea. *Advances in experimental medicine and biology* 1995; 395: 595-600.
- AMERICAN SOCIETY FOR REPRODUCTIVE MEDICINE. Revised ASRM classification of endometriosis: 1996. *Fertility and sterility* 1997; 67(5): 817-21.
- AMERICAN SOCIETY FOR REPRODUCTIVE MEDICINE. Treatment of pelvic pain associated with endometriosis. *Fertility and sterility* 2008; 90(5 Suppl): S260-9.
- ANAF V, CHAPRON C, EL NAKADI I, MOOR V, SIMONART T, NOEL J-C. Pain, mast cells, and nerves in peritoneal, ovarian, and deep infiltrating endometriosis. *Fertility and sterility* 2006; 86(5): 1336-43.
- ANAF V, SIMON P, EL NAKADI I, FAYT I, SIMONART T, BUXANT F, et al. Hyperalgesia, nerve infiltration and nerve growth factor expression in deep adenomyotic nodules, peritoneal and ovarian endometriosis. *Human reproduction (Oxford, England)* 2002; 17(7): 1895-900.
- ARELLANO ESTRADA C, BARCENA DE ARELLANO ML, SCHNEIDER A, MECHSNER S. Neuroimmunomodulation in the pathogenesis of endometriosis. Abstracts of the 10th Meeting of the German Endocrine Brain Immune Network (GEBIN). *Brain, Behavior, and Immunity* 2013; 29(supplement): S2.
- AS-SANIE S, HARRIS RE, NAPADOW V, KIM J, NESHEWAT G, KAIRYS A, et al. Changes in regional gray matter volume in women with chronic pelvic pain: a voxel-based morphometry study. *Pain* 2012; 153(5): 1006-14.
- BAKER PK. Musculoskeletal origins of chronic pelvic pain. Diagnosis and treatment. *Obstetrics and gynecology clinics of North America* 1993; 20(4): 719-42.
- BARCENA DE ARELLANO ML, ARNOLD J, VERCELLINO F, CHIANTERA V, SCHNEIDER A, MECHSNER S. Overexpression of nerve growth factor in peritoneal fluid from women with endometriosis may promote neurite outgrowth in endometriotic lesions. *Fertility and sterility* 2011; 95(3): 1123-6.
- BARCENA DE ARELLANO ML, ARNOLD J, LANG H, VERCELLINO GF, CHIANTERA V, SCHNEIDER A, et al. Evidence of neurotrophic events due to peritoneal endometriotic lesions. *Cytokine* 2013; 62(2): 253-61.
- BARCENA DE ARELLANO ML, GERICKE J, REICHEL U, OKUDUCU AF, EBERT AD, CHIANTERA V, et al. Immunohistochemical characterization of endometriosis-associated smooth muscle cells in human peritoneal endometriotic lesions. *Human reproduction (Oxford, England)* 2011; 26(10): 2721-30.
- BAYOGLU TEKIN Y, DILBAZ B, ALTINBAS SK, DILBAZ S. Postoperative medical treatment of chronic pelvic pain related to severe endometriosis: levonorgestrel-releasing intrauterine system versus gonadotropin-releasing hormone analogue. *Fertility and sterility* 2011; 95(2): 492-6.
- BENSON RC, SNEEDEN VD. Adenomyosis: a reappraisal of symptomatology. *American journal of obstetrics and gynecology* 1958; 76(5): 1044-57; discussion 57-61.
- BERKLEY KJ, DMITRIEVA N, CURTIS KS, PAPKA RE. Innervation of ectopic endometrium in a rat model of endometriosis. *Proceedings of the National Academy of Sciences of the United States of America* 2004; 101(30): 11094-8.
- BROSENS JJ, SOUZA NM, BARKER FG. Uterine junctional zone: function and disease. *Lancet (London, England)* 1995; 346(8974): 558-60.
- BROSENS JJ, SOUZA NM, BARKER FG. Steroid hormone-dependent myometrial zonal differentiation in the non-pregnant human uterus. *European journal of obstetrics, gynecology, and reproductive biology* 1998; 81(2): 247-51.
- BROSENS JJ, BARKER FG, SOUZA NM. Myometrial zonal differentiation and uterine junctional zone hyperplasia in the non-pregnant uterus. *Human reproduction update* 1998; 4(5): 496-502.
- BULLETTI C, ZIEGLER D, POLLI V, DEL FERRO E, PALINI S, FLAMIGNI C. Characteristics of uterine contractility during menses in women with mild to moderate endometriosis. *Fertility and sterility* 2002; 77(6): 1156-61.
- BURNS PD, MENDES JO, YEMM RS, CLAY CM, NELSON SE, HAYES SH, et al. Cellular mechanisms by which oxytocin mediates ovine endometrial prostaglandin F2alpha synthesis: role of G(i) proteins and mitogen-activated protein kinases. *Biology of reproduction* 2001; 65(4): 1150-5.
- CHAPRON C, FAUCONNIER A, DUBUISSON J-B, BARAKAT H, VIEIRA M, BREART G. Deep infiltrating endometriosis: relation between severity of dysmenorrhoea and extent of disease. *Human reproduction (Oxford, England)* 2003; 18(4): 760-6.
- CRAMER DW, MISSMER SA. The epidemiology of endometriosis. *Annals of the New York Academy of Sciences* 2002; 955: 11-22; discussion 34-6, 396-406.
- DAELS J. Uterine contractility patterns of the outer and inner zones of the myometrium. *Obstetrics and gynecology* 1974; 44(3): 315-26.
- DANIEL Y, GEVA E, AMIT A, ESHED-ENGLENDER T, BARAM A, FAIT G, et al. Do soluble cell adhesion molecules play a role in endometriosis? *American journal of reproductive immunology (New York, NY : 1989)* 2000; 43(3): 160-6.
- DRAKE TS, O'BRIEN WF, RAMWELL PW, METZ SA. Peritoneal fluid thromboxane B2 and 6-keto-prostaglandin F1 alpha in endometriosis. *American journal of obstetrics and gynecology* 1981; 140(4): 401-4.
- EKSTROM P, AKERLUND M, FORSLING M, KINDAHL H, LAUDANSKI T, MRUGACZ G. Stimulation of vasopressin release in women with primary dysmenorrhoea and after oral contraceptive treatment – effect on uterine contractility. *British journal of obstetrics and gynaecology* 1992; 99(8): 680-4.



30. FASSBENDER A, BURNEY RO, O DF, D'HOOGHE T, GIUDICE L. Update on Biomarkers for the Detection of Endometriosis. *BioMed research international* 2015; 2015: 130854.
31. FAUCONNIER A, CHAPRON C. Endometriosis and pelvic pain: epidemiological evidence of the relationship and implications. *Human reproduction update* 2005; 11(6): 595-606.
32. FAUCONNIER A, CHAPRON C, DUBUISSON J-B, VIEIRA M, DOUSSET B, BREART G. Relation between pain symptoms and the anatomic location of deep infiltrating endometriosis. *Fertility and sterility* 2002; 78(4): 719-26.
33. FEDELE L, BIANCHI S, BOCCIOLONE L, DI NOLA G, PARAZZINI F. Pain symptoms associated with endometriosis. *Obstetrics and gynecology* 1992; 79(5 ( Pt 1)): 767-9.
34. FERENCZY A. Pathophysiology of adenomyosis. *Human reproduction update* 1998; 4(4): 312-22.
35. FERRERO S, HAAS S, REMORGIDA V, CAMERINI G, FULCHERI E, RAGNI N, et al. Loss of sympathetic nerve fibers in intestinal endometriosis. *Fertility and sterility* 2010; 94(7): 2817-9.
36. FUCHS AR, COUTINHO EM. Suppression of uterine activity during menstruation by expansion of the plasma volume. *Acta endocrinologica* 1971; 66(1): 183-92.
37. FUJII S, KONISHI I, MORI T. Smooth muscle differentiation at endometrio-myometrial junction. An ultrastructural study. *Virchows Archiv A, Pathological anatomy and histopathology* 1989; 414(2): 105-12.
38. GAO X, OUTLEY J, BOTTEMAN M, SPALDING J, SIMON JA, PASHOS CL. Economic burden of endometriosis. *Fertility and sterility* 2006; 86(6): 1561-72.
39. GARRY R. The effectiveness of laparoscopic excision of endometriosis. *Current opinion in obstetrics & gynecology* 2004; 16(4): 299-303.
40. GIMPL G, FAHRENHOLZ F. The oxytocin receptor system: structure, function, and regulation. *Physiological reviews* 2001; 81(2): 629-83.
41. GREENE R, STRATTON P, CLEARY SD, BALLWEG ML, SINAII N. Diagnostic experience among 4,334 women reporting surgically diagnosed endometriosis. *Fertility and sterility* 2009; 91(1): 32-9.
42. GRUPPO ITALIANO PER LO STUDIO DELL'ENDOMETRIOSI. Relationship between stage, site and morphological characteristics of pelvic endometriosis and pain. *Human reproduction (Oxford, England)* 2001; 16(12): 2668-71.
43. GURGAN T, URMAN B, YARALI H. Adhesion formation and reformation after laparoscopic removal of ovarian endometriomas. *The Journal of the American Association of Gynecologic Laparoscopists* 1996; 3(3): 389-92.
44. HART R, HICKEY M, MAOURIS P, BUCKETT W, GARRY R. Excisional surgery versus ablative surgery for ovarian endometriomata: a Cochrane Review. *Human reproduction (Oxford, England)* 2005; 20(11): 3000-7.
45. HE W, LIU X, ZHANG Y, GUO SW. Generalized hyperalgesia in women with endometriosis and its resolution following a successful surgery. *Reprod Sci* 2010; 17(12): 1099-111.
46. JACOBSON TZ, DUFFY JMN, BARLOW D, KONINCKX PR, GARRY R. Laparoscopic surgery for pelvic pain associated with endometriosis. *The Cochrane database of systematic reviews* 2009; (4): CD001300.
47. KITAI I. Beitrag zur Anatomie und Genese der endometranen Adenomyosis (Adenomyosis uteri interna). *Archives of gynecology and obstetrics* 1925; 124 (1925): 178-212.
48. KONINCKX PR, MEULEMAN C, DEMEYERE S, LESAFFRE E, CORNILLIE FJ. Suggestive evidence that pelvic endometriosis is a progressive disease, whereas deeply infiltrating endometriosis is associated with pelvic pain. *Fertility and sterility* 1991; 55(4): 759-65.
49. KONISHI I, FUJII S, OKAMURA H, MORI T. Development of smooth muscle in the human fetal uterus: an ultrastructural study. *Journal of anatomy* 1984; 139 ( Pt 2): 239-52.
50. KUNZ G, BEIL D, HUPPERT P, NOE M, KISSLER S, LEYENDECKER G. Adenomyosis in endometriosis – prevalence and impact on fertility. Evidence from magnetic resonance imaging. *Human reproduction (Oxford, England)* 2005; 20(8): 2309-16.
51. LEE KH, KHAN-DAWOOD FS, DAWOOD MY. Oxytocin receptor and its messenger ribonucleic acid in human leiomyoma and myometrium. *American journal of obstetrics and gynecology* 1998; 179(3 Pt 1): 620-7.
52. LERNER EJ, JAFFE M, REE HJ, MCDUFF HC. Proliferation of myometrial nerves in a patient with severe dysmenorrhea. *Rhode Island medical journal* 1985; 68(6): 265-7.
53. LESSEY BA, HIGDON HL, 3RD, MILLER SE, PRICE TA. Intraoperative detection of subtle endometriosis: a novel paradigm for detection and treatment of pelvic pain associated with the loss of peritoneal integrity. *Journal of visualized experiments : JoVE* 2012; (70).
54. LEYENDECKER G, KUNZ G. Endometriosis and adenomyosis. *Zentralblatt fur Gynakologie* 2005; 127(5): 288-94.
55. LEYENDECKER G, KUNZ G, WILDT L, BEIL D, DEININGER H. Uterine hyperperistalsis and dysperistalsis as dysfunctions of the mechanism of rapid sperm transport in patients with endometriosis and infertility. *Human reproduction (Oxford, England)* 1996; 11(7): 1542-51.
56. LEYENDECKER G, KUNZ G, NOE M, HERBERTZ M, MALL G. Endometriosis: a dysfunction and disease of the archimetra. *Human reproduction update* 1998; 4(5): 752-62.
57. LIEDMAN R, HANSSON SR, HOWE D, IGIDBASHIAN S, RUSSELL RJ, AKERLUND M. Endometrial expression of vasopressin, oxytocin and their receptors in patients with primary dysmenorrhoea and healthy volunteers at ovulation. *European journal of obstetrics, gynecology, and reproductive biology* 2008; 137(2): 189-92.
58. LONG WN. Pelvic Pain. In: Walker HK, Hall WD, Hurst JW, eds. *Clinical methods The history, physical, and laboratory examinations*. 3. ed. ed. Boston: Butterworths; 1990: 805.
59. LUCIANO DE, ROY G, LUCIANO AA. Adhesion reformation after laparoscopic adhesiolysis: where, what type, and in whom they are most likely to recur. *Journal of minimally invasive gynecology* 2008; 15(1): 44-8.
60. LYONS EA, TAYLOR PJ, ZHENG XH, BALLARD G, LEVI CS, KREDENTSER JV. Characterization of subendometrial myometrial contractions throughout the menstrual cycle in normal fertile women. *Fertility and sterility* 1991; 55(4): 771-4.
61. MAGGI M, MAGINI A, FISCELLA A, GIANNINI S, FANTONI G, TOFFOLETTI F, et al. Sex steroid modulation of neurohypophysial hormone receptors in human nonpregnant myometrium. *The Journal of clinical endocrinology and metabolism* 1992; 74(2): 385-92.
62. MECHSNER S, BARTLEY J, LODDENKEMPER C, SALOMON DS, STARZINSKI-POWITZ A, EBERT AD. Oxytocin receptor expression in smooth muscle cells of peritoneal endometriotic lesions and ovarian endometriotic cysts. *Fertility and sterility* 2005; 83 Suppl 1: 1220-31.

63. MECHSNER S, SCHWARZ J, THODE J, LODDENKEMPER C, SALOMON DS, EBERT AD. Growth-associated protein 43-positive sensory nerve fibers accompanied by immature vessels are located in or near peritoneal endometriotic lesions. *Fertility and sterility* 2007; 88(3): 581-7.
64. MECHSNER S, KAISER A, KOPF A, GERICKE C, EBERT A, BARTLEY J. A pilot study to evaluate the clinical relevance of endometriosis-associated nerve fibers in peritoneal endometriotic lesions. *Fertility and sterility* 2009; 92(6): 1856-61.
65. MECHSNER S, GRUM B, GERICKE C, LODDENKEMPER C, DUDENHAUSEN JW, EBERT AD. Possible roles of oxytocin receptor and vasopressin-1alpha receptor in the pathomechanism of dysperistalsis and dysmenorrhea in patients with adenomyosis uteri. *Fertility and sterility* 2010; 94(7): 2541-6.
66. MEYER R. Adenomyosis, Adenofibrosis und Adenomyom. In: Stoeckel W, ed. *Handbuch der Gynäkologie*. München: J.F Bergmann; 1930: 356-669.
67. MOON YS, LEUNG PC, YUEN BH, GOMEL V. Prostaglandin F in human endometriotic tissue. *American journal of obstetrics and gynecology* 1981; 141(3): 344-5.
68. NISHIDA M. Relationship between the onset of dysmenorrhea and histologic findings in adenomyosis. *American journal of obstetrics and gynecology* 1991; 165(1): 229-31.
69. OTA H, IGARASHI S, SASAKI M, TANAKA T. Distribution of cyclooxygenase-2 in eutopic and ectopic endometrium in endometriosis and adenomyosis. *Human reproduction (Oxford, England)* 2001; 16(3): 561-6.
70. PARKER JD, SINAII N, SEGARS JH, GODOY H, WINKEL C, STRATTON P. Adhesion formation after laparoscopic excision of endometriosis and lysis of adhesions. *Fertility and sterility* 2005; 84(5): 1457-61.
71. PARKER JD, LEONDIRES M, SINAII N, PREMKUMAR A, NIEMAN LK, STRATTON P. Persistence of dysmenorrhea and nonmenstrual pain after optimal endometriosis surgery may indicate adenomyosis. *Fertility and sterility* 2006; 86(3): 711-5.
72. PERIC H, FRASER IS. The symptomatology of adenomyosis. *Best practice & research Clinical obstetrics & gynaecology* 2006; 20(4): 547-55.
73. PLOGHAUS A, NARAIN C, BECKMANN CF, CLARE S, BANTICK S, WISE R, et al. Exacerbation of pain by anxiety is associated with activity in a hippocampal network. *The Journal of neuroscience : the official journal of the Society for Neuroscience* 2001; 21(24): 9896-903.
74. PRENDERGAST SA, WEISS JM. Screening for musculoskeletal causes of pelvic pain. *Clinical obstetrics and gynecology* 2003; 46(4): 773-82.
75. SNOO K. *Das Problem der Menschwerdung im Lichte der vergleichenden Geburtshilfe*. 4 ed. Jena: Fischer; 1942.
76. STEINWALL M, BOSSMAR T, GAUD C, AKERLUND M. Inhibitory effects of SR 49059 on oxytocin- and vasopressin-induced uterine contractions in non-pregnant women. *Acta obstetrica et gynecologica Scandinavica* 2004; 83(1): 12-8.
77. STEINWALL M, AKERLUND M, BOSSMAR T, NISHII M, WRIGHT M. ONO-8815Ly, an EP2 agonist that markedly inhibits uterine contractions in women. *BJOG : an international journal of obstetrics and gynaecology* 2004; 111(2): 120-4.
78. STROMBERG P, AKERLUND M, FORSLING ML, GRANSTROM E, KINDAHL H. Vasopressin and prostaglandins in premenstrual pain and primary dysmenorrhea. *Acta obstetrica et gynecologica Scandinavica* 1984; 63(6): 533-8.
79. SWANK DJ, VAN ERP WFM, REPELAER VAN DRIEL OJ, HOP WCJ, BONJER HJ, JEEKEL H. A prospective analysis of predictive factors on the results of laparoscopic adhesiolysis in patients with chronic abdominal pain. *Surgical laparoscopy, endoscopy & percutaneous techniques* 2003; 13(2): 88-94.
80. TOKUSHIGE N, MARKHAM R, RUSSELL P, FRASER IS. Nerve fibres in peritoneal endometriosis. *Human reproduction (Oxford, England)* 2006; 21(11): 3001-7.
81. TUTTLIES F, KECKSTEIN J, ULRICH U, POSSOVER M, SCHWEPPE KW, WUSTLICH M, et al. ENZIAN-score, a classification of deep infiltrating endometriosis. *Zentralblatt fur Gynakologie* 2005; 127(5): 275-81.
82. VERCELLINI P. Endometriosis: what a pain it is. *Seminars in reproductive endocrinology* 1997; 15(3): 251-61.
83. VERCELLINI P, TRESPIDI L, GIORGI O, CORTESI I, PARAZZINI F, CROSIGNANI PG. Endometriosis and pelvic pain: relation to disease stage and localization. *Fertility and sterility* 1996; 65(2): 299-304.
84. VERCELLINI P, SOMIGLIANA E, DAGUATI R, VIGANO P, MERONI F, CROSIGNANI PG. Postoperative oral contraceptive exposure and risk of endometrioma recurrence. *American journal of obstetrics and gynecology* 2008; 198(5): 504.e1-5.
85. VERCELLINI P, SOMIGLIANA E, VIGANO P, ABBIATI A, BARBARA G, FEDELE L. Chronic pelvic pain in women: etiology, pathogenesis and diagnostic approach. *Gynecological endocrinology : the official journal of the International Society of Gynecological Endocrinology* 2009; 25(3): 149-58.
86. VERCELLINI P, SOMIGLIANA E, CONSONNI D, FRATTARUOLO MP, DE GIORGI O, FEDELE L. Surgical versus medical treatment for endometriosis-associated severe deep dyspareunia. I. Effect on pain during intercourse and patient satisfaction. *Hum Reprod* 2012; 27(12): 3450-9.
87. VERNON MW, BEARD JS, GRAVES K, WILSON EA. Classification of endometriotic implants by morphologic appearance and capacity to synthesize prostaglandin F. *Fertility and sterility* 1986; 46(5): 801-6.
88. VRIES K, LYONS EA, BALLARD G, LEVI CS, LINDSAY DJ. Contractions of the inner third of the myometrium. *American journal of obstetrics and gynecology* 1990; 162(3): 679-82.
89. WU M-H, SUN HS, LIN C-C, HSIAO K-Y, CHUANG P-C, PAN H-A, et al. Distinct mechanisms regulate cyclooxygenase-1 and -2 in peritoneal macrophages of women with and without endometriosis. *Molecular human reproduction* 2002; 8(12): 1103-10.

## 4.3

## Laparoscopic Surgery for Treatment of Endometriosis-Associated Pelvic Pain Including the Role of Presacral Neurectomy

Alan Lam<sup>a</sup> | Ted Lee<sup>b</sup>

### 4.3.1 Background

Endometriosis, characterised by the finding of endometrial-like tissue outside the uterus, is one of the most common gynaecological conditions associated with chronic pelvic pain amongst women of reproductive age.<sup>9</sup> In the evaluation of the role of laparoscopic surgery for the treatment of endometriosis-associated pain, it is appropriate to be reminded that pain is complex, subjective and variable. As such, it is fundamental to apply the definition of pain as suggested by the *International Association for the Study of Pain* (IASP) that defines pain as an unpleasant sensory and emotional subjective experience associated with actual or potential tissue damage.<sup>13</sup> While pain that resolves quickly is called acute, chronic pain refers to pain that continues beyond the expected healing time, traditionally accepted as beyond 6 months duration. *Chronic pelvic pain* (CPP) refers to non-cyclic pain that localizes to the anatomic pelvis, the anterior abdominal wall, the lumbosacral back or buttocks, of sufficient severity to cause functional disability or lead to medical care.<sup>3</sup>

The association between endometriosis and chronic pelvic pain is suggested by epidemiological studies which have found prevalence of endometriosis ranging from 30 to 90% amongst women undergoing laparoscopy for evaluation of chronic pelvic pain compared to 5% of those who do not have infertility or CPP.<sup>12</sup> This association is further supported by studies which have found surgical treatment of endometriosis is associated with significant improvement in CPP.<sup>1,23</sup> However, the relationship between pain and endometriosis is not clear cut as endometriotic lesions have been detected in up to 43% of asymptomatic women.<sup>20</sup>

This chapter aims to review the current understanding of the mechanisms, the neuroanatomical basis, the role and outcomes of surgical treatment and finally the role of presacral neurectomy for endometriosis-associated pelvic pain.

### 4.3.2 How Does Endometriosis Cause Pain?

The mechanisms by which endometriosis causes pain are complex and still not fully understood. Current evidence suggests that endometriosis-associated pain most likely arises through nociceptive, inflammatory and neuropathic pathways as a result of direct effects of cyclical active bleeding from endometriotic implants and indirect effects involving the production of cytokines and nerve growth factors by endometriotic cells and activated macrophages which activate silent nociceptors, stimulate and irritate neuronal ingrowth into nerve endings of pelvic floor nerves especially in the pouch of Douglas and the areas of the uterosacral ligaments.<sup>12</sup>

Pain associated with endometriosis varies from person to person and may encompass a variable and fluctuating constellation of dysmenorrhea, dyspareunia and non-menstrual chronic abdominal and pelvic pain with the sentinel symptom being dysmenorrhea.<sup>10,22</sup> Another puzzling aspect of endometriosis-associated pain is that the association between endometriosis stage and severity of pelvic symptoms is marginal and inconsistent making it difficult to evaluate pain as an outcome following surgical treatment of endometriosis.<sup>25–27</sup>

### 4.3.3 Neuro-Anatomical Innervation and Sensory Pathways for Pelvic Viscera

The pelvic viscera are innervated by both parasympathetic and sympathetic nerves that lie in the retroperitoneal space. They reach the pelvic organs via the superior hypogastric plexus (a single ganglionic midline plexus) which divides into the hypogastric nerves (two nerve trunks without ganglia) that connect with the inferior hypogastric plexus.<sup>7</sup>

The inferior hypogastric plexus is a mesh-like network of nerves that is formed by parasympathetic fibres from the pelvic splanchnic nerves from the second, third and fourth sacral segments and sympathetic fibres and sensory nerve fibres from the superior hypogastric plexus (SHP). The superior hypogastric plexus (also known as presacral nerve) lies within the connective tissues of the retroperitoneal space ventrally to the aorta and its bifurcation, the middle sacral vessels, left common iliac vein in front of the fifth lumbar vertebra and between the common iliac arteries. It consists of sympathetic fibres from the abdominal aortic plexus, bilateral lumbar splanchnic nerves, and parasympathetic fibres from the inferior hypogastric plexus, and afferent sensory nerve fibres from the pelvic viscera. To the right of the SHP lies the right ureter and common iliac vein and artery, to the left the sigmoid colon, inferior mesenteric vessels and the left ureter<sup>16</sup> (Fig. 4.6).

<sup>a</sup> MD; Associate Professor, Director of Centre for Advanced Reproductive Endosurgery (CARE), Sydney Medical School, Australia

<sup>b</sup> MD, Director, Minimally Invasive Gynecologic Surgery, Magee Women's Hospital, University of Pittsburgh Medical Center, Pittsburgh, USA

#### Corresponding author:

#### Alan Lam

Associate Professor, Northern Clinical School, Sydney Medical School  
Director, Director of Centre for Advanced Reproductive Endosurgery (CARE)

Level 4, Suite 407, AMA House

69 Christie Street, St Leonards NSW 2065

Australia

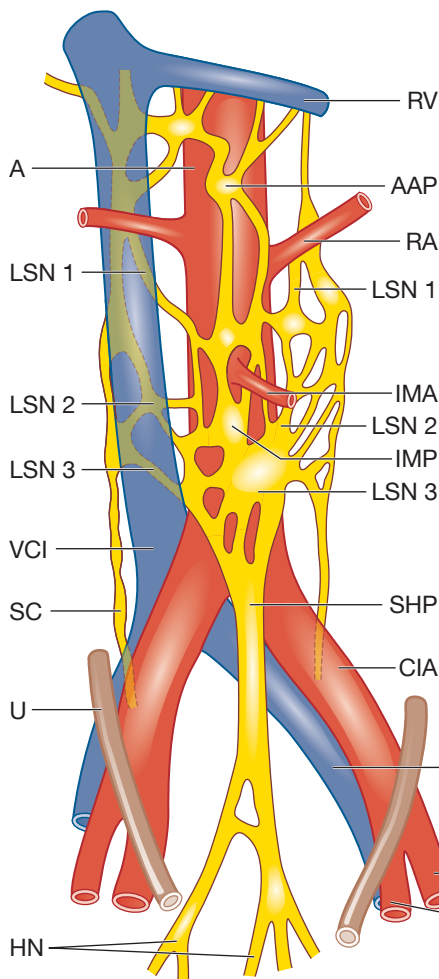
E-mail: alanlam@sydneycare.com.au



Pain impulses from the uterus, cervix, upper vagina and inner third of fallopian tubes travel via the inferior hypogastric plexuses through the hypogastric nerves to the superior hypogastric plexus. Pain impulses from the ovary and the outer two-thirds of the fallopian tubes travel via the plexus of nerves that accompany the ovarian vessels to the renal plexus.<sup>19</sup> In a series of 30 cadaveric dissections, Curtis et al. found that the superior hypogastric plexus is a single trunk in only 20% of the anatomical dissections, 75% of the time on the left, 25% in the midline and none on the right.<sup>6</sup>

#### 4.3.4 The Role of Surgery in the Treatment of Endometriosis-Associated Pain

Apart from its irrefutable diagnostic value, laparoscopic surgery has potential therapeutic benefits in improving pelvic pain by removing all visible endometriotic lesions and associated



**Fig. 4.6** Schematic representation of the superior hypogastric plexus and its neural in- and outflow structures.

##### Key to acronyms:

abdominal aorta (A); renal vein (RV); abdominal aortic plexus (AAP); renal artery (RA); lumbar splanchnic nerve (LSN); inferior mesenteric artery (IMA); inferior mesenteric plexus (IMP); vena cava inferior (VCI); sympathetic chain (SC); SHP: superior hypogastric plexus; common iliac artery (CIA); common iliac vein (CIV); ureter (U); hypogastric nerves (HN); external iliac artery (EIA); internal iliac artery (IIA). The schematic representation was adapted based on the following source: A.C. Kraima et al.<sup>16</sup>

adhesions, repairing damage or trauma to the affected organs and re-establishing normal pelvic and reproductive organ anatomy.<sup>18</sup>

In the 2009 Cochrane review by *Jacobson et al.* which assessed the efficacy of laparoscopic surgery in the treatment of pelvic pain associated with endometriosis, a total of 246 participants in five studies were included in the meta-analysis.<sup>15</sup> The authors concluded that laparoscopic surgery results in improved pain outcomes when compared to diagnostic laparoscopy alone but were unable to draw conclusions from the meta-analysis which specific laparoscopic surgical intervention is most effective.

In the 2014 Cochrane review by *Duffy et al.* which assessed the effectiveness of laparoscopic surgery in the treatment of pain associated with endometriosis, the authors identified 10 randomised controlled trials which included five RCTs comparing laparoscopic ablation or excision versus diagnostic laparoscopy only, two RCTs comparing laparoscopic excision versus diagnostic laparoscopy only, two RCTs comparing laparoscopic excision versus ablation and one RCT which compared laparoscopic ablation versus diagnostic laparoscopy and injectable gonadotropin-releasing hormone analogue (goserelin) with add-back therapy. The authors concluded that there was moderate quality evidence that showed laparoscopic surgery was associated with decreased overall pain (measured as 'pain better or improved') compared with diagnostic laparoscopy, both at six months and at 12 months.<sup>8</sup>

On the other hand, *Abbott et al.* found that surgery is associated with a 30% placebo response that is not dependent on the severity of the disease. They also found that 20% of women do not report an improvement after surgery.<sup>1</sup> Furthermore, a number of observational studies have found up to 24% cumulative risk of recurrent dysmenorrhoea and risk of further surgery up to 36% at 5 year follow-up.<sup>2,24</sup>

While current RCTs have failed to demonstrate clear benefits of excision over ablation, a recent RCT by Healy found a significantly greater reduction in dyspareunia VAS scores in the excision group and a higher use of medical treatments amongst the ablation group. It is also generally recommended to excise endometriosis lesions where possible, especially deep endometriotic lesions.<sup>11</sup>

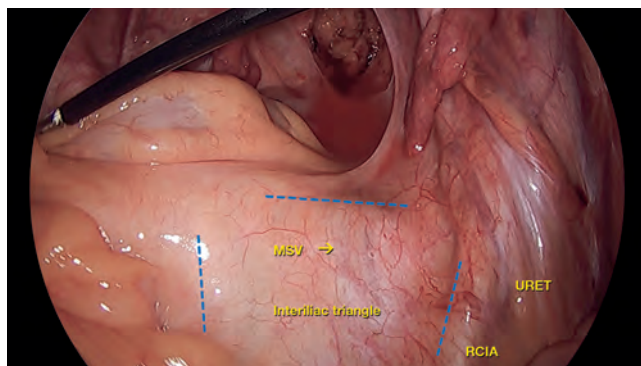
#### 4.3.5 The Role of Presacral Neurectomy (PSN)

Presacral neurectomy, first described by *Jaboulay*<sup>14</sup> in France and *Ruggi*<sup>21</sup> in Italy in 1899, is a surgical procedure in which the surgeon sets out to remove the sensory nerve fibres innervating the pelvic viscera in the hope of relieving intractable pelvic pain and dysmenorrhoea. Since the late 1980's, with increasing availability of medical and pain management options ranging from the oral contraceptive pills, NSAIDs, Mirena, progestogens and GnRh analogues, and increasing awareness of the potential unwanted side-effects of pelvic denervation procedures, PSN has become an uncommon surgical procedure, reserved for women with intractable central pelvic pain and dysmenorrhoea.<sup>17,19</sup>

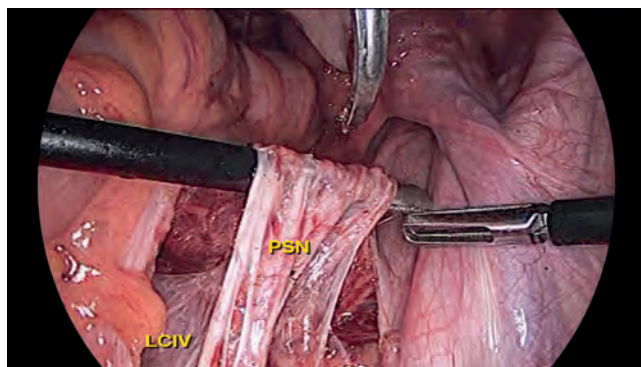
#### 4.3.5.1 Surgical Technique

For a laparoscopic surgeon performing presacral neurectomy, a comprehensive understanding of the presacral vascular anatomy and anatomic landmarks of the procedure is paramount. After surveying the superficial landmarks of surrounding interiliac triangle (Fig. 4.7), a vertical peritoneal incision is made between the sacral promontory and the aortic bifurcation. The peritoneum is elevated and retracted laterally to avoid injury to the underlying vasculature. The first vascular structure parallel to the left peritoneal edge is the rectal branch of the inferior mesenteric artery (IMA). An avascular plane is developed between IMA and presacral nerve to expose the left common iliac vein and artery underneath. IMA is the most relevant anatomic landmark for presacral neurectomy. Crossing over both the left common iliac vein (LCIV) and artery (LCIA), the IMA serves as the left lateral border of the dissection (Fig. 4.8). At times, the left ureter can be seen under and lateral to the IMA, but it is unnecessary to dissect lateral to the IMA to identify the left ureter.

The anatomy on the right side of the presacral dissection is simpler. The right common iliac artery (RCIA) and ureter are anatomic landmarks for the dissection. The fibroadipose tissue is dissected medially off the right common iliac artery. Dissection should remain medial to the right ureter.



**Fig. 4.7** The Cotte's interiliac triangle is an anatomic area defined caudally by the sacral promontory, and the common iliac arteries laterally. Key to acronyms: ureter (URET); right common iliac artery (RCIA); middle sacral vessels (MSV).

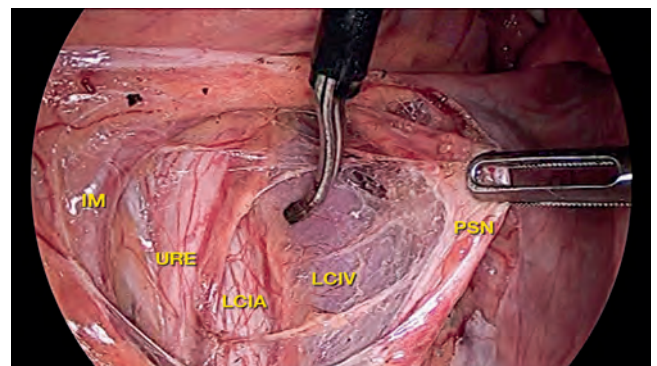


**Fig. 4.9** Presacral nerve elevated off sacral promontory below left common iliac vein. Key to acronyms: left common iliac vein (LCIV); presacral nerve (PSN).

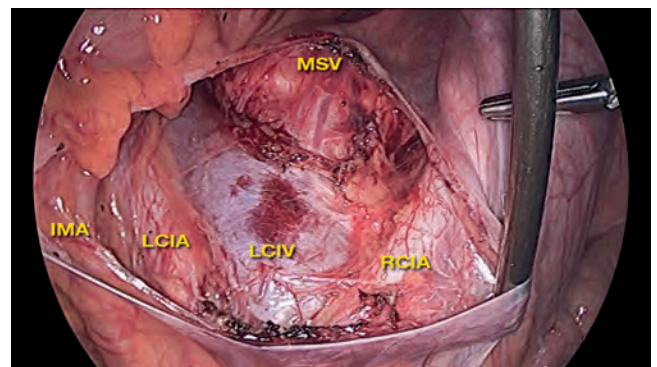
The presacral nerve is desiccated and transected after being elevated off sacral promontory below the lower border of left common iliac vein (Fig. 4.9). Great care should be taken to identify the lower border of the left common iliac vein before any kind of surgical energy source is applied. Once the presacral nerve is transected, it can be reflected cephalad off the left common iliac vein toward the bifurcation of aorta. Middle sacral vessels and left common vein are uncovered underneath after a segment of presacral nerve is transected for pathologic confirmation (Fig. 4.10).

#### 4.3.5.2 Outcomes

In a prospective randomized double-blind controlled trial by *Zullo et al.* involving 141 sexually active women of fertile age with chronic severe dysmenorrhea caused by endometriosis treated with conservative laparoscopic surgery and assigned randomly to not receive or receive presacral neurectomy, the authors defined the cure rate as the percentage of patients who reported an absence of dysmenorrhea or dysmenorrhea that did not require medical treatment at 6 and 12 months after the procedures. The cure rate was significantly higher in the PSN group compared with the non-PSN at a follow-up examination at 6 months (87.3% vs 60.3%) and 12 months (85.7% vs 57.1%). There was no difference in short-term



**Fig. 4.8** Relationship of the inferior mesenteric artery and surrounding structures with retraction of the peritoneal edge. Key to acronyms: inferior mesenteric artery (IMA); ureter (URET); left common iliac artery (LCIA); left common iliac vein (LCIV); presacral nerve (PSN).



**Fig. 4.10** Anatomy after a segment of the presacral nerve has been removed. The char edge on the lower part of the figure is the cephalad end of the transected presacral nerve. Key to acronyms: inferior mesenteric artery (IMA); ureter (URET); left common iliac artery (LCIA); left common iliac vein (LCIV); right common iliac artery (RCIA); middle sacral vessels (MSV).

surgical complications between the two groups, but 3.2% of women in the PSN group experienced temporary urine retention, while 3.3% encountered constipation at 6 months and 14.3% at 12 months.<sup>28</sup> At 2-year follow-up, the same authors found the severity and frequency of dysmenorrhea, dyspareunia, and CPP decreased significantly in both groups ( $P < 0.05$ ) in comparison with baseline values. The severity of dysmenorrhea, dyspareunia, and CPP was significantly ( $P < 0.05$ ) lower in the PSN than in the non-PSN group (83.3% vs. 53.3% cured; RR 1.62).<sup>29</sup>

#### 4.3.5.3 Complications

In one of the largest retrospective series of 655 patients undergoing laparoscopic PSN by *Chen et al.* (2007), the authors reported a 0.6% incidence of major complications which included one injury to the right internal iliac artery, 3 cases of laceration to the middle sacral vein, 3 chylous ascites, and a 74% incidence of postoperative constipation.<sup>5</sup> *Zullo et al.* reported 18% incidence of postoperative constipation, 5% urinary urgency, no urinary retention or sexual dysfunction.<sup>28</sup>

In a prospective observational study by *Chang CY et al.* using a modified method of presacral neurectomy in which the superior hypogastric nerve bundles were transected along the aortic bifurcation, not in the interiliac triangular area in 42 women with severe midline dysmenorrhoea, the authors found 90.5% had a pain score  $< 4$  on a 0 to 10-pain scale with no short-term complications of constipation and voiding dysfunction. The authors postulated that this could be due to the preservation of one sympathetic lumbar branch that joined the superior hypogastric plexus in the interiliac trigone.<sup>4</sup> While uncommon, presacral neurectomy carries potential for both intraoperative and postoperative complications which should be included in preoperative informed consent.

#### 4.3.6 Conclusion

Chronic pelvic pain is a common presenting symptom of endometriosis. The mechanisms responsible for endometriosis-associated pain are complex and may vary from time to time and from person to person. Laparoscopic treatment of endometriosis by excision or ablation has been shown to be effective for relief of endometriosis-associated pain, albeit that there is a gradual cumulative risk of recurrence. There is high-quality evidence demonstrating additional benefits of presacral neurectomy for relief of chronic, intractable central pelvic pain in carefully selected cases with careful consideration of benefits, surgical risks and risk of pelvic organ dysfunction.

#### 4.3.7 References

1. ABBOTT J, HAWE J, HUNTER D, HOLMES M, FINN P, GARRY R. Laparoscopic excision of endometriosis: a randomized, placebo-controlled trial. *Fertil Steril* 2004;82(4):878–84. doi:10.1016/j.fertnstert.2004.03.046.
2. ABBOTT JA, HAWE J, CLAYTON RD, GARRY R. The effects and effectiveness of laparoscopic excision of endometriosis: a prospective study with 2-5 year follow-up. *Hum Reprod* 2003;18(9):1922–7.
3. ACOG PRACTICE BULLETIN NO. 51. Chronic pelvic pain. *Obstet Gynecol* 2004;103(3):589–605.
4. CHANG CY, CHANG WC, HUNG YC, HO M, YEH LS, LIN WC. Comparison of a new modified laparoscopic presacral neurectomy and conventional laparoscopic presacral neurectomy in the treatment of midline dysmenorrhea. *Int J Gynaecol Obstet* 2007;99(1):28–32. doi:10.1016/j.ijgo.2007.03.016.
5. CHEN FP, SOONG YK. The efficacy and complications of laparoscopic presacral neurectomy in pelvic pain. *Obstet Gynecol* 1997;90(6):974–7.
6. CURTIS AH, ANSON BJ, ASHLEY FL, JONES T. The anatomy of the pelvic autonomic nerves in relation to gynecology. *Surg Gynecol Obstet* 1942;73:743–50.
7. DELANCEY J. Surgical anatomy of the female pelvis. In: Jones HW, Rock JA, editors. *Te Linde's operative gynecology*, 9th ed.: Lippincott William & Wilkins; 2003.
8. DUFFY JM, ARAMBAGE K, CORREA FJ, OLIVE D, FARQUHAR C, GARRY R et al. Laparoscopic surgery for endometriosis. *Cochrane Database Syst Rev* 2014;4:CD011031. doi:10.1002/14651858.CD011031.pub2.
9. GIUDICE LC. Clinical practice. Endometriosis. *N Engl J Med* 2010;362(25):2389–98. doi:10.1056/NEJMc1000274.
10. GUO SW, WANG Y. The prevalence of endometriosis in women with chronic pelvic pain. *Gynecol Obstet Invest* 2006;62(3):121–30. doi:10.1159/000093019.
11. HEALEY M, CHENG C, KAUR H. To excise or ablate endometriosis? A prospective randomized double-blinded trial after 5-year follow-up. *J Minim Invasive Gynecol* 2014;21(6):999–1004. doi:10.1016/j.jmig.2014.04.002.
12. HOWARD FM. Endometriosis and mechanisms of pelvic pain. *J Minim Invasive Gynecol* 2009;16(5):540–50. doi:10.1016/j.jmig.2009.06.017.
13. INTERNATIONAL ASSOCIATION FOR THE STUDY OF PAIN. Part III: Pain Terms, A Current List with Definitions and Notes on Usage" (pp 209–214) Classification of Chronic Pain, Second Edition, IASP Task Force on Taxonomy, edited by H. Merskey and N. Bogduk. [30, May 2016]; Available from: <http://www.iasp-pain.org/Taxonomy>.
14. JABOULAY M. Le traitement de la névralgie pelvienne par la paralysie du sympathique sacré. *Lyon Médicien* 90;1899:102–8.
15. JACOBSON TZ, DUFFY JM, BARLOW D, KONINCKX PR, GARRY R. Laparoscopic surgery for pelvic pain associated with endometriosis. *Cochrane Database Syst Rev* 2009(4):CD001300. doi:10.1002/14651858.CD001300.pub2.
16. KRAIMA AC, VAN SCHAIK J, SUSAN S, VAN DE VELDE CJ, HAMMING JF, LAKKE EA et al. New insights in the neuroanatomy of the human adult superior hypogastric plexus and hypogastric nerves. *Auton Neurosci* 2015;189:60–7. doi:10.1016/j.autneu.2015.02.001.
17. KWOK A, LAM A, FORD R. Laparoscopic presacral neurectomy: a review. *Obstet Gynecol Surv* 2001;56(2):99–104.



18. LAM A, et al. Surgical Therapies: Principles and Triage in Endometriosis. In: Giudice L, Evers J, Healy D, editors. *Endometriosis: Science and Practice*: Wiley-Blackwell; 2012. p. 387–95.
19. LEE TT, YANG LC. Pelvic denervation procedures: a current reappraisal. *Int J Gynaecol Obstet* 2008;101(3):304–8. doi:10.1016/j.ijgo.2008.02.010.
20. MOEN MH, STOKSTAD T. A long-term follow-up study of women with asymptomatic endometriosis diagnosed incidentally at sterilization. *Fertil Steril* 2002;78(4):773–6.
21. RUGGI C. La simpatectomia addominale utero-ovarica come mezzo di cura di alcune lesioni interne degli organi genitali della donna. Bologna: Zanichelli; 1899.
22. STRATTON P, BERKLEY KJ. Chronic pelvic pain and endometriosis: translational evidence of the relationship and implications. *Hum Reprod Update* 2011;17(3):327–46. doi:10.1093/humupd/dmq050.
23. SUTTON CJ, EWEN SP, WHITELAW N, HAINES P. Prospective, randomized, double-blind, controlled trial of laser laparoscopy in the treatment of pelvic pain associated with minimal, mild, and moderate endometriosis. *Fertil Steril* 1994;62(4):696–700.
24. VERCELLINI P, FEDELE L, AIMI G, GIORGI O DE, CONSONNI D, CROSIGNANI PG. Reproductive performance, pain recurrence and disease relapse after conservative surgical treatment for endometriosis: the predictive value of the current classification system. *Hum Reprod* 2006;21(10):2679–85. doi:10.1093/humrep/del230.
25. VERCELLINI P, FEDELE L, AIMI G, PIETROPAOLO G, CONSONNI D, CROSIGNANI PG. Association between endometriosis stage, lesion type, patient characteristics and severity of pelvic pain symptoms: a multivariate analysis of over 1000 patients. *Hum Reprod* 2007;22(1):266–71. doi:10.1093/humrep/del339.
26. VERCELLINI P, TRESPIDI L, GIORGI O DE, CORTESI I, PARAZZINI F, CROSIGNANI PG. Endometriosis and pelvic pain: relation to disease stage and localization. *Fertil Steril* 1996;65(2):299–304.
27. WHITESIDE JL, FALCONE T. Endometriosis-related pelvic pain: what is the evidence? *Clin Obstet Gynecol* 2003;46(4):824–30.
28. ZULLO F, PALOMBA S, ZUPI E, RUSSO T, MORELLI M, CAPPIELLO F et al. Effectiveness of presacral neurectomy in women with severe dysmenorrhea caused by endometriosis who were treated with laparoscopic conservative surgery: a 1-year prospective randomized double-blind controlled trial. *Am J Obstet Gynecol* 2003;189(1):5–10.
29. ZULLO F, PALOMBA S, ZUPI E, RUSSO T, MORELLI M, SENA T et al. Long-term effectiveness of presacral neurectomy for the treatment of severe dysmenorrhea due to endometriosis. *J Am Assoc Gynecol Laparosc* 2004;11(1):23–8.

## 4.4

## Postoperative Management of Endometriosis

Gabriele Centini<sup>a</sup> | Antonella Biscione<sup>a</sup> | Lucia Lazzeri<sup>b</sup> | Stefano Luisi<sup>b</sup> | Felice Petraglia<sup>c</sup>**4.4.1 Introduction**

It is well established that good integration of surgical and medical treatment modalities plays a pivotal role in the long-term therapy of endometriosis. In young patients, the endometriosis-related symptoms should be managed medically until there is a definite desire to give birth to a child, unless the symptoms are unresponsive to hormonal drugs. If surgery cannot be postponed, a postoperative hormonal therapy should be administered to reduce the risk of recurrence, however this, indeed, exposes the patient to the risk of re-intervention. Although conservative surgical removal is considered the most effective treatment option, the chronic nature of endometriosis makes a life-long management necessary and involves that medical treatment be utilized to the maximum extent possible in order to avoid recurrence and prevent the need for repeated surgical procedures.<sup>27</sup>

In recent decades, there is a trend for women to delay pregnancy until later in their reproductive period resulting in a high rate of recurrent symptoms after conservative surgery, which is why the authors suggest that patients be counselled on the potential risks of impaired fertility and re-intervention.

The recurrence risk of endometriosis is generally reported to range from 40–50% in a 5-year period with annual rates varying between 10 and 15%<sup>46</sup> (see chapter 4.7 Recurrent endometriosis). When speaking about recurrence, it is necessary to distinguish between endometriomas and deep infiltrating endometriosis. There is a larger number of data available on endometriomas, with recurrence rates varying between 30 and 50% after 2–5-years of follow-up, and analgetic and/or hormonal therapy needed in 50% of patients within 2 years after surgery.<sup>41</sup> Currently, laparoscopy is considered the most effective therapeutic option to surgically treat endometriosis in either its ovarian or deep form, however the way surgery is performed may have an impact on recurrence rates, especially in cases of deep infiltrating endometriosis.

<sup>a</sup> MD, Department of Molecular and Developmental Medicine, University of Siena, Italy

<sup>b</sup> MD, PhD; Department of Molecular and Developmental Medicine, University of Siena, Italy

<sup>c</sup> Professor, MD; Head of Department of Obstetrics and Gynecology, 'Santa Maria alle Scotte' University Policlinic of Siena, Italy

**Corresponding author:****Felice Petraglia**

Professore Ordinario di Ginecologia e Ostetricia Università degli Studi di Siena

Responsabile U.O.C. Ostetricia e Ginecologia

Policlinico "Santa Maria alle Scotte"

V.le M. Bracci, 16 – 53100 Siena, Italia

E-mail: felice.petraglia@unisi.it

Concerning postoperative medical therapy, there are two treatment strategies: an adjunctive short-term and a long-term hormonal treatment. The first one serves as an adjuvant therapy to improve surgical outcomes, but – according to the current ESHRE guidelines – clinicians should be clearly aware that there is no evidence suggesting a short-term (up to 6 months) administration of hormonal drugs for the sole purpose of improving the surgical outcome, whereas these medications should be used for at least 18–24 months to reduce the risk of symptom recurrence.<sup>7</sup> So far, there is only limited data available in the literature on the hormonal therapeutic regimen predominantly adopted in postoperative follow-up care. The decision-making should be guided by patient preferences, costs, therapeutic options available at your facility, and potential side effects. However, increased awareness of the role of prophylaxis in the prevention of recurrent disease and pain symptoms is needed when faced with patients who have a previous history of surgical treatment for endometriosis.

In the clinical management of endometriosis, multiple issues like pain, infertility, and recurrence have to be adequately considered. Although evidence has been provided that postoperative medical therapy is effective in controlling pain and reducing the risk of recurrent disease, the data available to date does not allow to confirm its efficacy in terms of endometriosis-associated infertility. Therefore, clinicians are advised not to prescribe adjunctive hormonal treatment after surgery with the sole therapeutic objective of improving the chance of spontaneous pregnancy.<sup>51</sup>

The long-term medical therapy can only prevent the risk of recurrence as long as the patient is compliant with the prescribed regimen, leaving the risk unchanged after discontinuation.<sup>33</sup> However, one should be clearly aware, that a partial or total relief of symptoms is accomplished in 80–90% of cases in a follow-up period of 2–4 years, however a recurrence of 15% and a re-intervention rate ranging from 7 to 10% should be anticipated in the same period.<sup>2,4</sup>

The recurrence rate seems to be related to both stage of the disease and an incomplete excisional surgery.<sup>32</sup>

**4.4.2 Which Strategy for the Post-Surgery Period?**

The major objectives of medical therapy are as follows:

- Inhibition of ovulation.
- Suppression of menstruation, in turn leading to a steady steroid hormone milieu.

These strategies are essentially geared toward producing a hypoestrogenic environment to reduce the tropism of endometrial lesions or to create a hyperprogestogenic state leading to pseudo-decidualization through administration of

hormonal medication, thus avoiding cyclical changes of the endometrium, which subsequently account for menstruation and inflammation at the ectopic site. Medical treatment of endometriosis is based on the rationale that the ectopic endometrium is modulated by sexual hormones and undergoes the same cyclic changes as the eutopic endometrium.

#### 4.4.3 Which Drugs for the Post-Surgery Period?

Medical management of endometriosis usually involves the use of specific hormonal drugs such as GnRH analogues and GnRH antagonists, oral progestins, vaginal progestins, intrauterine progestins, and oral contraceptives or symptomatic anti-inflammatory drugs. The first medication group acts on the pathophysiological mechanisms of the disease by reducing the progression and recurrence of the lesions while the second group has almost no impact on the underlying disease and is aimed at reducing the inflammatory state arising from menstruation at an ectopic site.

##### 4.4.3.1 Combined Oral Contraceptives

Oral contraceptives (OCs) are among the most widely studied hormonal drugs used to prevent recurrence of endometrioma in patients who do not wish to become pregnant while at the same time appreciating the good tolerability and safety profile of this group of medication.

The principle behind the use of OCs is based on decidualization and atrophic alteration of the endometrium, therefore reducing the amount of menstrual flow at both eutopic and ectopic sites.<sup>6,31</sup> With the use of these drugs, in fact, hormone levels are stabilized which in turn reduces the inflammatory reaction arising from the periodical response to the shedding of menstrual blood. In this way, oral contraceptives act against a potential endometrial implantation outside the uterus and are therefore suited to prevent the risk of recurrent disease.

The short-term treatment (6 months) with OCs has no beneficial effect on endometriosis-related symptoms. *Muzii et al.* reported that no significant difference was revealed in a prospective randomized trial based on 70 patients who were treated by laparoscopic excision of ovarian endometriomas, followed by either postoperative administration of low-dose cyclic oral contraceptives for 6 months or no treatment.<sup>23</sup> After a mean follow-up of 22 months, the recurrence rate was 2.9% (1/35) amongst the treatment group versus 6.1% (2/33) in the no-treatment group. Although the difference was not statistically significant, the effect on moderate-to-severe pain recurrence was 9.1% in the oral contraceptive group versus 17.1% in the control group. Furthermore, the life table analysis showed a lower recurrence rate at 12 months amongst those patients treated postoperatively with OCs, while there was no significant difference between both groups at 24 and 36 months, both in terms of anatomical recurrence and relapse of symptoms.<sup>23</sup> *Koga et al.* confirmed these findings, however it turned out that administration of postoperative medical treatment is not capable of significantly reducing the recurrence rate after a follow-up interval of 2 years.<sup>15</sup>

Unlike short-term medical treatment, long-term administration has been found to prevent recurrence of symptoms until discontinuation of therapy.

In a group of 277 patients followed-up for 24 months, a significantly lower recurrence rate was demonstrated in those women treated with OCs throughout the entire period when compared with the no-treatment group (9% vs 56%; OR: 0.07). Apart from that, the same study suggested a protective effect that may be related to the duration of treatment in patients with discontinued intake of OCs.<sup>47</sup> There is a reduced recurrence in patients treated with postoperative OCs (14.7% vs. 29%) after 24 months of follow-up, with a trend to discover smaller cysts at the time of diagnosis and a decelerated increase in the diameter of the cysts.<sup>29</sup> These findings not only suggest the existence of a protective effect, but may also be interpreted as a retarded progression of disease on account of the postoperative administration of OCs.<sup>31</sup>

The use of OCs cyclical therapy alone does not produce the desired effects on pain symptoms and recurrence irrespective of administration over a long period of time, whereas evidence has been adduced that continuous use of monophasic OCs can control endometriosis-associated recurrent dysmenorrhea.

Long-term continuous administration of OCs was shown to cause a significant reduction in Visual Analogue Scale (VAS) score from 75 to 32 observed at a 2-year follow-up interval in a series of patients who did not experience any clinical benefit from the cyclic use of OCs.<sup>45</sup>

In a recent study based on 311 women surgically treated for ovarian endometrioma, *Serrachioi et al.* revealed that after a 24-month interval, the frequency of recurrent dysmenorrhea was significantly lower in the cyclic (31%) or continuous (4%) OCs group than in the surgery-alone group (40%) and that the benefits of OCs emerged earlier in the continuous OCs group than in the cyclic group (6 vs. 18 months).<sup>30</sup>

A similar trend in favor of the continuous administration was also observed in a recent cohort study that analyzed 356 patients – subjected to laparoscopic treatment for symptomatic endometriosis – with regard to recurrence rates for endometrioma, dysmenorrhea, and non-menstrual pelvic pain (9.4% vs. 20.9%;  $P < 0.05$ ).<sup>49</sup>

Finally, a recent systematic review and meta-analysis by *Muzii et al.* (2016) revealed that a continuous regimen of OC appears to be more efficient than a cyclic regimen in reducing the recurrence rate of dysmenorrhea, reporting a Relative Risk (RR) of 0.24 (95% CI 0.06 to 0.91;  $p = 0.04$ ), but not for chronic pelvic pain and dyspareunia. Furthermore, a trend toward a decline in cyst recurrence rates for a continuous versus cyclic OC regimen was found, with a RR of 0.54 (95% CI 0.28 to 1.05), but statistical significance was not reached ( $p = 0.07$ ).<sup>22</sup>

It can be hypothesized that the potential of continuous OCs treatment to prevent or reduce the recurrence of dysmenorrhea may be attributed to inhibition of menses per se rather than to actual interference with pain mechanisms.<sup>49</sup> It is also interesting to note that the benefit of continuous OCs over



cyclic OC regarding the prevention of lesion recurrence seems to be not as obvious as the prevention of symptom recurrence, suggesting that the pain-relieving effects of continuous OCs may not be directly linked to the pathogenetic mechanisms that account for lesion recurrence.<sup>30</sup> Therefore, the use of continuous oral contraceptive therapy may represent an effective long-term treatment option, that is both safe and tolerated well in women not immediately seeking conception – however with the ultimate therapeutic strategy of giving birth to a child in the long term – in order to limit further harmful effects on future fertility.

#### 4.4.3.2 GnRH Analogs

GnRH analogs (GnRHa) are effective by suppressing estrogen production in the ovaries through a reversible down-regulation of GnRH receptors at pituitary level, causing a profound hypoestrogenism, and, consequently, amenorrhea and a hypotrophic regression of the heterotopic endometrium. They are considered as a second-line treatment option after failure of therapy with OCs/progestins taking into account that the latter are burdened with major side effects limiting long-term administration. GnRHa provide a reduction of symptoms in about 50% of cases, and administration after surgical treatment has been shown to prolong the pain-free interval. The benefits with regard to control of symptoms that can be derived from postoperative administration of GnRH analogs over a 3-month period are reported to last up to 6 months after treatment discontinuation.<sup>13,38</sup> Despite a good reported efficacy, their use must be limited to 3 to 6 months of treatment because of relevant side effects, such as deterioration in the lipid profile, depression, flushes, urogenital atrophy, loss of libido, and bone mass decrease. Moreover the postoperative administration of GnRHa seems to be burdened with a high rate of recurrence of pelvic pain, estimated to be close to 75% at 5 years after withdrawal of therapy.

In order to reduce side effects and to lengthen the maximum permissible duration of GnRHa treatment, an “add-back” therapy – typically given in conjunction with hormone replacement therapy (HRT) – can be adopted to avoid some of the side effects resulting from GnRHa-induced oestrogen deprivation.<sup>36</sup>

The ideal “add-back” therapy should be aimed at minimizing bone loss and inhibit peri-menopausal symptoms whilst maintaining good GnRHa efficacy. In earlier studies, progesterone-only medication has generally been used for “add-back” therapy to avoid oestrogen stimulation of the underlying disease. Administration of medroxyprogesterone acetate (MPA) in conjunction with norethindrone has been demonstrated to be both a safe and effective option that may be used in “add-back” therapy.<sup>52</sup> The suggested use of low-dose oestrogen plus progestin as “add-back” therapy in the treatment of endometriosis has become a hot topic in recent years and other “add-back” treatment options, such as oestrogen receptor modulators, synthetic steroid and tibolone, have been studied with promising results, but further evaluations are needed.<sup>20,37</sup> There are two studies available in the literature evaluating the efficacy of postoperative short-term therapy with GnRHa followed by long-term OCs administration

versus GnRHa alone. Patients receiving cyclic OCs after GnRHa treatment showed a significantly reduced recurrence risk.<sup>17,24</sup> These differences may not be attributed directly to the initial administration of GnRHa, which is why the efficacy of GnRHa therapy prior to OCs still remains questionable.<sup>14</sup>

#### 4.4.3.3 Progestins

Progestins have been used in the treatment of endometriosis for 30 years. Based on the proposed action mechanisms established so far, the mitogenic action and estrogen-induced proliferation are lacking. Initially, progestins cause the endometrium to undergo secretory transformation, followed by decidualization, finally causing atrophy, and thus inducing a state of pseudopregnancy.<sup>48</sup>

##### ■ *Norethindrone acetate*

Norethindrone acetate (NETA) is a 19-nortestosterone derivative that causes hypoestrogenism by suppressing gonadotropins, inhibiting ovulation, and developing amenorrhea with eventual decidualization and atrophy of the endometrium.<sup>34</sup>

NETA is effective in reducing chronic pelvic pain in women with laparoscopically confirmed endometriosis offering various advantages in the long-term treatment of endometriosis such as good control of uterine bleeding, positive effect on calcium metabolism and no negative impact on lipoprotein metabolism at low dosages.<sup>42</sup> NETA is one of the progestins considered to be best suited for the treatment of endometriosis and the US Food and Drug Administration approved its continuous administration for managing endometriosis-related symptoms. In a randomized study based on 90 women with recurrent moderate or severe pelvic pain after conservative surgery for symptomatic rectovaginal endometriosis, efficacy of oral NETA (2.5 mg/day) was compared with that of OCs revealing no differences between the two groups related to control of dysmenorrhea, deep dyspareunia, nonmenstrual pelvic pain, and dyschezia. Low-dose norethindrone acetate is considered an effective, well-tolerated and inexpensive first-choice alternative option to OCs in patients who do not seek conception.<sup>46</sup>

The use of NETA combined with letrozole in a group of 82 women with pain symptoms related to rectovaginal endometriosis showed superiority of the combined regimen over that of NETA alone; however, a higher incidence of adverse effects has been found to be associated with the combined regimen.<sup>10</sup>

##### ■ *Gestrinone and Danazol*

Other progestins have been studied for the treatment of endometriosis-associated pain, but despite good efficacy, they are burdened by excessive side effects that limit their administration.

Gestrinone has been shown to be effective in reducing pain associated with endometriosis through ovarian suppression, leading to atrophy of both endometrium and endometriosis lesions. Gestrinone also has antiprogestinic, antiestrogenic, and androgenic activities that arise from its low specificity for

the progesterone receptor and it has never been used on a large scale in the treatment of endometriosis.<sup>8</sup>

Danazol is a synthetic androgen derivative of 17alpha-ethinyltestosterone, commercially introduced about 45 years ago with a specific indication for the treatment of endometriosis.<sup>11</sup> Its multifactorial biological activity is known to induce a hypoestrogenic-hyperandrogenic state, which is very hostile to endometriotic tissue growth. Several studies have demonstrated the efficacy of danazol in reducing the pain associated with endometriosis.<sup>5</sup> At the beginning of the 1990s, danazol was proven to be as effective as medroxyprogesterone acetate (MPA) in controlling endometriosis symptoms. In fact, poor patient compliance represents the major drawback of danazol as a treatment for endometriosis. The agent has both androgenic and anabolic properties, leading to side effects, such as weight gain, edema, myalgia, acne, oily skin, hirsutism and deepening of the voice.<sup>3</sup> These concerns limit treatment duration to 6 months, and the use of this agent has been in decline in recent years. In a prospective study vaginal administration was proposed as an alternative option to reduce the side effects of danazol treatment. When used postoperatively, danazol (200 mg daily), administered vaginally for 12 months, showed a significant reduction in pain symptoms within a period of 3 months with efficacy lasting for the entire duration of treatment a few side effects.<sup>28</sup>

#### ■ Dienogest

Dienogest is among the progestins most recently approved in the EU for endometriosis, and has been developed to be highly selective for progesterone receptors and produces a powerful progestogenic effect on the endometrium with reduced side effects. Dienogest combines the pharmacological properties of 19-nortestosterone derivatives with those of natural progesterone derivatives. Furthermore, it has beneficial antiandrogenic properties, which cause minimal changes in serum lipid profile and carbohydrate metabolism. The effectiveness of dienogest in the treatment of endometriosis depends on its ability to create a hypoestrogenic and hyperprogestogenic endocrine environment, which, initially, induces decidualization of ectopic endometrial tissue. Subsequently, in the case of prolonged treatments, dienogest causes an atrophy of lesions. It suppresses a rise in estradiol levels by inhibiting growth of ovarian follicles and also has antiproliferative, anti-inflammatory, and antiangiogenic

properties. The optimal dose is 2 mg/day, in the postoperative period, the use of dienogest is well tolerated and associated with less side effects, in particular abnormal uterine bleeding, and it has only a mild effect on loss of bone mineral density (BMD).<sup>16</sup>

When compared against a placebo, dienogest was demonstrated to be significantly more effective in reducing endometriosis-associated pelvic pain and long-term treatment showed a persistent efficacy for up to 24 weeks after treatment discontinuation.<sup>25,35</sup> Similar results were found also when dienogest was compared with triptorelin and buserelin acetate in women with endometriomas diagnosed by laparotomy, laparoscopy, or imaging analysis.<sup>12</sup>

Despite its good efficacy and tolerability in the setting of adjuvant therapy, conclusive data related to prevention of postoperative recurrence are lacking. There is only one RCT that compares dienogest with leuprolide acetate in women with a previous history of laparoscopic intervention. It was demonstrated that both drugs are equivalent in reducing pelvic pain. However, dienogest was shown to be associated with a lower incidence of vasomotor symptoms and a lower impact on bone metabolism than leuprolide acetate, with a minimum change in BMD.

#### 4.4.3.4 Levonorgestrel-releasing intrauterine device (LNG-IUD)

Even though it is beyond controversy that oral progestogens are both effective and inexpensive medications, their efficacy is significantly determined by patient compliance and systemic side effects. Levonorgestrel is a potent steroid that is widely employed in oral contraceptives and subdermally implanted contraceptive devices.

LNG-IUD is a T-shaped intrauterine system, developed as a contraceptive device which releases LNG in the uterine cavity (Fig. 4.11). The effective rate of delivery of LNG from the IUD system is 20 µg per 24 h during the first year, and it slowly decreases throughout the following 5 years of use. The released progestogen induces endometrial atrophy although ovulation is usually not suppressed. This results in hypomenorrhea or amenorrhea and reduced dysmenorrhea. Currently, there is an emerging trend for the use of LNG-IUD in the treatment of endometriosis.<sup>9</sup>

A pilot study showed a great improvement in pain control as well as in the reduction of ultrasonographic dimensions of rectovaginal nodules amongst patients with recurrent moderate or severe dysmenorrhea after conservative surgery for endometriomas or rectovaginal endometriosis.<sup>40</sup> A significant reduction in pain symptoms as well as in the stage of disease was observed in women with minimal to moderate endometriosis confirmed by diagnostic laparoscopy over a period of 6 months after treatment with LNG-IUD.<sup>19</sup>

The use of LNG-IUD after surgical treatment of endometriosis has been studied. The first study compared expectant management with immediate follow-up treatment using LNG-IUD after laparoscopic surgery for symptomatic endometriosis. Twelve months after surgery, dysmenorrhea scores were significantly lower in the LNG-IUD group compared with the

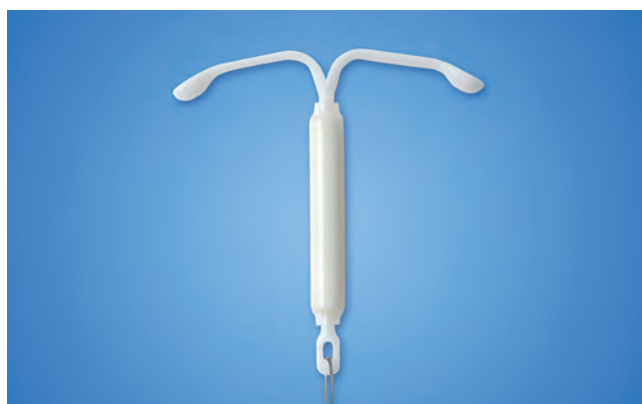

Fig. 4.11 Levonorgestrel-releasing intrauterine device.

expectant management group.<sup>44</sup> The second trial compared the efficacy of an LNG-IUD and a GnRH-agonist in the control of chronic pelvic pain in women with stage I-IV endometriosis during a period of 6 months. Both, the LNG-IUS and the GnRH-analogue were effective in control of endometriosis-associated chronic pelvic pain, although no differences were observed between the two treatments.<sup>26</sup>

The exact mechanism of action of the LNG-IUD is unclear, but LNG-IUD delivers significant amounts of LNG into the peritoneal fluid, and thus has a local effect on the endometriotic implants which may be mediated through estrogen and progesterone receptors, most probably inducing decidualization. As peritoneal fluid levels of LNG were closely related to the levels in serum, this suggests a dominant hematogenous mechanism by which LNG reaches the peritoneal cavity.<sup>18</sup>

A Cochrane systematic review evaluated the postoperative use of LNG-IUDs in women with endometriosis and concluded that, even though there is limited evidence that insertion of an LNG-IUD is capable of significantly reducing the incidence of recurrent painful periods, pain control was similar to that achieved through GnRHa administration.<sup>1</sup> The effectiveness of postoperative LNG-IUS in relieving pain was also demonstrated in a double-blind RCT, which ascertained that at 12 months postoperatively, women in the LNG-IUS group achieved a greater reduction in dysmenorrhea than controls (reduction in dysmenorrhea VAS of 81.0 vs. 50.0 mm;  $P < 0.001$ ).<sup>39</sup>

The use of LNG-IUS reduces the recurrence of postoperative dysmenorrhea. A pilot cohort study confirmed that postoperative administration of LNG-IUS helps prevent recurrence of moderate-to-severe dysmenorrhea when compared with the surgery-only group (10% vs. 45%).<sup>43</sup>

On the other hand, two cohort studies compared the efficacy of LNG-IUD with that of other medications. *Morelli et al.* revealed that – in comparison with the use of LNG-IUD – administration of OC was markedly more effective in reducing the severity of pelvic pain (VAS of 29.0 vs. 19.1 mm;  $P < 0.05$ ) and also with regard to the incidence of disease recurrence (but not significantly), although patient satisfaction was markedly greater in the LNG-IUD group.<sup>21</sup> *Wong et al.* demonstrated that both LNG-IUS and depot medroxyprogesterone acetate (MPA) administered for 3 years after laparoscopy can inhibit recurrence of dysmenorrhea and chronic pelvic pain, however the use of LNG-IUS was shown to yield a slightly higher pain reduction and better compliance.<sup>50</sup>

In conclusion, for women with endometriosis who are in need of long-term treatment, the LNG-IUD may represent a treatment of choice since it permits the same system to be used for at least 5 years with no modifications in estrogen levels and few hypoestrogenic side effects.<sup>26</sup>

In the long term, it is a low-cost therapy with usually fewer side effects than other progestogenic agents. This device could therefore become the treatment of choice for endometriosis-associated chronic pelvic pain in women who do not wish to conceive.

#### 4.4.4 Conclusion

Postoperative medical therapy plays a pivotal role in controlling recurrence of both symptoms and disease. On account of the most recently published research that has contributed to an improved understanding of the pathophysiology of endometriosis, the surgical removal of the disease should be delayed as determined by the patient's desire to conceive, but in cases where surgery cannot be deferred, postoperative hormonal therapy must be prescribed. Nowadays, there are many therapies available to control endometriosis-associated symptoms, however their efficacy and side effects must be matched to the priorities chosen by the patients.

#### 4.4.5 References

1. ABOU-SETTA AM, AL-INANY HG, FARQUHAR CM. Levonorgestrel-releasing intrauterine device (LNG-IUD) for symptomatic endometriosis following surgery. *Cochrane Database Syst Rev* 2006(4):CD005072. doi:10.1002/14651858.CD005072.pub2.
2. ABRAO MS, PETRAGLIA F, FALCONE T, KECKSTEIN J, OSUGA Y, CHAPRON C. Deep endometriosis infiltrating the recto-sigmoid: critical factors to consider before management. *Hum Reprod Update* 2015;21(3):329–39. doi:10.1093/humupd/dmv003.
3. BIBEROGLU KO, BEHRMAN SJ. Dosage aspects of danazol therapy in endometriosis: short-term and long-term effectiveness. *Am J Obstet Gynecol* 1981;139(6):645–54.
4. CENTINI G, AFORS K, MURTADA R, IM ARGAY, LAZZERI L, AKLADIOS CY et al. Impact of Laparoscopic Surgical Management of Deep Endometriosis on Pregnancy Rate. *J Minim Invasive Gynecol* 2016;23(1):113–9. doi:10.1016/j.jmig.2015.09.015.
5. CROSIGNANI P, OLIVE D, BERGQVIST A, LUCIANO A. Advances in the management of endometriosis: an update for clinicians. *Hum Reprod Update* 2006;12(2):179–89. doi:10.1093/humupd/dmi049.
6. DAVIS L, KENNEDY SS, MOORE J, PRENTICE A. Oral contraceptives for pain associated with endometriosis. *Cochrane Database Syst Rev* 2007(3):CD001019. doi:10.1002/14651858.CD001019.pub2.
7. DUNSELMAN GA, VERMEULEN N, BECKER C, CALHAZ-JORGE C, D'HOOGE T, BIE B DE et al. ESHRE guideline: management of women with endometriosis. *Hum Reprod* 2014;29(3):400–12. doi:10.1093/humrep/det457.
8. FEDELE L, BIANCHI S, VIEZZOLI T, ARCAINI L, CANDIANI GB. Gestrinone versus danazol in the treatment of endometriosis. *Fertil Steril* 1989;51(5):781–5.
9. FEDELE L, BIANCHI S, ZANCONATO G, PORTUESE A, RAFFAELLI R. Use of a levonorgestrel-releasing intrauterine device in the treatment of rectovaginal endometriosis. *Fertil Steril* 2001;75(3):485–8.
10. FERRERO S, CAMERINI G, SERACCHIOLI R, RAGNI N, VENTURINI PL, REMORGIDA V. Letrozole combined with norethisterone acetate compared with norethisterone acetate alone in the treatment of pain symptoms caused by endometriosis. *Hum Reprod* 2009;24(12):3033–41. doi:10.1093/humrep/dep302.
11. GREENBLATT RB, DMOWSKI WP, MAHESH VB, SCHOLER HF. Clinical studies with an antigonadotropin-Danazol. *Fertil Steril* 1971;22(2):102–12.
12. HARADA T, MOMOEDA M, TAKETANI Y, ASO T, FUKUNAGA M, HAGINO H et al. Dienogest is as effective as intranasal buserelin acetate for the relief of pain symptoms associated with endometriosis – a randomized, double-blind, multicenter, controlled trial. *Fertil Steril* 2009;91(3):675–81. doi:10.1016/j.fertnstert.2007.12.080.



13. HORNSTEIN MD, YUZPE AA, BURRY KA, HEINRICHS LR, BUTTRAM VL JR, ORWOLL ES. Prospective randomized double-blind trial of 3 versus 6 months of nafarelin therapy for endometriosis associated pelvic pain. *Fertil Steril* 1995;63(5): 955–62.
14. KOGA K, TAKAMURA M, FUJII T, OSUGA Y. Prevention of the recurrence of symptom and lesions after conservative surgery for endometriosis. *Fertil Steril* 2015;104(4):793–801. doi:10.1016/j.fertnstert.2015.08.026.
15. KOGA K, TAKEMURA Y, OSUGA Y, YOSHINO O, HIROTA Y, HIRATA T et al. Recurrence of ovarian endometrioma after laparoscopic excision. *Hum Reprod* 2006;21(8):2171–4. doi:10.1093/humrep/del125.
16. KÖHLER G, FAUSTMANN TA, GERLINGER C, SEITZ C, MUECK AO. A dose-ranging study to determine the efficacy and safety of 1, 2, and 4mg of dienogest daily for endometriosis. *Int J Gynaecol Obstet* 2010;108(1):21–5. doi:10.1016/j.ijgo.2009.08.020.
17. LEE DY, BAE DS, YOON BK, CHOI D. Post-operative cyclic oral contraceptive use after gonadotrophin-releasing hormone agonist treatment effectively prevents endometrioma recurrence. *Hum Reprod* 2010;25(12):3050–4. doi:10.1093/humrep/deq279.
18. LOCKHAT FB, EMEBOLU JE, KONJE JC. Serum and peritoneal fluid levels of levonorgestrel in women with endometriosis who were treated with an intrauterine contraceptive device containing levonorgestrel. *Fertil Steril* 2005;83(2):398–404. doi:10.1016/j.fertnstert.2004.07.961.
19. LOCKHAT FB, EMEBOLU JO, KONJE JC. The evaluation of the effectiveness of an intrauterine-administered progestogen (levonorgestrel) in the symptomatic treatment of endometriosis and in the staging of the disease. *Hum Reprod* 2004;19(1):179–84.
20. LONG QQ, ZHANG SF, HAN Y, CHEN H, LI XL, HUA KQ et al. Clinical efficacy and safety of gonadotropin releasing hormone agonist combined with estrogen-dydrogesteronea in treatment of endometriosis. *Zhonghua Fu Chan Ke Za Zhi* 2010;45(4):247–51.
21. MORELLI M, SACCHINELLI A, VENTURELLA R, MOCCIARO R, ZULLO F. Postoperative administration of dienogest plus estradiol valerate versus levonorgestrel-releasing intrauterine device for prevention of pain relapse and disease recurrence in endometriosis patients. *J Obstet Gynaecol Res* 2013;39(5):985–90. doi:10.1111/jog.12030.
22. MUZZI L, DI TUCCI C, ACHILLI C, DI DONATO V, MUSELLA A, PALAIA I et al. Continuous versus cyclic oral contraceptives after laparoscopic excision of ovarian endometriomas: a systematic review and metaanalysis. *Am J Obstet Gynecol* 2016;214(2): 203–11. doi:10.1016/j.ajog.2015.08.074.
23. MUZZI L, MARANA R, CARUANA P, CATALANO GF, MARGUTTI F, PANICI PB. Postoperative administration of monophasic combined oral contraceptives after laparoscopic treatment of ovarian endometriomas: a prospective, randomized trial. *Am J Obstet Gynecol* 2000;183(3):588–92. doi:10.1067/mob.2000.106817.
24. PARK HJ, KOO YA, YOON BK, CHOI D. Postoperative long-term maintenance therapy with oral contraceptives after gonadotropin-releasing hormone analog treatment in women with ovarian endometrioma. *J Minim Invasive Gynecol* 2009;16(1):34–9. doi:10.1016/j.jmig.2008.09.582.
25. PETRAGLIA F, HORNUNG D, SEITZ C, FAUSTMANN T, GERLINGER C, LUISI S et al. Reduced pelvic pain in women with endometriosis: efficacy of long-term dienogest treatment. *Arch Gynecol Obstet* 2012;285(1):167–73. doi:10.1007/s00404-011-1941-7.
26. PETTA CA, FERRIANI RA, ABRÃO MS, HASSAN D, ROSA ESJ, PODGAEC S et al. Randomized clinical trial of a levonorgestrel-releasing intrauterine system and a depot GnRH analogue for the treatment of chronic pelvic pain in women with endometriosis. *Hum Reprod* 2005;20(7):1993–8. doi:10.1093/humrep/deh869.
27. PRACTICE COMMITTEE OF AMERICAN SOCIETY FOR REPRODUCTIVE MEDICINE. Treatment of pelvic pain associated with endometriosis. *Fertil Steril* 2008;90(5 Suppl):S260–9. doi:10.1016/j.fertnstert.2008.08.057.
28. RAZZI S, LUISI S, CALONACI F, ALTOMARE A, BOCCHI C, PETRAGLIA F. Efficacy of vaginal danazol treatment in women with recurrent deeply infiltrating endometriosis. *Fertil Steril* 2007;88(4):789–94. doi:10.1016/j.fertnstert.2006.12.077.
29. SERACCHIOLI R, MABROUK M, FRASCA C, MANUZZI L, MONTANARI G, KERAMYDA A et al. Long-term cyclic and continuous oral contraceptive therapy and endometrioma recurrence: a randomized controlled trial. *Fertil Steril* 2010;93(1): 52–6. doi:10.1016/j.fertnstert.2008.09.052.
30. SERACCHIOLI R, MABROUK M, FRASCA C, MANUZZI L, SAVELLI L, VENTUROLI S. Long-term oral contraceptive pills and postoperative pain management after laparoscopic excision of ovarian endometrioma: a randomized controlled trial. *Fertil Steril* 2010;94(2):464–71. doi:10.1016/j.fertnstert.2009.03.083.
31. SERACCHIOLI R, MABROUK M, MANUZZI L, VICENZI C, FRASCA C, ELMAKKY A et al. Post-operative use of oral contraceptive pills for prevention of anatomical relapse or symptom-recurrence after conservative surgery for endometriosis. *Hum Reprod* 2009;24(11):2729–35. doi:10.1093/humrep/dep259.
32. SIBIUDE J, SANTULLI P, MARCELLIN L, BORGHESE B, DOUSSET B, CHAPRON C. Association of history of surgery for endometriosis with severity of deeply infiltrating endometriosis. *Obstet Gynecol* 2014;124(4):709–17. doi:10.1097/AOG.0000000000000464.
33. SOMIGLIANA E, VERCELLINI P, VIGANO P, BENAGLIA L, BUSNELLI A, FEDELE L. Postoperative medical therapy after surgical treatment of endometriosis: from adjuvant therapy to tertiary prevention. *J Minim Invasive Gynecol* 2014;21(3):328–34. doi:10.1016/j.jmig.2013.10.007.
34. STANCZYK FZ, ROY S. Metabolism of levonorgestrel, norethindrone, and structurally related contraceptive steroids. *Contraception* 1990;42(1):67–96.
35. STROWITZKI T, FAUSTMANN T, GERLINGER C, SEITZ C. Dienogest in the treatment of endometriosis-associated pelvic pain: a 12-week, randomized, double-blind, placebo-controlled study. *Eur J Obstet Gynecol Reprod Biol* 2010;151(2):193–8. doi:10.1016/j.ejogrb.2010.04.002.
36. SURREY ES. Gonadotropin-releasing hormone agonist and add-back therapy: what do the data show? *Curr Opin Obstet Gynecol* 2010;22(4):283–8. doi:10.1097/GCO.0b013e32833b35a7.
37. SURREY ES, GAMBONE JC, LU JK, JUDD HL. The effects of combining norethindrone with a gonadotropin-releasing hormone agonist in the treatment of symptomatic endometriosis. *Fertil Steril* 1990;53(4):620–6.
38. SURREY ES, HORNSTEIN MD. Prolonged GnRH agonist and add-back therapy for symptomatic endometriosis: long-term follow-up. *Obstet Gynecol* 2002;99(5 Pt 1):709–19.
39. TANMAHASAMUT P, RATTANACHAIYANONT M, ANGSUWATHANA S, TECHATRAISAK K, INDHAVIVADHANA S, LEERASIRI P. Postoperative levonorgestrel-releasing intrauterine system for pelvic endometriosis-related pain: a randomized controlled trial. *Obstet Gynecol* 2012;119(3):519–26. doi:10.1097/AOG.0b013e32824264c3.

40. VERCELLINI P, AIMI G, PANAZZA S, GIORGI O DE, PESOLE A, CROSIGNANI PG. A levonorgestrel-releasing intrauterine system for the treatment of dysmenorrhea associated with endometriosis: a pilot study. *Fertil Steril* 1999;72(3):505–8.
41. VERCELLINI P, CROSIGNANI PG, ABBIATI A, SOMIGLIANA E, VIGANO P, FEDELE L. The effect of surgery for symptomatic endometriosis: the other side of the story. *Hum Reprod Update* 2009;15(2):177–88. doi:10.1093/humupd/dmn062.
42. VERCELLINI P, FEDELE L, PIETROPAOLO G, FRONTINO G, SOMIGLIANA E, CROSIGNANI PG. Progestogens for endometriosis: forward to the past. *Hum Reprod Update* 2003;9(4):387–96.
43. VERCELLINI P, FRONTINO G, GIORGI O DE, AIMI G, ZAINA B, CROSIGNANI PG. Comparison of a levonorgestrel-releasing intrauterine device versus expectant management after conservative surgery for symptomatic endometriosis: a pilot study. *Fertil Steril* 2003;80(2):305–9.
44. VERCELLINI P, FRONTINO G, GIORGI O DE, AIMI G, ZAINA B, CROSIGNANI PG. Comparison of a levonorgestrel-releasing intrauterine device versus expectant management after conservative surgery for symptomatic endometriosis: a pilot study. *Fertil Steril* 2003;80(2):305–9.
45. VERCELLINI P, FRONTINO G, GIORGI O DE, PIETROPAOLO G, PASIN R, CROSIGNANI PG. Continuous use of an oral contraceptive for endometriosis-associated recurrent dysmenorrhea that does not respond to a cyclic pill regimen. *Fertil Steril* 2003;80(3):560–3.
46. VERCELLINI P, PIETROPAOLO G, GIORGI O DE, PASIN R, CHIODINI A, CROSIGNANI PG. Treatment of symptomatic rectovaginal endometriosis with an estrogen-progestogen combination versus low-dose norethindrone acetate. *Fertil Steril* 2005;84(5):1375–87. doi:10.1016/j.fertnstert.2005.03.083.
47. VERCELLINI P, SOMIGLIANA E, DAGUATI R, VIGANO P, MERONI F, CROSIGNANI PG. Postoperative oral contraceptive exposure and risk of endometrioma recurrence. *Am J Obstet Gynecol* 2008;198(5):504.e1–5. doi:10.1016/j.ajog.2007.11.010.
48. VIERIKKO P, KAUPPILA A, RONNBERG L, VIHKO R. Steroidal regulation of endometriosis tissue: lack of induction of 17 beta-hydroxysteroid dehydrogenase activity by progesterone, medroxyprogesterone acetate, or danazol. *Fertil Steril* 1985;43(2):218–24.
49. VLAHOS N, VLACHOS A, TRIANTAFYLLOU O, VITORATOS N, CREATSAS G. Continuous versus cyclic use of oral contraceptives after surgery for symptomatic endometriosis: a prospective cohort study. *Fertil Steril* 2013;100(5):1337–42. doi:10.1016/j.fertnstert.2013.07.008.
50. WONG AY, TANG LC, CHIN RK. Levonorgestrel-releasing intrauterine system (Mirena) and Depot medroxyprogesterone acetate (Depoprovera) as long-term maintenance therapy for patients with moderate and severe endometriosis: a randomised controlled trial. *Aust N Z J Obstet Gynaecol* 2010;50(3):273–9. doi:10.1111/j.1479-828X.2010.01152.x.
51. YAP C, FURNESS S, FARQUHAR C. Pre and post operative medical therapy for endometriosis surgery. *Cochrane Database Syst Rev* 2004(3):CD003678. doi:10.1002/14651858.CD003678.pub2.
52. ZUPI E, MARCONI D, SBRACIA M, ZULLO F, VIVO B DE, EXACUSTOS C et al. Add-back therapy in the treatment of endometriosis-associated pain. *Fertil Steril* 2004;82(5):1303–8. doi:10.1016/j.fertnstert.2004.03.062.

Nucelio L. B. M. Lemos<sup>a</sup> | Marta Maria Kemp<sup>b</sup> | Augusta Morgado Ribeiro<sup>b</sup> | Mauricio S. Abrão<sup>c</sup>

### 4.5.1 Introduction

The radical laparoscopic resection of deeply infiltrating endometriosis (DIE) of the posterior compartment of the pelvis with or without segmental bowel resection is long known<sup>27</sup> and has proven to offer good long-term symptomatic relief, especially in cases with severe debilitating symptoms.<sup>34</sup> Currently, this technique is adopted by the majority of specialized endometriosis surgical teams. However, the complete removal of DIE may damage the pelvic autonomic nerves, negatively affecting bladder, rectal and sexual function (vaginal lubrication and swelling), even in single-sided injuries.<sup>13,15</sup>

Urinary dysfunction is of major concern after surgery for DIE, especially when the colorectum is involved. *Ballester et al.* (2010)<sup>4</sup> described a high incidence of urinary side effects affecting quality of life reaching up to 17%. *Dubernard et al.* (2008)<sup>12</sup> reported incidences of urinary dysfunction after resection of the uterosacral ligaments, rectovaginal septum and colorectum in 19,1%, 28,6% and 38,5% of cases, respectively.

Those functions are related to the pelvic sympathetic and parasympathetic neural pathways – superior hypogastric plexus, hypogastric nerves, pelvic splanchnic nerves and the inferior hypogastric (pelvic) plexus. The first authors to describe a technique for nerve-sparing DIE surgery were *Possover et al.* (2004);<sup>31</sup> they named it *Laparoscopic Neuronavigation* (LANN) technique, because it is based on the use of intraoperative neurostimulation for identification and dissection of intrapelvic nerves. These authors described 0.61% of chronic bladder hypotonia or atonia using this technique.

Since then, several nerve-sparing procedures have been successfully adopted and have shown to be effective in preserving neurologic pelvic functions with similar disease-free intervals and clinical outcomes (Table 4.3).<sup>5,7,19,24,36</sup>

*Ceccaroni et al.* (2012),<sup>6</sup> in a study comparing classical radical and nerve-sparing radical resection of DIE (Negrar Method), reported a significantly higher rate of severe neurologic pelvic dysfunction in the first group (86.2% versus 1.6%), although no differences were found between the two groups in terms of colorectal dysfunction rates and bowel-rectal quality of life.

Other authors have also demonstrated the reproducibility of intraoperative nerve dissection and exposure.<sup>19,23,37</sup> The goal of all the cited nerve-sparing approaches is to better identify the visceral nerve bundles at the level of the pararectal fossae and the parametria.

An alternative to exposing the autonomic nerves is to use landmarks to avoid operating at their surroundings and inadvertently transecting those nerves. This is the case of the mesorectum-sparing sigmoidectomy,<sup>24</sup> which uses anatomical landmarks to avoid areas of high nerve density.

Nowadays, there has been a general attitude toward less radical and nerve-sparing treatments, with the objective of preserving function, reducing morbidity and maintaining cure rates while improving the quality of life.

Laparoscopic identification of the inferior hypogastric nerve and inferior hypogastric plexus is a feasible procedure for trained laparoscopic surgeons who have a good knowledge not only of the retroperitoneal anatomy, but also of the pelvic neuro-anatomy. Moreover, the simple awareness of pelvic neuroanatomy and the high nerve-density areas is a key factor in reducing perioperative morbidity. Therefore, the objective of this chapter is to review the anatomy of the autonomic nerves of the pelvis and describe the steps of the LANN technique to expose and preserve the autonomic nerves, as well as the anatomical landmarks to preserve those nerves without the need of previously exposing them.

## 4.5.2 Neurophysiology of the Pelvic Floor

### 4.5.2.1 Neurophysiology of the Lower Urinary Tract (LUT)

The voluntary control of the LUT demands participation of different structures in the brain, brain stem and spinal cord. The frontal cortex permits conscious control over micturition by allowing voluntary contraction of the striated rhabdosphincter and the elevator ani muscle. Correspondingly, the pontine micturition center allows for the voluntary stimulation of the detrusor activity and coordinates the relaxation of the smooth and striated urethral sphincters during voiding.<sup>17</sup>

Since the objective of this chapter is on nerve-sparing surgery, almost all the attention will be given to the nerve bundles crossing the pelvis: the superior hypogastric (presacral) plexus, the hypogastric nerves, the pelvic splanchnic nerves, the inferior hypogastric (pelvic) plexus and the pudendal nerves.

<sup>a</sup> | MD, PhD, Associate Professor of Ob/Gyn; University of Toronto Faculty of Medicine, Functional Pelvic Surgery and Neuropelvelogy, Women's College Hospital, Toronto, Canada  
Head of the Pelvic Neurodysfunction Clinics, Department of Gynecology, Federal University of São Paulo, Brazil

<sup>b</sup> | Fellow of the Pelvic Neurodysfunction Clinic,  
Department of Ob/Gyn, Federal University of São Paulo, Brazil

<sup>c</sup> | MD, PhD, Associate Professor; Director of Endometriosis Division,  
Department of Ob/Gyn, Sao Paulo University, Brazil

#### Corresponding author:

**Nucelio Luiz de Barros Moreira Lemos, MD, PhD**

76 Grenville Street | Room 5449

Women's College Hospital

Toronto, ON M5S 1B2, Canada

E-mail: nucelio@gmail.com



Author	Study Design	Follow-up	Nerve-Sparing Technique	Operating Time	Urinary Dysfunction	Bowel Dysfunction	Sexual Function	EDT Symptoms Reduction
<i>Possover et al., 2004</i>	Prospective case series n=261 (cervical cancer n=163 and DIE n=91)	N.D.	Dissection and exposure from the sacral nerve roots, to the pelvic splanchnic nerves and the inferior hypogastric plexuses for preservation through direct visualization of the nerve bundles	Reduction of 14 minutes in the cervical cancer group and of 31 minutes in the deep endometriosis group, compared to the classical surgical approach	Chronic bladder atony: 0,61 % in cervical cancer and 0 in EDT patients	N.D.	N.D.	Equivalent
<i>Ceccaroni, 2012</i>	Non-randomized controlled trial Non-nerve sparing (n=65) vs. nerve-sparing (n=61)	12 mos.	Dissection and exposure of from the sacral nerve roots, to the pelvic splanchnic nerves and the inferior hypogastric plexuses for preservation through direct visualization of the nerve bundles	Operating time significantly faster (51 minutes) in the nerve-sparing group	Urinary retention significantly lower in nerve-sparing group	No difference in quality of life	Significantly more impaired in the non-nerve sparing group	N.D.
<i>Spagnolo, 2014</i>	Prospective case series (n=25)	6 mos.	Dissection and exposure of the hypogastric nerves and the superior part of the inferior hypogastric plexuses for preservation through direct visualization of the nerve bundles	N.D.	No post-operative deterioration of urodynamic and clinically assessed function	Postoperative improvement of manometric and clinically assessed function	VAS showed no dyspareunia after surgery	Complete Resolution
<i>Kavalaris, 2011</i>	Non-randomized trial of nerve-sparing (n=16) versus non-nerve sparing technique	N.D.	Dissection and exposure of the hypogastric nerves and the superior part of the inferior hypogastric plexuses for preservation through direct visualization of the nerve bundles	82 min. (nerve sparing) and 190 min. (non-nerve sparing)	Urinary retention in 25,5% patients in Non-Nerve Sparing. No retention in nerve-sparing group	N.D.	N.D.	Complete Resolution
<i>Mangler, 2013</i>	Prospective cohort study, (n=110)	64 mos	Topographic nerve-sparing (mesorectum sparing) without direct visualization of nerve bundles	230 min.	2,7 % pt with $\geq$ 50 mL of residual urine	15.5 %	N.D.	Complete Resolution
<i>Che, 2014</i>	Non-randomized (patient selected allocation) controlled trial of nerve sparing (n=63) vs. non-nerve sparing (n=45)	22 mos.	Dissection and exposure of the hypogastric nerves and the superior part of the inferior hypogastric plexuses for preservation through direct visualization of the nerve bundles	N.D.	Urinary retention in 15,9% of patients in non-nerve sparing group. No retention in nerve-sparing group Significantly different IPSS scores, 6-month follow up but not at the 12- or 24-month follow up	N.D.	No difference between groups	Similar pain reduction in both groups

**Key to acronyms:** Not described (N.D); International Prostate Symptom Score (IPSS); deep infiltrating endometriosis (DIE); endometriosis (EDT)

**Table 4.3** Results from Different Nerve-Sparing Techniques.

The peripheral nervous system innervates the bladder and the urethra with autonomic efferent sympathetic fibers via the hypogastric nerves, originated from the thoracic-lumbar sympathetic division of the spinal cord (T10–L3), and the parasympathetic fibers via the pelvic splanchnic nerves (S2–S4).<sup>17,25</sup> The somatic efferent motoric innervation to the urethra striated rhabdosphincter and the pubovaginal (puboprostatic) branch of the pubococcygeus muscle runs in the pudendal nerves, while direct sacral fibers from S3–S4 – the levator ani nerves – innervate the posterior portions of the levator ani muscle.<sup>16,38</sup>

The somatic and sympathetic divisions promote storage while the parasympathetic divisions promote voiding. During most of the time, baseline sympathetic stimuli are constantly fired through the hypogastric nerves, maintaining the internal urethral sphincter tonus and detrusor relaxation. The beta adrenergic receptors on the detrusor muscle respond to norepinephrine causing relaxation and allowing the bladder to fill without an increase in pressure or change in tone. At the same time alpha1-adrenergic receptors in the urethral smooth muscles respond to norepinephrine stimulating contraction.<sup>17,29,30</sup>

When the volume of urine in the bladder exceeds a specific threshold, stretch receptors in the bladder wall generate nerve impulses transmitted along the hypogastric nerves to the thoracic lumbar spinal cord. These afferent impulses reach the *pontine micturition center* (PMC) eliciting the pontine micturition reflex, which activates the parasympathetic nuclei of the conus medularis that respond by firing impulses along the pelvic splanchnic nerves to the bladder and urethra with subsequent release of neurotransmitter acetylcholine, which stimulate M3 receptors at the detrusor, causing contraction, and at the urethra, causing relaxation. The PMC also sends impulses to the pudendal nerves, causing the urethral rhabdosphincter to relax. Concomitantly, other PMC impulses suppress sympathetic activity to the bladder and urethra.<sup>17,29,30</sup>

#### 4.5.2.2 Bowel Evacuation and Anorectal Neurophysiology

Fecal continence and evacuation are complex mechanisms that involve the pelvic floor muscles as well as the somatic and autonomic nervous systems (sympathetic and parasympathetic).

The efferent innervation, responsible for the motor activity of pelvic muscles and viscera, consists in a group of three nerves of somatic and autonomic nervous systems.

The sympathetic innervation of descending colon, sigmoid and rectum is provided by the lumbar splanchnic nerves (L1–L3), that synapse at the inferior mesenteric ganglion, and run along the arterial irrigation to the intestine walls. The sympathetic fibers to lower parts of the rectum, anal canal and internal anal sphincter are also originated from the same lumbar splanchnic nerves; however, these nerves come from the mesenteric ganglion to the superior hypogastric plexus and form the hypogastric nerves, that are going to integrate the inferior hypogastric plexus, accompanying the pubococcygeus fascia and reaching the anus (space between sphincters) and integrating the myenteric plexus (of Auerbach).

The areas above the splanchnic flexure of the colon are innervated by the vagus nerve.<sup>8,20,26</sup> Noradrenaline release by the sympathetic fibers activates the alpha1 adrenergic receptors, promoting internal anal sphincter contraction.<sup>10</sup>

The parasympathetic signals originate from the pelvic splanchnic nerves (S2–S4). These nerves cross short distances in the pararectal fossae and form the inferior hypogastric plexuses that will innervate the upper two thirds of the rectum.<sup>25,33</sup> The liberation of acetylcholine by these fibers stimulates the myenteric plexus.

The somatic nervous system is composed by the pudendal nerves (S2–S4), that pass through the Alcock's canal towards the perineum, where they divide in three branches: the inferior rectal nerves (motor innervation to external anal sphincter), the perineal nerves (innervation to transverse perineal, bulbocavernosus, bulbospongiosus, ischiocavernosus, urethral rhabdosphincter, anterior part of the pubococcygeus and pubovaginal muscles) and dorsal nerves of the clitoris (or penis).<sup>17,38</sup> Moreover, the levator ani nerve (S3–S4) innervates iliococcygeus and ischiococcygeus muscles (motor and sensitively).<sup>16</sup>

The rectal and vesical proprioception are controlled by myelin fibers (A gamma, efferent fibers) that ascend to pontine and hypothalamic centers by hypogastric nerves. In addition, those are responsible for nociception of descending colon, sigmoid colon and rectum, while the pelvic splanchnic nerves are responsible for their proprioception.<sup>14</sup> Fibers of the pelvic floor muscles also send signals through pudendal and levator ani nerves.

The role played by the extrinsic innervation in the bowel evacuation's mechanism is less important than it is in the bladder, since motility control is exerted by the myenteric plexus, whereas the sympathetic and parasympathetic systems only provide modulating or stimulating signals to this plexus.<sup>14</sup> Yet, the role of the pelvic floor muscles is fundamental to the anorectal function. Simultaneous contractions of anterior and posterior parts of the pelvic floor promote increasing of the anorectal angle and direct the rectal content upwards, decreasing the afferent impulses and the defecation desire.

When there are signals to initiate defecation, the central nervous system reduces the stimuli to the pudendal nerve, relaxing the anterior part of the pelvic floor and contracting the posterior part of the levator ani muscles, decreasing the anorectal angle and facilitating defecation.<sup>28</sup>

### 4.5.3 Laparoscopic Anatomy of the Intrapelvic Nerves

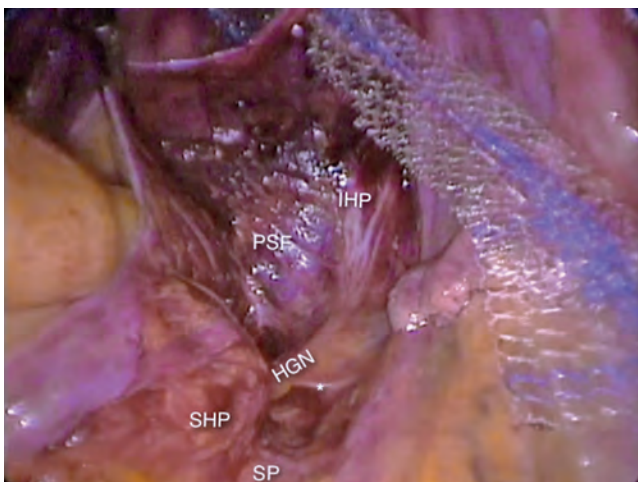
#### 4.5.3.1 Nerves of the Presacral and Pararectal Spaces

The superior hypogastric plexus is formed by fibers from para-aortic sympathetic trunk and gives rise to the left and right hypogastric nerves. The hypogastric nerves run over the presacral fascia in an anterior and distal direction. After crossing about two thirds of the distance between the sacrum and the uterine cervix or the prostate, its fibers spread to join the pelvic splanchnic nerves (described below) to form the inferior hypogastric plexus (Fig. 4.12).

The lateral limit of the presacral space is the hypogastric fascia, which is formed by the medialmost fibers of the uterosacral ligaments. The sacral nerve roots can be found justa-laterally to this fascia. They leave the sacral foramina and run anteriorly and distally, lying over the pyriformis muscle and crossing the internal iliac vessels laterally to them, to merge and form the nerves of the sacral plexus. Before crossing the internal iliac vessels, they give out the thin parasympathetic branches called pelvic splanchnic nerves, which promote detrusor contraction and provide extrinsic parasympathetic innervation to the colon descendens, sigmoid and rectum. They also carry nociceptive afferent signals from the pelvic viscerae. The pelvic splanchnic nerves join the hypogastric nerves to form the inferior hypogastric plexus in the pararectal fossae (Fig. 4.13).

#### 4.5.4 Nerve-Sparing by Direct Visualization of Nerve Bundles by Using the Laparoscopic Neuronavigation (LANN) Technique

The LANN technique is based on the concept of preserving integrity of nerve bundles by dissection and skeletonization prior to approaching the endometriotic foci.<sup>32</sup> This concept is similar to the one used to preserve the ureters, by dissecting them on healthy tissue, before it dives into the endometriotic area, to facilitate their identification in anatomically distorted regions.<sup>22</sup>

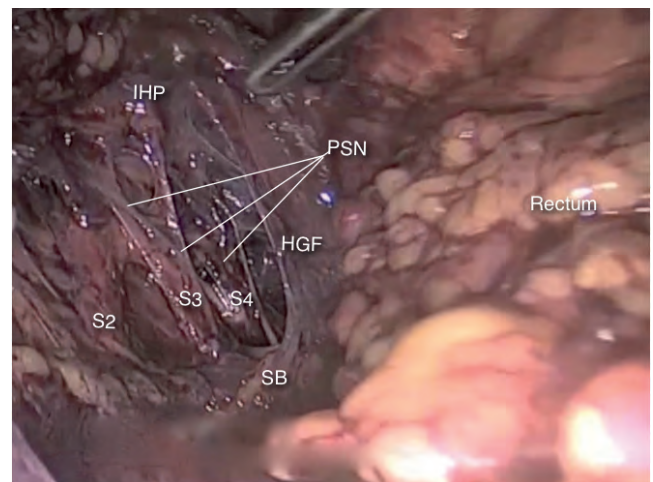


**Fig. 4.12** Right hypogastric nerve (HGN) originating from the superior hypogastric plexus (SHP) and running anteriorly and distally over the presacral fascia (PSF) to spread out in thinner branches that will form the inferior hypogastric plexus (IHP).

#### 4.5.4.1 Preservation of the Pelvic Splanchnic Nerves and the Inferior Hypogastric Plexus

The pelvic splanchnic nerves are thin bundles that can be easily mistaken for retroperitoneal connective trabeculae. Therefore, they can only be identified at their dorsal origin out of the sacral foramen and exposed, allowing for neuropreservation through direct visualization. According to the LANN technique, identification of the different sacral roots is performed using a bipolar laparoscopic forceps for electrostimulation and observing the motoric response.<sup>22,32</sup>

The sacral nerve roots are dissected by making an incision of the pararectal peritoneum medially to the ureter and opening the presacral fascia. The presacral space is developed by blunt dissection downwards, using the sacral and coccygeal bones as posterior and distal references, respectively. The dissection is expanded laterally, toward the hypogastric fascia, which is transected revealing the pyriformis muscle underneath. The sacral nerve roots run anteriorly and distally over the muscle fascia and can be precisely identified by means of the motoric response generated by intraoperative neurostimulation with a bipolar forceps delivering electrical impulses with a square-wave pulse duration of 10 ms, a pulse frequency of 2 Hz and electric potential of 1.5 mA, generated by a surgical neurostimulator. Stimulation of S2 produces an outward rotation of the leg, plantar flexion of the foot and a clamp-like squeeze of the anal sphincter from anterior and posterior, while S3 stimulation is visually shown as deepening and flattening of the buttock groove a marked flexion of the large toe and a less important flexion of the smaller toes. Following these roots ventrally will allow for the identification and exposure of the pelvic splanchnic nerves, as well as their pathways into the pararectal space to form the inferior hypogastric plexus. Dorsally, the rectal splanchnic nerves are visualized in a horizontal direction, crossing the sacral hypogastric fascia and finally anastomosing to the homolateral inferior plexus in laterodorsal position to the level of the rectum. The vesical splanchnic nerves originate from the middle portion of sacral roots, adopting a vertical direction and remaining lateral of the sacral hypogastric fascia, anastomosing with the homolateral inferior hypogastric plexus



**Fig. 4.13** Left pelvic splanchnic nerves (PSN) are the thin fibers arising from nerve roots S3 to S4, to join the hypogastric nerves and form the inferior hypogastric plexus (IHP). Sacral bone (SB)



at the level of the vagina or more ventral, lateral to the bladder pillar and caudal of the ureter and its junction to the bladder. The stimulation of the vesical splanchnic nerves increases intravesical pressure<sup>32</sup> (Figs. 4.14a, b).

Parametria can be safely resected after the exposure of splanchnic pelvic nerves from its origin to their anastomosis in the homolateral inferior hypogastric plexus, preserving the parasympathetic nerves at level of neural part of the cardinal ligament or more ventrally at level of the rectovaginal ligament or at the level of bladder pillar.<sup>32</sup>

Magnification, pneumoperitoneum facilitated dissection with minimum bleeding and directed lighting and visualization of the deeper spaces of pelvis, are important factors in favor of the laparoscopic surgery in the retroperitoneum, allowing for the development of the LANN technique which is substantially contributing to improve the knowledge of pelvic neuroanatomy. Also the technique proved to be reproducible in short operative time with notable reduction in postoperative functional morbidity after surgical treatment of endometriosis.<sup>23,32</sup>

All these strategies work very well in patients with endometriosis close by, but not directly affecting the pelvic splanchnic nerves. However, it is not possible to free the pelvic splanchnic nerves from endometriosis without tearing them. In these cases, bilateral exposure of the pelvic splanchnic nerves must be performed and the surgeon must try to estimate the amount of nerve damage that will be inflicted upon endometriotic resection. In case of bilateral disease, some endometriosis will likely have to be left behind, unless this has been previously discussed, and the patient has preoperatively opted to have self-catheterization instead of an incomplete resection.<sup>23</sup>

#### 4.5.4.2 Pelvic Wall and Somatic Nerves Endometriosis and Nerve Preservation

The complete exposure of sacral plexus and the identification of the somatic nerves requires the development of the lumbosacral and obturator spaces, starting at the level of the ilio-lumbar fossa, situated laterally to the external iliac vessels and goes further in a latero-caudal direction, allowing the identification of lumbosacral trunk and the proximal portion of the obturator nerve. When approaching the lateral pelvic wall, the elective dissection and medial mobilization of the internal iliac vessels and its branches is required to allow for a good anatomic exposure of the distal part of the sacral plexus – the sciatic nerve and its distal branches, the pudendal nerve and the nerves to the levator ani muscles. This technique allows for

a safe resection of the extensive endometriosis that infiltrates the sciatic foramen and the surroundings of the sciatic nerve and its branches. Moreover, pudendal nerves and vessels can be identified at the level of Alcock's canal, and the transection of the sacrospinous ligament and the pudendal vessels might be necessary for a further dissection.<sup>33</sup>

Recognition of the neuroanatomy of the pelvis leads to isolation and removal of all the disease with adequate surgical radicality, freeing the somatic nerves with the possibility of complete resolutions of symptoms.<sup>5</sup>

On top of knowledge on surgical neuroanatomy, the main factor for effective treatment and neuropreservation in somatic endometriosis of the pelvic sidewalls is preoperative recognition of symptoms and topographic diagnosis, based on neurologic examination and MRI.<sup>22</sup>

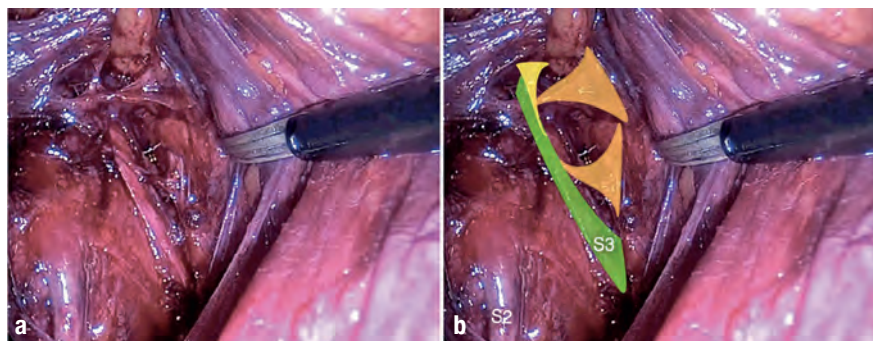
The main symptoms suggestive of endometriotic infiltration of the sciatic plexus are:

- Gluteal/perineal/lower limb pain or allodynia (pain on the dermatomes of the nerves of the lumbosacral plexus)
- Vaginal/retal foreign body sensation;
- refractory urinary urgency associated with single-sided pain on the dermatomes of the nerves of the lumbosacral plexus;
- refractory dischezia or proctalgia;
- vesical/rectal tenesmus, without signs of endometriotic infiltration of bladder or rectum.

Whenever one or more of these symptoms are present, careful workup of the lumbosacral plexus must be performed and the patient must only be taken to surgery after the exact site of entrapment (topographic diagnosis) has been performed.<sup>22</sup>

#### 4.5.4.3 Nerve Preservation Through the Use of Landmarks: the “Non-Touch” Technique

The above described technique is a technically demanding which requires high definition imaging, intraoperative neurostimulation and surgeon's training in laparoscopic nerve dissection. When those resources are not available due to lack of equipment or training, the use of surgical landmarks is recommended to avoid dissection in the areas of high nerve density and, therefore, higher risk of nerve injury. These are what we call “Non-Touch” techniques, since they involve reducing radicality to avoid inadvertent nerve injury.



**Fig. 4.14a,b** Pelvic splanchnic nerves branching out of S3 on the left side. Colored map on the right side shows the more horizontal bundles (light brown) to the rectum and the more vertical ones (yellow) to the inferior hypogastric plexus and bladder.

Fig. 4.15 shows the peritoneal view of the posterior cul-de-sac of a patient whose the left sacral nerve roots, pelvic splanchnic nerves and inferior hypogastric plexus has been dissected. Observe the dissection (dashed perimeter) area is the pararectal fossa, deeper to the presacral fascia. Fig. 4.16 shows the dissection of the left hypogastric nerve and inferior hypogastric plexus, to give a better understanding of the retroperitoneal anatomy.

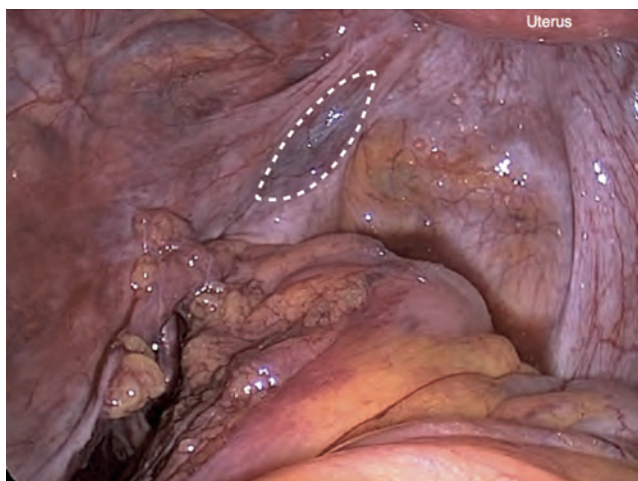
Through these images it is easy to come to the conclusion that deeper dissections at the pararectal fossae without prior exposition of the inferior hypogastric plexus should be avoided, especially in case of bilateral disease.<sup>23</sup>

Moreover, when dissecting the rectovaginal space, any dissection lateral to the rectum can damage the pelvic splanchnic nerves. The surgeon, therefore, must attempt to perform all dissections using the anterior rectal wall as a limit.

#### 4.5.4.4 Bowel Resection and Nerve Preservation

Bowel endometriotic nodules can be removed using various techniques, including mucosal skinning, nodulectomy, full-thickness disc resection, and segmental resection.<sup>1</sup>

The first intervention proposed for the treatment of intestinal endometriosis was anterior wall nodulectomy, which was described by *Nezhat et al.* in 1994,<sup>27</sup> prior to the development of laparoscopic staplers. However, many authors have proposed that this approach may leave residual disease tissue behind and increase the recurrence rate,<sup>35</sup> especially when the lesion infiltrates deeper than the inner muscularis.<sup>2</sup> In addition, as segmental resections have become increasingly feasible because of the technological development of mechanical sutures, this more radical procedure has become the most commonly performed technique for this indication.<sup>9</sup>

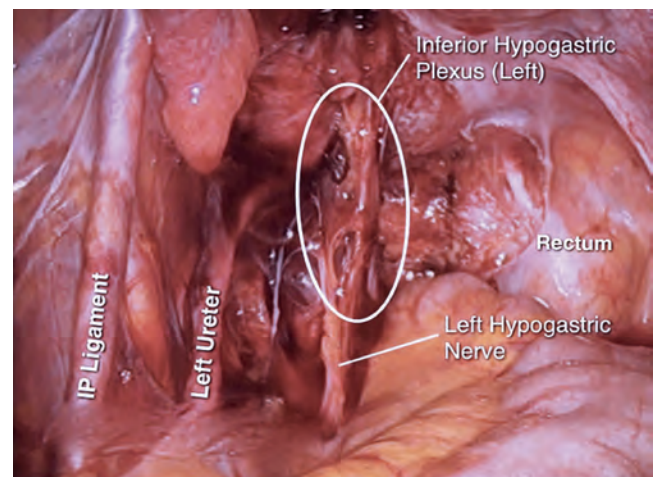


**Fig. 4.15** Transperitoneal view of the area of the left hypogastric plexus (dashed perimeter).

However, up to 45% of patients refer unchanged, worsened or de novo bowel dysfunction after segmental bowel resection for endometriosis.<sup>11</sup> This may be due to tight stenosis of the colorectal anastomosis, rectal denervation, colorectal intussusception through the anastomosis and post-operative transit constipation.<sup>3</sup> In that sense, anterior rectal wall nodulectomy seems to be a more reasonable, benign disease-oriented procedure, since endometriosis is believed to infiltrate the bowel from the serosal to the mucosal layer. In this manner, its theoretical advantages include reduced devascularization and denervation of the descending and sigmoid colon, since much less dissection is needed in the pararectal fossae, which can damage the autonomic nerves of the inferior hypogastric plexus either by directly sectioning them or by lateral thermal widespread.<sup>3</sup> This model can explain why *Fanfani et al.* (2010)<sup>13</sup> observed a 14% versus 0 urinary retention rate in women undergoing segmental and discoid resection, respectively. Bowel function scores are also better in patients undergoing the more conservative approach. Therefore, nodulectomy should be preferred over segmental resection whenever possible.<sup>1,18,21</sup>

#### 4.5.4.5 Key Points

The preservation of parasympathetic nerves is essential to a successful approach of DIE, for this reason, nerve-sparing techniques have been developed in different specialty areas and consist mainly of identifying and respecting, as far as possible, the nerves and neural plexus. As described by *Possover et al.* (2004),<sup>31,32</sup> the main principle of this technique consists on the identification of the pelvic splanchnic and hypogastric nerves and the inferior hypogastric plexus before approaching any lesion of the rectovaginal space and parametria. If nerve exposition is not feasible, landmarks should be used to guide the surgeon into avoiding high nerve density areas. In cases of rectal endometriosis, anterior wall nodulectomy is preferable over segmental resection.



**Fig. 4.16** Left hypogastric nerve and plexus, after peritonectomy of the ipsilateral pararectal and ovarian fossae. Infundibulo-pelvic ligament (IP).

### 4.5.5 References

- ABRÃO MS, PETRAGLIA F, FALCONE T, KECKSTEIN J, OSUGA Y, CHAPRON C. Deep endometriosis infiltrating the recto-sigmoid: critical factors to consider before management. *Hum Reprod Update* 2015;21(3):329–39. doi:10.1093/humupd/dmv003.
- ABRÃO MS, PODGAEC S, DIAS JA, AVERBACH M, SILVA LFF, MARINO DE CARVALHO F. Endometriosis lesions that compromise the rectum deeper than the inner muscularis layer have more than 40% of the circumference of the rectum affected by the disease. *J Minim Invasive Gynecol* 2008;15(3):280–5. doi:10.1016/j.jmig.2008.01.006.
- ARMENGOL-DEBEIR L, SAVOYE G, LEROI A, GOURCEROL G, SAVOYE-COLLET C, TUECH J et al. Pathophysiological approach to bowel dysfunction after segmental colorectal resection for deep endometriosis infiltrating the rectum: a preliminary study. *Hum Reprod* 2011;26(9):2330–5. doi:10.1093/humrep/der190.
- BALLESTER M, CHEREAU E, DUBERNARD G, COUTANT C, BAZOT M, DARAI E. Urinary dysfunction after colorectal resection for endometriosis: results of a prospective randomized trial comparing laparoscopy to open surgery. *Am J Obstet Gynecol* 2011;204(4):303.e1–6. doi:10.1016/j.ajog.2010.11.011.
- CECCARONI M, CLARIZIA R, ALBONI C, RUFFO G, BRUNI F, ROVIGLIONE G et al. Laparoscopic nerve-sparing transperitoneal approach for endometriosis infiltrating the pelvic wall and somatic nerves: anatomical considerations and surgical technique. *Surg Radiol Anat* 2010;32(6):601–4. doi:10.1007/s00276-010-0624-6.
- CECCARONI M, CLARIZIA R, BRUNI F, D'URSO E, GAGLIARDI ML, ROVIGLIONE G et al. Nerve-sparing laparoscopic eradication of deep endometriosis with segmental rectal and parametrial resection: the Negar method. A single-center, prospective, clinical trial. *Surg Endosc* 2012;26(7):2029–45. doi:10.1007/s00464-012-2153-3.
- CHE X, HUANG X, ZHANG J, XU H, ZHANG X. Is nerve-sparing surgery suitable for deeply infiltrating endometriosis? *Eur J Obstet Gynecol Reprod Biol* 2014;175:87–91. doi:10.1016/j.ejogrb.2014.01.027.
- CHUNG EAL, EMMANUEL AV. Gastrointestinal symptoms related to autonomic dysfunction following spinal cord injury. *Prog Brain Res* 2006;152:317–33. doi:10.1016/S0079-6123(05)52021-1.
- CICCO C DE, SCHONMAN R, CRAESSAERTS M, VAN CLEYNENBREUGEL B, USSIA A, KONINCKX PR. Laparoscopic management of ureteral lesions in gynecology. *Fertil Steril* 2009;92(4):1424–7. doi:10.1016/j.fertnstert.2008.08.021.
- COOK TA, BRADING AF, MORTENSEN NJ. The pharmacology of the internal anal sphincter and new treatments of ano-rectal disorders. *Aliment Pharmacol Ther* 2001;15(7):887–98.
- DUBERNARD G, PIKETTY M, ROUZIER R, HOURY S, BAZOT M, DARAI E. Quality of life after laparoscopic colorectal resection for endometriosis. *Hum Reprod* 2006;21(5):1243–7. doi:10.1093/humrep/dei491.
- DUBERNARD G, ROUZIER R, DAVID-MONTEFIORE E, BAZOT M, DARAI E. Urinary complications after surgery for posterior deep infiltrating endometriosis are related to the extent of dissection and to uterosacral ligaments resection. *J Minim Invasive Gynecol* 2008;15(2):235–40. doi:10.1016/j.jmig.2007.10.009.
- FANFANI F, FAGOTTI A, GAGLIARDI ML, RUFFO G, CECCARONI M, SCAMBIA G et al. Discoid or segmental rectosigmoid resection for deep infiltrating endometriosis: a case-control study. *Fertil Steril* 2010;94(2):444–9. doi:10.1016/j.fertnstert.2009.03.066.
- FENG B, BRUMOVSKY PR, GEBHART GF. Differential roles of stretch-sensitive pelvic nerve afferents innervating mouse distal colon and rectum. *Am J Physiol Gastrointest Liver Physiol* 2010;298(3):G402–9. doi:10.1152/ajpgi.00487.2009.
- GABRIEL B, NASSIF J, TROMPOUKIS P, LIMA AM, BARATA S, LANG-AVÉROUS G et al. Prevalence and outcome of urinary retention after laparoscopic surgery for severe endometriosis – does histology provide answers? *Int Urogynecol J* 2012;23(1):111–6. doi:10.1007/s00192-011-1492-2.
- GRIGORESCU BA, LAZAROU G, OLSON TR, DOWNIE SA, POWERS K, GREYSON WM et al. Innervation of the levator ani muscles: description of the nerve branches to the pubococcygeus, iliococcygeus, and puborectalis muscles. *Int Urogynecol J Pelvic Floor Dysfunct* 2008;19(1):107–16. doi:10.1007/s00192-007-0395-8.
- GROAT WC DE, YOSHIMURA N. Anatomy and physiology of the lower urinary tract. *Handb Clin Neurol* 2015;130:61–108. doi:10.1016/B978-0-444-63247-0.00005-5.
- KAMERGORODSKY G, LEMOS N, RODRIGUES FC, ASANUMA FY, D'AMORA P, SCHOR E et al. Evaluation of pre- and post-operative symptoms in patients submitted to linear stapler nodulectomy due to anterior rectal wall endometriosis. *Surg Endosc* 2015;29(8):2389–93. doi:10.1007/s00464-014-3945-4.
- KAVALLARIS A, BANZ C, CHALVATZAS N, HORNEMANN A, LUEDDERS D, DIEDRICH K et al. Laparoscopic nerve-sparing surgery of deep infiltrating endometriosis: description of the technique and patients' outcome. *Arch Gynecol Obstet* 2011;284(1):131–5. doi:10.1007/s00404-010-1624-9.
- KINUGASA Y, ARAKAWA T, MURAKAMI G, FUJIMIYA M, SUGIHARA K. Nerve supply to the internal anal sphincter differs from that to the distal rectum: an immunohistochemical study of cadavers. *Int J Colorectal Dis* 2014;29(4):429–36. doi:10.1007/s00384-013-1811-9.
- KONINCKX PR, USSIA A, ADAMYAN L, WATTIEZ A, DONNEZ J. Deep endometriosis: definition, diagnosis, and treatment. *Fertil Steril* 2012;98(3):564–71. doi:10.1016/j.fertnstert.2012.07.1061.
- LEMONS N, D'AMICO N, MARQUES R, KAMERGORODSKY G, SCHOR E, GIRÃO, MANOEL J B C. Recognition and treatment of endometriosis involving the sacral nerve roots. *Int Urogynecol J* 2016;27(1):147–50. doi:10.1007/s00192-015-2703-z.
- LEMONS N, SOUZA C, MARQUES RM, KAMERGORODSKY G, SCHOR E, GIRÃO, MANOEL J B C. Laparoscopic anatomy of the autonomic nerves of the pelvis and the concept of nerve-sparing surgery by direct visualization of autonomic nerve bundles. *Fertil Steril* 2015;104(5):e11–2. doi:10.1016/j.fertnstert.2015.07.1138.
- MANGLER M, HERBSTLEB J, MECHSNER S, BARTLEY J, SCHNEIDER A, KÖHLER C. Long-term follow-up and recurrence rate after mesorectum-sparing bowel resection among women with rectovaginal endometriosis. *Int J Gynaecol Obstet* 2014;125(3):266–9. doi:10.1016/j.ijgo.2013.12.010.
- MAUROY B, DEMONDION X, BIZET B, CLARET A, MESTDAGH P, HURT C. The female inferior hypogastric (= pelvic) plexus: anatomical and radiological description of the plexus and its afferences – applications to pelvic surgery. *Surg Radiol Anat* 2007;29(1):55–66. doi:10.1007/s00276-006-0171-3.
- MOSZKOWICZ D, PESCHAUD F, BESSEDE T, BENOIT G, ALSAID B. Internal anal sphincter parasympathetic-nitric and sympathetic-adrenergic innervation: a 3-dimensional morphological and functional analysis. *Dis Colon Rectum* 2012;55(4):473–81. doi:10.1097/DCR.0b013e318245190e.



27. NEZHAT C, NEZHAT F, PENNINGTON E, NEZHAT CH, AMBROZE W. Laparoscopic disk excision and primary repair of the anterior rectal wall for the treatment of full-thickness bowel endometriosis. *Surg Endosc* 1994;8(6):682–5.
28. PETROS PE, SWASH M. The Musculo-Elastic Theory of anorectal function and dysfunction. [February 17, 2016]; Available from: [http://www.pelviperiology.org/ano\\_rectal\\_function/pdf/musculo\\_elastic\\_theory\\_of\\_anorectal\\_function\\_and\\_dysfunction.pdf](http://www.pelviperiology.org/ano_rectal_function/pdf/musculo_elastic_theory_of_anorectal_function_and_dysfunction.pdf).
29. PETROS PE, ULMSTEN UI. An integral theory of female urinary incontinence. Experimental and clinical considerations. *Acta Obstet Gynecol Scand Suppl* 1990;153:7–31.
30. PETROS PE, ULMSTEN UI. An integral theory and its method for the diagnosis and management of female urinary incontinence. *Scand J Urol Nephrol Suppl* 1993;153:1–93.
31. POSSOVER M, RHIEM, CHIANTERA. The “Laparoscopic Neuro-Navigation” – LANN: from a functional cartography of the pelvic autonomous neurosystem to a new field of laparoscopic surgery. *Minim Invasive Ther Allied Technol* 2004;13(5):362–7. doi:10.1080/13645700410005392.
32. POSSOVER M. Laparoscopic exposure and electrostimulation of the somatic and new method for implantation of neuroprosthesis in paralysed patients. *J Gynecol Surg Endoscopy Imaging and Allied Techniques* 2004;1:87–90.
33. POSSOVER M, CHIANTERA V, BAEKELANDT J. Anatomy of the Sacral Roots and the Pelvic Splanchnic Nerves in Women Using the LANN Technique. *Surg Laparosc Endosc Percutan Tech* 2007;17(6):508–10. doi:10.1097/SLE.0b013e31812f81e4.
34. REDWINE DB, WRIGHT JT. Laparoscopic treatment of complete obliteration of the cul-de-sac associated with endometriosis: long-term follow-up of en bloc resection. *Fertil Steril* 2001;76(2):358–65.
35. REMORGIDA V, RAGNI N, FERRERO S, ANSERINI P, TORELLI P, FULCHERI E. How complete is full thickness disc resection of bowel endometriotic lesions? A prospective surgical and histological study. *Hum Reprod* 2005;20(8):2317–20. doi:10.1093/humrep/dei047.
36. SPAGNOLO E, ZANNONI L, RAIMONDO D, FERRINI G, MABROUK M, BENFENATI A et al. Urodynamic evaluation and anorectal manometry pre- and post-operative bowel shaving surgical procedure for posterior deep infiltrating endometriosis: a pilot study. *J Minim Invasive Gynecol* 2014;21(6):1080–5. doi:10.1016/j.jmig.2014.05.012.
37. VOLPI E, FERRERO A, SISMONDI P. Laparoscopic identification of pelvic nerves in patients with deep infiltrating endometriosis. *Surg Endosc* 2004;18(7):1109–12. doi:10.1007/s00464-003-9115-8.
38. WALLNER C, MAAS CP, DABHOIWALA NF, LAMERS WH, DERUITER MC. Innervation of the pelvic floor muscles: a reappraisal for the levator ani nerve. *Obstet Gynecol* 2006;108 (3 Pt 1):529–34. doi:10.1097/01.AOG.0000228510.08019.77.

Simone Ferrero<sup>a</sup> | Umberto Leone Roberti Maggiore<sup>a</sup> | Annalisa Racca<sup>a</sup> | Valentino Remorgida<sup>a</sup>

### 4.6.1 Introduction

Pelvic nerves are involved in voiding and storage functions of pelvic organs, sexuality, locomotion and in the transport of sensitive information generated in the lower limbs and pelvis to the central nervous system.<sup>45</sup> Neuropelveology, which literally means “the study of pelvic nerves”, is a new branch of medicine that focuses on the prevention, diagnosis and treatment of the pathologies of the pelvic nerves.<sup>45,52</sup> This discipline has emerged largely as a result of the pioneering work and research of *Marc Possover* (Zurich, Switzerland). Neuropelveology mainly focuses on the anatomy of the nerves of the lesser pelvis and their preservation during radical surgery (such as treatment of deep infiltrating endometriosis, radical hysterectomy, prostatectomy or tumor resection). However, its diagnostic and therapeutic spectrum is very large. Applications included in the multidisciplinary field of neuropelveology are as follows:

- Minimally-invasive laparoscopic procedures on the nerves of the lesser pelvis to treat nerve pain in the abdomen and pelvic cavity.
- Diagnosis and treatment of pelvic nerve pathologies that may account for functional disorders and pain.
- Diagnosis and treatment of functional disturbances related to the lesser pelvis that manifest with pelvic nerve pain or disorders without neurological symptoms.

Finally, another major area of neuropelveology specializes on research related to damage of pelvic nerves that can be found, for example, as a sequela of multiple sclerosis and spina bifida, but also in the case of traumatic spinal cord lesions and iatrogenic nerve injuries caused by extensive surgery.

Laparoscopy has become the standard of care in the diagnosis and treatment of endometriosis. It allows to overcome the limitations of open surgery, which are rooted in the fact that the method does not allow for identifying and dissecting pelvic nerves that are hidden deep in the retroperitoneal space behind

the pelvic vessels.<sup>43,45</sup> Due to the optimal magnification and the possibility of bloodless dissection, laparoscopy affords good access to all areas of the retroperitoneal pelvic space, and allows to expose and preserve the tiny pelvic nerves without causing iatrogenic surgical trauma to the vessels and nerves.<sup>29,74</sup> As a result of these technological advancements, radical pelvic surgery for diseases such as deep infiltrating endometriosis (DIE) and cancer can be performed with a reduced risk of adverse functional effects and complications (mainly related to bladder or bowel function).

#### 4.6.1.1 History

About 20 years ago, *Marc Possover* started his pioneering work that was primarily aimed at understanding the anatomy of pelvic nerves and identifying the nerves particularly at risk from iatrogenic injury during laparoscopic gynecological surgery. In a next stage, attempts were made to preserve integrity of these nerves (“nerve-sparing techniques”) by meeting the objectives of radical surgical procedures without increasing the incidence of functional complications related to iatrogenic nerve injuries.<sup>53,55</sup> Finally, in order to facilitate the intraoperative assessment of the function of pelvic nerves, *Marc Possover* introduced a technique of intraoperative nerve stimulation, known as *Laparoscopic Neuro-Navigation* (LANN), which marked the advent of neuropelveology.<sup>51</sup> All these aspects paved the way to the foundation of the *International Society of Neuropelveology* (ISON).

### 4.6.2 Neuroanatomy of the Pelvis

From a functional perspective, the pelvic part of the peripheral nervous system can be divided into nerves innervating the pelvic organs and nerves innervating the inferior limbs.

#### 4.6.2.1 Nerves Innervating the Pelvis

Two different systems innervate the pelvic organs: the visceral autonomic nervous system (with the orthosympathetic and parasympathetic components) and the somatic nervous system.

#### 4.6.2.2 Visceral Nervous System

Each organ in the pelvis is innervated by a dual set of visceral fibres: orthosympathetic and parasympathetic.<sup>69</sup>

##### ■ Orthosympathetic Component

The union of the lumbar splanchnic nerves (L1–L2) and the intermesenteric plexus results in the *superior hypogastric plexus* (SHP), which is located in the interiliac space, between the two ureters, behind the inferior mesenteric artery. This is a single and median structure. The SHP supplies the sympathetic innervation to the middle and distal rectum, the bladder and the genital organs. Underneath the sacral promontory, the SHP divides into two filaments of variable

<sup>a</sup> | Academic Unit of Obstetrics and Gynaecology, IRCCS AOU San Martino – IST, Genoa; Department of Neurosciences, Rehabilitation, Ophthalmology, Genetics, Maternal and Child Health (DiNOGMI), University of Genoa, Italy

#### Corresponding author:

**Simone Ferrero**, MD, PhD

Professore Associato

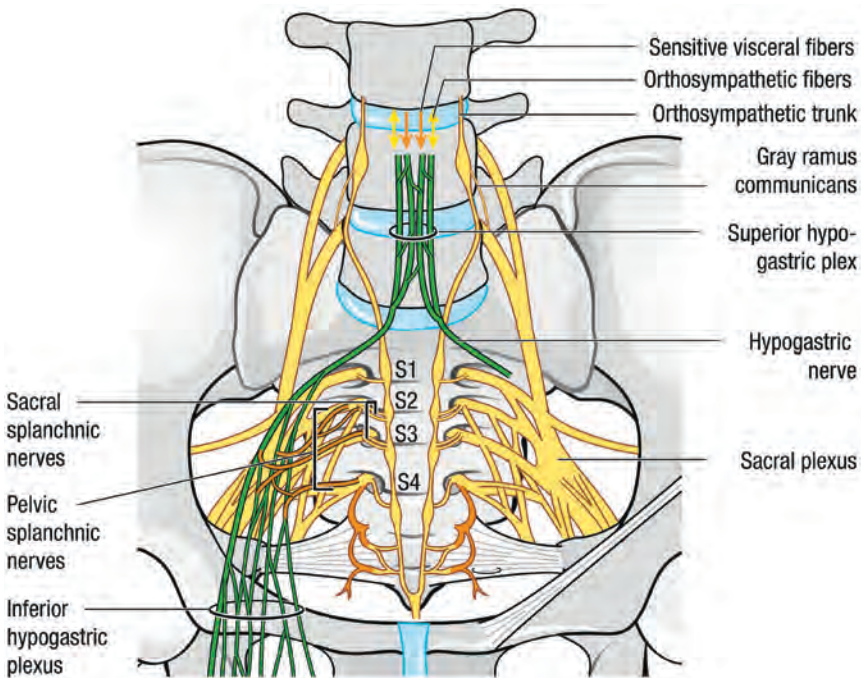
Dipartimento di Neuroscienze, Riabilitazione, Oftalmologia, Genetica e Scienze Materno-Infantili (DiNOGMI)

Clinica Ostetrica e Ginecologica IRCCS AOU San Martino, IST

Largo R. Benzi 10, 16132 Genoa, Italy

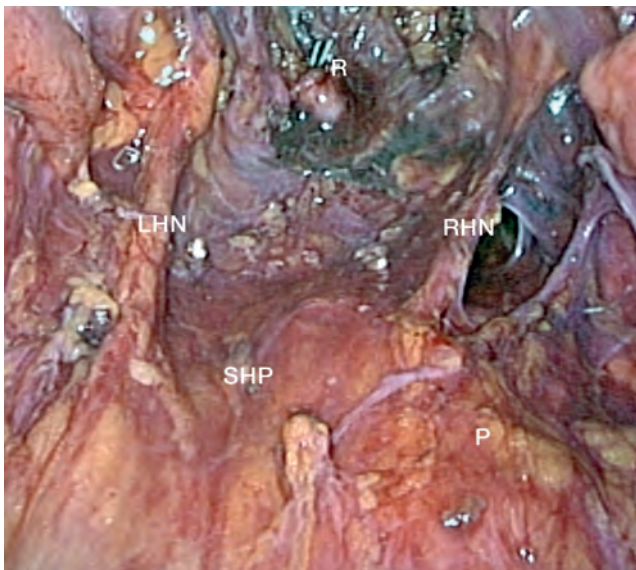
E-mail: simoneferrero@me.com

www.simoneferrero.it



**Fig. 4.17** Neuroanatomy of the inferior hypogastric plexus.

width (4–7 mm, depending upon the subject), which are called *hypogastric (or presacral) nerves (HNs)*<sup>37</sup> (Figs. 4.17, 4.18). The HNs take an oblique antero-inferior course with a concave course inside. They run inferiorly on their corresponding side of the body, parallel and medial to the ureters and the internal iliac arteries within the retroperitoneal fat.<sup>38</sup> They are in contact with the posterolateral mesorectum outside the perirectal fascia, clearly linked to the *uterosacral ligaments (USLs)* and the *rectovaginal ligaments*. The HNs are identifiable through the pelvic fascia, along the sidewalls of the pelvis until reaching the postero-superior corner of the *inferior hypogastric plexus (IHP)* contributing to its formation.



**Fig. 4.18** Identification of pelvic nerves during laparoscopic nerve-sparing excision of deep infiltrating endometriosis before segmental rectal resection. Promontorium (P), rectum (R), left hypogastric nerve (LHN), right hypogastric nerve (RHN), superior hypogastric plexus (SHP).

#### ■ Parasympathetic Component

The *pelvic splanchnic nerves (PSNs)* are the sacral contribution of the parasympathetic system. The PSNs are preganglionic fibres whose cell bodies are located in a small lateral horn of gray matter in spinal cord levels S2, S3, and S4<sup>69</sup> (Fig. 4.17). These preganglionic fibres leave the lateral horn, and subsequently pass through the ventral horn, ventral root, spinal nerve, and ventral ramus associated with S2, S3, and S4 about one centimetre distally from the point where such roots emerge from the piriformis muscle that covers the 2<sup>nd</sup>, 3<sup>rd</sup> and 4<sup>th</sup> sacral foramen. They can be brought out with a cautious traction of the mesorectum at the level of the presacral space. The PSNs are a network of 5–7 thin nerves, covered in the first three centimetres of their course by the parietal pelvic fascia. They cross the pararectal space at the level of the pelvic fascia in order to enter the visceral compartment of the pelvis and split into medial and lateral groups. The first group, the *rectal splanchnic nerves*, converges in the posterolateral side of the IHP; the second group, the *vesical splanchnic nerves*, have a more vertical direction and make anastomoses with the IHP at the level of the vagina and caudal ureter. The parasympathetic fibres travel through the plexuses, but wait to synapse until they reach the wall of their target organs and then send out very short postganglionic fibres.

#### ■ Inferior Hypogastric Plexus

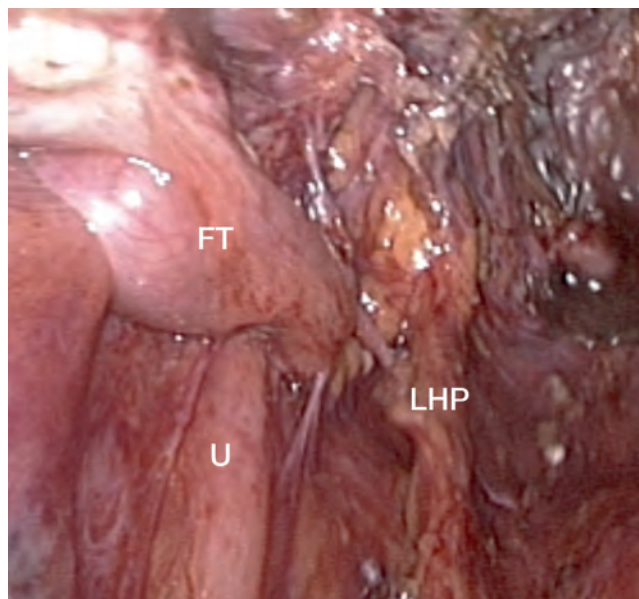
The IHP (also named pelvic plexus) is a structure formed by the merger of HN, the PSN and the *sacral sympathetic nerves (SSNs)*, which are derived from the ganglia chain located medially to the anterior sacral foramina, run behind the pelvic presacral fascia and are interposed between the HN and PSN (Fig. 4.17).<sup>2</sup> The portions of the lumbar and sacral sympathetic trunk, in continuity with each other at the level of the narrow pelvic top, converge down, in front of the sacrococcygeal synchondrosis forming a midline structure, named the *ganglion impar of Walther*. The IHP is located in the endopelvic fascia



under the broad ligament and positioned on the transverse cervical ligament.<sup>69</sup> The IHP has the shape of a triangle with a posterior base and an anterior inferior top.<sup>36</sup> It can be described as having three edges (posterior, superior and inferior) and three angles. The cranial edge is strictly parallel to the hypogastric artery, along which it runs at a distance of about 10 mm. The inferior edge extends from the fourth sacral root to the ureter's point of entry into the posterior layer of the broad ligament. Its dorsal or posterior edge is at the point of contact with the sacral roots, from which it receives its afferences. The three angles form a superior corner that represents the origin of the IHP following on from the homolateral HN; an anterior-inferior corner (constituting the top of the IHP) which is located exactly at the ureter's point of entry into the posterior layer of the broad ligament, and a posterior-inferior angle at the point of contact with the fourth sacral root.<sup>37</sup> During surgery, the IHP can be identified considering that it runs along the posterior edge of the hypogastric artery; its posterior superior edge is 10 mm away from it. The IHP covers the deep surface of the sacrum. The superior angle of the IHP crosses the origin of the hypogastric vein (HV). Its angle is at  $10 \pm 5$  mm from the vein confluence and 30–35 mm from the HV's termination angle, where it joins the external iliac vein (25–35 mm). The ureter is a key landmark for identification of the IHP (Fig. 4.19). The distance between the ureter and the superior angle of the IHP is variable, but the anterior-inferior angle is always located at the ureter's point of contact with the posterior layer of the broad ligament (where it perforates the broad ligament).<sup>37</sup>

In addition to the HN, the PSN and the sacral sympathetic trunks also contribute to the makeup of the HP.

The efferences of the IHP are divided into three groups: the *medial efferent bundle* (MEB), the *cranial efferent bundle* (CEB) and the *anterior efferent bundle* (AEB). The MEB is composed of thin fibres that travel medially toward the rectum and mesorectum. The CEB is composed of nerve branches from the upper portion of the IHP, starting through the parametrium and running cranially to the uterus. The AEB is a group of three or four fibres, which run outside the rectovaginal septum near the anterolateral face of the rectum. The intersection with the ureter and the uterine artery precisely locates the emergence of the vesical and vaginal efferences. From this point on, the vaginal efferences travel along the uterine artery and the vesical efferences run along the terminal segment of the ureter, underneath and outside of it (Table 4.4).



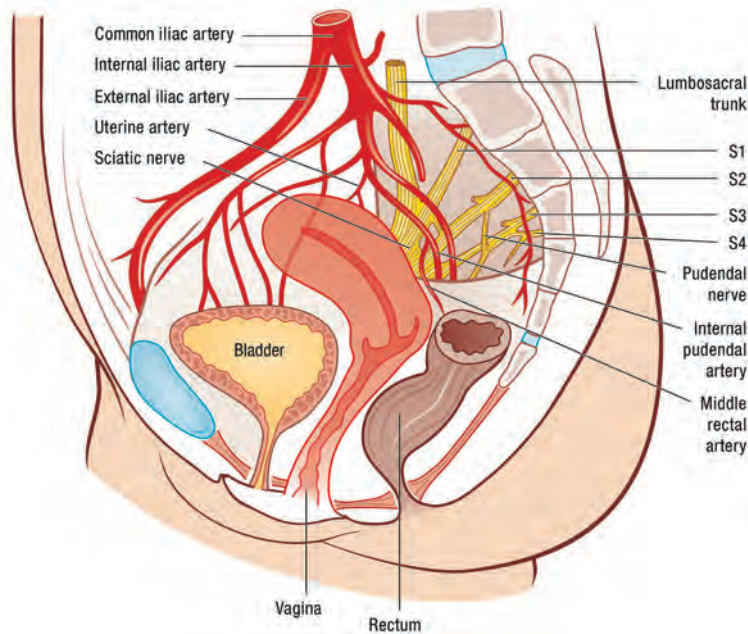
**Fig. 4.19** Identification of the left hypogastric plexus during excision of deep endometriosis. Ureter (U), fallopian tube (FT), left hypogastric nerve (LHN).

#### 4.6.2.3 Somatic Nervous System

The somatic nerves encountered within the pelvis originate from the pudendal and the coccygeal plexuses. The pudendal plexus is formed by the anterior branch of the 3<sup>rd</sup> sacral nerve, which connects with an anastomotic arch to the anterior branch of the 4<sup>th</sup> sacral nerve. Also a small part of the anterior branch of the 2<sup>nd</sup> sacral nerve contributes to its formation. It gives off nerves to the genital organs, the distal bowel, the urinary tract, the pelvic floor and the perineal skin. The pudendal plexus is closely related to the inferior part of the piriformis muscle and to the superior margin of the ischiococcygeus muscle; the pelvic fascia adheres to the anterior side of the plexus and fixes it to the posterolateral wall of the lesser pelvis, together with the lateral sacral vessels. Medially, it is separated from the rectal ampulla by the presence of the pararectal space. The pudendal plexus has few collateral branches (visceral and somatic) and one terminal branch, the *pudendal nerve* (PN).

Ganglion	Secondary plexus	Innervation
Superior hypogastric plexus (SHP)		
	Hypogastric nerves	Pelvic bowel
Inferior hypogastric plexus (IHP)		
Pelvic ganglions	Inferior and middle rectal plexus	Rectum (inferior and medium portion)
	Uterovaginal plexus	Uterus Fallopian tubes Vagina Ovaries
	Vesical plexus	Bladder
	Ureteric plexus	Ureter

**Table 4.4** Plexuses of the pelvic visceral nervous system.



**Fig. 4.20** Schematic illustration of the origin of the pudendal nerve.

#### ■ Pudendal Nerve

The PN is a paired, mixed sensory and motor nerve that originates from the anterior face of the pudendal plexus and is derived from all the pudendal plexus roots (S2, S3, S4) (Fig. 4.20).<sup>61</sup> The PN includes preganglionic nerve fibres of the sacral parasympathetic pathway that have vasodilatory effects on the reproductive organ arteries, therefore stimulating the erectile mechanism of the clitoris. With oblique direction down and sideways, it leaves the pelvis together with the internal pudendal vessels, passing through the lower part of the greater sciatic foramen, into the gap between the piriformis and ischiococcygeus muscles, lying medial and caudal to the sciatic nerve.<sup>60</sup> It enters the ischioanal fossa passing through the lesser sciatic foramen after surrounding the ischial spine. After re-entering the pelvis, it accompanies the internal pudendal artery and internal pudendal vein cranially and ventrally alongside the lateral wall of the ischioanal fossa, contained in a sheath of the obturator fascia termed the pudendal canal, along with the internal pudendal blood vessels.<sup>60</sup> Inside the pudendal canal, typically a single common PN divides into a collateral branch, the inferior rectal nerve (which sometimes arises directly from the sacral plexus) and two terminal branches, the perineal nerve and the dorsal nerve of the clitoris.<sup>32,61</sup> However, reports demonstrate variability in PN branching pattern, with up to three PN trunks individually contributing to its terminal branches.<sup>20,31,40,60</sup> The perineal nerve enters into the ischioanal fossa following the direction of the PN. It is the inferior and larger of the two terminal branches of the PN and is located below the internal pudendal artery. Accompanying the perineal artery and coursing behind the urogenital trigone, it divides into two branches: the superficial branch (posterior labial nerve) and the deep branch (muscular nerve branch). From the perineal nerve may arise, as a collateral, the inferior haemorrhoidal nerve, which mainly originates directly from the pudendal plexus.

The superficial perineal nerves turn behind the superficial transverse muscle of the perineum and when it becomes

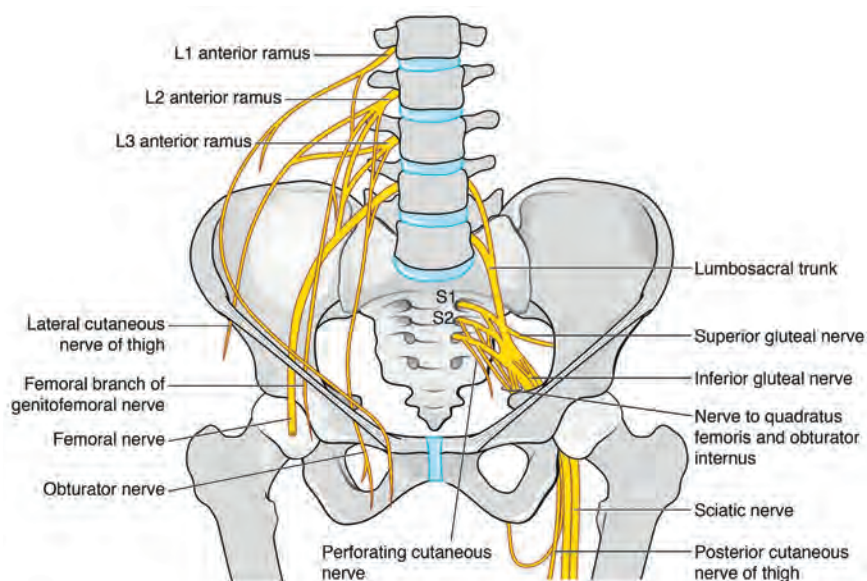
subcutaneous, the nerves spread to the perineal cutis and the labia majora. The deep perineal nerves supply the transversus perinei superficialis and profundus muscle, bulbocavernosus, ischiocavernosus and constrictor urethrae. Here, they give off branches, some motors, to the muscles listed above and others, sensory, to the vestibular bulb and the urethral mucosa.

The dorsal nerve of clitoris runs together with the pudendal vessels, located in the inner face of the ischiopubic branch along the sidewall of the ischioanal fossa. At the bottom margin of the pubic symphysis, it passes through the inferior pubic ligament to continue on the dorsum of the clitoris, at the side of the suspensory ligament. The nerve ends almost abruptly being distributed to the clitoris and the labia minora.

The PN has both motor and sensory functions. It does not carry parasympathetic fibres, but it carries sympathetic fibres. It supplies sensation to the clitoris through the branches of the dorsal nerve of clitoris. The labia in females are also supplied via the posterior labial nerve. The PN is one of various nerves providing sensation to these areas. Branches also supply sensation to the anal canal. By giving sensation to the clitoris, the PN constitutes the afferent component for clitoral erection. Branches also innervate muscles of the perineum and pelvic floor, namely the bulbospongiosus and ischiocavernosus muscles, the levator ani muscle (including the ileococcygeus, pubococcygeus, puborectalis and either pubovaginalis), the external anal sphincter and the external urethral sphincter. As it functions to innervate the external urethral sphincter, it is responsible for the tone of the sphincter mediated via acetylcholine release.

#### 4.6.2.4 Nerves Innervating the Inferior Limbs

The nerves innervating the inferior limbs originate from the lumbar plexus and the sacral plexus. These are mainly somatic nerves with few visceral fibres (orthosympathetic) for innervation of smooth muscle cells, fat cells and glandular cells of the inferior limbs.



**Fig. 4.21** Neuroanatomy of the obturator and sciatic nerves.

#### ■ Lumbar Plexus

The anterior branches of the 1<sup>st</sup>, 2<sup>nd</sup>, 3<sup>rd</sup> and 4<sup>th</sup> lumbar nerves form the lumbar plexus. The anastomotic branch, which originates from the last intercostal nerve, contributes to its formation. The lumbar plexus is placed in front of the transverse processes of the lumbar vertebrae, between the two levels of insertion of the paravertebral portion of the psoas muscle. Each anterior root of the plexus is divided into three branches, two of which extend in the peripheral branches of the plexus while the third descends as anastomotic branch to the anterior branch of the nerve below. The nerves of the lumbar plexus pass anterior to the hip joint and mainly innervate the anterior part of the thigh. The lumbar plexus emits numerous collateral branches, which can be divided into short and long collateral branches, and two terminal branches, the obturator and the femoral nerves. Short collateral branches are motor nerves to the trunk muscles, while long collateral branches (iliohypogastric nerve, ilioinguinal nerve, genitofemoral nerve are mixed nerves, and skin back of the thigh nerve is sensitive) innervate the inferior part of the abdominal wall, the external genitalia and the inferior limb.

#### ■ Obturator Nerve

The obturator nerve is a mixed nerve destined mainly to the medial thigh muscles (adductors) and a skin area corresponding to the lower half of the medial thigh. Moreover, it provides sensory branches to the joints of the hip and knee (Fig. 4.21). This nerve originates from the lumbar plexus with three roots from the anterior branches of the 2<sup>nd</sup>, 3<sup>rd</sup> and 4<sup>th</sup> lumbar nerves, which converge into a single trunk that descends vertically in the thickness of the psoas major muscle. The nerve travels in a direction toward the pelvis, always keeping between the bundles of psoas major muscle, leaving on its outer side the femoral nerve, and along the inner side, the lumbosacral trunk (Figs. 4.22, 4.23). At the level of the pelvic inlet, it leaves the psoas muscle from its medial margin, passing behind the common iliac vessels and laterally to internal iliac artery (Fig. 4.24); along the side wall of the lesser pelvis, following closely to the obturator internus

muscle, above and anteriorly of the obturator vessels, and thus reaches the obturator canal, the point where it gives off its unique collateral branch: the nerve to the obturator externus muscle. It leaves the obturator canal along with the homonymous vessels and ends shortly after, dividing into its two terminal branches: the anterior branch and the posterior branch.

#### ■ Sacral Plexus

The sacral plexus is formed by the union of the lumbosacral trunk (L4–L5) to the anterior branches of the 1<sup>st</sup>, 2<sup>nd</sup> and 3<sup>rd</sup> sacral nerves. The four roots of the sacral plexus gather in front of the greater sciatic notch, in a common trunk which gives off a large terminal branch, the sciatic nerve, and few collateral branches (that can be divided into anterior and posterior branches). The sacral plexus resembles a flattened and triangular band, with the base oriented toward the sacrum and the apex to the lower border of the greater sciatic foramen. It is located laterally in the lesser pelvis, runs close to the anterior face of the piriformis muscle and is coated anteriorly by the pelvic fascia that separates it from the internal iliac vessels and the sympathetic chain. Always through the fascia, the anterior visceral plexus is in contact with the rectum and the recto-uterine pouch. The anterior sacral plexus roots pass outside of the anterior sacral foramina and run laterally and below the pelvic wall. The lumbosacral trunk, which consists of part of the anterior branch of L4 and of the entire anterior branch of L5, runs cranially from the abdomen into the pelvic cavity passing in a position immediately anterior to the sacroiliac joint. From every branch of the anterior sacral nerve plexus two or three grey communicating branches (gray rami communicantes) are given off to the sympathetic chain. The sacral plexus emits several collateral branches, which can be divided into anterior and posterior, and one terminal branch, the ischiatic nerve. The anterior collateral nerves innervate the external rotators of the hip muscles, and the coxofemoral joint with the sensory fibres of the nerve to the quadratus femoris muscle. The posterior collateral nerves are the cutaneous nerve of the thigh (sensitive), the superior gluteal nerve, the inferior gluteal nerve and the piriformis nerve (motors).



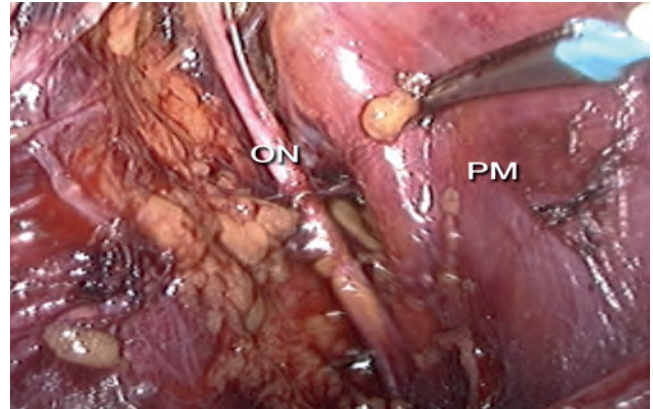
### ■ Sciatic Nerve

Extending from the pelvis to the foot, the sciatic nerve is the most voluminous and the longest nerve of the human body. It is a mixed nerve that innervates the muscles of the posterior compartment of the thigh, leg and foot as well as hip and knee joints, and it carries sensory fibres from the whole tibial and foot areas with the exception of the anteromedial tibial region and medial margin of the foot (Fig. 4.20). All the roots of the sacral nerve contribute in varying degrees to the formation of the sciatic nerve that, in its initial segment, is flattened in an anteroposterior direction measuring about 1.5 cm in width and 0.5 cm in thickness. The roots of the sciatic nerve, originating from the anterior branches of the 4<sup>th</sup> and 5<sup>th</sup> lumbar nerve and 1<sup>st</sup>, 2<sup>nd</sup> and 3<sup>rd</sup> sacral nerve, converge on the sides of the sacrum in a single trunk that leaves the pelvis through the inferior greater sciatic foramen below the inferior border of the piriformis muscle, lateral to the posterior cutaneous nerve of the thigh and descends between the greater trochanter and ischial tuberosity in the gluteal region. The nerve passes subsequently through the gluteal region in the thigh, at the level of the upper angle of the popliteal fossa where it divides into its two main branches, the common peroneal nerve (also termed common fibular nerve) and the tibial nerve. The dorsal branches of L4, L5, S1 and S2 are conveyed in the common peroneal nerve and the ventral branches of L4, L5, S1, S2 and S3 are conveyed in the tibial part.


### 4.6.3 Nerve-Sparing Surgery for Deep Infiltrating Endometriosis

It is well established that laparoscopic excision of deep infiltrating endometriosis is associated with a significant improvement of pain symptoms, quality of life, sexual life and a low rate of minimal persistent/recurrent disease.<sup>12,14,16,39,57,58</sup> However, extensive laparoscopic surgery for endometriosis may seriously affect bladder, rectal, and sexual function due to the involvement of the pelvic autonomic nerves that act as pathways for neurogenic control of these organs and sexual arousal.<sup>13,15,64,65</sup>

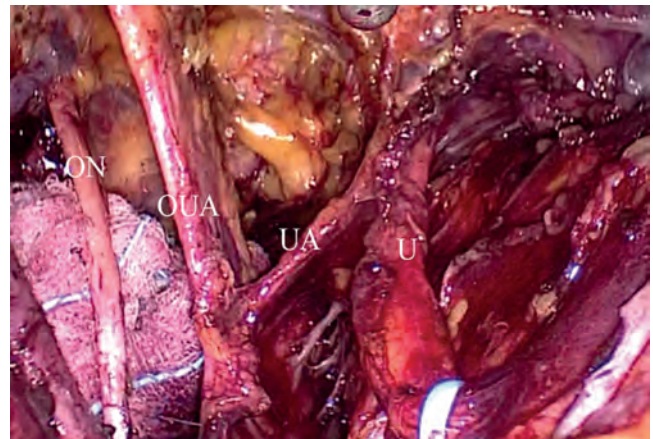
Nerve-sparing surgery has been originally proposed to decrease the postoperative complications of radical treatment of cervical cancer. In fact, radical hysterectomy, as described by Wertheim,<sup>68</sup> was associated with severe bladder dysfunction and colorectal motility disorders. Since the 1960s, several authors tried to preserve the pelvic splanchnic nerves (PSNs) and the hypogastric nerves (HNs) during radical hysterectomy (Table 4.5), in order to improve postoperative dysfunctional complications.<sup>3,18,19,27,55,56,71,72</sup> These techniques



**Fig. 4.22** Identification of the obturator nerve (ON) adjacent to the psoas muscle (PM).



**Fig. 4.23** Identification of the obturator nerve (ON) adjacent to the psoas muscle (PM). Sciatic nerve (SN), psoas muscle (PM), iliac vessels (IV).



**Fig. 4.24** Identification of the obturator nerve (ON). Obliterated umbilical artery (OUA), uterine artery (UA), ureter (U).

Surgical steps	Potential nerve injuries
Resection of the dorsal paracervix (uterosacral ligaments and rectovaginal ligaments)	HN
Division of the deep uterine vein in the cardinal ligament	PSNs
Dissection of lymph nodes medial to the internal iliac vein and around the deep uterine vein	PSNs
Resection of the vesico-uterine ligament	Vesical branches of the IHP
Pre-sacral and periaortic lymph node dissection	SHP

**Table 4.5** Surgical steps correlated with the autonomic nerves at risk during classical radical hysterectomy.<sup>17,24,59</sup>

**Key to acronyms:** Hypogastric nerve (HN), pelvic splanchnic nerves (PSNs), inferior hypogastric plexus (IHP), superior hypogastric plexus (SHP).

were aimed at identifying and sparing, as much as possible, the nerves involved in urinary, rectal and sexual function without compromising surgical outcomes.<sup>11,30,59</sup> This has prompted various authors to translate the concepts originating from oncologic nerve-sparing surgery to a new technique to be used in the treatment of deep infiltrating endometriosis (Table 4.6).<sup>5,7–9,23,28,33,53,66</sup>

#### 4.6.3.1 Surgical Technique

In recent years, *Ceccaroni et al.* have significantly contributed to the development of the laparoscopic nerve-sparing technique in the treatment of deep infiltrating endometriosis.<sup>5–9</sup> In 2012, the above authors published a step-by-step description of the nerve-sparing laparoscopic technique used to treat deep infiltrating endometriosis.<sup>6</sup>

Studies comparing Nerve-Sparing and Non-Nerve-Sparing Surgery in Radical Hysterectomy for Cervical Cancer and in Excision of Deep Infiltrating Endometriosis							
First author, year published	Study location	Type of study	Participants (n)	Age (years)	Disease	Disease stage	Results
Yabuki, 1996 <sup>72</sup>	Japan	Case-control	52 LtrH (15 NS)	–	Cervical cancer	–	Group NS: lower time to obtain post-void residual urine volume < 50 ml; lower blood loss. No significant difference in duration of surgery
Possover, 2000 <sup>55</sup>	Germany	Retrospective analysis of prospectively collected database	66 LARVH (38 NS)	–	Cervical cancer	FIGO IB2 to IIIA and IB1 with risk factors for lymphatic metastasis	Group NS: faster suprapubic drainage removal; decreased incidence of self-catheterization. No significant difference in radicality of resection of the cardinal ligaments
Querleu, 2002 <sup>56</sup>	France	–	95 LARVH (47 NS)	–	Cervical cancer	FIGO 1A2, 1B, 2	Group NS: longer duration of post-operative retention (residual urine volume > 100 ml). No significant difference in duration of surgery, blood loss, long-term urinary symptoms
Landi, 2006 <sup>28</sup>	Italy	Prospective non-randomized study	45 (25 NS)	31	Deep endometriosis	Deep endometriosis infiltrating the bowel	Group NS: reduced mean time until resumption of voiding function; higher score of patient satisfaction; better improvement in dysuria. No significant differences in blood loss, operative time, incidence of complications, mean length of stay
Kavallaris, 2011 <sup>23</sup>	Germany	Retrospective analysis of prospectively collected database	71 (16 NS)	32	Endometriosis	Deep endometriosis with or without bowel infiltration	Group NS: faster spontaneous bladder voiding (with residual urine volume < 50 ml); decreased risk of permanent self-catheterization
Ceccaroni, 2012 <sup>6</sup>	Italy	Prospective	126 (61 NS)	–	Endometriosis	Deep endometriosis infiltrating the bowel	Group NS: shorter duration of post-operative self-catheterization; lower incidence of postoperative urinary retention; lower incidence of severe pelvic dysfunction; higher sexual desire; higher frequency of orgasm achievement during intercourse; overall lower incidence of severe bladder/rectal/sexual dysfunctions. No significant difference in intraoperative, perioperative and postoperative complications; in rates of urinary incontinence, bladder hyposensibility, air/fecal incontinence, constipation.
Bogani, 2014 <sup>4</sup>	Italy	Prospective	96 LRH (33 NS)	51	Cervical cancer	FIGO stage IA2, IB1, IIA < 4 cm; after neoadjuvant chemotherapy: FIGO IB2, IIA > 4 cm and IIB	Group NS: lower catheterization time, less voiding dysfunctions and reduced constipation rate No significant difference in parametrial width and vaginal cuff length, in blood loss, in intraoperative and postoperative complications

**Table 4.6** Studies comparing nerve-sparing and non-nerve sparing surgery in radical hysterectomy for cervical cancer and in excision of deep endometriosis **Key to acronyms:** Laparotomic radical hysterectomy (LtrH); laparoscopic-assisted radical vaginal hysterectomy (LARVH); laparoscopic radical hysterectomy (LRH); nerve-sparing group (NS).



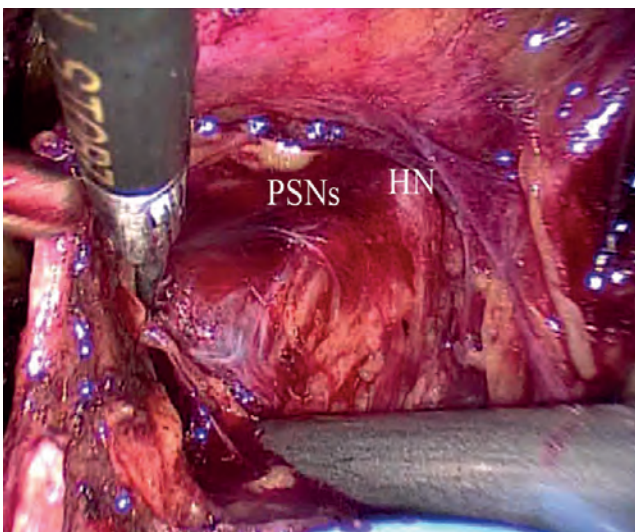
The peritoneum covering the promontorium is incised. Identification of the SHP and HNs is accomplished through blunt dissection of the loose fatty tissues of the rectosacral space until reaching the level of the rectosacral fascia. The nerves are then pushed ventrally and caudally with the rectum to facilitate a safe dissection of the mesorectum. Mobilization of the rectosigmoid colon and access to the lower mesorectum at the level of lateral rectal ligaments are achieved by opening the medial (Okabayashi's space) and lateral (Latzko's space) pararectal spaces. The Okabayashi's space is developed between the mesoureter and the rectouterine ligament by creating a space between the posterior leaf of the broad ligament (medial) and the ureter (lateral). The Latzko's space is developed between the mesoureter and the pelvic wall by opening up the space between the internal iliac artery (lateral) and the ureter (medial).<sup>8,9</sup> Once these two spaces have been created, the posterior and lateral parametrial ligaments (rectovaginal, lateral rectal, and cardinal ligament) are identified. In a next step, blunt dissection in the laterocaudal direction of the retrorectal space is performed, preparing the so-called 'holy plane of Heald' on the midline<sup>8,67</sup> to identify the sacral roots (S2–S4). The middle and distal portions of the HNs are embedded in the mesorectal fascia and may be injured if not correctly visualized. Dissection is carried on close to the rectum, towards the Okabayashi's spaces. The isolated SHP and HNs are then preserved and removed from the *uterosacral ligaments* (USLs) and rectovaginal ligaments. In addition, the lumbosacral sympathetic trunks and ganglia, located close to the sacrum, but in a more lateral and dorsal direction, are preserved. The posterior parametrium and ligaments can be dissected, and given endometriotic involvement of the cardinal ligament, it can be transected sparing all the fibres lodged within the rectovaginal ligaments. Dissection is carried on until exposure is achieved at the site where the HNs travel into the cranial part of the IHP in the anterolateral border of the rectum at the level of the posterior parametrium. The ureters and iliac vessels are isolated and ureterolysis is performed until healthy tissue is reached. The posterolateral parametrium is traversed bilaterally by the HNs, the anterior branches of the SSNs, the PSNs, and, more ventrally and caudally, by the proximal part of

the IHP. The caudal portion of the posterolateral parametrium is resected after medialization of the rectum infiltrated by endometriosis, followed by identification of the cranial and middle part of the IHP, and extreme lateralization of its fibres, leaving intact (when possible) the connective tissue in which they are embedded. If necessary, transection of the rectovaginal and lateral rectal ligaments is performed after completion of cranial and lateral dissection of the rectovaginal septum and further lateralization of the ureters, while keeping the PSNs and IHP fibres under constant laparoscopic vision. The *deep uterine vein* (DUV) is a landmark that facilitates identification of the plane dividing the parametrial vascular portion (ventrally and cranially) from the neural portion (dorsally and caudally). Next, the PSNs are identified at their origin from the sacral roots allowing for a safe dissection of the rectal wings and lower mesorectal planes, while keeping their parasympathetic bundles under constant vision. Following transection of the rectovaginal ligaments, identification of the IHP, caudal to the course of each DUV, is again performed to facilitate division of their efferent bundles, sparing the visceral afferent and efferent fibres to the uterus, vagina, and the bladder. Transection of lateral rectal ligaments is then safely completed by retracting them medially, after separating them from the PSNs and IHP. During transection of the lateral rectal ligaments and rectal resection, only rectal fibres of the resected bowel segment should be cut to minimize rectal denervation.

#### 4.6.3.2 Surgical Outcomes

In 2004, *Volpi et al.* for the first time reported on their experience with nerve-sparing surgery for laparoscopic treatment of deep infiltrating endometriosis. They conducted a prospective study to evaluate whether the HNs and the PSNs can be identified and preserved during laparoscopic surgery for deep infiltrating endometriosis involving the USLs and the rectovaginal septum (Fig. 4.25).

Twenty-four women operated on for deep endometriosis were enrolled in the study. The surgical procedure in all but two patients consisted of deep dissection of the retroperitoneal part of the pararectal fossa with exposure and resection of the *uterosacral ligaments* (USLs). Resection of vaginal nodules was performed in 18 of 24 (66.7%) patients, one patient (4.2%) underwent anterior resection of the rectosigmoid and another one (4.2%) underwent resection of the bladder wall. The authors visualized the HNs in 20 of 22 women (90.1%). Resection of at least one HN and of the upper part of the hypogastric plexus at least on one side was carried out in 8 of the 24 patients (33.3%). Bilateral resection of the nerves was recorded in 3 of 8 patients (37.5%). Resection of the USLs was bilateral in seven patients (29.2%), and in three of them (42.9%), the nerves were resected. Seven of 8 women (87.5%) who had resection of the nerves experienced urinary retention at discharge and had self-catheterization. Self-catheterization was necessary in five patients (100%) who had unilateral resection while no patient with preservation of the nerves required self-catheterization. The study showed that nerve identification is feasible in the majority of patients undergoing laparoscopic surgery for deep infiltrating endometriosis and confirmed that the nerve-sparing technique is crucial in preserving normal bladder function.<sup>66</sup>



**Fig. 4.25** Identification of the pelvic splanchnic nerves (PSNs) and left hypogastric nerve (HN).



In 2005, *Possover et al.* conducted a prospective pilot study to assess the feasibility and advantages of introducing the laparoscopic neuro-navigation (LANN) technique into laparoscopic gynaecologic radical pelvic surgery (163 patients with cervical cancer and 91 patients with deep infiltrating endometriosis of the parametria). The rationale underlying the surgical procedure included dissection, electrostimulation and consistent preservation of the PSNs before transection of the parametria, and subsequently, of the IHP. Functional selective identification of the neural roots was performed using the LANN technique. Mono- or bipolar laparoscopic forceps were used for electrostimulation (current with a square-wave pulse duration of 250 microseconds, pulse frequency of 35 Hz, and electric potential of 12 V). Laparoscopic dissection and electrostimulation of the PSNs was feasible in all women without any complications and without prolonging the total operative time. In addition, the LANN procedure was found to significantly reduce the rate of postoperative bladder dysfunction (< 1 % of the patients).<sup>53</sup>

More recently, a step-by-step tutorial including videos and pictures of the LANN technique for nerve-sparing radical endometriosis surgery has been published giving a detailed look at the anatomy of the intrapelvic bundles of the autonomic nerve system innervating the bladder, rectum, and pelvic floor. This didactic video guide is a great convenience for health care providers looking for an instructive presentation of the technique performed under constant laparoscopic visualization in order to localize, identify and preserve the sympathetic and parasympathetic nerves in the pelvis which are at risk during radical pelvic surgery.<sup>29</sup>

In 2006, a prospective non-randomized study assessed the feasibility and outcomes of laparoscopic nerve-sparing excision of endometriosis.<sup>28</sup> This study included 45 patients who underwent segmental bowel resection using a non-nerve-sparing technique (control group – group A, n = 20) and a nerve-sparing technique (case group – group B, n = 25). No statistical differences were reported between the study groups in terms of operative time, blood loss, and average length of stay. The median time until resumption of normal voiding function was significantly shorter in group B (3.0 days) than in group A (12.5 days; p < 0.01). After surgery, a significant improvement of pain symptoms was reported in both study groups without significant differences. More patients of group B (87.7 %) were 'very satisfied' in comparison with group A (59.0 %; p = 0.013).<sup>28</sup>

In 2011, a German study of *Kavallaris et al.* compared the outcomes of 16 patients who were treated by laparoscopic nerve-sparing radical resection of endometriosis within a database of 55 patients who received non-nerve-sparing surgery.<sup>23</sup> In all of the 16 patients treated with the nerve-sparing technique, at least single-sided resection of the USLs was performed. Two patients underwent anterior resection of the rectum, another two patients received bladder resection and one patient was treated by ureteral resection. Pain symptoms significantly improved postoperatively in all patients. In this study, visualization of the HNs and IHP was feasible in acceptable operative time and the mean operative time was 82 minutes (range 45–185). After surgery, with the exception of the three patients with bladder and ureter resection, in all

the other patients spontaneous voiding occurred on the first postoperative day with a median residual urine volume of < 50 ml. Following removal of the Foley catheter, the remaining three patients reported on spontaneous voiding (two patients with bladder resection on postoperative day 7, and the patient with ureter resection on postoperative day 9) with no urinary retention. The patients treated by a non-nerve-sparing technique underwent a combined laparoscopic vaginal technique with en bloc resection of part of the posterior vaginal wall, cul de sac, rectovaginal septum, USLs, and part of the rectosigmoid. The mean operative time was 190 min. Postoperatively, 14 patients (25.5 %) had bladder dysfunction with incomplete emptying of the bladder. All women were instructed for bladder self-catheterization. Bladder function resolved in ten patients spontaneously within 3 months and in two patients after 6 months. Two patients required permanent self-catheterization at the 6-year follow-up control.<sup>23</sup>

*Ceccaroni et al.* conducted a single-centre, prospective trial to compare the classic and nerve-sparing technique in terms of complications, neurologic postsurgical dysfunctions, clinical outcome, and quality of life. Sixty-one women underwent nerve-sparing radical excision of pelvic endometriosis with segmental bowel resection (group B) and 65 patients underwent the classical technique (group A). The number of patients who underwent bowel or bladder resection was similar in both groups; whereas, more patients of group B underwent major ureteral surgery or parametrectomy. The mean ( $\pm$  SD) operative time was shorter in group B (301.5  $\pm$  88.9 min) than in group A (351.8  $\pm$  113.9 min). No inter-group differences were reported in terms of intraoperative, perioperative, and postoperative complications. The average number of days of self-catheterization was significantly lower in the nerve-sparing group (39.8 days) than in the non-nerve-sparing group (121.1 days; p < 0.001). Women of group A experienced urinary retention more frequently between 1 and 6 months (p = 0.035) compared with group B, and did not have any amelioration between 6 months and 12 months (p = 0.018). Similar findings were observed in terms of incidence of urinary incontinence, bladder hyposensibility, air/fecal incontinence, and constipation at 1, 6, and 12 months of follow-up. Concerning sexual life, the rates of intercourses after surgery and of women experiencing dyspareunia, psychophysical distress related to dyspareunia or use of lubricants, vaginal dryness, and distress due to vaginal dryness, were similar in the two groups. Vaginal bleeding (p < 0.05) and reduced sexual desire (p < 0.001) were more common in women of group A. Besides, more patients in group A (10.8 %) reported on sexual sensations during intercourse without orgasm achievement than in group B (0 %; p < 0.001). In addition, a significantly higher percentage of women in group A (72.3 %) experienced no sexual sensations or no orgasmic pleasure at all than in group B (0 %; p < 0.001). More women in group B (47.5 %) had unchanged sexual pleasure compared with patients of group A (10.8 %; p < 0.001). Conversely, a decrease in sexual pleasure/orgasm frequency was reported by less women in group A (4.6 %) than in group B (18.0 %; p < 0.01). However, at long-term follow-up (> 12 months), overall severe bladder/rectal/sexual dysfunctions were significantly more common among patients of group A (56 women, 86.2 %) than in group B (1 woman, 1.6 %; p < 0.001).<sup>6</sup>

In 2014, a prospective study of *Mangler et al.* assessed the quality of a combined vaginal-abdominal surgical approach to rectovaginal endometriosis by evaluating long-term outcome and recurrence rates.<sup>33</sup> One hundred and ten women with endometriosis of the rectovaginal septum were included in this study; bowel infiltration was demonstrated intraoperatively and treated by a nerve-sparing, mesentery-preserving vaginal-abdominal operative technique. Bowel-infiltrating disease was confirmed during surgery in 71 (64.5%) women; non-infiltrating endometriosis with no involvement of the bowel surface was detected among 39 (35.5%) women. The average operative time was 230 minutes (range, 82–600 minutes). However, it was significantly longer in the group with bowel-infiltrating endometriosis (268.3 minutes) than in the non-infiltrating group (162.6 minutes;  $p < 0.001$ ). A segmental resection of the rectosigmoid was performed in 71 patients (64.5%). In the bowel-infiltrating group, the bladder was involved in 23 women (32.5%), 5 of whom had a partial bladder resection (7.0%); the ureter was affected in 12 patients (16.9%), 4 of whom required resection and ureteric reimplantation (5.6%). In the non-infiltrating group, the bladder was affected in 9 patients (23.1%), 2 of whom required partial bladder resection (5.1%), while the ureter was involved in 2 patients (5.1%). No long-term complication was reported. At a median follow-up of 64 months, no recurrence in the rectovaginal septum was observed among the study patients. Two women in the group with intestinal infiltration had residual urine at discharge from hospital. One woman had pre-existing self-catheterization. Another woman was only able to void the bladder completely by pressing after the surgery. One patient in the non-infiltrating group had voiding problems, but urine retention resolved after 3 weeks. After a median follow-up of 64 months, no recurrence in the rectovaginal septum and no long-term complication were reported.<sup>33</sup>

*Che et al.* conducted a prospective study to investigate the efficacy of nerve-sparing surgery for deeply infiltrating endometriosis and functional complications after this procedure.<sup>10</sup> A total of 108 patients who underwent conventional surgery (group A,  $n = 63$ ) and nerve-sparing surgery (group B,  $n = 45$ ) were included in the study. The rate of resections of the USLs, vaginal, ureter, bladder, parametrial, cul de sac, and bowel lesions were similar in the two study groups. After surgery, 9 women (15.9%) required self-catheterization with an average duration of 56 days (25 days to 8 months) in group A, while no patient required self-catheterization postoperatively in group B. Based on the *International Prostate Symptom Score* (IPSS), a significant alteration in voiding symptoms in group A was observed at 6 months, but not at 12 months or 24 months after surgery, whereas in group B no significant difference was reported after surgery. At follow-up, the intensity of pain symptoms was significantly reduced in both groups, although two patients (4.4%) in group B had no amelioration. The Total Female Sexual Function Index (FSFI) score and each domain score significantly improved in the two study groups after surgery except for the satisfaction domain score documented at 24-month follow up in group A.<sup>10</sup>

In a retrospective case series study, *Possover* evaluated 47 consecutive patients who suffered from urine retention after surgery for deep infiltrating endometriosis and reported

normal bladder sensation and bladder voiding function before surgery.<sup>46</sup> The mean interval from the surgery was 9.5 years (range, 7–15 years). Eighteen patients had acute paralytic motor bladder atony and 5 had acute neurogenic bladder atony. Twenty-four patients developed chronic neurogenic bladder atony. The first symptom of chronic urine retention was reduced urinary frequency; the most frequent complaints reported by the patients were a weak urinary stream and the need for Valsalva or Crede maneuver for bladder voiding. This study showed that segmental rectum resection with parametric resection exposes the most patients to the risk of a motor paralytic neurogenic bladder. However, the most frequent aetiology seemed to be chronic myogenic destruction secondary to chronic bladder overdistention.<sup>46</sup>

#### 4.6.4 Treatment of Endometriosis-Related Sacral Radiculopathies, Sciatica and Pudendal Neuralgia

Endometriosis may be the cause of sacral radiculopathies and other pelvic neuropathies.<sup>7,34,48,73</sup> In 2007, *Possover et al.* published their experience with 21 patients subjected to laparoscopic neurolysis of the plexus sacralis and the sciatic nerve combined with the LANN technique for the treatment of deep endometriotic infiltration of the lateral pelvic wall. This study demonstrated that laparoscopic neurolysis of the pelvic somatic nerves is a feasible procedure for trained laparoscopic surgeons who have a good knowledge of the retroperitoneal pelvic neuroanatomy.<sup>48</sup> In 2009, *Possover* conducted a retrospective study to assess the feasibility of the laparoscopic transperitoneal approach to the pelvic somatic nerves for the diagnosis and treatment of anogenital pain caused by pudendal and/or sacral nerve root lesions.<sup>41</sup> The study was based on a total of 134 patients of which 50 had endometriosis (sacral plexus endometriosis infiltration in 39 cases, sciatic nerve isolated endometriosis in 4 cases and sacral nerve roots S2/S3 entrapment by parametrium fibrosis secondary to endometriosis in 7 cases). Endometriosis lesions involving the sacral plexus caused a reduction in the mean ( $\pm$  SD) preoperative visual analogue scale score of  $8.7 \pm 1.9$  to  $1.1 \pm 0.7$  cm at a mean follow-up of 21 months in 78% of women.

A prospective cohort study including 213 patients who underwent laparoscopic management of sacral radiculopathy (sciatica, pudendal, gluteal pain) of unknown genesis was published in 2011.<sup>54</sup> Laparoscopy demonstrated isolated endometriosis of the sciatic nerve in 27 women, deeply infiltrating parametric endometriosis with sacral plexus infiltration in 148 women, sacral plexus vascular entrapment in 37 women, and pyriformis syndrome in one woman. Patients with sciatic nerve involvement were treated as follows: opening of the sciatic perineurium with intrafascicular neurolysis, excision of the lesion, and superficial coagulation of the entire sciatic foramen were performed in all patients. From a total of 27 women, 11 required an extended dissection of the nerve through the greater sciatic foramen downward to the gluteal region. Mean reduction ( $\pm$  SD) of visual analogue scale pain scores in patients with endometriosis at 6-month follow-up was significant ( $2.6 \pm 1.8$  cm) in comparison with baseline ( $7.7 \pm 1.2$  cm).<sup>54</sup>

#### 4.6.4.1 LION Procedure

Sacral nerve stimulation (SNS) is a technique originally developed for the treatment of chronic pelvic voiding dysfunctions to be considered after failure of medical treatments. The main indications of SNS are idiopathic detrusor overactivity leading to overactive bladder<sup>26</sup> and Fowler's syndrome.<sup>22</sup> Other clinical applications of SNS are neurogenic lower urinary tract dysfunction,<sup>70</sup> lower bowel motility dysfunctions (such as severe constipation)<sup>21,25</sup> and chronic pelvic pain.<sup>35</sup> Originally, the placement of neurostimulation electrodes was performed by open surgery<sup>62</sup> which later was abandoned in favor of an alternative option using a minimally invasive percutaneous approach performed under local anaesthesia.<sup>63</sup> However, the main limitation of the percutaneous transforaminal procedure lies in the fact that the method affords only stimulation of one sacral nerve root by one electrode. This deficiency has prompted the decision to adopt a laparoscopic approach which, in fact, allows a reproducible exposure of all pelvic motor and autonomic nerves and plexi. Hence, in this way, implantation of neurostimulation electrodes onto the pelvic nerves became feasible.<sup>47</sup> The technique has been called 'LION procedure' (*Laparoscopic Implantation Of Neuroprosthesis*) and has been implemented in the treatment of refractory pelvic and abdominal neuralgia/neuropathia,<sup>42,47</sup> the restoration of bladder function after spinal cord injury,<sup>49</sup> or after pelvic nerve destruction,<sup>50</sup> and in the treatment of various neurogenic dysfunctions of the bladder.<sup>44</sup> The procedure consists of a complete laparoscopic exposure of the SHP between the level of the inferior mesenteric artery and the aortic bifurcation, followed by placement of a multiple-channel electrode encompassing the entire SHP. In the papers published so far on the LION technique, the authors reported on the use of multiple-channel-type electrodes 'On-Point PNS, Model 3987' (Medtronic GmbH, 40670 Meerbusch, Germany). Systematic fixation was performed with a nonabsorbable 5-0 suture, while the cable was passed extraperitoneally under the descending colon avoiding any contact with the left ureter before connecting it to an external test stimulator.<sup>42,47</sup> Then, a permanent stimulator (type InterStim<sup>®</sup>, model no. 3023, Medtronic GmbH Germany;<sup>47</sup> or ITEL 3 Neurostimulation System, Medtronic GmbH, Germany)<sup>42</sup> was implanted. The decision-making as to whether a permanent stimulator should be implanted was based on a preliminary test phase of external electrostimulation over several days using alternating 'on'/'off' phases to enable an objective assessment of the efficacy of neuromodulation.

In 2009, *Possover* and *Chiantera* published a report investigating the impact of neuromodulation of the SHP in a small series of patients with bladder atonia secondary to pelvic surgery (including one case of surgery for deep infiltrating endometriosis). In 4 consecutive patients with bladder atonia secondary to pelvic surgery, the LION procedure was applied to the entire SHP. The study provided evidence that after laparoscopic implantation of a neurostimulator, one patient reported on full recovery of bladder function, two patients were able to obtain partial voiding while one patient did not report any improvement.<sup>50</sup>

#### 4.6.5 Discussion

Exposure of pelvic nerves during surgical treatment of endometriosis has become feasible not only on account of advancements made in the field of pelvic neuroanatomy, but also with regard to specific techniques that have been integrated in laparoscopic surgery to identify even tiny nerves in the depth of the pelvis.<sup>51</sup> Pelvic nerve injury secondary to operative procedures can precipitate pelvic visceral and sexual dysfunctions, problems with locomotion and various types of pain.<sup>45</sup> In this context, the ureter, is used as the key anatomical surgical landmark which delineates the upper boundaries of the IHP and of its vesical, vaginal and rectal efferences. Transgression of these boundaries is associated with an elevated risk of nerve lesions to the efferences of the IHP.<sup>37</sup> Damage to the upper two to three centimeters of the IHP induces hypoanesthesia of the fornix and the dorsal vaginal cuff, whereas damage to the middle part of the plexus may account for sensory bladder disorders. Detrusor motor dysfunctions (parasympathetic nerve damage) first occur by injury to the lower part of the plexus (approximately 3 cm caudal to the level of the pouch of Douglas).<sup>46</sup> Similarly, intraoperative injuries of fibres supplying the anal sphincter may cause terminal constipation of the bowel.<sup>1</sup> Surgical release of PSNs from endometriosis may not always be technically feasible because sometimes the disease directly involves the nerves supplying the rectum and the bladder. However, rectovaginal deep endometriosis is often associated with unilateral involvement of parametric tissues, so that it should be feasible to preserve integrity of the pelvic splanchnic nerves on the unaffected side. Considering that surgical maneuvers performed in the lower rectum are prone to reach the proximity of efferent nerve branches of the IHP, this may result in injuries not only from fibre sectioning, but also from necrosis due to lateral thermal diffusion.<sup>1</sup> The surgeon's knowledge of the anatomy of the autonomic pelvic nerves is a crucial factor in the prevention of nerve damage and related functional complications occurring during radical surgery for deep endometriosis. In fact, numerous studies have demonstrated the inherent benefits of laparoscopic nerve-sparing surgery in comparison to classical procedures with regard to preservation of bladder, rectal and sexual function.<sup>6,10,28</sup> Nerve-sparing techniques require a high level of experience in the treatment of deep infiltrating endometriosis and in laparoscopic surgery, hence, more complicated cases should be referred to tertiary specialized centres. Future studies should be designed to further elucidate the role of the LION technique in patients with pain refractory to conventional treatment and in those with long-term functional complications.

#### 4.6.6 Conclusion

Neuropelvelogy is an extremely innovative and continuously evolving medical specialty, which focuses on the prevention, diagnosis and treatment of pathologies of the pelvic nerves and plexuses. Good knowledge of neurology, pelvic neuroanatomy, pathologies of the pelvic organs and extensive training in laparoscopic (neuro-)surgery are core skills that form the backbone of daily work in this multidisciplinary field. By integrating selective nerve-sparing techniques into the various approaches currently used in laparoscopic gynecology,



neuropelveology opens up new prospects in the treatment of a wide range of pathologies. Omission of the pelvic nerves in medicine is no longer acceptable and continuing significant efforts should be made in the field of clinical and experimental laparoscopic research to further improve the nerve-sparing techniques.

#### 4.6.7 Acknowledgment

The authors are grateful to Prof. *Renato Seracchioli*, University of Bologna, Italy, who provided [Figs 4.24](#) and [4.25](#).

#### 4.6.8 References

- ARMENGOL-DEBEIR L, SAVOYE G, LEROI AM, GOURCEROL G, SAVOYE-COLLET C, TUECH JJ et al. Pathophysiological approach to bowel dysfunction after segmental colorectal resection for deep endometriosis infiltrating the rectum: a preliminary study. *Human reproduction (Oxford, England)* 2011;26(9):2330–5. doi:10.1093/humrep/der190.
- BAADER B, HERRMANN M. Topography of the pelvic autonomic nervous system and its potential impact on surgical intervention in the pelvis. *Clinical anatomy (New York, N.Y.)* 2003;16(2):119–30. doi:10.1002/ca.10105.
- BARTON DP, BUTLER-MANUEL SA, BUTTERY LD, A'HERN RP, POLAK JM. A nerve-sparing radical hysterectomy: guidelines and feasibility in Western patients. *International journal of gynecological cancer official journal of the International Gynecological Cancer Society* 2002;12(3):319; author reply 321.
- BOGANI G, CROMI A, UCCELLA S, SERATI M, CASARIN J, PINELLI C et al. Nerve-sparing versus conventional laparoscopic radical hysterectomy: a minimum 12 months' follow-up study. *International journal of gynecological cancer official journal of the International Gynecological Cancer Society* 2014;24(4):787–93. doi:10.1097/igc.000000000000110.
- CECCARONI M, CLARIZIA R, ALBONI C, RUFFO G, BRUNI F, ROVIGLIONE G et al. Laparoscopic nerve-sparing transperitoneal approach for endometriosis infiltrating the pelvic wall and somatic nerves: anatomical considerations and surgical technique. *Surgical and radiologic anatomy SRA* 2010;32(6):601–4. doi:10.1007/s00276-010-0624-6.
- CECCARONI M, CLARIZIA R, BRUNI F, D'URSO E, GAGLIARDI ML, ROVIGLIONE G et al. Nerve-sparing laparoscopic eradication of deep endometriosis with segmental rectal and parametrial resection: the Negrar method. A single-center, prospective, clinical trial. *Surgical endoscopy* 2012;26(7):2029–45. doi:10.1007/s00464-012-2153-3.
- CECCARONI M, CLARIZIA R, ROVIGLIONE G, BRUNI F, RUFFO G, PETERS I et al. Deep rectal and parametrial infiltrating endometriosis with monolateral pudendal nerve involvement: case report and laparoscopic nerve-sparing approach. *European journal of obstetrics, gynecology, and reproductive biology* 2010;153(2):227–9. doi:10.1016/j.ejogrb.2010.07.032.
- CECCARONI M, PONTRELLI G, SCIOSCIA M, RUFFO G, BRUNI F, MINELLI L. Nerve-sparing laparoscopic radical excision of deep endometriosis with rectal and parametrial resection. *Journal of minimally invasive gynecology* 2010;17(1):14–5. doi:10.1016/j.jmig.2009.03.018.
- CECCARONI M, PONTRELLI G, SPAGNOLO E, SCIOSCIA M, BRUNI F, PAGLIA A et al. Parametrial dissection during laparoscopic nerve-sparing radical hysterectomy: a new approach aims to improve patients' postoperative quality of life. *American journal of obstetrics and gynecology* 2010;202(3):320.e1–2. doi:10.1016/j.ajog.2009.12.019.
- CHE X, HUANG X, ZHANG J, XU H, ZHANG X. Is nerve-sparing surgery suitable for deeply infiltrating endometriosis? *European journal of obstetrics, gynecology, and reproductive biology* 2014;175:87–91. doi:10.1016/j.ejogrb.2014.01.027.
- CIBULA D, VELECHOVSKA P, SLAMA J, FISCHEROVA D, PINKAVOVA I, PAVLISTA D et al. Late morbidity following nerve-sparing radical hysterectomy. *Gynecologic oncology* 2010;116(3):506–11. doi:10.1016/j.ygyno.2009.10.061.
- CICCO C DE, CORONA R, SCHONMAN R, MAILOVA K, USSIA A, KONINCKX P. Bowel resection for deep endometriosis: a systematic review. *BJOG an international journal of obstetrics and gynaecology* 2011;118(3):285–91. doi:10.1111/j.1471-0528.2010.02744.x.
- DARAI E, THOMASSIN I, BARRANGER E, DETCHEV R, CORTEZ A, HOURY S et al. Feasibility and clinical outcome of laparoscopic colorectal resection for endometriosis. *American journal of obstetrics and gynecology* 2005;192(2):394–400. doi:10.1016/j.ajog.2004.08.033.
- DONNEZ J, NISOLLE M, GILLEROT S, SMETS M, BASSIL S, CASANAS-ROUX F. Rectovaginal septum adenomyotic nodules: a series of 500 cases. *British journal of obstetrics and gynaecology* 1997;104(9):1014–8.
- DUBERNARD G, ROUZIER R, DAVID-MONTEFIORE E, BAZOT M, DARAI E. Urinary complications after surgery for posterior deep infiltrating endometriosis are related to the extent of dissection and to uterosacral ligaments resection. *Journal of minimally invasive gynecology* 2008;15(2):235–40. doi:10.1016/j.jmig.2007.10.009.
- FERRERO S, ABBAMONTE LH, GIORDANO M, RAGNI N, REMORGIDA V. Deep dyspareunia and sex life after laparoscopic excision of endometriosis. *Human reproduction (Oxford, England)* 2007;22(4):1142–8. doi:10.1093/humrep/del465.
- FUJII S. Nerve-sparing radical hysterectomy. In: Abu-Rustum, NR, Barakat, RR, Levine, DA., editor. *Atlas of procedures in gynecologic oncology*. Boca Raton, FL, USA: CRC Press; 2013. p. 121–9.
- FUJII S, TAKAKURA K, MATSUMURA N, HIGUCHI T, YURA S, MANDAI M et al. Anatomic identification and functional outcomes of the nerve sparing Okabayashi radical hysterectomy. *Gynecologic oncology* 2007;107(1):4–13. doi:10.1016/j.ygyno.2007.08.076.
- FUJIWARA T. *Surgery for cervical cancer*. Tokyo: Igakushoin; 1983.
- FURTMULLER GJ, MCKENNA CA, EBMER J, DELLON AL. Pudendal nerve 3-dimensional illustration gives insight into surgical approaches. *Annals of plastic surgery* 2014;73(6):670–8. doi:10.1097/sap.0000000000000169.
- HOLZER B, ROSEN HR, NOVI G, AUSCH C, HOLBLING N, HOFMANN M et al. Sacral nerve stimulation in patients with severe constipation. *Diseases of the colon and rectum* 2008;51(5):524–29; discussion 529–30. doi:10.1007/s10350-007-9160-9.
- JONAS U, FOWLER CJ, CHANCELLOR MB, ELHILALI MM, FALL M, GAJEWSKI JB et al. Efficacy of sacral nerve stimulation for urinary retention: results 18 months after implantation. *The Journal of urology* 2001;165(1):15–9.
- KAVALLARIS A, BANZ C, CHALVATZAS N, HORNEMANN A, LUEDDERS D, DIEDRICH K et al. Laparoscopic nerve-sparing surgery of deep infiltrating endometriosis: description of the technique and patients' outcome. *Archives of gynecology and obstetrics* 2011;284(1):131–5. doi:10.1007/s00404-010-1624-9.
- KAVALLARIS A, HORNEMANN A, CHALVATZAS N, LUEDDERS D, DIEDRICH K, BOHLMANN MK. Laparoscopic nerve-sparing radical hysterectomy: description of the technique and patients' outcome. *Gynecologic oncology* 2010;119(2):198–201. doi:10.1016/j.ygyno.2010.07.020.

25. KENEFICK NJ. Sacral nerve neuromodulation for the treatment of lower bowel motility disorders. *Annals of the Royal College of Surgeons of England* 2006;88(7):617–23. doi:10.1308/003588406x149174.
26. KERREBROECK PE VAN, VOSKUILEN AC VAN, HEESAKKERS JP, LYCKLAMA A NIJHOLT AA, SIEGEL S, JONAS U et al. Results of sacral neuromodulation therapy for urinary voiding dysfunction: outcomes of a prospective, worldwide clinical study. *The Journal of urology* 2007;178(5):2029–34. doi:10.1016/j.juro.2007.07.032.
27. KOBAYASHI T. Abdominal radical hysterectomy with pelvic lymphadenectomy for cancer of the cervix. Tokyo: Nanzando; 1961.
28. LANDI S, CECCARONI M, PERUTELLI A, ALLODI C, BARBIERI F, FIACCAVENTO A et al. Laparoscopic nerve-sparing complete excision of deep endometriosis: is it feasible? *Human reproduction (Oxford, England)* 2006;21(3):774–81. doi:10.1093/humrep/dei324.
29. LEMOS N, SOUZA C, MARQUES RM, KAMERGORODSKY G, SCHOR E, GIRAO MJ. Laparoscopic anatomy of the autonomic nerves of the pelvis and the concept of nerve-sparing surgery by direct visualization of autonomic nerve bundles. *Fertility and sterility* 2015;104(5):e11–2. doi:10.1016/j.fertnstert.2015.07.1138.
30. MAAS K, MORIYA Y, KENTER G, TRIMBOS B, VAN DE VELDE C. A plea for preservation of the pelvic autonomic nerves. *Lancet (London, England)* 1999;354(9180):772–3. doi:10.1016/s0140-6736(05)76009-8.
31. MAHAKKANUKRAUH P, SURIN P, VAIDHAYAKARN P. Anatomical study of the pudendal nerve adjacent to the sacrospinous ligament. *Clinical anatomy (New York, N.Y.)* 2005;18(3):200–5. doi:10.1002/ca.20084.
32. MALDONADO PA, CHIN K, GARCIA AA, CORTON MM. Anatomic variations of pudendal nerve within pelvis and pudendal canal: clinical applications. *American journal of obstetrics and gynecology* 2015;213(5):727.e1–6. doi:10.1016/j.ajog.2015.06.009.
33. MANGLER M, HERBSTLEB J, MECHSNER S, BARTLEY J, SCHNEIDER A, KOHLER C. Long-term follow-up and recurrence rate after mesorectum-sparing bowel resection among women with rectovaginal endometriosis. *International journal of gynaecology and obstetrics: the official organ of the International Federation of Gynaecology and Obstetrics* 2014;125(3):266–9. doi:10.1016/j.ijgo.2013.12.010.
34. MANNAN K, ALTAF F, MANIAR S, TIRABOSCO R, SINISI M, CARLSTEDT T. Cyclical sciatica: endometriosis of the sciatic nerve. *The Journal of bone and joint surgery. British volume* 2008;90(1):98–101. doi:10.1302/0301-620x.90b1.19832.
35. MARTELLUCCI J, NALDINI G, CARRIERO A. Sacral nerve modulation in the treatment of chronic pelvic pain. *International journal of colorectal disease* 2012;27(7):921–6. doi:10.1007/s00384-011-1394-2.
36. MAUROY B, BIZET B, BONNAL JL, CROMBET T, DUBURCQ T, HURT C. Systematization of the vesical and uterovaginal efferences of the female inferior hypogastric plexus (pelvic): applications to pelvic surgery on women patients. *Surgical and radiologic anatomy SRA* 2007;29(3):209–17. doi:10.1007/s00276-007-0195-3.
37. MAUROY B, DEMONDION X, BIZET B, CLARET A, MESTDAGH P, HURT C. The female inferior hypogastric (= pelvic) plexus: anatomical and radiological description of the plexus and its afferences – applications to pelvic surgery. *Surgical and radiologic anatomy SRA* 2007;29(1):55–66. doi:10.1007/s00276-006-0171-3.
38. MAUROY B, DEMONDION X, DRIZENKO A, GOULLET E, BONNAL JL, BISERTE J et al. The inferior hypogastric plexus (pelvic plexus): its importance in neural preservation techniques. *Surgical and radiologic anatomy SRA* 2003;25(1):6–15. doi:10.1007/s00276-002-0083-9.
39. MEULEMAN C, TOMASSETTI C, D'HOORE A, VAN CLEYNENBREUGEL B, PENNINGCKX F, VERGOTE I et al. Surgical treatment of deeply infiltrating endometriosis with colorectal involvement. *Human reproduction update* 2011;17(3):311–26. doi:10.1093/humupd/dmq057.
40. MONTOYA TI, CALVER L, CARRICK KS, PRATS J, CORTON MM. Anatomic relationships of the pudendal nerve branches. *American journal of obstetrics and gynecology* 2011;205(5):504.e1–5. doi:10.1016/j.ajog.2011.07.014.
41. POSSOVER M. Laparoscopic management of endopelvic etiologies of pudendal pain in 134 consecutive patients. *The Journal of urology* 2009;181(4):1732–6. doi:10.1016/j.juro.2008.11.096.
42. POSSOVER M. Laparoscopic management of neural pelvic pain in women secondary to pelvic surgery. *Fertility and sterility* 2009;91(6):2720–5. doi:10.1016/j.fertnstert.2008.04.021.
43. POSSOVER M. Intractable neural pelvic pain. In: Gornall V, Brill AI, editors. *Reconstructive and reproductive surgery in gynecology*. London, UK: Informa Healthcare; 2010. p. 200–9.
44. POSSOVER M. The laparoscopic implantation of neuroprosthesis to the sacral plexus for therapy of neurogenic bladder dysfunctions after failure of percutaneous sacral nerve stimulation. *Neuromodulation journal of the International Neuromodulation Society* 2010;13(2):141–4. doi:10.1111/j.1525-1403.2009.00230.x.
45. POSSOVER M. The neuropelvelogy: a new speciality in medicine? *Pelvipelvineology* 2010;29:123–4.
46. POSSOVER M. Pathophysiologic explanation for bladder retention in patients after laparoscopic surgery for deeply infiltrating rectovaginal and/or parametric endometriosis. *Fertility and sterility* 2014;101(3):754–8. doi:10.1016/j.fertnstert.2013.12.019.
47. POSSOVER M, BAEKELANDT J, CHIANTERA V. The laparoscopic approach to control intractable pelvic neuralgia: from laparoscopic pelvic neurosurgery to the LION procedure. *The Clinical journal of pain* 2007;23(9):821–5. doi:10.1097/AJP.0b013e31815349a8.
48. POSSOVER M, BAEKELANDT J, FLASKAMP C, LI D, CHIANTERA V. Laparoscopic neurolysis of the sacral plexus and the sciatic nerve for extensive endometriosis of the pelvic wall. *Minimally invasive neurosurgery MIN* 2007;50(1):33–6. doi:10.1055/s-2007-970075.
49. POSSOVER M, BAEKELANDT J, KAUFMANN A, CHIANTERA V. Laparoscopic endopelvic sacral implantation of a Brindley controller for recovery of bladder function in a paralyzed patient. *Spinal cord* 2008;46(1):70–3. doi:10.1038/sj.sc.3102065.
50. POSSOVER M, CHIANTERA V. Neuromodulation of the superior hypogastric plexus: a new option to treat bladder atonia secondary to radical pelvic surgery? *Surgical neurology* 2009;72(6):573–6. doi:10.1016/j.surneu.2009.06.009.
51. POSSOVER M, CHIANTERA V, BAEKELANDT J. Anatomy of the Sacral Roots and the Pelvic Splanchnic Nerves in Women Using the LANN Technique. *Surgical laparoscopy, endoscopy & percutaneous techniques* 2007;17(6):508–10. doi:10.1097/SLE.0b013e31812f81e4.
52. POSSOVER M, FORMAN A, RABISCHONG B, LEMOS N, CHIANTERA V. Neuropelvelogy: New Groundbreaking Discipline in Medicine. *Journal of minimally invasive gynecology* 2015;22(7):1140–1. doi:10.1016/j.jmig.2015.06.009.
53. POSSOVER M, QUAKERNACK J, CHIANTERA V. The LANN technique to reduce postoperative functional morbidity in laparoscopic radical pelvic surgery. *Journal of the American College of Surgeons* 2005;201(6):913–7. doi:10.1016/j.jamcollsurg.2005.07.006.

54. POSSOVER M, SCHNEIDER T, HENLE KP. Laparoscopic therapy for endometriosis and vascular entrapment of sacral plexus. *Fertility and sterility* 2011;95(2):756–8. doi:10.1016/j.fertnstert.2010.08.048.
55. POSSOVER M, STOBER S, PLAUL K, SCHNEIDER A. Identification and preservation of the motoric innervation of the bladder in radical hysterectomy type III. *Gynecologic oncology* 2000;79(2):154–7. doi:10.1006/gyno.2000.5919.
56. QUERLEU D, NARDUCCI F, POULARD V, LACAZE S, OCCELLI B, LEBLANC E et al. Modified radical vaginal hysterectomy with or without laparoscopic nerve-sparing dissection: a comparative study. *Gynecologic oncology* 2002;85(1):154–8. doi:10.1006/gyno.2002.6588.
57. REDWINE DB, WRIGHT JT. Laparoscopic treatment of complete obliteration of the cul-de-sac associated with endometriosis: long-term follow-up of en bloc resection. *Fertility and sterility* 2001;76(2):358–65.
58. REMORGIDA V, FERRERO S, FULCHERI E, RAGNI N, MARTIN DC. Bowel endometriosis: presentation, diagnosis, and treatment. *Obstetrical & gynecological survey* 2007;62(7):461–70. doi:10.1097/01.ogx.0000268688.55653.5c.
59. ROB L, HALASKA M, ROBOVA H. Nerve-sparing and individually tailored surgery for cervical cancer. *The Lancet. Oncology* 2010;11(3):292–301. doi:10.1016/s1470-2045(09)70191-3.
60. SCHRAFFORDT SE, TJANDRA JJ, EIZENBERG N, DWYER PL. Anatomy of the pudendal nerve and its terminal branches: a cadaver study. *ANZ journal of surgery* 2004;74(1-2):23–6.
61. SHAFIK A, EL-SHERIF M, YOUSSEF A, OLFAT ES. Surgical anatomy of the pudendal nerve and its clinical implications. *Clinical anatomy (New York, N.Y.)* 1995;8(2):110–5. doi:10.1002/ca.980080205.
62. SIEGEL SW. Management of voiding dysfunction with an implantable neuroprosthesis. *The Urologic clinics of North America* 1992;19(1):163–70.
63. SPINELLI M, GIARDIELLO G, GERBER M, ARDUINI A, VAN DEN HOMBERGH U, MALAGUTI S. New sacral neuromodulation lead for percutaneous implantation using local anesthesia: description and first experience. *The Journal of urology* 2003;170(5):1905–7. doi:10.1097/01.ju.0000092634.64580.9a.
64. TARJANNE S, HEIKINHEIMO O, MENTULA M, HARKKI P. Complications and long-term follow-up on colorectal resections in the treatment of deep infiltrating endometriosis extending to bowel wall. *Acta obstetrica et gynecologica Scandinavica* 2015;94(1):72–9. doi:10.1111/aogs.12515.
65. THOMASSIN I, BAZOT M, DETCHEV R, BARRANGER E, CORTEZ A, DARAI E. Symptoms before and after surgical removal of colorectal endometriosis that are assessed by magnetic resonance imaging and rectal endoscopic sonography. *American journal of obstetrics and gynecology* 2004;190(5):1264–71. doi:10.1016/j.ajog.2003.12.004.
66. VOLPI E, FERRERO A, SISMONDI P. Laparoscopic identification of pelvic nerves in patients with deep infiltrating endometriosis. *Surgical endoscopy* 2004;18(7):1109–12. doi:10.1007/s00464-003-9115-8.
67. WANG GJ, GAO CF, WEI D, WANG C, MENG WJ. Anatomy of the lateral ligaments of the rectum: a controversial point of view. *World journal of gastroenterology* 2010;16(43):5411–5.
68. WERTHEIM E. Die erweiterte abdominale Operation bei Carcinoma colli uteri (auf Grund von 500 Fällen). Berlin: Urban & Schwarzenberg; 1911.
69. WILLARD F, SCHUENKE M. The neuroanatomy of female pelvic pain. In: Bailey, A. Bernstein, C., editor. *Pain in women*. New York: Springer; 2013. p. 17–58.
70. WOLLNER J, KREBS J, PANNEK J. Sacral neuromodulation in patients with neurogenic lower urinary tract dysfunction. *Spinal cord* 2015. doi:10.1038/sc.2015.124.
71. YABUKI Y, ASAMOTO A, HOSHIBA T, NISHIMOTO H, NISHIKAWA Y, NAKAJIMA T. Radical hysterectomy: An anatomic evaluation of parametrial dissection. *Gynecologic oncology* 2000;77(1):155–63. doi:10.1006/gyno.1999.5723.
72. YABUKI Y, ASAMOTO A, HOSHIBA T, NISHIMOTO H, SATOU N. A new proposal for radical hysterectomy. *Gynecologic oncology* 1996;62(3):370–8. doi:10.1006/gyno.1996.0251.
73. ZAGER EL, PFEIFER SM, BROWN MJ, TOROSIAN MH, HACKNEY DB. Catamenial mononeuropathy and radiculopathy: a treatable neuropathic disorder. *Journal of neurosurgery* 1998;88(5):827–30. doi:10.3171/jns.1998.88.5.0827.
74. ZANATTA A, ROSIN MM, MACHADO RL, CAVA L, POSSOVER M. Laparoscopic dissection and anatomy of sacral nerve roots and pelvic splanchnic nerves. *Journal of minimally invasive gynecology* 2014;21(6):982–3. doi:10.1016/j.jmig.2014.07.006.



## 4.7

## Recurrent Endometriosis

Martin Sillem<sup>a</sup>

## 4.7.1 Introduction

Endometriosis is a disease that presents with any combination of three symptoms: cyclic pelvic pain, infertility, and pelvic masses. A relapse or recurrence is best defined as the presence of these symptoms after the previous diagnosis and treatment of the condition (see Table 4.7).

**Factors contributing to the recurrence of endometriosis-related symptoms**

- Chronic nature of the disease itself.
- Ineffective medical treatment.
- Premature discontinuation of effective medical treatment.
- Inadequate surgical treatment.
- Incomplete surgical treatment.

Table 4.7

Reported recurrence rates vary over an extremely wide range. This is not surprising when we consider that therapy is instituted for subjective complaints and it is difficult to determine an objective endpoint for treatment. In a very scholarly article that also reviews the possible mechanisms of recurrence, Guo<sup>11</sup> calculated the recurrence risk of any form of endometriosis or any symptom related to the disease to be approximately 20% two years after primary treatment and, with even less certainty, approximately 50% at five years.

## 4.7.2 Prevention of Recurrence

Since no causal treatments for endometriosis have been established so far, correct diagnosis and clinical management in the primary setting are crucial for keeping recurrence rates as low as possible. In this section we will review some effective approaches to the prevention of recurrent disease.

## 4.7.2.1 Prevention of Recurrence Due to Misdiagnosis

The long-term efficacy of any treatment depends critically upon an accurate diagnosis regarding the cause of symptoms and the extent of pathologic changes.

Endometriosis is often described as an enigmatic condition that presents with a great variety of symptoms. However, dysmenorrhoea is almost always present on initial diagnosis.<sup>2</sup> If this variety of symptoms is present without a predominance of dysmenorrhoea, other possible diagnoses should be considered in order to avoid symptom recurrence or persistence due to treatment that is predictably ineffective for the true condition at hand.

Laparoscopy is the gold standard for diagnosing endometriosis, as it is usually the best method for obtaining histologic proof. However, if it is not combined with thorough palpation of the pelvic connective tissues, laparoscopy may reveal only the 'tip of the iceberg' while missing the true extent of disease (Figs. 4.26a–c). This underdiagnosis can have serious consequences if, for example, the examiner misses ureteral involvement that culminates in hydronephrosis.

While the above situation is rare, not infrequently pain symptoms are erroneously assigned to minimal endometriosis, while the true cause goes undiagnosed. Sporadic superficial endometriosis implants are present in approximately 20% of women at tubal ligation.<sup>17</sup> Other frequent causes of chronic pelvic pain in women are pelvic-floor muscle tenderness<sup>18</sup> (Fig. 4.27) and somatoform pain disorder.<sup>19</sup> Failure to recognize the presence of these conditions will invariably lead to symptom recurrence or persistence despite therapies that are proven to be effective for endometriosis.

<sup>a</sup> | Associate Professor, MD; Private Clinical Center 'Am Rosengarten', Mannheim, Germany

## Corresponding author:

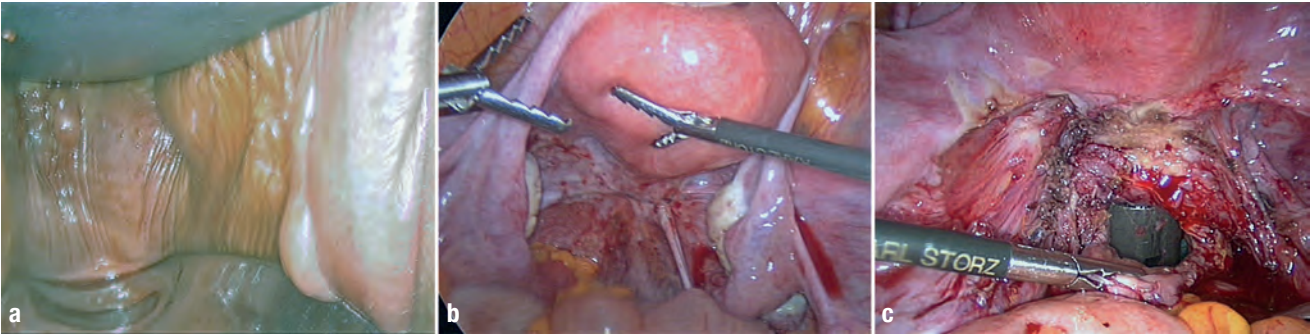
Priv.-Doz. Dr. med. **Martin Sillem**

Praxisklinik am Rosengarten

Augustaanlage 7–11

68165 Mannheim, Germany

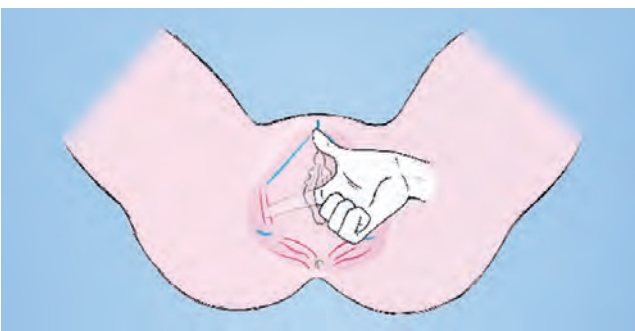
E-mail: msillem@praxisklinik-am-rosengarten.de



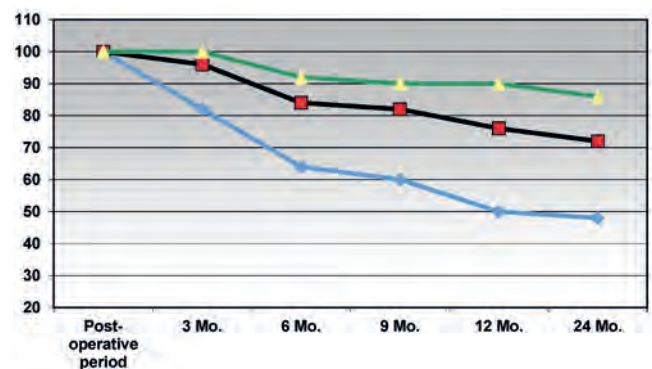
**Fig. 4.26a–c** ‘Tip of the iceberg.’ Failure to expose the posterior vaginal vault and palpate the pelvic connective tissue preoperatively will lead to underdiagnosis, undertreatment and persistence of disease, often misinterpreted as a recurrence. Endometriotic lesions in the posterior vaginal vault are indicative of deep infiltrating disease (a). (b) Same patient as in (a). Cul-de-sac lesions consistent with minimal endometriosis, assessed as stage I disease in the revised classification of the *American Society for Reproductive Medicine* (rASRM). Same patient as in (a, b). Endometriotic lesion in the vaginal vault exposed after colpotomy, ENZIAN A2 score (c).

#### 4.7.2.2 Prevention of Recurrence in the Treatment of Peritoneal Endometriosis

Laparoscopy for peritoneal endometriosis should always include the excision of at least one implant for histologic confirmation. Superficial implants can be excised or physically destroyed with equivalent results,<sup>4</sup> but the treatment of all foci is the goal. Even if this is accomplished, recurrence is common (Fig. 4.28) unless surgery is followed by long-term medical therapy, ideally aimed at the induction of amenorrhea. GnRH analogues, continuous oral contraceptives and progestins are probably equally effective in this regard.<sup>29</sup> Dienogest 2 mg has proven effective for pain relief, is well tolerated and is safe in terms of bone density.<sup>23</sup> The duration of treatment is determined by the patient’s desire for pregnancy, her age, and potential side effects rather than by virtue of expertise and experience on the part of the gynecologist.



**Fig. 4.27** Palpation of pelvic floor muscles. Drawing indicates the levator ani and obturator internus muscles, separated by the ‘white line.’ By courtesy of *Sillem M et al. Geburtshilfe Frauenheilkd* 2016.<sup>20</sup>



**Fig. 4.28** Recurrence rates of various types of endometriosis, based on a retrospective analysis of 492 patients operated for pain.<sup>13</sup> X-axis: time after surgery (months). Y-axis: percentage of pain-free patients. Ovarian endometriomas (△). Deep infiltrating disease (■). Peritoneal endometriosis (◆). By courtesy of *Hippach, M. et al. Zentralbl. Gynaekol* 2003.<sup>13</sup>

#### 4.7.2.3 Prevention of Recurrence in the Treatment of Ovarian Endometriomas

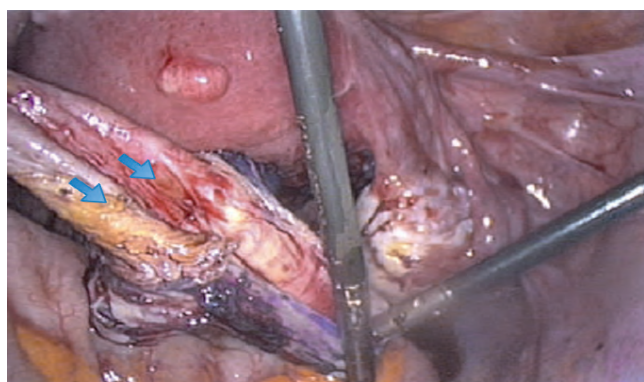
With ovarian endometriomas, recurrence is to be expected if treatment consists of fenestrating the cyst rather than removing the entire cyst wall<sup>12</sup> (Fig. 4.29). If pain is present and/or the cyst recurs despite correct surgical technique, denudation of the underlying pelvic sidewall should be considered<sup>5,16</sup> (Fig. 4.30). Generally speaking, the adherent cyst should be initially mobilized from the underlying pelvic sidewall by blunt dissection. There are three reasons for this:

1. The cyst may be opened at a site not covered by healthy ovarian tissue, obviating the need for dissection of the ovary.
2. The pelvic sidewall is now fully exposed and can be resected as deemed necessary.
3. The mobilized cyst can be resected at a safe distance from the ureter.

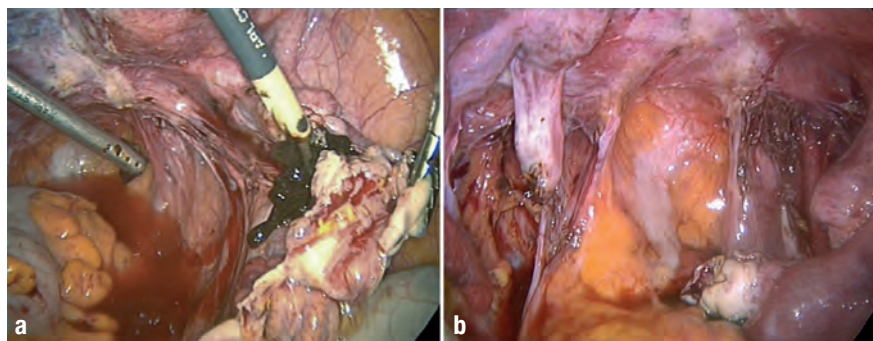
While ovarian endometriomas never fully resolve in response to primary medical therapy, there is a considerable body of evidence that favors continuous medical treatment to avoid recurrence and reoperation.<sup>29</sup> Considerations relating to the selection and duration of treatment apply as above.

#### 4.7.2.4 Prevention of Recurrence in the Treatment of Deep Infiltrating Disease

As discussed in other sections of this book, surgery for deep infiltrating endometriosis requires extensive planning and excellent surgical skills to yield high success rates with few complications. These standards are fulfilled most consistently at certified endometriosis centers.<sup>7,24</sup>



**Fig. 4.29** Excision of an endometriotic cyst. Note the follicles (blue arrows) that are being sacrificed.



**Fig. 4.30a,b** Mobilization of a right ovarian endometrioma (a). Pelvic sidewalls after the resection of endometriotic peritoneum (b).

In contrast to ovarian endometriomas, where cyst removal and recurrence can be established with reasonable certainty, this distinction is less clear-cut in the case of deep infiltrating lesions. The detection of deep endometriosis that has already been treated surgically may be due to incomplete removal (deliberate or inadvertent) or to the formation of new lesions, and it is often difficult to determine which is true. Consequently, a detailed description of the extent of disease, surgical procedure, and intraoperative rationale (e.g., a less radical excision to preserve fertility) should be recorded in the surgical report, ideally using the revised ENZIAN classification.<sup>25</sup> Complete surgical excision should be the goal whenever possible. If the patient's preference is unclear or the surgeon lacks the necessary technical expertise, it is wiser not to attempt a radical resection than to abandon it halfway through, since repeat surgery is fraught with higher complication rates.<sup>26</sup>

When surgery for deep infiltrating endometriosis is proposed in a woman who has completed her family planning, the inclusion of hysterectomy should be discussed as it is likely to reduce the rate of symptom recurrence. While data to support this concept are scarce and not recent,<sup>27</sup> it is clear that a high correlation exists between deep infiltrating endometriosis and adenomyosis<sup>10</sup> and that hysterectomy is an appropriate treatment for the latter condition. Conversely, performing a standard hysterectomy alone and leaving deep infiltrating endometriosis *in situ* for fear of complications will predictably lead to higher recurrence rates.<sup>8</sup>

Medical therapies to downstage the extent of disease prior to surgery and facilitate complete removal have been tested in several trials, but the results are not convincing. Hence it is not recommended by the *European Society of Human Reproduction and Embryology* (ESHRE).<sup>6</sup> More than being ineffective, preoperative hormonal suppressive therapy may actually lead to underestimation of disease extent and consequent undertreatment at the time of surgery.

On the other hand, the induction of amenorrhea after surgery has been shown to decrease recurrence rates, especially if the uterus has been preserved.<sup>3</sup> Again, the nature and duration of this therapy should be tailored individually rather than scheduled. An appealing option is the placement of a levonorgestrel-releasing intrauterine device (LNG IUD), especially if adenomyosis is suspected.<sup>9</sup>

Some interventions that can reduce the risk of recurrence are listed in Table 4.8.



Clinical Entity	Treatment Option	Reference
Peritoneal endometriosis	<ul style="list-style-type: none"> <li>■ Postoperative induction of amenorrhoea.</li> </ul>	23,29
Ovarian endometrioma	<ul style="list-style-type: none"> <li>■ Resection of cyst wall better than fenestration.</li> <li>■ Resection of underlying peritoneum.</li> <li>■ Postoperative induction of amenorrhoea.</li> </ul>	12 5,16 29
Deep infiltrating endometriosis	<ul style="list-style-type: none"> <li>■ Surgery that includes hysterectomy if family planning is complete.</li> </ul>	25,25

**Table 4.8** Overview of available treatment options for preventing recurrence.

### 4.7.3 Management of Recurrent Disease

In deciding how best to manage symptom recurrence, it is even more necessary than in primary settings to weigh the pros and cons of different treatment modalities and discuss them openly with the patient. Since in typical cases endometriosis is only one of a cluster of problems, rethinking the diagnosis in a broader context of the woman's personal history is often very rewarding (cf. Section 2.1 of this chapter). Findings or symptoms suggestive of recurrent endometriosis after menopause warrant a detailed workup for the exclusion of endometriosis-associated malignancy (cf. Section 4.10 of this chapter).

#### 4.7.3.1 Recurrent or Persistent Pain

If pain persists despite surgical treatment conforming to best practice guidelines, appropriate medical therapy (induction of amenorrhoea) should be initiated as outlined above. If response is poor, it is important to note the findings of a small study by *Ling*,<sup>14</sup> who initiated treatment with a GnRH analogue before surgery and compared the success or failure of this medication in relieving pain with their intraoperative findings. If the pain resolved, endometriosis was found in 60% of cases; if it persisted, endometriosis was seen in only 14%. Consequently, other causes for the pain should be investigated before reoperation is considered. If none are found, the best available option may be to focus treatment efforts on the pain itself using multimodal pain therapy

#### 4.7.3.2 Recurrent Endometrioma

Recurrence of ovarian endometrioma is rare with appropriate treatment. If it does recur, an individualized solution should be sought. The following factors should be kept in mind:

- **Age of the patient.** Surgery is more strongly indicated in perimenopausal and especially in postmenopausal women to avoid delaying a possible diagnosis of malignancy. The use of tumor markers and MRI for this decision is discouraged.<sup>26</sup>
- **The patient's wish to preserve fertility.** Repeat surgery to the ovary has adverse effects on the ovarian reserve.<sup>19</sup>

Thus, if recent histologic confirmation has been obtained and the endometrioma has a typical ultrasound appearance, is of limited size, and does not constitute a practical obstacle to oocyte retrieval, a 'watchful waiting' approach may be discussed with the patient.<sup>21</sup>

#### 4.7.3.3 Persistence of Infertility

Even more than pain, infertility in endometriosis patients should be considered the result of multiple factors. The situation is further complicated by the fact that published case data are difficult to compare since they reflect different treatment protocols and inclusion criteria.<sup>28</sup> Consequently, this situation should always be approached comprehensively with input from surgeons, reproductive endocrinologists, and andrologists.

The risk of persistent infertility after radical surgery for deep infiltrating endometriosis seems to range around 50%.<sup>22</sup> For these patients, secondary surgery appears to have no advantages over assisted reproductive technology.<sup>30</sup>

In the presence of residual disease, other factors (adenomyosis, age, anti-Müllerian hormone) appear to have a much greater limiting effect on assisted reproductive outcome than colorectal endometriosis itself.<sup>1</sup> This finding is in line with that of *Littman*, who achieved, after surgery, 15 non-IVF pregnancies and 7 IVF pregnancies in 29 patients with prior IVF failures.<sup>15</sup>

### 4.7.4 Conclusion

Endometriosis is usually a condition that affected women must face throughout their reproductive years. Initial management of the disease should include a comprehensive diagnostic workup and evidence-based treatments that are both safe and effective in the long term. If a recurrence is diagnosed, it requires a multidisciplinary approach and an individualized plan of treatment.

## 4.7.5 References

- BALLESTER M, D'ARGENT EM, MORCEL K, BELAISCH-ALLART J, NISOLLE M, DARAI E. Cumulative pregnancy rate after ICSI-IVF in patients with colorectal endometriosis: results of a multicentre study. *Hum Reprod* 2012;27(4):1043–9. doi:10.1093/humrep/des012.
- BALLWEG ML. Impact of endometriosis on women's health: comparative historical data show that the earlier the onset, the more severe the disease. *Best Pract Res Clin Obstet Gynaecol* 2004;18(2):201–18. doi:10.1016/j.bpobgyn.2004.01.003.
- BORGHESE B, SANTULLI P, STREULI I, LAFAY-PILLET M, ZIEGLER D DE, CHAPRON C. Recurrence of pain after surgery for deeply infiltrating endometriosis: How does it happen? How to manage? *J Gynecol Obstet Biol Reprod (Paris)* 2014;43(1):12–8. doi:10.1016/j.jgyn.2012.11.009.
- BUCHWEITZ O, TJANDRA R. Ablation versus Exzision: prospektiv randomisierte Studie zum Vergleich der operativen Therapie von peritonealer Endometriose (AFS I und II). Abstract, 60. DGGG- Kongress München 2014.
- CHAPRON C, SANTULLI P, ZIEGLER D DE, NOEL J, ANAF V, STREULI I et al. Ovarian endometrioma: severe pelvic pain is associated with deeply infiltrating endometriosis. *Hum Reprod* 2012;27(3):702–11. doi:10.1093/humrep/der462.
- DUNSELMAN GAJ, VERMEULEN N, BECKER C, CALHAZ-JORGE C, D'HOOGE T, BIE B DE et al. ESHRE guideline: management of women with endometriosis. *Hum Reprod* 2014;29(3):400–12. doi:10.1093/humrep/det457.
- EBERT AD, ULRICH U, KECKSTEIN J, MULLER M, SCHINDLER AE, SILLEM M et al. Implementation of certified endometriosis centers: 5-year experience in German-speaking Europe. *Gynecol Obstet Invest* 2013;76(1):4–9. doi:10.1159/000346457.
- FEDELE L, BIANCHI S, ZANCONATO G, BERLANDA N, BORRUTO F, FRONTINO G. Tailoring radicality in demolitive surgery for deeply infiltrating endometriosis. *Am J Obstet Gynecol* 2005;193(1):114–7. doi:10.1016/j.ajog.2004.12.085.
- FEDELE L, BIANCHI S, ZANCONATO G, PORTUESE A, RAFFAELLI R. Use of a levonorgestrel-releasing intrauterine device in the treatment of rectovaginal endometriosis. *Fertil Steril* 2001;75(3):485–8.
- FERRERO S, CAMERINI G, MENADA MV, BISCALDI E, RAGNI N, REMORGIDA V. Uterine adenomyosis in persistence of dysmenorrhea after surgical excision of pelvic endometriosis and colorectal resection. *J Reprod Med* 2009;54(6):366–72.
- GUO S. Recurrence of endometriosis and its control. *Hum Reprod Update* 2009;15(4):441–61. doi:10.1093/humupd/dmp007.
- HART R, HICKEY M, MAOURIS P, BUCKETT W, GARRY R. Excisional surgery versus ablative surgery for ovarian endometriomata: a Cochrane Review. *Hum Reprod* 2005;20(11):3000–7. doi:10.1093/humrep/dei207.
- HIPPACH M, HINRICHS I, SCHWEPPE K.-W. Möglichkeiten der Langzeittherapie bei rezidivierender Endometriose. *Zentralbl. Gynaekol* 2003;125:303.
- LING FW. Randomized controlled trial of depot leuprolide in patients with chronic pelvic pain and clinically suspected endometriosis. *Pelvic Pain Study Group. Obstet Gynecol* 1999;93(1):51–8.
- LITTMAN E, GIUDICE L, LATHI R, BERKER B, MILKI A, NEZHAT C. Role of laparoscopic treatment of endometriosis in patients with failed in vitro fertilization cycles. *Fertil Steril* 2005;84(6):1574–8. doi:10.1016/j.fertnstert.2005.02.059.
- MEREU L, FLORIO P, CARRI G, PONTIS A, PETRAGLIA F, MENCAGLIA L. Clinical outcomes associated with surgical treatment of endometrioma coupled with resection of the posterior broad ligament. *Int J Gynaecol Obstet* 2012;116(1):57–60. doi:10.1016/j.ijgo.2011.08.017.
- MOEN MH. Endometriosis in women at interval sterilization. *Acta Obstet Gynecol Scand* 1987;66(5):451–4.
- MONTENEGRO MLL, MATEUS-VASCONCELOS ECL, ROSA E SILVA JC, NOGUEIRA AA, DOS REIS FJC, POLI NETO OB. Importance of pelvic muscle tenderness evaluation in women with chronic pelvic pain. *Pain Med* 2010;11(2):224–8. doi:10.1111/j.1526-4637.2009.00758.x.
- SIEDENTOPF F, SILLEM M. Chronischer Unterbauchschmerz der Frau. *Schmerz* 2014;28(3):300–4. doi:10.1007/s00482-014-1408-4.
- SILLEM M, JUHASZ-BOSS I, KLAUSMEIER I, MECHSNER S, SIEDENTOPF F, SOLOMAYER E. Osteopathy for Endometriosis and Chronic Pelvic Pain – a Pilot Study. *Geburtshilfe Frauenheilkd* 2016;76(9):960–3. doi:10.1055/s-0042-111010.
- SOMIGLIANA E, BENAGLIA L, PAFFONI A, BUSNELLI A, VIGANO P, VERCELLINI P. Risks of conservative management in women with ovarian endometriomas undergoing IVF. *Hum Reprod Update* 2015;21(4):486–99. doi:10.1093/humupd/dmv012.
- STEPNIEWSKA A, POMINI P, SCIOSCIA M, MEREU L, RUFFO G, MINELLI L. Fertility and clinical outcome after bowel resection in infertile women with endometriosis. *Reprod Biomed Online* 2010;20(5):602–9. doi:10.1016/j.rbmo.2009.12.029.
- STROWITZKI T, FAUSTMANN T, GERLINGER C, SCHUMACHER U, AHLERS C, SEITZ C. Safety and tolerability of dienogest in endometriosis: pooled analysis from the European clinical study program. *Int J Womens Health* 2015;7:393–401. doi:10.2147/IJWH.S77202.
- TARJANNE S, HEIKINHEIMO O, MENTULA M, HARKKI P. Complications and long-term follow-up on colorectal resections in the treatment of deep infiltrating endometriosis extending to bowel wall. *Acta Obstet Gynecol Scand* 2015;94(1):72–9. doi:10.1111/aogs.12515.
- TUTTLES F. Der revidierte ENZIAN-Score – eine einfachere Klassifikation der tief infiltrierenden Endometriose; Available from: [http://www.endometriose-sef.de/dateien/EndometrioseAktuell\\_1\\_2010.pdf](http://www.endometriose-sef.de/dateien/EndometrioseAktuell_1_2010.pdf), last accessed 27th Dec 2015.
- ULRICH U, BUCHWEITZ O, GREB R, KECKSTEIN J, LEFFERN I VON, OPPELT P et al. National German Guideline (S2k): Guideline for the Diagnosis and Treatment of Endometriosis: Long Version - AWMF Registry No. 015-045. *Geburtshilfe Frauenheilkd* 2014;74(12):1104–18. doi:10.1055/s-0034-1383187.
- URBACH DR, REEDIJK M, RICHARD CS, LIE KI, ROSS TM. Bowel resection for intestinal endometriosis. *Dis Colon Rectum* 1998;41(9):1158–64.
- VERCELLINI P, BARBARA G, BUGGIO L, FRATTARUOLO MP, SOMIGLIANA E, FEDELE L. Effect of patient selection on estimate of reproductive success after surgery for rectovaginal endometriosis: literature review. *Reprod Biomed Online* 2012;24(4):389–95. doi:10.1016/j.rbmo.2012.01.003.
- VERCELLINI P, CROSIGNANI P, SOMIGLIANA E, VIGANO P, FRATTARUOLO MP, FEDELE L. 'Waiting for Godot': a commonsense approach to the medical treatment of endometriosis. *Hum Reprod* 2011;26(1):3–13. doi:10.1093/humrep/deq302.
- VERCELLINI P, SOMIGLIANA E, VIGANO P, MATTEIS S DE, BARBARA G, FEDELE L. The effect of second-line surgery on reproductive performance of women with recurrent endometriosis: a systematic review. *Acta Obstet Gynecol Scand* 2009;88(10):1074–82. doi:10.1080/00016340903214973.

## 4.8

## Definitive Surgery for Endometriosis after Completion of Family Planning

Tamer A. Seckin<sup>a</sup> | S. Seckin<sup>b</sup> | Harry Reich<sup>c</sup>

### 4.8.1 Introduction and Background

Endometriosis is a condition characterized by the presence of endometrial glands and stromal cells surrounded by reactive inflammatory fibrosis outside the inner layer of the uterus. This definition includes both adenomyosis, which is the infiltration of endometrial cells deeper into the myometrium, and inflammatory fibrosis of peritoneal layers outside the uterus.<sup>15</sup> A clear clinical understanding of the disease is necessary for definitive surgical treatment. Treatment can be achieved by complete excision of endometriotic fibrosis and implants.

It is estimated that endometriosis affects 6–10% of reproductive-aged women and causes cyclic pain, infertility, and loss of quality of life. Often these patients undergo multiple repetitive surgeries. According to a prospective 4-year longitudinal study in North America, 27% of patients were re-operated on after initial endometriosis surgery, and 12% of all patients initially operated on (44% with subsequent surgery) ultimately received a hysterectomy.<sup>28</sup>

Inflammatory endometriotic fibrosis, which is estrogen-dependent, can cause mild to severe changes in the morphology of the peritoneal membrane and the topography of the cul-de-sac and pelvic sidewalls. Superficial fibrosis and dense adhesions restrict the functions of pelvic reproductive and non-reproductive organs. This causes the characteristic, healthy texture of the peritoneum – which is normally shiny, slippery, and transparent – to change. Deep fibrotic involvement of the retroperitoneum presents an additional challenge in both visual recognition and surgical treatment. Menorrhagia with cyclic and chronic pelvic pain is the most recognizable symptom of endometriosis, along with dyschesia, dyspareunia, and constipation.

For women with endometriosis who no longer wish to have children, the definitive option for recurrent symptoms after conservative surgery is total hysterectomy with bilateral

oophorectomy and excision of visually recognized and suspected endometriosis tissues. Depending on the excision expertise of the surgeon, ovarian conservation may be considered.<sup>18</sup> According to the *American College of Obstetricians and Gynecologists*, ‘... surgeons should consider removing both fallopian tubes and spare the ovaries in women at low risk for ovarian cancer.’<sup>2</sup>

Endometriosis primarily affects the pelvic peritoneum in the first order and most of the signs and symptoms that make the disease elusive are secondary to peritoneal involvement. However, it is often said that endometriosis is a disease of the uterus and the most commonly accepted etiology is believed to be retrograde menstrual debris refluxed from the fallopian tubes.<sup>6</sup> According to the works of *Taylor*,<sup>11</sup> and *Gargett*,<sup>14</sup> stem cells of the endomyometrial junction and their further stimulation of angiogenesis and pelvic peritoneum are possibly the modern explanation that complements and brings together older theories of mulleriosis and retrograde menstruation.<sup>4</sup> The theory of retrograde cell trafficking has also been considered a major etiology that may explain why ovarian endometriosis is the precursor of 20% of ovarian cancers.<sup>27</sup> In the absence of visible endometriosis, the removal of the tubes and ovaries is an elective decision made based on patient history. There is literature that strongly suggests that hysterectomy alone may not treat the patient’s symptoms of pain due to unrecognized disease left behind (incomplete surgery).<sup>23</sup>

Some researchers believe that endometriosis can be present from birth – a theory separate from retrograde menstruation. The embryological concept is more probable because cells, which are supposed to end up inside the uterus, sometimes stay in ectopic locations.<sup>5,26</sup> Excision can definitively cure such cases of rectovaginal endometriosis of embryologic origin, in contrast with endometriosis due to implantation of retrograde menstrual blood, which may continue to implant. Cases of rectovaginal endometriosis are considered to be the ‘most painful’ and are often diagnosed just from rectovaginal examination.

In 1914, *Thomas Cullen* said, ‘the removal of extensive adenomyoma of the rectovaginal septum (deep endometriosis surgery) is infinitely more difficult than a hysterectomy (*Wertheim*) for carcinoma of cervix procedure’.<sup>9</sup> Today, most gynecologic oncology surgeons agree.

<sup>a</sup> MD, FACOG, ACGE; Department of Obstetrics and Gynecology, Lenox Hill Hospital, New York NY, USA

<sup>b</sup> MD; Department of Obstetrics and Gynecology, Mount Sinai St. Luke’s and Mount Sinai West, Icahn School of Medicine at Mount Sinai. New York NY, USA

<sup>c</sup> MD, FACOG, FACS; Wyoming Valley Health Care System, Wilkes-Barre, PA, USA; St. Vincent’s Medical Center, NY, USA; CMC, Scranton, PA, USA; Lenox Hill, NY, USA

#### Corresponding author:

**Tamer Seckin**

MD, FACOG, ACGE

872 Fifth Avenue

New York City, NY 10065, USA

E-mail: info@drseckin.com

www.drseckin.com

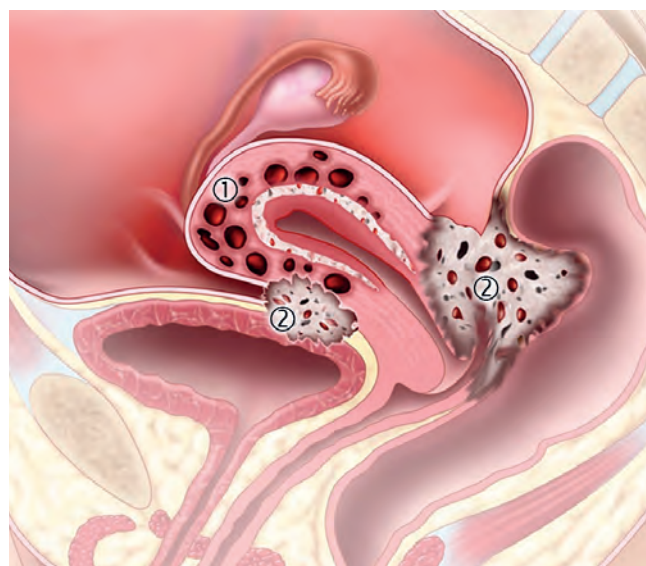

#### 4.8.1.1 Is there a Cure for Endometriosis?

My colleague, Dr. Harry Reich, does not strongly believe in the implantation and retrograde menstruation theory. He has said that, 'If endometriosis came back every month, there would be no point in doing surgery. The endometriosis cells in many women have been around since birth. These cells begin a cycle of chronic inflammation on a monthly basis starting with menstrual periods. Fibromuscular tissue is deposited around the endometriosis glands and connective tissue with resulting pain. If diagnosed early, this tissue can be excised completely using the laparoscope. Unfortunately this type of surgery sometimes may include bowel resection and resection of small portions of upper vagina behind the cervix. Most of these cases can be diagnosed by a simple rectovaginal exam in the doctor's office. MRI is rarely indicated.'

Many patients' fears are based on the idea that the disease will worsen and recur, thus becoming a chronic disease. They believe that the risk of recurrence is very high. In fact, no clinical data exists to determine whether endometriosis is a progressive and/or a recurrent disease, and many recurrent clinical symptoms may be explained by inadequate response to medical treatments and/or incomplete surgical excision of the disease.

Dr. Reich believes that true recurrence of the disease is rare. In most cases, the surgical excision patient's symptoms do not get much worse after the initial surgical excision diagnosis. 'Clinical recurrences' can often be explained by incomplete or inappropriate treatments. Most 'recurrences' occur in areas involved during the initial surgical procedure. A study of second-look laparoscopy showed that recurrent disease occurs most frequently at the site of treated disease after surgical treatment of early endometriosis, reflecting incomplete excision or ablation of disease.<sup>7</sup> After treatment of colorectal endometriosis, most re-operated patients are treated in the same area, suggesting that part of the disease was left behind due to an inadequate surgical procedure or because some organs were undertreated to minimize the risk of postoperative complications.



**Fig. 4.31** Adenomyosis. Intrinsic (①) and Extrinsic (②), DIE involving the bladder and rectum).

In addition, intentionally leaving endometriosis tissue behind and expecting that, by simply removing the ovaries, the lesions will begin an inactive phase, is a misappropriation of decision-making. In the presence of diffuse fibrosis of the peritoneum and unrecognized deep nodular and infiltrative disease, definitive surgery limited to simple total hysterectomy and bilateral salpingo-oophorectomy (BSO) is insufficient.

#### 4.8.1.2 Indications for Hysterectomy

The surgical choice for treatment of endometriosis depends on many factors, including the patient's age, severity of her symptoms, and whether she wants to have children. These are all key factors in decision-making. A thorough history and physical exam is warranted for determining many of these factors, as well as gauging the areas that may be affected in the pelvis. A hysterectomy alone will not definitively cure endometriosis if the tissues with endometriosis in the pelvis are not also removed.

Removal of the uterus should have justifiable indications. Pelvic pain, after all, may have multiple causes. Therefore, in the absence of uterine disease, doctors and patients should be cautious in proceeding with hysterectomy. In addition, pre-operative tests like MRIs do have false sensitivity in detecting uterine pathology such as endometriosis or adenomyosis.<sup>3</sup>

#### 4.8.2 Uterine Pathology

The most common uterine pathologies seen with endometriosis are adenomyosis, leiomyomata uteri, adhesions, and deep fibrotic disease involving posterior cul-de-sac, as well as anterior cul-de-sac involving the bladder. All of the above pathologies, particularly adenomyosis, are characterized by severe dysmenorrhea, menorrhagia, and pelvic pain. Adenomyosis is the thickening of the endo-myometrial junction and the extension of glands deep into the myometrium from the endometrial cavity (Fig. 4.31). However, the uterus can also be infiltrated by the presence of disease in neighboring organs through the serosal layer.

In advanced endometriosis, the presence of an ovarian endometrioma, a harbinger of retroperitoneal disease and deep nodular and infiltrative endometriosis, is one of the most important factors in determining severity and extent of pathology. An intraperitoneal spillage of chocolate cyst contents from an endometrioma may cause severe adhesions to the ovaries, the uterus, the pelvic sidewalls, the rectosigmoid, and the cul-de-sac. An endometrioma spillage may also occur retroperitoneally, causing severe fibrosis involving the ureter and the nerves.

#### 4.8.3 Preoperative Considerations

The disease can involve multiple pelvic organs, mainly the uterus, ovaries, tubes, bowel, and urinary tract, along with retroperitoneal spaces. The extra-uterine involvement determines the outcome of the planned procedure. Many of these patients, having had previous laparoscopic procedures, can present a wide range of symptoms suggestive of multiple organ involvement. Patients must be aware that endometriosis surgery carries 5–10 times more complications and risks

than simple laparoscopic procedures.<sup>8</sup> In order to obtain a proper consent, the best practice is to obtain a preoperative consultation with all the specialists in the surgical team. Outcome correlates positively with the experience and the skill of the surgeon and his or her team whose focus is exclusively endometriosis surgery.<sup>24</sup>

When extensive cul-de-sac involvement with endometriosis is suspected, either clinically or from another doctor's operative record, a mechanical bowel preparation should be considered prior to surgery. Polyethylene glycol-based isoosmotic solution (GoLYTELY or Colyte) works well. Following dissolution in water to a volume of 4 liters, oral administration induces a diarrhea that rapidly cleanses the bowel (generally within 4 hours). GoLYTELY is usually taken the afternoon before surgery so as not to interfere with sleep. Reglan (metoclopramide), 10 mg, is administered 30 minutes before the bowel prep to help promote gastric emptying and thus reduce abdominal bloating and distension.

#### 4.8.3.1 Hysterectomy Technique

The treatment of endometriosis is the excision of all endometriotic lesions. For definitive treatment of endometriosis when hysterectomy is indicated, the operation should be tailored to relieve all of the symptoms, not only the symptoms of suspected uterine origin. All extrauterine superficial and deep endometriosis should be excised first before the hysterectomy. The operation typically begins with adhesiolysis, followed by excision of endometriosis, after which hysterectomy is the final stage.

Hysterectomy is performed using an extra-fascial technique as opposed to an infra-fascial technique. In the extra-fascial approach, retroperitoneal exposure with the identification of ureter and the uterine vessels is essential. Similarly, parametrial ligaments, pericervical rings, and vaginal fornices are approached by using the extra-fascial technique to mobilize the bladder and rectum.

#### 4.8.3.2 Extrafascial Hysterectomy

An extra-fascial approach to hysterectomy for endometriosis often involves similar techniques used for modified radical hysterectomy for carcinoma of cervix. This extended version of modified hysterectomy is also referenced as a tailored radical hysterectomy for endometriosis.<sup>12</sup> In multiple organ involvement due to *deeply infiltrating endometriosis* (DIE), hysterectomy may be even more complex and technically more difficult than radical hysterectomy. Because of DIE, there is usually a more frequent necessity to repair the bowel, bladder, and ureter. It is key to have a very thorough understanding of pelvic retroperitoneal anatomy and an experienced strategy for hemostasis in identifying the uterine arteries from their origin before dividing the uterine ligaments and vaginal attachments.

At the start of surgery, regardless of the extent of the pelvic disease, one always begins with thorough inspection of the upper peritoneal cavity, the liver, and both diaphragmatic reflections, as well as careful inspection of the small bowel, the appendix, and colon. Steep Trendelenburg positioning of the patient with the uterine manipulator in place is very important

for the exposure and visualization of the pelvis. Introduction of a rectal probe at this initial stage may be helpful and failure to advance it may be a sign of narrowing.

Before hysterectomy is attempted, all issues regarding a safe procedure are planned and methodically exercised. After the patient's pelvic pathology is fully evaluated, the plan of surgery will be to mobilize and take the steps forward cautiously and patiently, from the easier to the more difficult steps. Many of the retroperitoneal spaces may be obliterated with infiltration by deep fibrotic disease and may not be identifiable or recognized. Due to endometriosis, these spaces anatomically are lost to retroperitoneal fibrosis.

#### 4.8.3.3 Pelvic Adhesiolysis

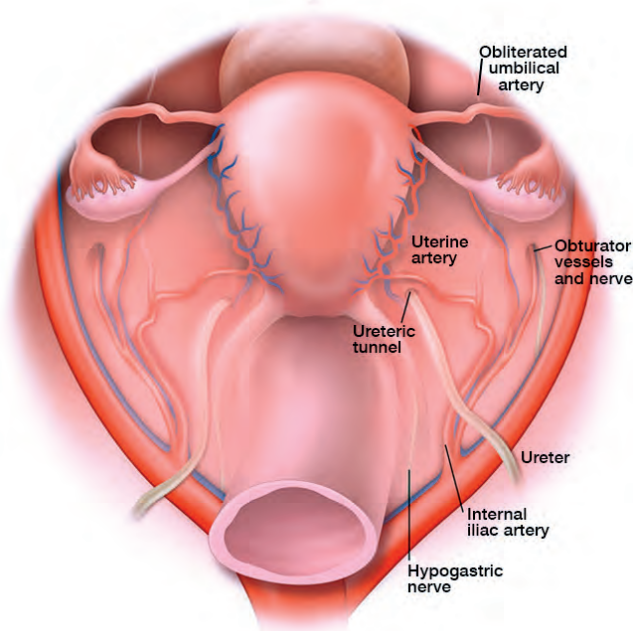
The first step is to free the uterus encased by surrounding adhesions and fibrotic endometriosis, along with freeing all bowel loops in the pelvis. Any small bowel that is attached to the vesicouterine peritoneal fold, uterus or the rectum should be liberated. There are three key points when performing intestinal adhesiolysis within the pelvis:

- Scissors dissection without electrosurgery;
- Countertraction;
- Blunt dissection.

The bowel is gently held with an atraumatic grasper and lifted away from the structure to which it is adhered, exposing the plane of dissection. When adhesive interfaces are obvious, scissors are used. The blunt-tipped scissors are used to sharply dissect the adhesions in small, successive cuts taking care not to damage the bowel serosa. Countertraction will further expose the plane of dissection and ultimately free the attachment. Electrosurgery and laser are generally **not** used for adhesiolysis involving the bowel due to the risk of thermal damage and recurrent adhesion formation. However, when adhesive aggregates blend into each other, initial incision is made very superficially with laser, and aquadissection distends the layers of the adhesions, facilitating identification of the involved structures. Division of adhesions continues with laser. The aquadissector and injected fluid from it are used as a backstop behind adhesive bands that are divided with the CO<sub>2</sub> laser.<sup>17</sup>

The rectosigmoid is often adherent to the left pelvic sidewall obscuring visualization of the left adnexa. Dissection starts well out of the pelvis in the left iliac fossa. Scissors are used to develop the space between the sigmoid colon and the psoas muscle to the iliac vessels, and the rectosigmoid is reflected toward the midline. Thereafter, with the rectosigmoid placed on traction, rectosigmoid and rectal adhesions to the left pelvic sidewall are divided starting cephalad and continuing caudad.

The round ligaments are bisected, and the incision is carried toward the midline vesicouterine fold. The vesicouterine fold is a common location of deep fibrotic endometriosis extending to full thickness into the bladder and the uterine wall. In a limited number of cases, when the bladder is completely frozen with adenomyosis, the need for bladder resection will



**Fig. 4.32** Anatomy.

be part of the extended hysterectomy procedure. Therefore, paired paravesical spaces will be further extended anteriorly into the Retzius space to mobilize the bladder anteriorly.

#### 4.8.3.4 Ureterolysis

Mobilization of rectosigmoid colon helps to gain access to the left retroperitoneum and in identifying the ureters at the pelvic brim. Using atraumatic forceps, the infundibulopelvic (IP) ligament is lifted anterolaterally and the ureter is identified medially at the pelvic brim as it crosses the common iliac artery.

The ureters will also be recognized after division of the round ligaments, and extending the incision which is carried cranially parallel and lateral to the ovarian vessels and adnexa on the roof of broad ligament. With traction on the adnexa medially, the external iliac major vessels will be exposed laterally. The ureter again will be at the medial leaf of the peritoneum above the bifurcation of the common iliac artery and 1 to 3 cm below

the IP ligament. Particular attention should be paid advancing into the paired paravesical and paired pararectal spaces as it is essential in isolation of both uterine arteries and the ureters.

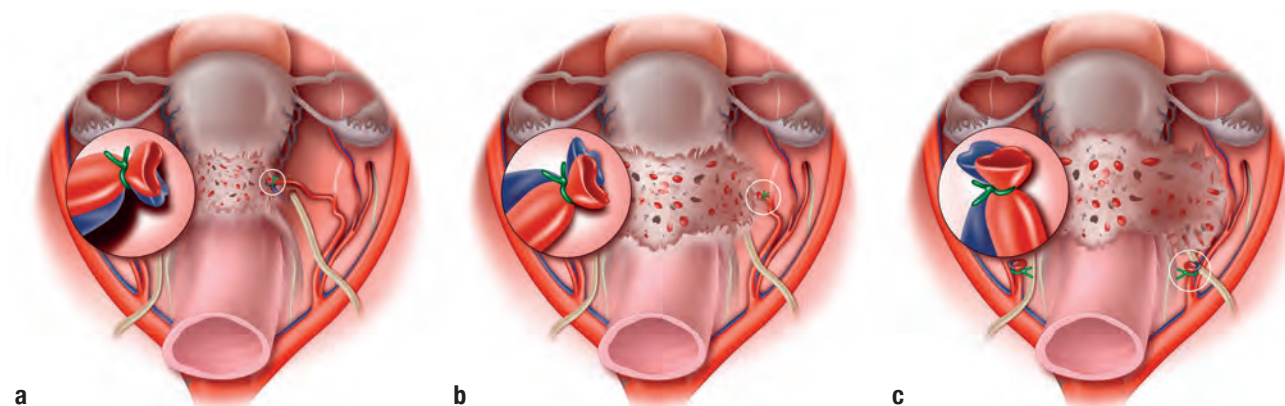
The critical objective at this step is to trace the ureters caudally to the level of the uterine artery bridge, also known as ureteric tunnel (Fig. 4.32). During the course of the dissection of the ureter from pelvic brim, the surgeon recognizes the internal iliac artery branching into the hypogastric division and obliterated umbilical artery lateral to the course of the ureter (Fig. 4.32). When deep nodular fibrosis involves the retroperitoneum at the ovarian fossa, the peritoneum making up the pelvic sidewall facing the ovarian endometrioma is thickened, contracted and deformed with inflammatory fibrosis. Using the fine-tipped Adson forceps (Reich modification), diseased peritoneum is lifted upwards and medially retracted and then excised to unroof the ovarian fossa medially to the uterosacral plate. Fibrotic endometriosis may involve deeper levels beyond the adventitia, as the ureter may well be encased completely with overlying uterine artery in the ureteric tunnel.

Due to unpredictable nature of the extent of fibrosis, ureteral stents may help reduce surgical time and prevent complications at this step. The difficulty of identifying the ureters by tracing them to the ureteric tunnel depends on the extent of the fibrosis. After the excision of the disease, the ureter can be repaired primarily, or end-to-end anastomosed with fine suturing. Hydrodistention of the peritoneum using contrast with methylene blue may aid in both identification of endometriotic lesions that otherwise may be left out and as well as increasing the safety of the procedure.

#### 4.8.3.5 Hypogastric and Uterine Artery Ligation

In order to avoid hemorrhage, the hypogastric and uterine artery can be ligated anywhere from its origin towards its course to the uterus. The uterine artery is identified by tracing the common iliac to internal iliac artery, and to hypogastric artery distally or by locating the obliterated umbilical artery and tracing it proximally.<sup>10</sup>

Depending on the involvement of the parametrial tunnel and the vesico-uterine pillars with fibrotic nodular endometriosis, the uterine arteries are ligated at any point from its origin from



**Fig. 4.33a–c** Level one ligation of uterine artery between the uterus and ureteric tunnel (a). Level two ligation of uterine artery between the ureteric tunnel and obliterated umbilical artery (b). Level three ligation of uterine artery at internal iliac proximal to obliterated umbilical artery (c).



the common iliac artery during its course towards the uterus. Three levels of uterine artery ligation are described here. *Level one* is the ligation of the uterine artery at the segment from the ureteric tunnel to the uterine junction (Fig. 4.33a). *Level two* is ligation between the obliterated umbilical ligament and the ureteric tunnel (Fig. 4.33b). Finally, if disease is extending to the obturators and to the hypogastric reflection, *level three* ligation at the level of the internal iliac artery may be performed (Fig. 4.33c). Another alternative is to implement suture ligation using the anterior approach from the prevesical space in cases where the posterior compartment is frozen.

When the ovarian vessels are ligated bilaterally and there are well-placed sutures on the uterine arteries, the uterus should blanch and change color immediately. Suture ligation is always preferred over energy-based modalities, like the harmonic scapel and bipolar electrocautery. The procedure will then proceed by dissecting the posterior cul-de-sac.

#### 4.8.3.6 Peritoneal Implants; Focal Excision and Peritonectomy

In order to treat superficial peritoneal endometriosis, endometriotic implants and their adjacent peritoneum can be excised using scissors or a needle electrode with a cutting current. An elliptical incision is made around the lesion, its edge lifted upward, and the lesion is undermined using the hydraulic effect of pressurized irrigant from an laparoscopic suction-irrigation pump (HAMOU Endomat®, KARL STORZ Tuttlingen, Germany). This pushes pelvic sidewall structures and the rectum away and allows for safer and easier undercutting of the lesion. Following excision with scissors, the ureter, the anterior rectal wall, and the upper posterior vagina are checked and superficial endometriosis in these areas are excised. A blue dye contrast may aid the surgeon to detect occult and atypical peritoneal lesions (Aqua Blue Contact Technique) (Figs. 4.34).<sup>25</sup>

Small pinpoint lesions can be excised using scissors, the CO<sub>2</sub> laser or electrosurgery with the resultant drainage of haemosiderin-filled fluid in cases where deposits have infiltrated beneath the peritoneum. The base of the lesion must also be excised until normal tissue is seen. Cold scissors with microbipolar back-up may result in better outcome due to their greater depth of access and ability to restore normal anatomy.

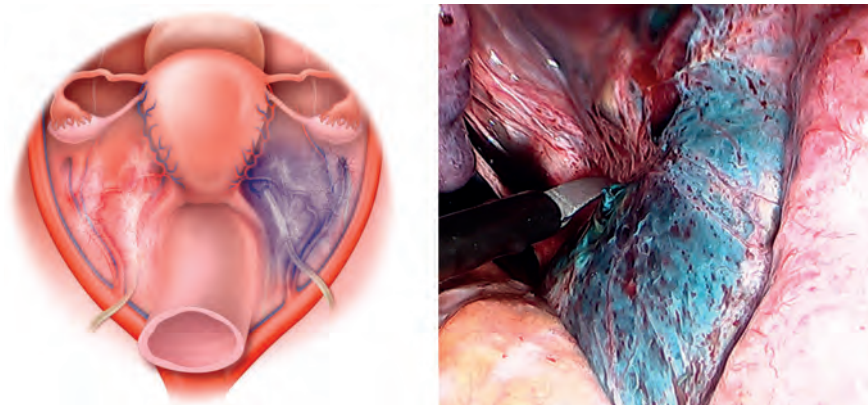
In cases of endometrioma, the anti ovarian peritoneal surface is largely involved in the disease. Peritoneum is thickened and contracted due to the fibrosis that extends deeper into pelvic sidewall and cul-de-sac. To treat deeper and wider peritoneal endometriosis, after the ovary is freed, a peritonectomy is performed where the peritoneum of the pelvic sidewall is excised to the extent of involvement with endometriosis. Using methylene blue water to enhance color contrast in the hydrodistention underneath the peritoneal layer may assist the surgeon in recognizing deeper implants. With blunt and sharp dissections, the uterine artery is skeletonized as the diseased tissue is retracted to the midline. After the identification of the uterine artery, the diseased peritoneum is excised all the way to the uterine artery tunnel.

At this juncture, the uterosacral ligament and its presacral attachments, which is the reflection of the inferior hypogastric nerves, is deferred and the pararectal space is identified in order to expose the extent of rectovaginal involvement.

When the rectal probe advances into the rectum and further into the rectosigmoid, countertraction is created. At the same time, the uterus is anteverted with its manipulator. The surgeon uses the blunt scissors to separate the rectum from its posterior uterine and posterior cervical and vaginal involvement.

#### 4.8.4 Endometriomas

A suction-irrigation pump (HAMOU Endomat®, KARL STORZ Tuttlingen, Germany) is used to lift up the ovaries if they are attached to their respective utero-sacral ligament and/or pelvic sidewall. Often, this maneuver will result in drainage of an endometrioma from the undersurface of the ovary. If no endometrioma is readily identified, and the patient has 'unexplained infertility' or pre- or post-menstrual spotting, a 3-mm knife electrode connected to unmodulated unipolar cutting current (80 W) is used to incise and drain areas on the ovary with superficial endometriosis and cysts suspicious for endometrioma. If an endometrioma is discovered by either of these two methods, the cyst cavity is rinsed with Ringer's lactate solution and then excised using 3-mm and 5-mm biopsy forceps, grasping forceps, and/or scissors. To help delineate the initial plane between normal ovarian cortex



**Fig. 4.34** Peritoneal endometriosis on the pelvic sidewall recognized with Aqua Blue Contact Technique (ABCt)<sup>TM</sup>.

and endometrioma cyst wall, cutting current through the knife electrode tip applied at the cyst wall-cortex junction results in the development of a dissection plane. This step is particularly useful near the utero-ovarian ligament as rough avulsion can lead to excessive bleeding. Grasping forceps are then used to stabilize ovarian cortex while the endometrioma cyst wall is avulsed. Excision can be performed with minimal bleeding from the cyst wall bed and the ovarian wall edges usually re-approximate quite well, though occasionally extracorporeal suturing is required.<sup>19</sup> Finally the pelvic sidewall peritoneum where the ovary was attached usually overlying the ureter is excised.

#### 4.8.4.1 Partial and Complete Cul-de-sac Obliteration

##### ■ *Cul-de-Sac Excision*

Cul-de-sac obliteration implies the presence of deep fibrotic endometriosis.

Partial cul-de-sac obliteration means that deep fibrotic endometriosis, i.e., endometriosis beneath the peritoneum, is present and is severe enough to alter the course of the rectum. The deep fibrotic endometriosis is usually located on the rectum, in the rectovaginal space, on the upper vagina, in the space between the upper vagina and the cervix (cervicovaginal angle), or in one or both utero-sacral ligaments. With deep cul-de-sac obliteration, fibrotic endometriosis and/or adhesions involve the entire area between the cervico-vaginal junction (and sometimes above) and the recto-vaginal septum. Often one area predominates.<sup>20</sup>

Careful inspection of the cul-de-sac is necessary to evaluate the extent of upward tenting of the rectum. To determine if cul-de-sac obliteration is partial or complete, a sponge on a ring forceps is inserted into the posterior vaginal fornix. Complete cul-de-sac obliteration implies that the outline of the posterior fornix cannot be visualized initially through the laparoscope, i.e., the rectum or fibrotic endometriosis nodules completely obscure the identification of the deep cul-de-sac. Partial cul-de-sac obliteration occurs where rectal tenting is visible but a protrusion from the sponge in the posterior vaginal fornix is noted between the rectum and the inverted 'U' of the utero-sacral ligaments.

In contrast to the procedure performed for superficial peritoneal endometriosis, deep fibrotic nodular endometriosis involving the cul-de-sac, often with invasion into posterior vagina, rectum, or posterior cervix, is a much more difficult problem and should be attempted only by the most expert laparoscopist. At this step the ureter is completely exposed bilaterally. First, the posterior uterus will be freed from its rectosigmoid. Then, following the placement of rectal, vaginal, and uterine probes, the rectal serosa is opened at its junction with the cul-de-sac lesion using scissors. Rather than concentrating on the excision of the nodular mass, attention is first directed to the complete dissection of the anterior rectum throughout its area of involvement. The cul-de-sac is approached with sharp dissection by scissors, avoiding any usage of energy-based instruments except the bipolar for hemostasis. Dense adhesions and fibrotic nodules are freed from the uterine border, leaving most of the disease above the

rectum on the posterior vagina, especially if the surgeon can visualize the outline of the rectal probe during the dissection. The dissection is performed until the loose areolar tissue of the recto-vaginal space is reached. Usually, this dissection extends 3–4 centimeters below the posterior fornix. Another technique in reaching the rectovaginal disease is performed by exploring the pararectal space bilaterally. Only after the rectum is mobilized should excision of the fibrotic endometriosis be attempted from the rectum, posterior vagina, and utero-sacral ligaments.

When a ureter is close to the lesion, its course in the deep pelvis is traced by opening its overlying peritoneum with scissors. On the left, this often requires scissors reflection of the rectosigmoid, as previously described, starting at the pelvic brim. Microbipolar forceps are used to control arterial and venous bleeding.

The rectum, with or without a fibrotic lesion must be separated from the posterior uterus and upper vagina, especially when operating close to the uterine vessels, as entry into these vessels can produce life-threatening haemorrhage requiring immediate application of the bipolar forceps.

Following separation of the rectum from the back of uterus and the upper posterior vagina, the dissection continues on top of the posterior vagina, the position of which is confirmed by the sponge in the posterior fornix. This dissection on the outside of the vaginal wall uses laser, aquadissection, electrosurgery or scissors. On occasion, the lesion may extend deep into or completely through the vaginal wall. Dissection should be performed accordingly with removal of all visible fibrotic endometriosis. Lesions extending totally through the vagina demand an en bloc resection from cul-de-sac to posterior vaginal wall as part of the extended hysterectomy. At this stage, the surgical team may also perform a low anterior rectal resection if rectal stricture is present, or the anterior surface of the rectum is compromised due to wide excision.

Our recommendation is to defer the low anterior segmental resection until after the hysterectomy is completed. The reason for this is that the natural orifice of the vagina could be used as an access route for the resected bowel to be removed.<sup>13</sup>

#### 4.8.4.2 Rectum

Endometriosis nodules infiltrating the rectal muscularis are excised, partially or totally, usually with the operator's or the assistant's finger, in the rectum just beneath the lesion. Some endometriosis nodules in the muscularis of the anterior rectum can be excised laparoscopically without entering the rectum. Full-thickness penetration of the rectum can occur during hysterectomy surgery, especially when excising rectal endometriosis nodules. Deep rectal muscularis defects should always be closed with suture. These defects are detected by filling the rectum and rectosigmoid with a blue dye solution. Full thickness rectal lesion excisions can be repaired by laparoscopic suture or incorporated in an anterior discoid resection using a # 29 or 33 EEA stapler. Following identification of the nodule or rent in the rectum, a closed circular stapler [Proximate ILS Curved Intraluminal Stapler (Ethicon, Stealth)] is inserted into the lumen just past

the lesion or hole, opened 1–2 cm, and held high to avoid the posterior rectal wall.<sup>21</sup> The proximal anvil is positioned just beyond the lesion or hole, which is invaginated into the opening, and the device closed. The instrument is fired and removed. If bowel resection is deemed necessary, it will be performed before the vaginal cuff is closed. In order to prevent complications, surgeons are cautioned against the use of active suction drains or mechanical suction drain pumps. The walls of pelvic organs which are already compromised and thinned due to extensive shaving and excision may be prone to leakage of the anastomosis or fistula formation. In addition, juxtapositional alignment of suture repair lines must be avoided when full thickness organs, such as the ureter, bowel, bladder and vagina, are simultaneously repaired. Mobilizing an omental pedicle pad in between the repaired organs may also be considered in order to prevent rectovaginal, uretrovaginal, vesicorectal, and vesicovaginal fistula formation.

When very low anterior bowel reanastomosis is performed or a compromised bowel wall tissue is suspected, a prophylactic temporary loop ileostomy is advised.<sup>1</sup> In cases when ureter re-anastomosis or re-implantation is performed, prolonged use of post-operative ureteral stents are necessary.

#### 4.8.4.3 Parametrium and Frozen Pelvis

When endometriosis involves the parametrium, the uterine and bowel may also be involved. This can result in a partially frozen pelvis. In this surgically challenging situation, the uterine arteries are ligated proximally at the hypogastric level or the internal iliac artery level. Stricture of the ureter and bowel is not uncommon when the uterus is partially frozen to the pelvic sidewall. The detachment of deep fibrotic tissue from parametrial extension in frozen pelvis is the most challenging aspect of a modified radical hysterectomy. These lesions may extend to the level of the obturator vessels and deep into ischial spine.

It is again very important to have pre-operatively placed ureteral stents since the ureters are almost always encased within this fibrotic process. Any muscular defect involving the ureter during this excision should be immediately repaired with 4.0 Prolene or Monocryl sutures in an interrupted fashion, whereas primary lesions on the rectum are closed with interrupted silk in a single layer. After the disease-free tissues are reached, both anteriorly and posteriorly, the cardinal ligaments are taken down either with a harmonic scalpel or pure cut electrical current.

#### 4.8.4.4 Uterosacral Ligaments

Removal of uterosacral ligaments with its presacral attachment and deep hypogastric extensions is again performed since the disease usually affects the proximal part of the uterosacral ligaments. However, deep nodules and cystic lesions may involve the pararectal space extending into the presacral and hypogastric compartments. Extreme caution must be practiced as well as avoidance of bilateral deep excisions in order to prevent the potential for serious bladder dysfunction secondary to injury of the deep hypogastric nerve.

#### ■ *Division of Cervicovaginal Attachments and Circumferential Culdotomy*

The cardinal ligaments and uterosacral ligaments on each side are divided lateral to endometriotic fibrosis. Bipolar forceps coagulate the uterosacral ligaments. The vagina is entered posteriorly over the uterovaginal manipulator below the cervicovaginal junction. A 4-cm-diameter reusable vaginal delineator tube is placed in the vagina to prevent loss of pneumoperitoneum and to outline the cervicovaginal junction circumferentially as it is incised using the CO<sub>2</sub> laser, harmonic scalpel, or electrosurgery to complete the circumferential culdotomy with the delineator as a backstop. The specimen of the uterus with its contiguous tissues (posterior vagina and parametrium, along with tubes and ovaries attached) is removed from the vagina. The uterus is morcellated vaginally, if necessary, and pulled out of the vagina.

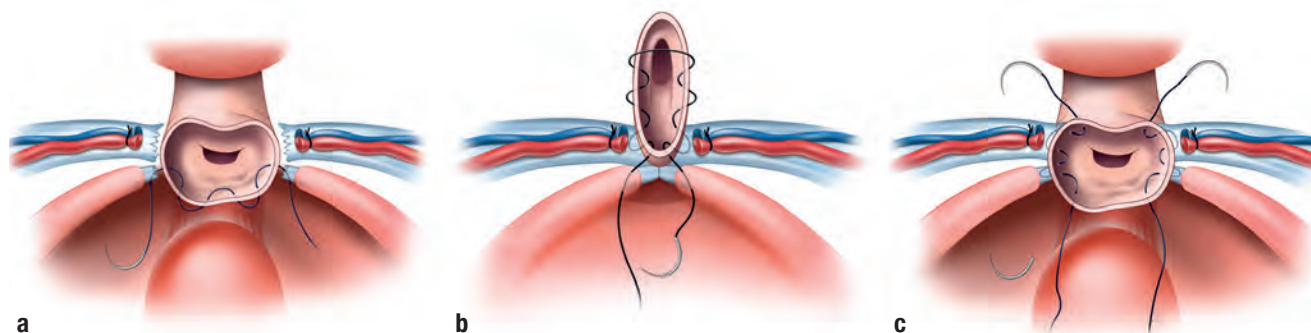
Extrafascial culdotomy with removal of the entire uterus is followed with anchoring of the vaginal cuff to the uterosacral ligaments.

Intrafascial culdotomy proximal to the uterosacral ligament insertion site preserving Level 1 support will promote future pelvic organ prolapse surgery and should never be done if endometriosis exists in the cul-de-sac. A supracervical hysterectomy will do the same! Culdotomy proximal to the uterosacral ligament insertion site preserving Level 1 support is more like a supracervical hysterectomy than a TLH. More important, the uterosacral insertions are the most common site of deep endometriosis, and, if left behind, may contribute to future pelvic pain and dyspareunia problems.

#### ■ *Laparoscopic Vaginal Vault Closure and Suspension with McCall Culdoplasty*

The vaginal delineator tube is placed back into the vagina for closure of the vaginal cuff, occluding it to maintain pneumoperitoneum, and hemostasis around the vaginal cuff obtained using microbipolar forceps with irrigation. The uterosacral ligaments are identified by bipolar desiccation markings or with the aid of a rectal probe. The first suture is complicated as it brings the uterosacral and cardinal ligaments, as well as the rectovaginal fascia, together. This single suture is tied extracorporeally, bringing the uterosacral ligaments, cardinal ligaments, and posterior vaginal fascia together across the midline. It provides excellent support to the vaginal cuff apex, elevating it and its endopelvic fascia superiorly and posteriorly toward the hollow of the sacrum. The rest of the vagina and overlying pubocervicovesicular fascia are closed vertically with one or two 0-Vicryl interrupted sutures. Cuff closure sutures are for fascia and not vaginal epithelium. They are used for support, not hemostasis. Strangulating sutures that inhibit tissue circulation are avoided. A drain is never used. Locked sutures are a cause of **both** tissue strangulation **and** poor drainage and are never used.





**Fig. 4.35a–c** Modified McCall closure of the vaginal cuff (First Layer) (a). Modified McCall closure of the vaginal cuff (Second Layer) (b). Modified Richardson antero-posterior closure of the vaginal cuff (c).

The cuff may be closed vertically or horizontally depending on whether the patient needs the support of the posterior vagina. The modified McCall culdoplasty procedure is performed when the cuff is closed vertically in two layers (Figs. 4.35a, b). When the cuff is closed horizontally, modified Richardson angle sutures are applied (Fig. 4.35c). In this technique, interrupted angle sutures are applied.

#### 4.8.5 Cystoscopy

Cystoscopy is done after vaginal closure to check for ureteral patency in most cases, after intravenous administration of indigo carmine dye. This is necessary when the ureter is identified but not dissected and especially necessary when the ureter has not been identified. Blue dye should be visualized through both ureteral orifices. The bladder wall should also be inspected for suture and thermal defects.<sup>22</sup>

##### 4.8.5.1 Underwater Examination

At the close of each operation, an underwater examination is used to detect bleeding from vessels and viscera tamponaded during the procedure by the increased intraperitoneal pressure of the CO<sub>2</sub> pneumoperitoneum. The CO<sub>2</sub> pneumoperitoneum is displaced with 2–4 L of Ringer's lactate solution, and the peritoneal cavity is vigorously irrigated and suctioned until the effluent is clear of blood products. Any further bleeding is controlled underwater using microbipolar forceps to coagulate through the electrolyte solution, and 2 L of lactated Ringer's solution is left in the peritoneal cavity.

##### 4.8.5.2 Skin Closure

The vertical intra-umbilical incision is closed with a single 4-0 Vicryl suture opposing deep fascia and skin dermis, with the knot buried beneath the fascia. This will prevent the suture from acting like a wick transmitting bacteria into the soft tissue or peritoneal cavity. The lower quadrant 5-mm incisions are loosely approximated with a Javid vascular clamp (V. Mueller, McGaw Park, Illinois, USA) and covered with Collodion (AMEND, Irvington, New Jersey, USA) to allow drainage of excess Ringer's lactate solution.

#### 4.8.6 Summary

Extensive stage IV endometriosis can be excised laparoscopically if the surgeon is willing to spend the time to do so. Hysterectomy usually results in relief of the patient's pain, including symptoms related to enlarged uterus and menorrhagia. Oophorectomy may not be necessary during hysterectomy for advanced endometriosis if the endometriosis is removed carefully.<sup>16</sup>

When hysterectomy is considered as the permanent solution for endometriosis patients, complete removal of the diseased tissue and the cervix is only feasible by implementing the extrafascial technique. A skilled and tenacious surgical team, consisting of colorectal and urology specialists and led by a gynecological surgeon who exclusively deals with endometriosis, is of paramount importance for the best long-term treatment of endometriosis.

### 4.8.7 References

- AKLADIOS C, MESSORI P, FALLER E, PUGA M, AFORS K, LEROY J et al. Is ileostomy always necessary following rectal resection for deep infiltrating endometriosis? *J Minim Invasive Gynecol* 2015;22(1):103–9. doi:10.1016/j.jmig.2014.08.001.
- AMERICAN COLLEGE OF OBSTETRICIANS AND GYNECOLOGISTS. Salpingectomy for Ovarian Cancer Prevention: Committee Opinion No. 620. *Obstet Gynecol* 2015(125):279–81.
- BAZOT M, DARAI E, HOURANI R, THOMASSIN I, CORTEZ A, UZAN S et al. Deep pelvic endometriosis: MR imaging for diagnosis and prediction of extension of disease. *Radiology* 2004;232(2):379–89. doi:10.1148/radiol.2322030762.
- BENAGIANO G, BROSENS I, HABIBA M. Structural and molecular features of the endomyometrium in endometriosis and adenomyosis. *Hum Reprod Update* 2014;20(3):386–402. doi:10.1093/humupd/dmt052.
- BOUQUET DJJ, AYOUBI JM, LESEC G, VALIDIRE P, GOGUIN A, GIANAROLI L et al. Identification of displaced endometrial glands and embryonic duct remnants in female fetal reproductive tract: possible pathogenetic role in endometriotic and pelvic neoplastic processes. *Front Physiol* 2012;3:444. doi:10.3389/fphys.2012.00444.
- BROSENS I, BENAGIANO G. Endometriosis, a modern syndrome. *Indian J Med Res* 2011;133:581–93.
- CANIS M, BOURDEL N, HOUILLE C, GREMEAU AS, BOTCHORISHVILI R, MATSUZAKI S. Endometriosis may not be a chronic disease: an alternative theory offering more optimistic prospects for our patients. *Fertil Steril* 2016;105(1):32–4. doi:10.1016/j.fertnstert.2015.09.009.
- CICCO C DE, CORONA R, SCHONMAN R, MAILOVA K, USSIA A, KONINCKX P. Bowel resection for deep endometriosis: a systematic review. *BJOG* 2011;118(3):285–91. doi:10.1111/j.1471-0528.2010.02744.x.
- CULLEN TS. Adenomyoma of the rectovaginal septum. *Journal of the American Medical Association* 1914;LXII(11):835. doi:10.1001/jama.1914.02560360015006.
- CUNDIFF GW, TE LINDE RW. Te Linde's atlas of gynecologic surgery. Philadelphia, PA: Lippincott Williams & Wilkins; 2013. (ISBN No. 160831068X).
- DU H, TAYLOR HS. Contribution of bone marrow-derived stem cells to endometrium and endometriosis. *Stem Cells* 2007;25(8):2082–6. doi:10.1634/stemcells.2006-0828.
- FEDELE L, BIANCHI S, ZANCONATO G, BERLANDA N, BORRUTO F, FRONTINO G. Tailoring radicality in demolitive surgery for deeply infiltrating endometriosis. *Am J Obstet Gynecol* 2005;193(1):114–7. doi:10.1016/j.ajog.2004.12.085.
- FLEISCH MC, HEPP P, KALETA T, AM SCHULTE EJ, REIN D, FEHM T et al. Feasibility and first long-term results after laparoscopic rectal segment resection and vaginal specimen retrieval for deep infiltrating endometriosis. *Arch Gynecol Obstet* 2014;289(6):1241–7. doi:10.1007/s00404-014-3146-3.
- GARGETT CE, SCHWAB KE, ZILLWOOD RM, NGUYEN HP, WU D. Isolation and culture of epithelial progenitors and mesenchymal stem cells from human endometrium. *Biol Reprod* 2009;80(6):1136–45. doi:10.1095/biolreprod.108.075226.
- GONZALES M, MATOS LA DE, DA COSTA GONÇALVES, MANOEL ORLANDO, BLASBALG R, DIAS JUNIOR JA, PODGAEC S et al. Patients with adenomyosis are more likely to have deep endometriosis. *Gynecol Surg* 2012;9(3):259–64. doi:10.1007/s10397-012-0746-4.
- MARTIN DC. Hysterectomy for treatment of pain associated with endometriosis. *J Minim Invasive Gynecol* 2006;13(6):566–72. doi:10.1016/j.jmig.2006.06.022.
- REICH H. Laparoscopic treatment of extensive pelvic adhesions, including hydrosalpinx. *J Reprod Med* 1987;32(10):736–42.
- REICH H. Issues surrounding surgical menopause. Indications and procedures. *J Reprod Med* 2001;46(3 Suppl):297–306.
- REICH H, MCGLYNN F. Treatment of ovarian endometriomas using laparoscopic surgical techniques. *J Reprod Med* 1986;31(7):577–84.
- REICH H, MCGLYNN F, SALVAT J. Laparoscopic treatment of cul-de-sac obliteration secondary to retrocervical deep fibrotic endometriosis. *J Reprod Med* 1991;36(7):516–22.
- REICH H, WOOD C, WHITTAKER M. Laparoscopic anterior resection of the rectum and hysterectomy in a patient with extensive pelvic endometriosis. *Gynaecological Endoscopy* 1998;7(2):79–83. doi:10.1046/j.1365-2508.1998.00162.x.
- RIBEIRO S, REICH H, ROSENBERG J, GUGLIELMINETTI E, VIDALI A. The value of intra-operative cystoscopy at the time of laparoscopic hysterectomy. *Hum Reprod* 1999;14(7):1727–9.
- RIZK B, FISCHER AS, LOTFY HA, TURKI R, ZAHED HA, MALIK R et al. Recurrence of endometriosis after hysterectomy. *Facts Views Vis Obgyn* 2014;6(4):219–27.
- RUFFO G, SCOPELLITI F, MANZONI A, SARTORI A, ROSSINI R, CECCARONI M et al. Long-term outcome after laparoscopic bowel resections for deep infiltrating endometriosis: a single-center experience after 900 cases. *Biomed Res Int* 2014;2014:463058. doi:10.1155/2014/463058.
- SECKIN TA, NEWMAN NC, SECKIN S. Histological Findings Following Excision of Peritoneal Endometriosis With and Without Using Aqua Blue Contrast Technique (ABC<sup>™</sup>). *J Minim Invasive Gynecol* 2015;22(6):S52. doi:10.1016/j.jmig.2015.08.143.
- SIGNORILE PG, BALDI F, BUSSANI R, D'ARMIENTO M, FALCO M DE, BALDI A. Ectopic endometrium in human foetuses is a common event and sustains the theory of mullerianosis in the pathogenesis of endometriosis, a disease that predisposes to cancer. *J Exp Clin Cancer Res* 2009;28:49. doi:10.1186/1756-9966-28-49.
- WEI JJ, WILLIAM J, BULUN S. Endometriosis and ovarian cancer: a review of clinical, pathologic, and molecular aspects. *Int J Gynecol Pathol* 2011;30(6):553–68. doi:10.1097/PGR.0b013e31821f4b85.
- WEIR E, MUSTARD C, COHEN M, KUNG R. Endometriosis: what is the risk of hospital admission, readmission, and major surgical intervention? *J Minim Invasive Gynecol* 2005;12(6):486–93. doi:10.1016/j.jmig.2005.09.001.

Pierre Collinet<sup>a</sup> | Julie Sussfeld<sup>a</sup> | Sandy Hanssens<sup>a</sup> | An Segaert<sup>a</sup> | Chrystèle Rubod<sup>a</sup>

### 4.9.1 Introduction

Endometriosis is defined as the presence of endometrial glands and stroma outside the uterine cavity.<sup>9,23</sup> The disease affects about 10 to 15% of women in reproductive age<sup>2</sup> and 50% of infertile women in the World.<sup>25,39</sup>

The treatment is both an ethical and public health issue. Symptoms as dyspareunia, chronic pain, dysuria, constipation and infertility can have a major impact on the patients' quality of life. There is no correlation between symptoms described by patients and the anatomical location of endometriotic lesions.<sup>9,17</sup>

A multidisciplinary approach with complete preoperative workup is recommended including clinical exam, pelvic ultrasound, *magnetic resonance imaging* (MRI) and *transrectal endoscopic ultrasound* (EUS).<sup>9</sup>

There are various treatment options available that need to be chosen as determined by patients' needs and complaints. One of these options is medical treatment,<sup>9</sup> the other one is surgery. Given the presence of deep infiltrating endometriotic lesions or given a history of failed attempts at medical therapy, surgical treatment should be considered.<sup>1,9,12</sup>

*Deep infiltrating endometriosis* (DIE) can involve vesico-vaginal septum, recto-vaginal septum and can lead to ureteral stenosis. Often, adhesions and invasion of anatomical structures (organs, vessels and nerves) are found to adversely affect the normal course of surgery and may lead to complications. Preoperatively, clear and complete information should be given to the patient, and finally, informed consent needs to be obtained. Standard laparoscopy is the gold standard for deep pelvic endometriosis surgery as shown by *Darai, et al.* in 2010.<sup>12</sup> Surgery for the treatment of this major disease can be complex and should be managed by an adequately skilled multidisciplinary team, preferably in the setting of a reference center.

### 4.9.2 History of Robotic-Assisted Laparoscopy

Comparing the use of *robotic-assisted laparoscopy* (RAL) in 2014 on a global scale, it became evident that RAL was most widely accepted in the United States (US). Approximately 2,000 robotic systems were used in the US while there were 500 robots in Europe and 80 in France. Urologists were the pioneers in robotic surgery, but in recent years, the modality has been increasingly adopted in the field of gynaecology. First robotic interventions were performed with the Zeus system,<sup>22</sup> which is no longer marketed since 2003.<sup>5</sup> The first intervention with the Da Vinci system (Intuitive Surgical, Inc., Sunnyvale, California, USA), was performed in 1997. In 2004, the *Food and Drug Administration* (FDA) approved the Da Vinci system for use in gynaecology.<sup>21</sup> Nowadays, robotic assistance is used both in surgical oncology and in operative treatment of benign conditions.<sup>34</sup>

A robotic-assisted surgical system usually comprises three components: a surgeon console, a 3D HD vision system and a patient-side cart with interactive robotic arms (3 in the Da Vinci system and 4 in Da Vinci S) to which proprietary wrist instruments can be attached. One of the robotic arms provides support for the 12-mm laparoscope. The latest model, Da Vinci S, can be equipped with a double console or a simulator. The Endowrist system gives 7 degrees of freedom, compared to 5 in standard laparoscopy.

The authors conducted a systematic review of the literature on the role of robotic-assisted laparoscopy in the surgical treatment of deep infiltrating endometriosis (Table 4.9). The following keywords were used for this purpose: robot/robotic/robotic assistance/robotically and endometriosis/deep infiltrating endometriosis. At the time this chapter was written, seventy-one articles were published on the topic, a fact that reflects the ongoing enthusiasm for this relatively new technology.

<sup>a</sup> | Department of Obstetrics and Gynaecology, Jeanne de Flandre Hospital, CHU Lille, France

#### Corresponding author:

**Pierre Collinet**

Professeur, gynécologue-obstétricien

Clinique de Gynécologie, Hôpital Jeanne de Flandre

CHRU Lille 59037 Lille Cedex, France

E-mail: pierre.collinet@chru-lille.fr



Name of first author / Year of publication	Number of cases	Title of study	Study design, outcomes and conclusions
<i>Diguisto et al.</i> <sup>15</sup> 2015	28 <ul style="list-style-type: none"> <li>■ 6 rectal resections</li> <li>■ 22 rectal shavings</li> </ul>	Laparoscopic robotic-assisted colorectal surgery: Morbidity of colorectal resection and shaving. [French original: Laparoscopie robot-assistée pour endométriose colorectale: Morbidité de la résection digestive et du shaving].	<ul style="list-style-type: none"> <li>■ No difference between the two groups concerning postoperative pain and recurrence rate.</li> <li>■ Operative time was significantly shorter (<math>P = 0.0002</math>).</li> <li>■ Estimated blood loss was significantly lower (200 ml vs 560 ml, <math>P = 0.04</math>) in the shaving procedure.</li> <li>■ Length of hospital stay was longer (<math>P = 0.0001</math>) in the resection group.</li> <li>■ At two-month follow-up interval, there was no significant difference between the two groups.</li> </ul>
<i>Nezhat et al.</i> <sup>33</sup> 2015	147 RAL procedures 273 CL procedures	Robotic-assisted laparoscopy vs conventional laparoscopy for the treatment of advanced stage endometriosis.	<ul style="list-style-type: none"> <li>■ No difference between the two groups.</li> <li>■ No difference between the two groups in terms of post-operative/perioperative complications.</li> <li>■ Longer duration of surgery and hospital stay.</li> </ul>
<i>Collinet et al.</i> <sup>10</sup> 2014	164 cases of endometriosis stage IV 8 centers <ul style="list-style-type: none"> <li>■ rectum (n = 88)</li> <li>■ bladder (n = 23)</li> <li>■ ureter and uterosacral ligaments (n = 115)</li> <li>■ hysterectomy (n = 28).</li> </ul>	Robot-assisted laparoscopy for deep infiltrating endometriosis: international multicentric retrospective study	<ul style="list-style-type: none"> <li>■ Largest study</li> <li>■ Decreased rate of conversion to laparoscopy (0.6%).</li> <li>■ Lower morbidity for complex and multiple procedures (1.8% of re intervention).</li> <li>■ RAL seems to be a promising therapeutic modality for deep infiltrating endometriosis, stages 3 and 4, no increase in surgical time, rates of perioperative/postoperative complications, and blood loss.</li> </ul>
<i>Siesto et al.</i> <sup>38</sup> 2013	47 <ul style="list-style-type: none"> <li>■ 19 bowel resections</li> <li>■ 23 rectovaginal septum resections</li> <li>■ 5 bladder resections</li> </ul>	Robotic surgery for deep endometriosis: a paradigm shift	<ul style="list-style-type: none"> <li>■ A five year cohort study</li> <li>■ Without complication</li> <li>■ Robotic assistance is a safe and viable alternative modality well-suited to accomplish comprehensive surgical treatment of DIE, particularly when bowel or bladder resections are needed.</li> </ul>
<i>Pellegrino et al.</i> <sup>37</sup> 2013	25	Robotic shaving technique in 25 patients affected by deep infiltrating endometriosis of the rectovaginal space	<ul style="list-style-type: none"> <li>■ Without complications concerning perioperative/postoperative complications, and blood loss.</li> </ul>
<i>Bedaiwy et al.</i> <sup>3</sup> 2013	43 cohort study 19 stage III 24 stage IV	Robotic-assisted hysterectomy for the management of severe endometriosis: a retrospective review of short-term surgical outcomes.	<ul style="list-style-type: none"> <li>■ Robot-assisted laparoscopic surgery appears to be also a reasonably safe and feasible method.</li> </ul>
<i>Ercoli et al.</i> <sup>16</sup> 2012	22	Robotic treatment of colorectal endometriosis: technique, feasibility and short-term results.	<ul style="list-style-type: none"> <li>■ The first to demonstrate the feasibility of colorectal shaving in deep infiltrating endometriosis treated by robotic surgery.</li> <li>■ Without major perioperative and postoperative complications.</li> </ul>
<i>Bot-Robin et al.</i> <sup>5</sup> 2011	6	Early evaluation of the feasibility of robot-assisted laparoscopy in the surgical treatment of deep infiltrating endometriosis	<ul style="list-style-type: none"> <li>■ Time of surgery: 173 minutes.</li> <li>■ Mean time of hospitalisation: 3 days.</li> <li>■ No conversions to laparotomy.</li> <li>■ No perioperative or postoperative complications except for one patient developing bilateral pyelonephritis with hematoma in the vesicovaginal space that was managed by an ultrasound-guided puncture and antibiotic therapy.</li> </ul>
<i>Nezhat et al.</i> <sup>30</sup> 2010	78 <ul style="list-style-type: none"> <li>■ 38 cases treated by standard laparoscopy</li> <li>■ 40 cases treated by robot-assisted laparoscopy</li> </ul>	Robotic versus standard laparoscopy for the treatment of endometriosis.	<ul style="list-style-type: none"> <li>■ Only study concerned with the treatment of endometriosis comparing the outcomes of both techniques: RAL versus standard laparoscopic approach.</li> <li>■ Age, body mass index, stage of endometriosis were comparable in both groups.</li> <li>■ Time of surgery and anesthesia was longer in the robotic group. (191 vs 159 minutes)</li> <li>■ The rate of perioperative/postoperative complications, and mean blood loss were similar.</li> </ul>

**Table 4.9** Literature review on the role of robotic-assisted laparoscopy in the treatment of deep infiltrating endometriosis.

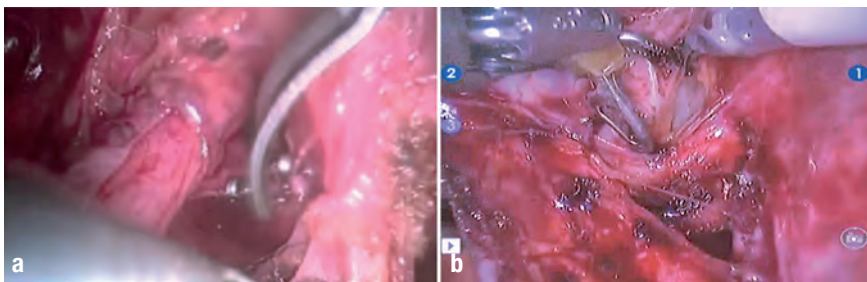
Robotic-Assisted Laparoscopy	versus	Standard Laparoscopy
<ul style="list-style-type: none"> <li>■ Improved surgical ergonomics.</li> <li>■ Three-dimensional stereoscopic vision.</li> <li>■ Lack of haptic feedback.</li> <li>■ Tremor filtration.</li> <li>■ Wider range of motion of wristed robotic instruments: seven degrees of freedom.</li> </ul>		<ul style="list-style-type: none"> <li>■ Limited surgical ergonomics.</li> <li>■ Two-dimensional vision.</li> <li>■ Haptic feedback.</li> <li>■ Tremor and operator fatigue account for inaccurate maneuvering of instruments and unsteady video camera work.</li> <li>■ Restricted range of motion of laparoscopic instruments: four degrees of freedom.</li> </ul>

**Table 4.10** Comparative overview of the pros and cons associated with robotic-assisted laparoscopy versus those of standard laparoscopy.

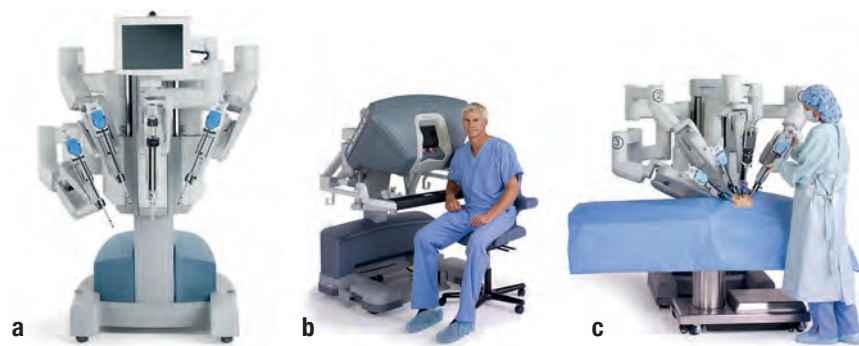
### 4.9.3 Advantages and Drawbacks of Robotic-Assisted Laparoscopic Surgery

Robotic-assisted laparoscopic surgery in gynaecology has multiple indications: hysterectomy, myomectomy, tubal re-anastomosis, sacrocolpopexy, cystectomy and pelvic and para-aortic lymphadenectomy.<sup>10,32,36</sup> Comparing the inherent features of a standard laparoscopic configuration with those of a robotic-assisted laparoscopic system, the following pros and cons should be taken into account.

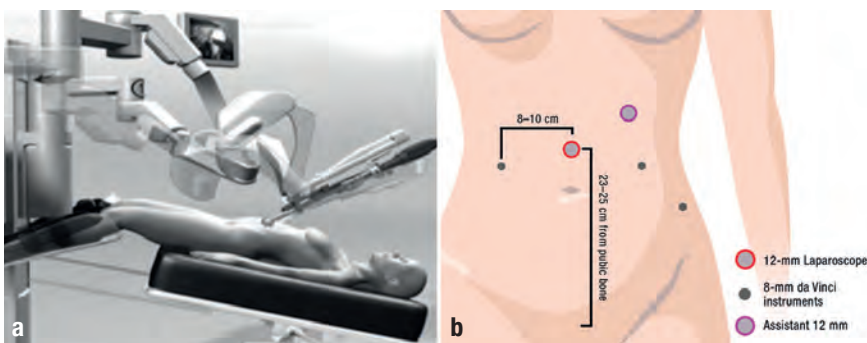
Handling of RAL systems is intuitive and the learning curve is rapid for surgeons who have already reached a good level of experience and dexterity in standard laparoscopy.<sup>4,11,20,22,31</sup> (Figs. 4.36–4.41). The main drawback of robotic-assisted surgery is the relatively high costs that limit its availability.



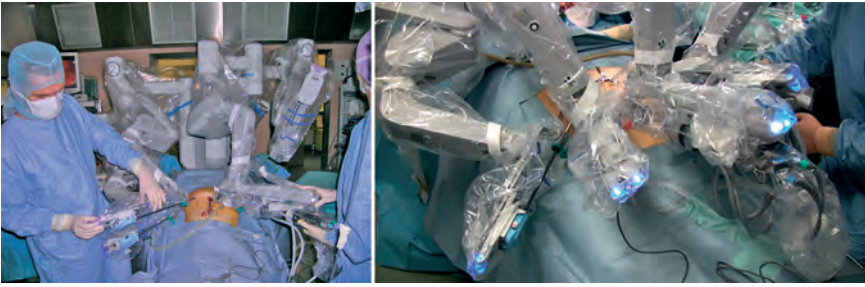
**Fig. 4.36a** Intraoperative views taken during standard laparoscopy (a) and robotic-assisted laparoscopy (RAL) (b).



**Fig. 4.37** Key components of a robotic-assisted laparoscopic system. Tiny wristed instruments are attached to 3 or 4 robotic arms (one of which is used for the 12-mm laparoscope) providing for a range of motion superior to that of the human hand (a). The ergonomically designed console (b) where the surgeon sits while operating provides for three-dimensional high definition vision. The patient-side cart (a, c) is equipped with a HD video monitor that allows the OR team to follow the course of the procedure.



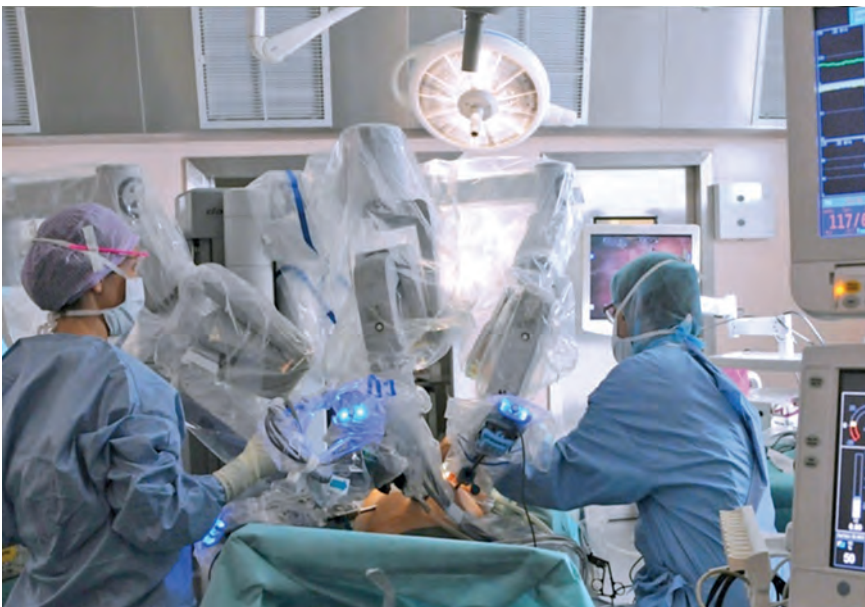**Fig. 4.38** Patient positioning (a) and port placement (b) using the *da Vinci* robotic system.



**Fig. 4.39** Robotic arms of the *da Vinci* system.



**Fig. 4.40** Surgeon console (a, b). The surgeon's fingers grasp the master controls below the display with hands and wrists naturally positioned relative to the eyes (c). Video camera, energy devices, and the 'master controls' can be operated via foot pedals (d).



**Fig. 4.41** Intraoperative image taken during robotic-assisted surgery at the University Hospital Center of Lille, France.



## 4.9.4 Case Reports and Studies on the Use of RAL for Surgical Treatment of DIE

### 4.9.4.1 Outcomes, Feasibility and Follow-up Care

Before 2008, only a few case reports were published evaluating the feasibility of this new surgical technique for the treatment of DIE. In 2008, *Chammas, et al.* described a robotic procedure for DIE including partial cystectomy and segmental rectal resection.<sup>8</sup> Other authors also reported on complex procedures performed with robotic assistance such as trachelectomy, partial cystectomy, ureterolysis, ureteral re-implantation, rectal shaving and segmental rectal resection.<sup>29</sup> The authors of this chapter issued a report confirming the feasibility of robotic surgery for DIE.<sup>5</sup> In this series of 6 cases, no conversion to laparotomy was observed.

Compared to standard laparoscopy, the rate of conversion to laparotomy seems to be decreased (0–0.6% for robotic-assisted laparoscopy versus 10–15% for standard laparoscopy).<sup>7,10,30</sup> To date, no study is available demonstrating any benefits of robotic-assisted laparoscopy in terms of perioperative morbidity.<sup>13,14,30,33</sup>

In a retrospective cohort controlled study published in 2010 by *Nezhat, et al.*<sup>30</sup> a total of 78 patients were treated for pelvic endometriosis, irrespective of the stage of disease. Two cohorts were the focus of this analysis, one for standard laparoscopy (n = 38), the other one for robotic-assisted laparoscopy (n = 40). So far, this study is the only comparative analysis of this kind, that is concerned with endometriosis. Age, body mass index and stage of endometriosis were comparable in both groups, and only 5% (2/40) of the patients had stage IV endometriosis. Robotic-assisted surgeries were longer (191 vs. 159 minutes), but complication rates and blood loss were comparable in both groups. In conclusion, *Nezhat, et al.* did not show any benefit of robotic-assisted laparoscopic resection for stages I and II endometriosis and therefore advised that this surgical modality be used electively for the most severe cases of DIE (stages III and IV).

In 2013, *Siesto, et al.* demonstrated similar results. This series of RAL procedures for DIE lends itself to demonstrate that robotic assistance is as a safe and viable alternative option that can be used effectively to achieve comprehensive surgical removal of DIE, especially in cases where bowel or bladder resection is needed.<sup>38</sup>

In 2014, *Nezhat, et al.* compared standard laparoscopy to robotic-assisted laparoscopy and did not reveal any difference between the 2 groups in terms of perioperative/postoperative complications. However, a longer operative time and a longer hospital stay were observed in the robotic group.<sup>33</sup>

A multicenter study of *Collinet et al.* published in 2014, was based on the SERGS (Society of European Robotic Gynaecological Surgery) registry of data obtained from robotic-assisted laparoscopic procedures for DIE.<sup>19</sup> The study reported a decreased rate of conversion to laparotomy (0.6%) and a lower morbidity for complex and multiple procedures (1.8% of re-intervention). RAL seems to represent a promising option in the treatment of DIE stage III and IV, demonstrating

no increase in operative time, perioperative and postoperative complications and blood loss. However, the results of this study should be evaluated more closely. Indeed, it is a retrospective study, that lacks comparable data from control groups and, apart from that, no long-term follow-up was included. Anyway, it is the largest study currently available on DIE.

### 4.9.4.2 Hysterectomy and Endometriosis

Concerning radical surgical treatment of women with severe endometriosis, in 2013, *Bedaiwy, et al.* reported 43 cases of robotic-assisted radical hysterectomy (n = 29) for stage III (n = 19) or stage IV (n = 24)<sup>3</sup>. The authors concluded that robotic-assisted hysterectomy for DIE appears to be both feasible and safe. *Patkowsky, et al.* showed that perioperative outcomes for standard laparoscopic or robotic-assisted hysterectomy, in regard to benign indications, appear to be equivalent.<sup>35</sup>

### 4.9.4.3 Endometriosis and Rectovaginal Infiltration

As regards endometriosis with colorectal involvement, *Ercoli, et al.*<sup>16</sup> in 2012 were the first to demonstrate feasibility of colorectal shaving for the treatment of DIE with robotic-assisted surgery: 22 cases in one year without any major perioperative/postoperative complication. Then, in 2015, *Diguisto, et al.*<sup>15</sup> compared rectal shaving and colorectal resection and did not reveal any difference between the two groups concerning postoperative pain and recurrence rate. *Pellegrino, et al.*<sup>37</sup> also reported complete surgical removal of rectal nodules without perioperative and/or postoperative complications. RAL for colorectal DIE seems to be both a safe and reliable procedure in the hands of well-trained surgeons.

### 4.9.4.4 Ureteral Endometriosis

The use of RAL for the treatment of ureteral endometriosis has also been reported.<sup>24,26,27</sup> In 2011, *Frick, et al.*<sup>18</sup> described two case reports of ureteral re-implantation with RAL. Both of the surgeries were completed successfully without perioperative and/or postoperative complications.

## 4.9.5 Endometriosis and Fertility

A small study published in 2013 showed a higher pregnancy rate in the RAL group compared to the standard laparoscopy group. In regard to minimal and moderate endometriosis, these results need be confirmed by randomized studies.<sup>28</sup> Concerning severe endometriosis, RAL seems to be a suitable option that may be considered in fertility surgery,<sup>6</sup> especially in cases of colorectal involvement. Again, comparative trials are needed to define the place of this technology.

## 4.9.6 Conclusion

Deep infiltrating endometriosis is probably one of the best indications for RAL. It is well known that the surgical treatment of DIE is among the most challenging and complex tasks to undertake in the field of gynecology. For these reasons, the technical aspects and special features of RAL (3D vision, tremor filtration, surgical ergonomics) lend themselves for being taken advantage of in this indication. To date, there is no sufficient scientific data available to clearly demonstrate

the benefits of RAL in terms of perioperative complications, blood loss, length of hospital stay and fertility outcomes. In order to allow these clinical parameters of RAL and standard laparoscopy to be compared, randomized control trials are necessary.

### 4.9.7 References

- ABBOTT J, HAWE J, HUNTER D, HOLMES M, FINN P, GARRY R. Laparoscopic excision of endometriosis: a randomized, placebo-controlled trial. *Fertil Steril* 2004;82(4):878–84. doi:10.1016/j.fertnstert.2004.03.046.
- BALLWEG ML. Impact of endometriosis on women's health: comparative historical data show that the earlier the onset, the more severe the disease. *Best Pract Res Clin Obstet Gynaecol* 2004;18(2):201–18. doi:10.1016/j.bpobgyn.2004.01.003.
- BEDAIWY MA, RAHMAN MYA, CHAPMAN M, FRASURE H, MAHAJAN S, GRUENIGEN VE VON et al. Robotic-assisted hysterectomy for the management of severe endometriosis: a retrospective review of short-term surgical outcomes. *JSLs* 2013;17(1):95–9. doi:10.4293/108680812X13517013317275.
- BOKHARI MB, PATEL CB, RAMOS-VALADEZ DI, RAGUPATHI M, HAAS EM. Learning curve for robotic-assisted laparoscopic colorectal surgery. *Surg Endosc* 2011;25(3):855–60. doi:10.1007/s00464-010-1281-x.
- BOT-ROBIN V, RUBOD C, ZINI L, COLLINET P. Early evaluation of the feasibility of robot-assisted laparoscopy in the surgical treatment of deep infiltrating endometriosis. *Gynecol Obstet Fertil* 2011;39(7–8):407–11. doi:10.1016/j.gyobfe.2011.05.002.
- CARBONNEL M, GOETGHELUCK J, FRATI A, EVEN M, AYOUBI JM. Robot-assisted laparoscopy for infertility treatment: current views. *Fertil Steril* 2014;101(3):621–6. doi:10.1016/j.fertnstert.2014.01.020.
- CARVALHO L, ABRAO MS, DESHPANDE A, FALCONE T. Robotics as a new surgical minimally invasive approach to treatment of endometriosis: a systematic review. *Int J Med Robot* 2012;8(2):160–5. doi:10.1002/rcs.451.
- CHAMMAS MF JR, KIM FJ, BARBARINO A, HUBERT N, FEUILLU B, COISSARD A et al. Asymptomatic rectal and bladder endometriosis: a case for robotic-assisted surgery. *Can J Urol* 2008;15(3):4097–100.
- COLLÈGE NATIONAL DES GYNÉCOLOGUES ET OBSTÉTRICIENS FRANÇAIS. CNGOF Guidelines for the Management of Endometriosis; Available from: [http://www.cngof.asso.fr/D\\_TELE/RPC\\_endometriose\\_en\\_BM.pdf](http://www.cngof.asso.fr/D_TELE/RPC_endometriose_en_BM.pdf).
- COLLINET P, LEGUEVAQUE P, NEME RM, CELA V, BARTON-SMITH P, HEBERT T et al. Robot-assisted laparoscopy for deep infiltrating endometriosis: international multicentric retrospective study. *Surg Endosc* 2014;28(8):2474–9. doi:10.1007/s00464-014-3480-3.
- DAKIN GF, GAGNER M. Comparison of laparoscopic skills performance between standard instruments and two surgical robotic systems. *Surg Endosc* 2003;17(4):574–9. doi:10.1007/s00464-002-8938-z.
- DARAI E, DUBERNARD G, COUTANT C, FREY C, ROUZIER R, BALLESTER M. Randomized trial of laparoscopically assisted versus open colorectal resection for endometriosis: morbidity, symptoms, quality of life, and fertility. *Ann Surg* 2010;251(6):1018–23. doi:10.1097/SLA.0b013e3181d9691d.
- DARAI E, LESIEUR B, DUBERNARD G, ROUZIER R, BAZOT M, BALLESTER M. Fertility after colorectal resection for endometriosis: results of a prospective study comparing laparoscopy with open surgery. *Fertil Steril* 2011;95(6):1903–8. doi:10.1016/j.fertnstert.2011.02.018.
- DARAI E, THOMASSIN I, BARRANGER E, DETCHEV R, CORTEZ A, HOUURY S et al. Feasibility and clinical outcome of laparoscopic colorectal resection for endometriosis. *Am J Obstet Gynecol* 2005;192(2):394–400. doi:10.1016/j.ajog.2004.08.033.
- DIGUISTO C, HÉBERT T, PATERNOTTE J, KELLAL I, MARRET H, OULDAMER L et al. Laparoscopie robot-assistée pour endométriose colorectale: Morbidité de la résection digestive et du shaving. *Gynécologie Obstétrique & Fertilité* 2015;43(4):266–70. doi:10.1016/j.gyobfe.2015.02.006.
- ERCOLI A, D'ASTA M, FAGOTTI A, FANFANI F, ROMANO F, BALDAZZI G et al. Robotic treatment of colorectal endometriosis: technique, feasibility and short-term results. *Hum Reprod* 2012;27(3):722–6. doi:10.1093/humrep/der444.
- FAUCONNIER A, FRITEL X, CHAPRON C. Endometriosis and pelvic pain: epidemiological evidence of the relationship and implications. *Gynecol Obstet Fertil* 2009;37(1):57–69. doi:10.1016/j.gyobfe.2008.08.016.
- FRICK AC, BARAKAT EE, STEIN RJ, MORA M, FALCONE T. Robotic-Assisted Laparoscopic Management of Ureteral Endometriosis. *JSLs* 2011;15(3):396–9. doi:10.4293/108680811X13125733356314.
- HANSSSENS S, NISOLLE M, LEGUEVAQUE P, NEME RM, CELA V, BARTON-SMITH P et al. Robotic-assisted laparoscopy for deep infiltrating endometriosis: the Register of the Society of European Robotic Gynaecological Surgery. *Gynecol Obstet Fertil* 2014;42(11):744–8. doi:10.1016/j.gyobfe.2014.09.005.
- HERNANDEZ JD, BANN SD, MUNZ Y, MOORTHY K, DATTA V, MARTIN S et al. Qualitative and quantitative analysis of the learning curve of a simulated surgical task on the da Vinci system. *Surg Endosc* 2004;18(3):372–8. doi:10.1007/s00464-003-9047-3.
- HOLLOWAY RW, PATEL SD, AHMAD S. Robotic surgery in gynecology. *Scand J Surg* 2009;98(2):96–109.
- JERBY BL, KESSLER H, FALCONE T, MILSOM JW. Laparoscopic management of colorectal endometriosis. *Surg Endosc* 1999;13(11):1125–8.
- KONINCKX PR, MEULEMAN C, DEMEYERE S, LESAFFRE E, CORNILLIE FJ. Suggestive evidence that pelvic endometriosis is a progressive disease, whereas deeply infiltrating endometriosis is associated with pelvic pain. *Fertil Steril* 1991;55(4):759–65.
- LEE Z, LLUKANI E, REILLY CE, MYDLO JH, LEE DI, EUN DD. Single surgeon experience with robot-assisted ureteroureterostomy for pathologies at the proximal, middle, and distal ureter in adults. *J Endourol* 2013;27(8):994–9. doi:10.1089/end.2013.0075.
- MISSMER SA, CRAMER DW. The epidemiology of endometriosis. *Obstet Gynecol Clin North Am* 2003;30(1):1–19, vii.
- MUSCH M, HOHENHORST L, PAILLIART A, LOEWEN H, DAVOUDI Y, KROEPFL D. Robot-assisted reconstructive surgery of the distal ureter: single institution experience in 16 patients. *BJU Int* 2013;111(5):773–83. doi:10.1111/j.1464-410X.2012.11673.x.
- MUSCH M, JANOWSKI M, STEVES A, ROGGENBUCK U, BOERGER A, DAVOUDI Y et al. Comparison of early postoperative morbidity after robot-assisted and open radical cystectomy: results of a prospective observational study. *BJU Int* 2014;113(3):458–67. doi:10.1111/bju.12374.
- NEME RM, SCHRAIBMAN V, OKAZAKI S, MACCAPANI G, CHEN WJ, DOMIT CD et al. Deep infiltrating colorectal endometriosis treated with robotic-assisted rectosigmoidectomy. *JSLs* 2013;17(2):227–34. doi:10.4293/108680813X13693422521836.
- NEZHAT C, HAJHOSSEINI B, KING LP. Robotic-assisted laparoscopic treatment of bowel, bladder, and ureteral endometriosis. *JSLs* 2011;15(3):387–92. doi:10.4293/108680811X13125733356396.

30. NEZHAT C, LEWIS M, KOTIKELA S, VEERASWAMY A, SAADAT L, HAJHOSSEINI B et al. Robotic versus standard laparoscopy for the treatment of endometriosis. *Fertil Steril* 2010;94(7):2758–60. doi:10.1016/j.fertnstert.2010.04.031.
31. NEZHAT C, SABERI NS, SHAHMOHAMADY B, NEZHAT F. Robotic-assisted laparoscopy in gynecological surgery. *JLS* 2006;10(3):317–20.
32. NEZHAT CH, ROGERS JD. Robot-assisted laparoscopic trachelectomy after supracervical hysterectomy. *Fertil Steril* 2008;90(3):850.e1–3. doi:10.1016/j.fertnstert.2007.08.042.
33. NEZHAT CR, STEVENS A, BALASSIANO E, SOLIEMANNJAD R. Robotic-assisted laparoscopy vs conventional laparoscopy for the treatment of advanced stage endometriosis. *J Minim Invasive Gynecol* 2015;22(1):40–4. doi:10.1016/j.jmig.2014.06.002.
34. OEHLER MK. Robot-assisted surgery in gynaecology. *Aust N Z J Obstet Gynaecol* 2009;49(2):124–9.
35. PATZKOWSKY KE, AS-SANIE S, SMORGICK N, SONG AH, ADVINCULA AP. Perioperative outcomes of robotic versus laparoscopic hysterectomy for benign disease. *JLS* 2013;17(1):100–6. doi:10.4293/108680812X13517013317914.
36. PAYNE TN, PITTEP MC. Robotic-assisted surgery for the community gynecologist: can it be adopted? *Clin Obstet Gynecol* 2011;54(3):391–411. doi:10.1097/GRF.0b013e31822b4998.
37. PELLEGRINO A, DAMIANI GR, TRIO C, FACCIOLI P, CROCE P, TAGLIABUE F et al. Robotic Shaving Technique in 25 Patients Affected by Deep Infiltrating Endometriosis of the Rectovaginal Space. *J Minim Invasive Gynecol* 2015;22(7):1287–92. doi:10.1016/j.jmig.2015.06.002.
38. SIESTO G, IEDA N, ROSATI R, VITOBELLO D. Robotic surgery for deep endometriosis: a paradigm shift. *Int J Med Robot* 2014;10(2):140–6. doi:10.1002/rcs.1518.
39. WITZ CA, BURNS WN. Endometriosis and infertility: is there a cause and effect relationship? *Gynecol Obstet Invest* 2002;53 Suppl 1:2–11.



## 4.10

## Endometriosis-Associated Malignant Neoplasms\*

Uwe Andreas Ulrich<sup>a</sup> | Dietmar Schmidt<sup>b</sup>

## 4.10.1 Introduction

Though a histologically benign condition,<sup>3,30</sup> endometriosis has been shown to share some characteristics with malignant tumors such as local invasion and tissue damage, neoangiogenesis with elevated VEGF expression, lymphangiogenesis, COX2 overexpression, genomic instability, resistance to apoptosis, and the elevation of CA-125 levels.<sup>15,20,34,55</sup> More importantly, endometriosis may be associated with certain malignant tumors. In fact, malignant tumors may arise in endometriosis, and there is some evidence that endometriosis may transform into malignant tissue through ‘atypical endometriosis’.<sup>43,58,63</sup> Endometriosis has even been termed a ‘precancerous lesion’,<sup>58</sup> or ‘precursor lesion’.<sup>7,49</sup>

## 4.10.2 Histopathology

As early as 1925, *Sampson*<sup>51</sup> speculated that endometrioid carcinoma of the ovary may arise in ovarian endometrial implants. He defined an *endometriosis-associated ovarian carcinoma* (EAO) as follows: First, there must be evidence of endometriosis in close proximity to the tumor. Second, another source of invasion must be excluded; and third, the presence of endometrial stroma should be clearly evident.<sup>51</sup> Later, another criterion was added: the transition from benign endometriosis to malignant change should be histologically proven.<sup>56</sup> Even today, there is no more sophisticated or up-to-date definition of the subject.<sup>30</sup>

According to the literature, 80 % of *endometriosis-associated malignancies* (EAMs) are located in the ovary and approximately 20 % develop at extragonadal sites<sup>18,23</sup> In our experience, the proportion of ovarian involvement is even higher. As the malignant transformation of endometriosis may occur at any anatomic site that potentially could harbor that tissue, extragonadal EAMs have been described in the pelvis (rectovaginal septum and parametrium), gastrointestinal tract, abdominal wall, umbilicus, pleura, and other organs. The most common sites of occurrence of extragonadal EAMs are the rectosigmoid colon and rectovaginal septum<sup>65</sup> (Table 4.10).

Location of extragonadal EAMs	Number of cases
Bowel	40 (78 % in rectum and sigmoid colon)
Rectovaginal	18
Uterus (i.e., arising from adenomyosis)	12
Peritoneum	8
Broad ligament and parametrium	6
Urinary bladder	4
Vagina	3
Fallopian tube	2
Cervix	2
Others (umbilicus, pleura, vulva, omentum)	44
Total	139

**Table 4.10** Extragonadal malignant tumors arising in endometriosis (adapted from *Ulrich et al.*).<sup>65</sup>

<sup>a</sup> | Professor, MD; Department of Obstetrics and Gynecology, Martin Luther Hospital, Berlin, Germany

<sup>b</sup> | Professor, MD, MD h.c.; Institute of Pathology, Viersen, Germany

**Corresponding author:**

Prof. Dr. med. **Uwe Andreas Ulrich**

Martin-Luther-Krankenhaus

Klinik für Gynäkologie und Geburtshilfe

Gynäkologisches Krebszentrum, Endometriosezentrum

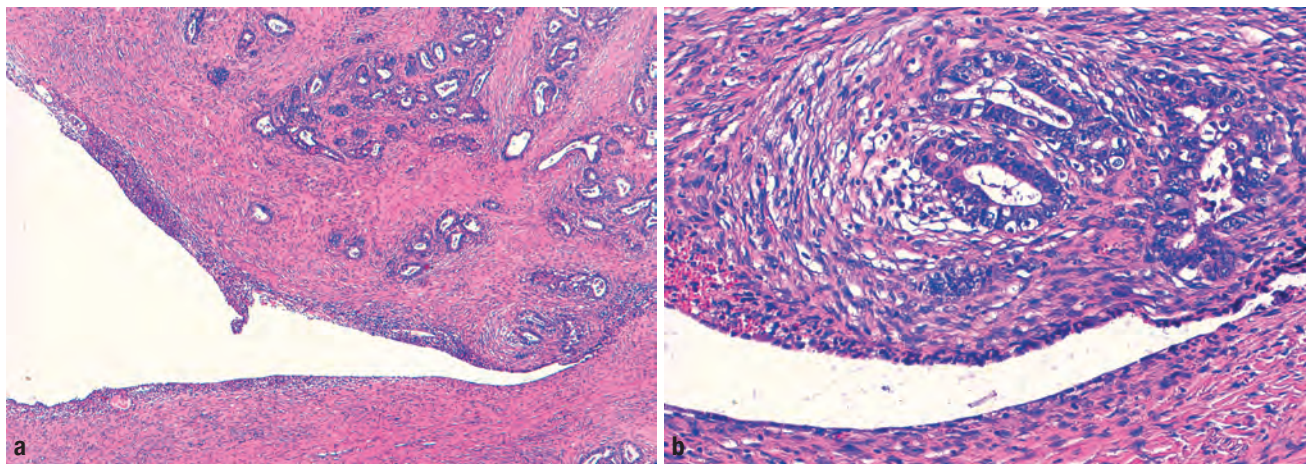
14193 Berlin, Germany

Caspar Theyss Str. 27–31

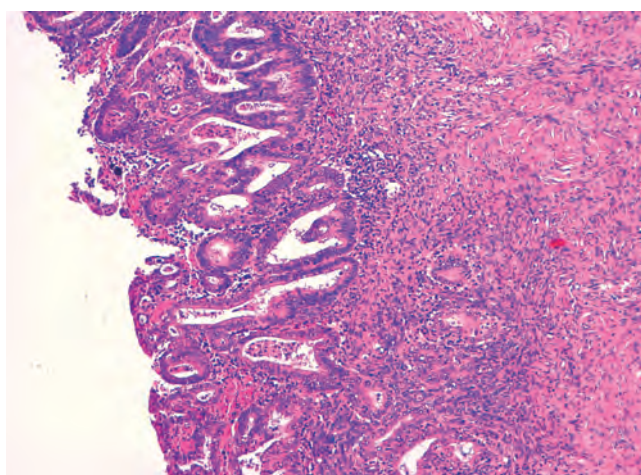
14193 Berlin, Germany

E-mail: u.ulrich@mlk-berlin.de

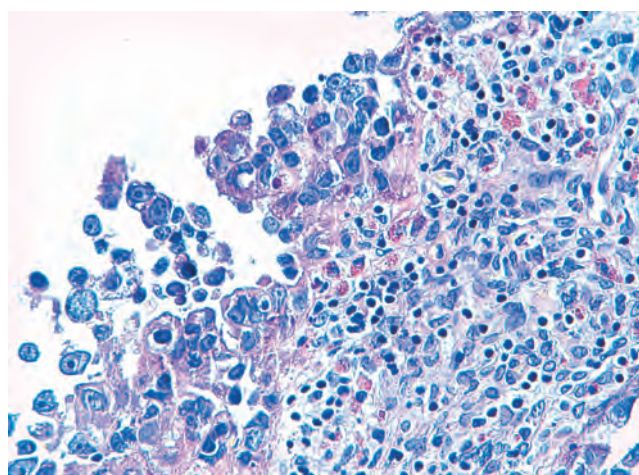
\* Note: Similar papers on the subject have been published by the authors recently; (see references<sup>11,55,66</sup>).



**Fig. 4.42a,b** Endometriotic cyst of the ovary with low-grade endometrioid carcinoma (grade 1) (a). High-power view showing cytological atypias (b).



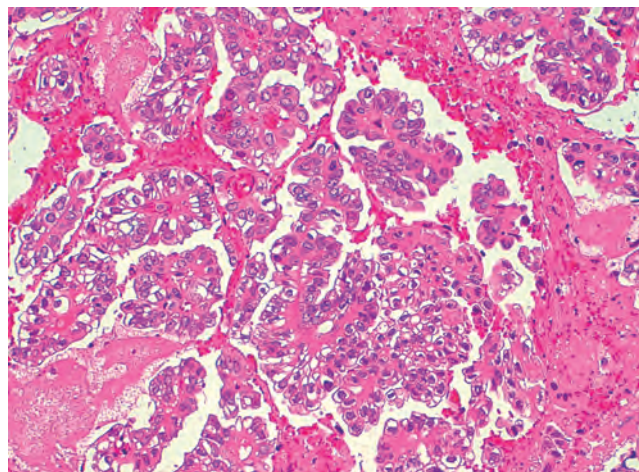
**Fig. 4.43** Papillary seromucinous adenocarcinoma (grade 1) with exophytic growth in an endometriotic cyst.



**Fig. 4.44** Endometriotic cyst is lined by a layer of atypical round cells with periodic acid-Schiff (PAS)-positive cytoplasm representing early clear cell carcinoma (carcinoma in situ).

While EAO (also referred to as *endometriosis-related ovarian neoplasms*, ERONs)<sup>33</sup> is most commonly of the clear-cell or endometrioid type, other types such as ovarian seromucinous borderline tumors, endometrial stromal sarcomas, and adenosarcomas have also been described in the literature<sup>23,55,65,70</sup> (Figs. 4.42–4.45).

EAMs may develop along different pathways. Potentially, EAOs could arise from atypical ovarian endometriosis.<sup>13,31</sup> Atypical endometriosis is characterized histologically by the hyperplasia of endometrial glands with cytological atypia or the presence of atypical ‘hobnail cells’ within ovarian endometriosis.<sup>8,55,57</sup> A direct link between atypical endometriosis and ovarian cancer was described as early as 1988: In five cases of ovarian cancer (three clear cell carcinomas and two endometrioid carcinomas), associated atypical endometriosis was found in the ovary, and in four out of five cases the atypical changes were contiguous with the area of invasive neoplasia.<sup>31</sup> Moreover, a higher rate of cytological atypia within endometriotic lesions has been found in association with EAO compared with benign endometriosis alone.<sup>48</sup> While the theory that atypical endometriosis is a premalignant condition appears to be supported by its presence in almost 80% of EAOs, there is still a lack of clear,



**Fig. 4.45** Clear cell adenocarcinoma with papillary growth pattern. Foci of hyalinization are seen in the stroma.

corroborative scientific evidence.<sup>13,73</sup> Another theory holds that while endometriosis was not a precancerous lesion, it has been linked to environmental, histologic, immunologic, and genetic factors. Some studies have shown that the microenvironments of endometriosis and EAOs share



similar conditions with respect to certain mediators and cytokines.<sup>67,73</sup> In short, there is still debate as to whether EAMs develop by direct malignant transformation of endometriotic cells through intermediate lesions (atypical endometriosis) or whether both benign endometriosis and EAMs share a similar ‘tissue environment’ in which they develop and coexist.<sup>43,60,73</sup> This ‘coexistence’ may be supported by the fact that parallel ovarian endometriosis was found in association with 53 % of clear cell ovarian cancers and 33 % of endometrioid ovarian cancers.<sup>9</sup>

### 4.10.3 Molecular Findings

A number of studies of endometriotic tissue specimens have revealed aberrations in tumor suppression genes such as p53 and PTEN (phosphatase and tensin homolog).<sup>35,44,69</sup> While PTEN mutations have been found to occur in approximately 50 % of endometrioid ovarian cancers, they are found in benign endometriotic cysts as well. On a molecular level, inactivation of the PTEN tumor suppressor gene may be one of the initial steps in carcinogenesis.<sup>52</sup> Similarly, alterations in the CTNNB1 gene (β-catenin) and PIK3CA (phosphatidylinositol-4,5-bisphosphate 3-kinase, catalytic subunit alpha) gene as well as the expression of their associated markers as distinct molecular events have been detected at early stages of neoplastic transformation in both endometrioid and clear cell ovarian cancers.<sup>36</sup> Mutations of the p53 tumor suppressor gene that are found in more than half of malignant tumors in general already occur in benign endometriotic tissue.<sup>14</sup> Furthermore, the inactivation of DNA mismatch repair genes by hypermethylation has been observed in endometriosis.<sup>35</sup>

Some years ago, a microsatellite analysis was performed in 10 patients with ovarian cancer and coexisting endometriosis, and both the tumor and endometriosis samples were analyzed for common molecular genetic alterations.<sup>49</sup> In that study, 63 events of loss of heterozygosity (LOH) were detected in the cancer specimens, and one-third of these were identified in the corresponding endometriosis samples as well. This supports the theory that endometriosis may be a precursor lesion for certain types of ovarian carcinoma.<sup>49</sup>

ARID1A (AT-rich interactive domain-containing protein 1A) gene mutations have been identified in approximately 46 % of clear-cell and 30 % of endometrioid ovarian cancers, but not in high-grade serous tumors. These mutations probably contribute to the malignant transformation of endometriosis<sup>33,50,58,72</sup> leading to a decrease in BAF250a (Brahma-associated factor) protein expression – an important tumor suppressor. In the future, the assessment of such markers may provide information as to whether or not an endometrioma will undergo eventual malignant transformation.<sup>50,58</sup> This could enable clinicians

to optimize their management of ovarian endometriomas in cases of recurrence where there is a question of ovarian removal versus ovary-preserving surgery.

KRAS (Kirsten rat sarcoma viral oncogene homolog) gene mutations have also been found in EAOCs with a frequency as high as 29 % of cases in a study of endometriosis-associated endometrioid adenocarcinomas.<sup>61</sup> Other mutations that have been identified in EAMs are CTNNB1 (beta-catenin gene)<sup>46</sup> and HNF1β (hepatocyte nuclear factor 1 homeobox B). Overexpression of HNF1β occurs in ovarian clear cell carcinomas and also in atypical and ordinary endometriosis. It has not been described in endometrioid ovarian carcinoma, however.<sup>21</sup> Similar to endometriotic cells, endometrioid ovarian cancer cells show changes in IL-1RII (interleukin-1 receptor, type II) protein expression, which is supposed to function as a protector against the carcinogenic effects of interleukin-1. This may point to a common protein signature of both benign endometriosis and endometrioid EAOCs.<sup>22</sup>

Finally, cyclic hemorrhage into ovarian endometriomas or retrograde menstruation may generate an iron-triggered oxidative stress that eventually promotes genetic alterations. It has been reported that the concentration of free iron as well as the level of oxidative stress-related markers such as lactose dehydrogenase and antioxidants were higher in endometriomas than in other types of ovarian cysts.<sup>19,24,33,74</sup>

### 4.10.4 Epidemiological Data

The risk of malignant transformation of endometriosis was estimated at 1 % in older publications.<sup>17,62</sup> While a figure of 2.5 % has been quoted specifically for ovarian endometriomas,<sup>16</sup> the range may be as much as 2 to 17 % as shown in a recent review.<sup>18</sup> Published standardized incidence ratios for the occurrence of ovarian cancer in women with endometriosis vary widely, with 1.3 to 1.9 reported by one group<sup>53</sup> and 8.95 by another.<sup>26</sup> The relative risks for the development of certain histologic types of ovarian cancer in women with endometriosis are listed in Table 4.11. The data show that the relative risk is increased not only for clear cell and endometrioid types but also for low-grade serous carcinoma. By contrast, no association has been found between endometriosis and the occurrence of mucinous and high-grade serous ovarian cancers or with borderline ovarian tumors,<sup>23,47</sup> although the finding for the latter group is controversial (*D. Schmidt*, unpublished data).

In addition, it has been shown that endometriosis is associated with an increased risk of developing various other malignancies, not all of them gynecologic. Cohort and case control studies found that women with endometriosis were

Clear cell ovarian cancer	RR 3.05	(95 %-KI 2.43–3.84, p < 0.0001)
Endometrioid ovarian cancer	RR 2.04	(95 %-KI 1.67–2.48, p < 0.0001)
Low-grade serous ovarian cancer	RR 2.11	(95 %-KI 1.39–3.20, p < 0.0001)
High-grade serous ovarian cancer	RR 1.13	(95 %-KI 0.97–1.32, p = 0.13)
Mucinous ovarian cancer	RR 1.02	(95 %-KI 0.69–1.50, p = 0.93)

**Table 4.11** Relative risk (RR) that patients with endometriosis will be diagnosed with a specific histologic type of ovarian cancer (adapted from *Pearce et al.*).<sup>47</sup>



more likely to be diagnosed with endometrial cancer, breast cancer, colorectal cancer, or non-Hodgkin lymphoma later in life.<sup>5,27,42,68</sup> To date, however, the clinical significance of these findings remains unclear, so doctors should avoid confusing their patients by citing unproven information.<sup>64</sup>

#### 4.10.5 Clinical Relevance

There are certain risk factors that make the development of an EAM more likely. Endometrioma size and postmenopausal status have been shown to be independent predictive factors for the development of ovarian cancer in endometriosis patients.<sup>25</sup> In one prospective cohort study, a cutoff diameter  $\geq 9$  cm for ovarian endometriomas was associated with an increased risk of developing ovarian cancer.<sup>25</sup> Also, both endogenous (like obesity) and exogenous hyperestrogenism, the use of unopposed estrogens after hysterectomy, and treatment with tamoxifen have been shown to be risk factors for the development of EAMs.<sup>37,73,75</sup> By contrast, oral hormonal contraceptive use, childbearing, tubal ligation, and hysterectomy appear to be protective factors.<sup>39,40</sup>

Clinically, EAOC is somewhat different from high-grade serous ovarian carcinoma.<sup>32</sup> Women with EAOC are suggested to have an earlier onset of their malignant disease by an average of 5.5 years, with a mean age of  $48.3 \pm 10.8$  years.<sup>2</sup> In another retrospective study, patients with endometriosis-associated clear cell ovarian cancer were on average 10 years younger than those with ovarian cancers not associated with endometriosis.<sup>45</sup>

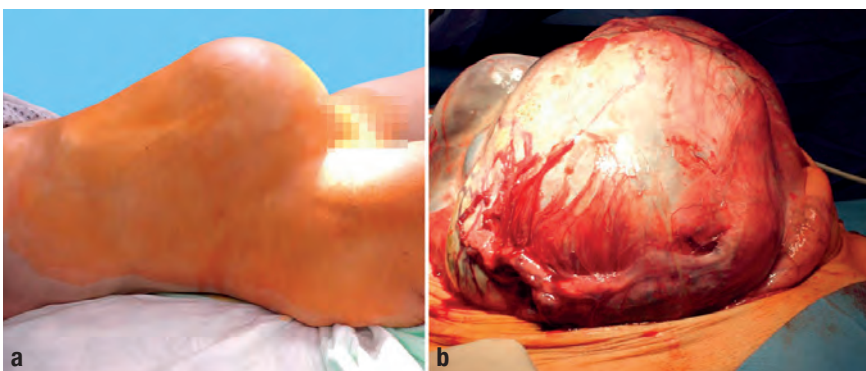
Endometrioid EAOC usually presents at a lower stage (FIGO I or II) and as low- or intermediate grade (grade 1 or 2) disease. Clear cell EAOCs, by definition, are high-grade tumors (grade 3). Ascites on initial presentation is rare<sup>10,54</sup> (Fig. 4.46). Several authors have claimed that EAOC is associated with a better prognosis in terms of both disease-free and overall survival compared with non-EAOC cases.<sup>1</sup> EAOC has even been described as a biologically distinct entity.<sup>4,11,12,23,45</sup> These findings, however, have been contradicted by other groups: after control for stage, age, grade, and treatment, no difference in overall survival between the two patient groups could be shown.<sup>10,29,38</sup> In other words, the better clinical outcomes of monophasic clear cell and endometrioid EAOC could be explained by a greater proportion of early-stage tumors rather than by an association with endometriosis (as a predictor) per se.<sup>9–11,29,54</sup> Whether the clinical courses of endometrioid and

clear cell EAMs are different needs to be explored in future studies.

The treatment of choice for EAOC and extragonadal EAM is oncologically sound removal with tumor-free margins. The stage-adapted surgical treatment strategy for EAOC is clearly defined.<sup>71</sup> In most cases this surgical treatment is straightforward for both EAOCs and extragonadal EAMs, as extrapelvic manifestations are rare. Extragonadal EAMs of the rectum are not easy to classify (FIGO, TNM). A gynecologic oncologist would tend to classify such tumors as ovarian or endometrial cancers, which they obviously are not, while a general surgeon might also incorrectly consider an EAM of the rectum to be colorectal cancer. There is a lack of clear guidelines for the appropriate classification of these tumors.

Since endometrioid EAOCs are mostly low- or intermediate-grade tumors, there has been debate as to the efficacy of postoperative chemotherapy in these patients.<sup>17,66</sup> Nevertheless, one study found no difference in the response of EAOC patients to chemotherapy relative to controls with papillary serous ovarian cancer.<sup>10</sup> Given the lack of suitable data, the postoperative management of EAOC still follows the standard, guideline-oriented chemotherapy recommendations for ovarian cancer.<sup>71</sup> However, in patients with endometrioid extragonadal EAMs, especially involving the rectum or rectovaginal septum, complete surgical resection followed by adjuvant pelvic radiotherapy may be the better option.<sup>12,17,65</sup>

Taking all available data into account, the possibility of malignant transformation should be considered in the management of endometriosis patients. Ultimately, endometriosis is associated with an increased risk of developing EAOC.<sup>6,16,26,43,70</sup> Clinicians should be alert to cases where postmenopausal women with a prior history of endometriosis report a recurrence of their familiar endometriosis symptoms after a long complaint-free interval, without having been exposed to hormone replacement therapy. Doctors are also well-advised to be careful when women on unopposed estrogens complain about nonspecific pelvic pain of recent onset. Moreover, caution is necessary if the sonographic criteria and size of a known, potentially long-standing endometrioma begin to change. Postmenopausal women with known endometriosis and a valid indication for hormone replacement therapy should be placed on a combined estrogen-progestin regimen, or on tibolone, even



**Fig. 4.46a,b** Giant ovarian tumor in a 57-year old woman (a) The same patient after laparotomy. Proper surgical staging was performed. The tumor was classified as clear cell EAOC FIGO IB (pT1b,N0) (b). (By courtesy of Springer Medizin Verlag GmbH; Ulrich et al.<sup>66</sup>).

after hysterectomy. Unopposed estrogens should be avoided in these patients.<sup>41, 59, 64</sup>

Obviously, EAOs and extragonadal EAMs will be acknowledged and documented as such only if they are recognized and appreciated by the pathologist. This raises the question of whether these rare tumors should ideally be seen by a reference pathologist, since a second opinion has been shown to be of significant value for other ovarian entities.<sup>28</sup> In the final analysis, much remains to be done before we can fully understand the pathogenesis of EAMs, which is a prerequisite for planning appropriate treatment.

#### 4.10.6 References

- ACIÉN P, VELASCO I, ACIÉN M, CAPELLO C, VELA P. Epithelial ovarian cancers and endometriosis. *Gynecol Obstet Invest* 2015;79(2):126–35. doi:10.1159/000367597.
- ARIS A. Endometriosis-associated ovarian cancer: A ten-year cohort study of women living in the Estrie Region of Quebec, Canada. *J Ovarian Res* 2010;3:2. doi:10.1186/1757-2215-3-2.
- BERKLEY KJ, RAPKIN AJ, PAPKA RE. The pains of endometriosis. *Science* 2005;308(5728):1587–9. doi:10.1126/science.1111445.
- BOYRAZ G, SELCUK I, YAZICIOGLU A, TUNCER ZS. Ovarian carcinoma associated with endometriosis. *Eur J Obstet Gynecol Reprod Biol* 2013;170(1):211–3. doi:10.1016/j.ejogrb.2013.06.001.
- BRINTON LA, GRIDLEY G, PERSSON I, BARON J, BERGQVIST A. Cancer risk after a hospital discharge diagnosis of endometriosis. *Am J Obstet Gynecol* 1997;176(3):572–9.
- BUIS CC, VAN LEEUWEN FE, MOOIJ TM, BURGER CW. Increased risk for ovarian cancer and borderline ovarian tumours in subfertile women with endometriosis. *Hum Reprod* 2013;28(12):3358–69. doi:10.1093/humrep/det340.
- CARMEN MG DEL. Evidence for the Relationship Between Endometriosis and Epithelial Ovarian Cancer. *Obstet Gynecol Surv* 2015;70(9):587–95. doi:10.1097/OGX.0000000000000218.
- CLEMENT PB. The pathology of endometriosis: a survey of the many faces of a common disease emphasizing diagnostic pitfalls and unusual and newly appreciated aspects. *Adv Anat Pathol* 2007;14(4):241–60. doi:10.1097/PAP.0b013e3180ca7d7b.
- CUFF J, LONGACRE TA. Endometriosis does not confer improved prognosis in ovarian carcinoma of uniform cell type. *Am J Surg Pathol* 2012;36(5):688–95. doi:10.1097/PAS.0b013e31824b6eed.
- DAVIS M, RAUH-HAIN JA, ANDRADE C, BORUTA D2, SCHORGE JO, HOROWITZ NS et al. Comparison of clinical outcomes of patients with clear cell and endometrioid ovarian cancer associated with endometriosis to papillary serous carcinoma of the ovary. *Gynecol Oncol* 2014;132(3):760–6. doi:10.1016/j.ygyno.2014.01.012.
- DENSCHLAG D, MANNS M, WOLL J, ULRICH U. Endometriose und ovarielle Malignome. *Frauenarzt* 2013;54:570–2.
- ERZEN M, RAKAR S, KLANCNIK B, SYRJANEN K. Endometriosis-associated ovarian carcinoma (EAO): an entity distinct from other ovarian carcinomas as suggested by a nested case-control study. *Gynecol Oncol* 2001;83(1):100–8. doi:10.1006/gyno.2001.6382.
- FUKUNAGA M, NOMURA K, ISHIKAWA E, USHIGOME S. Ovarian atypical endometriosis: its close association with malignant epithelial tumours. *Histopathology* 1997;30(3):249–55.
- GALLEGOS-ARREOLA MP, LE VALENCIA-RODRIGUEZ, AM PUEBLA-PEREZ, LE FIGUERA, ZUNIGA-GONZALEZ GM. The TP53 16-bp duplication polymorphism is enriched in endometriosis patients. *Gynecol Obstet Invest* 2012;73(2):118–23. doi:10.1159/000330702.
- GAZVANI R, TEMPLETON A. New considerations for the pathogenesis of endometriosis. *Int J Gynaecol Obstet* 2002;76(2):117–26.
- GORP T VAN, AMANT F, NEVEN P, VERGOTE I, MOERMAN P. Endometriosis and the development of malignant tumours of the pelvis. A review of literature. *Best Pract Res Clin Obstet Gynaecol* 2004;18(2):349–71. doi:10.1016/j.bpobgyn.2003.03.001.
- HEAPS JM, NIEBERG RK, BEREK JS. Malignant neoplasms arising in endometriosis. *Obstet Gynecol* 1990;75(6):1023–8.
- HEIDEMANN LN, HARTWELL D, HEIDEMANN CH, JOCHUMSEN KM. The relation between endometriosis and ovarian cancer - a review. *Acta Obstet Gynecol Scand* 2014;93(1):20–31. doi:10.1111/aogs.12255.
- HIGASHIURA Y, KAJIHARA H, SHIGETOMI H, KOBAYASHI H. Identification of multiple pathways involved in the malignant transformation of endometriosis (Review). *Oncol Lett* 2012;4(1):3–9. doi:10.3892/ol.2012.690.
- HORN LC, HENTSCHEL B, MEINEL A, ALEXANDER H, LEO C. Cyclooxygenase-2 expression, Ki-67 labeling index, and perifocal neovascularization in endometriotic lesions. *Ann Diagn Pathol* 2009;13(6):373–7. doi:10.1016/j.anndiagnpath.2009.08.001.
- KAJIHARA H, YAMADA Y, SHIGETOMI H, HIGASHIURA Y, KOBAYASHI H. The dichotomy in the histogenesis of endometriosis-associated ovarian cancer: clear cell-type versus endometrioid-type adenocarcinoma. *Int J Gynecol Pathol* 2012;31(4):304–12. doi:10.1097/PGP.0b013e318243a97b.
- KEITA M, AINMELK Y, PELMUS M, BESSETTE P, ARIS A. Endometrioid ovarian cancer and endometriotic cells exhibit the same alteration in the expression of interleukin-1 receptor II: to a link between endometriosis and endometrioid ovarian cancer. *J Obstet Gynaecol Res* 2011;37(2):99–107. doi:10.1111/j.1447-0756.2010.01320.x.
- KIM HS, KIM TH, CHUNG HH, SONG YS. Risk and prognosis of ovarian cancer in women with endometriosis: a meta-analysis. *Br J Cancer* 2014;110(7):1878–90. doi:10.1038/bjc.2014.29.
- KOBAYASHI H, IMANAKA S, NAKAMURA H, TSUJI A. Understanding the role of epigenomic, genomic and genetic alterations in the development of endometriosis (review). *Mol Med Rep* 2014;9(5):1483–505. doi:10.3892/mmr.2014.2057.
- KOBAYASHI H, SUMIMOTO K, KITANAKA T, YAMADA Y, SADO T, SAKATA M et al. Ovarian endometrioma – risks factors of ovarian cancer development. *Eur J Obstet Gynecol Reprod Biol* 2008;138(2):187–93. doi:10.1016/j.ejogrb.2007.06.017.
- KOBAYASHI H, SUMIMOTO K, MONIWA N, IMAI M, TAKAKURA K, KUROMAKI T et al. Risk of developing ovarian cancer among women with ovarian endometrioma: a cohort study in Shizuoka, Japan. *Int J Gynecol Cancer* 2007;17(1):37–43. doi:10.1111/j.1525-1438.2006.00754.x.
- KOK VC, TSAI HJ, SU CF, LEE CK. The Risks for Ovarian, Endometrial, Breast, Colorectal, and Other Cancers in Women With Newly Diagnosed Endometriosis or Adenomyosis: A Population-Based Study. *Int J Gynecol Cancer* 2015;25(6):968–76. doi:10.1097/IGC.0000000000000454.
- KOMMOSS S, PFISTERER J, DU BOIS A, SCHMIDT D, KOMMOSS F. Spezialisierte histopathologische Zweitbegutachtung fortgeschrittener Ovarialkarzinome. Erfahrungen an Kollektiven aus prospektiv randomisierten Phase-III-Studien. *Pathologie* 2014;35:355–60.
- KUMAR S, MUNKARAH A, ARABI H, BANDYOPADHYAY S, SEMAAN A, HAYEK K et al. Prognostic analysis of ovarian cancer associated with endometriosis. *Am J Obstet Gynecol* 2011;204(1):63.e1-7. doi:10.1016/j.ajog.2010.08.017.

30. KURMAN RJ, HEDRICK ELLENSON L, RONNETT BM, BLAUSTEIN A (EDS.). *Blaustein's pathology of the female genital tract: With 125 tables*. 6th ed. New York, NY: Springer; 2011. (ISBN No. 9781441904898).
31. LAGRENADE A, SILVERBERG SG. Ovarian tumors associated with atypical endometriosis. *Hum Pathol* 1988;19(9):1080–4.
32. MACHADO-LINDE F, SANCHEZ-FERRER ML, CASCALES P, TORROBA A, OROZCO R, SILVA SY et al. Prevalence of endometriosis in epithelial ovarian cancer. Analysis of the associated clinical features and study on molecular mechanisms involved in the possible causality. *Eur J Gynaecol Oncol* 2015;36(1):21–4.
33. MAEDA D, SHIH I. Pathogenesis and the role of ARID1A mutation in endometriosis-related ovarian neoplasms. *Adv Anat Pathol* 2013;20(1):45–52. doi:10.1097/PAP.0b013e31827bc24d.
34. MAIORANA A, CICERONE C, NICETA M, ALIO L. Evaluation of serum CA 125 levels in patients with pelvic pain related to endometriosis. *Int J Biol Markers* 2007;22(3):200–2.
35. MARTINI M, CICCARONE M, GARGANESE G, MAGGIORE C, EVANGELISTA A, RAHIMI S et al. Possible involvement of hMLH1, p16(INK4a) and PTEN in the malignant transformation of endometriosis. *Int J Cancer* 2002;102(4):398–406. doi:10.1002/ijc.10715.
36. MATSUMOTO T, YAMAZAKI M, TAKAHASHI H, KAJITA S, SUZUKI E, TSURUTA T et al. Distinct beta-catenin and PIK3CA mutation profiles in endometriosis-associated ovarian endometrioid and clear cell carcinomas. *Am J Clin Pathol* 2015;144(3):452–63. doi:10.1309/AJCPZ5T2POOFMQRV.
37. MCCLUGGAGE WG, BRYSON C, LAMKI H, BOYLE DD. Benign, borderline, and malignant endometrioid neoplasia arising in endometriosis in association with tamoxifen therapy. *Int J Gynecol Pathol* 2000;19(3):276–9.
38. MELIN A, LUNDHOLM C, MALKI N, SWAHN ML, SPAREN P, BERGQVIST A. Endometriosis as a prognostic factor for cancer survival. *Int J Cancer* 2011;129(4):948–55. doi:10.1002/ijc.25718.
39. MERRITT MA, PARI M DE, VITONIS AF, TITUS LJ, CRAMER DW, TERRY KL. Reproductive characteristics in relation to ovarian cancer risk by histologic pathways. *Hum Reprod* 2013;28(5):1406–17. doi:10.1093/humrep/des466.
40. MODUGNO F, NESS RB, ALLEN GO, SCHILDKRAUT JM, DAVIS FG, GOODMAN MT. Oral contraceptive use, reproductive history, and risk of epithelial ovarian cancer in women with and without endometriosis. *Am J Obstet Gynecol* 2004;191(3):733–40. doi:10.1016/j.ajog.2004.03.035.
41. MOEN MH, REES M, BRINCAT M, EREL T, GAMBACCIANI M, LAMBRINOUDAKI I et al. EMAS position statement: Managing the menopause in women with a past history of endometriosis. *Maturitas* 2010;67(1):94–7. doi:10.1016/j.maturitas.2010.04.018.
42. MUNKSGAARD PS, BLAAKAER J. The association between endometriosis and gynecological cancers and breast cancer: a review of epidemiological data. *Gynecol Oncol* 2011;123(1):157–63. doi:10.1016/j.ygyno.2011.06.017.
43. NESS RB. Endometriosis and ovarian cancer: thoughts on shared pathophysiology. *Am J Obstet Gynecol* 2003;189(1):280–94.
44. NEZHAT F, COHEN C, RAHAMAN J, GRETZ H, COLE P, KALIR T. Comparative immunohistochemical studies of bcl-2 and p53 proteins in benign and malignant ovarian endometriotic cysts. *Cancer* 2002;94(11):2935–40. doi:10.1002/cncr.10566.
45. OREZZOLI JP, RUSSELL AH, OLIVA E, CARMEN MG DEL, EICHHORN J, FULLER AF. Prognostic implication of endometriosis in clear cell carcinoma of the ovary. *Gynecol Oncol* 2008;110(3):336–44. doi:10.1016/j.ygyno.2008.05.025.
46. PALACIOS J, GAMALLO C. Mutations in the beta-catenin gene (CTNNB1) in endometrioid ovarian carcinomas. *Cancer Res* 1998;58(7):1344–7.
47. PEARCE CL, TEMPLEMAN C, ROSSING MA, LEE A, AM NEAR, WEBB PM et al. Association between endometriosis and risk of histological subtypes of ovarian cancer: a pooled analysis of case-control studies. *Lancet Oncol* 2012;13(4):385–94. doi:10.1016/S1470-2045(11)70404-1.
48. PREFUMO F, TODESCHINI F, FULCHERI E, VENTURINI PL. Epithelial abnormalities in cystic ovarian endometriosis. *Gynecol Oncol* 2002;84(2):280–4. doi:10.1006/gyno.2001.6529.
49. PROWSE AH, MANEK S, VARMA R, LIU J, GODWIN AK, MAHER ER et al. Molecular genetic evidence that endometriosis is a precursor of ovarian cancer. *Int J Cancer* 2006;119(3):556–62. doi:10.1002/ijc.21845.
50. SAMARTZIS EP, NOSKE A, DEDES KJ, FINK D, IMESCH P. ARID1A mutations and PI3K/AKT pathway alterations in endometriosis and endometriosis-associated ovarian carcinomas. *Int J Mol Sci* 2013;14(9):18824–49. doi:10.3390/ijms140918824.
51. SAMPSON JA. Endometrial carcinoma of the ovary, arising in endometrial tissue in that organ. *Arch Surg* 1925;10(1):1–72. doi:10.1001/archsurg.1925.01120100007001.
52. SATO N, TSUNODA H, NISHIDA M, MORISHITA Y, TAKIMOTO Y, KUBO T et al. Loss of heterozygosity on 10q23.3 and mutation of the tumor suppressor gene PTEN in benign endometrial cyst of the ovary: possible sequence progression from benign endometrial cyst to endometrioid carcinoma and clear cell carcinoma of the ovary. *Cancer Res* 2000;60(24):7052–6.
53. SAYASNEH A, TSIVOS D, CRAWFORD R. Endometriosis and ovarian cancer: a systematic review. *ISRN Obstet Gynecol* 2011;2011:140310. doi:10.5402/2011/140310.
54. SCARFONE G, BERGAMINI A, NOLI S, VILLA A, CIPRIANI S, TACCAGNI G et al. Characteristics of clear cell ovarian cancer arising from endometriosis: a two center cohort study. *Gynecol Oncol* 2014;133(3):480–4. doi:10.1016/j.ygyno.2014.03.017.
55. SCHMIDT D, ULRICH U. Endometrioseassoziierte Tumorerkrankungen des Ovars. *Pathologe* 2014;35(4):348–54. doi:10.1007/s00292-014-1949-4.
56. SCOTT RB. Malignant changes in endometriosis. *Obstet Gynecol* 1953;2(3):283–9.
57. SEIDMAN JD. Prognostic importance of hyperplasia and atypia in endometriosis. *Int J Gynecol Pathol* 1996;15(1):1–9.
58. SIUFI NJ, KHO RM, SIUFI DF, BARACAT EC, ANDERSON KS, ABRAO MS. Cellular, histologic, and molecular changes associated with endometriosis and ovarian cancer. *J Minim Invasive Gynecol* 2014;21(1):55–63. doi:10.1016/j.jmig.2013.07.021.
59. SOLIMAN NF, HILLARD TC. Hormone replacement therapy in women with past history of endometriosis. *Climacteric* 2006;9(5):325–35. doi:10.1080/13697130600868711.
60. SOMIGLIANA E, VIGANO P, PARAZZINI F, STOPPELLI S, GIAMBATTISTA E, VERCELLINI P. Association between endometriosis and cancer: a comprehensive review and a critical analysis of clinical and epidemiological evidence. *Gynecol Oncol* 2006;101(2):331–41. doi:10.1016/j.ygyno.2005.11.033.
61. STEWART CJ, LEUNG Y, WALSH MD, WALTERS RJ, YOUNG JP, BUCHANAN DD. KRAS mutations in ovarian low-grade endometrioid adenocarcinoma: association with concurrent endometriosis. *Hum Pathol* 2012;43(8):1177–83. doi:10.1016/j.humpath.2011.10.009.



62. SWIERSZ LM. Role of endometriosis in cancer and tumor development. *Ann N Y Acad Sci* 2002;955:281-92; discussion 293-5, 396-406.
63. TANASE Y, FURUKAWA N, KOBAYASHI H, MATSUMOTO T. Malignant Transformation from Endometriosis to Atypical Endometriosis and Finally to Endometrioid Adenocarcinoma within 10 Years. *Case Rep Oncol* 2013;6(3):480-4. doi:10.1159/000355282.
64. ULRICH U, BUCHWEITZ O, GREB R, KECKSTEIN J, LEFFERN I VON, OPPELT P et al. German and Austrian Societies for Obstetrics and Gynecology. National German Guideline (S2k): Guideline for the Diagnosis and Treatment of Endometriosis: Long Version – AWMF Registry No. 015-045. *Geburtshilfe Frauenheilkd* 2014;74(12):1104-18. doi:10.1055/s-0034-1383187.
65. ULRICH U, RHIEM K, KAMINSKI M, WARDELMANN E, TROG D, VALTER M et al. Parametrial and rectovaginal adenocarcinoma arising from endometriosis. *Int J Gynecol Cancer* 2005;15(6):1206-9. doi:10.1111/j.1525-1438.2005.00184.x.
66. ULRICH U, WUNSCHEL A, REICHERT VM, DARB-ESFAHANI S, DENSCHLAG D, HORN L et al. Endometriose-assoziierte maligne Tumoren. *Gynäkologe* 2015;48(3):221-7. doi:10.1007/s00129-014-3424-y.
67. VARMA R, ROLLASON T, GUPTA JK, MAHER ER. Endometriosis and the neoplastic process. *Reproduction* 2004;127(3):293-304. doi:10.1530/rep.1.00020.
68. VERCELLINI P, PARAZZINI F, BOLIS G, CARINELLI S, DINDELLI M, VENDOLA N et al. Endometriosis and ovarian cancer. *Am J Obstet Gynecol* 1993;169(1):181-2.
69. VIGANO P, SOMIGLIANA E, CHiodo I, ABBIATI A, VERCELLINI P. Molecular mechanisms and biological plausibility underlying the malignant transformation of endometriosis: a critical analysis. *Hum Reprod Update* 2006;12(1):77-89. doi:10.1093/humupd/dmi037.
70. VLAHOS NF, KALAMPOKAS T, FOTIOU S. Endometriosis and ovarian cancer: a review. *Gynecol Endocrinol* 2010;26(3):213-9. doi:10.1080/09513590903184050.
71. WAGNER U, HARTER P, HILPERT F, MAHNER S, REUSS A, DU BOIS A et al. S3-Guideline on Diagnostics, Therapy and Follow-up of Malignant Ovarian Tumours: Short version 1.0 – AWMF registration number: 032/035OL, June 2013. *Geburtshilfe Frauenheilkd* 2013;73(9):874-89. doi:10.1055/s-0033-1350713.
72. WIEGAND KC, SHAH SP, AL-AGHA OM, ZHAO Y, TSE K, ZENG T et al. ARID1A mutations in endometriosis-associated ovarian carcinomas. *N Engl J Med* 2010;363(16):1532-43. doi:10.1056/NEJMoa1008433.
73. WORLEY MJ, WELCH WR, BERKOWITZ RS, NG SW. Endometriosis-associated ovarian cancer: a review of pathogenesis. *Int J Mol Sci* 2013;14(3):5367-79. doi:10.3390/ijms14035367.
74. YAMAGUCHI K, MANDAI M, TOYOKUNI S, HAMANISHI J, HIGUCHI T, TAKAKURA K et al. Contents of endometriotic cysts, especially the high concentration of free iron, are a possible cause of carcinogenesis in the cysts through the iron-induced persistent oxidative stress. *Clin Cancer Res* 2008;14(1):32-40. doi:10.1158/1078-0432.CCR-07-1614.
75. ZANETTA GM, WEBB MJ, LI H, KEENEY GL. Hyperestrogenism: a relevant risk factor for the development of cancer from endometriosis. *Gynecol Oncol* 2000;79(1):18-22. doi:10.1006/gyno.2000.5905.

Serena Pinzauti<sup>a</sup> | Gabriele Centini<sup>a</sup> | Lucia Lazzeri<sup>a</sup> | Errico Zupi<sup>b</sup>

### 4.11.1 Introduction

Adenomyosis has been frequently defined as the “neglected diagnosis” and “elusive disease” because of its highly variable characteristics. Adenomyosis is not only considered an enigmatic disease because of the inherent difficulties in defining, classifying and diagnosing the condition, but also on account of its unclear and vague clinical presentation.<sup>1–6</sup>

Adenomyosis is a benign gynecological disease histologically characterized by the presence of endometrial glands and stroma in the myometrium resulting in hyperplasia of the surrounding smooth muscle cells. The first description of what is now known as adenomyosis dates back to 1860, but the current definition of adenomyosis was coined only in 1972.<sup>7</sup> In the past, numerous classifications have been proposed to better define adenomyosis. Primarily, adenomyosis can be defined as focal (one or more foci in the myometrium; adenomyoma) or diffuse (numerous foci spread across the myometrium) and it is often asymmetric affecting predominantly the posterior wall of uterus.

The most common symptoms of adenomyosis are abnormal uterine bleeding, dysmenorrhea and dyspareunia and infertility. Even though there is still controversy about the role of adenomyosis in the etiopathogenesis of abnormal uterine bleeding, the presence of this symptom is observed in a variable percentage of women (23–82%) and, recently, adenomyosis has been included in the system of FIGO PALM-COEIN classification for abnormal uterine bleeding.<sup>34</sup>

Furthermore, many researchers currently place particular focus on exploring the association between adenomyosis and infertility. Little attention has been given in the past to a possible relationship between adenomyosis and infertility since the definitive diagnosis was still based on histological examination after hysterectomy. While the gold standard for diagnosis of adenomyosis is based on the histological examination of specimens obtained from hysterectomy, the assessment of adenomyosis is challenging because of many confounding biases that are related to indication for surgery, advanced age of patients and difficulties that may arise in the diagnostic workup, in turn leading to failed diagnosis of the disease in many cases. During the last

decade, technological advancements in imaging modalities for the diagnosis of adenomyosis have largely contributed to improved non-invasive diagnosis of the disease. Magnetic resonance imaging (MRI) provides an accurate diagnosis of adenomyosis in symptomatic women with an overall accuracy of 80%, allowing for visualization of the endomyometrial junctional zone (JZ), whose focal or diffuse thickening is related to adenomyosis. Given the high costs incurred in MRI, it stands to reason that the current mainstay of diagnostic imaging for adenomyosis is *2D-transvaginal sonography* (2D-TVS). Even though the use of 2D-TVS is largely operator-dependent, experts in the field have rated the overall accuracy to be satisfactory, especially in clinical suspect cases. With advancements made in imaging techniques, their application has also gained more widespread acceptance in the diagnosis of adenomyosis. The use of 2D-TVS allows to use specific criteria applicable in the diagnosis of adenomyosis and the recent introduction of 3D-TVS technique provides a more distinct visualization of the junctional zone. The availability of a non-invasive diagnostic modality, like TVS, offers the chance that a diagnosis of adenomyosis can be made in a larger proportion of women with less costs and better compliance.

### 4.11.2 Major Aspects of Managing Patients with Adenomyosis

Considering the difficulties in classification and diagnosis of adenomyosis, it comes without surprise that the management of adenomyosis also poses specific challenges and multiple imponderabilities. This is why the authors strongly advise that due consideration should be given to therapeutic planning and management, which must be individualized according to each patient's specific clinical characteristics.

Classically, hysterectomy was considered the mainstay of treatment for patients with adenomyosis, but nowadays, they may also profit from the use of new therapeutic strategies. In recent years, adenomyosis therapy has in fact been subject to changes related to the introduction of new drugs, and nowadays, patients can profit from a better understanding of the pathophysiology of the disease. The choice of treatment methods and modalities is closely related to several factors:

- Patient age.
- Presence of specific symptoms and associated severity.
- Desire to preserve future fertility of the woman.
- Localization and the extent of lesions (diffuse or focal).
- Association with other gynaecological disease.

Given the current lack of specific guidelines for the management of adenomyosis, there are two conflicting objectives that should be weighed against each other: the reduction or resolution of symptoms (abnormal uterine bleeding, dysmenorrhea, dyspareunia and infertility) and the patient's desire for giving birth to a child.

<sup>a</sup> | MD; University of Siena, Department of Obstetric and Developmental Medicine, Siena, Italy

<sup>b</sup> | MD, Associate Professor of Obstetrics and Gynecology; Tor Vergata University of, Rome, Italy

#### Corresponding author:

**Errico Zupi**

Associate Professor of Obstetrics and Gynecology  
Tor Vergata University of Rome  
Via Orazio Raimondo, 18, 00173 Rome, Italy  
E-mail: ezupi@libero.it

Moreover, the frequent association of adenomyosis with other gynecological diseases is an additional confounding factor to understand the typical symptomatology and to address the correct management. In particular, there is considerable controversy about the relationship between endometriosis and adenomyosis. With the identification and characterization of the JZ, the hypothesis that endometriosis and adenomyosis represent two different aspects of the same disease entity received increasingly widespread acceptance. It is possible that long-term severe dysmenorrhea, experienced by patients with endometriosis, is strongly correlated with adenomyosis and that there is also a correlation between the severity of endometriosis and adenomyosis. Recently, it has been shown that patients who suffer from deep infiltrating endometriosis (DIE) and adenomyosis, have a significantly higher postoperative VAS score for dysmenorrhea than those presenting with DIE only, and the same results are found in the subgroup of patients with adenomyosis and ovarian endometriosis. Apart from that, evaluation of abnormal uterine bleeding in the follow-up care after surgical treatment has demonstrated, that there is a persistence of menorrhagia in adenomyosis patients with coexisting DIE and/or ovarian endometriosis.

Based on the finding that persistence of dysmenorrhea can be observed after optimal surgical resection of endometrioma or DIE, the question as to whether adenomyosis coexists with dysmenorrhea and/or abnormal uterine bleeding seems to be of crucial importance. Recent studies have shown a high correlation of adenomyosis with concomitant endometrioma (45.4%), and with DIE (47.8%). This information emphasizes the importance of a thorough diagnostic workup confirming the coexistence of endometriosis and adenomyosis, or the contrary, in order to develop a well-adapted management plan that suits the individual needs of each patient.<sup>8–13</sup>

### 4.11.3 Surgical Treatment of Adenomyosis

Treatment for adenomyosis includes symptomatic hormonal treatments and radical or conservative surgery.

Surgery should be considered in patients whose symptoms are non-responsive to medical treatment or in the event of poorly-tolerated side effects. Surgery may also be considered for infertile patients, because hormonal treatment is incompatible with the patient's desire to conceive and its effects are unsatisfactory in fertility enhancement.<sup>15</sup>

In the past, hysterectomy was the most common surgical treatment chosen for adenomyosis patients. Hysterectomy was the first diagnostic and therapeutic option for adenomyosis. Currently, hysterectomy is the surgical treatment of choice for patients in perimenopause, who no longer maintain a reproductive desire, and for those refractive to medical treatment. However, for women who want to conceive in the future or those who decline hysterectomy, conservative treatment should be performed.

The current scientific literature is focusing on many surgical options and techniques that are geared toward uterus preservation in women with childbearing potential and it

appears that the concept of “uterine-sparing surgery” is on the rise. *Grimbizis et al.* (2013) published an accurate classification and revision of uterus-sparing techniques for adenomyosis, that are suited to achieve a complete excision of the adenomyotic lesions or a cytoreductive effect, and the authors also explored the potential of non-excisional techniques.<sup>18</sup>

#### 4.11.3.1 Adenomectomy – Old and New Techniques

Adenomectomy, i.e., the focal excision of nodular adenomyotic lesions presenting as adenomyoma, is considered the most common alternative to radical surgical treatment for adenomyosis.

Adenomectomy should be offered to symptomatic patients who wish to maintain fertility, although the results in terms of pregnancy rate and obstetric outcome, control of symptoms and recurrence of lesions are still inconsistent. Major problems usually arise as a result of incomplete surgical removal of adenomyotic lesions. Unlike with myomectomy, adenomectomy can be difficult to perform due to the lack of a typical capsule surrounding the lesion. Considering these limitations, it is likely that a portion of the adenomyotic lesion is left behind and the disease remains symptomatic or that there will be a recurrence. In this context, an important role accrues to preoperative diagnostic assessment, which should be accurate enough to clearly distinguish between the various potential types of lesions (myoma or adenomyoma), size and localizations, which in the end should enable a precise and well-adapted surgical management.<sup>18,20</sup>

After the first description of the classic technique for adenomectomy in 1952 by *Hyams*,<sup>22</sup> a multitude of varying techniques emerged and, in selected cases, adenomectomy has also been proposed for the treatment of diffuse adenomyosis with reconstruction of the uterine wall for preserving integrity of the uterus.

The “classic adenomectomy” can be performed both by laparotomy and laparoscopy and requires the surgeon to follow a series of specific steps. After exploration of the pelvic cavity and localization of lesion, bipolar electrocoagulation should be used to place a longitudinal incision on the uterine wall overlying the adenomyoma.

The critical margin between the adenomyoma and the normal uterine muscle must be identified prior to proceeding with dissection of the lesion using a monopolar electrode until transection of all fibrotic bands and detachment of the lesion from the uterine body is achieved.<sup>21,23</sup> After electrocoagulation for hemostasis of the uterine wall, the seromuscular layer should be sutured with two or more layers. Hence, adenomectomy includes the same steps as myomectomy, and in case of a laparoscopic approach, the adenomyoma should be removed with the aid of a morcellator.<sup>19,22</sup>

Moreover, various alternative options have been suggested which are essentially based on a modification of uterine reconstruction or seromuscular suturing. This particularly applies to laparoscopic techniques that include the use of “overlapping flaps”<sup>51</sup> and “U-shaped suturing”<sup>50</sup> for wall reconstruction. The first laparoscopic modification involves



a different approach to the adenomyotic lesion using a monopolar needle to make a transverse incision down to the endometrium, which is then divided and split into an upper part and a lower part, followed by removal of the lesion. In a next step, the upper and lower serosal flaps are overlapped and sutured, and eventually used to counteract the loss of myometrium.<sup>51</sup>

The second technique consists of a two-step suture which is used to close the area of the lesion and to restore the normal shape of the uterus by laparoscopy: closure of the uterine wound is accomplished with a U-shaped suture at the muscle layer and figure-of-eight sutures applied to the seromuscular layer.<sup>50</sup>

A novel approach has been proposed for seromuscular suturing which is mainly represented by the laparotomic “triple-flap technique”.<sup>39</sup> Following bisection of the uterine wall for excision of the lesion (in the midline and in the sagittal plane), reconstruction is initiated by placing several interrupted sutures to approximate the antero-posterior plane of myometrium and serosa. Subsequently, the contralateral side is brought over the reconstructed first side to cover the seromuscular suture line. There is no need to overlap the sutures, only myometrial tissue flaps must overlap, while care should be taken that the myometrium of the underlying flap be stripped off from the serosal surface layer.<sup>15–19,39</sup>

Recently, a laparoscopic-assisted adenomyomectomy has been proposed using a “double flap technique”.<sup>24</sup> Following creation of pneumoperitoneum, a pelvic examination is performed to localize the lesions and to determine the size and shape of the uterus. The length of the mini-laparotomy incision should be kept minimal to match the size of the uterus and that of the anticipated lesions. Subsequently, the adenomyotic tissue is incised on both sides and cut away using a scalpel or monopolar electrosurgery. In a next step, the endometrial cavity is sutured and the first flap created in one side wall of the uterus is brought into contact with the second flap at the other side of the uterine wall, i.e., the second is covered by the first flap. Prior to this, the serosal surface of the underlying flaps is stripped off to ensure that only myometrial tissue flaps make contact. To finish, the second flap in the other side of the uterine wall is brought to cover the first flap located in one side of the uterine wall.<sup>24</sup>

Finally, taking into account that the variable blood supply of adenomyoma differs considerably from that of normal myometrium, there is a significant risk of blood loss. Therefore, adequate prophylactic measures should be taken, such as intralesional instillation of vasopressin prior to cutting the uterine wall, and the use of anti-adhesive agents applied to the uterine body at the end of the operation.<sup>27–29,31–33</sup>

To conclude, as previously stated, the results of all these techniques in terms of pregnancy outcome, control of symptoms and prevention of recurrent lesions are still subject of a lively debate in the literature and a clear consensus on the best surgical techniques for adenomyomectomy has not been reached yet. Recent data support a high level of relief from symptoms of dysmenorrhea and a reduced rate of

abnormal uterine bleeding.<sup>39,50</sup> Conversely, the recurrence rate of lesions (15 %) and that of symptoms (3 %) was very low and the reproductive outcome was positive in 25–33 % of infertile women.<sup>39,50</sup> Apart from that, when taking an overall look at the techniques reported in the literature, only a few postoperative complications were observed and only a few uterine complications occurred during pregnancies. In summary, the quantified pregnancy rate and delivery rate was 60.5 % and 83.1 %, respectively.

#### 4.11.3.2 Cytoreductive Techniques/Partial Adenomyomectomy

Cytoreductive techniques should be considered in selected patients with diffuse adenomyosis, where a complete removal of lesions would result in excision of a critical amount of healthy myometrium and would therefore be tantamount to “functional” hysterectomy.<sup>38,54</sup> The term “cytoreductive” was coined to describe a partial removal of all clinically recognizable adenomyotic lesions.

By definition, the term *partial adenomyomectomy* is applied to various techniques which may comprise *wedge resection* of the uterine wall, *transverse H-incision* technique and *asymmetric dissection* of the uterus. These techniques are frequently associated with disease recurrences and spontaneous uterine rupture during pregnancy.

The traditional “wedge resection” of adenomyoma limits the complete surgical removal since the cuneiform excision frequently leaves behind some fragments of adenomyotic tissue, increasing the risk of recurrences and unfavourable pregnancy outcome.<sup>50</sup> Another traditional technique involves the use of a complete vertical or transverse incision of the uterine wall to identify solitary non-microscopical adenomyotic lesions and closure with a single interrupted suture layer. This technique has been recently modified resulting in the so-called *transverse H-incision* technique. Once the vertical incision is made on the uterine wall, two transverse incisions are placed perpendicularly to the first incision, facilitating a more complete exploration of the myometrium.<sup>17</sup>

In 2010, *Nishida et al.* also described a conservative technique for diffuse adenomyosis consisting in an “asymmetric dissection of the uterus” by laparotomy.<sup>38,38</sup> The serosal incision is made starting from the level of the internal os at the anterior/posterior wall and the uterine fundus, dissecting the myometrium in a diagonal direction. Then adenomyotic lesions are excised using a loop electrode to a thickness of 5 mm of the inner myometrium.<sup>38</sup>

Recently, *Saremi et al.* proposed a novel technique of adenomyomectomy in women with severe uterine adenomyosis. Using a laparotomic approach, the uterus is incised placing a vertical incision deeply into the myometrium until the uterine cavity is reached and the myometrial thickness is measured. The adenomyotic lesions were radically resected in several layers on both edges of the uterus. Following accurate haemostasis and suture closure of the endometrium and myometrium, the external serous layer is sutured in such a way that the cut margins are inverted inside.<sup>47</sup>

Similarly to adenomyomectomy, use of cytoreductive techniques for the treatment of adenomyosis can provide comprehensive control of symptoms, however the resulting pregnancy rates appear to be lower (46.9%).

#### 4.11.3.3 Endometrial Ablation

Hysteroscopic endometrial ablation is a new and less aggressive therapeutic option for adenomyosis, indicated as conservative treatment in perimenopausal or menopausal patients or in those who have already fulfilled their desire for future pregnancy. Endometrial ablation is mainly indicated for the control of abnormal uterine bleeding, while also allowing for sufficient control of pain symptoms. Recent studies report an amenorrhea rate ranging from 25% to 40%, but also a high hypomenorrhea rate (55–68%).

Endometrial ablation can be performed using YAG laser, rollerball resection, or other ablation techniques (thermal balloon ablation, cryoablation, circulated hot fluid ablation, microwave ablation, and bipolar radiofrequency ablation).

The postoperative outcomes of resectoscopic endometrial ablation with the rollerball in patients with adenomyosis are strictly related to the depth of the foci to be treated.<sup>30</sup> Similarly, the use of YAG laser is limited when foci penetration exceeded 2.5 mm.<sup>30</sup>

Generally, the thermal effect applied in these procedures can destroy the endometrium as deep as 2–3 mm and causes fibrosis as well as scarring of the basal layer to prevent further endometrial proliferation, in turn leading to amenorrhea or hypomenorrhea. Moreover, the destruction of the endometrial layer also contributes to a decrease in the production of prostaglandins, resulting in a consistent attenuation of pain symptoms. *McCausland et al.* described an endometrial resection technique for adenomyosis with a myometrial penetration depth of 2.3 mm, considering that the major origin of abnormal uterine bleeding arises from arteries located at a depth of approximately 5 mm in the myometrium.<sup>33</sup> It is noteworthy that patients with superficial adenomyosis (< 2 mm) – unlike those with deep adenomyosis – had a positive outcome of treatment. In case of deep adenomyosis, the ectopic endometrial glands may persist and eventually proliferate through the area of ablation or resection, leading to recurrent bleeding. Patients with deep endometrial penetration into the myometrium presented with poor outcomes after ablation. Patients with focal and superficial adenomyosis seem to be ideal candidates for hysteroscopic resection, but on the other hand, ablation seems to be less effective in patients with enlarged uterus and/or deep adenomyosis.

Recently, some authors reported that incomplete excision of adenomyotic foci could entail cell proliferation enhancing disease progression. It seems reasonable that this effect may also create adenomyosis de novo and stimulate bleeding from foci by impaired contractions of the damaged surrounding myometrium.<sup>30</sup>

In an attempt to optimize the postoperative results, some authors also examined the usefulness of GnRH pre-treatment

before endometrial ablation for adenomyosis, reporting that ablation during the natural proliferative phase of menstrual cycle without any prior treatment resulted in a significantly longer operative time with a higher risk of side effects related to intravasation.<sup>44</sup>

A potential alternative procedure in case of diffuse and deep adenomyosis may be microwave endometrial ablation (MEA). Using a frequency of 2.45 GHz, surgeons undertake endometrial ablation only once in each area of the uterus, taking into account that repeated treatment may cause severe iatrogenic damage to surrounding organs. Conversely, *Nakamura et al.* stated that adenomyosis patients with thickened myometrium were found to be unresponsive to treatment using the conventional single-session MEA and that multiple MEA treatments would improve menorrhagia outcomes in non-responsive patients. Hence, a myometrium thickness of at least 2.9 cm is necessary to perform triplicate MEA safely.<sup>36</sup>

In conclusion, the postoperative success of endometrial ablation for adenomyosis is mainly related to the penetration depth of adenomyotic foci. In addition, the high efficacy rate may be partly due to the size of the uterus and to concomitant submucosal myoma or polyps, which underscores the importance of a thorough preoperative diagnostic assessment. The hysteroscopic approach may allow quick recovery and reduced hospitalization, with a low incidence of complications (3.9%). On the other hand, the uncertain future fertility after endometrial ablation makes it necessary to limit the procedure to cases where fertility is not an issue.

#### 4.11.3.4 Uterine Artery Embolization (UAE)

Recently, the use of uterine artery embolization (UAE) has been suggested as a treatment for symptomatic patients with adenomyosis, although scientific studies on procedure outcome still do not allow to draw conclusive findings.<sup>25</sup> The scientific literature has shown a variable success rate which stems from various contributing factors such as the use of diverse agents and the presence of coexisting surrounding myomas. Myomas generally have large-caliber arteries that may require a more vigorous embolization than the smaller arteries that are found in adenomyotic lesions, thus resulting in a higher failure rate in patients with concomitant disease. Some studies revealed the only predictors of procedure failure – with hysterectomy in the follow-up period – to be rather related to the initial thickness of the junction zone than to the presence of concomitant disease or to the invasion depth of adenomyotic foci.<sup>16,49</sup>

Apart from that, UAE ideally requires that complete occlusion of the arterial supply be achieved<sup>35–37</sup> until a point of stasis or near stasis is confirmed. This is why devascularisation of adenomyotic areas should also be considered to predict long-term success of UAE. Due attention should also be given to the presence of processes that can incite platelet aggregation and thrombosis in adenomyosis-affected sites.<sup>48</sup>

Taking into account that the data derived from the literature on recurrence of symptoms revealed promising outcomes only

in the short-term follow-up, it is evident that further studies are needed to investigate long-term results. Many studies indicate an optimal control of abnormal uterine bleeding and dysmenorrhea with an increased quality of life.<sup>29,31–33</sup>

Up to now, UAE should be considered as an effective treatment option in symptomatic women unresponsive to medical treatment who are not eligible for surgery, but who have already completed family planning. Hence, the current data available in the literature are not enough to define the future reproductive outcome in patients undergoing UAE for adenomyosis.

#### 4.11.3.5 Magnetic Resonance-Guided Focused Ultrasound Surgery

Nowadays, magnetic resonance-guided focused ultrasound surgery (MRgFUS) – a new non-invasive technique that has been used successfully for the treatment of uterine myomas – is currently investigated to estimate its potential efficiency in the treatment of adenomyosis.<sup>45</sup> Ultrasound beams are precisely directed to the adenomyotic foci with a transducer that is concentrated in a focal point within the body. The energy delivered to the target area induces a rise in tissue temperature above 45°–60° leading to thermal coagulation and necrosis in a circumscribed area of the myometrium. Magnetic resonance-guidance in real-time allows for a precise and well-adjusted treatment that can be modified as determined by anatomical circumstances and lesions.<sup>14</sup>

The sequential ultrasound beams are focused precisely on the site of the lesion to prevent damage to surrounding healthy myometrium and thus allows to preserve the fertility potential of the patient. Initial short-term results showed that MRgFUS is efficient in improving abnormal uterine bleeding and in reducing lesion size; both pregnancy and delivery were not affected by the procedure. Moreover, the procedure can be performed in an outpatient setting, requiring only conscious sedation, and causing only minimal to moderate post-procedural pain.<sup>55</sup>

#### 4.11.3.6 Uterine Artery Ligation

Scientific literature reports only one study that has investigated the therapeutic potential of uterine artery ligation in symptomatic women with diffuse adenomyosis. The authors describe the laparoscopic ligation of both uterine arteries with hemoclips and electrocoagulation.<sup>53</sup>

Treatment outcome was rated as satisfactory by only 15% of patients, and 45% were dissatisfied.<sup>53</sup> Poor satisfaction in this preliminary study suggests that symptomatic adenomyosis may not be effectively treated by laparoscopic uterine artery ligation.

### 4.11.4 Which is the Best Treatment for Adenomyosis?

In 1977, *Owolabi and Strickler* stated that “*adenomyosis is the addendum to text book chapters on ectopic endometrium; it is the forgotten process and a neglected diagnosis*” attesting to the difficulties not only in understanding the etiopathogenesis, but also in establishing the diagnosis.<sup>40,41</sup> Currently, we must admit that the choice of the best and most effective treatment

for adenomyosis is strictly related to a correct patient assessment both in terms of symptoms and preoperative diagnosis.

The diagnosis of adenomyosis remains a challenging issue, but it cannot be emphasized enough that the diagnostic workup represents the key step to optimize future management. Establishing a correlation between clinical features, 2D and 3D-TVS features and MRI imaging may allow a correct evaluation, even if the recent findings related to disease epidemiology may address the wrong direction.<sup>43</sup>

The ongoing changes in women’s lives have a considerable impact on transformations in adenomyosis “features”, i.e., that later marriage age, age at first pregnancy and infertility incidence give reason to suggest that adenomyosis should no longer be considered a typical perimenopausal or menopausal disease.<sup>42</sup> The evaluation of findings related to the manifestation of adenomyosis in young and infertile women has been neglected for many years and lead to large proportion of patients with missed diagnosis, considering that histological assessment after hysterectomy has long been the gold standard in the diagnosis of the disease. Recent studies have demonstrated that the presence of specific ultrasound features of adenomyosis can be appreciated early in childbearing years and often can be associated with dysmenorrhea and metrorrhagia. Based on the results of these studies, the management of patients with adenomyosis should be revolutionized and the authors hold the opinion that development and implementation of conservative therapeutic strategies specifically adapted to the needs of young women is indispensable.<sup>46</sup>

The principles of best practice in the management of adenomyosis should be applied in an individualized manner considering that, to date, there is no a uniform standard to measure the efficacy of surgical treatment for adenomyosis. While from a clinical standpoint, the major goal of treatment is to induce relief from symptoms and improve fertility, from a surgical point of view, the excision of a maximum amount of adenomyotic tissue and preservation of uterine wall integrity is of primary interest. It goes without saying that these conflicting goals must be balanced against each other.

While hysterectomy for adenomyosis is based on well-defined and precise indications, it is equally important that due attention be given to the current armamentarium of conservative treatments from which particularly young and symptomatic patients can benefit most. Uterus-sparing techniques appear to have a similar potential in the treatment of dysmenorrhea, while the key points that enable control of abnormal uterine bleeding seem to be strictly related to the amount of excised tissue and to the destruction of endometrium. In terms of fertility outcomes, younger women can draw advantage from uterus-sparing surgery, even though there is still a risk that the chosen conservative procedure can alter the uterine anatomy and adversely affect the postoperative pregnancy rate. Nonetheless, this type of uterus-sparing surgery is a valid treatment option that should be considered in women with a prior history of failed IVF attempts.<sup>26</sup>



An additional interesting point lies in the controversial use of pre-operative GnRH analogues. Among the benefits that can be derived from preoperative treatment with GnRH-a are reduced fluid absorption (in case of endometrial ablation), reduced operative time and level of difficulty, resolution of preoperative anaemia and reduction of endometrial thickness. Conversely, the limitations of preoperative treatment with GnRH-a include side effects and high costs, increased rate of lesion recurrence and incomplete resection, increased risk of the 'sinking' phenomenon and risk of uterine perforation.

In conclusion, with the exception of radical surgery, uterus-sparing treatment for adenomyosis offers the chance of a consistent control of symptoms<sup>52</sup> and preservation of future fertility, even though this is frequently associated with the drawback of incomplete excision of lesions and the risk of recurrences. Moreover, the concurrent removal of healthy myometrium happens inevitably during excision of the lesion, so the procedure is still partly destructive for the uterine wall and the advantages of removing an affected area must be balanced against the disadvantages of leaving behind a possibly defective uterine wall, which is of particular relevance to the management of infertile patients. The recent introduction of non-excisional procedures may represent the future direction of adenomyosis management and the authors hold the opinion that upcoming studies will confirm their efficacy.<sup>56</sup>

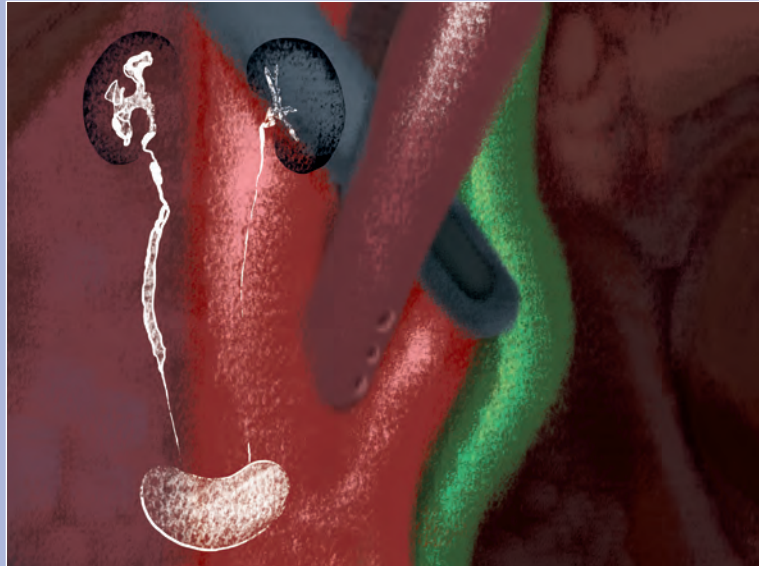
#### 4.11.5 References

1. BAZOT M, CORTEZ A, DARAI E, ROUGER J, CHOPIER J, ANTOINE JM et al. Ultrasonography compared with magnetic resonance imaging for the diagnosis of adenomyosis: correlation with histopathology. *Hum Reprod* 2001;16(11):2427–33.
2. BENAGIANO G, BROSENS I. History of adenomyosis. *Best Pract Res Clin Obstet Gynaecol* 2006;20(4):449–63. doi:10.1016/j.bpobgyn.2006.01.007.
3. BENAGIANO G, BROSENS I, CARRARA S. Adenomyosis: new knowledge is generating new treatment strategies. *Womens Health (Lond Engl)* 2009;5(3):297–311. doi:10.2217/whe.09.7.
4. BENAGIANO G, BROSENS I, HABIBA M. Structural and molecular features of the endomyometrium in endometriosis and adenomyosis. *Hum Reprod Update* 2014;20(3):386–402. doi:10.1093/humupd/dmt052.
5. BENAGIANO G, BROSENS I, HABIBA M. Adenomyosis: a life-cycle approach. *Reprod Biomed Online* 2015;30(3):220–32. doi:10.1016/j.rbmo.2014.11.005.
6. BERGHOLT T, ERIKSEN L, BERENDT N, JACOBSEN M, HERTZ JB. Prevalence and risk factors of adenomyosis at hysterectomy. *Hum Reprod* 2001;16(11):2418–21.
7. BIRD CC, MCELIN TW, MANALO-ESTRELLA P. The elusive adenomyosis of the uterus – revisited. *Am J Obstet Gynecol* 1972;112(5):583–93.
8. CAMPO S, CAMPO V, BENAGIANO G. Infertility and adenomyosis. *Obstet Gynecol Int* 2012;2012:786132. doi:10.1155/2012/786132.
9. DUEHOLM M, LUNDORF E. Transvaginal ultrasound or MRI for diagnosis of adenomyosis. *Curr Opin Obstet Gynecol* 2007;19(6):505–12. doi:10.1097/GCO.0b013e3282f1bf00.
10. DUEHOLM M, LUNDORF E, HANSEN ES, SORENSEN JS, LEDERTOUG S, OLESEN F. Magnetic resonance imaging and transvaginal ultrasonography for the diagnosis of adenomyosis. *Fertil Steril* 2001;76(3):588–94.
11. EXACOUSTOS C, BRIENZA L, DI GIOVANNI A, SZABOLCS B, ROMANINI ME, ZUPI E et al. Adenomyosis: three-dimensional sonographic findings of the junctional zone and correlation with histology. *Ultrasound Obstet Gynecol* 2011;37(4):471–9. doi:10.1002/uog.8900.
12. EXACOUSTOS C, MANGANARO L, ZUPI E. Imaging for the evaluation of endometriosis and adenomyosis. *Best Pract Res Clin Obstet Gynaecol* 2014;28(5):655–81. doi:10.1016/j.bpobgyn.2014.04.010.
13. FEDELE L, BIANCHI S, ZANOTTI F, MARCHINI M, CANDIANI GB. Fertility after conservative surgery for adenomyomas. *Hum Reprod* 1993;8(10):1708–10.
14. FERRARI F, ARRIGONI F, MICCOLI A, MASCARETTI S, FASCETTI E, MASCARETTI G et al. Effectiveness of Magnetic Resonance-guided Focused Ultrasound Surgery (MRgFUS) in the uterine adenomyosis treatment: technical approach and MRI evaluation. *Radiol Med* 2016;121(2):153–61. doi:10.1007/s11547-015-0580-7.
15. FINCO A, CENTINI G, LAZZERI L, ZUPI E. Surgical management of abnormal uterine bleeding in fertile age women. *Womens Health (Lond Engl)* 2015;11(4):513–25. doi:10.2217/whe.15.12.
16. FROELING V, SCHEURIG-MUENKLER C, HAMM B, KROENCKE T.J. Uterine artery embolization to treat uterine adenomyosis with or without uterine leiomyomata: results of symptom control and health-related quality of life 40 months after treatment. *Cardiovasc Intervent Radiol* 2012;35(3):523–9. doi:10.1007/s00270-011-0254-3.
17. FUJISHITA A, MASUZAKI H, KHAN KN, KITAJIMA M, ISHIMARU T. Modified reduction surgery for adenomyosis. A preliminary report of the transverse H incision technique. *Gynecol Obstet Invest* 2004;57(3):132–8. doi:10.1159/000075830.
18. GRIMBIZIS GF, MIKOS T, TARLATZIS B. Uterus-sparing operative treatment for adenomyosis. *Fertil Steril* 2014;101(2):472–87. doi:10.1016/j.fertnstert.2013.10.025.
19. GRIMBIZIS GF, MIKOS T, ZEPİRİDİS L, THEODORİDİS T, MILIARAS D, TARLATZIS BC et al. Laparoscopic excision of uterine adenomyomas. *Fertil Steril* 2008;89(4):953–61. doi:10.1016/j.fertnstert.2007.04.063.
20. HORNG HC, CHEN CH, CHEN CY, TSUI KH, LIU WM, WANG PH et al. Uterine-sparing surgery for adenomyosis and/or adenomyoma. *Taiwan J Obstet Gynecol* 2014;53(1):3–7. doi:10.1016/j.tjog.2014.01.001.
21. HUANG X, HUANG Q, CHEN S, ZHANG J, LIN K, ZHANG X. Efficacy of laparoscopic adenomyomectomy using double-flap method for diffuse uterine adenomyosis. *BMC Womens Health* 2015;15:24. doi:10.1186/s12905-015-0182-5.
22. HYAMS LL. Adenomyosis; its conservative surgical treatment (hysteroplasty) in young women. *N Y State J Med* 1952;52(22):2778–84.
23. KEPKEP K, TUNCAY YA, GOYNUMER G, TUTAL E. Transvaginal sonography in the diagnosis of adenomyosis: which findings are most accurate? *Ultrasound Obstet Gynecol* 2007;30(3):341–5. doi:10.1002/uog.3985.
24. KIM JK, SHIN CS, KO YB, NAM SY, YIM HS, LEE KH. Laparoscopic assisted adenomyomectomy using double flap method. *Obstet Gynecol Sci* 2014;57(2):128–35. doi:10.5468/ogs.2014.57.2.128.

25. KIM MD, KIM S, KIM NK, LEE MH, AHN EH, KIM HJ et al. Long-term results of uterine artery embolization for symptomatic adenomyosis. *AJR Am J Roentgenol* 2007;188(1):176–81. doi:10.2214/AJR.05.1613.
26. KISHI Y, YABUTA M, TANIGUCHI F. Who will benefit from uterus-sparing surgery in adenomyosis-associated subfertility? *Fertil Steril* 2014;102(3):802–807.e1. doi:10.1016/j.fertnstert.2014.05.028.
27. KUNZ G, HERBERTZ M, BEIL D, HUPPERT P, LEYENDECKER G. Adenomyosis as a disorder of the early and late human reproductive period. *Reprod Biomed Online* 2007;15(6):681–5.
28. KWON YS, ROH HJ, AHN JW, LEE SH, IM KS. Conservative adenomyomectomy with transient occlusion of uterine arteries for diffuse uterine adenomyosis. *J Obstet Gynaecol Res* 2015;41(6):938–45. doi:10.1111/jog.12649.
29. LAZZERI L, DI GIOVANNI A, EXACOUSTOS C, TOSTI C, PINZAUTI S, MALZONI M et al. Preoperative and Postoperative Clinical and Transvaginal Ultrasound Findings of Adenomyosis in Patients With Deep Infiltrating Endometriosis. *Reprod Sci* 2014;21(8):1027–33. doi:10.1177/1933719114522520.
30. LEVGUR M. Therapeutic options for adenomyosis: a review. *Arch Gynecol Obstet* 2007;276(1):1–15. doi:10.1007/s00404-006-0299-8.
31. LEVY G, DEHAENE A, LAURENT N, LERNOUT M, COLLINET P, LUCOT JP et al. An update on adenomyosis. *Diagn Interv Imaging* 2013;94(1):3–25. doi:10.1016/j.diii.2012.10.012.
32. MATALLIOTAKIS IM, KATSIKIS IK, PANIDIS DK. Adenomyosis: what is the impact on fertility? *Curr Opin Obstet Gynecol* 2005;17(3):261–4.
33. MCCAUSLAND AM, MCCAUSLAND VM. Depth of endometrial penetration in adenomyosis helps determine outcome of rollerball ablation. *Am J Obstet Gynecol* 1996;174(6):1786–93; 1793–4.
34. MUNRO MG, CRITCHLEY HO, BRODER MS, FRASER IS. FIGO classification system (PALM–COEIN) for causes of abnormal uterine bleeding in nongravid women of reproductive age. *Int J Gynaecol Obstet* 2011;113(1):3–13. doi:10.1016/j.ijgo.2010.11.011.
35. NAFTALIN J, HOO W, PATEMAN K, MAVRELOS D, FOO X, JURKOVIC D. Is adenomyosis associated with menorrhagia? *Hum Reprod* 2014;29(3):473–9. doi:10.1093/humrep/det451.
36. NAKAMURA K, NAKAYAMA K, ISHIKAWA M, KATAGIRI H, KATAGIRI A, ISHIBASHI T et al. Efficacy of multiple microwave endometrial ablation technique for menorrhagia resulting from adenomyosis. *J Obstet Gynaecol Res* 2015;41(11):1769–72. doi:10.1111/jog.12787.
37. NISHIDA M. Relationship between the onset of dysmenorrhea and histologic findings in adenomyosis. *Am J Obstet Gynecol* 1991;165(1):229–31.
38. NISHIDA M, TAKANO K, ARAI Y, OZONE H, ICHIKAWA R. Conservative surgical management for diffuse uterine adenomyosis. *Fertil Steril* 2010;94(2):715–9. doi:10.1016/j.fertnstert.2009.03.046.
39. OSADA H, SILBER S, KAKINUMA T, NAGAISHI M, KATO K, KATO O. Surgical procedure to conserve the uterus for future pregnancy in patients suffering from massive adenomyosis. *Reprod Biomed Online* 2011;22(1):94–9. doi:10.1016/j.rbmo.2010.09.014.
40. OTSUBO Y, NISHIDA M, ARAI Y, ICHIKAWA R, TANEICHI A, SAKANAKA M. Association of uterine wall thickness with pregnancy outcome following uterine-sparing surgery for diffuse uterine adenomyosis. *Aust N Z J Obstet Gynaecol* 2016;56(1):88–91. doi:10.1111/ajo.12419.
41. OWOLABI TO, STRICKLER RC. Adenomyosis: a neglected diagnosis. *Obstet Gynecol* 1977;50(4):424–7.
42. PINZAUTI S, LAZZERI L, TOSTI C, CENTINI G, ORLANDINI C, LUISI S et al. Transvaginal sonographic features of diffuse adenomyosis in 18–30-year-old nulligravid women without endometriosis: Association with symptoms. *Ultrasound Obstet Gynecol* 2015;46(6):730–6. doi:10.1002/uog.14834.
43. PINZAUTI S, LAZZERI L, TOSTI C, CENTINI G, PINO I, PETRAGLIA F et al. 2D and 3D Ultrasound Evaluation of Adenomyosis in Endometriosis: Pain Assessment before and after Surgery. Florence, Italy, March 28, 2014, Society for Gynecologic Investigation (SGI).
44. PREUTTHIPAN S, HERABUTYA Y. Hysteroscopic rollerball endometrial ablation as an alternative treatment for adenomyosis with menorrhagia and/or dysmenorrhea. *J Obstet Gynaecol Res* 2010;36(5):1031–6. doi:10.1111/j.1447-0756.2010.01251.x.
45. RABINOVICI J, INBAR Y, EYLON SC, SCHIFF E, HANANEL A, FREUNDLICH D. Pregnancy and live birth after focused ultrasound surgery for symptomatic focal adenomyosis: a case report. *Hum Reprod* 2006;21(5):1255–9. doi:10.1093/humrep/dei458.
46. REINHOLD C, MCCARTHY S, BRET PM, MEHIO A, ATRI M, ZAKARIAN R et al. Diffuse adenomyosis: comparison of endovaginal US and MR imaging with histopathologic correlation. *Radiology* 1996;199(1):151–8. doi:10.1148/radiology.199.1.8633139.
47. SAREMI A, BAHRAMI H, SALEHIAN P, HAKAK N, POOLADI A. Treatment of adenomyomectomy in women with severe uterine adenomyosis using a novel technique. *Reprod Biomed Online* 2014;28(6):753–60. doi:10.1016/j.rbmo.2014.02.008.
48. SISKIN GP, ENGLANDER M, STAINKEN BF, AHN J, DOWLING K, DOLEN EG. Embolic agents used for uterine fibroid embolization. *AJR Am J Roentgenol* 2000;175(3):767–73. doi:10.2214/ajr.175.3.1750767.
49. SMEETS AJ, NIJENHUIS RJ, BOEKKOOI PF, VERVEST HA, VAN ROOIJ WJ, LOHLE PN. Long-term follow-up of uterine artery embolization for symptomatic adenomyosis. *Cardiovasc Intervent Radiol* 2012;35(4):815–9. doi:10.1007/s00270-011-0203-1.
50. SUN AJ, LUO M, WANG W, CHEN R, LANG JH. Characteristics and efficacy of modified adenomyomectomy in the treatment of uterine adenomyoma. *Chin Med J (Engl)* 2011;124(9):1322–6.
51. TAKEUCHI H, KITADE M, KIKUCHI I, SHIMANUKI H, KUMAKIRI J, KITANO T et al. Laparoscopic adenomyomectomy and hysteroplasty: a novel method. *J Minim Invasive Gynecol* 2006;13(2):150–4. doi:10.1016/j.jmig.2005.12.004.
52. TOSTI C, ZUPI E, EXACOUSTOS C. Could the uterine junctional zone be used to identify early-stage endometriosis in women? *Womens Health (Lond Engl)* 2014;10(3):225–7. doi:10.2217/whe.14.20.
53. WANG CJ, YEN CF, LEE CL, SOONG YK. Laparoscopic uterine artery ligation for treatment of symptomatic adenomyosis. *J Am Assoc Gynecol Laparosc* 2002;9(3):293–6.
54. WOOD C. Surgical and medical treatment of adenomyosis. *Hum Reprod Update* 1998;4(4):323–36.
55. YANG Z, CAO YD, HU LN, WANG ZB. Feasibility of laparoscopic high-intensity focused ultrasound treatment for patients with uterine localized adenomyosis. *Fertil Steril* 2009;91(6):2338–43. doi:10.1016/j.fertnstert.2008.03.017.
56. ZUPI E, CENTINI G, LAZZERI L, FINCO A, EXACOUSTOS C, AFORS K et al. Hysteroscopic Endometrial Resection Versus Laparoscopic Supracervical Hysterectomy for Abnormal Uterine Bleeding: Long-term Follow-up of a Randomized Trial. *J Minim Invasive Gynecol* 2015;22(5):841–5. doi:10.1016/j.jmig.2015.04.004.

# 5 Urological Approaches

---



5.1	Diagnosis and Management of Urinary Tract Endometriosis .....	382
5.2	Diagnosis of Urinary Tract Endometriosis, Counseling and Therapeutic Management .....	395
5.3	Ureteral Endometriosis .....	399
5.4	Bladder Endometriosis .....	409
5.5	Surgical Treatment of Bladder Endometriosis .....	415



Alireza Aminsharifi<sup>a</sup> | Amir Farokhi<sup>b</sup>

### 5.1.1 Introduction

Endometriosis is defined as the presence of endometrial glandular and stromal tissue outside the uterus. Although endometriosis is usually confined to the ovaries, uterosacral ligaments and cul-de-sac, it can occur almost anywhere in the body.<sup>55</sup>

Endometriotic lesions of the urinary tract are present in 1–5% of women with endometriosis.<sup>7</sup> Urinary tract endometriosis most commonly affects the bladder (80%) and less frequently the ureter (14%) and kidneys (4%).<sup>34</sup> Although ureteral and bladder endometriosis both occur in the urinary tract, they do not often coexist and they differ in their clinical presentation and management. Bladder endometriosis causes urinary discomfort that often mimics recurrent cystitis but rarely results in significant complications. Ureteral endometriosis is often asymptomatic but may lead to a silent loss of renal function. Very rare cases of renal and urethral involvement have been reported.

Three theories have been advanced on the pathogenesis of endometriosis. They involve the spread of endometrial cells via retrograde menstruation, lymphatic or hematogenous dissemination, and coelomic metaplasia. Some experts have suggested that vesical endometriosis represents bladder adenomyosis or may be an extension of adenomyosis from the uterus due to the anatomic proximity of the bladder and uterus or imperfect closure of the uterus during a cesarean delivery.<sup>16,38,42,79,118</sup>

Deep endometriosis is defined as a solid mass situated deeper than 5 mm below the peritoneum. According to the theory of retrograde menstruation, deep endometriosis results from the implantation of cells in the most dependent areas of the pelvis, such as spaces anterior and posterior to the uterus. These spaces serve as anatomic shelters that harbor endometrial cells and prevent them from being cleared by the usual processes within the peritoneal cavity. The presence of endometrial cells incites an inflammatory response and, eventually, a fibrotic nodule is formed and buried beneath the peritoneum.

<sup>a</sup> | MD, Associate Professor of Urology, Department of Urology; Laparoscopy Research Center, Shiraz University of Medical Sciences, Shiraz, Iran

<sup>b</sup> | MD, Fellowship in Endourology and Urolaparoscopy; Department of Urology, Laparoscopy Research Center, Shiraz University of Medical Sciences, Shiraz, Iran

#### Corresponding author:

**Alireza Aminsharifi**

MD, Associate Professor of Urology;  
Department of Urology, Laparoscopy Research Center,  
Shiraz University of Medical Sciences, Shiraz, Iran  
E-mail: aminsharifi\_ar@yahoo.com

The diagnosis and management of bladder and ureteral endometriosis are reviewed in this chapter.

### 5.1.2 Bladder Endometriosis

The urinary bladder is the most commonly affected site in urinary tract endometriosis. In most cases this condition is diagnosed when patients complain of urinary symptoms during gynecologic follow-up procedures for deep pelvic endometriosis. Deep infiltrating pelvic endometriosis is defined as the implantation of endometrial stromal and glandular epithelium outside the endometrial cavity and the uterine musculature, penetrating into the retroperitoneal space or into the wall of pelvic organs to a depth of at least 5 mm. Deep infiltrating endometriosis may involve the torus uteri, posterior fornix, uterosacral ligaments, vagina, rectum, and urinary tract.

More cases of urinary tract endometriosis have been diagnosed in recent years.<sup>54</sup> According to the literature, urinary tract involvement is present in 0.3–12% of all women affected by endometriosis.<sup>37,44,50,92</sup> Collaboration between the gynecologist and urologist is necessary in order to determine the correct diagnostic procedure and the most appropriate treatment.

#### 5.1.2.1 Epidemiology

The bladder is the most commonly affected site within the urinary tract. Bladder endometriosis was first described by *Judd* in 1921.<sup>56</sup> In 36% of cases the endometriosis is confined to the bladder. A detrusor nodule per se does not represent a risk factor for additional urologic lesions. Different sites of urinary tract endometriosis may coexist, however.<sup>30,72,82</sup>

Bladder endometriosis predominantly affects women of reproductive age, with an average patient age of 35 years.<sup>30</sup> Postmenopausal occurrence is extremely rare because endometriotic tissue is dependent upon estrogen for continued growth and generally regresses after menopause.<sup>69</sup>

Two distinct forms of bladder endometriosis – primary and secondary – are described in the literature.

Primary bladder endometriosis occurs spontaneously and is found in 11% of all patients diagnosed with endometriosis. Secondary bladder endometriosis is defined as an iatrogenic lesion that occurs after pelvic surgery such as cesarean delivery or hysterectomy.<sup>23,62,96,107</sup> Approximately 50% of patients with bladder endometriosis have a prior history of pelvic surgery.<sup>30</sup>

The lesions of bladder endometriosis most commonly affect the detrusor muscle in the bladder trigone. Lesions typically spread from the serosal surface of the bladder toward the mucosa.<sup>23,62,96,107</sup>

### 5.1.2.2 Pathogenesis

The pathogenesis of urinary tract endometriosis is not yet fully understood, and a unifying theory on the origin of endometriosis remains elusive. The etiologic hypotheses proposed to date include the embryonic theory, migration theory, transplantation theory, and iatrogenic theory.

#### ■ Embryonic Theory

Bladder endometriosis may originate from müllerian remnants located predominantly in the vesicouterine and vesicovaginal septa.<sup>35,126</sup> *Donnez et al.* were the first to propose this theory<sup>35</sup>, but some authors have questioned the histologic evidence of müllerian remnants in the urothelium of the bladder.<sup>126</sup>

#### ■ Migration (Reflux) Theory

This most widely accepted theory was initially proposed by *Sampson* in the 1920s<sup>96</sup> and was then supported by the findings of *Vercellini et al.*<sup>96,116</sup> It claims that menstrual blood regurgitates into the pelvis through the fallopian tubes in a retrograde manner, delivering cells that implant on the bladder wall and urinary system. Indeed, the bladder constitutes a privileged target for the implantation of regurgitated endometrial cells because it is located in the anterior cul-de-sac, a dependent portion of the peritoneal cavity. After implantation, regurgitated endometrial cells sandwiched between the bladder dome and anterior uterine wall incite an inflammatory process in the peritoneum, leading to adhesion of the two organs.<sup>116,118</sup> Detrusor nodules are almost invariably found adherent to the uterine body; they are seldom detected cranial to the vesicovaginal and vesicocervical septa.<sup>34,35,72,118</sup>

#### ■ Transplantation Theory

This theory holds that ectopic endometrial implants result from the lymphatic or hematogenous dissemination of endometrial cells. Microvascular studies have detected lymph flow from the uterine body into the ovary, indicating a possible role of the lymphatic system in the etiology of endometriosis.<sup>18,55,96</sup> This theory postulates that bladder endometriosis should be defined as adenomyosis arising from the spread of adenomyotic lesions by lymphogenous or hematogenous embolization, or by direct extension through the uterine wall.<sup>23,35,73</sup> Nevertheless, imaging and surgical findings have shown that, in the vast majority of cases, bladder endometriosis originates intraperitoneally in the vesicouterine pouch and that its association with uterine adenomyosis is not frequent.<sup>34,72,73</sup>

#### ■ Iatrogenic Theory

This theory attributes urinary tract endometriosis to the iatrogenic spread of endometrial cells during surgery. In this case the vesical nodule is not seen as the manifestation of a more generalized disease but as an isolated lesion caused by intraoperative dissemination of endometrial cells or an imperfect surgical technique for closure of the low transverse uterine incision.<sup>26,27,33,36,81,84,90,102</sup>

### 5.1.2.3 Symptoms

The symptoms caused by bladder endometriosis are variable and depend on the location and size of the lesion.<sup>35,39,78,121</sup>

In one-third of patients with bladder endometriosis, the lesions are asymptomatic and are detected incidentally during follow-up for known endometriosis or for infertility.

In most of these asymptomatic cases, the diameter of the bladder lesions does not exceed 1–2 cm. Nevertheless, 70% of women with bladder endometriosis present with urinary symptoms at the time of diagnosis.

The most common symptoms of bladder endometriosis are listed in [Table 5.1](#). Interestingly, 40% of patients affected by bladder endometriosis have reported these symptoms occurring in a cyclical pattern, with symptoms being strongest during the premenstrual period.<sup>1,2,64,72,124</sup> The differential diagnosis should include chronic bladder inflammation, interstitial cystitis, acute or chronic urethral syndrome, overactive bladder and, most importantly, bladder malignancy.<sup>14,21,45,87,106</sup> Moreover, endometriosis has the potential for malignant transformation.<sup>53,113</sup> Malignant transformation of endometriosis is quite rare, with only 9 cases reported in the Anglo-American literature to date. Malignant transformation of infiltrative bladder endometriosis in the form of endometrioid adenocarcinoma or adenocarcinoma is extremely rare.<sup>4,114</sup>

### 5.1.2.4 Diagnosis

#### ■ Physical Examination

Bimanual physical examination is considered positive and suggestive of endometriotic infiltration of the pelvis when a palpable nodule, thickened area, or palpable cystic expansion is found at the level of uterosacral ligaments, vagina, rectovaginal space, cul-de-sac, rectosigmoid, or posterior bladder wall. Moreover, the presence of lesions in these areas could suggest involvement of the ureter(s), with associated evidence of hydronephrosis or impaired renal function.<sup>66,94</sup>

#### ■ Laboratory Data

Extensive bladder endometriosis may be associated with significant anemia, and therefore all patients should be assessed for anemia. Renal function is also commonly impaired in these patients and should be tested by serum creatinine assay. The urine should be evaluated for gross or microscopic hematuria and cultured to exclude an infectious etiology for irritative voiding symptoms. Urine culture is usually negative. Urine cytology is also necessary to exclude in situ bladder carcinoma as a possible cause of irritative urinary symptoms.<sup>121,124</sup>

Common Symptoms of Bladder Endometriosis <sup>39,78,121,124</sup>	
Acute urethral syndrome (40%)	<ul style="list-style-type: none"> <li>■ Frequency</li> <li>■ Dysuria</li> <li>■ Suprapubic pain or discomfort</li> </ul>
Hematuria (20–35%)	
Menuria <sup>1</sup> (20–25%)	

**Table 5.1** Common symptoms of bladder endometriosis in symptomatic patients.

<sup>1</sup> Hematuria synchronous with menstruation.

### ■ Ultrasound

Ultrasound is the initial imaging study for diagnosing bladder endometriosis owing to its low cost, high availability, and lack of radiation exposure. A combination of abdominal, transvaginal and transrectal scans, depending on the complaints, may reveal endometriosis at infrequent sites, including the bladder.<sup>9,12,22,49,61,67</sup>

Transvaginal scanning is performed with a 5- to 9-MHz probe to image the bladder, adnexa, uterus, vagina, rectovaginal space, uterosacral ligaments, and rectosigmoid pouch. The probe is first introduced into the posterior vaginal fornix and is slowly retracted to evaluate the cul-de-sac, uterosacral ligaments, bladder, and vagina and to ensure adequate visualization of all these structures.<sup>22,49,67</sup>

Endometrial lesions may appear as heterogeneous, hyperechoic, intraluminal, usually spherical or comma-shaped vegetations with regular margins which protrude from the posterior wall or dome of the bladder. These nodules show only scant vascularity in power Doppler scans.<sup>22,49,67</sup>

A moderate amount of urine in the bladder creates a clear acoustic window that facilitates the detection of nodules along the bladder wall, but excessive bladder distention will push the dome away from the tip of the vaginal probe, and this can make it more difficult to detect a nodule in the bladder roof. Visualization of a distinct plane between the detrusor nodule and anterior uterine wall is sufficient to exclude the presence of a leiomyoma.<sup>22,49,67,71,95</sup>

In a study by *Thonnon et al.* (2015) comparing three-dimensional color Doppler ultrasound with MRI and cystoscopy in the diagnosis of bladder endometriosis, the authors found that ultrasound was superior to cystoscopy and equivalent to MRI for in the diagnosis of bladder endometriosis.<sup>115</sup>

### ■ Pelvic Magnetic Resonance Imaging (MRI)

Pelvic MRI has a sensitivity up to 88% and specificity up to 99% for the diagnosis of bladder endometriosis. Its diagnostic accuracy is approximately 98%. These considerations justify the use of MRI as a complementary modality in complex cases of endometriosis with extensive adhesions and as a gold-standard modality for the diagnosis of bladder endometriosis.<sup>9,22,71,95</sup>

In clinical practice, a conventional MRI protocol for evaluating pelvic endometriosis includes sagittal and axial T2- and T1-weighted images before and after fat suppression. Bladder endometriomas are characterized by high signal intensity on T1-weighted images and low signal intensity on T2-weighted images. Coronal sequences are of particular interest as they allow an accurate investigation of associated lesions in the pelvis, which have been documented in 50–70% of cases. Pelvic MRI performed with a 3-Tesla system ensures high spatial and contrast resolution, providing accurate information on endometriotic implants with good preoperative mapping of lesions involving both rectal and bladder surfaces and the rectouterine ligament.<sup>9,11,19,22,49,67</sup>

### ■ Cystoscopy

Cystoscopy still represents one of the most cost-effective tests. Findings may be normal due to the intraperitoneal origin of the lesions, but cystoscopy may demonstrate an intraluminal mass on the posterior bladder wall or dome.

The morphologic characteristics of endometriotic bladder lesions may change with the phases of menstrual cycle, showing the most distinct alterations before and during menstruation. Endometriotic nodules are larger and more congested during menses, and their cystoscopic visualization is optimal at that time. Small lesions affecting only the bladder adventitia may not be visualized by cystoscopy.

Bladder lesions often appear as an irregular, adenomatous nodular mass of variable shape and color. They are most commonly described as bluish-red, bluish-black, or bluish-brown in color. The urothelium is not ulcerated in most cases. The lesions may be solitary or multifocal, approximately 1–3 cm in diameter, and usually located on the dome or at the base. At cystoscopy, it is necessary to determine the distance between the endometrial lesions and ureteral orifices in order to determine the optimal surgical approach. In patients with no prior history of surgical treatment, the distance between the inferior border of the endometriotic lesion and the interureteric ridge is rarely < 2 cm.<sup>30,69,72,94,104,124</sup>

Histopathologic evaluation of tissue specimens obtained by laparoscopic biopsy is critical for excluding bladder carcinoma, varices, papillomas, angiomas, and detrusor mesenchymal tumors. While transurethral resection of the lesions will yield adequate specimens, cystoscopically guided biopsy is not always diagnostic for endometriosis. In rare cases where the inferior border of the endometriotic lesion is < 2 cm from the interureteric ridge, a ureteroneocystostomy may be required, and the surgical procedure should be planned accordingly. Close proximity of the endometriotic nodule to the bladder trigone is more common in patients who have undergone prior transurethral resectoscopic surgery.<sup>67,72</sup>

### ■ Differential Diagnosis

When the bladder mass or lesion has been documented by noninvasive imaging or cystoscopy, the differential diagnosis should include bladder carcinoma, angioma, leiomyoma, amyloidosis, malakoplakia, glandular cystitis, nephrogenic adenoma, and extravesical processes such as diverticulitis. Histologic evaluation is necessary in almost all cases.<sup>67</sup>

#### 5.1.2.5 Treatment

The treatment of urinary tract endometriosis is controversial because the rarity of this condition almost makes randomized studies unfeasible. Specifically, the treatment of bladder endometriosis may depend on several factors such as patient age, fertility preference, extent of disease, severity of lower urinary tract symptoms, coexisting pelvic lesions, and degree of menstrual dysfunction.<sup>30,72</sup> Treatment may be medical, surgical, or a combination of both.



### ■ Medical Treatment

The aim of most medical or hormonal therapy is to induce regression of the endometrial tissue. Medical treatments have focused on hormonal alterations of the menstrual cycle in an attempt to induce pseudopregnancy, pseudomenopause, or a chronic anovulatory condition. Each of these states is believed to create a less-than-optimum milieu for the growth and maintenance of endometrial tissue.<sup>60,124</sup>

The most common agents used in the treatment of endometriosis include gonadotropin-releasing hormone (GnRH) agonists (leuprolide acetate) and antagonists (danazol), progestins (Dienogest), and combined oral contraceptives. Hormone therapy can induce temporary regression of endometriosis and is often selected as the initial treatment for younger women and those desiring to preserve their fertility.<sup>30</sup>

#### GnRH Agonists

GnRH agonists such as leuprolide acetate induce a state of hypogonadotropic hypogonadism, with a consequent decline in serum estrogens to castration levels. This causes anovulation and endometrial tissue regression. Possible side effects include hot flashes, diaphoresis, sleep disturbance, vaginal dryness, headache, mood changes, osteopenia, loss of libido, and weight gain.<sup>70,74,85,88,89,110,125</sup>

#### GnRH Antagonists

GnRH antagonists such as danazol reduce the production of FSH and LH, thereby inducing an anovulatory state. Possible side effects are weight gain, edema, skin rash, nausea, diaphoresis, irritability, hot flashes, hirsutism, acne, and oily skin.<sup>85,100,125</sup>

#### Progestins

Progestins (i.e. medroxyprogesterone acetate, Dienogest) induce suppression of ovarian activity and transformation of the endometrium after its previous exposure to estrogens. Their principal side effect is abnormal menstrual bleeding.<sup>5,13,15,31,52,97,98,109–111</sup>

#### Combined Oral Contraceptives

As a “pseudopregnancy regimen,” the goal of this treatment is the suppression of menses leading to therapeutic amenorrhea. Breakthrough bleeding, nausea, headache, increased risk of venous thromboembolism, loss of libido, sodium and fluid retention are some possible side effects.<sup>51,112,117,127</sup>

Though all these drugs ease the severity of pelvic pain, dysmenorrhea and dyspareunia, the symptoms often recur when therapy is discontinued. Moreover, they are frequently associated with safety and tolerance issues, and they always postpone childbearing without improving fertility.<sup>67</sup>

Unfortunately, almost 50% of patients with deep infiltrating endometriosis (DIE) do not respond to hormonal therapy. The relapse rate is quite high (approximately 56%), indicating that such treatment induces only a temporary resolution of lesions in patients with deep endometriosis and bladder endometriosis.

The ideal candidate for this type of treatment is a menopausal woman with a single, small (< 5 mm) endometrial nodule in the bladder.<sup>61</sup>

Indeed, medical management appears to have a high recurrence rate after treatment withdrawal and is often considered a palliative modality for bladder endometriosis. Additionally, some authors have noted that bladder pain and a desmoplastic reaction within the detrusor from repetitive bleeding and absorption of menstrual debris may respond poorly to hormonal manipulation.<sup>67</sup>

The potential of endometriotic cells to migrate, metastasize, invade, and induce angiogenesis resembles that of malignant cells. With this in mind, researchers have been investigating various anticancer drugs in the management of urinary tract endometriosis.<sup>17</sup> Recently a combination of aromatase inhibitors with progestins or GnRH agonists has proven effective, but because of its high complication rates and costs, this regimen has not yet been implemented in routine clinical practice.

### ■ Surgical Treatment

Surgery is the only treatment that offers the chance for a cure. Complete excision results in significant reduction of pain and improvement in quality of life.<sup>67</sup> The surgical options for bladder endometriosis include transurethral resection (TUR), open or laparoscopic partial cystectomy, and a combination of TUR and laparoscopic partial cystectomy. An accurate preoperative diagnostic workup is essential for planning the best surgical approach.

Apart from that, it is crucial to rule out neoplastic lesions of the bladder, determine the precise location of the bladder nodule relative to the ureteral orifices, and evaluate the status of the ureters and upper tract. These tests are geared toward defining an individualized surgical strategy, which is key to achieving the complete removal of symptomatic endometriotic lesions. The recurrence of an endometrial bladder nodule is closely linked to the efficacy of the surgical procedure in terms of a complete resection or excision of the mass.<sup>24,63,77,91,103</sup>

Patient age has been identified as a major risk factor for treatment failure. The younger the patient, the greater the risk of recurrence. This may be related to the fact that surgeons establishing a treatment plan for a woman in the younger age group, are generally more hesitant to opt for a radical treatment such as partial cystectomy.<sup>41</sup>

#### Transurethral Resection (TUR)

During TUR, the bladder lesion should be resected as deep as possible (preferably to a depth of 0.5–1 cm) in order to minimize the risk of recurrence. Due caution should be exercised at all times, however, because an extensive resection may be complicated by bladder perforation.<sup>67</sup>

The combination of laparoscopic procedures like TUR with hormone therapy is a suitable option in young patients wanting to preserve fertility. However, the failure rate may be as high as 25–35%.<sup>61</sup> The ideal candidates are fertile patients and women approaching menopause, because the lesions usually regress spontaneously with the onset of menopause.<sup>69</sup>

### Partial Cystectomy

Partial cystectomy is a bladder-preserving treatment option that involves the localized, full-thickness surgical excision of endometriotic bladder lesions. Generally speaking, a segmental bladder resection for detrusor endometriosis is a relatively simple and safe procedure. Several reports have documented excellent outcomes with this approach in terms of symptom relief and recurrence rate, regardless of whether the procedure employs open or laparoscopic technique. Concurrent cystoscopy can be useful for precisely delineating the margins of the endometrial lesion. Cystoscopic catheterization of the ureters before the procedure is an option that may be considered, especially in cases where the caudal border of the endometriotic lesion is less than 2 cm from the interureteric ridge.<sup>36,77,91,103</sup>

### Open Partial Cystectomy

The procedure begins with careful delineation of the nodule boundaries and the dissection of any adhesions between the anterior uterine wall and vesicouterine pouch. Since the removal of a detrusor nodule is not feasible without opening the bladder lumen, an intentional perinodular incision through the bladder dome is recommended. The most favorable anatomic situation is an endometriotic lesion in the bladder dome. A lesion on the posterior bladder wall is more complex; in this case a segmental bladder resection can be performed by the lysis of adhesions that have formed between the anterior uterine wall and the vesicouterine peritoneal fold. Very often, one or both round ligaments are distorted and involved in the fibrotic process. After excision of the lesion, the bladder is closed with absorbable sutures placed in two layers.<sup>30,72</sup>

### Laparoscopic Partial Cystectomy

The laparoscopic approach includes a dissection of the vesicouterine space in order to mobilize the nodule and dissect the bladder, enabling the whole nodule to be excised with adequate clear margins. The bladder is then closed in a single layer. Cystoscopy at the end of the procedure is advisable to ensure a watertight closure and check the integrity of the ureteral orifices. The outcome of partial cystectomy is excellent in most series, with pain relief reported in 95–100% of patients. Laparoscopy also permits the simultaneous treatment of extravesical lesions and concomitant oophorectomy with or without hysterectomy (preferred in patients who do not desire pregnancy and in women approaching menopause). Finally, laparoscopic partial cystectomy can yield the same results as open surgery while offering several advantages such as less bleeding, a shorter operating time, shorter hospital stay, earlier return to work, greatly reduced postoperative pain, and decreased risk of postoperative morbidity.<sup>24,28,63,77,91,103,120</sup>

Combining transurethral partial cystectomy with laparoscopic bladder reconstruction for the treatment of bladder endometriosis and coexisting abdominal endometriosis fits the trend toward minimally invasive surgery and could provide an alternative to traditional laparotomy in women with bladder endometriosis, especially those who have simultaneous pelvic endometriosis.

This approach requires the combined services of a gynecologist and urologist or an experienced laparoscopic surgeon.<sup>80,101</sup>

### Robotic Approach

Compared with standard laparoscopy, robotic-assisted laparoscopy has the advantage of an improved freedom of instrument manipulations that may allow a more precise suturing technique. However, the longer setup time and higher costs limit its use to a few reference centers. *Nezhat et al.* reported their experience with robotic-assisted laparoscopy in the treatment of one patient with bladder endometriosis and two patients with ureteral endometriosis. They demonstrated the safety and feasibility of this approach in patients with urinary tract endometriosis.<sup>76</sup>

## 5.1.3 Ureteral Endometriosis

The ureter is the second most common site of involvement by urinary tract endometriosis. The incidence of ureteral endometriosis has been rising in the contemporary literature owing to improvements in diagnostic tools and a greater awareness and skill among clinicians in recognizing the disease.

The distal part of ureter is the most commonly affected site, while very rare cases of proximal ureteral involvement have been reported. Bilateral ureteral endometriosis is also rare, occurring in 10–20% of patients.<sup>23,30,36,48,57,126</sup>

In most cases this condition is asymptomatic and is diagnosed incidentally during gynecologic follow-up. However, the delayed diagnosis and treatment of ureteral endometriosis may lead to a silent loss of renal function. Nowadays the modalities for diagnosis and treatment are a matter of debate, and there is growing evidence of the need for close collaboration between the gynecologist and urologist.

### 5.1.3.1 Epidemiology

*Cullen* was the first to report a case of ureteral endometriosis in 1917.<sup>32</sup> Since then, more than 200 cases have been described in the literature. Subclinical disease is probably underestimated as it is easily missed even on surgical inspection, so its true prevalence is higher than previously assumed.<sup>25</sup> Ureteral endometriosis has been reported more frequently in the contemporary literature, reflecting the greater ability of clinicians to recognize the disease and the significant improvement in imaging and other diagnostic tools.<sup>68</sup>

Ureteral endometriosis occurs in 0.1–1% of all endometriosis patients, with a peak incidence at 30–35 years of age.<sup>30,70,74,85,126</sup> Ureteral endometriosis has been described rarely in postmenopausal women.<sup>126</sup>

### 5.1.3.2 Pathogenesis

Ureteral involvement may be either intrinsic or extrinsic. Intrinsic endometriosis is characterized by endometrial glands and stroma within the lamina propria, tunica muscularis, or ureteral lumen. Extrinsic endometriosis is localized within the periureteral tissue. Eighty percent of ureteral endometriosis is extrinsic and primarily involves the distal ureter. The left side

is more commonly affected, and bilateral disease has been reported in up to 23 % of cases.<sup>6,86</sup>

One theory attributes ureteral involvement to retrograde menstruation and the implantation of refluxed endometrial cells. This is believed to be more frequent on the left side due to relationships with the sigmoid colon and ipsilateral ovary and anatomic differences between the right and left sides of the pelvis.<sup>119</sup>

The extrinsic and intrinsic forms of ureteral involvement are difficult to distinguish. The depth of invasion in the extrinsic form must ultimately rely on histologic examination, so differentiation cannot be reliably established preoperatively or at surgery.

In extrinsic disease the endometrial tissue invades only the ureteral adventitia or surrounding connective tissue, eventually causing ureteral obstruction. This is the most common form of ureteral endometriosis and represents 80 % of cases.<sup>30,103,126</sup>

In intrinsic disease (20 % of cases), ectopic endometrial tissue directly infiltrates the ureteral wall within the muscularis propria, lamina propria, or ureteral lumen. It most likely arises from lymphatic or venous metastasis. The two pathologic types may coexist.<sup>30,126</sup>

Interestingly, the proportion of left-sided gonadal and ureteral lesions is remarkably similar (63 % and 64 %, respectively), with ovarian endometriosis being a prerequisite for ureteral involvement.<sup>61</sup> The asymmetry in the occurrence of ureteral endometriosis is compatible with the menstrual reflux theory and with the anatomic asymmetry of the left and right hemipelvises. The presence of the sigmoid colon creates a hidden microenvironment around the left fallopian tube and ovary. As a result, endometrial cells regurgitated through the left tube are less exposed to peritoneal fluid flow and may partially escape from the macrophage disposal system. The large bowel does not provide the right hemipelvis with this sort of anatomic shelter due to the more cranial position of the cecum.<sup>68</sup>

However, this hypothesis fails to explain the cases of proven ureteral endometriosis in women who have no evidence of any other focus of peritoneal disease in the pelvis. The second theory to explain the origin of ureteral involvement is the embryonal one. Support for this hypothesis stems from the pathologic findings of hyperplasia of smooth-muscle cells surrounding the affected ureter, with sparse endometriotic glands and scant stroma in surgical specimens from women who had undergone segmental ureteral resection.<sup>68</sup>

The histologic resemblance of ureteral implants to adenomyosis has led some investigators to introduce the concept of adenomyotic disease of the retroperitoneal space, postulating a primary development of endometriosis in the retroperitoneum from embryonic remnants of the müllerian duct.

Endometriosis has some potential for malignant transformation.<sup>113</sup> Malignancy arising in ureteral endometriosis has been reported in only a few studies. *Nezhat et al.* described

the first case of pelvic adenocarcinoma arising from ureteral endometriosis in a woman who underwent hysterectomy and bilateral salpingo-oophorectomy, without any evidence of pelvic endometriosis.<sup>78</sup>

The differential diagnosis of ureteral endometriosis consists mainly of primary cancer, metastatic cancer, retroperitoneal lymphadenopathy, and idiopathic retroperitoneal fibrosis.

### 5.1.3.3 Symptoms

Classic signs and symptoms of ureteral endometriosis may include cyclic flank pain, dysuria, urgency, urinary tract infection, and hematuria.<sup>55</sup> These symptoms are more pronounced in intrinsic ureteral endometriosis than in extrinsic disease.

Notably, a significant percentage of patients with ureteral endometriosis do not have genitourinary symptoms. For example, in one series ureteral obstruction was silent in approximately 40 % of patients with severe ureteral endometriosis.<sup>6</sup> Silent deterioration of renal function has also been reported in 25–43 % of patients with ureteral endometriosis and may lead to complete function loss in the affected kidney.<sup>122</sup> Historically, up to one-third of kidneys affected by ureteral endometriosis were lost.<sup>86</sup>

Because a large percentage of patients with ureteral endometriosis may have an asymptomatic renal obstruction with loss of renal function, evaluation of the upper urinary tract has been recommended in all patients with pelvic endometriosis.

There is a lack of correlation between symptoms and severity of obstruction, as a severe obstruction may be asymptomatic for a long time, leaving the patient at risk for eventual loss of renal function (25–43 % of cases).<sup>25,30,126</sup>

Approximately 50 % of women with ureteral involvement may have pelvic symptoms such as dyspareunia, severe or incapacitating dysmenorrhea, pelvic pain, and menorrhagia.<sup>68</sup>

Among these symptoms, the severity of dysmenorrhea may correlate directly with the extension of endometriosis to the rectovaginal septum, uterosacral ligaments, broad ligament, and ovaries.<sup>68</sup>

Several authors have noted a positive correlation between ureteral endometriosis with incapacitating dysmenorrhea and coexisting lesions of the retrocervical region or rectosigmoid.<sup>68</sup> Conversely, the principal site of involvement by endometriosis is related to the potential for symptomatic ureteral endometriosis. Patients with retrocervical endometriosis were found to have a 7-fold greater chance of suffering from ureteral endometriosis; for patients with endometriosis of the rectosigmoid, this risk was 22 times greater.<sup>124</sup>



### 5.1.3.4 Diagnosis

#### ■ Physical Examination

Physical examination is unrewarding. However, a strong association has been reported between large endometriotic nodules involving the rectovaginal septum and ureteral endometriosis.<sup>41</sup>

#### ■ Laboratory Data

All patients should be assessed for anemia and for renal function by serum creatinine assay. Urine should be evaluated for evidence of gross or microscopic hematuria and cultured to exclude an infectious etiology. Urinary cytology is also necessary to exclude malignancy.

#### ■ Imaging Modalities

Given the risk of silent renal function loss, the upper tract should be periodically evaluated during medical therapy or before and after surgery. However, imaging techniques are of limited value in accurately defining the extent of disease and detecting infiltration of the ureteral wall.

Abdominal ultrasound is routinely used as a screening tool to exclude urinary tract obstruction in patients with pelvic endometriosis. It is a simple, noninvasive test that requires no intravenous contrast, and the findings are highly sensitive for hydronephrosis.<sup>59,83</sup>

Intravenous pyelography has been the traditional functional imaging study in women with suspected urinary tract endometriosis. Radiologic findings such as hydroureteronephrosis, narrowing of the pelvic ureter and, rarely, an intraluminal ureteral mass are possible nonspecific findings. Moreover, intravenous pyelography can confirm that the kidney is functioning and can accurately define the location, extent, and degree of ureteral stenosis. Pyelographic findings of intrinsic disease include ureteral filling defects, whereas extrinsic disease tends to cause smooth strictures in affected ureteral segments.<sup>108</sup>

Despite its limitations, intravenous pyelography, combined with retrograde pyelography, still remains the most common and valuable procedure for the assessment of ureteral endometriosis.<sup>68</sup>

Although computerized tomography can identify endometriomas, its poor specificity and high radiation dose have limited its use in the evaluation of endometriosis, especially in fertile women.

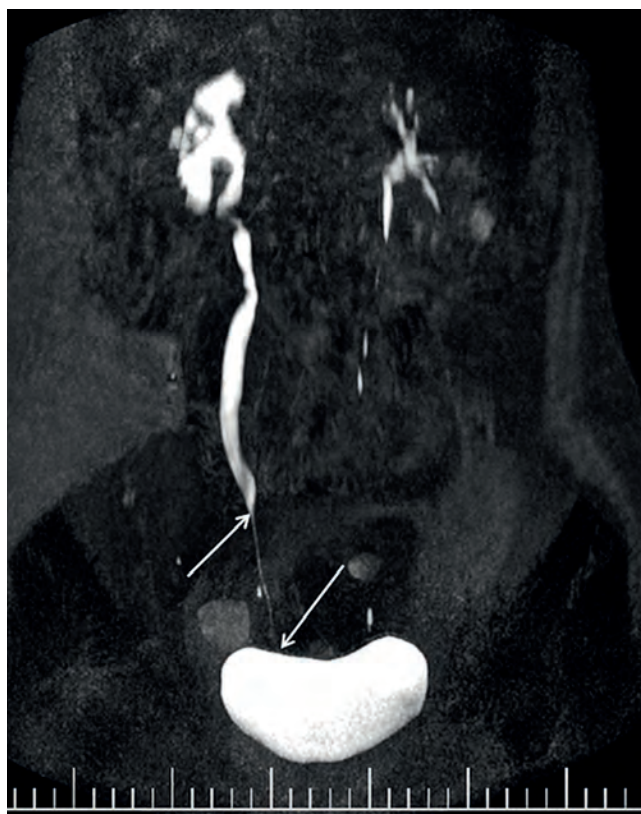
Instead, MRI may reveal direct signs such as a nodule or mass invading the ureter in its course or at the ureterovesical junction.<sup>10,58,105</sup>

Since the ureter is a hollow tube only 4–5 mm in diameter, it can be difficult to analyze with MRI. An indirect sign of ureteral involvement is the possible presence of hydroureteronephrosis above the level of the suspected lesion. MR urography consists of heavily T2-weighted sequences acquired over a wide field in the coronal plane and may be useful in detecting hydroureteronephrosis and evaluating other pathology in the abdomen and pelvis<sup>10,58,105</sup> (Fig. 5.1).

On MRI, the most frequent sign of ureteral endometriosis is the detection of a hypointense nodule along with hyperintense foci adjacent to the ureter on T2- and T1-weighted images.<sup>10</sup>

MRI is the ideal modality in patients with suspected urinary tract endometriosis because it can visualize all components of the urinary system and can explore all possible pelvic locations of endometriosis.

Ureteroscopy has been used to diagnose intrinsic ureteral endometriosis. This procedure allows direct observation of the bladder and/or ureteral lesions and can provide biopsy specimens for histology. The macroscopic appearance of the lesions changes with the phases of the menstrual cycle, showing the most distinct alterations before and during menstruation. Endometriotic lesions often appear edematous and irregular and show variable shape and coloration: bluish-red, bluish-black, or bluish-brown. The lesions may be solitary or multifocal. It is important to measure the distance from the lesion to the ureteral orifices. Endoscopy may be unrewarding if the ectopic tissue does not extend beyond the ureteral adventitial layer. Consequently, negative endoscopic findings do not necessarily confirm the absence of ureteral endometriosis. Ureteroscopic biopsy remains a useful, minimally invasive option for some patients with localized ureteral endometriosis, in order to establish the diagnosis prior to endoscopic ablation.<sup>30,120</sup> Immunostaining of the biopsied tissue for estrogen and progesterone receptors, CK7, CA125, and CD10 may help to establish the diagnosis.<sup>3</sup>



**Fig. 5.1** Magnetic resonance urogram in a patient with right ureteral stenosis caused by endometriotic tissue (arrows).

### 5.1.3.5 Treatment Options

The treatment of choice for ureteral endometriosis is controversial. Treatment has several goals: preservation of renal function with long-term relief of urinary obstruction, management of ongoing disease by complete excision or ablation of endometriotic tissues along with their reactive fibrotic component, the preservation of fertility, and the alleviation of symptoms using the least invasive methods available.

Treatment should be individualized according to age, reproductive desire, symptom severity, lesion size, and the organs involved.<sup>30</sup>

#### ■ Hormonal Therapy

As described above, several regimens with variable results have been reported for hormonal therapy. Hormone manipulation may shrink the tissues affected by endometriosis, but obstruction secondary to fibrous tissue and adhesions does not usually resolve. Hormone therapy should be considered an option for patients of childbearing age who desire pregnancy. Close follow-up care with ultrasonography at 6-month intervals is recommended to exclude upper urinary tract obstruction.<sup>50</sup>

If renal function is normal and there is minimal to mild hydronephrosis with no functional obstruction as determined by radionuclide renal scanning, hormone therapy may be instituted. Ovarian hormonal ablation with GnRH agonists has been used with success in some series.<sup>93</sup>

Local progesterone therapy, such as a levonorgestrel-releasing IUD, may be useful as a conservative medical approach. Although this treatment is frequently used in gynecology for contraception or for idiopathic menorrhagia, it is also effective in patients with endometriotic foci in the pelvis and vesicovaginal septum, possibly because it delivers high concentrations of the drug to the endometrium and adjacent areas despite low plasma levels. This offers two important advantages: it is effective for 5 years and does not affect future fertility after treatment is discontinued.

Though all of these drugs have been shown to alleviate the severity of pelvic pain, dysmenorrhea and dyspareunia, the symptoms often recur when therapy is withdrawn. Moreover,

the drugs are frequently associated with safety and tolerance problems, and they do not improve fertility.<sup>68</sup>

Since the relapse rate of DIE is quite high (approximately 56%), this treatment provides only a temporary resolution of lesions in these patients.

To summarize, hormonal therapy is generally less effective in patients with extensive endometriosis, as reflected by its high rates of treatment failure and recurrence.<sup>65</sup>

#### ■ Surgical Therapy

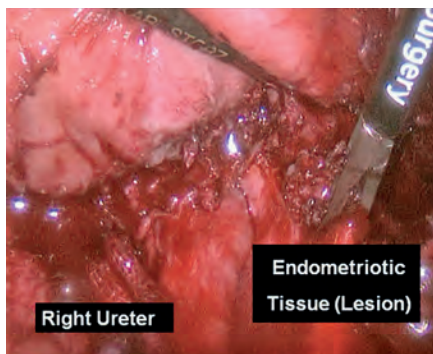
Surgical intervention is the treatment of choice for most patients with significant hydronephrosis and periureteral disease. The main indications for surgical treatment of ureteral endometriosis are the presence of symptoms and/or hydronephrosis.<sup>66</sup>

Historically, open surgery was the preferred treatment option in patients with extensive disease.

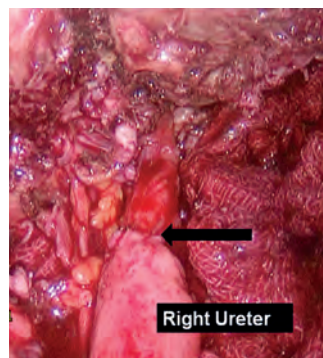
Laparoscopic interventions such as ureterolysis, ureterostomy, and ureteral reimplantation for ureteral stricture disease secondary to endometriosis can be performed following the same principles applied in traditional open surgery. Advantages include a magnified view, better exposure, and an enhanced ability for lesion detection in the pelvis, retroperitoneal space, and around the lower urinary tract.<sup>8,20,29,40,43,46,47,75,77,99,123</sup>

Ureterolysis may resolve ureteral obstruction in patients with extrinsic disease. If laparoscopic ureterolysis is proposed, a transperitoneal approach is preferable in that it allows a better assessment of endometrial implants on the peritoneum overlying the ureter<sup>43,122</sup> (Figs. 5.2, 5.3). A success rate of approximately 85% has been reported for this approach.<sup>47</sup> If patients are suspected to have intraluminal ureteral involvement, ureteroscopic resection or ablation should be considered.<sup>47</sup> Relapse rate after the nonradical removal of lesions is up to 30%.<sup>40</sup>

If these procedures are unsuccessful or extensive disease is present, distal ureterectomy with reimplantation is advised. This can be accomplished by using either an open, laparoscopic or robotic-assisted approach, which often yields excellent long-term results while preserving renal integrity.<sup>6,7,99</sup>



**Fig. 5.2** Dissection of the right ureter from endometriotic tissue.

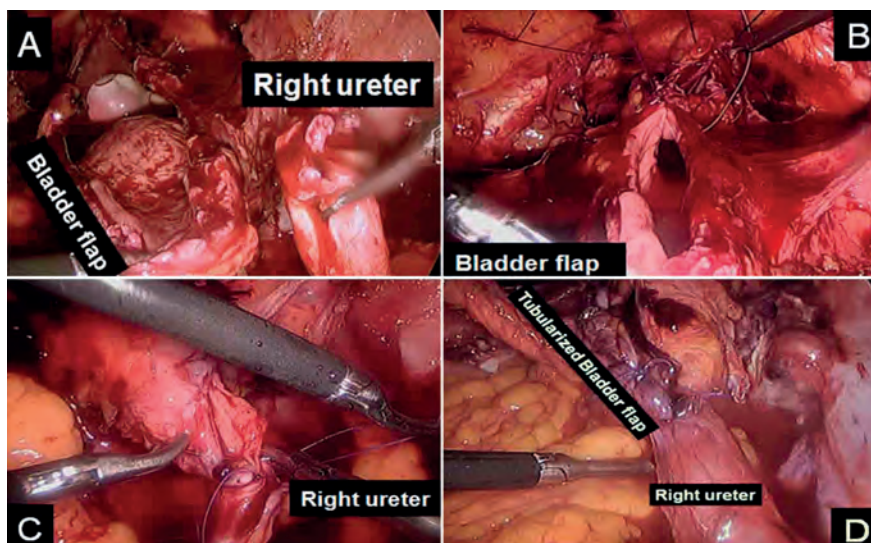


**Fig. 5.3** Complete excision of the endometriotic tissue and full dissection of the pelvic ureter. Note the constriction of the distal ureter (arrow) caused by intrinsic fibrosis.

The surgical treatment of choice may change according to the diagnosis of intrinsic or extrinsic ureteral endometriosis.

Preoperative planning should be rigorous, and the complete surgical excision of ureteral endometriosis should be ensured by a team of experts who are familiar with endometriosis.





**Fig. 5.4a–c** Laparoscopic harvesting of the bladder (Boari) flap (a) to bridge the gap from midureter to bladder after complete excision of the fibrotic distal ureter. The bladder flap is tubularized (b) in preparation for end-to-end anastomosis (c) to the right ureter over a ureteric stent using an intracorporeal suture technique. Final view of laparoscopic ureteroneocystostomy using a bladder (Boari) flap (d).

#### 5.1.3.6 Extrinsic Ureteral Endometriosis

Elective ureterolysis is indicated only if there is an extrinsic lesion less than 3 cm in diameter and/or in cases of nonobstructive ureteral involvement.<sup>7,30,43,75</sup>

There is still controversy in the literature about the preoperative or intraoperative use of a double-J stent.<sup>8,20,123</sup> The double-J stent can also be positioned after ureterolysis.

Ureterolysis is contraindicated for intrinsic endometriosis due to high rates of recurrence and stenosis.<sup>75</sup>

#### 5.1.3.7 Intrinsic Ureteral Endometriosis

Indications for ureteral resection include an intrinsic ureteral lesion, lesions longer than 3 cm, and lesions located below the level of the iliac vessels.<sup>20,99,126</sup>

Traditionally, this type of surgery is performed by laparotomy, which is associated with a high risk of postoperative morbidity. Resection of the ureter is followed by one of three available techniques of ureteral reconstruction:

- Ureteral end-to-end anastomosis
- Ureteral reimplantation with an antireflux technique (e.g., *Lich-Gregoire* or *Leadbetter-Politano*)
- Psoas hitch or bladder (*Boari*) flap technique (Fig. 5.4)

The placement of a double-J stent may provide a useful landmark for the surgeon during dissection and resection, simplifying all stages of reanastomosis or reimplantation.

Despite all ureteral surgical techniques, the incidence of progressive renal function deterioration may be as high as 40% and may culminate in nephrectomy.<sup>86,126</sup>

Ultrasound surveillance is advised for the detection of recurrent ureteral obstruction in patients with ureteral endometriosis that has been treated by hormone therapy, endourologic ablation, or surgical resection and reconstruction.<sup>40</sup>

#### 5.1.4 Summary

Given the rising incidence of urinary tract endometriosis in recent years, close collaboration between the gynecology and urology teams is crucial for an adequate diagnostic workup and proper management plan. While different diagnostic modalities may be needed to address this condition, the management plan should be individualized based on the extent of disease and patients' expectations. Both hormonal therapy and minimally invasive urologic procedures hold promise as the most rewarding treatment strategy for these complex cases.

#### 5.1.5 References

1. ABRAO MS, DIAS JA JR, BELLELIS P, PODGAEC S, BAUTZER CR, GROMATSKY C. Endometriosis of the ureter and bladder are not associated diseases. *Fertil Steril* 2009;91(5):1662–7. doi:10.1016/j.fertnstert.2008.02.143.
2. AKPINAR S, YILMAZ G, CELEBIOGLU E. A rare cyclic recurrent hematuria case; bladder endometriosis. *Quant Imaging Med Surg* 2015;5(3):485–7. doi:10.3978/j.issn.2223-4292.2014.08.05.
3. AL-KHAWAJA M, TAN PH, MACLENNAN GT, LOPEZ-BELTRAN A, MONTIRONI R, CHENG L. Ureteral endometriosis: clinicopathological and immunohistochemical study of 7 cases. *Hum Pathol* 2008;39(6):954–9. doi:10.1016/j.humpath.2007.11.011.
4. ALLEN D, O'BRIEN T, PINGLE P, CHANDRA A. Endometrioid adenocarcinoma of the bladder. *Histopathology* 2005;46(2):232–3. doi:10.1111/j.1365-2559.2004.01987.x.
5. ANDRES MDP, LOPES LA, BARACAT EC, PODGAEC S. Dienogest in the treatment of endometriosis: systematic review. *Arch Gynecol Obstet* 2015;292(3):523–9. doi:10.1007/s00404-015-3681-6.
6. ANTONELLI A, SIMEONE C, FREGO E, MININI G, BIANCHI U, CUNICO SC. Surgical treatment of ureteral obstruction from endometriosis: our experience with thirteen cases. *Int Urogynecol J Pelvic Floor Dysfunct* 2004;15(6):407–12; discussion 412. doi:10.1007/s00192-004-1171-7.
7. ANTONELLI A, SIMEONE C, ZANI D, SACCONI T, MININI G, CANOSSI E et al. Clinical aspects and surgical treatment of urinary tract endometriosis: our experience with 31 cases. *Eur Urol* 2006;49(6):1093–7; discussion 1097–8. doi:10.1016/j.eururo.2006.03.037.



8. ASSIMOS DG, PATTERSON LC, TAYLOR CL. Changing incidence and etiology of iatrogenic ureteral injuries. *J Urol* 1994;152(6 Pt 2): 2240–6.
9. BALLEYGUIER C, CHAPRON C, DUBUISSON JB, KINKEL K, FAUCONNIER A, VIEIRA M et al. Comparison of magnetic resonance imaging and transvaginal ultrasonography in diagnosing bladder endometriosis. *J Am Assoc Gynecol Laparosc* 2002;9(1):15–23.
10. BALLEYGUIER C, ROUPRET M, NGUYEN T, KINKEL K, HELENON O, CHAPRON C. Ureteral endometriosis: the role of magnetic resonance imaging. *J Am Assoc Gynecol Laparosc* 2004;11(4):530–6.
11. BAZOT M, GASNER A, LAFONT C, BALLESTER M, DARAI E. Deep pelvic endometriosis: limited additional diagnostic value of postcontrast in comparison with conventional MR images. *Eur J Radiol* 2011;80(3):e331–9. doi:10.1016/j.ejrad.2010.12.006.
12. BAZOT M, THOMASSIN I, HOURANI R, CORTEZ A, DARAI E. Diagnostic accuracy of transvaginal sonography for deep pelvic endometriosis. *Ultrasound Obstet Gynecol* 2004;24(2):180–5. doi:10.1002/uog.1108.
13. BIZZARRI N, REMORGIDA V, LEONE ROBERTI MAGGIORE U, SCALA C, TAFI E, GHIRARDI V et al. Dienogest in the treatment of endometriosis. *Expert Opin Pharmacother* 2014;15(13):1889–902. doi:10.1517/14656566.2014.943734.
14. BOGART LM, BERRY SH, CLEMENS JQ. Symptoms of interstitial cystitis, painful bladder syndrome and similar diseases in women: a systematic review. *J Urol* 2007;177(2):450–6. doi:10.1016/j.juro.2006.09.032.
15. BROWN J, KIVES S, AKHTAR M. Progestagens and anti-progestagens for pain associated with endometriosis. *Cochrane Database Syst Rev* 2012;3:CD002122. doi:10.1002/14651858.CD002122.pub2.
16. BUKA NJ. Vesical endometriosis after cesarean section. *Am J Obstet Gynecol* 1988;158(5):1117–8.
17. BULUN SE. Endometriosis. *N Engl J Med* 2009;360(3):268–79. doi:10.1056/NEJMra0804690.
18. BURNEY RO, GIUDICE LC. Pathogenesis and pathophysiology of endometriosis. *Fertil Steril* 2012;98(3):511–9. doi:10.1016/j.fertnstert.2012.06.029.
19. BUSARD MPH, MIJATOVIC V, VAN KUIJK C, PIETERS-VAN DEN BOS, I C, HOMPEGA, VAN WAESBERGHE, J H T M. Magnetic resonance imaging in the evaluation of (deep infiltrating) endometriosis: the value of diffusion-weighted imaging. *J Magn Reson Imaging* 2010;32(4):1003–9. doi:10.1002/jmri.22310.
20. CAMANNI M, BONINO L, DELPIANO EM, BERCHIALLA P, MIGLIARETTI G, REVELLI A et al. Laparoscopic conservative management of ureteral endometriosis: a survey of eighty patients submitted to ureterolysis. *Reprod Biol Endocrinol* 2009;7:109. doi:10.1186/1477-7827-7-109.
21. CERVIGNI M, NATALE F. Gynecological disorders in bladder pain syndrome/interstitial cystitis patients. *Int J Urol* 2014;21 Suppl 1:85–8. doi:10.1111/iju.12379.
22. CHAMIE LP, BLASBALG R, PEREIRA RMA, WARMBRAND G, SERAFINI PC. Findings of pelvic endometriosis at transvaginal US, MR imaging, and laparoscopy. *Radiographics* 2011;31(4):E77–100. doi:10.1148/rg.314105193.
23. CHAPRON C, CHOPIN N, BORGHESE B, FOULOT H, DOUSSET B, VACHER-LAVENU MC et al. Deeply infiltrating endometriosis: pathogenetic implications of the anatomical distribution. *Hum Reprod* 2006;21(7):1839–45. doi:10.1093/humrep/del079.
24. CHAPRON C, DUBUISSON JB. Laparoscopic management of bladder endometriosis. *Acta Obstet Gynecol Scand* 1999;78(10):887–90.
25. CHAPRON C, FAUCONNIER A, VIEIRA M, BARAKAT H, DOUSSET B, PANSINI V et al. Anatomical distribution of deeply infiltrating endometriosis: surgical implications and proposition for a classification. *Hum Reprod* 2003;18(1):157–61.
26. CHATZIPARADEISI A, DANILIDIS A, DIAVATIS S, VRACHNIS N, CARCEA F, GIANNOULIS C. Abdominal wall endometriosis after a caesarian section – an interesting case report. *Clin Exp Obstet Gynecol* 2014;41(3):360–1.
27. CHOI CH, KIM JJ, KIM WY, MIN KW, KIM DH. A rare case of post-hysterectomy vault site iatrogenic endometriosis. *Obstet Gynecol Sci* 2015;58(4):319–22. doi:10.5468/ogs.2015.58.4.319.
28. CHOPIN N, VIEIRA M, BORGHESE B, FOULOT H, DOUSSET B, COSTE J et al. Operative management of deeply infiltrating endometriosis: results on pelvic pain symptoms according to a surgical classification. *J Minim Invasive Gynecol* 2005;12(2):106–12. doi:10.1016/j.jmig.2005.01.015.
29. CHUNG H, JEONG BC, KIM HH. Laparoscopic ureteroneocystostomy with vesicopsoas hitch: nonrefluxing ureteral reimplantation using cystoscopy-assisted submucosal tunneling. *J Endourol* 2006;20(9):632–8. doi:10.1089/end.2006.20.632.
30. COMITER CV. Endometriosis of the urinary tract. *Urol Clin North Am* 2002;29(3):625–35.
31. CROSIGNANI PG, LUCIANO A, RAY A, BERGQVIST A. Subcutaneous depot medroxyprogesterone acetate versus leuprolide acetate in the treatment of endometriosis-associated pain. *Hum Reprod* 2006;21(1):248–56. doi:10.1093/humrep/dei290.
32. CULLEN TS. Adenomyoma of the recto-vaginal septum. *Bull Johns Hopkins Hosp* 1917;28:343–9.
33. DING D, HSU S. Scar endometriosis at the site of cesarean section. *Taiwan J Obstet Gynecol* 2006;45(3):247–9. doi:10.1016/S1028-4559(09)60234-5.
34. DONNEZ J, SPADA F, SQUIFFLET J, NISOLLE M. Bladder endometriosis must be considered as bladder adenomyosis. *Fertil Steril* 2000;74(6):1175–81.
35. DONNEZ J, VAN LANGENDONCKT A, CASANAS-ROUX F, VAN GOSSUM J, PIRARD C, JADOUL P et al. Current thinking on the pathogenesis of endometriosis. *Gynecol Obstet Invest* 2002;54 Suppl 1:52–8; discussion 59–62.
36. DONNEZ O, SQUIFFLET J, LECONTE I, JADOUL P, DONNEZ J. Posthysterectomy pelvic adenomyotic masses observed in 8 cases out of a series of 1405 laparoscopic subtotal hysterectomies. *J Minim Invasive Gynecol* 2007;14(2):156–60. doi:10.1016/j.jmig.2006.09.008.
37. DOUGLAS C, ROTIMI O. Extragenital endometriosis – a clinicopathological review of a Glasgow hospital experience with case illustrations. *J Obstet Gynaecol* 2004;24(7):804–8. doi:10.1080/01443610400009568.
38. ESKENAZI B, WARNER ML. Epidemiology of endometriosis. *Obstet Gynecol Clin North Am* 1997;24(2):235–58.
39. FAUCONNIER A, CHAPRON C, DUBUISSON J, VIEIRA M, DOUSSET B, BREART G. Relation between pain symptoms and the anatomic location of deep infiltrating endometriosis. *Fertil Steril* 2002;78(4):719–26.
40. FEDELE L, BIANCHI S, ZANCONATO G, BERGAMINI V, BERLANDA N, CARMIGNANI L. Long-term follow-up after conservative surgery for bladder endometriosis. *Fertil Steril* 2005;83(6):1729–33. doi:10.1016/j.fertnstert.2004.12.047.

41. FEDELE L, BIANCHI S, ZANCONATO G, BETTONI G, GOTSCH F. Long-term follow-up after conservative surgery for rectovaginal endometriosis. *Am J Obstet Gynecol* 2004;190(4):1020–4. doi:10.1016/j.ajog.2003.10.698.
42. FEDELE L, PIAZZOLA E, RAFFAELLI R, BIANCHI S. Bladder endometriosis: deep infiltrating endometriosis or adenomyosis? *Fertil Steril* 1998;69(5):972–5.
43. FRENNA V, SANTOS L, OHANA E, BAILEY C, WATTIEZ A. Laparoscopic management of ureteral endometriosis: our experience. *J Minim Invasive Gynecol* 2007;14(2):169–71. doi:10.1016/j.jmig.2006.09.009.
44. GABRIEL B, NASSIF J, TROMPOUKIS P, BARATA S, WATTIEZ A. Prevalence and management of urinary tract endometriosis: a clinical case series. *Urology* 2011;78(6):1269–74. doi:10.1016/j.urology.2011.07.1403.
45. GENC M, GENC B, KARAAARSLAN S, SOLAK A, SARACOGLU M. Endometriosis localized to urinary bladder wall mimicking urinary bladder carcinoma. *Arch Ital Urol Androl* 2014;86(3):233–4. doi:10.4081/aiua.2014.3.233.
46. GENERAO SE, KEENE KD, DAS S. Endoscopic diagnosis and management of ureteral endometriosis. *J Endourol* 2005;19(10):1177–9. doi:10.1089/end.2005.19.1177.
47. GHEZZI F, CROMI A, BERGAMINI V, SERATI M, SACCO A, MUELLER MD. Outcome of laparoscopic ureterolysis for ureteral endometriosis. *Fertil Steril* 2006;86(2):418–22. doi:10.1016/j.fertnstert.2005.12.071.
48. GIUDICE LC, KAO LC. Endometriosis. *Lancet* 2004;364(9447):1789–99. doi:10.1016/S0140-6736(04)17403-5.
49. GRASSO RF, GIACOMO V DI, SEDATI P, SIZZI O, FLORIO G, FAIELLA E et al. Diagnosis of deep infiltrating endometriosis: accuracy of magnetic resonance imaging and transvaginal 3D ultrasonography. *Abdom Imaging* 2010;35(6):716–25. doi:10.1007/s00261-009-9587-7.
50. GUSTILO-ASHBY AM, PARAISO MFR. Treatment of urinary tract endometriosis. *J Minim Invasive Gynecol* 2006;13(6):559–65. doi:10.1016/j.jmig.2006.07.012.
51. HANSEN KA, CHALPE A, EYSTER KM. Management of endometriosis-associated pain. *Clin Obstet Gynecol* 2010;53(2):439–48. doi:10.1097/GRF.0b013e3181dbda06.
52. HARADA M, OSUGA Y, IZUMI G, TAKAMURA M, TAKEMURA Y, HIRATA T et al. Dienogest, a new conservative strategy for extragenital endometriosis: a pilot study. *Gynecol Endocrinol* 2011;27(9):717–20. doi:10.3109/09513590.2010.533800.
53. HERNANDEZ E, WOODRUFF JD. Endometrial adenocarcinoma arising in adenomyosis. *Am J Obstet Gynecol* 1980;138(7 Pt 1):827–32.
54. HOSSEINI SY, SAFARINEJAD M. Endometriosis of the urinary tract: a report of 3 cases. *Urol J* 2005;2(1):45–8.
55. JUBANYIK KJ, COMITE F. Extrapelvic endometriosis. *Obstet Gynecol Clin North Am* 1997;24(2):411–40.
56. JUDD ES. Adenomyomata presenting as a tumor of the bladder. *Surg Clin North Am* 1921(1):1271–8.
57. KARADAG MA, AYDIN T, KARADAG OI, AKSOY H, DEMIR A, CECEN K et al. Endometriosis presenting with right side hydronephrosis only: a case report. *J Med Case Rep* 2014;8:420. doi:10.1186/1752-1947-8-420.
58. KINKEL K, FREI KA, BALLEYGUIER C, CHAPRON C. Diagnosis of endometriosis with imaging: a review. *Eur Radiol* 2006;16(2):285–98. doi:10.1007/s00330-005-2882-y.
59. KNABBen L, IMBODEN S, FELLMANN B, NIRGIANAKIS K, KUHN A, MUELLER MD. Urinary tract endometriosis in patients with deep infiltrating endometriosis: prevalence, symptoms, management, and proposal for a new clinical classification. *Fertil Steril* 2015;103(1):147–52. doi:10.1016/j.fertnstert.2014.09.028.
60. KODAMAN PH. Current strategies for endometriosis management. *Obstet Gynecol Clin North Am* 2015;42(1):87–101. doi:10.1016/j.ogc.2014.10.005.
61. KOLODZIEJ A, KRAJEWSKI W, DOLOWY L, HIRNLE L. Urinary Tract Endometriosis. *Urol J* 2015;12(4):2213–7.
62. KONINCKX PR, MEULEMAN C, DEMEYERE S, LESAFFRE E, CORNILLIE FJ. Suggestive evidence that pelvic endometriosis is a progressive disease, whereas deeply infiltrating endometriosis is associated with pelvic pain. *Fertil Steril* 1991;55(4):759–65.
63. KOVOOR E, NASSIF J, MIRANDA-MENDOZA I, WATTIEZ A. Endometriosis of bladder: outcomes after laparoscopic surgery. *J Minim Invasive Gynecol* 2010;17(5):600–4. doi:10.1016/j.jmig.2010.05.008.
64. KUMAR S, TIWARI P, SHARMA P, GOEL A, SINGH JP, VIJAY MK et al. Urinary tract endometriosis: Review of 19 cases. *Urol Ann* 2012;4(1):6–12. doi:10.4103/0974-7796.91613.
65. LAM AM, FRENCH M, CHARNOCK FM. Bilateral ureteric obstruction due to recurrent endometriosis associated with hormone replacement therapy. *Aust N Z J Obstet Gynaecol* 1992;32(1):83–4.
66. LE TOHIC A, CHIS C, YAZBECK C, KOSKAS M, MADELENAT P, PANEL P. Bladder endometriosis: diagnosis and treatment. A series of 24 patients. *Gynecol Obstet Fertil* 2009;37(3):216–21. doi:10.1016/j.gyobfe.2009.01.018.
67. MACCAGNANO C, PELLUCCHI F, ROCCHINI L, GHEZZI M, SCATTONI V, MONTORSI F et al. Diagnosis and treatment of bladder endometriosis: state of the art. *Urol Int* 2012;89(3):249–58. doi:10.1159/000339519.
68. MACCAGNANO C, PELLUCCHI F, ROCCHINI L, GHEZZI M, SCATTONI V, MONTORSI F et al. Ureteral endometriosis: proposal for a diagnostic and therapeutic algorithm with a review of the literature. *Urol Int* 2013;91(1):1–9. doi:10.1159/000345140.
69. MAEDA T, UCHIDA Y, NAKAJIMA F. Vesical endometriosis following the menopause. *Int Urogynecol J Pelvic Floor Dysfunct* 2009;20(12):1515–7. doi:10.1007/s00192-009-0925-7.
70. MAHUTTE NG, ARICI A. Medical management of endometriosis-associated pain. *Obstet Gynecol Clin North Am* 2003;30(1):133–50.
71. MANGANARO L, FIERRO F, TOMEI A, IRIMIA D, LODISE P, SERGI ME et al. Feasibility of 3.0T pelvic MR imaging in the evaluation of endometriosis. *Eur J Radiol* 2012;81(6):1381–7. doi:10.1016/j.ejrad.2011.03.049.
72. METTLER L, GAIKWAD V, RIEBE B, SCHOLLMEYER T. Bladder endometriosis: possibility of treatment by laparoscopy. *JSLs* 2008;12(2):162–5.
73. METTLER L, SALMASSI A, SCHOLLMEYER T, SCHMUTZLER AG, PUNGEL F, JONAT W. Comparison of c-DNA microarray analysis of gene expression between eutopic endometrium and ectopic endometrium (endometriosis). *J Assist Reprod Genet* 2007;24(6):249–58. doi:10.1007/s10815-007-9116-y.
74. MOUNSEY AL, WILGUS A, SLAWSON DC. Diagnosis and management of endometriosis. *Am Fam Physician* 2006;74(4):594–600.
75. MU D, LI X, ZHOU G, GUO H. Diagnosis and treatment of ureteral endometriosis: study of 23 cases. *Urol J* 2014;11(4):1806–12.

76. NEZHAT C, HAJHOSSEINI B, KING LP. Robotic-assisted laparoscopic treatment of bowel, bladder, and ureteral endometriosis. *JLS* 2011;15(3):387–92. doi:10.4293/108680811X13125733356396.
77. NEZHAT C, NEZHAT F, NEZHAT CH, NASSERBAKHT F, ROSATI M, SEIDMAN DS. Urinary tract endometriosis treated by laparoscopy. *Fertil Steril* 1996;66(6):920–4.
78. NEZHAT CH, MALIK S, OSIAS J, NEZHAT F, NEZHAT C. Laparoscopic management of 15 patients with infiltrating endometriosis of the bladder and a case of primary intravesical endometrioid adenocarcinoma. *Fertil Steril* 2002;78(4):872–5.
79. OLIVE DL, PRITTS EA. Treatment of endometriosis. *N Engl J Med* 2001;345(4):266–75. doi:10.1056/NEJM200107263450407.
80. PANG S, CHAO A, WANG C, LIN G, LEE C. Transurethral partial cystectomy and laparoscopic reconstruction for the management of bladder endometriosis. *Fertil Steril* 2008;90(5):2014.e1–3. doi:10.1016/j.fertnstert.2008.04.045.
81. PASALEGA M, MIREA C, VILCEA ID, VASILE I, PLESEA IE, CALOTA F et al. Parietal abdominal endometriosis following Cesarean section. *Rom J Morphol Embryol* 2011;52(1 Suppl):503–8.
82. PASTOR-NAVARRO H, GIMENEZ-BACHS JM, DONATE-MORENO MJ, PASTOR-GUZMAN JM, RUIZ-MONDEJAR R, ATIENZAR-TOBARRA M et al. Update on the diagnosis and treatment of bladder endometriosis. *Int Urogynecol J Pelvic Floor Dysfunct* 2007;18(8):949–54. doi:10.1007/s00192-007-0342-8.
83. PATEMAN K, HOLLAND TK, KNEZ J, DERDELIS G, CUTNER A, SARIDOGAN E et al. Should a detailed ultrasound examination of the complete urinary tract be routinely performed in women with suspected pelvic endometriosis? *Hum Reprod* 2015;30(12):2802–7. doi:10.1093/humrep/dev246.
84. PATIL NJ, KUMAR V, GUPTA A. Scar endometriosis—a sequel of caesarean section. *J Clin Diagn Res* 2014;8(4):FD09–10. doi:10.7860/JCDR/2014/7554.4267.
85. PEREZ-UTRILLA PEREZ M, AGUILERA BAZAN A, ALONSO DORREGO JM, HERNANDEZ A, FRANCISCO MG DE, MARTIN HERNANDEZ M et al. Urinary tract endometriosis: clinical, diagnostic, and therapeutic aspects. *Urology* 2009;73(1):47–51. doi:10.1016/j.urology.2008.08.470.
86. PONTICELLI C, GRAZIANI G, MONTANARI E. Ureteral endometriosis: a rare and underdiagnosed cause of kidney dysfunction. *Nephron Clin Pract* 2010;114(2):c89–93. doi:10.1159/000254380.
87. POTEPALOV S, BILELLO S, GOMELSKY A. A 45-year-old woman with an asymptomatic, extensive bladder mass. *Urology* 2009;74(6):1191–4. doi:10.1016/j.urology.2009.07.1220.
88. PRENTICE A, DEARY AJ, BLAND E. Progestagens and anti-progestagens for pain associated with endometriosis. *Cochrane Database Syst Rev* 2000(2):CD002122. doi:10.1002/14651858.CD002122.
89. PRENTICE A, DEARY AJ, GOLDBECK-WOOD S, FARQUHAR C, SMITH SK. Gonadotrophin-releasing hormone analogues for pain associated with endometriosis. *Cochrane Database Syst Rev* 2000(2):CD000346. doi:10.1002/14651858.CD000346.
90. PRICE DT, MALONEY KE, IBRAHIM GK, CUNDIFF GW, LEDER RA, ANDERSON EE. Vesical endometriosis: report of two cases and review of the literature. *Urology* 1996;48(4):639–43. doi:10.1016/S0090-4295(96)00224-5.
91. RAJAKUMAR C, VILOS GA, VILOS AG, MARKS JL, ETTLER HC, PAUTLER SS. Combined transurethral and laparoscopic partial cystectomy and robotically assisted bladder repair for the treatment of bladder endocervicosis: case report and review of the literature. *J Obstet Gynaecol Can* 2014;36(2):141–5.
92. RAZZAGHI MR, RAHJOO T, GOLSHAN A. Endometriosis with pure urinary symptoms. *Urol J* 2009;6(2):132–4.
93. RIVLIN ME, MILLER JD, KRUEGER RP, PATEL RB, BOWER JD. Leuprolide acetate in the management of ureteral obstruction caused by endometriosis. *Obstet Gynecol* 1990;75(3 Pt 2):532–6.
94. ROMAN H, ARAMBAGE K, PASQUIER G, RESCH B, HUET E. Combined cystoscopic and laparoscopic approach in deep endometriosis of the bladder. *J Minim Invasive Gynecol* 2014;21(6):978–9. doi:10.1016/j.jmig.2014.02.009.
95. SABA L, SULCIS R, MELIS GB, CECCO CN DE, LAGHI A, PIGA M et al. Endometriosis: the role of magnetic resonance imaging. *Acta Radiol* 2015;56(3):355–67. doi:10.1177/0284185114526086.
96. SAMPSON JA. Metastatic or Embolic Endometriosis, due to the Menstrual Dissemination of Endometrial Tissue into the Venous Circulation. *Am J Pathol* 1927;3(2):93–110.43.
97. SCHINDLER AE. Dienogest in long-term treatment of endometriosis. *Int J Womens Health* 2011;3:175–84. doi:10.2147/IJWH.S5633.
98. SCHLAFF WD, CARSON SA, LUCIANO A, ROSS D, BERGQVIST A. Subcutaneous injection of depot medroxyprogesterone acetate compared with leuprolide acetate in the treatment of endometriosis-associated pain. *Fertil Steril* 2006;85(2):314–25. doi:10.1016/j.fertnstert.2005.07.1315.
99. SCHONMAN R, DOTAN Z, WEINTRAUB AY, GOLDENBERG M, SEIDMAN DS, SCHIFF E et al. Long-term follow-up after ureteral reimplantation in patients with severe deep infiltrating endometriosis. *Eur J Obstet Gynecol Reprod Biol* 2013;171(1):146–9. doi:10.1016/j.ejogrb.2013.08.027.
100. SELAK V, FARQUHAR C, PRENTICE A, SINGLA A. Danazol for pelvic pain associated with endometriosis. *Cochrane Database Syst Rev* 2001(4):CD000068. doi:10.1002/14651858.CD000068.
101. SENER A, CHEW BH, DUVDEVANI M, BROCK GB, VILOS GA, PAUTLER SE. Combined transurethral and laparoscopic partial cystectomy and robot-assisted bladder repair for the treatment of bladder endometrioma. *J Minim Invasive Gynecol* 2006;13(3):245–8. doi:10.1016/j.jmig.2006.01.014.
102. SEPILIAN V, DELLA BADIA C. Iatrogenic endometriosis caused by uterine morcellation during a supracervical hysterectomy. *Obstet Gynecol* 2003;102(5 Pt 2):1125–7.
103. SERACCHIOLI R, MABROUK M, MONTANARI G, MANUZZI L, CONCETTI S, VENTUROLI S. Conservative laparoscopic management of urinary tract endometriosis (UTE): surgical outcome and long-term follow-up. *Fertil Steril* 2010;94(3):856–61. doi:10.1016/j.fertnstert.2009.04.019.
104. SERACCHIOLI R, MANNINI D, COLOMBO FM, VIANELLO F, REGGIANI A, VENTUROLI S. Cystoscopy-assisted laparoscopic resection of extramucosal bladder endometriosis. *J Endourol* 2002;16(9):663–6. doi:10.1089/089277902761403014.
105. SILLOU S, POIREE S, MILLISCHER AE, CHAPRON C, HELENON O. Urinary endometriosis: MR imaging appearance with surgical and histological correlations. *Diagn Interv Imaging* 2015;96(4):373–81. doi:10.1016/j.diii.2014.11.010.
106. SIRCUS SI, SANT GR, UCCI AA JR. Bladder detrusor endometriosis mimicking interstitial cystitis. *Urology* 1988;32(4):339–42.



107. SOMIGLIANA E, VERCELLINI P, GATTEI U, CHOPIN N, CHIODO I, CHAPRON C. Bladder endometriosis: getting closer and closer to the unifying metastatic hypothesis. *Fertil Steril* 2007;87(6):1287–90. doi:10.1016/j.fertnstert.2006.11.090.
108. STEBBING JF, NOTLEY RG. Noncalculous obstruction due to involvement of the ureter in endometriosis. *Eur Urol* 1995;28(2):122–5.
109. STROWITZKI T, FAUSTMANN T, GERLINGER C, SCHUMACHER U, AHLERS C, SEITZ C. Safety and tolerability of dienogest in endometriosis: pooled analysis from the European clinical study program. *Int J Womens Health* 2015;7:393–401. doi:10.2147/IJWH.S77202.
110. STROWITZKI T, MARR J, GERLINGER C, FAUSTMANN T, SEITZ C. Dienogest is as effective as leuprolide acetate in treating the painful symptoms of endometriosis: a 24-week, randomized, multicentre, open-label trial. *Hum Reprod* 2010;25(3):633–41. doi:10.1093/humrep/dep469.
111. TAKAGI H, MATSUNAMI K, ICHIGO S, IMAI A. Novel corrected medical management of primary bladder endometriosis with dienogest: a case report. *Clin Exp Obstet Gynecol* 2011;38(2):184–5.
112. TAKAMURA M, KOGA K, OSUGA Y, TAKEMURA Y, HAMASAKI K, HIROTA Y et al. Post-operative oral contraceptive use reduces the risk of ovarian endometrioma recurrence after laparoscopic excision. *Hum Reprod* 2009;24(12):3042–8. doi:10.1093/humrep/dep297.
113. TAKEUCHI M, MATSUZAKI K, UEHARA H, NISHITANI H. Malignant transformation of pelvic endometriosis: MR imaging findings and pathologic correlation. *Radiographics* 2006;26(2):407–17. doi:10.1148/rg.262055041.
114. TARUMI Y, MORI T, KUSUKI I, ITO F, KITAWAKI J. Endometrioid adenocarcinoma arising from deep infiltrating endometriosis involving the bladder: A case report and review of the literature. *Gynecol Oncol Rep* 2015;13:68–70. doi:10.1016/j.gore.2015.07.003.
115. THONNON C, PHILIP C, FASSI-FEHRI H, BISCH C, COULON A, SAINT-HILAIRE P DE et al. Three-dimensional ultrasound in the management of bladder endometriosis. *J Minim Invasive Gynecol* 2015;22(3):403–9. doi:10.1016/j.jmig.2014.10.021.
116. VERCELLINI P, ABBIATI A, VIGANO P, SOMIGLIANA ED, DAGUATI R, MERONI F et al. Asymmetry in distribution of diaphragmatic endometriotic lesions: evidence in favour of the menstrual reflux theory. *Hum Reprod* 2007;22(9):2359–67. doi:10.1093/humrep/dem224.
117. VERCELLINI P, ESKENAZI B, CONSONNI D, SOMIGLIANA E, PARAZZINI F, ABBIATI A et al. Oral contraceptives and risk of endometriosis: a systematic review and meta-analysis. *Hum Reprod Update* 2011;17(2):159–70. doi:10.1093/humupd/dmq042.
118. VERCELLINI P, FRONTINO G, PISACRETA A, GIORGI O DE, CATTANEO M, CROSIGNANI PG. The pathogenesis of bladder detrusor endometriosis. *Am J Obstet Gynecol* 2002;187(3):538–42.
119. VERCELLINI P, PISACRETA A, PESOLE A, VICENTINI S, STELLATO G, CROSIGNANI PG. Is ureteral endometriosis an asymmetric disease? *BJOG* 2000;107(4):559–61.
120. VIGNALI M, BIANCHI S, CANDIANI M, SPADACCINI G, OGGIONI G, BUSACCA M. Surgical treatment of deep endometriosis and risk of recurrence. *J Minim Invasive Gynecol* 2005;12(6):508–13. doi:10.1016/j.jmig.2005.06.016.
121. VILLA G, MABROUK M, GUERRINI M, MIGNEMI G, MONTANARI G, FABBRI E et al. Relationship between site and size of bladder endometriotic nodules and severity of dysuria. *J Minim Invasive Gynecol* 2007;14(5):628–32. doi:10.1016/j.jmig.2007.04.015.
122. WATANABE Y, OZAWA H, UEMATSU K, KAWASAKI K, NISHI H, KOBASHI Y. Hydronephrosis due to ureteral endometriosis treated by transperitoneal laparoscopic ureterolysis. *Int J Urol* 2004;11(7):560–2. doi:10.1111/j.1442-2042.2004.00828.x.
123. WEINGERTNER AS, RODRIGUEZ B, ZIANE A, GIBON E, THOMA V, OSARIO F et al. The use of JJ stent in the management of deep endometriosis lesion, affecting or potentially affecting the ureter: a review of our practice. *BJOG* 2008;115(9):1159–64. doi:10.1111/j.1471-0528.2008.01795.x.
124. WESTNEY OL, AMUNDSEN CL, MCGUIRE EJ. Bladder endometriosis: conservative management. *J Urol* 2000;163(6):1814–7.
125. WINKEL CA, SCIALLI AR. Medical and surgical therapies for pain associated with endometriosis. *J Womens Health Gen Based Med* 2001;10(2):137–62. doi:10.1089/152460901300039485.
126. YOHANNES P. Ureteral endometriosis. *J Urol* 2003;170(1):20–5. doi:10.1097/01.ju.0000054836.32660.9e.
127. ZIEGLER D DE, GAYET V, AUBRIOT FX, FAUQUE P, STREULI I, WOLF JP et al. Use of oral contraceptives in women with endometriosis before assisted reproduction treatment improves outcomes. *Fertil Steril* 2010;94(7):2796–9. doi:10.1016/j.fertnstert.2010.05.056.

## 5.2

## Diagnosis of Urinary Tract Endometriosis, Counseling and Therapeutic Management

Alexandra Kruse<sup>a</sup> | Ingo Kausch von Schmeling<sup>a</sup>

### 5.2.1 Introduction

Endometriosis, defined as the occurrence of functional endometrial tissue outside the uterus, has been documented in almost every organ system in the body. Because it is estrogen-dependent, it occurs only in women of reproductive age and therefore may recur as long as ovarian function is sustained. Endometriosis most commonly occurs in women 25–35 years of age. Malignant transformation of endometriotic lesions has never been reported. Genitourinary endometriosis is rare, with an overall incidence of 1–5%. One theory on the pathogenesis of urinary endometriosis is based on retrograde menstruation and the implantation of endometrial cells.<sup>8,9</sup> In 70–80% of women with genitourinary endometriosis, the lesions are located in the bladder. Ureteral endometriosis accounts for 15–20% of cases, while renal and urethral involvement has been described only in isolated case reports (Table 5.2).<sup>8,9</sup> Endometriosis of the bladder is usually confined to a single site. The lesions of ureteral endometriosis can be classified as *extrinsic* or *intrinsic*. Intrinsic endometriosis typically involves endometrial glands and stroma within the lamina propria, muscularis, or ureteral lumen. Extrinsic lesions are located in the periureteral tissue.<sup>8</sup> The majority of lesions are extrinsic and located in the distal ureter, with more frequent involvement of the left ureter than the right. Approximately one-fourth of cases are bilateral.<sup>8</sup>

Symptoms of urinary tract endometriosis may include hematuria, frequency, dysuria, urinary tract infection, pelvic and abdominal pain, and possible colicky flank pain. A significant percentage of patients with ureteral endometriosis present no symptoms. Patients with intrinsic endometriosis are more likely to develop symptoms such as colic and hematuria than patients with extrinsic lesions.<sup>8,10</sup> Asymptomatic hydronephrosis with loss of renal function occurs in up to 40% of the patients with ureteral endometriosis.<sup>8,9</sup>

### 5.2.2 Diagnosis of Urinary Tract Endometriosis

#### 5.2.2.1 Imaging Modalities

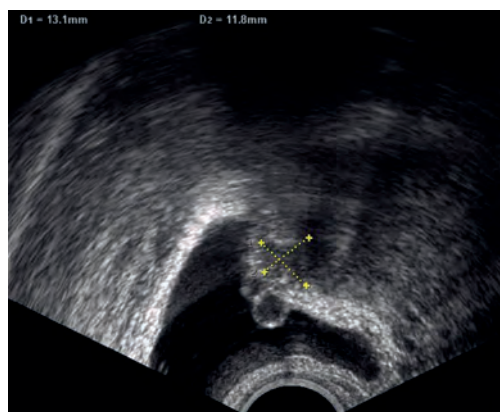
Imaging of the upper urinary tract in patients with pelvic endometriosis is strongly recommended in all cases due to the frequent development of renal obstruction.<sup>1,8</sup>

Ultrasound is the initial imaging modality used to diagnose hydronephrosis and detect possible large masses infiltrating the bladder.<sup>8</sup> Typical ultrasound documentation of bladder endometriosis is illustrated in Fig. 5.5. Intravenous urography (IVU) or retrograde pyelography are useful studies for detecting ureteral endometriosis. Intrinsic lesions appear as filling defects, while extrinsic disease will appear as smooth, strictured ureteral segments caused by extrinsic

**Sites of Involvement by Urinary Tract Endometriosis**

Bladder	70–80%
Ureter	15–20%
Urethra	1–2%
Kidney	up to 4%

**Table 5.2** Sites of involvement by urinary tract endometriosis.



**Fig. 5.5** Ultrasound scan in a patient with bladder endometriosis displays a typical small nodule in the bladder wall.

<sup>a</sup> | Ammerlandklinik Westerstede, Department of Urology and Pediatric Urology, Westerstede, Germany

#### Corresponding authors:

**Alexandra Kruse, Ingo Kausch von Schmeling**

Ammerlandklinik Westerstede

Klinik für Urologie und Kinderurologie

Lange Straße 88, 26655 Westerstede, Germany

E-mail: alexandra.raileanu@ammerland-klinik.de

ingo.kausch@ammerland-klinik.de

compression.<sup>5,6,8,9</sup> Figures 5.6–5.8 illustrate delayed contrast excretion and filling defects noted in two different cases.

CT and MRI can add information by establishing the location and volume of endometriotic lesions and determining the degree of organ infiltration. MRT can be especially useful in diagnosing ureteral endometriosis as well as infiltrating bladder endometriosis due to the distinctive appearance of the lesions on T2- and T1-weighted images.<sup>8,9</sup> Endometriotic lesions typically appear as hypointense areas with hyperintense foci adjacent to the ureter.<sup>6</sup>

The isotope nephrogram is an optional study in patients with hydronephrosis secondary to ureteral endometriosis, providing therapeutically relevant information on renal function and possible urodynamically significant ureteral obstruction.<sup>8</sup> Fig. 5.9 documents renal function impairment on the left side.

#### 5.2.2.2 Endoscopy

The need for endoscopic evaluation will depend upon the patient's symptoms and the extent of disease detected in imaging studies.

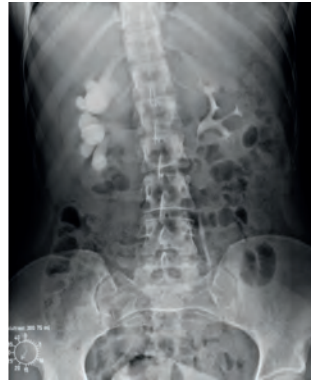Diagnostic cystoscopy is indicated in all patients with pelvic endometriosis who present with urinary tract symptoms and/or hematuria. The procedure should include the biopsy of intravesical masses. Macroscopically, endometriotic lesions have been described as slightly elevated, livid areas with well-defined margins.<sup>4,6,8,9</sup> A typical endometriotic lesion is illustrated in Fig. 5.10. Ureteroscopy should be performed when involvement of the upper urinary tract is suspected and should include the biopsy of any intraluminal foci. The most common site of obstruction is the level where the ureter crosses the infundibulopelvic ligament.<sup>8</sup>

#### 5.2.2.3 Diagnostic Laparoscopy

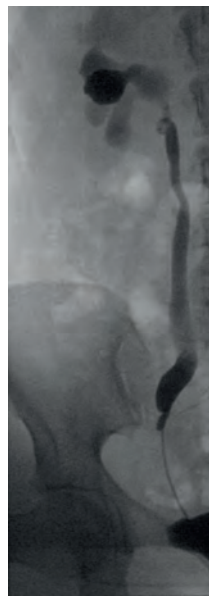
Endometriosis of the bladder most commonly presents as a solitary lesion involving the bladder roof. Invasive bladder disease that may result in full-thickness bladder resection may present as significant scarring and retraction of the bladder peritoneum with underlying nodularity and massive overlying hemorrhagic and exophytic changes. Occasionally a nodule of invasive bladder endometriosis may appear only as a superficial hemorrhagic change, and traction must be placed on the bladder peritoneum to expose the underlying nodule infiltrating the bladder wall.<sup>6</sup> Fig. 5.11 illustrates a laparoscopic resection of bladder endometriosis.

#### 5.2.2.4 Treatment Goals

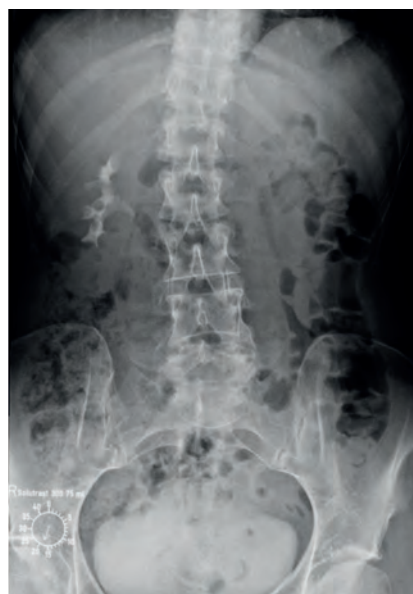- Relief of obstruction.
- Preservation of renal function.
- Complete ablation of endometriotic foci.
- Relief of symptoms.
- Preservation of fertility.



**Fig. 5.6** IU documents delayed contrast excretion in a patient with right ureteral endometriosis.



**Fig. 5.7** Retrograde pyelography shows a distal ureteral stricture resulting from ureteral endometriosis (same patient as in Fig. 5.6).



**Fig. 5.8** IU in ureteral endometriosis with a silent kidney documents absence of contrast excretion on the affected side.



### 5.2.3 Counseling and Alternative Therapeutic Options

Treatment planning is directed by key factors such as patient age, the severity of symptoms, the affected organs and lesion extent, and the desire for future pregnancy.<sup>8</sup>

Suspicious lesions should be resected or coagulated as completely as possible. Once the diagnosis of endometriosis has been confirmed histologically, a course of hormonal therapy has been recommended.<sup>6,8</sup>

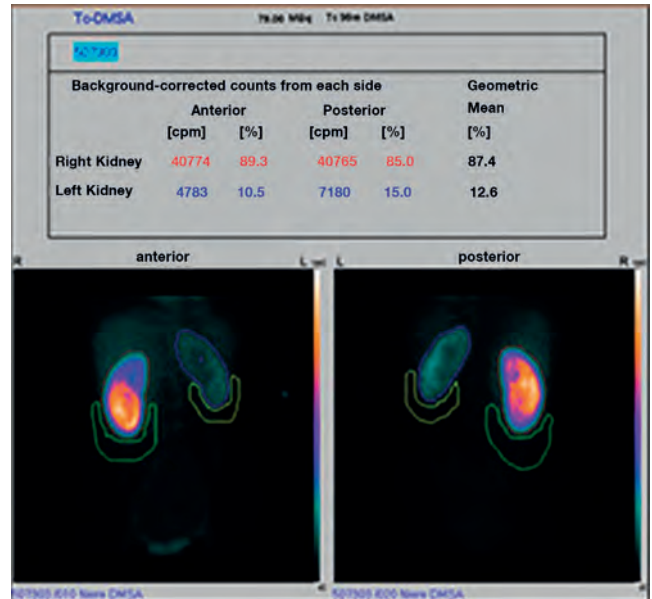
Endometriosis of the bladder is diagnosed by transurethral resection (TUR-B), which can also be done for curative intent in patients with superficial lesions. In cases where lesions infiltrate all layers of the bladder (deep vesical endometriosis), TUR-B alone is insufficient. A high recurrence rate has been reported for lesions treated by transurethral resection.<sup>8</sup> A more effective option is partial cystectomy (open, laparoscopic, or robotic).<sup>2,6,8</sup> Lesions of the bladder wall are approached by dissecting first into normal, soft bladder muscularis adjacent to the lesion. The nodule is circumscribed and undermined by incising normal muscularis, then removed completely in a partial-thickness or full-thickness resection. Partial cystectomy should be preceded by ureteral stenting, especially if the distance between the inferior border of the endometriotic focus and the trigone is less than 2 cm.<sup>8,10</sup> In patients who were treated by partial cystectomy, none required later surgery for bladder recurrence.<sup>2,6,8</sup> For lesions of the bladder floor and posterior wall in close proximity to the uterus, the resection of 0.5–1 cm of opposed myometrium may prevent a recurrence.<sup>10</sup> Superficial endometriosis of the bladder peritoneum is treated by peritoneal resection without dissecting into the muscularis.<sup>6</sup>

Hormonal therapy alone is only an option in patients with minimal hydronephrosis, good renal function, and no urodynamically significant obstruction by radioisotope renal scan. The outcomes are better in cases with extrinsic rather than intrinsic endometriosis.<sup>8</sup>

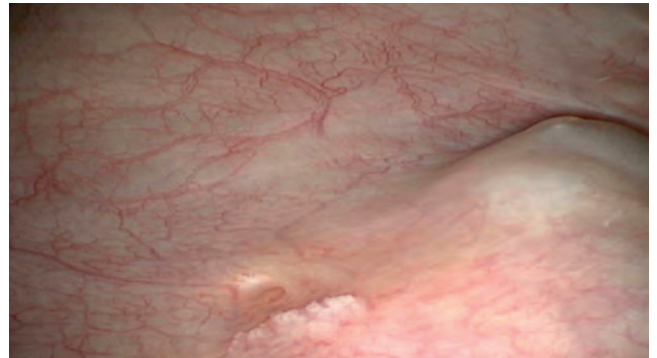
Laser coagulation is technically feasible in selected patients who have small, intrinsic ureteral lesions.<sup>8</sup>

The treatment of first choice in patients with extensive lesions (extrinsic and intrinsic) is surgery. Ureterolysis alone may be sufficient to resolve ureteral obstruction in cases with extrinsic lesions, with documented success rates of 85%.<sup>8</sup> However, of all the surgical treatment options for ureteral endometriosis, ureterolysis is associated with the highest rates of complications and recurrence.<sup>10</sup> Should ureterolysis be undertaken, the preferred approach is laparoscopic transperitoneal, as it allows the assessment of lesions within the peritoneum adjacent to the ureter. Ureteral stenting should be carried out prior to ureterolysis.<sup>8</sup>

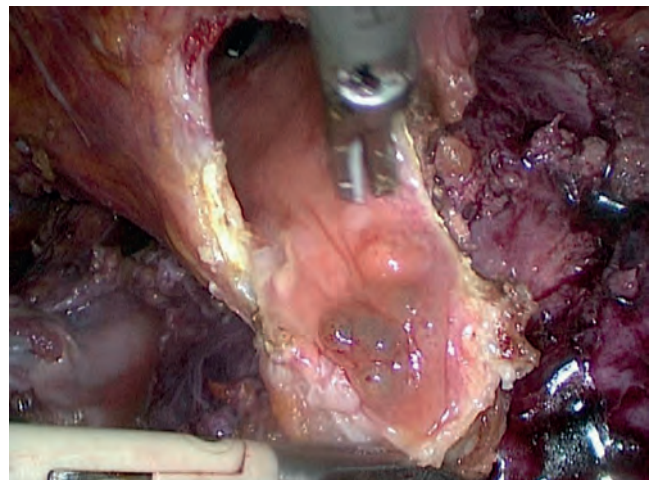
Extrinsic lesions with intraluminal infiltration should be treated by complete resection of the affected ureteral segment with subsequent end-to-end anastomosis or ureteroneocystostomy using the psoas hitch or Boari flap technique.<sup>1,6,8</sup> Cases of bilateral involvement are treated by bilateral segmental ureterectomy and trans-uretero-ureterocystostomy with bladder-to-psoas hitching, since the bladder capacity is usually not large enough for a bilateral



**Fig. 5.9** Radionuclide renal scan in ureteral endometriosis documents almost complete loss of renal function on the left side (same patient as in Fig. 5.8).



**Fig. 5.10** Cystoscopy of bladder endometriosis reveals a lesion medial to the right ureteral orifice. A small area of trigone metaplasia is also noted close to the lesion. By courtesy of Dr. P. Drazic, Dept. of Gynecology and Obstetrics, Ammerland Clinical Center Westerstede, Germany.



**Fig. 5.11** Laparoscopy of bladder endometriosis. A partial, full-thickness laparoscopic bladder resection is performed to encompass the endometriotic lesions. By courtesy of Dr. P. Drazic, Dept. of Gynecology and Obstetrics, Ammerland Clinical Center Westerstede, Germany.

psoas hitch procedure.<sup>1</sup> Depending on the specific center and individual surgeon experience, the above interventions may be performed through an open, laparoscopic, or robot-assisted approach.<sup>8</sup> The most frequent complications are ureteral fistula and anastomotic stricture.

As ureteral obstruction is asymptomatic in a large number of patients, the diagnosis of hydronephrosis may be delayed. Consequently, affected kidneys may show significant function impairment in the radionuclide nephrogram by the time of diagnosis. Nephroureterectomy (open, laparoscopic, or robotic) may be appropriate in such cases.<sup>8</sup>

Posttherapeutic follow-up relies on ultrasonography. The main purpose of follow-up is the early detection of recurrent ureteral obstruction.<sup>1,8</sup> Patients with renal function impairment prior to therapy require the regular monitoring of retention parameters (serum creatinine, glomerular filtration rate) in addition to a radionuclide study 6–12 weeks after the conclusion of therapy.<sup>1,8</sup>

Endometriosis of the kidney is very rare. Only sporadic case reports are found in the literature.<sup>3,7</sup> It may present with flank pain or hematuria not always occurring during menstruation. Some symptomatic cases have been diagnosed by nephrectomy as cystic masses, usually with associated intralesional hemorrhage. Histology identifies glands and stroma characteristic of endometriosis.<sup>6</sup> Needle biopsies of the lesions reveal glandular fragments and cuboidal epithelium typical of endometrial tissue.

### 5.2.4 Summary

Endometriotic lesions of the urinary tract are present in 1 to 5% of women affected by endometriosis. Most patients present with concomitant lesions in other organ systems. Endometrial tissue responds to cyclic hormonal changes. The growing and bleeding stage is accompanied by inflammation, which later leads to fibrosis, with subsequent adhesions leading to stenosis (ureter) and tissue retraction due to scarring (bladder). In 70–80% of cases, urinary tract endometriosis is located in the bladder. Ureteral involvement is noted in 15–20% of cases. Whether this involvement is extrinsic or intrinsic is largely irrelevant in terms of clinical management. Intrinsic endometriosis is known to be a more frequent cause of cyclic flank pain, hematuria, dysuria, and urinary tract infection than extrinsic endometriosis. All patients with pelvic endometriosis should undergo upper tract imaging. The imaging studies appropriate for ureteral endometriosis are intravenous urography or retrograde pyelography, CT or MRI, and radionuclide scanning. The major treatment goals in ureteral endometriosis are preservation of renal function, symptom relief by the complete ablation of endometriotic lesions, and maintenance of fertility. Primary hormonal therapy should be considered only in patients who do not have urodynamically significant obstruction. Ureterolysis alone may be sufficient to resolve ureteral obstruction in patients with extrinsic lesions, with documented success rates of 85%. Lesions of the distal ureter are managed by resection of the stenosed segment and ureteroneocystostomy, while lesions in the middle or proximal third are treated by resection of the stenosed segment and

end-to-end ureteral anastomosis. Bladder endometriosis may require a full-thickness resection of the bladder wall. Transurethral resection alone is frequently inadequate since endometrial tissue is present throughout the detrusor muscle. Ureteral stenting prior to resection is indicated if the lesion is less than 2 cm from the orifice. Renal and urethral endometriosis have been described only in sporadic case reports.

### 5.2.5 References

- ANTONELLI A, SIMEONE C, FREGO E, MININI G, BIANCHI U, CUNICO SC. Surgical treatment of ureteral obstruction from endometriosis: our experience with thirteen cases. *Int Urogynecol J Pelvic Floor Dysfunct* 2004;15(6):407-12; discussion 412. doi:10.1007/s00192-004-1171-7.
- CHAPRON C, BOURRET A, CHOPIN N, DOUSSET B, LECONTE M, AMSELLEM-OUAZANA D et al. Surgery for bladder endometriosis: long-term results and concomitant management of associated posterior deep lesions. *Hum Reprod* 2010;25(4):884–9. doi:10.1093/humrep/deq017.
- HELLBERG D, FORS B, BERGQVIST C. Renal endometriosis treated with a gonadotrophin releasing hormone agonist. Case report. *Br J Obstet Gynaecol* 1991;98(4):406–7.
- HYLER DS, BALUCH JD, TAYLOR RR. Intramural vesical endometriosis. A case report. *J Reprod Med* 1994;39(10):832–4.
- LUCERO SP, WISE HA, KIRSH G, DEVOE K, HESS ML, KANDAWALLA N et al. Ureteric obstruction secondary to endometriosis. Report of three cases with a review of the literature. *Br J Urol* 1988;61(3):201–4.
- REDWINE D, HOPTON L. Endometriosis of the Urinary Tract: Symptoms, Diagnosis and Treatment; Available from: <http://endopaedia.info/subtype10.html>.
- ROUSSELOT F, LIARD-MEILLON ME. Renal endometriosis. Report of a case [Article in French]. *Prog Urol* 1996;6(6):936–9.
- SINGH I, STRANDHOY J, ASSIMOS D. Pathophysiology of urinary tract obstruction: Benign Pelvic Abnormalities: Endometriosis. In: Wein AJ, Kavoussi LR, Novick AC, Partin AW, Peters CA, editors. *Campbell-Walsh Urology*, 10th ed. Philadelphia: Saunders Elsevier; 2012. p. 1114–6. (ISBN No. 9781416069119).
- THÜROFF JW. Urologische Komplikationen gynäkologischer Erkrankungen: Endometriose. In: Miller K, Jocham D, editors. *Praxis der Urologie*, 3rd ed. Stuttgart: THIEME; 2007. (ISBN No. 9783131260031).
- YARMOHAMADI A, MOGHARABIAN N. Urinary Tract Endometriosis. *Endometriosis - Basic Concepts and Current Research Trends* 2012; Available from: [www.intechopen.com/download/pdf/36752](http://www.intechopen.com/download/pdf/36752).

## 5.3

## Ureteral Endometriosis

Alberto Vázquez Rodríguez<sup>a</sup> | Boris Gabriel<sup>b</sup> | Brice Rodríguez<sup>c</sup> | Cristina Redondo Guisasola<sup>d</sup> | Arnaud Wattiez<sup>e</sup>

### 5.3.1 Introduction

Endometriosis is the most common pelvic gynecologic disorder<sup>7</sup> and is mainly seen in young women with pelvic pain or infertility. Furthermore, endometriosis is both an enigmatic and complex disease. The virtually unknown etiopathogenesis, the great variety of symptoms and pathological findings, the lack of consensus among experts concerning the definition and treatment of the disease, as well as the absence of prospective and randomized studies, all these issues account for the fact that management of endometriosis poses a real challenge for any gynecologist. When it comes to ureteral endometriosis (UE), the challenge is maximum (Fig. 5.12). The primary objectives of endometriosis treatment, which mainly include surgical treatment options, are summarized as follows:

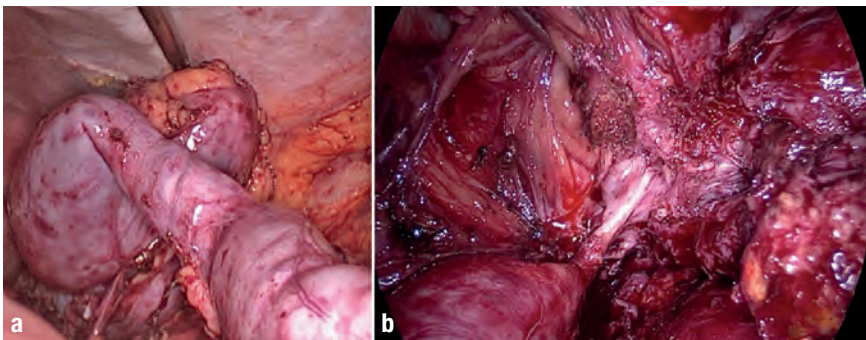
- Improvement of quality of life, i.e., pain relief and preservation of functional integrity;
- Enhancement of fertility status;
- Prevention of recurrence.

However, even in the most experienced hands, these goals are difficult to achieve due to controversy about the nature of disease and the risk of severe complications that may arise after surgical treatment, which is particularly true for ureteral endometriosis. For that reason, treatment should be tailored to each patient as determined by clinical presentation, personal expectations and the potential risks of surgical treatment, which must be carefully addressed in the informed consent discussion with the patient.

### 5.3.2 Definition and Prevalence

The presence of endometrial glands and/or stroma in or around the ureter can be regarded as the least-common-denominator definition of ureteral endometriosis. Nevertheless, UE can involve any situation where endometriosis or fibrosis surrounding endometriotic foci causes compression or distortion of the normal ureteral anatomy (Fig. 5.12b)<sup>8,17</sup>

Ureteral endometriosis is a rare condition, but occurs more frequently than assumed in patients with severe endometriosis.



**Fig. 5.12a,b** Dilated ureter and hydronephrosis (a). (By courtesy of Dr. Filipa Osório, Lisbon, Portugal). Dilated ureter with stricture (b). (By courtesy of Dr. Filipa Osório, Lisbon, Portugal).

- <sup>a</sup> MD, Gynecologist; Reproductive Endoscopic Surgery, Assisted Reproduction Clinics, Barcelona and Madrid, Spain
- <sup>b</sup> Professor, MD; Head of Department of Obstetrics and Gynecology, St. Josef's Hospital, Wiesbaden, Germany
- <sup>c</sup> Consultant, Obstetrics and Gynecology; Lancashire Teaching Hospital, Lancashire, United Kingdom
- <sup>d</sup> Gynecologist, Endometriosis Surgery; Ob/Gyn Department, University Hospital Fundación Jiménez Díaz, Madrid, Spain
- <sup>e</sup> MD; Head of Gynecology Department, Latifa Hospital, Dubai, United Arab Emirates; Director of Advanced Courses in Gynecological Endoscopy at IRCAD/ EITS, Strasbourg, France

#### Corresponding author:

#### Alberto Vázquez Rodríguez

Gynecologist, Reproductive Endoscopic Surgery  
 IVI Barcelona: Ronda General Mitre 14, 08017 Barcelona, Spain  
 IVI Madrid: Avenida del Talgo 68, 28023 Madrid, Spain  
 E-mail: alberto.vazquez@ivi.es

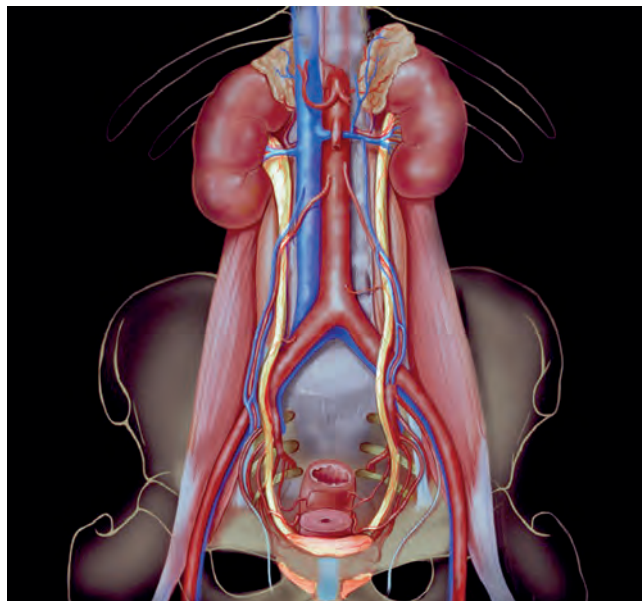
UE is now increasingly detected, thanks to greater clinicians' awareness and improved diagnostic tools. The prevalence of UE reported in the literature is less than 1% in patients with endometriosis,<sup>16,45,61</sup> however in severe endometriosis its prevalence may rise up to 20%.<sup>21</sup> The diagnostic inclusion of periureteral endometriosis-associated fibrosis may help to explain the significant variability in prevalence rates for UE. A new consensus about the histological definition of deep infiltrating endometriosis is needed to clarify these findings.



### 5.3.3 Pathological Findings and Location

The predilection sites for urinary tract endometriosis (UTE) are bladder (84%), ureter (10%), kidney (4%) and urethra (2%)<sup>1,32</sup> (Fig. 5.13). UE is usually associated with endometriosis elsewhere in the pelvis,<sup>13</sup> mainly with ipsilateral endometrioma,<sup>62</sup> ipsilateral uterosacral ligament<sup>42</sup> and with the presence of a recto-vaginal nodule larger than 3 cm.<sup>17,31</sup> Isolated ureteral endometriosis is of rare occurrence.<sup>58</sup> Patients with UTE have more advanced stages of disease.<sup>1</sup> Patients with ureteral or bladder endometriosis are more frequently diagnosed with rAFS stage III or IV than patients without UTE.<sup>30</sup>

Ureteral endometriosis is commonly confined to the distal ureteral segment (pelvic ureter), 3–4 cm above the vesico-ureteric junction where the ureter crosses the uterine artery.<sup>37,43,49</sup> Unilateral involvement is observed in approximately 80–90% of cases, with a predilection on the left side.<sup>21,27,39,55,62,64</sup> The menstrual reflux theory and the anatomical differences between the left and right hemipelvis may explain this asymmetry in the occurrence of UE.<sup>26,62,68</sup> In the left hemipelvis, the rectosigmoid represents an anatomical shelter that prevents endometriosis cells from being cleared by the peritoneal circulation and macrophages. However, the large bowel does not provide the right hemipelvis with this sort of anatomical shelter because the cecum is more cranial.<sup>62,68</sup> Ureteral endometriosis is usually divided into two groups according to the depth to which endometriosis has infiltrated the ureteral wall: extrinsic and intrinsic ureteral endometriosis. Differentiation between these pathological entities cannot be made preoperatively or at surgery since an histological examination is required. In extrinsic UE, which is the most common type (80%), endometrial tissue only invades the adventitia or surrounding connective tissue, and thus leads to compression of the ureter and secondary ureteral obstruction.<sup>15,57,67</sup> In case of intrinsic disease, ectopic endometrial tissue has infiltrated the muscularis or even the



**Fig. 5.13** Schematic anatomical representation of the urinary tract. (Drawing by Catherine Mennier-Cers, medical illustrator at IRCAD, Strasbourg, France; modified by Rodrigo Fernandes, São Paulo, Brazil)

mucosa. Hematogenic and lymphogenic spread have been proposed to explain the pathogenesis of intrinsic UE.<sup>9,20</sup>

### 5.3.4 Diagnosis

Preoperative diagnosis of UE is challenging and requires great vigilance. To investigate the presence of ureteral involvement, a large variety of diagnostic modalities have been proposed.<sup>28,67</sup> Nevertheless, UE can be confirmed only by laparoscopic inspection in conjunction with histological confirmation of periureteral endometriotic lesions.<sup>8</sup> As UE often remains undetected preoperatively, additional criteria may be helpful in the preoperative assessment.

#### 5.3.4.1 Symptoms

Ureteral endometriosis is prevalent in women diagnosed with severe disease. Only 9% to 16% of the patients with UE present urinary symptoms.<sup>19,60</sup> On the other hand, the majority of patients suffering from bladder endometriosis are symptomatic with dysuria, hematuria and recurrent urinary tract infection.<sup>21</sup> It seems that ureteral and bladder endometriosis are two different entities. Patients with UE usually complain about nonspecific symptoms such as dysmenorrhea, dyspareunia and chronic pelvic pain,<sup>21,30</sup> which is why it is difficult to make a tentative clinical diagnosis of ureteric involvement prior to surgery, thus leading to a diagnostic delay.<sup>54,67</sup> This can aggravate the patient's condition and contributes to significant morbidity such as silent loss of renal function.<sup>14,23,33</sup>

Because of the absence of specific urinary symptoms and the risk of silent loss of the affected kidney, assessment of integrity of the ureter is highly recommended in patients with severe endometriosis.

#### 5.3.4.2 Diagnostic Modalities

##### ■ Physical Exam

If a large endometriotic nodule is revealed during a physical exam of the rectovaginal septum, this finding may indicate to ureteral involvement.<sup>17,31</sup>

##### ■ Blood Tests

Patients should be assessed for anemia and renal function by hemoglobin and creatinine measurements.

##### ■ Urine Exams

The urine must be evaluated for evidence of hematuria and should be cultured to exclude urinary infection.

##### ■ Imaging Techniques

The diagnostic value of these techniques in providing accurate information on the extent of disease and on the infiltration of the ureteral wall is limited and there seems to be no clear evidence as to which is the ideal diagnostic imaging modality to be used.<sup>11</sup>

**Ultrasonography (US)** is used in the initial diagnostic workup as a screening tool to rule out urinary tract obstruction in patients with pelvic endometriosis. The exam is both simple and minimally invasive while offering the advantage of being highly sensitive for detection of hydronephrosis. However,

unless the ureter is dilated, it is difficult to visualize the ureteral pathway. In clinical practice, patients should undergo periodic kidney ultrasound (at 6-month intervals from the time of initial diagnosis) because this modality is generally suggested to identify early changes in the upper urinary system and thus helps prevent further deterioration of renal function.<sup>39,45</sup>

**Intravenous pyelography (IVP)** has been the functional imaging modality most commonly used to evaluate patients suspected of having ureteral endometriosis. The technique has shown to be helpful in pinpointing the location of disease, the extent and degree of ureteral stenosis as well as in yielding specific information about renal function. Despite inherent limitations, intravenous pyelography, coupled with retrograde pyelography, is currently the exam most frequently used to assess intrinsic UE.

**Renal scintigraphy** is used to determine the degree of residual kidney function and it is indicated only in cases where severe ureteral obstruction is confirmed.

**Magnetic resonance imaging (MRI)** is the best imaging modality for ureteral evaluation<sup>11</sup>. Especially useful in detecting hydroureteronephrosis are the sequences known as MR urography. Nowadays, MRI represents the ideal 'all-in-one' diagnostic modality for urinary tract endometriosis because it provides visualization of all components of the urinary system and affords a more comprehensive evaluation of the complete pelvis.

**Computed tomography** and **ureteroscopy** are currently considered to be of limited value for the diagnosis of UE.

### 5.3.5 Treatment Options

The therapeutic management of endometriosis is determined by the age of the patient, her individual preferences (desire for fertility preservation, pain relief), severity of symptoms, as well as by the extent and location of disease. The treatment of UE should be tailored to the patient's specific clinical condition in order to relieve ureteral obstruction, preserve renal function and to prevent recurrence of disease while minimizing the morbidity associated with surgery.<sup>41</sup>

**Medical treatment** is geared toward modulating the endometrial tissue response to hormonal stimulation. Gonadotropin-releasing hormone (GnRH) agonist and antagonist, progestins and combined oral contraceptives are the most common medical therapies used in the treatment of endometriosis. These drugs may be effective in relieving dysmenorrhea, dyspareunia and pelvic pain, but the symptoms often recur when treatment is stopped.<sup>18</sup> For that reason, medical management is considered a palliative modality for the treatment of deep endometriosis. Moreover, medical therapies do not improve the patient's fertility status and are usually associated with suboptimal compliance and safety issues. Probably, the ideal candidates for medical treatment are postmenopausal women.

Ureteral lesions rarely respond to medical treatment.<sup>6,23,35,46,63</sup> Accordingly, the authors hold the opinion that patients with ureteral involvement should receive surgical treatment.

#### 5.3.5.1 Surgical Treatment

Surgical treatment remains the gold standard for deep endometriosis. Historically, open surgery has been the first-line surgical approach for extensive endometriosis.<sup>18</sup> However, recent studies have shown that laparoscopic treatment of UE is feasible with good results.<sup>3,12,41,52,66</sup> Despite the unique characteristics of endoscopy – that provides the surgeon with a magnified view, enhanced exposure of the surgical site and improved options to develop the retroperitoneal space – there is still controversy among experts as to whether laparoscopic excision of ureteral lesions should be undertaken.<sup>12,23,41,66</sup> Ureterolysis is mostly carried out by laparoscopy, but in cases of ureteral resection with end-to-end anastomosis, and particularly in cases with ureteroneocystostomy, most of the patients are nonetheless treated by laparotomy. Anyway, the inherent complexity of surgical treatment requires that it be performed only in specialized centers by a team of experts and adequately skilled surgeons who are familiar with endometriosis and its management.

#### ■ Preoperative Management

Preoperative planning in the treatment of UE is the same as in other cases of severe endometriosis. A low-residue diet prescribed 3–5 days before surgery should be enough to facilitate perioperative mobilization of the bowel and adequate exposure.<sup>34</sup> Rectal enema is used the night before surgery. The use of a double-J stent before surgery is still controversial.<sup>4,38,66</sup>

A double-J stent should be placed intraoperatively in the following situations:

- if ureteral resection is deemed necessary,
- in the event of an iatrogenic lesion inflicted on the ureter,
- if an endometriotic lesion on the bladder is located near the trigone,
- and if there are any doubts arising during surgery as to the integrity of the ureter.

It is important to take into account that a double-J stent adds rigidity to the ureter and may interfere with dissection while concurrently increasing the risk of iatrogenic injury.

#### ■ Surgical Procedure

Before establishing a diagnosis of ureteral involvement and prior to defining a surgical technique that is accurately tailored to the needs of each individual case of UE, a few essentials and ergonomic principles common to all surgeries for deep endometriosis should be observed.<sup>65</sup> The patient is placed in a lithotomy position with both arms tucked to the side and the coccyx placed at the edge of the table. The legs should assume a semi-flexed position to give the assistant optimal access to the vagina and rectum, and to avoid compression of blood vessels and nerves. In some cases, endometriosis surgery can take longer than planned, which is why proper patient positioning is a crucial part of the surgical procedure and can help to prevent undue complications.

Laparoscopy is performed under general anesthesia. Once the patient is asleep, a careful rectovaginal exam should be undertaken in a systematic manner in order to

reevaluate endometriotic lesions. Bladder catheter and uterine manipulator must be inserted to facilitate the surgical procedure. Subsequently, the laparoscope is introduced at the level of the umbilicus and three 5-mm trocars are inserted under direct vision, two at the level of the iliac fossa and one midline trocar at the level of the lateral ports, or slightly higher to obtain an ergonomic configuration. Once the scope is inside the abdominal cavity, a careful inspection of the whole cavity is mandatory to determine the severity of the disease and to establish an adequate surgical strategy.

Adequate exposure of the operative site is mandatory when dealing with severe endometriosis. The surgery begins by trying to restore the normal pelvic anatomy. For that purpose, adhesiolysis is subsequently performed starting at the physiological attachments of the sigmoid. This maneuver should give access to the left ureter. Adhesiolysis is then continued by taking down adhesions spanning from the ovary to the ovarian fossa. In the presence of ovarian cysts, they are opened and drained and finally both ovaries are suspended to the abdominal wall. Suspension has been found to improve exposure of the surgical field and frees the hand of the assistant who then is at the disposal of the surgeon. As ovarian cystectomy is probably the easiest part of the surgical procedure, it is carried out at the end of the operation. Nevertheless, great care should be taken during this operative stage to prevent any iatrogenic injury to the ovary, especially in patients with gestational desire.

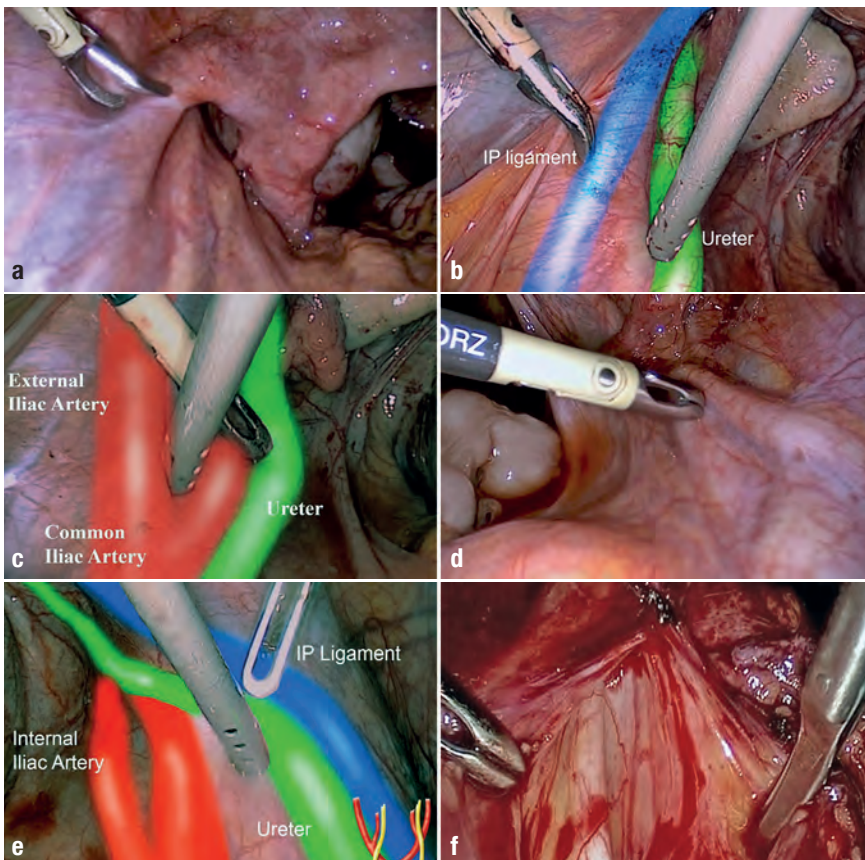
At this significant point of the procedure, both ureters must be identified before starting dissection. The left ureter crosses the left common iliac artery and the right one crosses the right external iliac artery (Figs. 5.14a–e). Both ureters are located medially to the infundibulopelvic (IP) ligament. It is recommended that dissection of the ureter be initiated at the level of the IP ligament (Fig. 5.14f).

Medially to the ureter, access to the pararectal fossa is obtained allowing dissection to be carried down to the pelvic floor. In this manner, the ureter is lateralized thereby adding safety to the procedure. Once the anatomy has been adequately restored and both ureters have been identified, the surgical technique deemed to be most appropriate for treating the patient's specific state of disease can be applied.

During the surgical procedure, grasping bipolar forceps, employed also for dissection, and scissors are the laparoscopic instruments most commonly used.

#### ■ Surgical Techniques and Indications

There is still some controversy in the literature regarding the various techniques that have been proposed for the surgical treatment of UE. As ureteral endometriosis is a rare entity, prospective randomized studies – needed for comparison and evaluation of the various surgical treatment options – are not available to date and may be difficult to conduct in the future. The primary technique to be adopted is determined by



**Fig. 5.14a–f** Left ureter (a).<sup>\*</sup> Left ureter is found medially to the IP ligament (b).<sup>\*\*</sup> Left ureter crosses left common iliac artery (c).<sup>\*\*</sup> Right ureter (d). Right ureter crosses the right external iliac artery (e).<sup>\*\*</sup> Left ureter dissection (f).

<sup>\*</sup> Figs. 5.15–5.19 by courtesy of Prof. Arnaud Wattiez, IRCAD, Strasbourg, France.

<sup>\*\*</sup> Details of anatomy highlighted by Rodrigo Fernandes, São Paulo, Brazil.



the location and depth of the lesion. The authors suggest to subdivide the anticipated technique in two groups:

- *conservative techniques* that include ureterolysis (exposure of the ureter) and nodule removal with partial thickness resection of the adventitia, and
- *more radical techniques* that include segmental resection of the ureter and posterior ureteral reconstruction with end-to-end anastomosis or ureteroneocystostomy. In cases of complete functional loss nephrectomy may be indicated.<sup>57</sup>

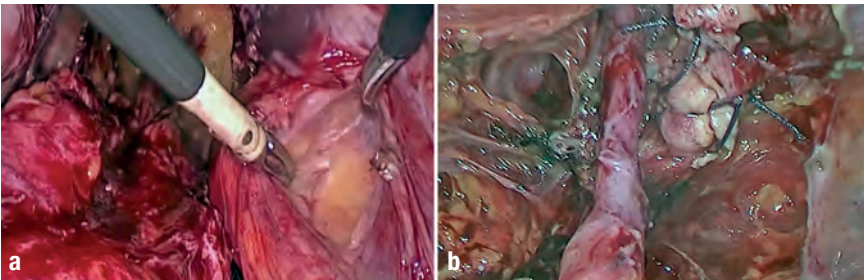
A conservative surgical technique for UE is usually safe and effective.<sup>12,36,58</sup> A more radical approach should be adopted as the treatment of first choice in cases when conservative surgery fails to reestablish the patency of the lumen and to correct the distorted course of the ureter.

Ureterolysis is effective in most cases of UE even in the presence of hydronephrosis. The technique of ureterolysis is used as a first-line therapeutic option in the treatment of extrinsic, nonobstructive disease with surrounding fibrosis<sup>8,10,17,60</sup> (Fig. 5.15a). The level of difficulty associated with the anticipated surgical procedure depends on the location, size and depth of infiltration of the ureteral lesion and degree of traction caused by fibrosis. Peri-ureteral fibrosis produces retraction and distortion, mainly in the lower third of the ureter, changing its normal lateral course in a medial direction. Ureterolysis should be carried out starting from healthy tissue at the level of the pelvic brim. Once the ureter has been identified, blunt dissection is performed as usual, proceeding caudally to the uterosacral ligament, up to the ureteric canal. The uterine artery may be coagulated if needed to facilitate

dissection. Ureterolysis is considered to be complete when the ureter has been freed from fibrotic tissue and when a normal-looking ureter is visible proximally and distally to the stricture. During dissection, ureteral devascularization must be avoided, trying not to harm the ureteral adventitia. If, after ureterolysis, the affected segment still looks stenotic or if severe devascularization is still noticeable (wall discoloration, absence of capillary refill, or lack of a bleeding edge)<sup>50</sup> (Fig. 5.15b), it is recommended to insert a double-J stent in order to decrease the risk of ureteral fistula formation. If persistent stenosis inhibits the passage of a stent, a more radical approach is indicated. In cases of iatrogenic ureteral injury occurring during dissection, insertion of a double-J stent is also indicated. To solve the problem, a simple suture or a non-conservative technique can be applied. The main limitation of ureterolysis is the risk of recurrent disease as a result of incomplete surgery with persistence of endometrial tissue.

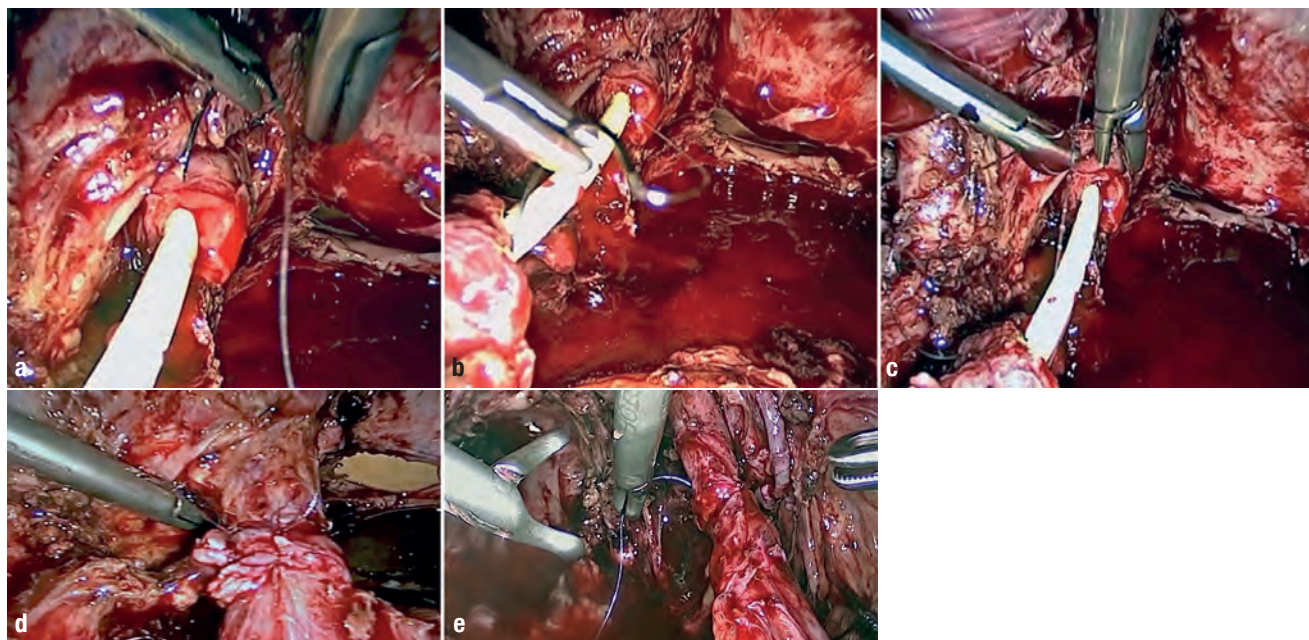
In some cases of ureteral nodule removal, a partial breach of the ureteral wall may occur and the defect must be repaired with a 4-0 suture. The insertion of a double-J stent is also recommended in these cases.

A radical surgical approach for UE may comprise ureteral segmental resection. The main indications for this approach are intrinsic UE and failure of conservative surgery. Ureteral resection requires ureteral reconstruction with end-to-end anastomosis or ureteroneocystostomy, as determined by the location of the endometriotic lesion as well as the length of the resected ureteral segment and remaining ureter. To facilitate reconstruction, a double-J stent must be inserted.



**Fig. 5.15a,b** Ureterolysis of the right ureter (a). Devascularization of the ureter (b).

Ureteral resection with end-to-end anastomosis is a radical technique most probably applied by the majority of gynecologists. The ureter is transected obliquely with cold scissors to excise the obstructed segment. The anastomosis is performed over the ureteral stent by placing four interrupted 4-0 stitches at 3, 6, 9 and 12 o'clock to approximate the proximal and distal ureteral segments using an intracorporeal knotting technique. The ureteral stent helps the surgeon to identify the two ends of the ureter and adds some rigidity to the tissues. The latter has shown to be useful in adjusting the depth of the suture (Figs. 5.16a–e).



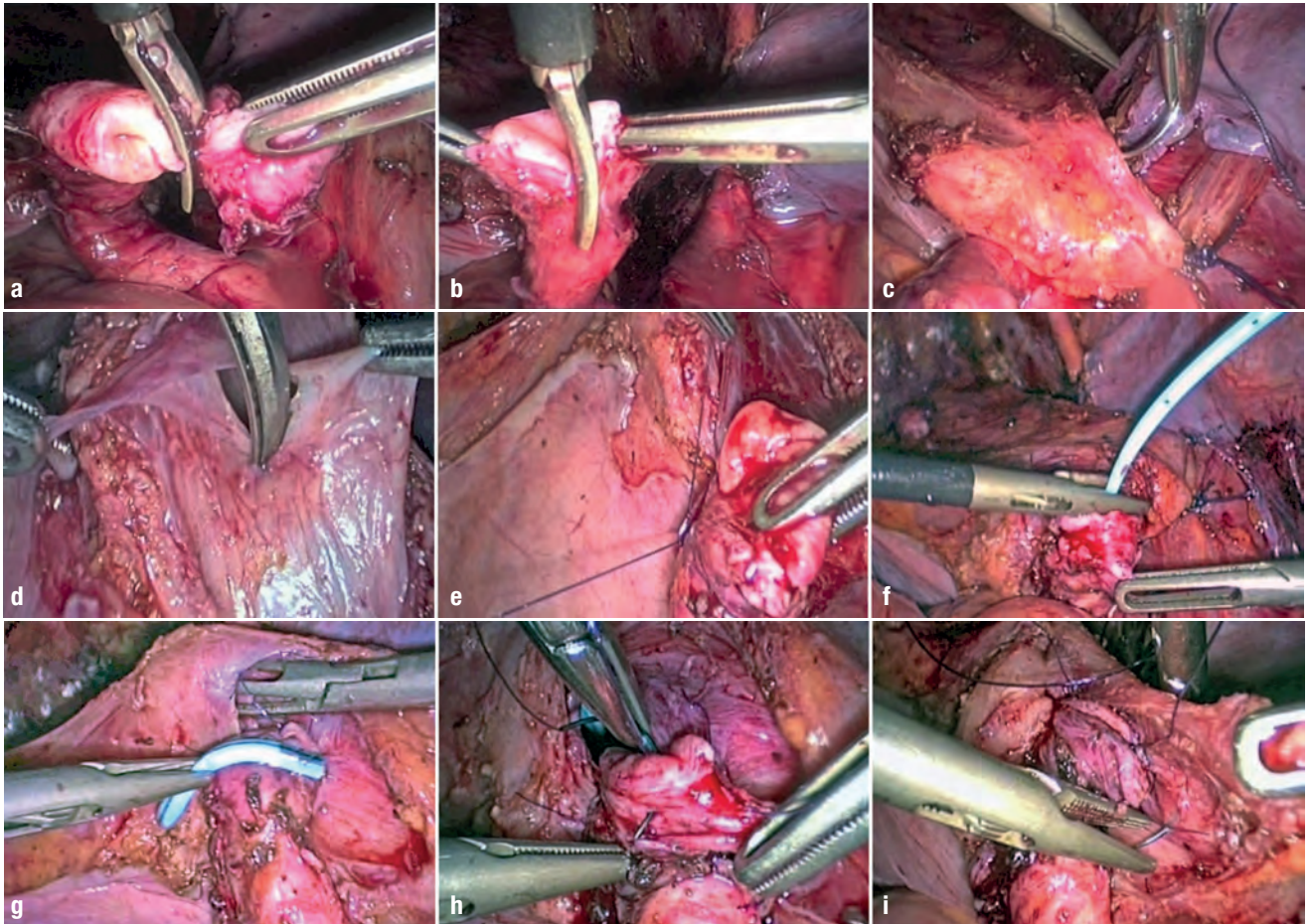
**Fig. 5.16a–e** Suturing of the distal part of the ureter for ureteral end-to-end anastomosis (a). Suturing of the proximal part of the ureter for ureteral end-to-end anastomosis (b). Intracorporeal knotting technique employed for ureteral end-to-end anastomosis (c). Ureteral end-to-end anastomosis. Final result (d). Suturing for right ureteral end-to-end anastomosis, with the needle holder controlled by the right hand (e).



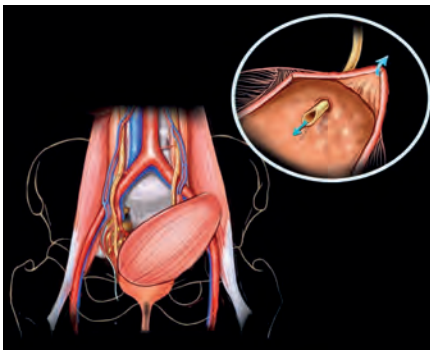
Ureteral resection with ureteroneocystostomy (ureteral reimplantation) can be carried out when the lesion is located near the ureterovesical junction or when a large segment in this area is involved by the disease. This technique is commonly used by urologists and, in most cases, a laparotomy approach is still used for this purpose.<sup>21</sup> In cases where the length of the ureter is found to be insufficient, a vesico-psoas hitch suspension can be carried out to assure a tension-free anastomosis (Figs. 5.17a–i, 5.18). Many other techniques have been described.<sup>2,40,47,56,59</sup> It remains to be established which technique is most effective in terms of endometriosis recurrence and functional results. The

major predictive factors contributing to the outcome of surgical treatment still remain the skills of the surgeon and the level of difficulty associated with the case itself.<sup>44</sup>

In cases where loss of renal function is encountered despite the use of the above surgical techniques, nephrectomy may become necessary. However, evaluation of renal function is always required before going ahead with the planned surgical procedure. Care must be taken in the diagnostic assessment, because sometimes the lesion can mimic an urothelial carcinoma.<sup>29,67</sup>



**Fig. 5.17a–i** Ureteral resection for ureteral reimplantation (a). Preparation of ureter for reimplantation (b). Fixation of bladder in psoas muscle (c). Bladder opening for reimplantation (d). Reference stitch in the posterior part of the ureter (e). Introduction of double-J stent into the ureter (f). Introduction of double-J stent into the bladder (g). The ureter is sutured to the bladder (h). Antireflux technique (i).



**Fig. 5.18** Schematic drawing illustrating the psoas hitch technique. (Drawing by *Catherine Mennier-Cers*, medical illustrator at IRCAD, Strasbourg, France; modified by *Rodrigo Fernandes*, São Paulo, Brazil)



### ■ Postoperative Management

The specific protocol to be employed for postoperative management of ureteral endometriosis should include the use of a double-J stent and a bladder catheter. The double-J stent should be left in place for at least 6 weeks. If the bladder wall needs to be incised, the catheter should be left in place for at least one week. Before retrieving the bladder catheter, the patient should be instructed to take part in re-educational exercises, and a cystography should be performed to assess the integrity of the anastomosis.

### ■ Results and Complications

Surgical treatment for UE has been found to be effective in relieving pain symptoms, both urinary and non-specific ones, and in restoring renal function, however long-term follow up is required to check for potential recurrence of disease after this highly demanding type of surgery that is often associated with complications, even in the most experienced hands.<sup>42,57</sup>

The most frequent perioperative complication is ureteral injury, with a rate of approximately 0.2–2%.<sup>25,51,67</sup> Provided the injury is detected intra-operatively, a simple suture can be placed to solve the problem. Nevertheless, about 70% of ureteral injuries are diagnosed postoperatively, mainly due to fistula formation (uretero-vaginal and vesicovaginal). Among the risk factors contributing to these major complications are diathermy-related injuries, ischemia as a potential sequela of surgery and the endometriotic involvement of other pelvic structures like bowel, vagina and bladder. Unfortunately, in more than two thirds of cases, conversion to laparotomy is the first-line option in the management of these severe complications.<sup>5,24,25,48,51,53</sup> If, after radical surgery, voiding dysfunction or even urinary retention persists, intermittent self-catheterization can become necessary.<sup>22</sup> It is important to stress that patience, both from the patient and the doctor, is necessary until urinary function has been restored.

A close collaboration between gynecologist and urologist is advisable, particularly in specialized centers. This has proven useful to avoid complications and to make sure that viable and proven measures are taken, if required.

### 5.3.6 Conclusions

Ureteral endometriosis is an uncommon condition that is often asymptomatic, but should always be reckoned with in patients with deep infiltrating endometriosis (DIE), especially in the presence of rectovaginal involvement. Surgical treatment is the therapeutic modality of choice in the management of DIE, and a laparoscopic approach is considered feasible and appears to be safe. Nevertheless, explicit attention must be paid to the fact that complications can occur, even in experienced teams dealing with severe endometriosis on a daily basis. The surgical technique must be chosen according to the type of UE, the size and location of the lesions as well as the distance to the ureteral orifices. Further scientific research is necessary to compare the pros and cons of various surgical approaches and to enable the operating surgeon to define a treatment strategy that is tailored to the condition and needs of each patient.

### 5.3.7 References

1. ABRAO MS, DIAS JA JR, BELLELIS P, PODGAEC S, BAUTZER CR, GROMATSKY C. Endometriosis of the ureter and bladder are not associated diseases. *Fertil Steril* 2009;91(5):1662–7. doi:10.1016/j.fertnstert.2008.02.143.
2. AHN M, LOUGHLIN KR. Psoas hitch ureteral reimplantation in adults – analysis of a modified technique and timing of repair. *Urology* 2001;58(2):184–7.
3. ANTONELLI A, SIMEONE C, ZANI D, SACCONI T, MININI G, CANOSSI E et al. Clinical aspects and surgical treatment of urinary tract endometriosis: our experience with 31 cases. *Eur Urol* 2006;49(6):1093–7; discussion 1097–8. doi:10.1016/j.eururo.2006.03.037.
4. ASSIMOS DG, PATTERSON LC, TAYLOR CL. Changing incidence and etiology of iatrogenic ureteral injuries. *J Urol* 1994;152(6 Pt 2):2240–6.
5. ASSIMOS DG, PATTERSON LC, TAYLOR CL. Changing incidence and etiology of iatrogenic ureteral injuries. *J Urol* 1994;152(6 Pt 2):2240–6.
6. BOHRER J, CHEN CCG, FALCONE T. Persistent bilateral ureteral obstruction secondary to endometriosis despite treatment with an aromatase inhibitor. *Fertil Steril* 2008;90(5):2004.e7–9. doi:10.1016/j.fertnstert.2008.03.040.
7. BOLOGNA RA, WHITMORE KE. Genitourinary endometriosis. *AUA Update Series* 1999(4):26–31.
8. BOSEV D, NICOLL LM, BHAGAN L, LEMYRE M, PAYNE CK, GILL H et al. Laparoscopic management of ureteral endometriosis: the Stanford University hospital experience with 96 consecutive cases. *J Urol* 2009;182(6):2748–52. doi:10.1016/j.juro.2009.08.019.
9. BULKLEY GJ, CARROW LA, ESTENSEN RD. Endometriosis of the ureter. *J Urol* 1965;93:139–43.
10. CAMANNI M, BONINO L, DELPIANO EM, BERCHIALLA P, MIGLIARETTI G, REVELLI A et al. Laparoscopic conservative management of ureteral endometriosis: a survey of eighty patients submitted to ureterolysis. *Reprod Biol Endocrinol* 2009;7:109. doi:10.1186/1477-7827-7-109.
11. CHAMIE LP, BLASBALG R, PEREIRA RMA, WARMBRAND G, SERAFINI PC. Findings of pelvic endometriosis at transvaginal US, MR imaging, and laparoscopy. *Radiographics* 2011;31(4):E77–100. doi:10.1148/rg.314105193.
12. CHAPRON C, CHIODO I, LECONTE M, AMSELLEM-OUAZANA D, CHOPIN N, BORGHESE B et al. Severe ureteral endometriosis: the intrinsic type is not so rare after complete surgical exeresis of deep endometriotic lesions. *Fertil Steril* 2010;93(7):2115–20. doi:10.1016/j.fertnstert.2009.01.102.
13. CLEMENT PB. Endometriosis, lesions of the secondary Mullerian system, and pelvic mesothelial proliferations. In: Blaustein A, Kurman RJ, editors. *Blaustein's pathology of the female genital tract*, 3rd ed. New York: Springer; 1989. p. 516–59.
14. COLLINET P, MARCELLI F, VILLERS A, REGIS C, LUCOT J, COSSON M et al. Management of endometriosis of the urinary tract. *Gynecol Obstet Fertil* 2006;34(4):347–52. doi:10.1016/j.gyobfe.2006.02.014.
15. COMITER CV. Endometriosis of the urinary tract. *Urol Clin North Am* 2002;29(3):625–35.
16. DOLNEZ J, BROSENS I. Definition of ureteral endometriosis? *Fertil Steril* 1997;68(1):178–80.
17. DOLNEZ J, NISOLLE M, SQUIFFLET J. Ureteral endometriosis: a complication of rectovaginal endometriotic (adenomyotic) nodules. *Fertil Steril* 2002;77(1):32–7.

18. DOUGLAS C, ROTIMI O. Extragenital endometriosis – a clinicopathological review of a Glasgow hospital experience with case illustrations. *J Obstet Gynaecol* 2004;24(7):804–8. doi:10.1080/01443610400009568.
19. FRENNA V, SANTOS L, OHANA E, BAILEY C, WATTIEZ A. Laparoscopic management of ureteral endometriosis: our experience. *J Minim Invasive Gynecol* 2007;14(2):169–71. doi:10.1016/j.jmig.2006.09.009.
20. FUJITA K. Endometriosis of the ureter. *J Urol* 1976;116(5):664.
21. GABRIEL B, NASSIF J, TROMPOUKIS P, BARATA S, WATTIEZ A. Prevalence and management of urinary tract endometriosis: a clinical case series. *Urology* 2011;78(6):1269–74. doi:10.1016/j.urology.2011.07.1403.
22. GABRIEL B, NASSIF J, TROMPOUKIS P, LIMA AM, BARATA S, LANG-AVEROUS G et al. Prevalence and outcome of urinary retention after laparoscopic surgery for severe endometriosis – does histology provide answers? *Int Urogynecol J* 2012;23(1):111–6. doi:10.1007/s00192-011-1492-2.
23. GHEZZI F, CROMI A, BERGAMINI V, BOLIS P. Management of ureteral endometriosis: areas of controversy. *Curr Opin Obstet Gynecol* 2007;19(4):319–24. doi:10.1097/GCO.0b013e328216f803.
24. GIANNAKOPOULOS X, LOLIS D, GRAMMENIATIS E, KOTOUKAS K. Iatrogenic injuries to the distal ureter during gynecologic interventions. *J Urol (Paris)* 1995;101(2):69–76.
25. GRAINGER DA, SODERSTROM RM, SCHIFF SF, GLICKMAN MG, DECHERNEY AH, DIAMOND MP. Ureteral injuries at laparoscopy: insights into diagnosis, management, and prevention. *Obstet Gynecol* 1990;75(5):839–43.
26. HANSEN KA, CHALPE A, EYSTER KM. Management of endometriosis-associated pain. *Clin Obstet Gynecol* 2010;53(2):439–48. doi:10.1097/GRF.0b013e3181dbda06.
27. HARADA M, OSUGA Y, IZUMI G, TAKAMURA M, TAKEMURA Y, HIRATA T et al. Dienogest, a new conservative strategy for extragenital endometriosis: a pilot study. *Gynecol Endocrinol* 2011;27(9):717–20. doi:10.3109/09513590.2010.533800.
28. IOSCA S, LUMIA D, BRACCHI E, DUKA E, BON M DE, LEKAJ M et al. Multislice computed tomography with colon water distension (MSCT-c) in the study of intestinal and ureteral endometriosis. *Clin Imaging* 2013;37(6):1061–8. doi:10.1016/j.clinimag.2013.07.003.
29. KLEIN RS, CATTOLICA EV. Ureteral endometriosis. *Urology* 1979;13(5):477–82.
30. KNABBEN L, IMBODEN S, FELLMANN B, NIRGIANAKIS K, KUHN A, MUELLER MD. Urinary tract endometriosis in patients with deep infiltrating endometriosis: prevalence, symptoms, management, and proposal for a new clinical classification. *Fertil Steril* 2015;103(1):147–52. doi:10.1016/j.fertnstert.2014.09.028.
31. KONDO W, BRANCO AW, TRIPPIA CH, RIBEIRO R, ZOMER MT. Retrocervical deep infiltrating endometriotic lesions larger than thirty millimeters are associated with an increased rate of ureteral involvement. *J Minim Invasive Gynecol* 2013;20(1):100–3. doi:10.1016/j.jmig.2012.09.012.
32. KUMAR S, TIWARI P, SHARMA P, GOEL A, SINGH JP, VIJAY MK et al. Urinary tract endometriosis: Review of 19 cases. *Urol Ann* 2012;4(1):6–12. doi:10.4103/0974-7796.91613.
33. LANGEBREKKE A, QVIGSTAD E. Ureteral endometriosis and loss of renal function: mechanisms and interpretations. *Acta Obstet Gynecol Scand* 2011;90(10):1164–6. doi:10.1111/j.1600-0412.2011.01210.x.
34. LIJOI D, FERRERO S, MISTRANGELO E, CASA ID, CROSA M, REMORGIDA V et al. Bowel preparation before laparoscopic gynaecological surgery in benign conditions using a 1-week low fibre diet: a surgeon blind, randomized and controlled trial. *Arch Gynecol Obstet* 2009;280(5):713–8. doi:10.1007/s00404-009-0986-3.
35. MACCAGNANO C, PELLUCCHI F, ROCCHINI L, GHEZZI M, SCATTONI V, MONTORSI F et al. Diagnosis and treatment of bladder endometriosis: state of the art. *Urol Int* 2012;89(3):249–58. doi:10.1159/000339519.
36. MACCAGNANO C, PELLUCCHI F, ROCCHINI L, GHEZZI M, SCATTONI V, MONTORSI F et al. Ureteral endometriosis: proposal for a diagnostic and therapeutic algorithm with a review of the literature. *Urol Int* 2013;91(1):1–9. doi:10.1159/000345140.
37. MAHUTTE NG, ARICI A. Medical management of endometriosis-associated pain. *Obstet Gynecol Clin North Am* 2003;30(1):133–50.
38. MARCELLI F, COLLINET P, VINATIER D, ROBERT Y, TRIBOULET J, BISERTE J et al. Ureteric and bladder involvement of deep pelvic endometriosis. Value of multidisciplinary surgical management. *Prog Urol* 2006;16(5):588–93.
39. MCCORMACK PL. Dienogest: a review of its use in the treatment of endometriosis. *Drugs* 2010;70(16):2073–88. doi:10.2165/11206320-000000000-00000.
40. MELLIN P, EICKENBERG HU. Ureteral reimplantation: Lich-Gregoire method. *Urology* 1978;11(3):315.
41. MEREU L, GAGLIARDI ML, CLARIZIA R, MAINARDI P, LANDI S, MINELLI L. Laparoscopic management of ureteral endometriosis in case of moderate-severe hydronephrosis. *Fertil Steril* 2010;93(1):46–51. doi:10.1016/j.fertnstert.2008.09.076.
42. MIRANDA-MENDOZA I, KOVOOR E, NASSIF J, FERREIRA H, WATTIEZ A. Laparoscopic surgery for severe ureteric endometriosis. *Eur J Obstet Gynecol Reprod Biol* 2012;165(2):275–9. doi:10.1016/j.ejogrb.2012.07.002.
43. MOUNSEY AL, WILGUS A, SLAWSON DC. Diagnosis and management of endometriosis. *Am Fam Physician* 2006;74(4):594–600.
44. NASSIF J, TROMPOUKIS P, BARATA S, FURTADO A, GABRIEL B, WATTIEZ A. Management of deep endometriosis. *Reprod Biomed Online* 2011;23(1):25–33. doi:10.1016/j.rbmo.2010.08.012.
45. NEZHAT C, NEZHAT F, NEZHAT CH, NASSERBAKHT F, ROSATI M, SEIDMAN DS. Urinary tract endometriosis treated by laparoscopy. *Fertil Steril* 1996;66(6):920–4.
46. NISOLLE M, DE LA OSA ESCRIBANO, INIGO LOPEZ, SQUIFFLET J, DONNEZ J. Ureteral endometriosis. *Gynaecol Endosc* 2001;10(2):95–7. doi:10.1046/j.1365-2508.2001.00424.x.
47. NUNEZ-MORA C, GARCIA-MEDIERO JM, CABRERA PM, HERNANDEZ E, GARCIA-TELLO A, ANGULO JC. Treatment of distal ureteral stricture by laparoscopic ureterovesical reimplantation. *Actas Urol Esp* 2011;35(1):31–6. doi:10.1016/j.acuro.2010.10.001.
48. OSTRZENSKI A, RADOLINSKI B, OSTRZENSKA KM. A review of laparoscopic ureteral injury in pelvic surgery. *Obstet Gynecol Surv* 2003;58(12):794–9. doi:10.1097/01.OGX.0000097781.79401.0B.
49. PEREZ-UTRILLA PEREZ M, AGUILERA BAZAN A, ALONSO DORREGO JM, HERNANDEZ A, FRANCISCO MG DE, MARTIN HERNANDEZ M et al. Urinary tract endometriosis: clinical, diagnostic, and therapeutic aspects. *Urology* 2009;73(1):47–51. doi:10.1016/j.urology.2008.08.470.
50. PRESTI JC JR, CARROLL PR, MCANINCH JW. Ureteral and renal pelvic injuries from external trauma: diagnosis and management. *J Trauma* 1989;29(3):370–4.
51. RAFIQUE M, ARIF MH. Management of iatrogenic ureteric injuries associated with gynecological surgery. *Int Urol Nephrol* 2002;34(1):31–5.

52. ROZSNYAI F, ROMAN H, RESCH B, DUGARDIN F, BERROCAL J, DESCARGUES G et al. Outcomes of surgical management of deep infiltrating endometriosis of the ureter and urinary bladder. *JSLs* 2011;15(4):439–47. doi:10.4293/108680811X13176785203798.
53. SAIDI MH, SADLER RK, VANCAILLIE TG, AKRIGHT BD, FARHART SA, WHITE AJ. Diagnosis and management of serious urinary complications after major operative laparoscopy. *Obstet Gynecol* 1996;87(2):272–6.
54. SANYAL D, ARGENT VP. Silent pelvic endometriosis presenting as pyelonephritis and ureteric obstruction. *J Obstet Gynaecol* 2003;23(3):328–9.
55. SCHLAFF WD, CARSON SA, LUCIANO A, ROSS D, BERGQVIST A. Subcutaneous injection of depot medroxyprogesterone acetate compared with leuprolide acetate in the treatment of endometriosis-associated pain. *Fertil Steril* 2006;85(2):314–25. doi:10.1016/j.fertnstert.2005.07.1315.
56. SCHWENTNER C, OSWALD J, LUNACEK A, DEIBL M, KOERNER I, BARTSCH G et al. Lich-Gregoir reimplantation causes less discomfort than Politano-Leadbetter technique: Results of a prospective, randomized, pain scale-oriented study in a pediatric population. *Eur Urol* 2006;49(2):388–95. doi:10.1016/j.eururo.2005.11.015.
57. SERACCHIOLI R, MABROUK M, MONTANARI G, MANUZZI L, CONCETTI S, VENTUROLI S. Conservative laparoscopic management of urinary tract endometriosis (UTE): surgical outcome and long-term follow-up. *Fertil Steril* 2010;94(3):856–61. doi:10.1016/j.fertnstert.2009.04.019.
58. SERACCHIOLI R, MANUZZI L, MABROUK M, SOLFRINI S, FRASCA C, MANFERRARI F et al. A multidisciplinary, minimally invasive approach for complicated deep infiltrating endometriosis. *Fertil Steril* 2010;93(3):1007.e1-3. doi:10.1016/j.fertnstert.2009.09.058.
59. SIRACUSANO S, LIGUORI G, D'ALOIA G, TROMBETTA C, BELGRANO E. Simplified Politano-Leadbetter's ureteral reimplantation associated with psoas-hitch technique using a new clamp. *Urology* 2002;59(6):930–1.
60. SORIANO D, SCHONMAN R, NADU A, LEOVITZ O, SCHIFF E, SEIDMAN DS et al. Multidisciplinary team approach to management of severe endometriosis affecting the ureter: long-term outcome data and treatment algorithm. *J Minim Invasive Gynecol* 2011;18(4):483–8. doi:10.1016/j.jmig.2011.04.011.
61. STILLWELL TJ, KRAMER SA, LEE RA. Endometriosis of ureter. *Urology* 1986;28(2):81–5.
62. TAKAGI H, MATSUNAMI K, ICHIGO S, IMAI A. Novel corrected medical management of primary bladder endometriosis with dienogest: a case report. *Clin Exp Obstet Gynecol* 2011;38(2):184–5.
63. VERCELLINI P, CROSIGNANI PG, SOMIGLIANA E, BERLANDA N, BARBARA G, FEDELE L. Medical treatment for rectovaginal endometriosis: what is the evidence? *Hum Reprod* 2009;24(10):2504–14. doi:10.1093/humrep/dep231.
64. VERCELLINI P, ESKENAZI B, CONSONNI D, SOMIGLIANA E, PARAZZINI F, ABBIATI A et al. Oral contraceptives and risk of endometriosis: a systematic review and meta-analysis. *Hum Reprod Update* 2011;17(2):159–70. doi:10.1093/humupd/dmq042.
65. WATTIEZ A, PUGA M, ALBORNOZ J, FALLER E. Surgical strategy in endometriosis. *Best Pract Res Clin Obstet Gynaecol* 2013;27(3):381–92. doi:10.1016/j.bpobgyn.2012.12.003.
66. WEINGERTNER AS, RODRIGUEZ B, ZIANE A, GIBON E, THOMA V, OSARIO F et al. The use of JJ stent in the management of deep endometriosis lesion, affecting or potentially affecting the ureter: a review of our practice. *BJOG* 2008;115(9):1159–64. doi:10.1111/j.1471-0528.2008.01795.x.
67. YOHANNES P. Ureteral endometriosis. *J Urol* 2003;170(1):20–5. doi:10.1097/01.ju.0000054836.32660.9e.
68. ZIEGLER D de, GAYET V, AUBRIOT FX, FAUQUE P, STREULI I, WOLF JP et al. Use of oral contraceptives in women with endometriosis before assisted reproduction treatment improves outcomes. *Fertil Steril* 2010;94(7):2796–9. doi:10.1016/j.fertnstert.2010.05.056.



## 5.4

## Bladder Endometriosis

Zaraq Khan<sup>a</sup> | Gaurang S. Daftary<sup>b</sup>**5.4.1 Introduction and Prevalence**

Urinary tract endometriosis, even though rare, comes with its unique symptomatology as well as diagnostic and therapeutic challenges. Traditionally reported in about 1–2% of women with symptomatic endometriosis,<sup>1,9,36</sup> urinary tract endometriosis can include endometrial tissue in and/or around the bladder, ureters, urethra or kidneys – each variant with its own presentation, symptoms and treatment.<sup>10,40,45</sup> More recent estimates of prevalence of urinary tract endometriosis range from 0.3 to 6% of cases.<sup>7,12</sup>

Bladder endometriosis is defined as endometriosis infiltrating the detrusor muscle. This was first described by *Judd* in 1921.<sup>43</sup> The bladder is the most common site of endometriotic lesions of the urinary tract.<sup>1</sup> Most reports quote bladder involvement in about 84% of patients with urinary tract endometriosis compared to 15% involving the ureters, 4% involving the kidneys and 2% involving the urethra.<sup>1,35</sup>

**5.4.2 Pathophysiology**

Three individual theories for bladder endometriosis have been described, although there is no consensus in the medical community regarding the prevailing one. These include:

- Trans-tubal menstrual reflux of endometrial cells onto the peritoneal lining covering the dome of the bladder.<sup>41</sup>
- Metaplasia of müllerian remnants in the vesicovaginal septum.<sup>11</sup>
- Extension of adenomyosis from anterior uterine wall into the bladder.<sup>15</sup>

There is description of spontaneous and iatrogenic bladder endometriosis, spontaneous variant of the disease as a manifestation of generalized disease, whereas iatrogenic as a result from implantation at time of cesarean delivery.<sup>41</sup> On the other hand, reports of bladder endometriosis in a male patient give prime importance to the role of metaplasia of müllerian remnants in the urogenital tract.<sup>27</sup> The role of inflammatory

mediators and genetic variation is now also universally accepted to play a pivotal role in the pathogenesis of this multifactorial disease.<sup>46</sup>

**5.4.3 Clinical Symptomatology**

Endometriosis mainly affects the detrusor muscle of the trigone and the bladder apex. Most patients with bladder endometriosis have non-specific symptoms and almost a third of patients are asymptomatic.<sup>19</sup> Newer reports have challenged these traditional numbers as being underestimated. A latest report with a large sample size reported 68.8% of women with bladder endometriosis to have some urinary symptoms.<sup>18</sup> Symptoms usually depend on the location and size of lesion.<sup>16,19</sup> Hematuria with menstruation is seen in only around 20–30% of women since bladder mucosa is not involved in the majority of cases.<sup>19,44</sup> Similarly higher frequency and severity of dysuria is seen in patients with nodules in the bladder base (vs. dome) that are larger in diameter (Table 5.3).<sup>42</sup>

Other common symptoms include menstrual dysuria, urinary frequency, suprapubic pain, urgency, nocturia and urge incontinence (Table 5.3).<sup>9,11,35</sup> The link between infertility and isolated bladder endometriosis is yet to be established.<sup>2</sup>

Symptom	Frequency	Reference
Asymptomatic	~33%	19
Symptomatic (any symptom)	~68%	18,19
Urinary frequency	41–71%	9,16,44
Dysuria (any area of involvement)	11–27%	9,16,18,44
Bladder base	~77%	42
Bladder dome	~34%	42
Suprapubic pain	38–43%	9,16,44
Dyspareunia	11–21%	16,18,44
Urge incontinence	~21%	44
Hematuria	0–30%	18,19,44

**Table 5.3** Symptoms of bladder endometriosis.

**5.4.4 Diagnosis**

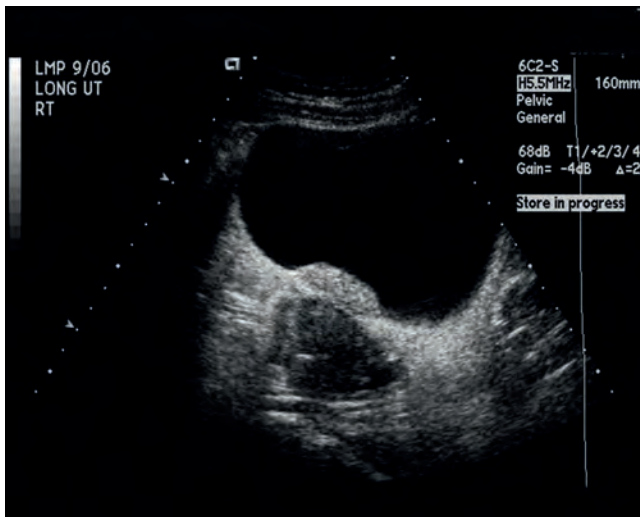
Clinical diagnosis of bladder endometriosis on history and physical examination is often difficult given the non-specific and subtle symptomatology. Since 50% of patients with bladder endometriosis have had some form of gynecologic surgery, it becomes an important screening question.<sup>28</sup> Physical examination can detect suprapubic and anterior vaginal wall tenderness in around 50% of patients.<sup>9</sup> It is however, a high index of suspicion that often leads to a timely diagnosis in most cases.

<sup>a</sup> | MBBS, MS, Assistant Professor of Obstetrics and Gynecology; Division of Reproductive Endocrinology and Infertility, Mayo Clinic, Rochester, MN, USA

<sup>b</sup> | MD, Assistant Professor of Obstetrics and Gynecology, Division of Reproductive Endocrinology and Infertility Mayo Clinic, Rochester MN, USA

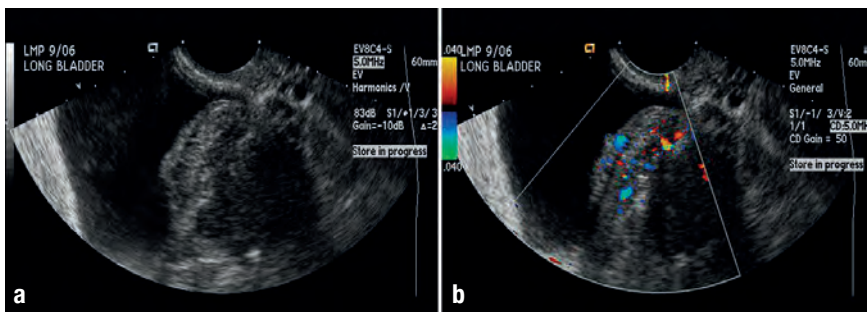
**Corresponding author:****Zaraq Khan**

MBBS, MS; Assistant Professor of Obstetrics and Gynecology  
Division of Reproductive Endocrinology and Infertility  
Mayo Clinic  
200 First Street SW  
Rochester, MN 55901, USA  
E-mail: khan.zaraq@mayo.edu

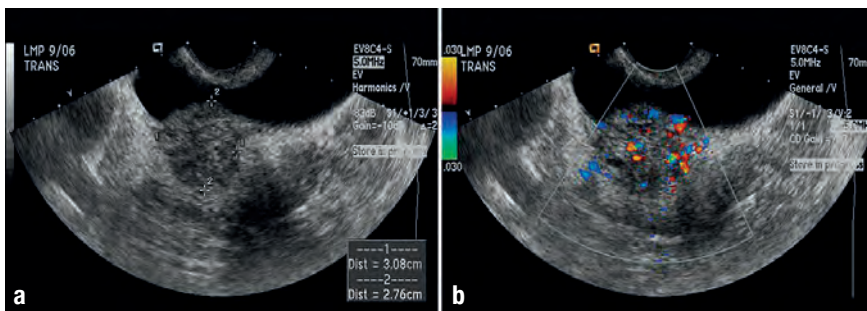


**Fig. 5.19** Pelvic ultrasound showing an endometriotic lesion of the posterior wall of the bladder. Increased thickness in the posterior wall of the bladder can be appreciated as well. This is characteristic of bladder endometriosis; however differential diagnosis includes a bladder tumor.

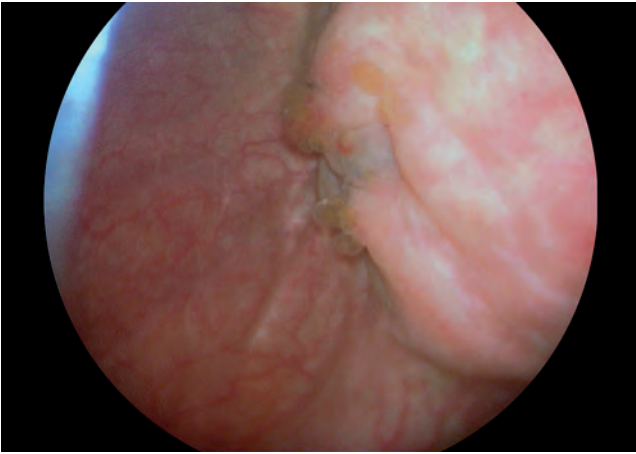
There is controversy about the ideal imaging modality for diagnosis of bladder endometriosis. Pelvic ultrasonography usually reveals bladder wall thickness with an occasional protrusion into the bladder lumen (Figs. 5.19–5.21).<sup>17</sup> Lesions less than 3 cm may be difficult to visualize with ultrasonography.<sup>19</sup> Magnetic resonance imaging (MRI) can also be helpful with sensitivity as high as 88 % and specificity higher than 98 % for urinary tract endometriosis.<sup>22,30</sup> Three-dimensional ultrasound with color Doppler has also shown promising results comparable to MRI for bladder endometriosis.<sup>39</sup>



**Fig. 5.20a, b** A lesion in the bladder with polypoid protrusion noted on pelvic ultrasound (a). Flow in the lesion noted when color Doppler is used. Bladder tumor will again be an important differential diagnosis to be ruled out in this case scenario (b).



**Fig. 5.21a, b** A sagittal plane image of a pelvic ultrasound showing a lesion that almost arises in the uterus and erodes into the bladder. This is another typical appearance of bladder endometriosis. Cases like this give strength to the theory of bladder endometriosis arising from uterine adenomyotic lesions (a). Same image as (a), but with color Doppler flow. A clear vesicouterine border cannot be noted. Surgical resection of such lesions is challenging and will require extensive dissection in the vesicouterine plane (b).



**Fig. 5.22** Cystoscopic view of bladder endometriosis. Edematous lesion with characteristic bluish-black color typical of bladder endometriosis is appreciated. The location of the lesion is in close proximity to the ureteral orifice which would make surgery challenging in this particular case.

However, since endometriosis is typically diagnosed by direct visualization of the implants, biopsy and histologic examination is considered the gold standard for diagnosis. Likewise for bladder endometriosis, cystoscopy with biopsy is usually necessary for definitive diagnosis. Morphologic appearance of endometriosis in the bladder at cystoscopy depends on the phase of the menstrual cycle. The lesions can appear edematous, bluish-red, bluish-black and/or bluish-brown and have an irregular shape (Fig. 5.22).<sup>16,19</sup> Adjunctive cystoscopy helps in pre-operative planning as lesions within 2 cm of the ureteral openings may also require ureteral replantation surgery in addition to bladder resection.<sup>19</sup>

#### 5.4.4.1 Differential Diagnosis

The non-specific symptoms of bladder endometriosis can be caused by other causes of chronic bladder irritation and inflammation. These can include chronic cystitis due to infectious bacterial and parasitic organisms, post radiation cystitis, interstitial cystitis overactive bladder and neoplastic processes involving the bladder. A urine culture with cytology and cystoscopy helps rule out these conditions in most cases.

### 5.4.5 Management

Treatment of bladder endometriosis is controversial as randomized controlled trials are not feasible given the disease prevalence. As a result, most treatment recommendations come from case reports or small case series. Treatment of bladder endometriosis can be either medical or surgical. The

principle of therapy is the same as in pelvic endometriosis which is aimed at control of symptoms. An additional goal in the treatment of bladder endometriosis is to relieve any asymptomatic hydronephrosis if present. The choice of therapy depends on multiple factors for example, patient's age, fertility desire, extent of bladder disease, symptomatology, history of previous disease and most importantly patient's choice.

#### 5.4.5.1 Medical Management

Agents used for medical therapy for bladder endometriosis are the same as those used for pelvic disease. However, since medical therapy for pelvic endometriosis remains as elusive as its etiology, current therapeutic strategies of enhancing or eliminating sex steroids are often non-mechanistic and unsatisfactory. Medical therapy for bladder endometriosis is hence often considered palliative or is reserved for women reluctant to surgical treatment. Sex hormone therapy in form of low-dose combined oral contraceptives has shown promising results in some reports.<sup>13,44</sup> Likewise, gonadotropin releasing hormone analogs (GnRH analogs) can also be used.<sup>19</sup>

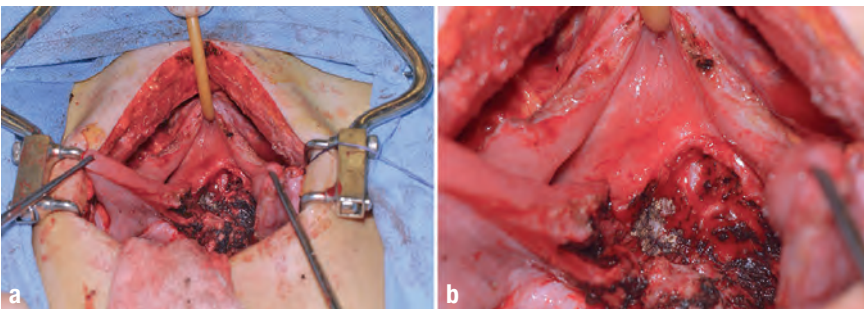
Recently, the efficacy of dienogest (a synthetic oral progestin)<sup>23</sup> has been reported for deep infiltrating endometriosis.<sup>37</sup> Doses of 2 mg/day of dienogest have shown improvement in symptoms from bladder endometriosis in a few case reports and may be of benefit in women refusing to undergo surgery.<sup>3,38</sup>

#### 5.4.5.2 Surgical Management

Definitive management of bladder endometriosis entails removal of the entire lesion. Full thickness resection of the bladder wall at the site of lesion is considered the treatment of choice for most women, given that most lesions are deeply infiltrated (Figs. 5.23a, b).<sup>4,5,9,26</sup> Very rarely, shaving of the bladder without performing a resection yields a successful outcome.<sup>20</sup>

Typically, surgical resection can be carried out either laparoscopically or with a laparotomy. The aim is to achieve complete resection of the lesion considering that incomplete removal can cause recurrence.<sup>33</sup> Complete resection has led to significant reduction in pain caused by bladder endometriosis in women with a mean follow-up of 3.2 years in one report.<sup>8</sup>

Laparoscopic resection of bladder lesions has been well described in several cases. An experienced surgeon is essential for success of such cases. Most reports have shown this approach to be safe and efficacious.<sup>25,26,33</sup> On the bladder dome resection may not require any preliminary dissection. In contrast, nodules involving the posterior bladder or the vesicle



**Fig. 5.23a, b** Image at laparotomy from a patient with extensive posterior bladder wall endometriosis. An elective cystotomy has been made. The Foley catheter can be seen entering the bladder anteriorly. The vesicle base and posterior wall is involved with a very large deeply infiltrating endometriotic lesion. Close-up view (b) of the bladder shown in (a). The large endometriotic lesion can be appreciated in greater magnification. On gross inspection, this appearance can be confused with necrotic tumor.



base must be mobilized from the uterus by dissecting in the vesicouterine space in order to remove it in its entirety and hence decrease the risk of recurrence.<sup>6</sup> In addition, for such lesions resection of the underlying myometrium where the bladder is apposed to the uterus has also shown to decrease recurrence rates.<sup>14</sup> In most cases, the bladder is closed in double-layer technique using running 2-0 polyglactin (Vicryl™) suture or the like, though single layer closure has also been described.<sup>6,25</sup> Postoperatively, a bladder catheter is left in place for 7 to 10 days to prevent fistula formation. Similar to conventional laparoscopy, robot-assisted bladder resection has also been reported to be safe and efficacious.<sup>24</sup>

Transurethral resection is typically contraindicated for bladder endometriosis, given the deep infiltrative nature of these lesions. However, an alternative technique for surgical resection is to perform cystoscopy and resect the nodule cystoscopically, followed by suture closure of the bladder defect via conventional or robot-assisted laparoscopy. This procedure has been described in several reports.<sup>21,32,34</sup>

Preoperative characteristics that suggest the need of an advanced procedure and the possibility of a multidisciplinary approach include:

- The endometriotic lesion being less than 2 cm away from the inter-ureteric ridge.
- The patient is undergoing surgery for a recurrence
- Bladder endometriosis is associated with hydronephrosis or possible ureteral endometriosis.

There is a strong recommendation for use of preoperative ureteral stents by some authors for such cases (Figs. 5.24a, b).<sup>19</sup>

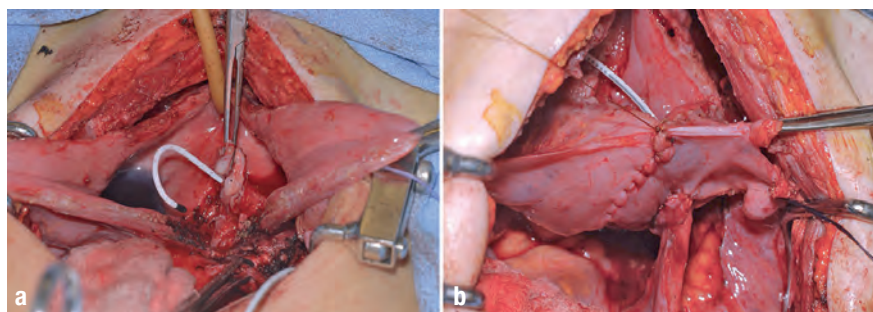
#### 5.4.6 Surgical Complications and Outcomes

Due to the rare nature of bladder endometriosis most surgical complications and long-term outcomes are evaluated from case series or small cohorts with short-term follow-up. Other than the usual complications that could occur with anesthesia, laparoscopy and cystoscopy, the potential complications reported to occur during bladder resection for endometriosis include bladder or vesicovaginal hematoma,<sup>5</sup> vesicovaginal fistula<sup>5,29</sup> and atonic bladder requiring long term urinary catheterization (Table 5.4).<sup>29</sup> Even though these complications are very rare they should not be overlooked.

Most reports have reported very low rates of recurrence after complete resection of disease.<sup>5,14,20,29,31</sup> The largest cohort is composed of 75 women followed for 60 months with over 70% of them showing improvement of their symptoms.<sup>5</sup> Others with substantial numbers include 47 women followed for 36 months,<sup>14</sup> and 21 women followed for 20 months without a recurrence (Table 5.4).<sup>20</sup>

#### 5.4.7 Conclusion

Endometriosis of the urinary bladder – though the most common variant of endometriosis of the urinary tract – is a rare disease. Given the non-specific symptomatology of the disease, its diagnosis is not only difficult but also paramount, as surgical resection can give definitive relief with few postoperative complications.



**Fig. 5.24a,b** Given the close proximity to the uretero vesicular junction, double-J stents are used as discussed in the chapter (a). After removal of the endometriotic tissue, the bladder is reconstructed and reapproximated in two layers using a running suture. The ureter had to be reimplemented via ureteroneocystostomy as seen in this image (b).

**Complications and Outcomes of Bladder Endometriosis after Surgical Resection**

Reference	Number of study subjects	Time period of study	Intraoperative complications	Follow-up period (months)	Recurrence of symptoms (%)	Recurrence symptoms requiring reoperation (%)	Long-term complications
Chapron et al. 2010 <sup>5</sup>	75	1992–2007	none	59.9 ± 44.6*	2.7%	0%	1 vesicovaginal fistula 1 bladder hematoma
Kovoor et al. 2010 <sup>20</sup>	21	2006–2009	none	20 (5–38) <sup>∞</sup>	5.3%	5.3%	2 vesicovaginal fistula 2 bladder hematoma
Fedele et al. 2005 <sup>14</sup>	47	1989–2001	none	33.5 ± 20.1	17.5%	10.9%	none
Rozsnyai et al. 2011 <sup>29</sup>	15	2006–2010	1 ureteral injury	24.9 ± 17.8	~46%	0%	1 vesicovaginal fistula 1 atonic bladder
Schonman et al. 2013 <sup>31</sup>	69	2005–2011	none	60 (4–92)	7.3%	0%	none

**Table 5.4** Complications and outcomes of bladder endometriosis after surgical resection.

\* (Mean ±SD), <sup>∞</sup> Median (range)

### 5.4.8 Acknowledgement

All pictures were provided by courtesy of Dr. *Christopher J. Klingele*, Associate Professor of Obstetrics and Gynecology, Division of Gynecologic Surgery, Department of Obstetrics and Gynecology, Mayo Clinic, Rochester MN, USA.

### 5.4.9 References

- ABESHOUSE BS, ABESHOUSE G. Endometriosis of the urinary tract: a review of the literature and a report of four cases of vesical endometriosis. *J Int Coll Surg* 1960;34:43–63.
- ABRAO MS, DIAS JA JR, BELLELIS P, PODGAEC S, BAUTZER CR, GROMATSKY C. Endometriosis of the ureter and bladder are not associated diseases. *Fertil Steril* 2009;91(5):1662–7. doi:10.1016/j.fertnstert.2008.02.143.
- AGARWAL S, FRASER MA, CHEN I, SINGH SS. Dienogest for the treatment of deep endometriosis: case report and literature review. *J Obstet Gynaecol Res* 2015;41(2):309–13. doi:10.1111/jog.12527.
- ANTONELLI A, SIMEONE C, ZANI D, SACCONI T, MININI G, CANOSSO E et al. Clinical aspects and surgical treatment of urinary tract endometriosis: our experience with 31 cases. *Eur Urol* 2006;49(6):1093–7; discussion 1097–8. doi:10.1016/j.eururo.2006.03.037.
- CHAPRON C, BOURRET A, CHOPIN N, DOUSSET B, LECONTE M, AMSELLEM-OUAZANA D et al. Surgery for bladder endometriosis: long-term results and concomitant management of associated posterior deep lesions. *Hum Reprod* 2010;25(4):884–9. doi:10.1093/humrep/deq017.
- CHAPRON C, DUBUISSON JB. Laparoscopic management of bladder endometriosis. *Acta Obstet Gynecol Scand* 1999;78(10):887–90.
- CHAPRON C, FAUCONNIER A, VIEIRA M, BARAKAT H, DOUSSET B, PANSINI V et al. Anatomical distribution of deeply infiltrating endometriosis: surgical implications and proposition for a classification. *Hum Reprod* 2003;18(1):157–61.
- CHOPIN N, VIEIRA M, BORGHESE B, FOULOT H, DOUSSET B, COSTE J et al. Operative management of deeply infiltrating endometriosis: results on pelvic pain symptoms according to a surgical classification. *J Minim Invasive Gynecol* 2005;12(2):106–12. doi:10.1016/j.jmig.2005.01.015.
- COMITER CV. Endometriosis of the urinary tract. *Urol Clin North Am* 2002;29(3):625–35.
- DONNEZ J, NISOLLE M, SQUIFFLET J. Ureteral endometriosis: a complication of rectovaginal endometriotic (adenomyotic) nodules. *Fertil Steril* 2002;77(1):32–7.
- DONNEZ J, SPADA F, SQUIFFLET J, NISOLLE M. Bladder endometriosis must be considered as bladder adenomyosis. *Fertil Steril* 2000;74(6):1175–81.
- DOUGLAS C, ROTIMI O. Extragenital endometriosis – a clinicopathological review of a Glasgow hospital experience with case illustrations. *J Obstet Gynaecol* 2004;24(7):804–8. doi:10.1080/01443610400009568.
- FEDELE L, BIANCHI S, MONTEFUSCO S, FRONTINO G, CARMIGNANI L. A gonadotropin-releasing hormone agonist versus a continuous oral contraceptive pill in the treatment of bladder endometriosis. *Fertil Steril* 2008;90(1):183–4. doi:10.1016/j.fertnstert.2007.09.060.
- FEDELE L, BIANCHI S, ZANCONATO G, BERGAMINI V, BERLANDA N, CARMIGNANI L. Long-term follow-up after conservative surgery for bladder endometriosis. *Fertil Steril* 2005;83(6):1729–33. doi:10.1016/j.fertnstert.2004.12.047.
- FEDELE L, PIAZZOLA E, RAFFAELLI R, BIANCHI S. Bladder endometriosis: deep infiltrating endometriosis or adenomyosis? *Fertil Steril* 1998;69(5):972–5.
- GUSTILO-ASHBY AM, PARAISO MF. Treatment of urinary tract endometriosis. *J Minim Invasive Gynecol* 2006;13(6):559–65. doi:10.1016/j.jmig.2006.07.012.
- KINKEL K, FREI KA, BALLEYGUIER C, CHAPRON C. Diagnosis of endometriosis with imaging: a review. *Eur Radiol* 2006;16(2):285–98. doi:10.1007/s00330-005-2882-y.
- KNABBen L, IMBODEN S, FELLMANN B, NIRGIANAKIS K, KUHN A, MUELLER MD. Urinary tract endometriosis in patients with deep infiltrating endometriosis: prevalence, symptoms, management, and proposal for a new clinical classification. *Fertil Steril* 2015;103(1):147–52. doi:10.1016/j.fertnstert.2014.09.028.
- KOLODZIEJ A, KRAJEWSKI W, DOLOWY L, HIRNLE L. Urinary Tract Endometriosis. *Urol J* 2015;12(4):2213–7.
- KOVOOR E, NASSIF J, MIRANDA-MENDOZA I, WATTIEZ A. Endometriosis of bladder: outcomes after laparoscopic surgery. *J Minim Invasive Gynecol* 2010;17(5):600–4. doi:10.1016/j.jmig.2010.05.008.
- LITTA P, SACCARDI C, D'AGOSTINO G, FLORIO P, ZORZI L DE, BIANCO MD. Combined transurethral approach with Versapoint((R)) and laparoscopic treatment in the management of bladder endometriosis: technique and 12 months follow-up. *Surg Endosc* 2012;26(9):2446–50. doi:10.1007/s00464-012-2208-5.
- MANGANARO L, FIERRO F, TOMEI A, IRIMIA D, LODISE P, SERGI ME et al. Feasibility of 3.0T pelvic MR imaging in the evaluation of endometriosis. *Eur J Radiol* 2012;81(6):1381–7. doi:10.1016/j.ejrad.2011.03.049.
- MCCORMACK PL. Dienogest: a review of its use in the treatment of endometriosis. *Drugs* 2010;70(16):2073–88. doi:10.2165/11206320-000000000-00000.
- NEZHAT C, HAJHOSSEINI B, KING LP. Robotic-assisted laparoscopic treatment of bowel, bladder, and ureteral endometriosis. *JLS* 2011;15(3):387–92. doi:10.4293/108680811X13125733356396.
- NEZHAT C, NEZHAT F, NEZHAT CH, NASSERBAKHT F, ROSATI M, SEIDMAN DS. Urinary tract endometriosis treated by laparoscopy. *Fertil Steril* 1996;66(6):920–4.
- NEZHAT CH, MALIK S, OSIAS J, NEZHAT F, NEZHAT C. Laparoscopic management of 15 patients with infiltrating endometriosis of the bladder and a case of primary intravesical endometrioid adenosarcoma. *Fertil Steril* 2002;78(4):872–5.
- OLIKER AJ, HARRIS AE. Endometriosis of the bladder in a male patient. *J Urol* 1971;106(6):858–9.
- PRICE DT, MALONEY KE, IBRAHIM GK, CUNDIFF GW, LEDER RA, ANDERSON EE. Vesical endometriosis: report of two cases and review of the literature. *Urology* 1996;48(4):639–43. doi:10.1016/S0090-4295(96)00224-5.
- ROZSNYAI F, ROMAN H, RESCH B, DUGARDIN F, BERROCAL J, DESCARGUES G et al. Outcomes of surgical management of deep infiltrating endometriosis of the ureter and urinary bladder. *JLS* 2011;15(4):439–47. doi:10.4293/108680811X13176785203798.
- SABA L, SULCIS R, MELIS GB, CECCO CN DE, LAGHI A, PIGA M et al. Endometriosis: the role of magnetic resonance imaging. *Acta Radiol* 2015;56(3):355–67. doi:10.1177/0284185114526086.
- SCHONMAN R, DOTAN Z, WEINTRAUB AY, BIBI G, EISENBERG VH, SEIDMAN DS et al. Deep endometriosis inflicting the bladder: long-term outcomes of surgical management. *Arch Gynecol Obstet* 2013;288(6):1323–8. doi:10.1007/s00404-013-2917-6.

32. SENER A, CHEW BH, DUJDEVANI M, BROCK GB, VILOS GA, PAUTLER SE. Combined transurethral and laparoscopic partial cystectomy and robot-assisted bladder repair for the treatment of bladder endometrioma. *J Minim Invasive Gynecol* 2006;13(3): 245–8. doi:10.1016/j.jmig.2006.01.014.
33. SERACCHIOLI R, MABROUK M, MONTANARI G, MANUZZI L, CONCETTI S, VENTUROLI S. Conservative laparoscopic management of urinary tract endometriosis (UTE): surgical outcome and long-term follow-up. *Fertil Steril* 2010;94(3):856–61. doi:10.1016/j.fertnstert.2009.04.019.
34. SERACCHIOLI R, MANNINI D, COLOMBO FM, VIANELLO F, REGGIANI A, VENTUROLI S. Cystoscopy-assisted laparoscopic resection of extramucosal bladder endometriosis. *J Endourol* 2002;16(9):663–6. doi:10.1089/089277902761403014.
35. SHOOK TE, NYBERG LM. Endometriosis of the urinary tract. *Urology* 1988;31(1):1–6.
36. STANLEY KE JR, UTZ DC, DOCKERTY MB. Clinically significant endometriosis of the urinary tract. *Surg Gynecol Obstet* 1965;120:491–8.
37. SUGIMOTO K, NAGATA C, HAYASHI H, YANAGIDA S, OKAMOTO A. Use of dienogest over 53 weeks for the treatment of endometriosis. *J Obstet Gynaecol Res* 2015;41(12):1921–6. doi:10.1111/jog.12811.
38. TAKAGI H, MATSUNAMI K, ICHIGO S, IMAI A. Novel corrected medical management of primary bladder endometriosis with dienogest: a case report. *Clin Exp Obstet Gynecol* 2011;38(2):184–5.
39. THONNON C, PHILIP CA, FASSI-FEHRI H, BISCH C, COULON A, SAINT-HILAIRE P DE et al. Three-dimensional ultrasound in the management of bladder endometriosis. *J Minim Invasive Gynecol* 2015;22(3):403–9. doi:10.1016/j.jmig.2014.10.021.
40. VERCELLINI P, FRONTINO G, PISACRETA A, GIORGI O DE, CATTANEO M, CROSIGNANI PG. The pathogenesis of bladder detrusor endometriosis. *Am J Obstet Gynecol* 2002;187(3):538–42.
41. VERCELLINI P, MESCHIA M, GIORGI O DE, PANAZZA S, CORTESI I, CROSIGNANI PG. Bladder detrusor endometriosis: clinical and pathogenetic implications. *J Urol* 1996;155(1):84–6.
42. VILLA G, MABROUK M, GUERRINI M, MIGNEMI G, MONTANARI G, FABBRI E et al. Relationship between site and size of bladder endometriotic nodules and severity of dysuria. *J Minim Invasive Gynecol* 2007;14(5):628–32. doi:10.1016/j.jmig.2007.04.015.
43. VITAGLIANO G, VILLET M, CASTILLO O. Laparoscopic partial cystectomy in the management of bladder endometriosis: report of two cases. *J Endourol* 2006;20(12):1072–4. doi:10.1089/end.2006.20.1072.
44. WESTNEY OL, AMUNDSEN CL, MCGUIRE EJ. Bladder endometriosis: conservative management. *J Urol* 2000;163(6):1814–7.
45. YANG J, SONG RJ, XU C, ZHANG SQ, ZHANG W. Renal endometriosis tends to be misdiagnosed as renal tumor: a rare case report. *Int Surg* 2015;100(2):376–80. doi:10.9738/INTSURG-D-13-00190.1.
46. ZUBRZYCKA A, ZUBRZYCKI M, JANECKA A, ZUBRZYCKA M. New Horizons in the Etiopathogenesis and Non-Invasive Diagnosis of Endometriosis. *Curr Mol Med* 2015;15(8):697–713.



## 5.5

## Surgical Treatment of Bladder Endometriosis

Basma Darwish<sup>a</sup> | Emanuela Stochino Loi<sup>a</sup> | Horace Roman<sup>a,b</sup>

### 5.5.1 Introduction

No substantive guidelines are available for the treatment of urinary tract endometriosis. This condition is less frequent than other forms of endometriosis, hence the inability to conduct large randomized trials. In our series of patients managed for deep infiltrating endometriosis from June, 2009, to October, 2015, we recorded 430 patients treated for deep infiltrating colorectal endometriosis versus only 50 patients with bladder involvement, resulting in a ratio of 9:1.

Surgery is the treatment option that offers a more complete cure, long-term relief of symptoms, and a lower rate of recurrence, especially in young patients far from menopause. Several studies have shown high efficacy of surgery in relieving symptoms, improving quality of life, and forestalling recurrence.<sup>4,8,9,13</sup> Medical therapy can halt the evolution of deep endometriosis lesions<sup>5</sup> and relieve symptoms by suppressing menstrual cycles,<sup>11</sup> but the lesions will most likely continue to grow after the cessation of medical therapy. As a result, medical treatment may be considered in patients who do not desire pregnancy or to prevent recurrence following curative surgery.

Lesions in bladder endometriosis infiltrate the bladder from the outside toward the mucosa, so they cannot always be

visualized by bladder endoscopy and cannot be completely excised through the urethra by endoscopic procedures such as transurethral resection of the bladder (TURB). For these reasons, cystoscopy can be used to assess involvement of the bladder mucosa, determine lesion distance from the ureteral orifices, or simply to incise the mucosa around the nodule prior to laparoscopic lesion removal.<sup>10</sup>

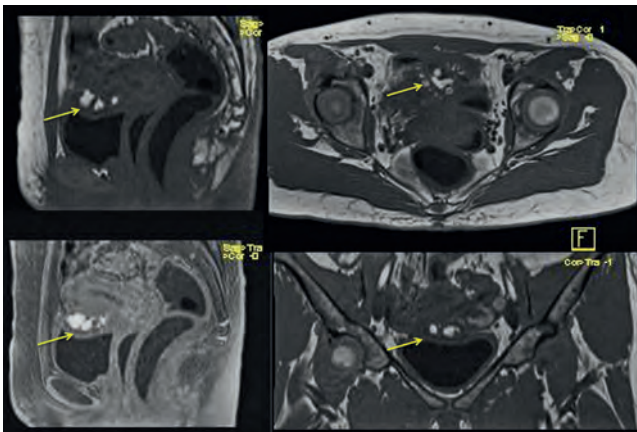
It is essential to perform appropriate preoperative imaging and obtain good endoscopic visualization of lesions at the time of surgery. It is also important to accurately evaluate the size and location of endometriotic lesions in the bladder, including their relation to the ureteral orifices, and to make a global assessment of the upper urinary tract.

### 5.5.2 Preoperative Workup

Full bladder transabdominal and transvaginal ultrasonography is widely considered to be the first-line imaging technique for suspected bladder endometriosis owing to its high availability, low cost, and easy access. Localized bladder wall thickening is easily visualized with ultrasound, which can immediately narrow the differential diagnosis of wall thickening to bladder endometriosis. The specificity of a skilled ultrasound examination approaches 100%, although sensitivity may be poorer for lesions smaller than 3 cm, in previously operated patients, and in an empty bladder.

*Thonnon et al.*<sup>14</sup> recently advocated the use of 3D ultrasound for the assessment of bladder endometriosis, reporting high sensibility and specificity and the accurate spatial reconstruction of deep nodules.

But since bladder endometriosis rarely occurs in isolation, magnetic resonance imaging (MRI) cannot only accurately delineate the bladder lesion but can also potentially identify additional sites of deep infiltrating endometriosis. Typical MRI features include localized or diffuse bladder wall thickening involving the dome or posterior bladder wall, heterogeneous low T2-weighted signal intensity, and occasional T1 hyperintensity due to hemorrhage, which is highly sensitive for the presence of endometriosis (Fig. 5.25).



**Fig. 5.25** MRI demonstrates bladder nodules caused by endometriosis (yellow arrows).

<sup>a</sup> | MD; Department of Gynecology and Obstetrics, Rouen University Hospital, Rouen, France

<sup>b</sup> | MD, PhD; Research Group EA 4308 'Spermatogenesis and Gamete Quality', IHU Rouen Normandy, IFRMP23, Reproductive Biology Laboratory, Rouen University Hospital, Rouen, France

#### Corresponding author:

**Basma Darwish, MD**

Centre Hospitalier de Rouen, Service de Gynécologie Obstétrique

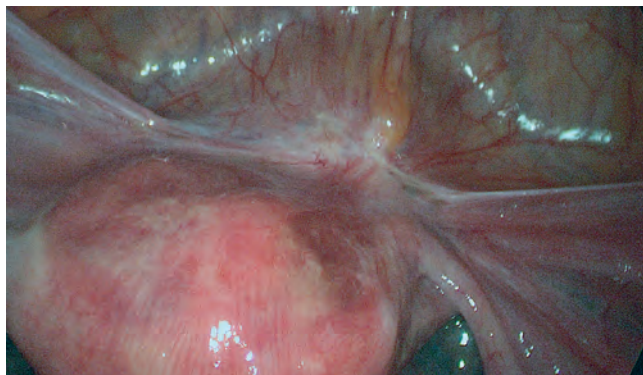
1 Rue Germont, 76000 Rouen, France

E-mail: basma.darwish@gmail.com

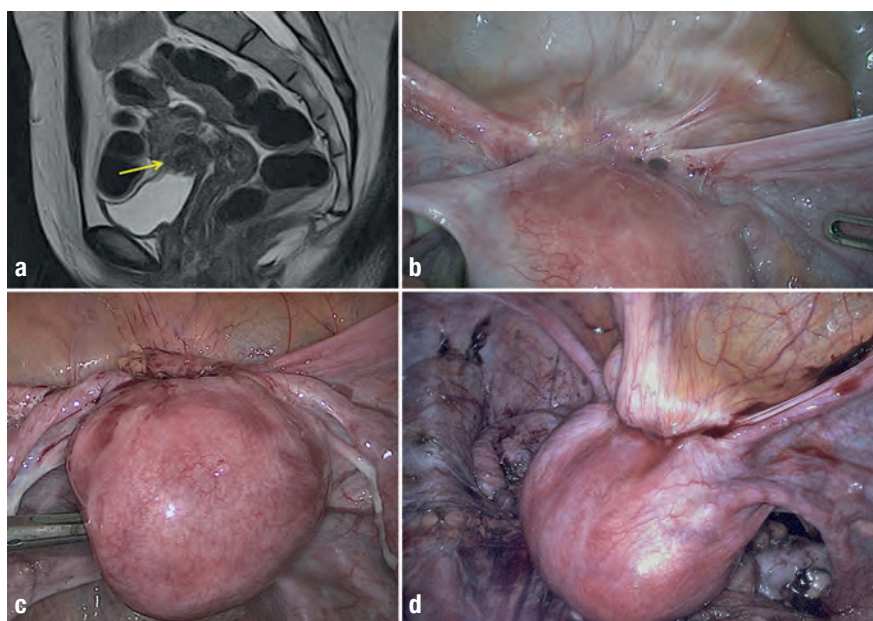
MRI may also help in defining the location of the nodule, measuring its distance from the distal ureters, and depicting ureteral obstruction, due more commonly to an associated mass effect than direct invasion by endometriosis. This is relevant for surgical planning, as treatment may require the placement of ureteral double-J stents or ureteral reimplantation. It also indicates whether the bladder nodule results from deep progression of an endometriotic lesion on the peritoneum of the anterior cul-de-sac (Fig. 5.26) or is merely the extension of

an anterior uterine adenomyoma (Fig. 5.27). In the latter case, complete resection of the adenomyoma is unlikely to be achieved unless hysterectomy is added to the procedure.

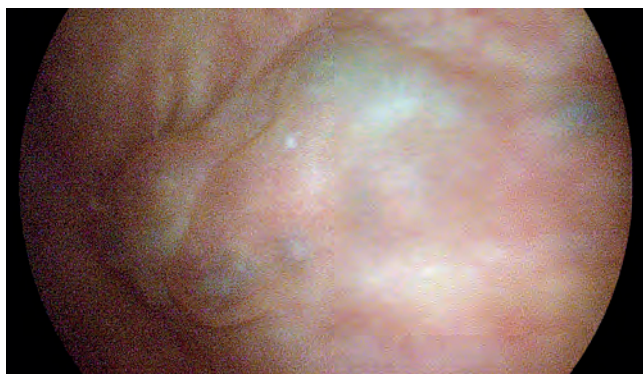
Cystoscopy is unnecessary and usually unrewarding in the diagnosis of bladder endometriosis. Cystoscopy may occasionally reveal a bluish tinge to the mucosa (Fig. 5.28), but negative cystoscopy does not exclude significant invasion of the muscularis.



**Fig. 5.26** Laparoscopic view of bladder endometriosis in its peritoneal form.



**Fig. 5.27a–d** Preoperative sagittal MRI in a patient with bladder endometriosis (a). Arrow indicates the anterior uterine adenomyoma extending to the bladder. Laparoscopic views of bladder endometriosis resulting from extension of an anterior uterine adenomyoma (b–d).



**Fig. 5.28** Cystoscopic view of bladder endometriosis.

Urodynamic testing may be performed if there is clinical suspicion of bladder dysfunction. This condition may result from large, low endometriotic bladder nodules abutting the urinary trigone, or it may occur in patients presenting with associated large, deep endometriosis infiltrating both uterosacral ligaments in contact with the inferior hypogastric plexus and splanchnic nerves. In these cases, preoperative awareness of bladder dysfunction may prompt a more conservative surgical resection with the goal of avoiding severe postoperative bladder dysfunction. Urologic MRI or computed tomography may be performed if ureteral involvement is suspected, eliminating the need for an intravenous pyelogram. Even if the ureters are not infiltrated, they may be injured during surgery in cases where large anterior adenomyomas infiltrating the bladder have shortened the distance between the uterine vascular pedicles and pelvic portion of the ureters, placing them close to the lateral borders of the adenomyoma.<sup>12</sup>

### 5.5.3 Surgical Treatment

The surgical treatment of bladder endometriosis is usually performed by laparoscopy, which has become fairly routine at many endometriosis treatment centers. There are several reports on the high efficacy of laparoscopic partial cystectomy in relieving symptoms, improving quality of life, and preventing recurrence (Table 5.5).<sup>1-3,6,8,9,12,13</sup> The bladder is easily visualized and accessible at laparoscopy, and laparoscopic bladder surgery can be performed with low morbidity.

A low-residue diet designed to reduce the frequency and volume of fecal output while prolonging intestinal transit time is maintained for 4–7 days before surgery to aid intraoperative exposure. Surgery is usually preceded by urinalysis to exclude urinary tract infection.

#### 5.5.3.1 Operative Technique

After induction of general anesthesia, the patient is placed in a low lithotomy position with both arms next to the body. The legs are semiflexed to allow optimal vaginal and urinary access. After the patient is positioned, the abdomen, perineum and vagina are prepared and draped. A Ch 16 or 18 Foley catheter is placed in the bladder. A 3-way catheter may be useful in cases where hematuria persists at the end of surgery. Indeed, the continuous slow infusion of a saline solution into the bladder will prevent clot formation that may obstruct the catheter. An intrauterine manipulating device is introduced to permit uterine manipulations during laparoscopy.

A 10-mm primary trocar is introduced at the umbilicus, then three 5-mm secondary trocars are placed: one each in the left and right iliac fossa, 2 cm superior to the anterosuperior iliac spine, and one in the suprapubic midline.

First the pelvic cavity is explored. The bladder and vesicouterine pouch are evaluated after retroflexion of the uterus with the uterine cannula. Usually the bladder is firmly adherent to the uterus, similar to the findings seen in women with a prior cesarean section (Fig. 5.27). When bladder endometriosis results from the extension of an anterior adenomyoma, the anterior uterine wall is infolded around the nodule and the bladder may be adherent to the uterus as high up as the uterine fundus. The round ligaments may also be encased in the bladder nodule (Fig. 5.27). Care should be taken not to injure the ureters during dissection, as the distal part of the ureter is usually retracted toward the midline, as previously mentioned.

Superficial peritoneal bladder endometriosis is treated either by peritoneal resection of the involved area, in which lesions may appear as dark blue, black or red implants or white fibrosis, or by simple ablative techniques such as bipolar coagulation or vaporization with a CO<sub>2</sub> laser or plasma jet.

Deep infiltrating lesions may include partial-thickness lesions limited to the bladder muscularis, which can be managed by resecting the nodule without opening the bladder (shaving). Full-thickness lesions with total infiltration of the muscularis or mucosa would require a full-thickness resection that opens the bladder. This can usually be accomplished by laparoscopy alone. In cases where nodules are large, a combined cystoscopy-guided laparoscopic approach is preferred to economize the resection while achieving complete removal of the nodule.<sup>10</sup>

Study	Number of patients	Length of follow-up (months)	Symptom recurrence	Anatomic recurrence
<i>Nezhat et al., 1996</i> <sup>8</sup>	28	22	2	0
<i>Chapronet et al., 1999</i> <sup>2</sup>	8	31.6	0	0
<i>Chapron et al., 2000</i> <sup>3</sup>	13	29	0	0
<i>Nezhat et al., 2002</i> <sup>9</sup>	15	15	3	0
<i>Antonelli et al., 2006</i> <sup>1</sup>	31	58	6	5
<i>Frenna et al., 2007</i> <sup>6</sup>	45	9	0	4
<i>Serracchioli et al., 2010</i> <sup>13</sup>	56	36	8	0
<i>Rozsnyai et al., 2011</i> <sup>12</sup>	30	25	0	0

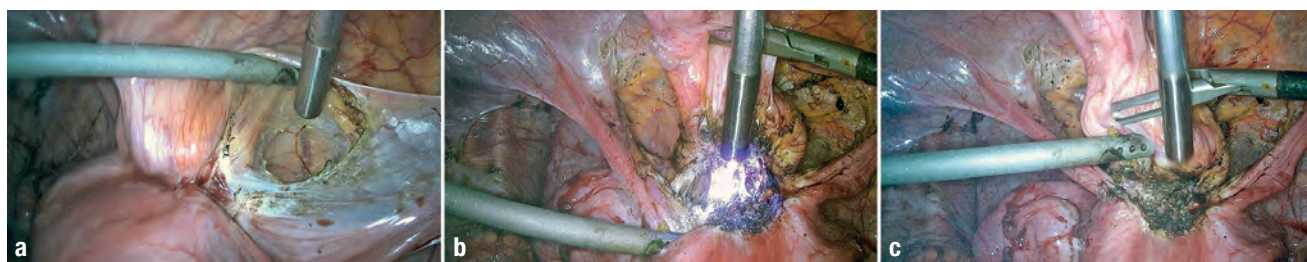
**Table 5.5** Studies describing the conservative laparoscopic management of urinary tract endometriosis.



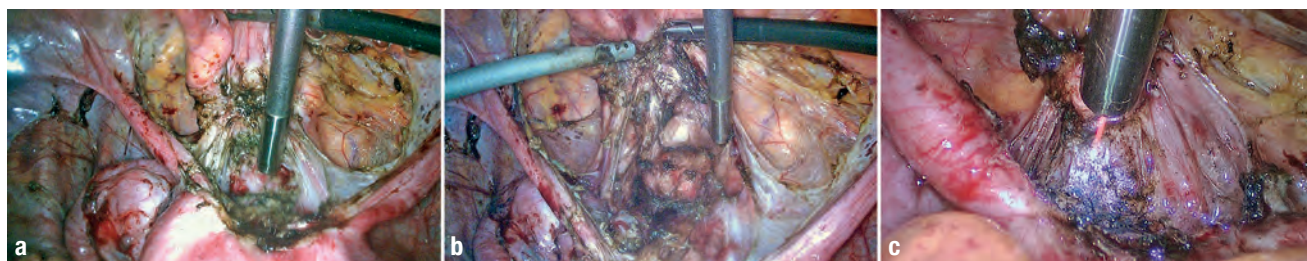
The procedure starts by opening the paravesical spaces close to the lateral wall of the bladder on each side (Fig. 5.29a). Once contact with the uterus is made, the nodule must be separated from the anterior uterine wall (Fig. 5.29b). The dissection proceeds in contact with the uterus by superficially shaving the anterior uterine wall down to the vesicouterine space (Fig. 5.29c). This can be accomplished by dissecting the adherent tissue while the uterus is retroflexed and the bladder dome is pulled upward with a grasper (Fig. 5.29c). It is important to keep the dissection medial since the distal portion of the ureters is in most cases retracted toward the midline. Dissection should not go any lower than the superior limit of the trigone to avoid bladder denervation. The plane of dissection can be exposed by applying gentle traction. This plane exists when the nodule originates in the anterior cul-de-sac, similar in some ways to a type 1 rectovaginal nodule (Fig. 5.26).<sup>7</sup> There is no dissection plane between the nodule and uterus when the bladder is infiltrated by adenomyoma; in this case dissecting inside the uterus may result in excising part of the anterior uterine wall, which could adversely affect fertility (Fig. 5.27).

The last step in the dissection aims at reaching the healthy vesicovaginal space located beneath the nodule (Fig. 5.30a). The surgeon can guide this step by intraoperative transvaginal palpation of the anterior fornix (Fig. 5.30b). In our experience, when dissection is performed with a PlasmaJet® device (Plasma Surgical Inc., Roswell, GA, USA), the kinetic energy of the plasma jet separates soft tissues located ahead and enhances the dissection by identifying the underlying vesicovaginal space (Fig. 5.30c). Care should be taken to avoid inadvertent opening of the vagina, as this would increase the risk of postoperative vesicovaginal fistula.

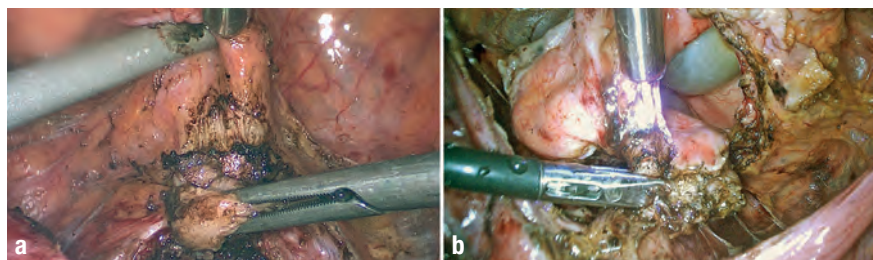
Once the bladder is completely freed, the limits of the endometriotic nodule are defined by first dissecting into normal soft tissue adjacent to the firmer nodule (Fig. 5.31a). The nodule is then dissected along its circumference and undermined by incising normal muscularis (Fig. 5.31b) until complete removal is achieved in a partial-thickness or full-thickness resection (Fig. 5.32). Once the bladder is opened, laparoscopic inspection can identify the limits of mucosal infiltration along with the bladder trigone and ureteral orifices (Fig. 5.33).



**Fig. 5.29a–c** Opening the paravesical space (a). The bladder nodule is dissected from the anterior uterine wall (b). Shaving of the anterior uterine wall. This provides access to the vesicouterine space (c).



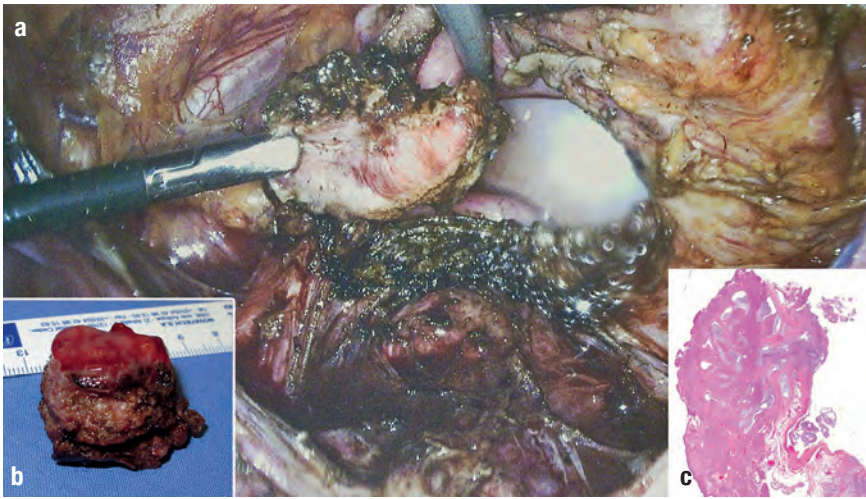
**Fig. 5.30a–c** Laparoscopic view of the healthy vesicovaginal space located beneath the dissected nodule (a). The vesicovaginal space is opened by concurrent palpation of the anterior fornix (b). Dissection is performed using plasma energy (c).



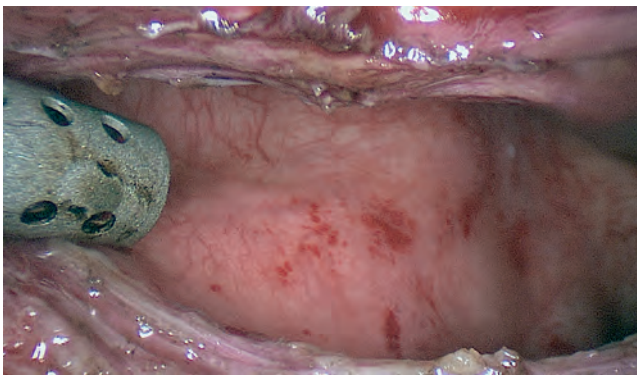
**Fig. 5.31a,b** The nodule is identified, and normal bladder tissue adjacent to the nodule is incised (a). The bladder nodule is dissected along its circumference and undermined to normal muscularis (b).

These steps can be accomplished with a monopolar hook, harmonic scalpel, plasma energy device, or bipolar forceps and scissors. We routinely employ a plasma energy device, which can enhance the dissection, free adhered tissues, and provide a highly controlled, superficial-to-deep thermal effect with no lateral diffusion.

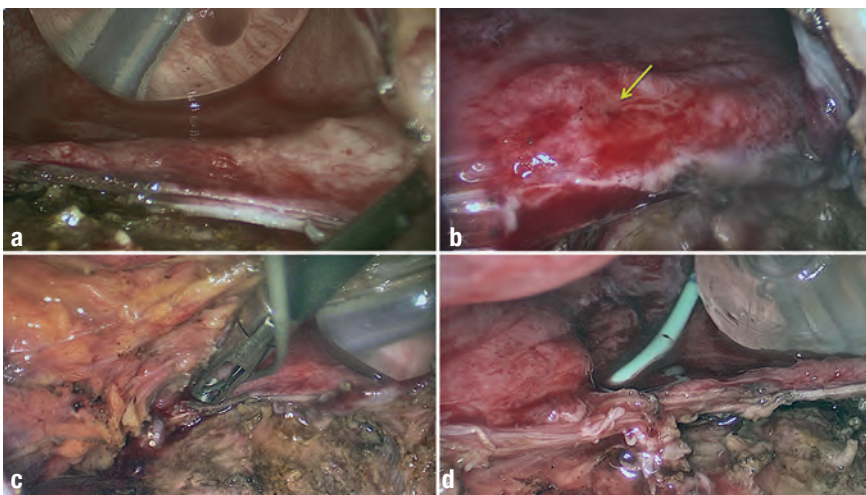
When endometriotic lesions are large, located on the bladder trigone, or in close contact with the ureteral orifices, we place ureteral double-J stents before or during the procedure (Fig. 5.34) to avoid direct ureteral injury and reduce the risk of ureteral fistula due to thermal diffusion. Indeed, the major



**Fig. 5.32** Complete excision of the bladder nodule (a). Bladder nodule specimen following resection (b). Histologic section from the excised nodule (c).



**Fig. 5.33** Laparoscopic view of the internal bladder mucosa. The trigone area and ureteral orifices are identified.



**Fig. 5.34** Double-J stents are placed to facilitate identification of the ureteral orifices (a, c, d). Internal view of the bladder displaying the ureteral orifice (arrow) (b).

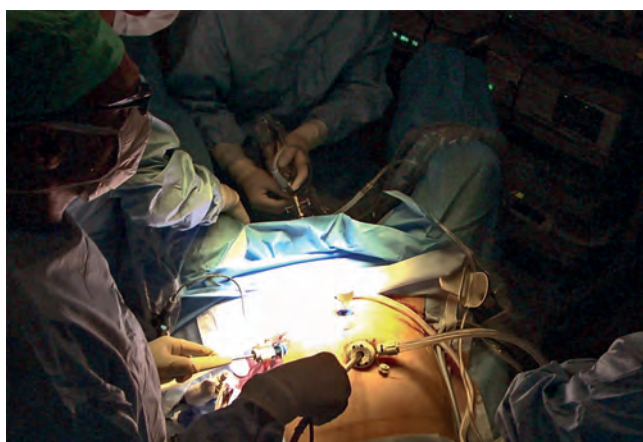

risk is damage to the distal, intramural segment of the ureter. We employ a combined cystoscopic-laparoscopic approach at these challenging sites (Fig. 5.35).<sup>10</sup> This approach requires a multidisciplinary team including a gynecologist and a urologist. This strategy allows for complete resection of the lesion while preserving a maximum amount of healthy bladder tissue and avoiding ureteral injury. Cystoscopy is performed by the urologist, who circumscribes the lesion with monopolar or bipolar current, enabling a complete resection close to the limits of bladder infiltration (Fig. 5.36). Subsequent steps are performed by laparoscopy as described above.

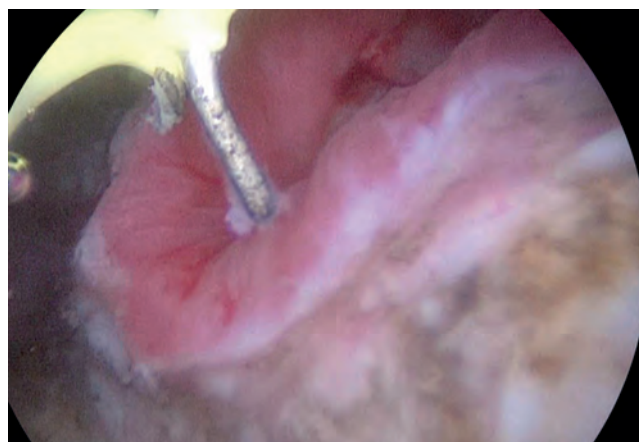The bladder is reapproximated in two layers with absorbable running sutures (Fig. 5.37a). Prior to suturing, the retropubic space (called also the space of Retzius) can be widely opened to reduce traction on the suture line during healing (Fig. 5.37b).

The first suture line reapproximates the muscularis layer, while the second suture line reinforces and supports the area. While a running suture may be adequate in most cases, interrupted sutures may sometimes be necessary to allow better approximation of tissue margins. A running suture may be placed transversally or longitudinally. The sutures can be tied with intra- or extracorporeal knots (Fig. 5.38).

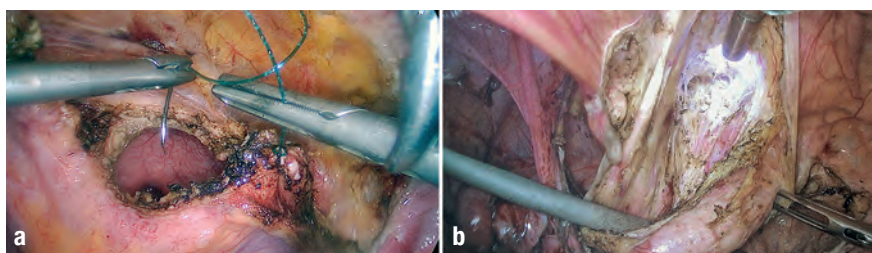
Finally the bladder is distended to confirm a watertight seal. The uterus can then be anteverted to treat associated endometriosis lesions.



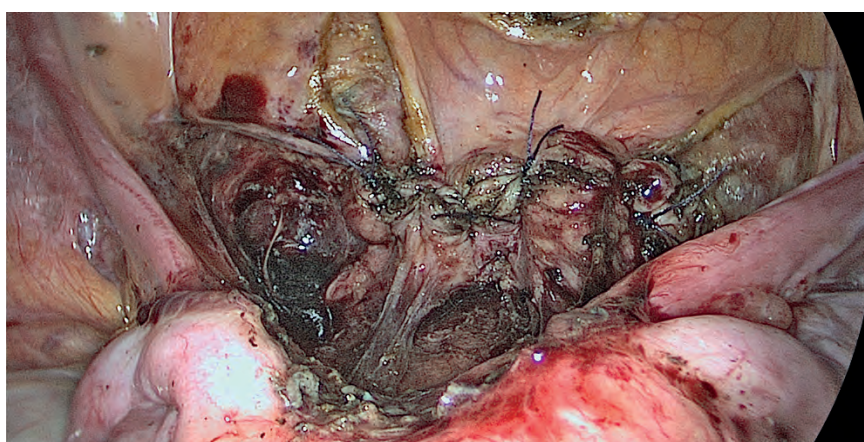
**Fig. 5.35** View of the OR team and external surgical field during a combined cystoscopic-laparoscopic approach.



**Fig. 5.36** The boundaries of the bladder nodule are delineated by cystoscopy.



**Fig. 5.37a,b** The bladder is reapproximated in two layers with absorbable running sutures (a). In order to reduce traction on the suture line during healing, the space of Retzius may be widely opened before suturing is initiated (b).



**Fig. 5.38** The sutures are tied with intra- or extracorporeal knots.



### 5.5.3.2 Postoperative Care

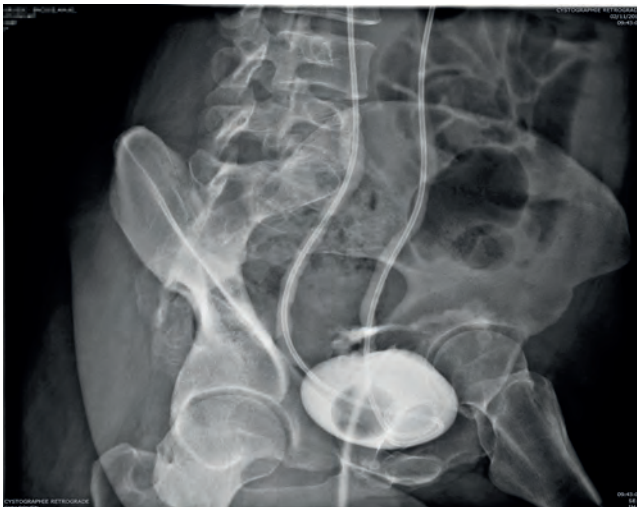The urinary catheter should be closely monitored for patency during the postoperative period, since catheter blockage and bladder distention could cause suture dehiscence. A retrograde cystogram is obtained at 7–10 days. If the bladder is watertight at that time, the catheter can be removed. Post-void residual urine volume is carefully assessed by a bedside bladder scan following removal of the urinary catheter to rule out bladder atony. Persistent residual volumes greater than 100cc would necessitate temporary intermittent catheterization, which can usually be discontinued within a few weeks. In our experience, temporary treatment with an alpha-blocker (Xatral®, alfuzosin, 10 mg/day) is indicated during intermittent catheterization, since ureteral sphincter tonus may be increased after surgery.

If the cystogram shows incomplete healing (Fig. 5.39), the urinary catheter can be left in place for another 7 days and another retrograde cystogram obtained before considering catheter removal. If the bladder has not healed by one month, a second surgery can be discussed depending on the size of

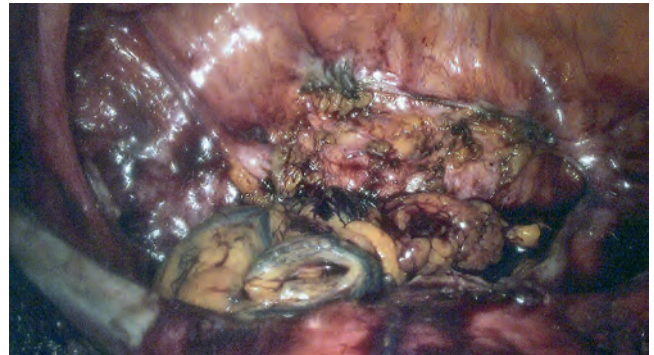
the bladder defect. However, the surgeon should note that this procedure is usually challenging due to the friable consistency of the bladder tissue. In performing a secondary bladder closure, we use widely spaced interrupted sutures reinforced by an anterior omentoplasty (Fig. 5.40).

### 5.5.4 Role of Robotic and Single-Port Surgery in the Treatment of Bladder Endometriosis

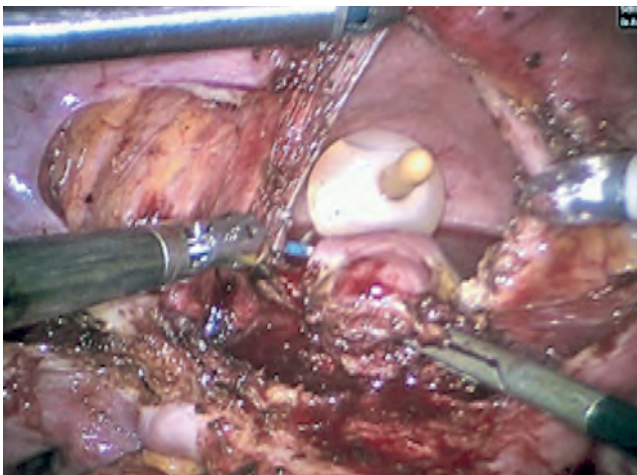
Robotic assistance can facilitate some steps in the surgical procedure, especially the placement of bladder sutures. For skilled laparoscopic surgeons, however, no major benefit is apparent. No study has documented a definite advantage of robotic assistance over conventional laparoscopy in terms of postoperative outcomes (Fig. 5.41). With regard to single-port laparoscopy, our practice has shown that dissection is time-consuming and bladder suturing is technically demanding (Fig. 5.42). Our clinical experience and the literature to date do not support a recommendation for single-port access surgery in the treatment of endometriotic bladder nodules.



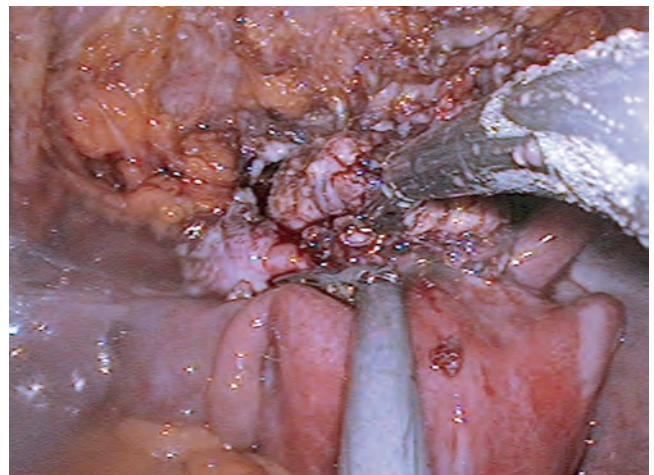
**Fig. 5.39** The cystogram presents with signs of incomplete healing.



**Fig. 5.40** In a secondary bladder closure, the authors prefer the use of widely spaced interrupted sutures which are reinforced by an anterior omentoplasty.



**Fig. 5.41** Bladder endometriosis being managed via robotic-assisted laparoscopy.



**Fig. 5.42** Treatment of bladder endometriosis using a single-port laparoscopic approach.

### 5.5.5 Postoperative Complications

Complications may include infection and injury to adjacent organs. There is a risk of injury to the ureter, especially the distal intramural segment, which in most cases is retracted medially by the fibrotic endometriosis mass. Intraoperative injuries can be repaired either by direct suture of the ureter or by reimplanting the ureter into the bladder. Delayed complications may include ureteral fistula due to thermal injury, vesicovaginal fistula, or bladder dysfunction. Each of these complications requires specific management, and a more detailed description would exceed our present scope.

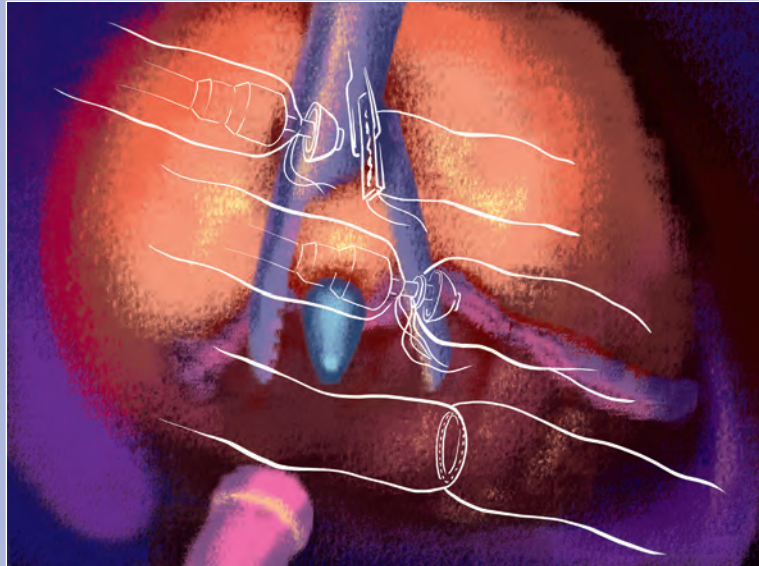
### 5.5.6 Conclusion

Surgical treatment of bladder endometriosis is feasible for the majority of laparoscopic surgeons and usually yields good functional outcomes and symptom relief. In most cases the surgical technique is reproducible, with an average operating time of one hour. It is unnecessary to have a urologist on the surgical team. Nevertheless, surgeons should be aware of the technical difficulty of dealing with large, low nodules in close proximity to the ureteral orifices and bladder trigone, which are associated with a significant risk of complications. Cases of this kind should be treated at tertiary referral centers where experienced, multidisciplinary teams are available for complex surgical procedures with substantially less risk of delayed complications and unfavorable outcomes.

### 5.5.7 References

- ANTONELLI A, SIMEONE C, CANOSSO E, ZANI D, SACCONI T, MININI G et al. Surgical approach to urinary endometriosis: experience on 28 cases. *Archivio italiano di urologia, andrologia organo ufficiale [di] Societa italiana di ecografia urologica e nefrologica/Associazione ricerche in urologia* 2006;78(1):35–8.
- CHAPRON C, DUBUISSON JB. Laparoscopic management of bladder endometriosis. *Acta obstetrica et gynecologica Scandinavica* 1999;78(10):887–90.
- CHAPRON C, DUBUISSON JB, JACOB S, FAUCONNIER A, COSTA VIEIRA M DA. [Laparoscopy and bladder endometriosis]. *Gynecologie, obstetrique & fertilité* 2000;28(3):232–7.
- COLLINET P, MARCELLI F, VILLERS A, REGIS C, LUCOT JP, COSSON M et al. [Management of endometriosis of the urinary tract]. *Gynecologie, obstetrique & fertilité* 2006;34(4):347–52. doi:10.1016/j.gyobfe.2006.02.014.
- DARWISH B, LELEUP G, MARTIN C, ROMAN H. Our experience with long-term triptorelin therapy in a large endometriosis nodule arising in an episiotomy scar. *Gynecologie, obstetrique & fertilité* 2015;43(11):757–8. doi:10.1016/j.gyobfe.2015.09.008.
- FRENNA V, SANTOS L, OHANA E, BAILEY C, WATTIEZ A. Laparoscopic management of ureteral endometriosis: our experience. *Journal of minimally invasive gynecology* 2007;14(2):169–71. doi:10.1016/j.jmig.2006.09.009.
- KONINCKX PR, MARTIN DC. Deep endometriosis: a consequence of infiltration or retraction or possibly adenomyosis externa? *Fertility and sterility* 1992;58(5):924–8.
- NEZHAT C, NEZHAT F, NEZHAT CH, NASSERBAKHT F, ROSATI M, SEIDMAN DS. Urinary tract endometriosis treated by laparoscopy. *Fertility and sterility* 1996;66(6):920–4.
- NEZHAT CH, MALIK S, OSIAS J, NEZHAT F, NEZHAT C. Laparoscopic management of 15 patients with infiltrating endometriosis of the bladder and a case of primary intravesical endometrioid adenocarcinoma. *Fertility and sterility* 2002;78(4):872–5.
- ROMAN H, ARAMBAGE K, PASQUIER G, RESCH B, HUET E. Combined cystoscopic and laparoscopic approach in deep endometriosis of the bladder. *Journal of minimally invasive gynecology* 2014;21(6):978–9. doi:10.1016/j.jmig.2014.02.009.
- ROMAN H, SAINT GHISLAIN M, MILLES M, MARTY N, HENNETIER C, MOATASSIM S et al. Improvement of digestive complaints in women with severe colorectal endometriosis benefiting from continuous amenorrhoea triggered by triptorelin. A prospective pilot study. *Gynecologie, obstetrique & fertilité* 2015;43(9):575–81. doi:10.1016/j.gyobfe.2015.07.001.
- ROZSNYAI F, ROMAN H, RESCH B, DUGARDIN F, BERROCAL J, DESCARGUES G et al. Outcomes of surgical management of deep infiltrating endometriosis of the ureter and urinary bladder. *JSLs Journal of the Society of Laparoendoscopic Surgeons/Society of Laparoendoscopic Surgeons* 2011;15(4):439–47. doi:10.4293/108680811x13176785203798.
- SERACCHIOLI R, MABROUK M, MONTANARI G, MANUZZI L, CONCETTI S, VENTUROLI S. Conservative laparoscopic management of urinary tract endometriosis (UTE): surgical outcome and long-term follow-up. *Fertility and sterility* 2010;94(3):856–61. doi:10.1016/j.fertnstert.2009.04.019.
- THONNON C, PHILIP CA, FASSI-FEHRI H, BISCH C, COULON A, SAINT-HILAIRE P DE et al. Three-dimensional ultrasound in the management of bladder endometriosis. *Journal of minimally invasive gynecology* 2015;22(3):403–9. doi:10.1016/j.jmig.2014.10.021.

# 6 General Surgical Approach



6.1	Diagnosis of Bowel Endometriosis .....	424
6.2	Surgical Management of Recto-Sigmoid Endometriosis – Resection Using EEA Stapler .....	429
6.3	Bowel Surgery in Deep Infiltrating Endometriosis .....	436



## 6.1

## Diagnosis of Bowel Endometriosis

Mathias S.S. Löhnert<sup>a</sup> | J. Marek Doniec<sup>b</sup>

## 6.1.1 Introduction

Endometriosis, one of the most common diseases in gynecology, is often associated with therapeutic setbacks or failures that can be very frustrating for patients and their doctors. Almost 10% of all menstruating females suffer from endometriosis. Although it is a benign disease, pain and discomfort can significantly compromise a patient's quality of life in the long term. The incidence of endometriosis in infertile patients rises to 15–20%.<sup>3</sup>

The staging of endometriosis is usually based on the four-part classification of the *American Society for Reproductive Medicine (ASRM)*.<sup>7</sup> Patients with stage IV disease often suffer from dysmenorrhea, infertility, and diffuse abdominal, pelvic, anal and lower back pain. Symptoms occur predominantly during the menstrual or perimenstrual phase and may take a chronic course.<sup>1,4</sup> If the gastrointestinal tract is involved, endometriosis most commonly affects the rectum and is often associated with anal bleeding and related pain,<sup>8</sup> even though transanal bleeding cannot be singled out as being pathognomonic for bowel endometriosis. To date, the recommended treatment option for rectal endometriosis is still laparotomy with bowel resection, whereas a laparoscopic approach is the preferred method for other cases of deep infiltrating endometriosis.<sup>1,4,6</sup> This underscores the importance of accurate preoperative staging, including the precise localization of extragenital endometriotic foci and possible involvement of the rectal wall.

## 6.1.1.1 Is Endoscopic Screening Sufficient?

Rectal endometriosis should be suspected in any woman presenting with pelvic pain associated with defecation or rectal filling and/or transanal bleeding, the latter sometimes occurring synchronously with menstruation. Rectoscopy or colonoscopy can detect intramucosal endometriosis, sometimes accompanied by submucosal involvement, appearing as protrusions of the mucosa caused by the presence of cystic areas. Intramucosal or submucosal endometriosis accounts for

20% of all bowel involvement by endometriosis, because most rectal endometriotic foci are located in the muscularis propria or directly adjacent to the bowel wall. Thus, approximately 80% of all bowel endometriosis is not accessible to digital palpation or endoscopy, and pelvic imaging techniques are necessary for further investigation in patients with suspected rectal endometriosis.

MR and CT imaging of the pelvis are known to have an accuracy of approximately 70% in the diagnosis of rectal endometriotic infiltration.<sup>5</sup> Endorectal ultrasound (ERUS) offers high resolution images of the rectal wall and perirectal structures and can accurately depict each layer of the rectal wall. Accordingly, ERUS has become a widely accepted modality for the pretherapeutic staging of rectal and anal cancer, with an accuracy of more than 85% for the staging of local intra- and extramural extension of malignant tumors.<sup>2</sup> Detection of a discontinuity in the layered structure of the bowel wall correlates strongly with involvement of the affected layers. In cancer surgery, the greatest disadvantage of ERUS is its inability to differentiate between direct cancer invasion and perirectal inflammatory changes that mimic the malignant invasion of deeper layers. Thus, approximately 10% accuracy is lost in detecting infiltration of the submucosa and muscularis propria. In cancer treatment, of course, staging a lesion as T1 versus T2 has a direct impact on the surgical procedure of choice, i.e., limited excision or radical surgery. But in the case of endometriosis, poor discrimination between inflammatory changes and endometriotic tissue has no impact on surgical treatment as there is no need for the resection of perirectal lymph nodes. Thus, ERUS can clearly identify affected bowel wall layers to determine whether excision is feasible without opening the bowel, or it would be better to proceed with a segmental resection.

Gastroenterologists prefer endoluminal ultrasound with a flexible probe mounted on the tip of a flexible fiberscope, as commonly used in upper gastrointestinal (GI) endosonography. The use of flexible ultrasound probes extends the access range to the colon and has become a widely accepted modality in gastroenterology units. Colorectal surgeons favor ERUS using a rigid probe that can be introduced directly or through a preplaced rectoscope. Rigid ERUS probes are cheaper, do not require a videoendoscopy unit, provide accurate lesion detection, and allow the surgeon to measure the distance to the anal verge and sphincter muscles for planning a sphincter-sparing procedure. In addition, 3D data acquisitions with rigid probe units are simplifying the preoperative visualization of endometriotic foci and their relation to the rectal wall.

<sup>a</sup> | Professor Dr. hc. (TashPMI), Dr. med. habil.,  
Department of General and Colorectal Surgery,  
Clinical Center Bielefeld, Germany

<sup>b</sup> | MD; Private Office for Endoscopic Gastroenterology  
and Proctology, Kiel, Germany

## Corresponding author:

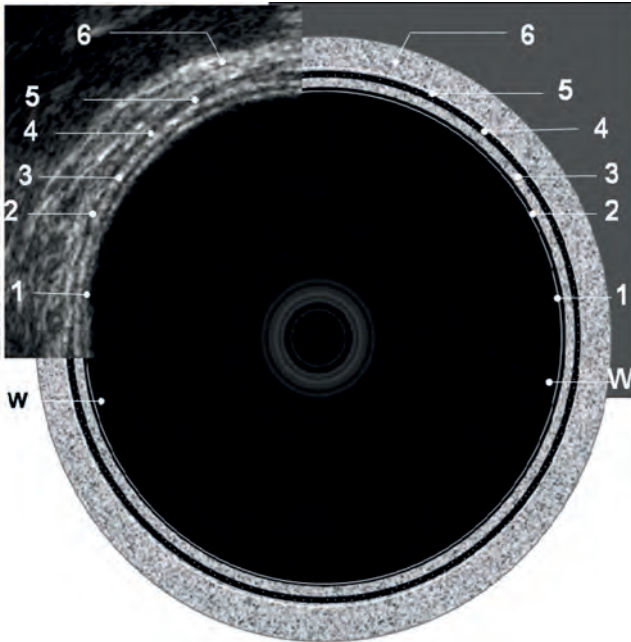
## Mathias Löhnert

Prof. Dr. hc (TashPMI) Dr. med. habil.  
Facharzt für Chirurgie, Schwerpunkt Viszeralchirurgie,  
Proktologie Klinikum Bielefeld Rosenhöhe –  
Klinik für Allgemeinchirurgie und Koloproktologie  
An der Rosenhöhe 27  
33659 Bielefeld, Germany  
E-mail: mathias.loehnert@klinikumbielefeld.de

### 6.1.2 Endorectal Ultrasound – Anatomic Structures and Findings in Endometriosis Patients

The rigid ultrasound probe is introduced via a rectoscope positioned at the rectosigmoid junction. When a 7.5-, 10.0- or 20.0-MHz probe is used, the sonogram displays the bowel wall with three anatomic layers and two artificial layers. Starting from the innermost (luminal) aspect, the **first layer** is a hyperechoic artificial ring formed by the interface between the water-filled balloon covering the ERUS probe and the mucosa. Next comes a hypoechoic ring (**second layer**) representing the

mucosa of the bowel wall. The second hyperechoic ring (**third layer** of the wall) consists of the submucosa and a second interface between the submucosa and muscularis propria. The second hypoechoic ring (**fourth layer** of the wall) corresponds to the muscularis propria and is surrounded by the outer (third) artificial hyperechoic ring (**fifth layer**), which is formed by the interface between the muscularis propria and perirectal fat or serosa (Fig. 6.1).



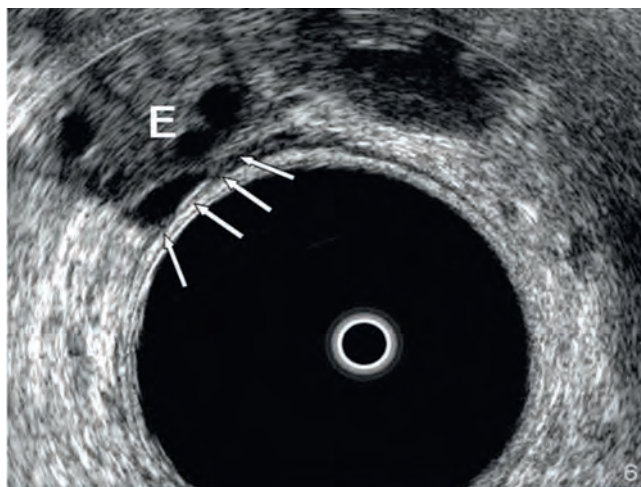
**Fig. 6.1 Normal endorectal sonogram:**

Water (**W**); hyperechoic interface between water-filled balloon and mucosa (**1**); hypoechoic mucosa (**2**); hyperechoic submucosa and interface between submucosa and muscularis propria (**3**); hypoechoic muscularis propria (**4**); hyperechoic margin between muscularis propria and perirectal region or serosa (**5**); fatty tissue (**6**).

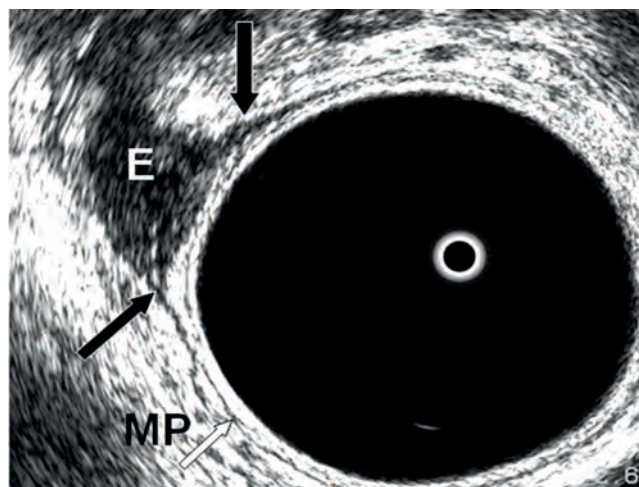
Diagnostic modality	Advantages	Disadvantages
Endoscopy	Reveals intraluminal findings with high accuracy.	Peri- or intramural masses are detectable only by their visible mass effect. No differentiation from adjacent and infiltrating tumors.
X-ray	Reveals intraluminal findings with high accuracy.	Peri- or intramural masses are detectable only by their visible mass effect.
CT	Reveals intra- and extraluminal findings.	Poor accuracy in differentiating between adjacent invading perimural tumors.
MRI	Accurate depiction of tumor site and involved mural layers. Both intra- and perimural masses are detectable.	Very high cost. Only intrarectal MRI probe provides accuracy comparable to endosonography.
Flexible ERUS	Accurate depiction of tumor site and involved mural layers. Both intra- and perimural masses are detectable. Permits lesion detection into the colon.	High cost, measurement of distance to anal canal is not accurate. Accuracy is examiner-dependent.
Rigid ERUS	Accurate depiction of tumor site and involved mural layers. Both intra- and perimural masses are detectable. Low cost. Accurate measurement of distance to anal canal.	Accuracy is examiner-dependent. Scanning is limited to the rectum and rectosigmoid.

**Table 6.1** Diagnostic imaging modalities used in the preoperative assessment of pelvic endometriosis.

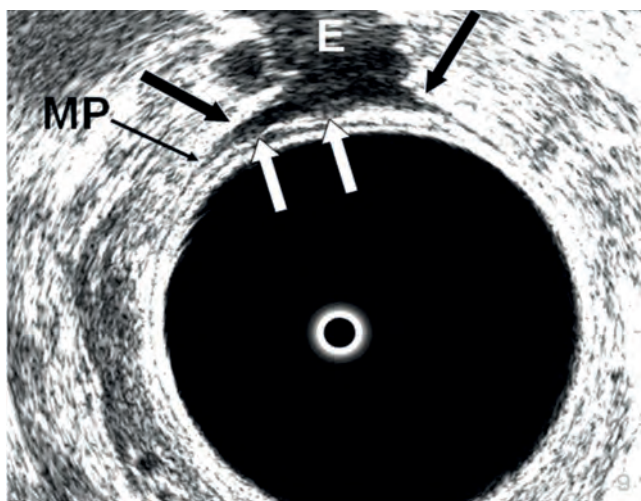
Key to acronyms: Computed Tomography (CT); Magnetic Resonance Imaging (MRI); Endorectal Ultrasound (ERUS).



**Fig. 6.2** ERUS image of an endometriotic mass (E) (approximately 2 cm) in the cul-de-sac adjacent to the rectal wall. The third hyperechoic layer between the muscularis propria and perirectal region ( $\Rightarrow \Rightarrow$ ) is intact and not thickened. This finding excludes involvement of the rectal wall.



**Fig. 6.3** ERUS image of an endometriotic mass (E) (approximately 1.5 cm) infiltrating the rectal wall (between  $\blackrightarrow$ ). The third hyperechoic layer, the muscularis propria (MP,  $\Rightarrow$ ), is thickened, indicating involvement, and cannot be differentiated from the mass. This finding indicates rectal wall involvement with infiltration of the muscularis propria. Normal muscularis propria (MP, second hypoechoic layer).



**Fig. 6.4** ERUS image of an endometriotic mass (E) (approximately 2.5 cm) infiltrating the rectal wall (between  $\blackrightarrow$ ). The third hyperechoic layer, the muscularis propria (MP,  $\blackrightarrow$ ), is thickened, indicating involvement, and cannot be differentiated from the mass. The second hyperechoic layer is irregular ( $\Rightarrow \Rightarrow$ ). These findings indicate rectal wall involvement with infiltration of the muscularis propria and submucosa. Normal muscularis propria (MP, third hypoechoic layer).

ERUS finding	Total	Laparotomy	Laparoscopy	Conservative treatment
No abnormalities	13	2	4	7
Pelvic mass not in contact with the rectal wall	21	6	10	5
Mass abutting the rectal wall	12	4	7	1
Rectal wall infiltration	39	25	7	7
M. propria	32	20	6	6
Submucosa	7	5	1	1

**Table 6.2** Results of ERUS in 85 patients with suspected rectal involvement by endometriosis and correlation with treatment (conventional laparotomy, laparoscopy, or no surgery). The overall sensitivity of ERUS for rectal wall involvement was 97%.



The imaging appearance of (para)rectal endometriosis depends on the activity of the lesion. Active endometriotic lesions are hypoechoic and include cystic changes, while inactive lesions show heterogeneous echogenicity due to fibrosis. It is very common to find coexisting active and inactive lesions in one patient, so ERUS findings are normally irregular with a mixed hypoechoic and hyperechoic pattern. An asymmetric appearance of perirectal structures with mixed echogenicity in premenopausal women is always suspicious for perirectal endometriosis. This diagnosis can be established by correlating ultrasound findings with the clinical presentation.

The staging of ERUS findings in endometriosis is outlined below.

**Stage 1:** No relation to the rectal wall, pararectal endometriosis without rectal involvement. ERUS shows asymmetric mixed echogenicity in the perirectal fat. No direct contact with bowel wall structures is observed. The outer hyperechoic (fifth) layer of the bowel wall is not disrupted, and there is no evidence of intramural infiltration.

**Stage 2:** Endometriotic tissue is in direct contact with the bowel wall. ERUS shows no disruption of the outer hyperechoic layer, which excludes involvement of the rectal wall (Fig. 6.2).

**Stage 3:** Infiltration of the bowel wall is detectable by ERUS. The depth of infiltration should be noted:

- Infiltration into the **muscularis propria** is characterized by disruption of the hyperechoic fifth layer and thickening of the hypoechoic fourth layer (muscularis propria). The hyperechoic third layer (interface) remains intact and is not interrupted (Fig. 6.3).
- Infiltration of the **submucosa**: The suspected endometriotic tissue is in the third hyperechoic layer or has spread directly through the outer layers into the third layer. In this case, the submucosa, represented by the third layer, shows an irregular shape with hypoechoic areas in the hyperechoic layer (Fig. 6.4).
- Infiltration of the **mucosa**: Endometriosis directly involves the mucosa (second hypoechoic layer) or the mucosa and submucosa (disruption of the hyperechoic second layer by a hypoechoic or heterogeneous structure). Full-thickness infiltration through all the outer layers into the hypoechoic second layer indicates involvement of the whole bowel wall.

In our own series, the sensitivity of ERUS imaging for defining the depth of rectal wall infiltration was 76 % percent (20/26). Sensitivity for the muscularis propria was 97 % (26/27). Overall sensitivity for rectal wall infiltration was 97 % (26/27).<sup>2</sup>

### 6.1.3 Management of Rectal Endometriosis

Every patient with transrectal bleeding should have a complete colonoscopy to exclude cancer, polyps, and inflammatory disease. If the history suggests external endometriosis as a possible cause of symptoms (menstruation-associated rectal bleeding, anal/pelvic pain, or suspicious pararectal findings by bimanual examination and/or endovaginal ultrasound), ERUS should be performed to detect or exclude endometriosis in the pararectal region. ERUS results are correlated with examiner experience, so the procedure requires an experienced colorectal surgeon who is used to performing ERUS routinely.

If ERUS demonstrates stage 1 or 2 endometriosis (unrelated to the bowel wall or abutting the wall without disrupting the outer hyperechoic layer), the treatment of first choice is primary laparoscopy performed by a gynecologic surgeon without colorectal assistance.

If ERUS is suspicious for rectal infiltration (stage 3), laparoscopic resection of a rectal wall segment should be performed with the simultaneous help of a colorectal surgeon. In some cases, if the endometriotic mass is less than 10 mm in diameter, the resection can be performed with a linear stapler to cut off a limited portion of the bowel wall and reapproximate the wall in one step.

With an endometriotic mass larger than 10 mm, the infiltration depth does not interfere with the type of resection. In most cases, an anterior rectal resection is necessary for the complete removal of all affected tissue. Experienced colorectal surgeons can perform a low anterior rectal resection laparoscopically, so the preferred approach will depend largely on the skills of the surgeon. Conventional resection can be considered in all advanced cases with extensive involvement of the lower third of the rectum in order to preserve the sphincter.

If ERUS confirms the presence of well-circumscribed endometrial lesions that are confined to the mucosa and/or submucosa without affecting the muscularis propria, an endoscopic approach may be considered. A mucosal lesion less than 3 cm in diameter can be treated by endoscopic mucosal resection, similar to a polypectomy. If submucosal spread is found, the authors recommend an endoscopic submucosal dissection as the treatment of choice.

### 6.1.4 Conclusion

ERUS is a useful, noninvasive diagnostic tool in endometriosis, especially in patients with proven or suspected endometriosis involving the bowel wall.

ERUS can safely stratify cases that are appropriate for an endoscopic approach, laparoscopy without bowel resection, a laparoscopic segmental bowel resection, or conventional rectal resection. ERUS provides high sensitivity and specificity for rectal involvement by endometriosis and is recommended in every patient with suspected extragenital pelvic endometriosis.

### 6.1.5 References

1. CHAPRON C, DUBUISSON JB. Management of deep endometriosis. *Ann N Y Acad Sci* 2001;943:276–80.
2. DONIEC JM, KAHLKE V, PEETZ F, SCHNIEWIND B, MUNDHENKE C, LOEHNERT MS et al. Rectal endometriosis: high sensitivity and specificity of endorectal ultrasound with an impact for the operative management. *Dis Colon Rectum* 2003;46(12):1667–73. doi:10.1097/01.DCR.0000093605.32384.07.
3. FARINON AM, STROPPA I, CHIARELLI C. Therapy of colorectal endometriosis. *Colo Proctology* 1992;14:230–4.
4. KONINCKX PR, MARTIN DC. Surgical treatment of deeply infiltrating. In: Shaw RW, editor. *Endometriosis. Current Understanding and Management*. Oxford: Blackwell Scientific; 1995. p. 264–81.
5. ROSEAU G, DUMONTIER I, PALAZZO L, CHAPRON C, DOUSSET B, CHAUSSADE S et al. Rectosigmoid endometriosis: endoscopic ultrasound features and clinical implications. *Endoscopy* 2000;32(7):525–30. doi:10.1055/s-2000-9008.
6. SCHRODER J, LOEHNERT M, DONIEC JM, DOHRMANN P. Endoluminal ultrasound diagnosis and operative management of rectal endometriosis. *Dis Colon Rectum* 1997;40(5):614–7.
7. THE AMERICAN FERTILITY SOCIETY. Revised American Fertility Society classification of endometriosis: 1985. *Fertil Steril* 1985;43(3):351–2.
8. ZWAS FR, LYON DT. Endometriosis. An important condition in clinical gastroenterology. *Dig Dis Sci* 1991;36(3):353–64.

## 6.2

## Surgical Management of Recto-Sigmoid Endometriosis – Resection Using EEA Stapler

John E. Morrison<sup>a</sup>

### 6.2.1 Introduction

Endometriosis can involve the distal sigmoid colon and rectum. Most patients with this problem will present with rectal bleeding, tenesmus, urge and or pain with defecation raising the index of suspicion for colon or rectal involvement. When endometriosis is found to involve the distal sigmoid or rectum, adequate treatment usually necessitates resection of any area affected by the disease and this often includes the rectosigmoid area as the pouch of Douglas is frequently involved. The involved area may either be resected primarily with primary closure or – given more extensive involvement particularly with stenosis of the bowel – segmental resection of the affected bowel may be preferable.

The decision on whether the area can be primarily closed or resected is determined by the extent to which the bowel lumen is involved. Any resection to be performed in a patient with over 50% lumen involvement, requires segmental resection with primary anastomosis. Trying to close this primarily will result in stenosis of the bowel lumen. When the involved segment is the intraperitoneal colon, sigmoid or proximal colon, standard techniques of anastomosis apply: either a side-to-side functional end-to-end anastomosis stapled or hand-sewn or end-to-end anastomosis can be performed depending on the surgeons' preference.

Because of the presence of a serosal layer on the intraperitoneal colon, the potential risk for leak from the anastomosis is reduced when compared to a rectal anastomosis because the rectum does not have a serosal layer.<sup>1,3,4</sup> Prior to the development of stapling technology, resection with anastomosis deep in the pelvis usually was technically difficult to accomplish. Prior to the development of an end-to-end stapler in the early 1980's, these low anastomoses were performed with hand-sewn techniques which was a difficult task as the surgeon was placing sutures in a very deep site with little room to work. The circular EEA stapler has made this a much easier feat to accomplish, however there are several unique characteristics of the stapler which are specific to the device. This chapter will deal with the proper use of the stapler and give some tips on how to increase the likelihood of a successful anastomosis. The EEA stapling device may be used in resecting lesions involving less than 50% of the bowel wall where formal segmental bowel resection has not been carried out and the following stapler principles still apply.

<sup>a</sup> MD, FACS, Associate Professor of Surgery; Department of Surgery, Louisiana State University School of Medicine, New Orleans, Louisiana; USA

#### Corresponding author:

MD, FACS; Associate Professor of Clinical Surgery  
 Section of General Surgery  
 Director of Resident Education  
 LSU Health Sciences Center, School of Medicine  
 Department of Surgery  
 1542 Tulane Avenue, 7<sup>th</sup> floor  
 New Orleans, LA, 70112, USA  
 E-mail: jmorr3@lsuhsc.edu



## 6.2.2 Important Steps in Proper Function of the EEA Stapler

There are several steps that are very important to insure that the staple line is secure. This chapter will be discussing crucial steps in using the stapler including:

- the proper positioning of the patient,
- proper alignment as well as firing of the staple device,
- and evaluation of the finished staple line.

These steps are critical to proper functioning of the EEA stapler. There are two manufacturers of the device currently, Ethicon Endo-Surgery and Covidien (Figs. 6.5a, b). There are few differences between the two staplers and the following discussion applies to both staplers with differences being pointed out when important to the proper functioning of the device.

### 6.2.2.1 Positioning of the Patient

For the stapler to be easily inserted and properly positioned in the rectosigmoid colon, the patient must be positioned in the lithotomy position. The patient's buttocks also have to extend several centimeters past the end of the table with the anorectum past the midline hole in the operating table (Fig. 6.6a).

Placement of the patient in this manner is necessary because when the stapler is inserted into the rectum it must be angled down at a very acute angle towards the operating room floor in order to safely advance the device into the rectum and sigmoid. Failure to do this will result in the inability to safely advance the stapler with the possibility of bowel injury posteriorly as the stapler is advanced under tension. This is one of the most crucial steps in preparing the patient for surgery when a low anastomosis is anticipated.

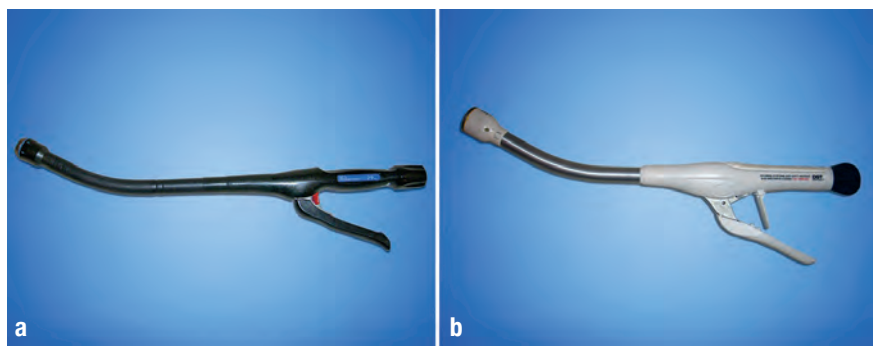
There also has to be taken into account that the patient will be in steep Trendelenberg position during the procedure (Fig. 6.6b) and with this there usually will be some shifting of the patient towards the head of the bed. If the buttocks slide up on the table to the point that the coccyx is lying over the solid portion of the bed, the surgeon will not be able to safely angle the stapler down as he or she is advancing the stapler within the lumen of the bowel without placing excessive tension on the wall of the colon. This again can result in an injury to the wall of the rectum or sigmoid that may go unrecognized.

Prior to surgery whether the patient needs to be placed on mechanical and or antibiotic bowel prep is at the present time a controversial issue. There are studies that support the use of mechanical prep and those that on analysis do not support the need for a prep. The use of oral antibiotics also is a topic that is undergoing further discussion and change in the surgical literature.<sup>2</sup> Both of these decisions should be the choice of the surgeon and are not within the scope of this chapter.

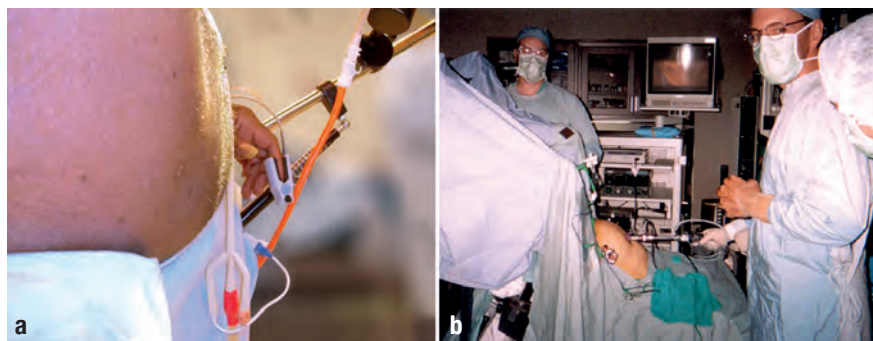
### 6.2.2.2 Mobilization of the Rectum/Sigmoid

The area of colon to be resected must be adequately mobilized and there must be a sufficient blood supply to the remaining proximal and distal segments that are to be reapproximated. Leaving a short distal segment of either rectum or sigmoid for the stapled anastomosis is preferable. This makes the advancement of the stapler much easier when reaching the distal staple line.

The rectum lies in the sacral bed giving it its natural curve. The end-to-end stapler also has a curve in order to accommodate this anatomically without putting excessive tension on the bowel as the anastomosis is being created. The length of the staple devices, from the staple line to the mechanical handle



**Fig. 6.5a,b** Ethicon Endo-Surgery EEA stapler (a). Covidien circular EEA stapler (b).



**Fig. 6.6a,b** The patient's buttocks should extend several centimeters past the end of the table with the anorectum past the midline hole in the operating table (a). Patient in steep Trendelenberg position (b).

ranges from 23 cm to 30 cm, depending on which stapler is chosen (Fig. 6.7). The Ethicon stapler (on bottom of the figure) measures 30 cm from staple line to handle while the Covidien stapler (at the top of the figure) measures 23 cm.

The rectum proper ranges in length from 10 to 15 cm beginning at the anoderm line and ending just below the sacral promontory and the anus adds another 2.5 cm to the total length of bowel that the device must clear in order to reach the staple line from transaction of the bowel. This leaves from 6 cm to 13 cm length on the stapler past the end of the true rectum for accommodation of any distal sigmoid colon left.

Mobilization of the rectum from the sacral recess gives more length for anastomosis as well as allowing easier alignment of the stapler with proximal bowel for anastomosis. It also makes available more stapler length for reaching the proximal bowel. Consideration should be given to these points when mobilizing the distal bowel segment.

### 6.2.2.3 Mobilization of Proximal Bowel

The proximal bowel that is to be attached to the rectum must be adequately mobilized so that there is no excessive tension on the anastomosis. Usually, if the proximal bowel lies in the pelvis after mobilization, with the patient still in Trendelenberg position without retracting back above the sacral promontory, this indicates adequate mobilization. In mobilizing the proximal bowel, the surgeon must keep in mind that there must also be an adequate blood supply to the bowel. Lack of tension and an adequate blood supply are the two key points to a successful outcome. A successfully completed anastomosis in the presence of poor blood supply and or tension will result in leak. Giving due attention to these two details is crucial in obtaining a good outcome.

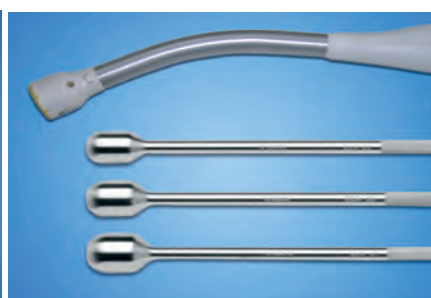There are technologies available now involving the use of dyes with special imaging and detection devices that evaluate the perfusion in the remaining segment of bowel to be anastomosed. Despite the theoretical usefulness and advantage over visualization of the bowel, there doesn't seem to be a significant reduction in leaks when using this technology. Further studies will need to be done in order to determine the usefulness of these techniques.



**Fig. 6.7** The Ethicon stapler (Ⓔ) measures 30 cm from staple line to handle while the Covidien stapler (Ⓘ) measures 23 cm.



**Fig. 6.8** Anvil of the EEA™ stapler.



**Fig. 6.9** EEA™ reusable stainless steel sizers help evaluate the inner diameter of the bowel segments to be anastomosed. The sizer heads correspond to the diameter of the stapling device.

### 6.2.2.4 Selection of Staple Size

Staplers for anastomosis are available in various sizes. The sizes range from 21 mm to 33 mm. The operating surgeon must be aware that the diameter of the anastomosis when completed by the stapler is not the outside diameter of the staple device itself.

Most surgeons when choosing an EEA stapler for colon anastomosis, use a 29 mm or greater size. The stated stapler size is the outside diameter of the staple device and does not reflect the inside luminal diameter when the anastomosis is complete. The largest-diameter stapler measures 33 mm, which when fired results in a luminal diameter of only 2.47 cm (Insert in stapler device: *EEA Stapler Covidien Inc.*, USA). This is the maximal diameter available for circular staple devices, any stapler smaller than 29 mm may result in a stricture at a later date.

When choosing the appropriate staple size for anastomosis, there are several things that need to be taken into consideration: first, the diameter of the proximal bowel that the anvil (Fig. 6.8) will be placed into is usually the limiting factor on staple choice.

The anvil is the backstop for the forming of the staples during firing of the device. In narrowed bowel such as that seen in diverticular disease, the lumen can be very stenotic and safely placing the anvil in the bowel without tearing the wall of the colon may be difficult. If this is the case, the anvil may be placed sideways in the bowel lumen instead of end-on, so that there is no stretching of the bowel wall when the anvil is secured. This results in an end-to-side anastomosis which functions just as well as an end-to-end type and is preferable to injuring of the bowel wall when trying to place an anvil that is too large for the proximal bowel. In any instance, selecting the proper size of staple for the bowel to be anastomosed cannot be emphasized too much.

Second consideration is the distal segment to be stapled to. Since this is usually the rectum in cases of severe endometriosis, the staplers usually easily fit into the rectal vault without tension. If the distal segment has sigmoid colon still present and the surgeon wishes to evaluate the lumen of the bowel on either end prior to choosing a stapler, there are sizers available to accurately evaluate the lumen of the bowel and make staple choice more accurate (Fig. 6.9). These sizers are helpful also in dilating the anal sphincter prior to inserting the staple device into the rectum.

The last consideration is the design of the staple device which must allow the two bowel segments that will be stapled to be safely compressed to 2 mm. This usually can easily be accomplished given a normal healthy bowel, but if the latter is thickened or inflamed, the staples may not adequately secure the anastomosis.

#### 6.2.2.5 Securing the Anvil

Once the staple size is determined, the anvil must be secured into the lumen of the proximal bowel in order to guarantee a secure staple line (Fig. 6.10a). The open end of the bowel must be firmly secured around the anvil post so that when the stapler is closed there is no prolapse of mucosa out of the anvil and staple line which will result in an incomplete anastomosis. Instruments have been devised to facilitate placing the suture around the anvil post, but this author and most colorectal surgeons prefer suturing the lumen closed with a monofilament suture material; i.e. polypropylene in a running baseball type of stitch around the shaft of the anvil. This helps insure that the mucosa is inverted, the lumen closed tightly around the anvil post and there is no extrusion of the proximal bowel through the staple device when it is closed (Fig. 6.10b).

#### 6.2.2.6 Placing and Opening the Stapler

The stapler is placed transrectally, advanced to the end of the distal staple line and the penetrating alignment post is opened. Fig. 6.11a demonstrates the anvil with the alignment shaft of the stapler. Prior to opening the post, the surgeon must make sure that the area on the distal bowel segment to be stapled is clear of any other structures such as bladder or bowel, so that they are not included in the staple line and to make sure that when the stapler is closed the tissues that are brought together will be approximated adequately by the staples. A key point

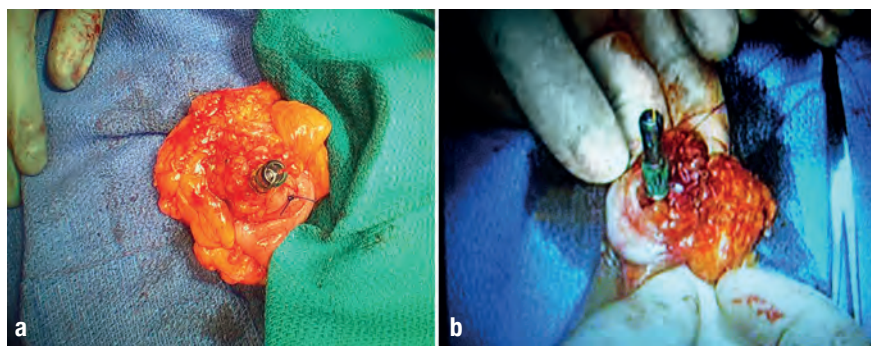
in choosing where the penetrating alignment post will come through the distal staple line is that the post emerges as close to the staple line as possible. This prevents leaving a band of devascularized tissue between the final circular anastomosis and the distal staple line which will result in a leak. An attempt should be made to incorporate as much of the distal staple line as possible in the circular stapled anastomosis (Fig. 6.11b).

Both major stapler manufacturers have a circular opening device at the end of the stapler which is clearly marked for opening and closing the device. It must be stated here that as the surgeon is opening the stapler, and as the penetrating alignment shaft is being deployed, the surgeon must be watching closely so that the shaft does not injure any surrounding structures in the pelvis. This is assisted by angling the end of the stapler as ventral as possible to avoid the sacral promontory and vascular structures surrounding that area.

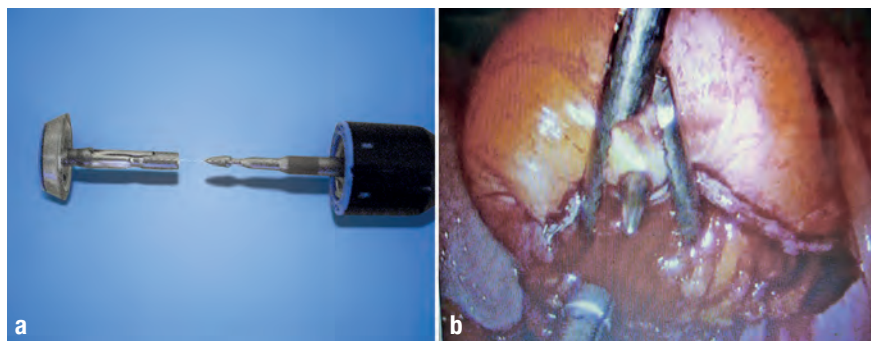
#### 6.2.2.7 Closing the Stapler

The anvil with attached proximal bowel is now aligned with the penetrating shaft of the stapler and the two devices are docked (Fig. 6.12a). As the anvil is secured firmly on the guide post of the stapler, there is a mechanical click felt when the anvil and stapler are attached properly. Also there is a color-coded line on the alignment post of the stapler that, when covered, indicates that the device is now ready to be closed and fired (Fig. 6.12b). Failure to sense the click and cover the orange line on the stapling device with the anvil shaft will result in the two ends not seating properly.

Prior to closing the stapler, the surgeon must make certain that the proximal bowel is not twisted, aligned appropriately and again that there will be no tension or other structures included in the staple line.

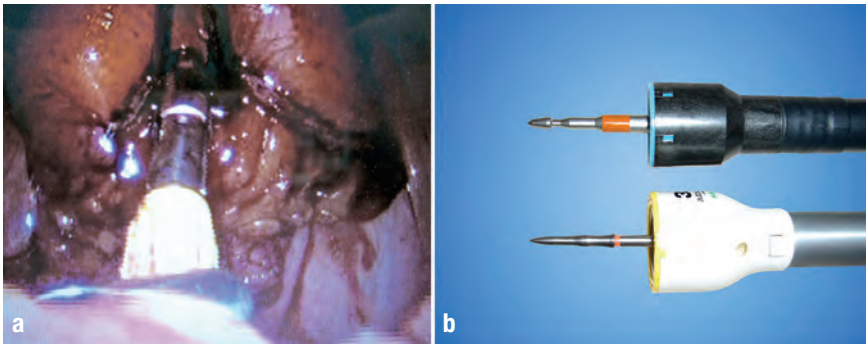


**Fig. 6.10a,b** Bowel secured to anvil (a). Securing bowel to anvil using 0-polypropylene suture (b).



**Fig. 6.11a,b** The anvil with the alignment shaft of the stapler (a). An attempt should be made to incorporate as much of the distal staple line as possible in the circular stapled anastomosis (b).






**Fig. 6.12a,b** The anvil with attached proximal bowel is now aligned with the penetrating shaft of the stapler and the two devices are docked (a). Once the color-coded line on the alignment post of the stapler is covered, this indicates that the device is ready to be closed and fired (b).

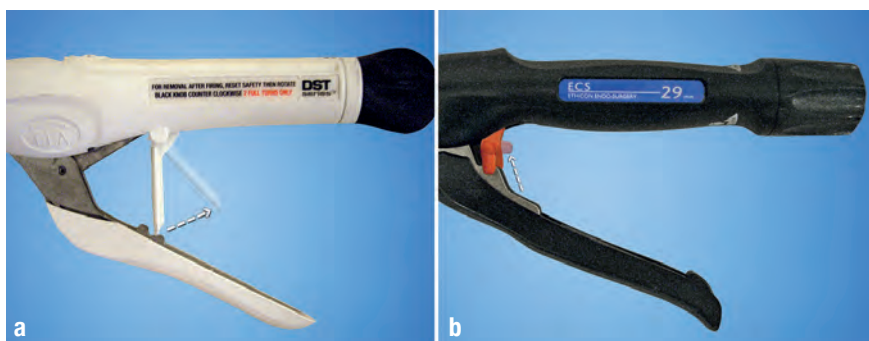
As the stapler is closed, and as the anvil approximates the staple device, there should be some degree of resistance as the anvil seats in the stapler. If there is no resistance, usually this means that the anvil has come apart from the guide rod on the stapler and the stapler should be opened and the anvil secured again on the stapler before attempting to fire the device.

During this entire closing process the surgeon should be observing the closing of the stapler to assure that it is functioning properly and that the two ends are coming together easily, there are no other structures in the staple line and there is no dehiscence of the proximal bowel off of the anvil.

There is an approximation indicator on each stapler close to the closing mechanism which tells the surgeon when the device is properly closed. In the Covidien model there is a green line which must be visible (Fig. 6.13a). The Ethicon model has a small window with a red line that, when seen, indicates that the staples will be deployed properly (Fig. 6.13b). The device should not be fired if the indicators are not visible. Failure to see the indicators will result in a misfire and inadequate staple line.



**Fig. 6.13** Approximation indicator of the Ethicon (a) and Covidien (b) stapler models.



**Fig. 6.14a,b** The white safety latch (pointer) must be flipped up in order to fire the stapler (Covidien) (a). The red safety lever (pointer) must be switched up prior to firing the stapler (Ethicon) (b).

#### 6.2.2.8 Firing the Stapler

After the surgeon is certain that the two ends of the stapler are seated properly, and there are no other structures in the stapler and the stapler appears to have closed properly, the stapler is ready to be fired. In both manufacturers, there is a safety mechanism which must be released prior to firing the stapler. Fig. 6.14a demonstrates the white safety latch that must be flipped up in order to fire the stapler and Fig. 6.14b shows the red safety lever on the Ethicon stapler which must be switched up for the same purpose.

After releasing the safety the stapler is fired **once**. The handle should not be closed twice, as the blade that cuts the tissue from the staple line, will be discharged each time that the stapler is closed and this can result in injury to the bowel wall. After firing the stapler, the stapler is opened and removed slowly from the bowel again while watching the anastomosis to make certain that undue tension is not being placed on the staple line.

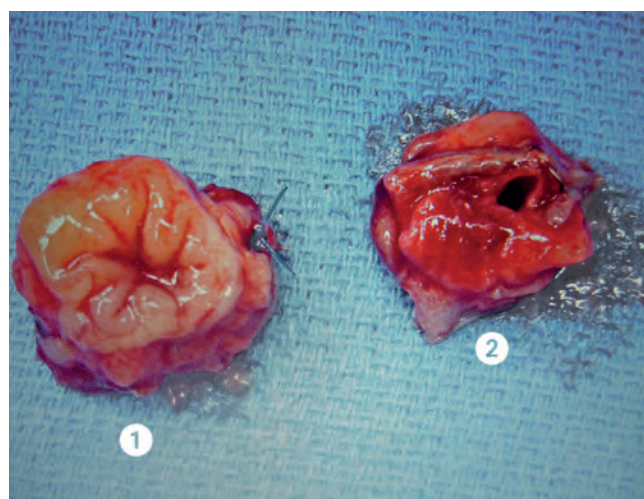
### 6.2.2.9 Evaluating the Anastomosis

There are several steps involved in evaluating the anastomosis. First, the stapler is removed and after removal of the staple device, the anvil is detached and the tissue 'donuts' are examined (Fig. 6.15). As shown in (Fig. 6.15), the circular tissue on the left (①) is from the anvil side of the anastomosis. The other tissue segment on the right (②) is from the distal margin. If there is any suspicion of malignancy or other concerns for abnormal pathology, the segments are sent separately to pathology for examination.

The following options are available:

1. Take down the anastomosis, resecure the distal segment of bowel – since there is now a hole in that segment – and replace the anvil in the proximal bowel. Subsequently, attempt to create the anastomosis again with a new stapler. It is now even more important to make sure that there is no tension on the anastomosis, because more bowel is being resected and both segments are shorter. Here, there is the potential for tension on the staple line where there may not have been any on the first attempt.
2. Check the anastomosis with the leak test, which is done routinely, and if the defect in the staple line is small, see about suturing the defect and also consider proximal diversion i.e. (ileostomy) for protection of the repaired staple line. Most colorectal surgeons in this instance would opt for a diverting loop ileostomy if there is concern about the integrity of the anastomosis.

The anastomosis should be evaluated regardless of whether the surgeon feels the staple line is secure or not. Most surgeons use the leak test which consists of placing saline solution in the pelvis, then using either a bulb irrigating syringe device filled with air, or rigid proctoscope or colonoscopic evaluation. The bowel is filled with air while the anastomosis is under saline which allows the surgeon to look for any air leaks.



**Fig. 6.15** Macroscopic view of tissue 'donuts' following completion of anastomosis.

The circular segments of proximal and distal bowel that are cut from the inside of the staple line should be two complete donuts of tissue. If this is not the case, then the staple line is considered disrupted and the surgeon must decide what course of action to take.

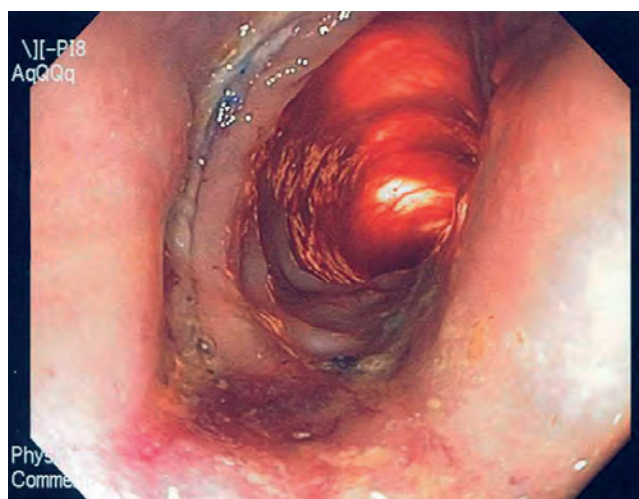
If the colonoscope is used, which is the preference of the author, this offers the advantage that the anastomosis can be directly visualized, checked for bleeding and or leak (Fig. 6.16). In this instance, a significant amount of air is used, which usually requires the bowel proximal to the anastomosis to be clamped in order to prevent over distention of the colon.

### 6.2.2.10 Covering or Sealing the Anastomosis

If the anastomosis is from colon to true rectum, below the peritoneal reflection, the overlying peritoneum may be pulled over the anastomosis loosely to aid in securing the staple line. The use of antiadhesive agents is not recommended in these types of anastomoses because of the absence of serosa on the rectal wall surface which makes the incidence of leak higher than in colo-colo anastomosis. Because of this fact, the surgeon relies on surrounding tissues to help seal the staple line. Closing the peritoneum too tightly over the staple line can also increase the risk of abscess formation and may compromise the luminal diameter, which is why great care must be exercised when choosing to close the peritoneum over the staple line.

### 6.2.2.11 Retrieving Small Bowel From Under the Colon

After the anastomosis is complete, there is a large mesenteric defect under the proximal colon which was brought down to the pelvis for anastomosis. Most surgeons do not close this defect. It is important to make certain that any small bowel that may have slipped under the colon is brought out to the midline to avoid an obstruction from a resulting internal hernia. This is easily accomplished by grasping the small bowel and gently pulling it medially until the mesenteric defect is visualized and there is no small bowel under the defect.



**Fig. 6.16** The anastomosis is visually checked for bleeding and /or leakage by use of a flexible colonoscope.

### 6.2.3 Conclusions

The incidence of leak, the long-term durability and stricture rates are comparable in sutured versus stapled anastomosis in colo-rectal surgery. The two major principles that must be observed in both methods are as follows:

- Adequate blood supply.
- Lack of tension.

Use of circular staplers for creating these low anastomoses is a welcomed addition to the surgical armamentarium, but there are several key points that are vital in the proper use of these devices:

- Proper positioning of the patient.
- Adequate mobilization of the distal (rectal) segment and proximal colon segments.
- Choosing an adequate stapler size: 29 mm or larger.
- Attention to detail that the proximal bowel is secured properly to the anvil.
- Place the stapler and alignment shaft as close to the distal resection line as possible when opening the stapler.
- Close the stapler slowly, watching to insure no tension, torsion on the bowel and to prevent other structures from being included in the device.
- Check for intact tissue donuts and integrity of the anastomosis with air-leak test.
- The use of antiadhesive materials is contraindicated in rectal anastomosis.
- Retrieve the small bowel from under the colon to avoid internal hernia.

### 6.2.4 References

1. JEELANI S, SHAFI J, AHMAD R, MIR S, AKBAR A, RAINA AH. Comparison between stapled anastomosis and hand sewn anastomosis in low anterior resection. *International Journal of Advanced Research* 2013;1(10):21–4.
2. KUMAR AS, KELLEHER DC, SIGLE GW. Bowel Preparation before Elective Surgery. *Clin Colon Rectal Surg* 2013;26(3):146–52. doi:10.1055/s-0033-1351129.
3. MULHOLLAND MW, DOHERTY GM. *Complications in Surgery*. 2nd ed. Philadelphia: Wolters Kluwer Health; 2011. (ISBN No. 9781605475301).
4. RAIYANI G, VOHRA A, CHAVDA P, MEHTA K, PARMAR A. Comparison between stapler and hand sewn anastomosis in elective gastrointestinal surgeries conducted at government tertiary hospital, Western India: A prospective study. *International Journal of Scientific Research* 2014;3(1):317–9.



## 6.3

## Bowel Surgery in Deep Infiltrating Endometriosis

Joël Leroy<sup>a,c</sup> | Antonio D'Urso<sup>b,c</sup> | Arthur R. Wijsmuller<sup>b,c</sup> | Frédéric Bretagnol<sup>b,d</sup>

## 6.3.1 Introduction

Endometriosis is a benign disease, defined as the presence of ectopic endometrial gland tissue outside the uterine cavity. Predilection sites of endometriotic bowel nodules are the sigmoid colon and the rectum, as well as the ileum, the appendix and the caecum.<sup>26</sup> Most commonly, small endometriotic lesions reaching only the subserosal fat tissue, do not cause symptoms.<sup>27</sup> Larger nodules infiltrating the intestinal muscular layer may cause a wide range of symptoms including dyschezia, constipation, diarrhea, abdominal bloating, painful bowel movements, passage of mucus in the stools and cyclical rectal bleeding.<sup>4,27</sup> Deep infiltrating endometriosis (DIE) can severely affect a patient's quality of life. Given involvement of the rectum, this may result in obstructive symptoms, making it hard to differentiate malignant from inflammatory disease.<sup>24</sup> Bowel involvement should be suggested in the presence of a palpable lesion found in the rectovaginal septum or if the patient presents with gastrointestinal symptoms. Even though there is still controversy regarding the first-line therapeutic approach to be adopted, it is widely accepted that surgical management is the primary treatment for more severe forms of endometriosis, such as symptomatic DIE with colorectal spread.<sup>9,10</sup>

Gastrointestinal involvement is one of the most challenging manifestations of endometriosis a surgeon can be faced with. Therefore, this pathology requires close collaboration of a multidisciplinary team of specialists from the fields of gynecology, urology and gastroenterology. The major objective of surgical management is to remove all endometriotic tissue with the primary intent of alleviating pain, preventing recurrence, improving fecundity and managing complications such as obstruction, stenosis or severe rectal hemorrhage. Accordingly, an extensive dissection is often required. A complete excision of DIE lesions enhances the prospects of reliable and persistent relief of pain symptoms, improvement of quality of life and acceptable postoperative fertility rates.

However, radical surgery excision is associated with a high risk of severe morbidity.

Laparoscopic segmental bowel resection or excision of the rectum and other types of colorectal surgeries, such as wedge resection and superficial shaving, have become increasingly popular, however, it still remains controversial which type of surgical approach should be chosen in the treatment of this challenging condition.<sup>13</sup> A multitude of surgical procedures have been proposed for the treatment of endometriosis with bowel involvement, such as laparoscopy, open surgery, transvaginal/transanal approaches or a combined approach. The amount of bowel that should be resected depends on the extension of pathology. Bowel resection is performed in compliance with best practice standards applicable in the surgical treatment of benign disease.

The scope of surgical treatment options includes (Fig. 6.17):

- **Superficial shaving excision** defined as superficial peeling of the serosal and subserosal bowel layers affected by endometriosis (with diathermy or laser) or selective excision without creating an opening in the bowel wall.
- **Partial full-thickness wedge resection** defined as selective excision of endometriotic deposits in the bowel wall by extraluminal or endoluminal resection.
- **Segmental bowel resection** defined as resection of a bowel segment affected by endometriosis and followed by anastomosis.

a| MD, FRCS

b| MD, PhD

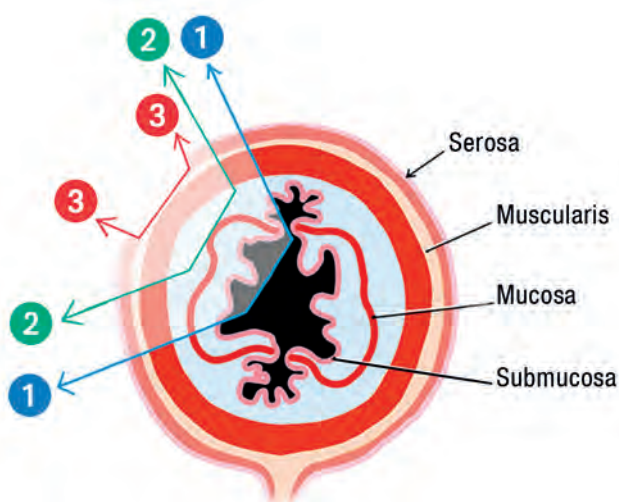
c| IRCAD/EITS, Department of General, Digestive and Endocrine Surgery, Nouvel Hôpital Civil, University Hospital of Strasbourg, Strasbourg, France

d| Professor of Gastrointestinal Surgery; Department of General and Digestive Surgery, Hôpital Louis Mourier, Paris, France

## Corresponding author:

Dr. Joël Leroy

Service de Chirurgie Digestive et Endocrinienne  
Nouvel Hôpital Civil, Hôpitaux Universitaires de Strasbourg,  
Strasbourg, France  
1 Place de l'Hôpital  
67091 Strasbourg cedex, France  
E-mail: joel.leroy@chru-strasbourg.fr  
Joel.leroy@ircad.fr



**Fig. 6.17** Schematic drawing of the various types of conservative bowel surgery available for “nodulectomy”. Shaving (3), mucosal skinning (2) and discoid resection (1).

Specimen extraction may be accomplished by using a natural orifice procedure (transvaginal or transanal) or through a cosmetically acceptable atraumatic abdominal incision (Pfannenstiel). The decision as to which operative technique should be chosen is determined by extent of disease, depth of bowel/pelvic infiltration, and by individual preferences/skills of the surgeon. Once the patient has been counselled on the nature, scope and risks of the surgical procedure, it is mandatory that valid informed consent be obtained. The various types of procedures should be explained in layman's terms and include the risks of postoperative leak/fistula formation, as well as the risks of temporary stoma and urinary dysfunction.

#### 6.3.1.1 Laparoscopy Versus Laparotomy

Nowadays, laparoscopic excision of DIE lesions is among the most widely accepted treatment options. Over the last two decades, laparoscopic treatment has been proposed as the first-line operative therapy, even for advanced and complex lesions. With the advent of a new generation of instruments and medical devices (powered devices particularly), and integration of HD video technology in laparoscopy, considerable headway has been made in the standardization of operative procedures. Due to the pressure provided by the pneumoperitoneum, retraction is facilitated in all directions. The use of dedicated endo-uterine manipulators and laparoscopic retractors has proven to facilitate exposure.

#### 6.3.1.2 Bowel Preparation

Provided that preoperative work-up, symptoms and/or clinical signs strongly suggest a diagnosis of bowel involvement, a low residue diet should be started one week before the elective procedure. This preliminary measure helps the patient to prepare psychologically for the forthcoming surgery. Efficacy of bowel preparation in the prevention of postoperative morbidity has not been demonstrated for open surgery procedures. Even though the use of preoperative mechanical bowel preparation (MBP) is common practice in North America, neither meta-analyses<sup>28,30</sup> nor randomized controlled trials<sup>5,6,12,33</sup> have furnished clear evidence of any benefits for the patient. It should be noted that these studies evaluated the use of MBP in open colorectal surgery. It is unclear whether the outcomes inferred from these trials can be extrapolated to laparoscopic colorectal surgery. Some studies seem to suggest a lower rate of fistula formation and postoperative infections after bowel preparation for left colectomies and rectal resection.<sup>21,29</sup> Based on reports in the literature it is suggested that MBP facilitates manipulation of the bowel during laparoscopic resection, and primes the colon for intraoperative colonoscopy which may become necessary to localize a lesion or to visually check the outcome of anastomosis.<sup>17,19,23</sup> If bowel preparation is decided upon in the setting of a laparoscopic approach, the authors advise against the use of polyethylene glycol (PEG) solution due to the associated risk of small bowel dilatation. Preparatory administration of sodium phosphate (Fleet Phospho-Soda, Casen Recordati, Utebo, Spain) and sennoside (X-Prep Liquid, Mudipharma Medical Company, Basel, Switzerland) is tolerated well with superior efficacy. Given the use of sodium phosphate, a test on blood ionic composition is

recommended, especially in patients with cardiac and hepatic problems. Renal insufficiency is a contraindication for the use of sodium phosphate. In case of laparoscopic resection, the authors employ bowel preparation with a colonic enema washout, using 2 liters of PEG administered the evening before the operation and complemented by a Normacol® washout, early on the day of the operation.

#### 6.3.1.3 Antibiotic Prophylaxis

Prophylactic administration of antibiotics is part of a series of measures that aim at reducing the risk of infection. Current recommendations suggest the use of antibiotic prophylaxis with a single intravenous injection given at the moment of anesthesia induction, or 20–30 minutes before the first surgical incision. If there is no major contamination occurring during the operation, antibiotics should not be administered in the postoperative period. In terms of antibiotic coverage, there is no difference between laparotomy and a laparoscopic approach.

#### 6.3.1.4 Operating Room Setup

In the presence of colorectal lesions, the patient is placed in a Lloyd-Davies position with a right tilt. The authors adhere to a standard protocol that is based on a double-team approach. The colorectal surgeon and first assistant are positioned on the right side of the patient while the second assistant is placed between the patient's legs. The laparoscopic platform is placed on the left side of the patient at the level of the legs. The nurse assumes a place on the right side of the patient at the level of the legs.

In patients with right colic lesions, the colorectal surgeon may be positioned between the patient's legs or on her left side, the first and second assistant are placed on the patient's left side, the laparoscopic platform is placed on her right side, at the level of the legs. The scrub nurse is positioned on the right side of the patient close to the surgeon.

### 6.3.2 Surgical Strategy

Most patients with endometriosis of the rectal and rectovaginal septum do not require bowel resection. In the presence of obstruction or stenosis, severe rectal hemorrhage, or diffuse full-thickness involvement, the authors endorse the use of resection. The decision-making related to the amount of bowel to be resected will depend on the depth of bowel wall involvement. It is essential to preserve as much tissue as possible, considering that adherence to the principles of surgical oncology is not required here.

Surgical planning for laparoscopic treatment of rectosigmoid DIE lesions can be divided in two subgroups, **conservative** and **segmental bowel resections**.

**Conservative bowel surgery** (Fig. 6.17) may also be called “nodulectomy” and implies resection of the intestinal DIE implant. It can be achieved using the following techniques:

- Rectal shaving.<sup>3,15</sup>
- Full-thickness wedge or discoid resection.<sup>3,8</sup>

The nodule can be resected with scissors after which the bowel wall is closed with sutures, however, the authors advocate the use of a circular or linear stapler.

**Segmental bowel surgery** involves the following:

- Complete segmental bowel resection and anastomosis.

The decision-making on the surgical technique to be adopted is based partly on the characteristics of the intestinal lesions, such as number/size of nodules, depth of infiltration of the intestinal wall and the proportion to which the intestinal circumference is infiltrated by endometriosis. In the end, due consideration should be given to the surgeon's level of experience as well as to individual preferences, which may also contribute to the final decision.

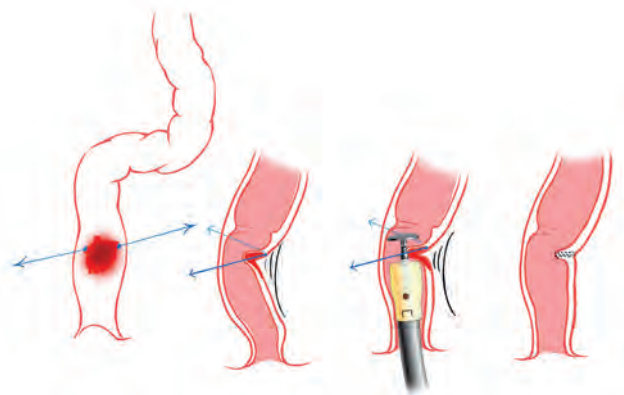
#### 6.3.2.1 Superficial Shaving Resection

Shaving may be performed on the bowel wall with a more or less aggressive course of action (Fig. 6.17). Conventional shaving is indicated in the presence of DIE lesions affecting the rectum up to the muscular layer. The aim of the procedure is to develop a plane that is interposed within the muscular layer of the rectum where there is no more evidence of endometriotic glands. The deeper the lesion, the higher the risk of intraoperative mucosal perforation of the bowel during resection. Provided the lesion has infiltrated the submucosal layer, shaving with mucosal skinning can be a feasible option.<sup>16</sup> Provided the technique is performed as proposed, integrity of the mucosa is preserved and the defect in the bowel wall is closed with a suture. Taking into account that preservation of the mucosal layer is not a straightforward task, there is an elevated risk of inadvertently causing a full-thickness breach in the anterior rectal wall.

Once the endometriotic nodule has been identified on the anterior rectosigmoid wall, a stay suture with a 3/0 absorbable suture is placed on the lesion which allows to apply traction and improves the angle of access for dissection of the anterior wall. Resection is carried out with cold scissors in order to prevent thermal injury to the bowel wall which can give rise to the development of a postoperative leak. Once the nodule has been completely resected, the serosal edges of the wall defect are re-approximated with single or running 3/0 absorbable sutures. An air/blue dye leak test is performed to assess the fluid-tight seal of defect closure. No abdominal drain is placed. The patient can eat immediately after the procedure.

#### 6.3.2.2 Partial Full-Thickness Wedge Resection

Full-thickness wall resection is another option for rectosigmoid DIE lesions, especially in those cases where endometriotic infiltration reaches beyond the muscular layer of the bowel (Fig. 6.17). This type of resection can be employed in the presence of an unifocal lesion, which does not exceed 3 cm in size on the anterior rectosigmoid wall, and provided no more than 30% of the circumference are involved.<sup>20,25</sup> It is not known whether radicality of the resection is directly correlated with a clinical improvement of symptoms. Recently, *Mabrouk et al.*<sup>20</sup> have shown that the presence of satellite lesions or positive resection margins does not seem to adversely affect clinical outcomes of segmental bowel resection.



**Fig. 6.18** Endolumenal wedge resection with a circular stapler.

#### ■ Endo-Rectal Wedge Resection with Circular Stapler<sup>25,32</sup>

Once the rectum has been completely dissected and the nodule is freed from the anterior wall, a rectal probe is inserted to check the integrity of the rectal wall. Absorbable stitches (3/0) are placed 1 cm laterally to the right and left of the lesion. The circular stapler (sized larger than 31 mm) is then inserted through the anal canal by the assistant standing between the patient's legs. The stapler is advanced proximally and opened while mobilizing the anterior nodule with the sutures under laparoscopic control until the nodule is placed between the anvil and the stapling head. The stapler is then closed and resection is performed (Fig. 6.18). An air/blue dye leak test is performed to eliminate the risk of failure. The suture line can be covered with omentum or with a peritoneal flap. The authors do not use postoperative drains and the patient can eat immediately in the postoperative period.

Some authors have been using a double-stapling anterior disc resection technique with the intent to resect larger lesions (up to 60 mm in diameter) with good results.<sup>32</sup> A margin of 1 cm should be sufficient.

#### ■ Laparoscopic Wedge Resection with Linear Stapler

This approach can be technically less demanding provided the endometriotic nodule is located more proximally on the rectosigmoid wall. Dissection is performed in the same fashion as described above. Once the sigmoid and rectum are clearly prepared, two absorbable 3/0 sutures are applied to both ends of the lesion in order to prevent the risk of stricture formation after resection. These two stay sutures are then pulled upwards in order to insert a linear stapler and resect the anterior wall, but if the resected area is smaller than 4 cm in size, the linear stapler can be inserted vertically without any major risk of postoperative stricture formation.

#### ■ Low Rectal Transanal "Pull-Through" Wedge Resection

In the presence of an endometriotic nodule involving the anterior wall of the rectum close to the anal verge, the following course of action is adopted. After mobilizing the rectovaginal septum anteriorly, up to 2 cm or less from the anus, the nodule is prolapsed through the anus and a linear stapler is applied to the segment of the anterior rectal wall containing the lesion. Occasionally, two applications are required to accomplish



a complete resection. The nodule is then excised and two absorbable 3/0 sutures are placed along the staple line. The rectum is pushed back in the pelvis under direct vision and fluid-tight seal of the staple line is confirmed by means of an air/blue dye leak test.

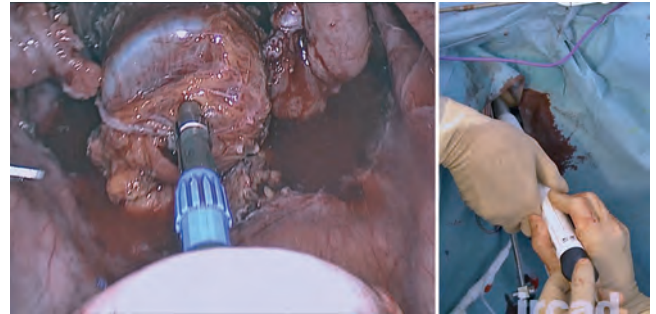
#### ■ Laparoscopic Wedge Resection with Scissors and Manual Suture

After complete mobilization another option for full-thickness excision is resection and subsequent closure by means of a hand-sewn suture. Excision is started proximal to the area of the visible nodule. Following identification of normal tissue, the lesion is mobilized at its proximal end with a grasping forceps. An incision is made with scissors cutting through the bowel serosa and muscularis until the lumen is entered. The lesion is completely excised from the anterior rectal wall. The bowel defect is repaired transversely in one layer once two traction sutures have been placed on the wound margins, resulting in a transverse opening. A 3/0 absorbable interrupted or running suture is applied. Upon completion of suturing, an air/blue dye leak test is performed to check for a fluid-tight seal of the closed defect.

### 6.3.3 Segmental Bowel Resections

#### ■ Colonic Resections

Patients with more advanced and extended lesions of the colon require a segmental resection. There is no need to respect the oncological principles of dissection, since endometriosis is a benign disease. Only the bowel segment affected by endometriotic tissue should be resected. Prior to commencing resection, the proximal and distal boundaries of the affected segment are identified. In a first step, the mesocolon is divided close to the bowel in order to prevent devascularization of the distal and proximal bowel, followed by mobilization of the proximal bowel (which may include the use of splenic flexure mobilization in sigmoidectomy). Dissection of the mesocolon is performed using either electro-surgical bipolar devices (LigaSure™, Medtronic, Dublin, Ireland) or ultrasonic devices (Sonicision™, Medtronic, Dublin, Ireland). The next steps comprise resection of the colon or rectum



**Fig. 6.19** Anastomosis according to the Knight-Griffen technique.

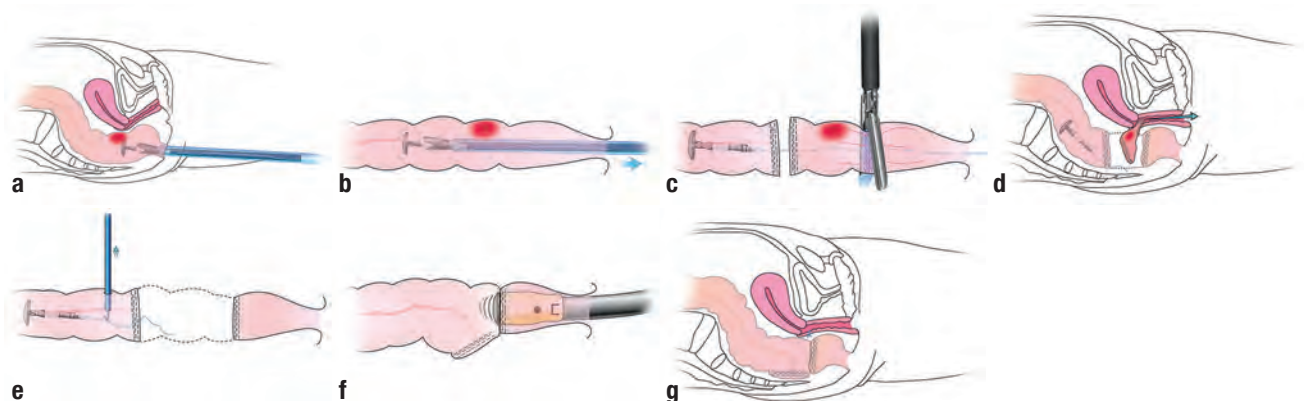
segment and anastomosis. For this purpose, one may choose from various options available. Bowel anastomosis is usually performed mechanically. Care must be taken that the 2 segments of bowel are well vascularized and anastomosed in a tension-free fashion.

#### ■ Standard Sigmoidectomy<sup>16,20</sup>

The procedure comprises resection of a sigmoid segment and should include the rectosigmoid junction (in order to facilitate end-to-end anastomosis and reduce the risk of postoperative formation of a leak and/or fistula). Distal division is performed with a 60-mm endoscopic linear stapler with a medium to thick range staple size as determined by the thickness of tissue (blue or purple cartridge Endo-GIA™, Medtronic, Dublin, Ireland). Once the distal division has been completed, the specimen is extracted through a suprapubic Pfannenstiel incision, protected by a plastic wound protector. The segment of sigmoid is pulled through the incision after which the anvil of a 28-mm circular stapler (EEA™, Medtronic, Dublin, Ireland) is delivered into the proximal colon. Anastomosis is then performed under laparoscopic control according to the Knight-Griffen technique (Fig. 6.19).

#### ■ Natural Orifice Specimen Extraction (NOSE) Sigmoidectomy

The procedure comprises a sigmoidectomy under laparoscopic control and involves extraction of the sigmoid specimen through the opening of the rectal stump (transanal) or an opening in the vagina (transvaginal) prior to proceeding with anastomosis.<sup>1,11,18,22</sup>



**Fig. 6.20a–g** Transanal introduction of the anvil (a). The anvil is advanced beyond the endometriotic nodule (b). Division of the rectum distal and proximal from the site of the nodule (c). Transvaginal specimen extraction (d). The “fishing” technique involves that the suture is picked up with a hook that is passed through a small fenestration made with a hook electrode close to the corner of the staple line on the antimesenteric side (e). Firing of the stapler and completion of anastomosis (f). Final aspect after vaginal closure (g).

*Transvaginal NOSE Sigmoidectomy*

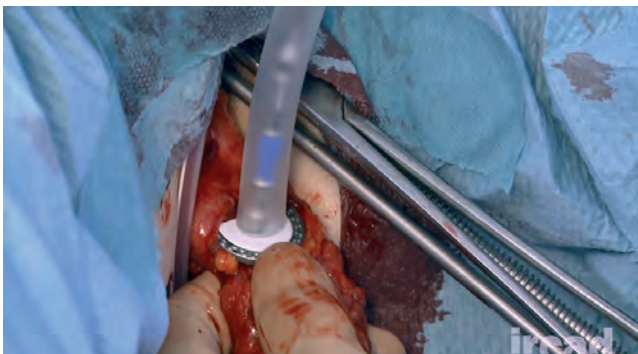Transvaginal NOSE sigmoidectomy (with or without sigmoid/rectal stenosis) (Fig. 6.20) is proposed in cases where vaginal resection of an endometriotic nodule is indicated.<sup>1</sup> In the absence of stenosis, the assistant standing between the legs introduces the anvil transanally into the lumen of the proximal colon after mobilization of the sigmoid. In case of stenosis, the sigmoid is exteriorized transvaginally after its mobilization and distal division. The assistant standing between the legs of the patient introduces a forceps through the vaginal orifice to grasp the distal sigmoid which is exteriorized outside the vagina until the stenotic segment is accessible. The anvil can then be introduced into the lumen of the proximal colon via a small colostomy (Fig. 6.21).

Prior to its insertion, a sturdy, long suture (decimal 2) is attached to the anvil's extremity. Advancement of the anvil in the descending colon is checked laparoscopically (Fig. 6.21). Once the anvil has been placed in the proximal colon, the proximal sigmoid is divided with a linear stapler (EndoGIA™

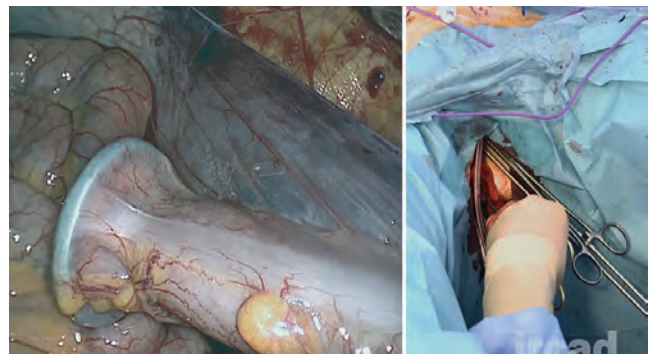
60 mm/Blue size) cutting the colon and mesocolon away from the shaft of the anvil that has been secured by a suture (Fig. 6.22).

Prior to proceeding with the anastomosis, the vagina is closed with care and hemostasis is completed, if necessary. In order to complete the anastomosis, the anvil is exteriorized applying traction to the suture which has been trapped in the staple line during proximal division of the sigmoid. For that purpose, a small transmural opening is made with a hook electrode at the corner of the staple line on the anti-mesenteric side in order to open the lumen of the colon and to pick up the suture with a hook (fishing technique) (Fig. 6.24). Next, the anvil is passed through the proximal open end of the bowel which is secured with a single suture and fixed to the base of the anvil.

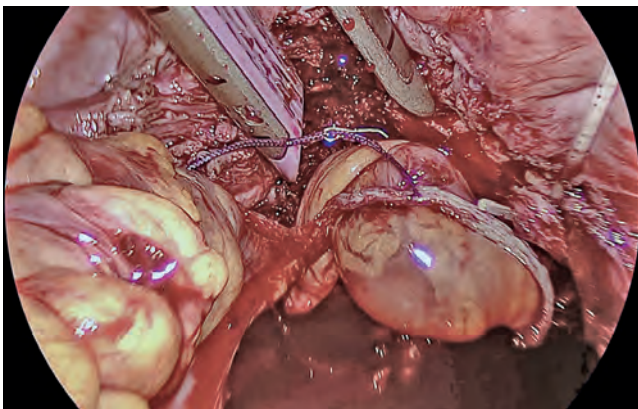
The anastomosis is then completed with a circular stapler according to the standard operative steps of the Knight-Griffen technique<sup>1</sup> (Fig. 6.19).



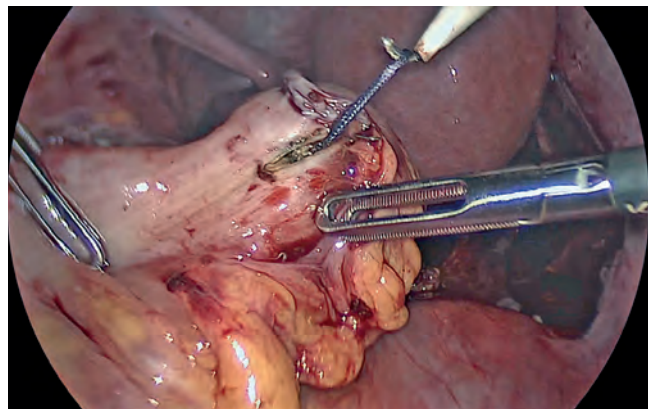
**Fig. 6.21** Transanal introduction of the anvil.



**Fig. 6.22** Advancement of the anvil in the descending colon under laparoscopic vision.



**Fig. 6.23** Transanal introduction of the anvil.



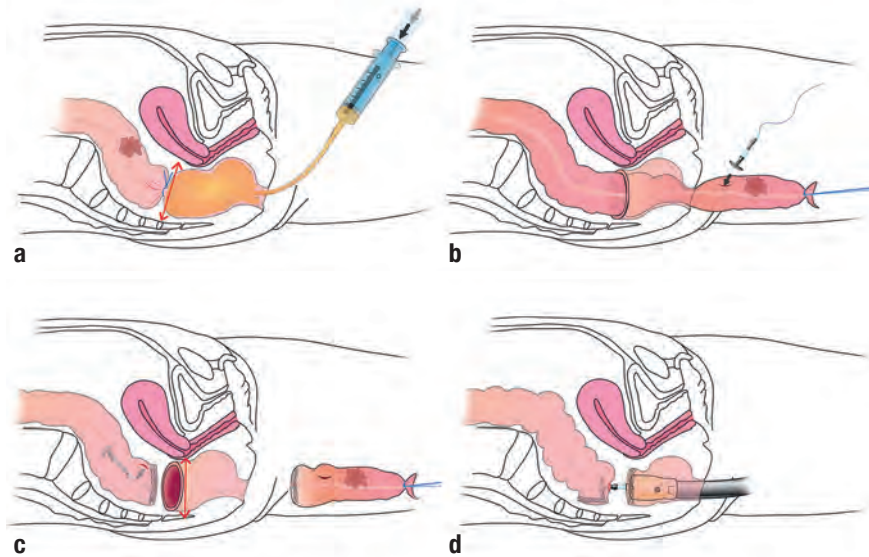
**Fig. 6.24** "Fishing" technique, as illustrated in Fig. 6.21e.



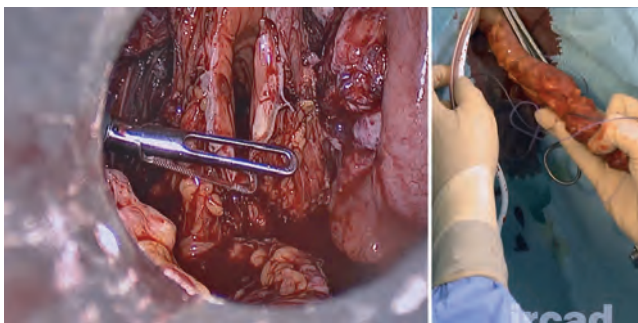
### Transanal NOSE Sigmoidectomy

Transanal NOSE sigmoidectomy (without sigmoid/rectal stenosis) (Fig. 6.25) is a technique the authors first described in sigmoidectomy for sigmoiditis.<sup>18</sup> The procedure can be performed provided there is no need to create an opening in the vagina. In the case of natural orifice specimen extraction, a #2 suture is attached to the anvil which is then advanced into the proximal colon via the transanal route (given the absence of stenosis). Once the anvil is placed in the proximal colon, the bowel is ligated distally to the anvil with a suture before proceeding to divide the distal segment after transanal cleaning. Through the rectal stump, which is kept open, the proximal colon is delivered through the anus until the area affected by endometriosis is accessible. The colon is divided under laparoscopic vision, distally to the shaft of the anvil, and the specimen is extracted via the anal canal (Fig. 6.26). Upon closure of the rectal stump with a linear stapler, the anvil of the circular stapler is retrieved close to the antimesenteric aspect of the suture line using the “fishing” technique. The anvil is then withdrawn from the bowel and secured with a purse string suture before completing the anastomosis according to the standard operative steps of the Knight-Griffen technique.<sup>11,18,22</sup> (Fig. 6.19).

In all procedures, an air/blue dye leak test is performed to ensure a fluid-tight seal of the anastomosis.



**Fig. 6.25a–d** Exclusion of the stenotic distal segment (a) and cleansing (b). Transanal extraction of the colon and introduction of the anvil through a fenestration made distally to the area of stenosis (b). Division of the proximal colon, extraction of the specimen, and closure of the rectal stump (c). Retrieval of the anvil and completion of anastomosis (d).



**Fig. 6.26** The specimen is extracted through the anal canal after division of the colon distally to the anvil.

### Protective Ileostomy

A protective ileostomy should be considered in cases where anastomosis is performed at a low level, because the lower the anastomosis needs to be made, the higher the risk of leakage. This measure is recommended for anastomoses made at 5 cm or less from the anal verge and strongly recommended for anastomoses made at 2 cm or less from the anal verge. A defunctioning stoma does not reliably prevent the occurrence of adverse effects resulting from leakage, but can greatly reduce such a risk. It is justified in case of a large rectal resection in patients with a poor local and/or general status, with previous radiotherapy and/or radiochemotherapy (RCT). Morbidities represent 10% to 20% of re-admissions for dehydration<sup>7,31</sup> with a total complication rate as high as 35%.<sup>14</sup> It should not be performed routinely but selectively in patients with significant comorbidities or in those identified to have a high-risk anastomosis.<sup>2</sup>



### ■ Small Bowel Resection Anastomosis

After isolation of the anticipated area of resection, the small bowel is divided proximally and distally with an endoscopic linear stapler (white cartridge Endo-GIA™, Medtronic, Dublin, Ireland). The length of bowel to be resected should be kept as short as possible considering the benign nature of disease. Anastomosis can be performed mechanically or hand-sewn in a side-to-side or in an end-to-side fashion. Frequently, a mechanical side-to-side anastomosis is made. Two enterotomies are performed with scissors or with a hook electrode after approximation of the two segments. Anastomosis is usually performed in an isoperistaltic fashion with a 60-mm cartridge. The entry site of the stapler is closed with a 3/0 absorbable running suture.

### ■ Ileocaecal Resection

Provided an ileocecal resection is performed, dissection of the last small bowel loop is carried out in order to mobilize the caecum. Dissection is accomplished starting from the lower part and proceeding to the lateral side in the right fossa. Once the caecum has been completely mobilized, the mesentery is dissected and the ascending colon is transected with the 60-mm endoscopic linear stapler (blue cartridge Endo-GIA™, Medtronic, Dublin, Ireland). A stapled side-to-side ileocolic anastomosis is made in an isoperistaltic fashion between the ascending colon and distal ileum. This can be accomplished using an intracorporeal or extracorporeal technique through a mini-laparotomy following adequate submesocolic mobilization. Enterotomy and colotomy are performed after approximation of the two segments. A 60-mm endoscopic linear stapler (blue cartridge Endo-GIA™, Medtronic, Dublin, Ireland) is used and the entry site of the cartridge is closed with a 3/0 absorbable running suture. The NOSE technique may also be used if the vagina or rectum are opened.

### 6.3.4 Conclusions

Surgical management of DIE lesions is among the topics of major interest increasingly debated in the current literature, considering that the procedure requires a multidisciplinary approach through close collaboration of surgical teams from the fields of gynecology, urology and gastroenterology. Bowel surgery can be broadly divided into conservative bowel surgery and segmental bowel surgery with resection. There is a wide range of conservative and advanced surgical treatment options available to remove all endometriotic tissue and to restore integrity and function of anatomical structures distorted by the disease. Finally, the current trend is to customize the treatment strategy, including surgery, to obtain the best clinical results with minimal surgical trauma.

### 6.3.5 References

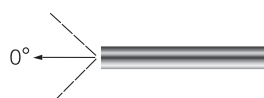
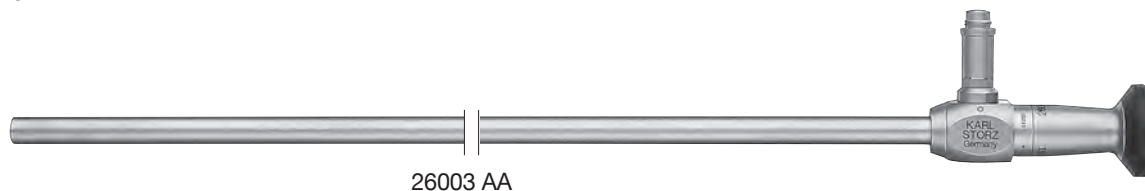
- AKLADIOS C, FALLER E, AFORS K, PUGA M, ALBORNOZ J, REDONDO C et al. Totally laparoscopic intracorporeal anastomosis with natural orifice specimen extraction (NOSE) techniques, particularly suitable for bowel endometriosis. *J Minim Invasive Gynecol* 2014;21(6):1095–102. doi:10.1016/j.jmig.2014.05.003.
- AKLADIOS C, MESSORI P, FALLER E, PUGA M, AFORS K, LEROY J et al. Is ileostomy always necessary following rectal resection for deep infiltrating endometriosis? *J Minim Invasive Gynecol* 2015;22(1):103–9. doi:10.1016/j.jmig.2014.08.001.
- BAILEY HR, OTT MT, HARTENDORP P. Aggressive surgical management for advanced colorectal endometriosis. *Dis Colon Rectum* 1994;37(8):747–53.
- BAZOT M, LAFONT C, ROUZIER R, ROSEAU G, THOMASSIN-NAGGARA I, DARAI E. Diagnostic accuracy of physical examination, transvaginal sonography, rectal endoscopic sonography, and magnetic resonance imaging to diagnose deep infiltrating endometriosis. *Fertil Steril* 2009;92(6):1825–33. doi:10.1016/j.fertnstert.2008.09.005.
- BROWNSON P, JENKINS SA, NOTT D, ELLENBOGEN S. Mechanical bowel preparation before colorectal surgery: results of a prospective randomized trial. *Br J Surg* 199;79:461–462.
- CONTANT CM, HOP WC, VAN'T SHP, OOSTVOGEL HJ, SMEETS HJ, STASSEN LP et al. Mechanical bowel preparation for elective colorectal surgery: a multicentre randomised trial. *Lancet* 2007;370(9605):2112–7. doi:10.1016/S0140-6736(07)61905-9.
- DUCHESNE JC, WANG YZ, WEINTRAUB SL, BOYLE M, HUNT JP. Stoma complications: a multivariate analysis. *Am Surg* 2002;68(11):961–6; discussion 966.
- DUEPREE HJ, SENAGORE AJ, DELANEY CP, MARCELLO PW, BRADY KM, FALCONE T. Laparoscopic resection of deep pelvic endometriosis with rectosigmoid involvement. *J Am Coll Surg* 2002;195(6):754–8.
- DUFFY JM, ARAMBAGE K, CORREA FJ, OLIVE D, FARQUHAR C, GARRY R et al. Laparoscopic surgery for endometriosis. *Cochrane Database Syst Rev* 2014;4:CD011031. doi:10.1002/14651858.CD011031.pub2.
- EMMANUEL KR, DAVIS C. Outcomes and treatment options in rectovaginal endometriosis. *Curr Opin Obstet Gynecol* 2005;17(4):399–402.
- FALLER E, ALBORNOZ J, MESSORI P, LEROY J, WATTIEZ A. A new technique of laparoscopic intracorporeal anastomosis for transrectal bowel resection with transvaginal specimen extraction. *J Minim Invasive Gynecol* 2013;20(3):333. doi:10.1016/j.jmig.2013.02.017.
- FA-SI-OEN P, ROUMEN R, BUITENWEG J, VAN DE VELDE C, VAN GELDERE D, PUTTER H et al. Mechanical bowel preparation or not? Outcome of a multicenter, randomized trial in elective open colon surgery. *Dis Colon Rectum* 2005;48(8):1509–16. doi:10.1007/s10350-005-0068-y.
- GARRY R. The effectiveness of laparoscopic excision of endometriosis. *Curr Opin Obstet Gynecol* 2004;16(4):299–303.
- IHNAT P, GUNKOVA P, PETEJA M, VAVRA P, PELIKAN A, ZONCA P. Diverting ileostomy in laparoscopic rectal cancer surgery: high price of protection. *Surg Endosc* 2016. doi:10.1007/s00464-016-4811-3.
- IKEDA F, VANNI D, VASCONCELOS A, PODGAEC S, ABRAO MS. Microlaparoscopy vs. conventional laparoscopy for the management of early-stage pelvic endometriosis: a comparison. *J Reprod Med* 2005;50(10):771–8.
- KONINCKX PR, USSIA A, ADAMYAN L, WATTIEZ A, DONNEZ J. Deep endometriosis: definition, diagnosis, and treatment. *Fertil Steril* 2012;98(3):564–71. doi:10.1016/j.fertnstert.2012.07.1061.
- LANTHALER M, BIEBL M, MITTERMAIR R, OFNER D, NEHODA H. Intraoperative colonoscopy for anastomosis assessment in laparoscopically assisted left-sided colon resection: is it worthwhile? *J Laparoendosc Adv Surg Tech A* 2008;18(1):27–31. doi:10.1089/lap.2007.0058.
- LEROY J, COSTANTINO F, CAHILL RA, D'AGOSTINO J, MORALES A, MUTTER D et al. Laparoscopic resection with transanal specimen extraction for sigmoid diverticulitis. *Br J Surg* 2011;98(9):1327–34. doi:10.1002/bjs.7517.

19. LI VK, WEXNER SD, PULIDO N, WANG H, JIN HY, WEISS EG et al. Use of routine intraoperative endoscopy in elective laparoscopic colorectal surgery: can it further avoid anastomotic failure? *Surg Endosc* 2009;23(11):2459–65. doi:10.1007/s00464-009-0416-4.
20. MABROUK M, SPAGNOLO E, RAIMONDO D, D'ERRICO A, CAPRARA G, MALVI D et al. Segmental bowel resection for colorectal endometriosis: is there a correlation between histological pattern and clinical outcomes? *Hum Reprod* 2012;27(5):1314–9. doi:10.1093/humrep/des048.
21. MARIETTE C, ALVES A, BENOIST S, BRETAGNOL F, MABRUT JY, SLIM K. Perioperative care in digestive surgery. Guidelines for the French society of digestive surgery (SFCD). *Ann Chir* 2005;130(2):108–24. doi:10.1016/j.anchir.2004.12.003.
22. MESSORI P, FALLER E, ALBORNOZ J, LEROY J, WATTIEZ A. Laparoscopic sigmoidectomy for endometriosis with transanal specimen extraction. *J Minim Invasive Gynecol* 2013;20(4):412. doi:10.1016/j.jmig.2013.02.025.
23. MIETTINEN RP, LAITINEN ST, MAKELA JT, PAAKKONEN ME. Bowel preparation with oral polyethylene glycol electrolyte solution vs. no preparation in elective open colorectal surgery: prospective, randomized study. *Dis Colon Rectum* 2000;43(5):669–75; discussion 675–7.
24. PAKSOY M, KARABICAK I, AYAN F, AYDOGAN F. Intestinal obstruction due to rectal endometriosis. *Mt Sinai J Med* 2005;72(6):405–8.
25. PEREIRA RM, ZANATTA A, REICH H, BIANCHI PH, FETTBACK PB, MOTTA EL et al. Use of circular stapler for laparoscopic excision of rectosigmoid anterior wall endometriosis. *Surg Technol Int* 2008;17:181–6.
26. REMORGIDA V, FERRERO S, FULCHERI E, RAGNI N, MARTIN DC. Bowel endometriosis: presentation, diagnosis, and treatment. *Obstet Gynecol Surv* 2007;62(7):461–70. doi:10.1097/01.ogx.0000268688.55653.5c.
27. REMORGIDA V, RAGNI N, FERRERO S, ANSERINI P, TORELLI P, FULCHERI E. The involvement of the interstitial Cajal cells and the enteric nervous system in bowel endometriosis. *Hum Reprod* 2005;20(1):264–71. doi:10.1093/humrep/deh568.
28. SLIM K, VICAUT E, LAUNAY-SAVARY MV, CONTANT C, CHIPPONI J. Updated systematic review and meta-analysis of randomized clinical trials on the role of mechanical bowel preparation before colorectal surgery. *Ann Surg* 2009;249(2):203–9. doi:10.1097/SLA.0b013e318193425a.
29. SLIM K, VICAUT E, PANIS Y, CHIPPONI J. Meta-analysis of randomized clinical trials of colorectal surgery with or without mechanical bowel preparation. *Br J Surg* 2004;91(9):1125–30. doi:10.1002/bjs.4651.
30. STAHL TJ, GREGORCYK SG, HYMAN NH, BUIE WD. Practice parameters for the prevention of venous thrombosis. *Dis Colon Rectum* 2006;49(10):1477–83. doi:10.1007/s10350-006-0686-z.
31. TAN WS, TANG CL, SHI L, EU KW. Meta-analysis of defunctioning stomas in low anterior resection for rectal cancer. *Br J Surg* 2009;96(5):462–72. doi:10.1002/bjs.6594.
32. WOODS RJ, HERIOT AG, CHEN FC. Anterior rectal wall excision for endometriosis using the circular stapler. *ANZ J Surg* 2003;73(8):647–8.
33. ZHU QD, ZHANG QY, ZENG QQ, YU ZP, TAO CL, YANG WJ. Efficacy of mechanical bowel preparation with polyethylene glycol in prevention of postoperative complications in elective colorectal surgery: a meta-analysis. *Int J Colorectal Dis* 2010;25(2):267–75. doi:10.1007/s00384-009-0834-8.

## HOPKINS® Telescopes

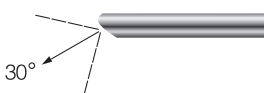
Diameter 10 mm, length 31 cm and 32 cm

Trocar size 11 mm



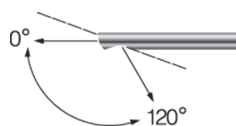

26003 AA

**HOPKINS® Straight Forward Telescope 0°**, enlarged view, diameter 10 mm, length 31 cm, **autoclavable**, fiber optic light transmission incorporated, color code: green



26003 BA

**HOPKINS® Forward-Oblique Telescope 30°**, enlarged view, diameter 10 mm, length 31 cm, **autoclavable**, fiber optic light transmission incorporated, color code: red



26003 AE

**ENDOCAMELEON® HOPKINS® Telescope**, diameter 10 mm, length 32 cm, **autoclavable**, variable direction of view from 0° – 120°, adjustment knob for selecting the desired direction of view, fiber optic light transmission incorporated, color code: gold

## VERESS Pneumoperitoneum Needle




26120 JL

**VERESS Pneumoperitoneum Needle**, with spring-loaded blunt inner cannula, LUER-Lock, **autoclavable**, diameter 2.1 mm, length 13 cm

It is recommended to check the suitability of the product for the intended procedure prior to use.



## Plastic Container for Sterilizing and Storage of Two Telescopes



39301 A – D

39301 C

**Plastic Container for Sterilization and Storage of two Telescopes**, perforated, with transparent lid, with silicone telescope holder, external dimensions (w x d x h): 520 x 90 x 45 mm, for 10 mm Laparoscopy Telescopes and similar, including:  
**Bottom Part**  
**Lid**  
**Silicone Telescope Holder**

## Silicone Telescope Holder




39301 CH



39301 CH **Silicone Telescope Holder**, for two telescopes, up to size 10 mm, i. e. for use with plastic containers 39301 B to D

## Trocars and Accessories


Size 6 mm and 11 mm, working length 10.5 cm



30103 MC




30103 MC **Trocar**, with conical tip, with insufflation stopcock, size 11 mm, working length 10.5 cm, color code: green, including:  
**Cannula**, without valve  
**Trocar only**  
**Multifunctional Valve**



30160 MC




30160 MC **Trocar**, with conical tip, insufflation stopcock, size 6 mm, working length 10.5 cm, color code: black, including:  
**Cannula**, without valve  
**Trocar only**  
**Multifunctional Valve**



30160 MC

30160 S **Thread Sleeve**, for trocar size 6 mm, color code: black




30103 MTR



30103 MTR **TERNAMIAN EndoTIP® Cannula**, with thread and rotatable insufflation stopcock, size 11 mm, working length 10.5 cm, color code: green, including:  
**Cannula**  
**Multifunctional Valve**  
**Telescope Stopper**, sterile, package of 12


## Trocars

Size 6 mm and 11 mm, working length 10.5 cm and 10 cm




30160 TMR

- 30160 TMR **TERNAMIAN EndoTIP® Cannula**,  
with thread and rotatable insufflation stopcock,  
size 6 mm, working length 10.5 cm,  
color code: black,  
including:  
**Cannula**  
**Multifunctional Valve**  
**Telescope Stopper**, sterile, package of 12



30103 GYG

- ♦ 30103 GYG **Trocar**, with conical tip,  
with LUER-Lock connector for insufflation,  
size 11 mm length 10 cm,  
color code: green,  
including:  
**Cannula**  
**Trocar only**  
**Valve Seal**



30160 GYG

- ♦ 30160 GYG **Trocar**, with conical tip,  
with LUER-Lock connector for insufflation,  
size 6 mm, length 10 cm,  
color code: black,  
including:  
**Cannula**  
**Trocar only**  
**Valve Seal**

♦ Not available for sale in the U.S.A.



## CLICKLINE Grasping Forceps



33351 ME



33351 ME

**CLICKLINE Grasping Forceps**, rotating, dismantling, insulated, with connector pin for unipolar coagulation, with LUER-Lock irrigation connector for cleaning, single action jaws, multiple teeth, width of jaws 4.8 mm, for atraumatic and accurate grasping, size 5 mm, length 36 cm,

including:

**Plastic Handle**, without ratchet, with larger contact area**Metal Outer Sheath**, insulated**Forceps Insert**

33351 MG

**CLICKLINE Grasping Forceps**, “tiger jaws”, rotating, dismantling, insulated, with connector pin for unipolar coagulation, with LUER-Lock irrigation connector for cleaning, single action jaws, 2 x 4 teeth, size 5 mm, length 36 cm,

including:

**Plastic Handle**, without ratchet, with larger contact area**Metal Outer Sheath**, insulated**Forceps Insert**

33351 MA

**CLICKLINE Grasping Forceps**, “cobra jaws”, rotating, dismantling, insulated, with connector pin for unipolar coagulation, with LUER-Lock irrigation connector for cleaning, single action jaws, 1 x 2 teeth, size 5 mm, length 36 cm,

including:

**Plastic Handle**, without ratchet, with larger contact area**Metal Outer Sheath**, insulated**Forceps Insert**

33361 ON



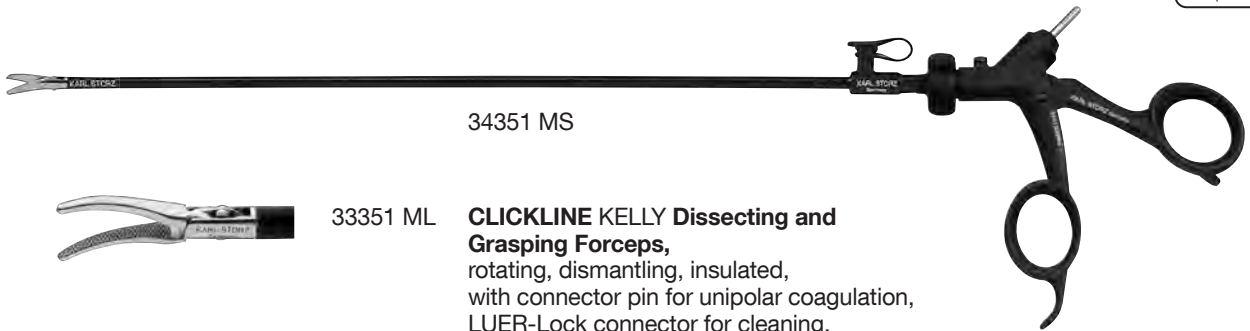
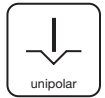33361 ON

**CLICKLINE Grasping Forceps**, rotating, dismantling, without connector pin for unipolar coagulation, with LUER-Lock irrigation connector for cleaning, single action jaws, with especially fine atraumatic serration, fenestrated, size 5 mm, length 36 cm,

including:

**Metal Handle**, without ratchet, with larger contact area**Metal Outer Sheath**, insulated**Forceps Insert**

## CLICKLINE Grasping Forceps and Scissors



34351 MS



33351 ML

**CLICKLINE KELLY Dissecting and Grasping Forceps,**

rotating, dismantling, insulated, with connector pin for unipolar coagulation, LUER-Lock connector for cleaning, double action jaws, long, size 5 mm, length 36 cm, including:

**Plastic Handle**, without ratchet, with larger contact area

**Metal Outer Sheath**, insulated

**Forceps Insert**



34351 MS

**CLICKLINE METZENBAUM Scissors,**

rotating, dismantling, with connector pin for unipolar coagulation, with LUER-Lock irrigation connector for cleaning, double action jaws, curved, length of jaws 15 mm, size 5 mm, length 36 cm, including:

**Plastic Handle**, without ratchet, with larger contact area

**Metal Outer Sheath**, insulated

**Scissors Insert**



34351 MD

**CLICKLINE Scissors,**

rotating, dismantling, insulated, with connector pin for unipolar coagulation, with LUER-Lock irrigation connector for cleaning, double action jaws, straight, size 5 mm, length 36 cm, including:

**Plastic Handle**, without ratchet, with larger contact area

**Metal Outer Sheath**, insulated

**Scissors Insert**



34351 EH

**CLICKLINE Hook Scissors,**

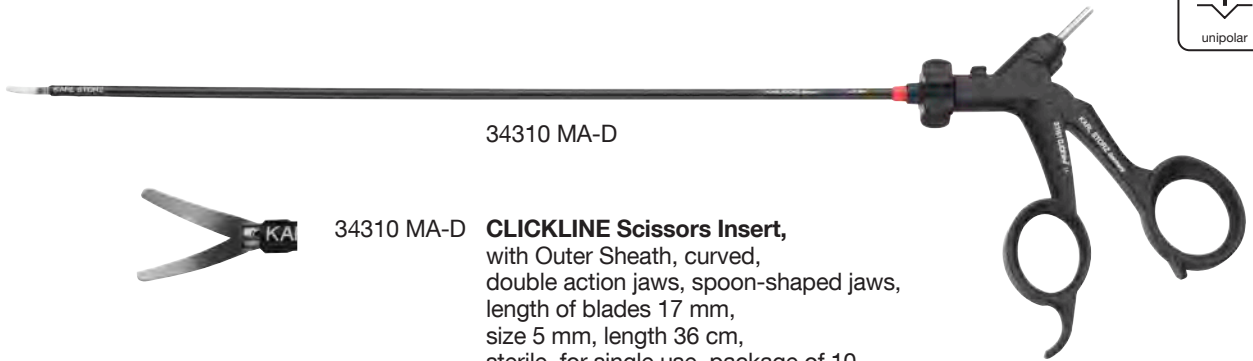
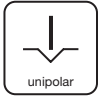rotating, dismantling, insulated, with connector pin for unipolar coagulation, with LUER-Lock connector for cleaning, single action jaws, size 5 mm, length 36 cm, including:

**Plastic Handle**, without ratchet, with larger contact area

**Metal Outer Sheath**, insulated

**Scissors Insert**

## CLICKLINE Single use Scissors



34310 MA-D

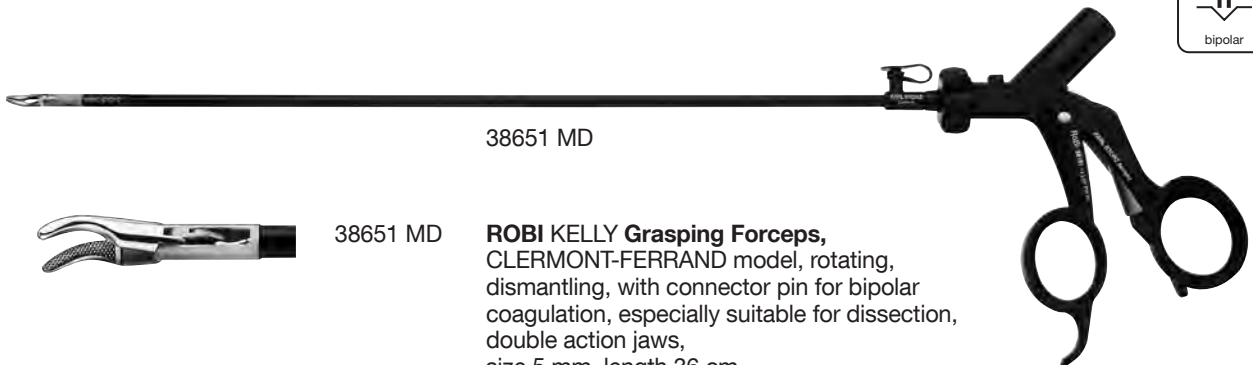


34310 MA-D **CLICKLINE Scissors Insert**, with Outer Sheath, curved, double action jaws, spoon-shaped jaws, length of blades 17 mm, size 5 mm, length 36 cm, sterile, for single use, package of 10



34310 MS-D **CLICKLINE METZENBAUM Scissors**, curved, length of blades 12 mm, double action jaws, size 5 mm, length 36 cm, sterile, for single use, package of 10

## ROBI Grasping Forceps



38651 MD



38651 MD **ROBI KELLY Grasping Forceps**, CLERMONT-FERRAND model, rotating, dismantling, with connector pin for bipolar coagulation, especially suitable for dissection, double action jaws, size 5 mm, length 36 cm, color code: light blue, including:  
**ROBI Plastic Handle**, without ratchet  
**ROBI Metal Outer Sheath**  
**ROBI Forceps Insert**



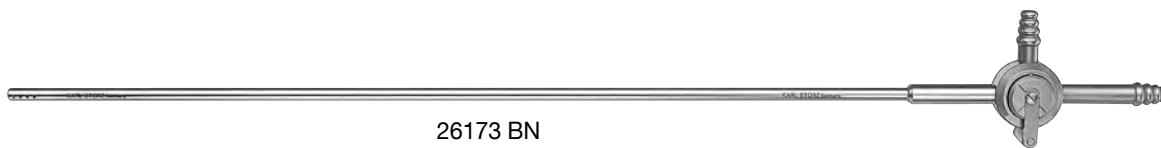38651 ML **ROBI KELLY Grasping Forceps**, CLERMONT-FERRAND model, rotating, dismantling, with connector pin for bipolar coagulation, double action jaws, especially suitable for dissection, size 5 mm, length 36 cm, color code: light blue, including:  
**ROBI Plastic Handle**, without ratchet  
**ROBI Metal Outer Sheath**  
**ROBI Forceps Insert**



38651 ON **ROBI Grasping Forceps**, CLERMONT-FERRAND model, rotating, dismantling, with connector pin for bipolar coagulation, with especially fine atraumatic serration, fenestrated jaws, double action jaws, size 5 mm, length 36 cm, color code: light blue, including:  
**ROBI Plastic Handle**, without ratchet  
**ROBI Metal Outer Sheath**  
**ROBI Forceps Insert**



## Suction and Irrigation Tube



26173 BN



26173 BN

**Suction and Irrigation Tube**, with lateral holes, anti-reflex surface, with two-way stopcock for single hand control, size 5 mm, length 36 cm

## GORDTS and CAMPO Coagulating Suction and Irrigation Cannula



37370 GC



37370 GC

**GORDTS and CAMPO Coagulation Suction and Irrigation Tube**, bipolar, diameter 5 mm, length 36 cm, for use with suction and irrigation handles

## High Frequency Needle



30675 ND



30675 ND

**High Frequency Needle**, for splitting and coagulation, insulated, retractable, with connector pin for unipolar coagulation, length 31 cm



## Coagulating and Dissecting Electrodes



26775 UF



26775 UF

**Coagulating and Dissecting Electrode,**  
L-shaped, with connector pin for unipolar coagulation,  
size 5 mm, length 36 cm



26775 UE

**Coagulating and Dissecting Electrode,**  
insulated sheath,  
with connector pin for unipolar coagulation,  
spatula-shaped, blunt, size 5 mm, length 36 cm

## High Frequency Cords



26005 M

**Unipolar High Frequency Cord,** with 5 mm plug, length 300 cm,  
for AUTOCON® II 400 SCB system (111, 115, 122, 125),  
AUTOCON® II 200, AUTOCON® II 80, KARL STORZ AUTOCON®  
system (50, 200, 350) and Erbe type ICC



26176 LE

**Bipolar High Frequency Cord,** for AUTOCON® II 400 SCB  
system (111, 113, 115, 122, 125), AUTOCON® II 200,  
AUTOCON® II 80, KARL STORZ Coagulator 26021 B/C/D,  
860021 B/C/D, 27810 B/C/D, 28810 B/C/D, AUTOCON® series  
(50, 200, 350), Erbe-Coagulator, T and ICC series, length 300 cm







## KOH Macro Needle Holders

### KOH Assistant Needle Holder

#### Size 5 mm

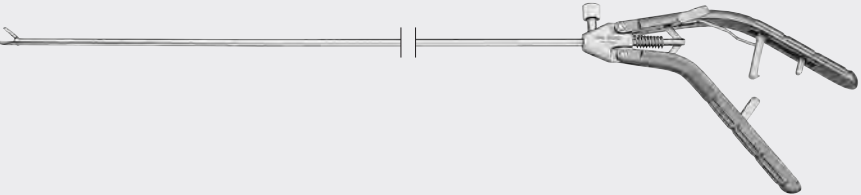
Operating instruments, lengths 33 and 43 cm,  
for use with trocars size 6 mm





Length	Instrument
33 cm	
43 cm	

Distal tip	Instrument	
	26173 KAF	KOH <b>Macro Needle Holder</b> , with tungsten carbide insert, ergonomic straight handle with disengageable ratchet, ratchet position right, jaws straight
	26178 KAF	
	26173 KAL	KOH <b>Macro Needle Holder</b> , with tungsten carbide insert, ergonomic straight handle with disengageable ratchet, ratchet position right, jaws curved to left
	26178 KAL	
	26173 KAR	KOH <b>Macro Needle Holder</b> , with tungsten carbide insert, ergonomic straight handle with disengageable ratchet, ratchet position left, jaws curved to right
	26178 KAR	

#### Size 5 mm

Operating instruments, lengths 33 and 43 cm, with pistol handle  
for use with trocars size 6 mm

Length	Instrument
33 cm	
43 cm	

Distal tip	Instrument	
	26173 KPF	KOH <b>Macro Needle Holder</b> , with tungsten carbide insert, ergonomic pistol handle with disengageable ratchet, ratchet position left, jaws straight
	26178 KPF	
	26173 KPL	KOH <b>Macro Needle Holder</b> , with tungsten carbide insert, ergonomic pistol handle with disengageable ratchet, ratchet position left, jaws curved to left
	26178 KPL	
	26173 KPR	KOH <b>Macro Needle Holder</b> , with tungsten carbide insert, ergonomic pistol handle with disengageable ratchet, ratchet position right, jaws curved to right
	26178 KPR	
	<b>NEW</b> 26173 KG	KOH <b>Assistant Needle Holder</b> , ergonomic pistol handle with disengageable ratchet, ratchet position left, straight jaws with distal hole









## KOH Macro Needle Holder

dismantling

Size 5 mm

Operating instruments, lengths 33 and 43 cm,  
for use with trocars size 6 mm

Length	Handle		
	30173 AR	30173 AL	30173 AO
33 cm			
43 cm			

### Single-action jaws

Working Insert	Complete Instrument		
30173 R	30173 RAR	30173 RAL	30173 RAO
30178 R	30178 RAR	30178 RAL	30178 RAO




KOH **Macro Needle Holder**, jaws curved to right,  
with tungsten carbide inserts, for use with suture material size 0/0 – 7/0

30173 L	30173 LAR	30173 LAL	30173 LAO
30178 L	30178 LAR	30178 LAL	30178 LAO



KOH **Macro Needle Holder**, jaws curved to left,  
with tungsten carbide inserts, for use with suture material size 0/0 – 7

30173 F	30173 FAR	30173 FAL	30173 FAO
30178 F	30178 FAR	30178 FAL	30178 FAO



KOH **Macro Needle Holder**, straight jaws,  
with tungsten carbide inserts, for use with suture material size 0/0 – 7/0

30173 G	30173 GAR	30173 GAL	30173 GAO
---------	-----------	-----------	-----------

**NEW**




KOH **Macro Assistant Needle Holder**, straight jaws

## KOH Macro Needle Holder





dismantling

Size 5 mm

Operating instruments, lengths 33 and 43 cm,  
for use with trocars size 6 mm

Length	Handle		
	30173 PR	30173 PL	30173 PO
33 cm			
43 cm			

### Single-action jaws





Working Insert	Complete Instrument		
30173 R	30173 RPR	30173 RPL	30173 RPO
30178 R	30178 RPR	30178 RPL	30178 RPO
	KOH <b>Macro Needle Holder</b> , jaws curved to right, with tungsten carbide inserts, for use with suture material size 0/0 – 7/0		
30173 L	30173 LPR	30173 LPL	30173 LPO
30178 L	30178 LPR	30178 LPL	30178 LPO
	KOH <b>Macro Needle Holder</b> , jaws curved to left, with tungsten carbide inserts, for use with suture material size 0/0 – 7/0		
30173 F	30173 FPR	30173 FPL	30173 FPO
30178 F	30178 FPR	30178 FPL	30178 FPO
	KOH <b>Macro Needle Holder</b> , straight jaws, with tungsten carbide inserts, for use with suture material size 0/0 – 7/0		
30173 G	30173 GPR	30173 GPL	30173 GPO
	KOH <b>Macro Assistant Needle Holder</b> , straight jaws		

## SZABO-BERCI Needle Holders “PARROT-JAW®”

### Size 5 mm


Operating instruments, lengths 33 and 43 cm,  
for use with trocars size 6 mm

Length	Instrument
33 cm	

Distal tip	Instrument
	26173 SC SZABO-BERCI Needle Holder “PARROT-JAW®”, straight handle, with ratchet, for suture material 2/0 – 4/0, needle sizes SH (Ethicon), EN-S (Ski), V-20 (USSC)
	26173 SE SZABO-BERCI Needle Holder “PARROT-JAW®”, jaws with tungsten carbide inserts, straight handle, with ratchet, for suture material 2/0 – 4/0, needle sizes SH (Ethicon), EN-S (Ski), V-20 (USSC)
	26173 CQ SZABO-BERCI Needle Holder “PARROT-JAW®”, straight handle, with ratchet, for suture material 4/0 – 6/0, needle sizes RB (Ethicon), CV-23 (USSC)
	26173 CE SZABO-BERCI Needle Holder “PARROT-JAW®”, jaws with tungsten carbide inserts, straight handle, with ratchet, for suture material 4/0 – 6/0, needle sizes RB (Ethicon), CV-23 (USSC)

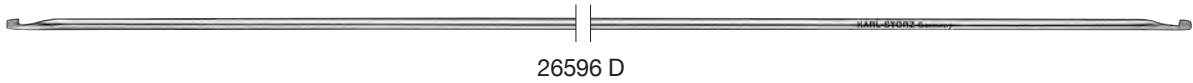
### with diamond coated jaws

Length	Instrument
33 cm	


Distal tip	Instrument
	26173 SP SZABO-BERCI Needle Holder “PARROT-JAW®”, with diamond coated jaws, straight handle, with ratchet, for suture material 2/0 – 4/0, needle sizes SH (Ethicon), EN-S (Ski), V 20 (USSC)



## Knot Tier and Palpation Probe

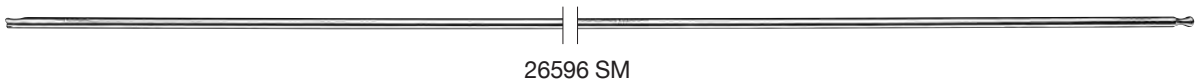


26596 D



26596 D

**Knot Tier**, for extracorporeal knotting, with open and closed end, size 5 mm, length 36 cm




26596 SM



26596 SM

**Knot Tier and Palpation Probe**, size 5 mm, length 50 cm

## Uterine Manipulator



26168 Z

26168 Z KECKSTEIN **Uterine Manipulator**, complete, including:

**Handle**

**Manipulator Sheath**

**Cap**, diameter 37 mm, length 30 mm

**Cap**, diameter 42 mm, length 30 mm

**Spiral Insert**, diameter 15 mm

**Spiral Insert**, diameter 20 mm

**Working Insert**, length 60 mm

**Working Insert**, length 40 mm

**Y-Tube Connector**, length 190 mm

2x **LUER-Lock Tube Connector**

**Seal**

### ALKATOUT Retractor



30623 AR



30623 AR ALKATOUT **Retractor**,  
size 10 mm, length 43 cm

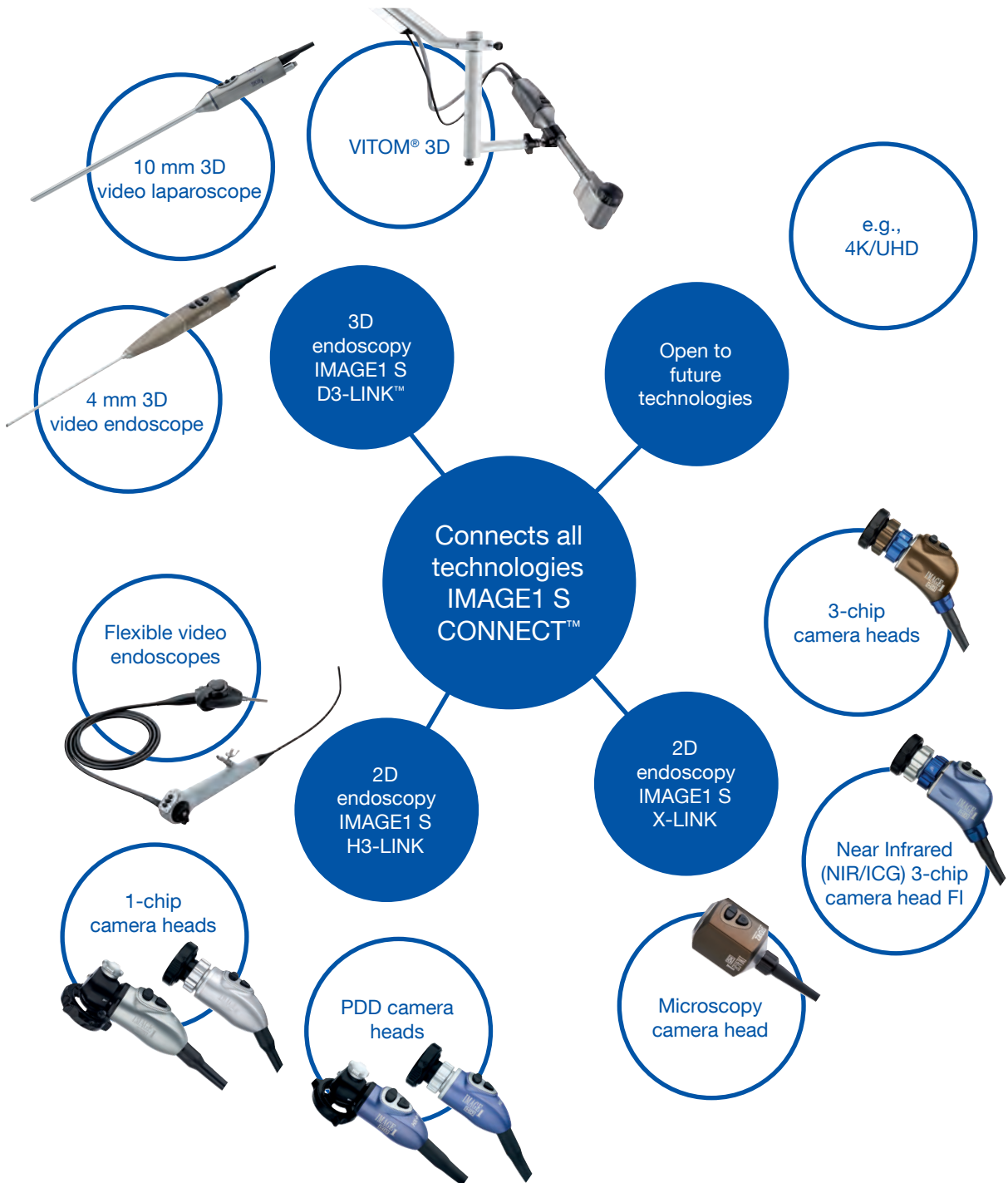


30623 ARS



30623 ARS ALKATOUT **Retractor**,  
size 5 mm, length 43 cm

## IMAGE1 S – A System for all Requirements





## IMAGE1 S

As individual as your requirements

# IMAGE1 S

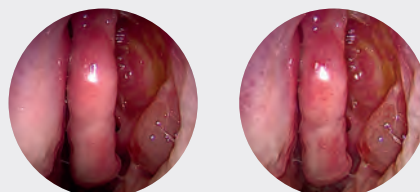
With the IMAGE1 S camera platform, KARL STORZ once again sets a new milestone in endoscopic imaging, consolidating their reputation as an innovative leader in minimally invasive surgery.

The IMAGE1 S camera platform offers surgeons a single system for all applications. As a modular camera platform, IMAGE1 S combines various technologies (e.g., rigid, flexible and 3D endoscopy) in one system and can therefore be adapted to individual customer needs. Furthermore, near infrared (NIR/ICG) for fluorescence imaging, the integration of operating microscopes and the use of VITOM® 3D exoscopes is possible via the camera platform.

### Brilliant imaging

- Versatile visualization options for diagnosis and therapy
- Innovative S-Technologies for easy differentiation of tissue structures
- Clear and razor-sharp imaging
- Natural color rendition
- Automatic light source control

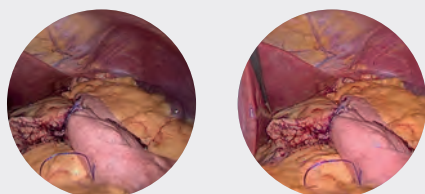
**CLARA + CHROMA:** Homogeneous illumination + contrast enhancement



Standard Image

CLARA + CHROMA

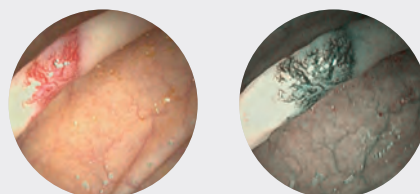
**CLARA:** Homogeneous illumination



Standard Image

CLARA

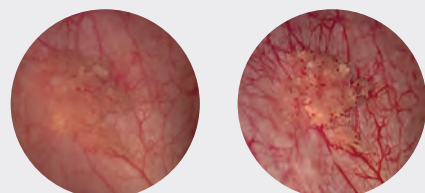
**\*SPECTRA A:** Color hue shift and exchange (filtering reds)



Standard Image

\*SPECTRA A

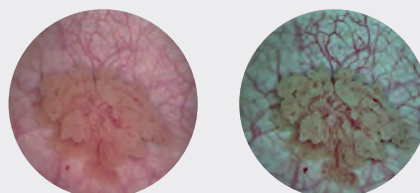
**CHROMA:** Contrast enhancement



Standard Image

CHROMA

**\*SPECTRA B:** Spectral color shift (intensification of greens and blues)



Standard Image

\*SPECTRA B

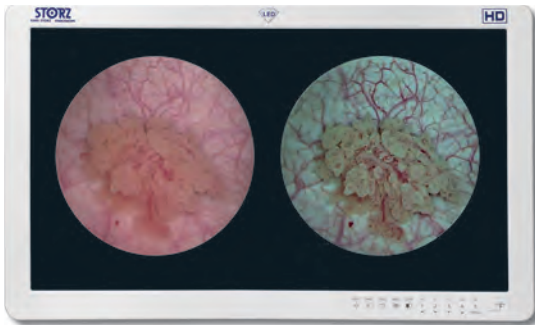
\* SPECTRA A: **Not available for sale in the U.S.A.**

\* SPECTRA B: **Not available for sale in the U.S.A.**

## IMAGE1 S

As individual as your requirements

# IMAGE1 S



Side-by-side View:  
Parallel display of standard image and \*SPECTRA B

### Innovative Design

- Side-by-side View: Parallel display of standard image and visualization mode possible
- Multiple source management: Simultaneous control, display and documentation of two image sources possible (e.g., hybrid procedures)
- Intuitive user guidance (dashboard, live menu and setup menu)
- Intelligent icons display settings and status
- Individual presets possible
- 50 patient data records can be archived



Dashboard



Status indication icons



### Economical and futureproof

- Modular platform: Rigid, flexible and 3D technology can be selected according to individual preferences
- Easy integration of new technologies
- Forward and backward compatibility
- No additional equipment (e.g., special light sources) required for S-Technologies

\* SPECTRA A: **Not available for sale in the U.S.A.**

\* SPECTRA B: **Not available for sale in the U.S.A.**


## IMAGE1 S

As individual as your requirements

# IMAGE1 S

### IMAGE1 S 3D

IMAGE1 S 3D is a further component in the IMAGE1 S camera platform. The 3D system provides surgeons with excellent depth perception. Furthermore, the 3D stereoscopic imaging system is particularly valuable for activities that demand a high degree of spatial perception. The 3D camera platform from KARL STORZ impresses with its wide range of applications – from laparoscopy, gynecology, ENT to microsurgical interventions.

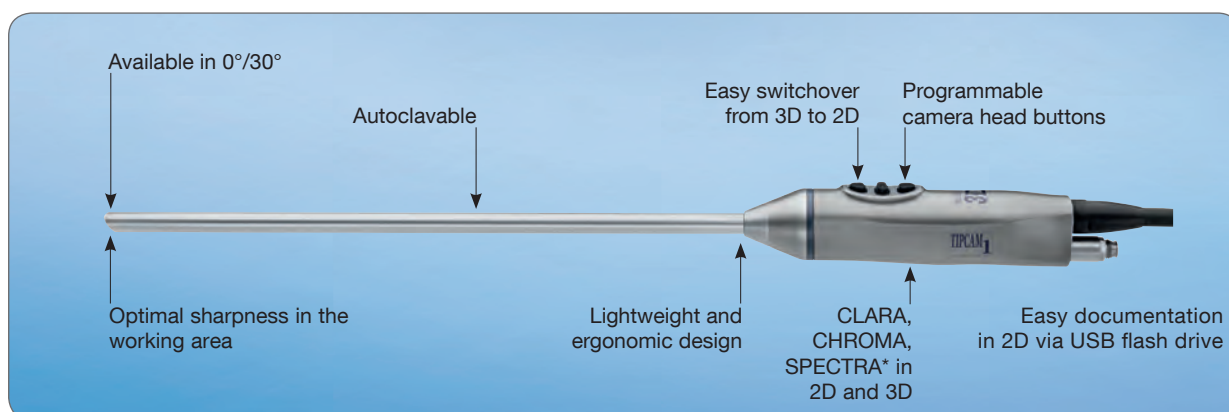


### Benefits of IMAGE1 S 3D

- Brilliant and razor-sharp imaging in 2D and 3D
- Switchover from 3D to 2D at the touch of a button
- Easy integration into the IMAGE1 S platform
- CLARA, CHROMA, SPECTRA\* in 2D and 3D
- 3D system with video endoscopes with diameters of 10 mm and 4 mm as well as VITOM® 3D

### Benefits of 3D integration into the IMAGE1 S camera platform

- Communication between all units
- One system for multiple applications
- Reduced space requirements
- One user interface for all applications
- Synergy effects between the OR workflow and financing



\* SPECTRA: Not available for sale in the U.S.A.



## IMAGE1 S Camera System

# IMAGE1 S



TC 200EN\* **IMAGE1 S CONNECT**, connect module, for use with up to 3 link modules, resolution 1920 x 1080 pixels, with integrated KARL STORZ-SCB and digital Image Processing Module, power supply 100–120 VAC/200–240 VAC, 50/60 Hz including:

**Mains Cord**, length 300 cm

**DVI-D Connecting Cable**, length 300 cm

**SCB Connecting Cable**, length 100 cm

**USB Flash Drive**, 32 GB, USB silicone keyboard, with touchpad, US

\* Available in the following languages: DE, ES, FR, IT, PT, RU

### Specifications:

HD video outputs	- 2x DVI-D - 1x 3G-SDI
Format signal outputs	1920 x 1080p, 50/60 Hz
LINK video inputs	3x
USB interface	4x USB, (2x front, 2x rear)
SCB interface	2x 6-pin mini-DIN

Power supply	100–120 VAC/200–240 VAC
Power frequency	50/60 Hz
Protection class	I, CF-Defib
Dimensions w x h x d	305 x 54 x 320 mm
Weight	2.1 kg

### For use with IMAGE1 S IMAGE1 S CONNECT Module TC 200EN



TC 300 **IMAGE1 S H3-LINK**, link module, for use with IMAGE1 FULL HD three-chip camera heads, power supply 100–120 VAC/200–240 VAC, 50/60 Hz, **for use with IMAGE1 S CONNECT TC 200EN** including:

**Mains Cord**, length 300 cm

**Link Cable**, length 20 cm

### Specifications:

<b>Camera System</b>	<b>TC 300 (H3-Link)</b>
Supported camera heads/video endoscopes	TH 100, TH 101, TH 102, TH 103, TH 104, TH 106 (fully compatible with IMAGE1 S) <b>222200 55-3, 222200 56-3, 222200 53-3, 222200 60-3, 222200 61-3, 222200 54-3, 222200 85-3</b> (compatible without IMAGE1 S technologies CLARA, CHROMA, SPECTRA*)
LINK video outputs	1x
Power supply	100–120 VAC/200–240 VAC
Power frequency	50/60 Hz
Protection class	I, CF-Defib
Dimensions w x h x d	305 x 54 x 320 mm
Weight	1.86 kg

\* SPECTRA A: Not available for sale in the U.S.A.

\*\* SPECTRA B: Not available for sale in the U.S.A.

## IMAGE1 S Camera Heads



For use with IMAGE1 S Camera System  
**IMAGE1 S CONNECT Module TC 200EN, IMAGE1 S H3-LINK Module TC 300**  
 and with all IMAGE1 HUB™ HD Camera Control Units



TH 100

**IMAGE1 S H3-Z Three-Chip FULL HD Camera Head**, 50/60 Hz, IMAGE1 S compatible, progressive scan, soakable, gas- and plasma-sterilizable, with integrated Parfocal Zoom Lens, focal length  $f = 15\text{--}31$  mm (2x), 2 freely programmable camera head buttons, for use with IMAGE1 S and IMAGE1 HUB™ HD/HD



TH 103

**IMAGE1 S H3-P Three-Chip FULL HD Pendulum Camera Head**, 50/60 Hz, IMAGE1 S compatible, **with pendulum system and fixed focus**, progressive scan, soakable, gas- and plasma-sterilizable, focal length  $f = 16$  mm, 2 freely programmable camera head buttons, for use with IMAGE1 S and IMAGE1 HUB™ HD/HD

### Specifications:

IMAGE1 FULL HD Camera Heads	IMAGE1 S H3-Z	IMAGE1 S H3-P
Product no.	TH 100	TH 103
Image sensor	3x 1/8" CCD chip	3x 1/8" CCD chip
Dimensions w x h x d	39 x 49 x 114 mm	35 x 47 x 88 mm
Weight	270 g	226 g
Optical interface	integrated Parfocal Zoom Lens, $f = 15\text{--}31$ mm (2x)	pendulum system, fixed focus $f = 16$ mm
Min. sensitivity	F 1.4/1.17 Lux	F 1.4/1.17 Lux
Grip mechanism	standard eyepiece adaptor	standard eyepiece adaptor
Cable	non-detachable	non-detachable
Cable length	300 cm	300 cm

## IMAGE1 S Camera Heads

# IMAGE1 S

For use with IMAGE1 S Camera System  
**IMAGE1 S CONNECT Module TC 200EN, IMAGE1 S H3-LINK Module TC 300**  
 and with all IMAGE1 HUB™ HD Camera Control Units



TH 104

**IMAGE1 S H3-ZA Three-Chip FULL HD Camera Head**, 50/60 Hz, IMAGE1 S compatible, **autoclavable**, progressive scan, soakable, gas- and plasma-sterilizable, with integrated Parfocal Zoom Lens, focal length  $f = 15\text{--}31\text{ mm}$  (2x), 2 freely programmable camera head buttons, for use with IMAGE1 S and IMAGE1 HUB™ HD/HD

### Specifications:

IMAGE1 FULL HD Camera Heads	IMAGE1 S H3-ZA
Product no.	TH 104
Image sensor	3x 1/8" CCD chip
Dimensions w x h x d	39 x 49 x 100 mm
Weight	299 g
Optical interface	integrated Parfocal Zoom Lens, $f = 15\text{--}31\text{ mm}$ (2x)
Min. sensitivity	F 1.4/1.17 Lux
Grip mechanism	standard eyepiece adaptor
Cable	non-detachable
Cable length	300 cm



39301 Z3TS

**Plastic Container for Sterilization and Storage** of camera heads **IMAGE1 H3-Z, H3-ZA, H3-FA, IMAGE1 S H3-Z, H3-ZA and H3-FA, autoclavable**, suitable for use with steam, gas and hydrogen peroxide sterilization, Sterrad® compatible, external dimensions (w x d x h): 385 x 255 x 75 mm

**Please note:** The instrument displayed is not included in the plastic container.

Only camera heads marked "autoclave" can be placed in the tray for steam sterilization.



39301 PHTS

**Plastic Container for Sterilization and Storage** of camera heads **IMAGE1 H3-P, H3-ZI, IMAGE1 S H3-P and H3-ZI, autoclavable**, suitable for use with steam, gas and hydrogen peroxide sterilization, Sterrad® compatible, external dimensions (w x d x h): 385 x 255 x 75 mm

**Please note:** The instrument displayed is not included in the plastic container.

Only camera heads marked "autoclave" can be placed in the tray for steam sterilization.



## Monitors



9619 NB

**19" HD Monitor,**  
color systems **PAL/NTSC**, max. screen  
resolution 1280 x 1024, image format 4:3,  
power supply 100–240 VAC, 50/60 Hz,  
wall-mounted with VESA 100 adaption,  
including:  
**External 24 VDC Power Supply**  
**Mains Cord**



9826 NB

**26" FULL HD Monitor,**  
wall-mounted with VESA 100 adaption,  
color systems **PAL/NTSC**,  
max. screen resolution 1920 x 1080,  
image format 16:9,  
power supply 100–240 VAC, 50/60 Hz  
including:  
**External 24 VDC Power Supply**  
**Mains Cord**

## Monitors

KARL STORZ HD and FULL HD Monitors	19"	26"
Wall-mounted with VESA 100 adaption	9619 NB	9826 NB
<b>Inputs:</b>		
DVI-D	●	●
Fibre Optic	–	–
3G-SDI	–	●
RGBS (VGA)	●	●
S-Video	●	●
Composite/FBAS	●	●
<b>Outputs:</b>		
DVI-D	●	●
S-Video	●	–
Composite/FBAS	●	●
RGBS (VGA)	●	–
3G-SDI	–	●
<b>Signal Format Display:</b>		
4:3	●	●
5:4	●	●
16:9	●	●
Picture-in-Picture	●	●
PAL/NTSC compatible	●	●

### Optional accessories:

9826 SF      **Pedestal**, for monitor 9826 NB

9626 SF      **Pedestal**, for monitor 9619 NB

### Specifications:

KARL STORZ HD and FULL HD Monitors	19"	26"
<b>Desktop with pedestal</b>	optional	optional
Product no.	9619 NB	9826 NB
Brightness	200 cd/m <sup>2</sup> (type)	500 cd/m <sup>2</sup> (type)
Max. viewing angle	178° vertical	178° vertical
Pixel distance	0.29 mm	0.3 mm
Reaction time	5 ms	8 ms
Contrast ratio	700:1	1400:1
Mount	100 mm VESA	100 mm VESA
Weight	7.6 kg	7.7 kg
Rated power	28 W	72 W
Operating conditions	0–40°C	5–35°C
Storage	-20–60°C	-20–60°C
Rel. humidity	max. 85%	max. 85%
Dimensions w x h x d	469.5 x 416 x 75.5 mm	643 x 396 x 87 mm
Power supply	100–240 VAC	100–240 VAC
Certified to	EN 60601-1, protection class IPX0	EN 60601-1, UL 60601-1, MDD93/42/EEC, protection class IPX2

## Cold Light Fountain Power LED 300 SCB <sup>NEW</sup>



TL 300

**Cold Light Fountain Power LED 300** with integrated KARL STORZ-SCB, high-performance LED module and one KARL STORZ light outlet, power supply: 100–240 VAC, 50/60 Hz including: **Mains Cord**

## Fiber Optic Light Cable



495 NCSC

**Fiber Optic Light Cable**, with straight connector, extremely heat-resistant, with safety lock, diameter 4.8 mm, length 250 cm

495 TIP

**Fiber Optic Light Cable**, with straight connector, extremely heat-resistant, enhanced light transmission, diameter 4.8 mm, length 300 cm, for use with TIPCAM®

## AUTOCON® III 400 SCB <sup>NEW</sup>



\* UH 400

**AUTOCON® III 400 High-End, Set**, with KARL STORZ SCB control NEO, power supply 220–240 VAC, 50/60 Hz, HF connecting sockets unipolar: 2 x 3-pin US type, 5 mm connector KARL STORZ/Erbe VIO, 2 x 4 mm connector (via footswitch), BOVIE (via footswitch) bipolar: 2 x 2-pin US type (28.58), 3x KARL STORZ/Erbe VIO, neutral electrode 2-pol. System requirements: SCB-R-UI Software Release 20090001-46 or higher including: **Mains Cord**

\* Not available for sale in the U.S.A.



# ENDOFLATOR® 40 SCB <sup>NEW</sup>

## Recommended System Configuration

### Special Features:

- High degree of patient safety due to CF application part
- Ease of use thanks to touch screen control
- Clear, adjacent displays for set value and actual value facilitate monitoring of the insufflation process
- Fast and reliable insufflation via an adjustable flow rate up to 40 l/min
- Innovative sensitive mode with special safety limits for sensitive applications
- Automatic adjustment of insufflation rate to diverse instrument resistance values ensures the fastest possible insufflation
- Fully automatic, electronically controlled gas refill (e. g. in case of gas loss when changing instruments)
- SECUVENT® Safety System: Constant monitoring of intraabdominal pressure; any overpressure is reduced immediately
- SCB model with connections to the KARL STORZ Communication Bus (KARL STORZ-SCB)




UI400 S1

**ENDOFLATOR® 40 SCB**, with integrated SCB module, power supply 100 – 240 VAC, 50/60 Hz including:

**Mains Cord**, length 300 cm

**SCB Connecting Cable**, length 100 cm

**Universal Wrench**

**Insufflation Tubing Set\***, with gas filter, sterile, STERILE  for single use, package of 5

### Specifications:

Operating mode	- high-flow mode - sensitive mode
Gas flow	- sensitive mode: 0.1–15 l/min - high-flow mode: 1–40 l/min
Pressure	- sensitive mode: 1–15 mmHg - high-flow mode: 1–30 mmHg
Gas	CO <sub>2</sub>
Measuring/control system	electronic
Parameter display	- set pressure - actual pressure (intraabdominal) - gas flow - gas consumption: 0–999 l - status indicator for gas supply

SECUVENT® safety system	●
Power supply	100–240 VAC, 50/60 Hz
Dimensions w x h x d	305 x 164 x 315 mm
Weight	6 kg
Certified to	IEC 601-1, CE acc. to MDD

## ENDOFLATOR® 50 SCB <sup>NEW</sup>

with Speed-flow Insufflation (50 l/min),  
Recommended Standard Set Configuration

### Special Features:

- Ease of use due to large, color 7" touch screen
- Simultaneous display of set values and actual values facilitate monitoring of the insufflation process
- Automatic adjustment of insufflation rate to diverse instrument resistance values ensures the fastest possible insufflation
- Fully automatic, electronically controlled gas refill (e.g. in case of gas loss when changing instruments)
- **SECUVENT® Safety System: Constant monitoring of intraabdominal pressure**
- Very high gas flow capacity of up to 50 l/min
- Especially suitable for providing a high gas flow when using smoke generating techniques
- Powerful high-flow mode for fast insufflation of large gas volumes up to 50 l/min
- A High-Capability Trocar (HiCap®) is a recommended option
- Tubing set with integrated heating element for preheating gas to body temperature to prevent peritoneum from cooling down
- SCB model with connections to the KARL STORZ Communication Bus (KARL STORZ-SCB)



UI500 S1

**ENDOFLATOR® 50 SCB**, with integrated SCB module,  
power supply 100 – 240 VAC, 50/60 Hz  
including:

**Mains Cord**, length 300 cm

3x **Insufflation Tubing Set\***, with integrated gas heater  
and gas filter, for single use, sterile

STERILE 

5x **Insufflation Tubing Set\***, with gas filter, for single use, sterile

STERILE 

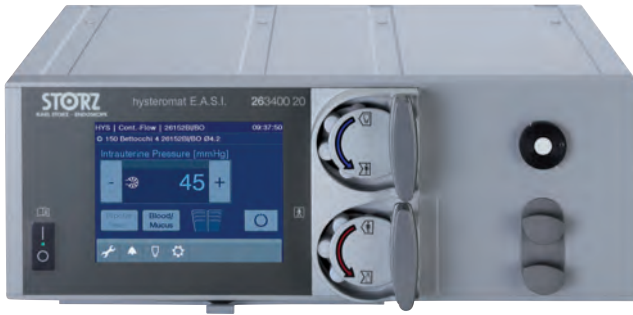**Universal Wrench**

**SCB Connecting Cable**, length 100 cm

### Specifications:

Operating mode	- high-flow mode - sensitive mode
Gas flow	- sensitive mode: 0.1–15 l/min - high-flow mode: 1–40 l/min
Pressure	- sensitive mode: 1–15 mmHg - high-flow mode: 1–30 mmHg
Gas	CO <sub>2</sub>
Measuring/control system	electronic
Parameter display	- set pressure - actual pressure (intraabdominal) - gas flow - gas consumption: 0–999 l - status display gas consumption

SECUVENT® safety system	●
Gas heating	●
Power supply	100–240 VAC, 50/60 Hz
Dimensions w x h x d	305 x 164 x 315 mm
Weight	7.7 kg
Certified to	IEC 601-1, CE acc. to MDD

**HYSTEROMAT E.A.S.I.™**



- ♦ 26340001-1 **HYSTEROMAT E.A.S.I.™ Set**, power supply 100 – 240 VAC, 50/60 Hz, HYSTEROMAT E.A.S.I.™: SCB ready, compatible from RUI Release 44, including:

**Mains Cord**

**SCB Connecting Cable**, length 100 cm

\* **Basic Tubing Set**, for single use

**Recommended accessories:**

- \* 031717-10 **IRRIGATION tubing set**, STERILE   
for single use, sterile, package of 10, for use with KARL STORZ HYSTEROMAT E.A.S.I.™
- \* 031217-10 **SUCTION tubing set**, STERILE   
for single use, sterile, package of 10, for use with KARL STORZ HYSTEROMAT E.A.S.I.™

**Optional accessories:**



- 26340330 **Two-Pedal Footswitch**, one-stage, digital, for use with HYSTEROMAT E.A.S.I.™

♦ Not available for sale in the U.S.A.

**HAMOU® ENDOMAT® with KARL STORZ SCB****Suction and Irrigation System**

- ♦ 26331101-1 **HAMOU® ENDOMAT® SCB**, power supply 100 – 240 VAC, 50/60 Hz including:
- Mains Cord**
- 5x **HYST Tubing Set\***, for single use
- 5x **LAP Tubing Set\***, for single use
- SCB Connecting Cable**, length 100 cm
- VACUsafe Promotion Pack Suction\***, 2 l

**Recommended accessories:**

- \*031517-10 **Cassette Tubing Set**, Hysteroscopy, STERILE   
Hysteroscopy, with two puncture needles, for single use, sterile, package of 10
- \*031518-10 **Cassette Tubing Set**, Laparoscopy, STERILE   
for single use, sterile, package of 10

♦ Not available for sale in the U.S.A.



## ENDOMAT® SELECT SCB

Roller Pump – Suction / Irrigation System,  
Recommended System Configuration

### Special Features:

- Easy-to-use pressure-/flow-regulated roller pump system, for suction / irrigation
- Activation via footswitch of UNIDRIVE® S III motor system
- Interdisciplinary application combined with user-friendly interface and convenient handling of accessories
- SCB model with connections to the KARL STORZ Communication Bus (KARL STORZ-SCB)
- Upgradeable via Ethernet-interface



- ♦ UP 210 **ENDOMAT® Select SCB** with integrated KARL STORZ-SCB module, suction and irrigation pump, power supply 100 – 240 VAC, 50/60 Hz including:  
**Mains Cord**
- UP 601 **Surgery, Software**, License for selection of „LAP“, „THOR“ and „PROCTO“ procedures
- UP 602 **Hysteroscopy, Software**, License for selection of „HYS“ procedure
- UP 603 **IBS® Shaver, Software**, License for selection of „IBS®-Shaver“ procedure
- UP 609 **Advanced Package, Software**, License, extends functions of installed software packages, for use with ENDOMAT® SELECT UP 210

### Recommended optional accessories (Plural):

- \*031523-10 **Tubing Set**, Irrigation, PC, for single use, sterile, package of 10 STERILE
- \*031524-10 **Tubing Set**, Irrigation, FC, for single use, sterile, package of 10 STERILE
- \*030647-10 **Tubing Set**, Suction, DS, for single use

### Specifications:

HYS Procedure: (Pressure-regulated)	- Pressure	Max. 150 mmHg
	- Flow	200/400/600 ml/min
IBS® Procedure (Suction)	- Suction	Max. 1800 ml/min
LAP Procedure (Flow-regulated)	- Flow	Max. 3500 ml/min
	- Pressure	100/300/500 mmHg

Dimensions w x h x d	305 x 110 x 260 mm
Weight	4.7 kg
Certified to	IEC 601-1, CE acc. to MDD



♦ Not available for sale in the U.S.A.

## Data Management and Documentation

### KARL STORZ AIDA® – Exceptional documentation



The name AIDA stands for the comprehensive implementation of all documentation requirements arising in surgical procedures: A tailored solution that flexibly adapts to the needs of every specialty and thereby allows for the greatest degree of customization.

This customization is achieved in accordance with existing clinical standards to guarantee a reliable and safe solution. Proven functionalities merge with the latest trends and developments in medicine to create a fully new documentation experience – AIDA.

AIDA seamlessly integrates into existing infrastructures and exchanges data with other systems using common standard interfaces.



WD 200-XX\* **AIDA Documentation System**,  
for recording still images and videos,  
dual channel up to FULL HD, 2D/3D,  
power supply 100-240 VAC, 50/60 Hz  
including:

**USB Silicone Keyboard**, with touchpad  
**ACC Connecting Cable**  
**DVI Connecting Cable**, length 200 cm  
**HDMI-DVI Cable**, length 200 cm  
**Mains Cord**, length 300 cm



WD 250-XX\* **AIDA Documentation System**,  
for recording still images and videos,  
dual channel up to FULL HD, 2D/3D,  
**including SMARTSCREEN® (touch screen)**,  
power supply 100-240 VAC, 50/60 Hz  
including:

**USB Silicone Keyboard**, with touchpad  
**ACC Connecting Cable**  
**DVI Connecting Cable**, length 200 cm  
**HDMI-DVI Cable**, length 200 cm  
**Mains Cord**, length 300 cm

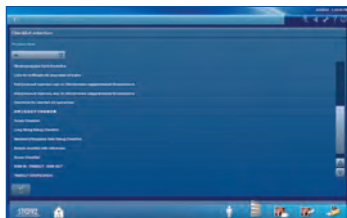
\*XX Please indicate the relevant country code  
(DE, EN, ES, FR, IT, PT, RU) when placing your order.

## Workflow-oriented use



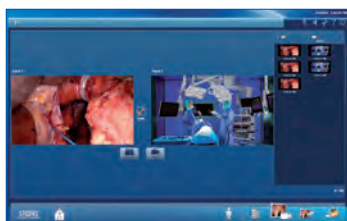### Patient

Entering patient data has never been this easy. AIDA seamlessly integrates into the existing infrastructure such as HIS and PACS. Data can be entered manually or via a DICOM worklist. All important patient information is just a click away.



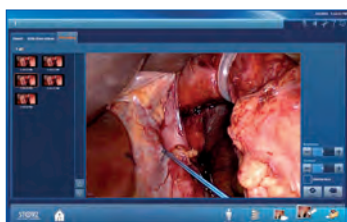### Checklist

Central administration and documentation of time-out. The checklist simplifies the documentation of all critical steps in accordance with clinical standards. All checklists can be adapted to individual needs for sustainably increasing patient safety.



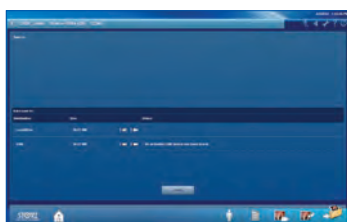
### Record

High-quality documentation, with still images and videos being recorded in FULL HD and 3D. The Dual Capture function allows for the parallel (synchronous or independent) recording of two sources. All recorded media can be marked for further processing with just one click.



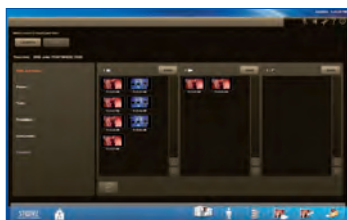### Edit

With the Edit module, simple adjustments to recorded still images and videos can be very rapidly completed. Recordings can be quickly optimized and then directly placed in the report. In addition, freeze frames can be cut out of videos and edited and saved. Existing markings from the Record module can be used for quick selection.



### Complete

Completing a procedure has never been easier. AIDA offers a large selection of storage locations. The data exported to each storage location can be defined. The Intelligent Export Manager (IEM) then carries out the export in the background. To prevent data loss, the system keeps the data until they have been successfully exported.



### Reference

All important patient information is always available and easy to access. Completed procedures including all information, still images, videos, and the checklist report can be easily retrieved from the Reference module.



## Equipment Cart



UG 220

UG 220

### Equipment cart

wide, high, rides on 4 antistatic dual wheels equipped with locking brakes 3 shelves, mains switch on top cover, central beam with integrated electrical subdistributors with 12 sockets, holder for power supplies, potential earth connectors and cable winding on the outside,

#### Dimensions:

*Equipment cart:* 830 x 1474 x 730 mm (w x h x d),

*shelf:* 630 x 510 mm (w x d),

*caster diameter:* 150 mm

including:

**Base module equipment cart,** wide

**Cover equipment,** equipment cart wide


**Beam package equipment,** equipment cart high

3x **Shelf,** wide

**Drawer unit with lock,** wide

2x **Equipment rail,** long

**Camera holder**



UG 540

UG 540

### Monitor swivel arm,

height and side adjustable, can be turned to the left or the right side, swivel range 180°, overhang 780 mm, overhang from centre 1170 mm, load capacity max. 15 kg, with monitor fixation VESA 5/100, for usage with equipment carts UG xxx

## Recommended Accessories for Equipment Cart



UG 310

**UG 310 Isolation Transformer,**  
200 V–240 V; 2000 VA with 3 special mains socket,  
expulsion fuses, 3 grounding plugs,  
dimensions: 330 x 90 x 495 mm (w x h x d),  
for usage with equipment carts UG xxx



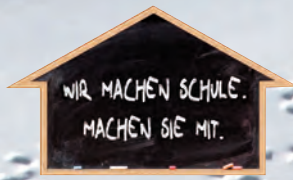UG 410

**UG 410 Earth leakage monitor,**  
200 V–240 V, for mounting at equipment cart,  
control panel dimensions: 44 x 80 x 29 mm (w x h x d),  
for usage with isolation transformer UG 310



UG 510

**UG 510 Monitor holding arm,**  
height adjustable, inclinable,  
mountable on left or right,  
turning radius approx. 320°, overhang 530 mm,  
load capacity max. 15 kg,  
monitor fixation VESA 75/100,  
for usage with equipment carts UG xxx



**Liselotte Mettler, Ibrahim Alkatout, Jörg Keckstein  
and Ivo Meinhold-Heerlein**

Endometriosis - A Concise Practical Guide to Current Diagnosis and Treatment

**Voluntary Appeal for Donations to the  
“Stiftung St. Franziskus Heiligenbronn”  
[St. Francis Foundation, Heiligenbronn, Germany]**

**DONATE TO CHILDREN WITH SENSORY DISABILITIES  
A PERSPECTIVE**

Children want to make something of themselves, even if they have sensory disabilities, are blind, hearing impaired, or deaf-blind. Unfortunately, these children’s disabilities are often severe enough to keep them from attending “normal” schools.

The “stiftung st. franziskus heiligenbronn“ is building two new schools for children with sensory disabilities to give these boys and girls a future and the opportunity to lead a successful life. You can help – with your donation for children with sensory disabilities.

**KARL STORZ will help, too.**

As an ambassador for the fundraising campaign “Wir machen Schule. Machen Sie mit!” [We set an example. Get involved!], KARL STORZ is again taking social responsibility. We have made it our mission to help children with sensory disabilities throughout the German state of Baden-Wuerttemberg, and to familiarize our customers and business partners with this fundraising campaign’s worthy cause.

Please help support the fundraising campaign  
**“Wir machen Schule. Machen Sie mit.”**

For additional information, go to [www.wir-machen-schule-machen-sie-mit.de](http://www.wir-machen-schule-machen-sie-mit.de)

For bank transfers from abroad:  
IBAN: DE56642500400000540340  
SWIFT/BIC-Code: SOLA DE S1 RWL

**STORZ**  
KARL STORZ – ENDOSKOPE



**Notes**

## Notes

**Notes**





