

Ultrasonographically detectable markers of fetal chromosomal defects

K. Nicolaidis, L. Shawwa, M. Brizot and R. Snijders

Harris Birthright Research Centre for Fetal Medicine, King's College Hospital Medical School, London, UK

Key words: ULTRASONOGRAPHY, PRENATAL DIAGNOSIS, KARYOTYPING, CORDOCENTESIS, FETAL CHROMOSOMAL DEFECTS

Most fetuses with major cytogenetic abnormalities have either external or internal defects¹, which can be recognized by detailed ultrasonographic examination. Since it is now well accepted that such a detailed ultrasound examination should be offered routinely to all pregnant women², it is very likely that ultrasonography will constitute the most effective method of screening for chromosomal abnormalities.

This article reviews the incidence of chromosomal abnormalities in a wide range of fetal malformations and the phenotypic expression of the different types of chromosomal abnormalities in prenatal ultrasonographic studies.

BRAIN ABNORMALITIES

Ventriculomegaly

Several reports on fetal hydrocephalus have established an association with chromosomal defects (Table 1)³⁻¹⁶. However, many of these studies included other brain abnormalities, such as holoprosencephaly or poren-

cephalic cysts, and they did not provide data on the presence of other system malformations. Nevertheless, in a study of 105 fetuses with lateral cerebral ventriculomegaly, excluding those where the hydrocephalus was due to spina bifida, abnormal karyotypes were found in two of 42 (5%) with isolated ventriculomegaly and in 40 of 144 (28%) of those with additional malformations (Table 2)¹⁶. In the chromosomally abnormal fetuses, there was a tendency for the degree of ventriculomegaly to be mild (Figure 1)¹².

Holoprosencephaly

Fetal holoprosencephaly is associated with a high incidence of other morphological and chromosomal defects, mainly trisomy 13 (Table 3)¹⁶⁻²⁰. The incidence of chromosomal abnormalities is strongly related to the presence of multisystem malformations. Thus, in one series, chromosomal defects were found in 12 of 26 (46%) fetuses with holoprosencephaly and extrafacial defects but in none of the 23 where the holoprosencephaly was either isolated or it was associated with facial defects only²⁰.

Table 1 Summary of reports on antenatally diagnosed hydrocephalus providing data on the presence of other defects. Under abnormal karyotype, data are provided, where possible, only for cases without holoprosencephaly

Author	n	Other defects			
		Total (%)	Holoprosencephaly (%)	Neural tube defects (%)	Abnormal karyotype (%)
Chervenak <i>et al.</i> ³	53	44 (83)	—	15 (28)	4/?
Cochrane <i>et al.</i> ⁴	41	32 (78)	3 (7)	15 (37)	1/?
Pretorius <i>et al.</i> ⁵	40	28 (70)	1 (3)	13 (33)	2/7 (29)
Pilu <i>et al.</i> ⁶	30	9 (30)	—	—	3/30 (10)
Serlo <i>et al.</i> ⁷	38	32 (84)	1 (3)	—	4/?
Nyberg <i>et al.</i> ⁸	61	51 (84)	13 (21)	23 (38)	2/21 (10)
Vintzileos <i>et al.</i> ⁹	20	16 (70)	1 (5)	6 (30)	2/19 (11)
Hudgins <i>et al.</i> ¹⁰	47	35 (74)	15 (32)	—	1/47 (2)
Drugan <i>et al.</i> ¹¹	43	31 (72)	3 (7)	18 (42)	5/19 (26)
Nicolaidis <i>et al.</i> ^{12*}	267	209 (78)	—	184 (67)	12/64 (19)
Bromley <i>et al.</i> ¹³	44	17 (39)	—	3 (18)	5/12 (42)
Anhoury <i>et al.</i> ¹⁴	85	46 (54)	—	2 (48)	6/33 (18)
Brummfield <i>et al.</i> ¹⁵	24	—	—	—	3/24 (13)
Nicolaidis <i>et al.</i> ¹⁶	186	144 (77)	—	—	42/186 (23)

*Cases included in Nicolaidis *et al.*¹⁶, with permission

Table 2 Gestation at referral and incidence of chromosomal abnormalities for ultrasonographically detectable fetal malformations and/or growth retardation. From Nicolaides *et al.*¹⁶, reproduced with permission

	Gestation at referral (weeks)		Number with chromosomal abnormality/total with defect (%)		Chromosomal abnormalities					
	Median	Range	Isolated (%)*	Multiple (%)	Trisomy					
					21	18	13	Triploidy	Turner	Other [†]
Brachycephaly	23	17-38	—	43/114 (38)	7	19	5	3	8	1
Strawberry-shaped head	24	16-39	—	44/54 (82)	—	43	—	1	—	—
Microcephaly	22	18-37	—/1	8/51 (16)	1	1	3	—	—	3
Ventriculomegaly	23	16-38	2/42 (5)	40/144 (28)	7	12	3	12	3	5
Holoprosencephaly	22	17-36	—/7	15/51 (29)	—	3	11	—	—	1
Choroid plexus cyst	21	16-38	1/49 (2)	33/72 (46)	2	30	1	—	—	1
Posterior fossa cyst	22	16-38	—/1	21/44 (48)	—	8	6	3	—	4
Facial cleft	22	17-37	—/8	31/56 (55)	1	10	15	1	—	4
Micrognathia	23	17-37	—	37/56 (66)	—	21	3	9	—	4
Macroglossia	24	20-37	—	10/13 (77)	9	—	—	—	—	1
Nuchal edema	21	16-38	—/12	53/132 (40)	31	5	7	2	3	5
Cystic hygromata	19	16-35	—/4	35/48 (73)	1	1	—	—	33	—
Hydrops	26	16-39	7/104 (7)	18/106 (17)	14	1	2	2	2	4
Diaphragmatic hernia	21	17-38	—/38	17/41 (41)	—	10	2	1	—	4
Heart defect	23	17-39	—/4	101/152 (66)	21	37	14	4	16	9
Exomphalos	21	16-39	1/30 (3)	41/86 (48)	—	32	7	1	—	2
Duodenal atresia	32	20-36	1/6 (17)	9/17 (53)	10	—	—	—	—	—
Esophageal atresia	27	20-37	—/1	18/23 (78)	1	17	—	—	—	—
Renal defects	22	16-40	9/482 (2)	87/360 (24)	23	25	20	5	8	15
Abnormal extremities	23	16-40	—/18	195/457 (43)	35	71	21	38	22	8
Growth retardation	28	17-39	4/251 (2)	133/424 (31)	13	48	15	40	9	12

*Trisomies: 8 (*n* = 1), 21 (*n* = 9) and 22 (*n* = 2); duplication marker (*n* = 1); deletions: 2q (*n* = 1), 3p (*n* = 1), 4p (*n* = 4) and 5p (*n* = 1); unbalanced translocations: (1;1) and (11;12); Turner's syndrome (*n* = 2, one mosaic), 47,XXY (*n* = 2), 47,XYY (*n* = 1)
[†]Trisomies: 8 (*n* = 1), 9 (*n* = 2) and 22 (*n* = 2), isochromosome 12p (*n* = 2); duplications: 4q (*n* = 1), 11p (*n* = 1) and marker (*n* = 1); deletions: 2q (*n* = 3), 3p (*n* = 1), 4p (*n* = 5), 5p (*n* = 1), 5q (*n* = 1), 6p (*n* = 1), 7q (*n* = 1), 8q (*n* = 1), 8p (*n* = 1), 9p (*n* = 1), 13q (*n* = 1), 14q (*n* = 1), and 21q (*n* = 1); unbalanced translocations: (1;1), (11;12), (4;15), and (17;19); 47,XXY (*n* = 3); 47,XYY (*n* = 2)

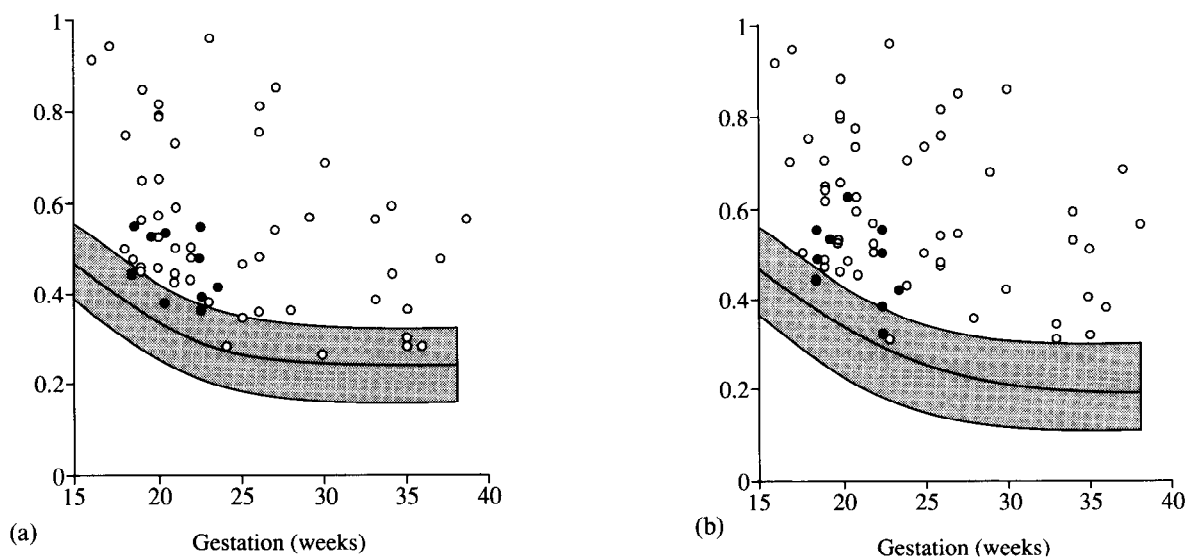


Figure 1 Anterior (a) and posterior (b) lateral cerebral ventricle : hemisphere ratio in 64 fetuses with ventriculomegaly that were karyotyped antenatally, plotted on the appropriate reference range (mean, 5th and 95th centiles) for gestation. The chromosomally abnormal fetuses (●) tended to have mild ventriculomegaly

Microcephaly

In a series of 2086 fetuses that were karyotyped because of fetal malformations or growth retardation, microcephaly defined by head circumference to femur length ratio < 2.5th centile was diagnosed in 52 cases and eight (16%) were chromosomally abnormal (Table 2)¹⁶.

Choroid plexus cysts

Several reports have documented the association between choroid plexus cysts and chromosomal abnormalities, mainly trisomy 18 (Table 4)^{16,21-30}. In the vast majority of cases, the chromosomally abnormal fetuses had additional malformations. However, there are cases in which

the cysts were the only antenatal finding, and at present there is considerable controversy as to whether fetal karyotyping should be undertaken for apparently isolated choroid plexus cysts^{28,29,31,32}.

Absent corpus callosum

A small number of case reports have established an association of agenesis of the corpus callosum and trisomies 8, 13, 18 and triploidy³³⁻³⁵. In the largest prenatal series, Bertino and colleagues found trisomy 8 in one of five fetuses³⁵.

Short frontal lobe

Frontothalamic distance is measured from the inner table of the frontal bone to the posterior thalamus. In a study of 19 trisomy 21 fetuses and 125 normal controls at 16-21 weeks' gestation, the frontothalamic distance to biparietal diameter ratio was significantly lower in the trisomic fetuses. When the observed to expected ratio was ≤ 0.84 , the positive predictive value was 1.2% for a population with a 0.37% risk for trisomy 21; the sensitivity and specificity were 21% and 95%, respectively³⁶.

Posterior fossa abnormalities

In a series of 46 fetuses with posterior fossa cysts, 45 had additional defects, and 20 (43%) had chromosomal abnormalities, mainly trisomies 18 and 13 (Table 2)¹⁶. Nyberg and colleagues³⁷ examined 33 fetuses with enlarged cisterna magna (≥ 10 mm) at 16-38 weeks' gestation and 18 (55%) had chromosomal abnormalities, mainly trisomies 18 and 13. The risk for chromosomal abnormalities was much higher in fetuses with multisystem malformations and in those where the enlarged cisterna magna was not associated with lateral cerebral ventriculomegaly. In contrast, Watson and colleagues³⁸, in a study of 585 fetuses undergoing karyotyping at 14-21

weeks' gestation, found no significant difference in mean cisterna magna diameter of the 28 chromosomally abnormal fetuses from those with a normal karyotype.

ABNORMALITIES OF THE SHAPE OF THE SKULL

Strawberry skull

In some fetuses with trisomy 18, there is a characteristic shape of the head that is best seen in the suboccipito-bregmatic view. There is flattening of the occiput and narrowing of the frontal part of the head. The most likely explanation for the narrow frontal region is hypoplasia of the face and frontal cerebral lobes. Similarly, flattening of the occiput may be due to hypoplasia of the hindbrain. In a series of 54 fetuses with strawberry-shaped head, they all had additional malformations and 44 (81%) had chromosomal abnormalities³⁹.

Brachycephaly

In postnatal life it is well recognized that children with trisomy 21 have brachycephaly. In a prenatal study, however, Perry and colleagues⁴⁰ found no difference in the mean cephalic index between eight second-trimester fetuses with trisomy 21 and 308 normal fetuses. Similarly, Shah and colleagues⁴¹ found no significant difference in

Table 3 Summary of major series on antenatally diagnosed holoprosencephaly providing data on the presence of associated malformations and chromosomal defects

Author	n	Other defects		Abnormal karyotype
		Facial	Extracranial	
Filly <i>et al.</i> ¹⁷	5	—	—	1/?
Chervenak <i>et al.</i> ¹⁸	7	—	1	4/7
Nyberg <i>et al.</i> ¹⁹	14	3	4	6/11
Berry <i>et al.</i> ^{20*}	49	14	26	12/49
Nicolaides <i>et al.</i> ²¹	58	—	—	15/58

*Cases included in Nicolaides *et al.*¹⁶, with permission

Table 4 Summary of reports providing data on antenatal karyotyping for fetal choroid plexus cysts. Several reports have established that the incidence of choroid plexus cysts is 1-2% at 16-18 weeks' gestation and in thousands of cases there were no other defects. However, these studies did not undertake fetal karyotyping

Author	Abnormal karyotypes						
	Incidences			Types			
	Total	Isolated	+ Other defects	13	18	21	Other
Nicolaides <i>et al.</i> ²¹	3/4	—	3/4	—	3	—	—
Ricketts <i>et al.</i> ²²	1/4	0/3	1/1	—	—	1	—
Chitkara <i>et al.</i> ²³	1/30	0/27	1/3	—	1	—	—
Gabrielli <i>et al.</i> ²⁴	4/65	0/60	4/5	—	4	—	—
Thorpe-Beeston <i>et al.</i> ^{25*}	20/46	0/12	20/34	1	16	—	3
Achiron <i>et al.</i> ²⁶	2/16	1/15	1/1	—	2	—	—
Twinning <i>et al.</i> ²⁷	2/3	—	2/3	—	1	1	—
Platt <i>et al.</i> ²⁸	4/62	0/?	4/?	—	3	1	—
Perpignano <i>et al.</i> ²⁹	6/83	5/?	1/?	—	4	1	1
Rotmensch <i>et al.</i> ³⁰	1/1	1/1	—	—	—	1	—
Nicolaides <i>et al.</i> ¹⁶	34/121	1/49	33/72	1	30	2	1

*Cases included in Nicolaides *et al.*¹⁶, with permission

the biparietal diameter, occipitofrontal diameter or cephalic index between 17 fetuses with trisomy 21 at 15–23 weeks' gestation and 17 matched controls. In our series of 114 fetuses with brachycephaly (biparietal to occipitofrontal diameter ratio > 97.5th centile), 43 had chromosomal abnormalities, including trisomies 13, 18 and 21, triploidy and Turner's syndrome (Table 2)¹⁶. However, in our total series of 69 fetuses with trisomy 21 and 231 fetuses with other chromosomal abnormalities, 90% and 84%, respectively had a biparietal to occipitofrontal diameter ratio < 97.5th centile.

FACIAL DEFECTS

Facial cleft

Postnatally, chromosomal abnormalities are found in less than 1% of babies with facial clefts⁴². However, in two prenatal series, the incidence of chromosomal abnormalities, mainly trisomies 13 and 18, was four of ten and 31 of 64 (48%), respectively^{43,44}. In all chromosomally abnormal fetuses, there were additional malformations.

Ocular and nasal abnormalities

A variety of eye abnormalities, such as hypotelorism and cyclopia, and nasal defects, such as nasal aplasia or hypoplasia, single nostril, or proboscis, are often seen in the presence of holoprosencephaly. Although all chromosomally abnormal fetuses with holoprosencephaly have extracraniofacial defects, the risk for chromosomal abnormalities increases if facial defects are also present⁴⁴.

Macroglossia

Postnatally, macroglossia is a common feature of trisomy 21. Antenatally, an enlarged tongue protruding through the open mouth can be demonstrated in the mid-sagittal view of the face. In a series of 69 fetuses with trisomy 21, macroglossia was diagnosed in nine; 10% (five of 49) of those examined at < 28 weeks and 20% (four of 20) of those diagnosed ≥ 28 weeks. It is possible that with advancing gestation there is progressive enlargement/protrusion of the tongue to account for the higher incidence of macroglossia at term⁴⁴.

Micrognathia

Postmortem studies have demonstrated micrognathia to be present in > 80% of fetuses with trisomy 18 or triploidy⁴⁵. However, in an ultrasonographic study of 83 fetuses with trisomy 18 and 42 with triploidy, micrognathia was detected in only 21 (25%) and nine (21%) of the cases, respectively⁴⁴. These findings suggest that at present only severe micrognathia is amenable to prenatal diagnosis.

NUCHAL FLUID

Nuchal cystic hygromata

Reports on antenatally diagnosed cystic hygromata have established an association with hydrops fetalis, found in 40–100% of the cases, congenital heart defects, in 0–92% of the cases, and chromosomal defects in 46–90% of the fetuses (Table 5)^{46–67}. Recently, Azar and colleagues⁶⁷ suggested that the wide range in the reported incidence

Table 5 Summary of reported series on antenatally diagnosed cystic hygromata providing data on the presence of associated chromosomal defects

Author	Gestation (weeks)	n	Total (%)	Turner's (%)	Abnormal karyotype		Other
					Trisomy 21 (%)	Trisomy 18 (%)	
Chervenak <i>et al.</i> ⁴⁶	18–29	15	11 (73)	11 (100)	—	—	—
Newman <i>et al.</i> ⁴⁷	16–26	3	2 (67)	1 (50)	1 (50)	—	—
Redford <i>et al.</i> ⁴⁸	17–26	5	4 (80)	2 (50)	1 (25)	1 (25)	—
Marchese <i>et al.</i> ⁴⁹	16–20	6	5 (83)	4 (80)	—	1 (20)	—
Nicolaides <i>et al.</i> ⁵⁰	16–22	8	6 (75)	5 (83)	1 (17)	—	—
Pearce <i>et al.</i> ⁵¹	16–26	22	17 (77)	14 (82)	2 (12)	1 (6)	—
Carr <i>et al.</i> ⁵²	17–28	5	3 (60)	2 (67)	1 (33)	—	—
Garden <i>et al.</i> ⁵³	14–26	16	13 (81)	11 (85)	—	1 (8)	47,XXY
Palmer <i>et al.</i> ⁵⁴	16–26	8	6 (63)	4 (67)	1 (17)	—	46,XX + 5p
Gembruch <i>et al.</i> ⁵⁵	13–26	29	17 (48)	10 (59)	6 (35)	1 (6)	—
Hegge <i>et al.</i> ⁵⁶	15–17	4	3 (75)	2 (50)	1 (25)	—	—
Pijpers <i>et al.</i> ⁵⁷	12–25	15	9 (60)	8 (89)	—	1 (11)	—
Abramowicz <i>et al.</i> ⁵⁸	12–31	17	10 (59)	6 (60)	3 (30)	1 (10)	—
Cohen <i>et al.</i> ⁵⁹	10–30	15	10 (67)	5 (50)	4 (40)	1 (10)	—
Edyoux <i>et al.</i> ⁶⁰	12–32	41	19 (46)	14 (74)	4 (21)	1 (5)	—
Miyabara <i>et al.</i> ⁶¹	12–23	10	9 (90)	4 (44)	—	3 (33)	47,XX + 13,46,XX,del4p
Holzgreve <i>et al.</i> ⁶²	—	15	10 (67)	7 (70)	2 (20)	1 (10)	—
Langer <i>et al.</i> ⁶³	12–29	17	8 (47)	7 (88)	1 (12)	—	—
Rizzo <i>et al.</i> ⁶⁴	15–27	13	10 (77)	8 (80)	1 (10)	1 (10)	—
Tannirandon <i>et al.</i> ⁶⁵	16–23	11	7 (64)	5 (71)	—	1 (14)	47,XX + 13
MacLeod <i>et al.</i> ⁶⁶	16–21	15	10 (67)	3 (30)	3 (30)	2 (20)	47,XX + 13, 46,XX + 5q
Azar <i>et al.</i> ⁶⁷	16–26	44	33 (75)	31 (94)	1 (3)	1 (3)	—
Total	12–32	334	222 (66)	164 (74)	33 (15)	18 (8)	7 (3)

Table 6 Summary of reported series on first-trimester fetal nuchal edema or cystic hygromata providing data on the presence of associated chromosomal defects

Author	Gestation (weeks)	n	Abnormal karyotype					
			Total (%)	Turner's	Trisomy 13	Trisomy 18	Trisomy 21	Others
Gustavii <i>et al.</i> ⁷³	12	1	—	—	—	—	—	—
Dallapiccola <i>et al.</i> ⁷⁴	12	1	—	—	—	—	—	—
Reuss <i>et al.</i> ⁷⁵	12	1	1 (100)	1	—	—	—	—
Reuss <i>et al.</i> ⁷⁶	10	1	—	—	—	—	—	—
Pons <i>et al.</i> ⁷⁷	11–14	4	4 (100)	1	—	3	—	—
Bronshtein <i>et al.</i> ⁷⁸	11–12	2	1 (50)	—	—	—	1	—
Cullen <i>et al.</i> ⁷⁹	11–13	29	15 (52)	4	—	2	6	3*
Szabo and Gellen ⁸⁰	11–12	8	7 (88)	—	—	—	7	—
Hill <i>et al.</i> ⁸¹	13–14	2	2 (100)	—	—	2	—	—
MacLeod <i>et al.</i> ⁶⁶	10–14	5	4 (90)	2	1	1	—	—
Nicolaides <i>et al.</i> ⁸²	10–13	51	18 (35)	—	2	4	10	2†
Shulman <i>et al.</i> ⁸³	10–13	32	15 (47)	4	3	4	4	—
van Zalen-Sprock <i>et al.</i> ⁸⁴	10–14	18	5 (28)	—	—	1	3	1‡
Schulte-Vallentin and Schindler ⁸⁵	10–14	8	7 (88)	—	—	—	7	—
Ville <i>et al.</i> ⁸⁶	9–14	85	24 (28)	4	1	9	9	1**
Sepulveda and Giaffardi ⁸⁷	11	2	1 (50)	1	—	—	—	—
Total	9–14	250	104 (42)	17	7	26	47	7

*47,XY + 15/46,XX; 49,XXXXY; 47,XX-21 + der(21)t(18q;21p); †47,XY + fragment, trisomy 22; ‡45,X-15 + der(15) + t(Y;15); **47,XXX

of hydrops fetalis, cardiac defects and both the presence and types of chromosomal abnormalities may be a consequence of differences in the diagnostic criteria for cystic hygromata used in the various reports. In fetuses with bilateral, septated, cervical, dorsal hygromata the incidence of chromosomal defects is 75% and the commonest is Turner's syndrome (94%). Furthermore, there is a strong association between this chromosomal abnormality and decreased femur length to biparietal diameter ratio (90%), congenital heart defects (48%), and renal abnormalities (19%). Nuchal cystic hygromata should be distinguished from nuchal edema, which has a high association with trisomies, or unilateral cervical cysts, which are usually detected in the third trimester and have a good prognosis after postnatal surgery.

Nuchal edema

Benacerraf and colleagues^{68,69} noted the association between increased soft tissue thickening on the posterior aspect of the neck and trisomy 21. In a series of 1704 consecutive amniocenteses at 15–20 weeks' gestation in which there were 11 fetuses with trisomy 21, 45% of the trisomic and 0.06% of the normal fetuses had nuchal thickness > 5 mm. Similarly, Lynch and colleagues⁷⁰, who retrospectively examined the sonograms of nine pairs of discordant twins, found nuchal thickening > 5 mm in five of nine fetuses with trisomy 21 but in none of the normal co-twins. However, Perella and colleagues⁷¹ retrospectively examined the sonograms of 14 fetuses with trisomy 21 and 128 normal controls and found nuchal thickening in only 21% of the trisomic fetuses and in 9% of the normals.

In a series of 145 fetuses with nuchal edema ≥ 7 (that produces a characteristic tremor on ballotment of the fetal head), 52 (36%) had chromosomal abnormalities, mainly trisomy 21, but also other trisomies, deletions or

translocations, triploidy and Turner's syndrome⁷². Furthermore, the chromosomally normal fetuses had a very poor prognosis because in many cases there was an underlying skeletal dysplasia, genetic syndrome or cardiac defect.

Hydrops fetalis

Hydrops fetalis is characterized by generalized skin edema and pericardial, pleural, or ascitic effusions. This is a non-specific finding in a wide variety of fetal and maternal disorders, including hematological, chromosomal, cardiovascular, renal, pulmonary, gastrointestinal, hepatic and metabolic abnormalities, congenital infection, neoplasms and malformations of the placenta and umbilical cord. In a series of 210 fetuses with non-rhesus hydrops (excluding those with cystic hygromata, mentioned above), 25 (12%) had chromosomal abnormalities, mainly trisomy 21 (Table 2)¹⁶.

First-trimester nuchal translucency

Recent publications have suggested the possible association between abnormal nuchal fluid and chromosomal abnormalities in the first trimester of pregnancy (Table 6)^{66,73–87}. Although in some studies the condition was defined as multiseptated, thin-walled cystic mass similar to that seen in the second trimester, in others the term was used loosely to include nuchal thickening or edema.

In a prospective study of 827 women with singleton pregnancies undergoing first-trimester fetal karyotyping because of advanced maternal age, parental anxiety or a family history of a chromosomal abnormality in the absence of balanced parental translocation, transabdominal ultrasound examination was performed to obtain a sagittal section of the fetus for measurement of the

maximum thickness of the subcutaneous translucency between the skin and the soft tissue overlying the cervical spine⁸². The incidence of chromosomal defects was 3% (28 of 827 cases). In the 51 (6%) fetuses with nuchal translucency 3–8 mm in thickness, the incidence of chromosomal defects was 35% (18 cases). In contrast, only ten of the remaining 776 (1%) fetuses were chromosomally abnormal.

This screening study established that:

- (1) The presence of fetal nuchal translucency ≥ 3 mm is associated with a more than ten-fold increase and absence of translucency with a three-fold decrease in risk for chromosomal abnormality;
- (2) The risk of chromosomal abnormalities increases with increasing thickness of the nuchal translucency;
- (3) The pattern of associated chromosomal defects, trisomies rather than Turner's syndrome, is similar to that observed in second-trimester fetuses with nuchal edema rather than with cystic hygromata; and
- (4) The sensitivity of the test for trisomy 21 is more than 75% and the incidence of nuchal translucency ≥ 3 mm in chromosomally normal fetuses is approximately 4%.

INTRATHORACIC ABNORMALITIES

Diaphragmatic hernia

Benacerraf and Adzick⁸⁸ and Thorpe-Beeston and colleagues⁸⁹ reported chromosomal abnormalities in 21% and 31% of 19 and 36 fetuses with diaphragmatic hernia, respectively. In our extended series of 79 fetuses with diaphragmatic hernia, 16 (20%) had chromosomal defects, mainly trisomy 18 (Table 2), and in all cases in addition to the hernia there were other malformations such as choroid plexus cysts, facial cleft, congenital heart defects, and digital abnormalities¹⁶. None of the 37 fetuses with isolated diaphragmatic hernia had chromosomal defects.

Cardiac defects

Nora and Nora⁹⁰ reported that heart defects are found in more than 99% of fetuses with trisomy 18, in 90% of those with trisomy 13, 50% of trisomy 21, 40–50% of those with deletions or partial trisomies involving chromosomes 4, 5, 8, 9, 13, 14, 18 or 22 and in 35% of 45,X.

In two prenatal studies, of ultrasonographically detectable fetal cardiac defects, Crawford and colleagues⁹¹ and Copel and colleagues⁹² reported chromosomal defects in 22% of 74 cases and in 32% of 34 cases respectively. In our series of 156 fetuses with cardiac defects, 101 (65%) had chromosomal abnormalities (Table 2). However, in 152 of the 156 cases there were additional fetal malformations¹⁶.

GASTROINTESTINAL TRACT DEFECTS

Esophageal atresia

Associated chromosomal abnormalities were reported in 3–4% of livebirths with esophageal atresia^{93,94}. Prenatally the diagnosis of esophageal atresia is suspected when, in the presence of polyhydramnios, repeated ultrasonographic examinations fail to demonstrate the fetal stomach; other possible diagnoses include lack of fetal swallowing, due to arthrogryposis, and intrathoracic compression, due to cystic adenomatoid malformation or pleural effusion. In the presence of a tracheo-esophageal fistula the stomach bubble may be normal.

In a series of 20 fetuses with the presumptive diagnosis of esophageal atresia, 17 (85%) had trisomy 18 (Table 2)⁹⁵. Only one of the 20 fetuses survived and the infant had a normal gastrointestinal tract. Permission for post-mortem examination was obtained from 14 of the remaining 19 parents; in 12 the diagnosis of esophageal atresia was confirmed; in one case the gastrointestinal tract was apparently normal and in another the stomach was small but there was no esophageal atresia.

Duodenal atresia

Postnatally, trisomy 21 is found in 20–30% of cases of duodenal atresia^{96,97}. In a prenatal series of 23 fetuses with duodenal atresia, ten (43%) had trisomy 21, and in all but one of the fetuses there were additional malformations (Table 2)⁹⁵.

Bowel obstruction

In a postnatal series of 589 infants with a total jejunoileal atresia, cardiovascular or chromosomal anomalies were found in 7% of cases⁹⁸. In a prenatal study of 24 fetuses with suspected bowel obstruction (Table 2), there were 14 cases of small bowel obstruction, six cases of large bowel obstruction, and four cases where the dilated bowel was subsequently found to be due to megacystis-microcolon-intestinal hypoperistalsis syndrome or myotonia dystrophica⁹⁵. The karyotype was normal in all but one case, in which the fetus had multiple abnormalities.

Echogenic bowel

Nyberg and colleagues⁹⁹ described an association between chromosomal abnormalities and echogenic bowel, which was present in 7% of second-trimester fetuses with Down's syndrome. Scioscia and colleagues¹⁰⁰ karyotyped 19 fetuses with echogenic bowel at 15–26 weeks and found trisomy 21 in five and trisomy 18 in one (32%). However, in four of the chromosomally abnormal fetuses, there were additional malformations and in five of the cases there was advanced maternal age or low maternal serum α -fetoprotein. Dicke and Crane¹⁰¹ found a chromosomal abnormality (trisomy 18) in only one of their 30 cases (3.3%) and in this case there were additional malformations.

Abdominal cysts

These include ovarian, mesenteric, adrenal and hepatic cysts. In a series of 24 fetuses with abdominal cysts⁹⁵, there were four cases with a mesenteric cyst, five cases with an ovarian cyst, one with a hepatic cyst, and four with adrenal cysts. In two of the latter cases, the fetuses had the Beckwith-Wiedemann syndrome, and, in addition to the multiple adrenal cysts, they had hepatosplenomegaly and enlarged hyperechogenic pancreas. In six cases the nature of the cysts was uncertain because they resolved antenatally and there were no pathological findings at postnatal examination. In three cases with a large central abdominal cyst, postnatal surgery demonstrated a hydronephrotic sac that was excised. In another case a large tubular prehepatic cyst was found to be a dilated umbilical vein, and postnatally this was found to be associated with aortic valve stenosis. In one of the fetuses with Beckwith-Wiedemann syndrome, the karyotype was 46,XX/46,XX, dup(11p); all other fetuses had a normal karyotype.

Liver nodules

In two fetuses, referred to our unit at 21–22 weeks' gestation, there were multiple hyperechogenic nodules (2–3 mm in diameter) in the liver⁹⁵. In one case, there was nuchal edema and digital abnormalities and the karyotype was trisomy 21. The pregnancy was terminated, and at postmortem examination the hepatic nodules could not be identified. In the second fetus there were no other abnormalities and the karyotype was normal; the infant was born at term and postnatal X-ray examination demonstrated areas of calcification at the origin of the right hepatic vein.

ANTERIOR ABDOMINAL WALL DEFECTS

Exomphalos

Several reports of fetal exomphalos have established an association with chromosomal defects, mainly trisomy 18 (Table 7)^{21,60,62,64,95,102–112}. Furthermore, the incidence of chromosomal abnormalities is much higher when there are multisystem malformations and the exomphalos is small and contains only omentum or bowel rather than liver.

Gastroschisis

In gastroschisis, associated chromosomal abnormalities are rare, and, although other malformations are found in 10–30% of the cases, these are mainly gut atresias, probably due to gut strangulation and infarction *in utero*. In a prenatal series of 26 fetuses with gastroschisis, there were no chromosomal abnormalities (Table 2)⁹⁵.

URINARY TRACT DEFECTS

Postnatal and postmortem studies have established that urinary tract defects are commonly found in many chromosomal abnormalities¹. The reported incidence of chromosomal abnormalities on antenatally diagnosed renal defects varies from 2 to 33% (Table 8)^{21,60,62,64,109,113–122}. In the largest series¹²¹, renal defects were classified as

- (1) Mild hydronephrosis, where only the renal pelvis was dilated and both the bladder and amniotic fluid volume were normal;
- (2) Moderate to severe hydronephrosis, with varying degrees of pelvic-calyceal dilatation;

Table 7 Summary of reports on antenatally diagnosed exomphalos providing data on the relation between abnormal karyotype and the presence of defects other than exomphalos, contents of the exomphalos and the sex of the fetuses

Author	Incidence of chromosomal abnormalities						Chromosomal defects				
	Total	Other defects		Exomphalos content		Fetal sex		Trisomy			
		Absent	Present	Bowel	Liver ± bowel	Male	Female	13	18	21	Other*
Nakayama <i>et al.</i> ¹⁰²	1/10	1/4	—/6	—/1	1/9	—/4	1/6	—	1	—	—
Nielson <i>et al.</i> ¹⁰³	2/8	—/3	2/5	—	—	—/3	2/5	2	—	—	—
Nicolaides <i>et al.</i> ²¹	8/12	1/3	7/9	—	—	7/9	1/3	—	7	—	1
Gilbert <i>et al.</i> ¹⁰⁴	19/35	1/10	18/25	—	—	17/26	2/9	—	17	—	2
Sermer <i>et al.</i> ¹⁰⁵	4/10	—/2	4/8	—	—	—	—	1	2	—	1
Eydoux <i>et al.</i> ⁶⁰	12/46	7/27	5/19	—	—	—	—	2	6	—	4
Hughes <i>et al.</i> ¹⁰⁶	13/30	3/8	10/22	10/10	3/20	—	—	5	4	2	2
Nyberg <i>et al.</i> ¹⁰⁷	10/26	4/17	6/9	8/8	2/18	6/11	4/15	4	4	1	1
Benacerraf <i>et al.</i> ¹⁰⁸	4/22	—/7	4/15	4/6	—/16	—	—	2	1	—	1
Holzgreve <i>et al.</i> ⁶²	5/10	—	—	—	—	—	—	1	3	—	1
Rizzo <i>et al.</i> ⁶⁴	7/12	2/6	5/6	—	—	—	—	2	5	—	—
Shah <i>et al.</i> ¹⁰⁹	2/4	—	—	—	—	—	—	—	1	—	1
Van de Geyn <i>et al.</i> ¹¹⁰	10/22	—/4	10/18	—	—	—	—	1	6	—	3
Getachew <i>et al.</i> ¹¹¹	5/22	—/3	5/19	4/6	1/16	—	—	1	3	—	1
Rezai <i>et al.</i> ¹¹²	7/24	—	—	—	—	—	—	1	5	—	1
Nicolaides <i>et al.</i> ⁹⁵	42/116	1/29	41/87	24/44	17/72	36/73	6/43	6	32	—	4

*47,XXY; 45,XO; 46,XY,5p-; 46,XY,7q-; 46,XY,14q-; 46,XY,8p+; 46,XY,5p+; 46,XX,il8p; 46,XX,t(9,11); 46,XY/49,XY,+2,+7,+19; 46,XY,-14,+tdic(13q14q); 69,YYY; 69,XXY (n = 2); 46,XX,17p-; 46,XY,+13; 46,XY,-18+i(18q); 46,XY-13+der(13)t(13q18p); 46,XX/46,XX dup(11p15); 46i, XY₁ inv (11); 49,+2,+7,+19

Table 8 Summary of reports on antenatally diagnosed renal anomalies with data on presence of other defects and fetal karyotype

Author	Renal defects	Number with chromosome abnormality/total with defect			Chromosomal abnormalities			
		Total	Isolated	Multiple	Trisomy			
					13	18	21	Other
Curry <i>et al.</i> ^{113*}	mixture	3/41	—/30	3/11	—	—	1	2
Nicolaidis <i>et al.</i> ²¹	mixture	11/45	—	—	2	6	—	3
Rizzo <i>et al.</i> ¹¹⁴	multicystic	2/6	—/3	2/3	1	—	—	1
Boue <i>et al.</i> ¹¹⁵	mixture	24/221	10/165	14/56	3	6	5	10
Hegge <i>et al.</i> ¹¹⁶	mixture	1/3	—	—	—	—	—	1
Reuss <i>et al.</i> ¹¹⁷	obstruction	5/43	2/27	3/16	2	2	1	—
Edyoux <i>et al.</i> ⁶⁰	mixture	12/111	1/55	11/56	3	4	2	3
Benacerraf <i>et al.</i> ¹¹⁸	pyelectasis	7/210	—	—	—	—	7	—
Holzgreve <i>et al.</i> ⁶²	mixture	4/16	—	—	2	1	—	1
Rizzo <i>et al.</i> ⁶⁴	mixture	1/44	1/44	—	—	—	—	1
Shah <i>et al.</i> ¹⁰⁹	mixture	3/9	—	—	1	—	1	1
Stoll <i>et al.</i> ^{119†}	mixture	21/79	—	—	4	6	4	7
Brumfield <i>et al.</i> ¹²⁰	obstruction	7/30	5/25	2/5	2	2	—	3
Nicolaidis <i>et al.</i> ¹²¹	mixture	85/682	16/476	69/206	18	20	19	28
Corteville <i>et al.</i> ¹²²	pyelectasis	7/127	0/116	7/11	—	—	4	3 [‡]

*Postmortem study including eight cases that were diagnosed antenatally; †54.4% diagnosed antenatally, the others stillborn or liveborn up to age 5 years; ‡for the three chromosomal abnormalities other than trisomy 21 the details were not given

- (3) Multicystic dysplasia, with multiple non-communicating cysts of variable size and irregular hyperechoic stroma; and
- (4) Renal agenesis.

The renal defects were either unilateral or bilateral. In the fetuses with bilateral moderate/severe hydronephrosis and multicystic kidneys, the obstruction was considered to be either low (dilated bladder), or high (bladder normal or empty) and there was either oligohydramnios or the amniotic fluid volume was normal/reduced (Table 9).

The overall incidence of chromosomal abnormalities was 12%, and the commonest defects were trisomy 13, trisomy 18 and trisomy 21. There were more than twice as many males than females but the incidence of chromosomal defects in females was almost double (18%) that in males (10%)¹²¹. Furthermore, compared to the overall maternal age-related risk, the risk for fetal chromosomal abnormalities was three times higher when there was an isolated renal defect and 30 times higher when there were additional malformations. The risk of chromosomal abnormalities was similar for fetuses with unilateral or bilateral involvement, different types of renal defects, urethral or ureteric obstruction, and oligohydramnios or normal/reduced amniotic fluid volume. Nevertheless, the patterns of chromosomal abnormalities, and consequently that of associated malformations, were related to the different types of renal defects. Thus, in mild hydronephrosis, the commonest chromosomal abnormality was trisomy 21, whereas in moderate/severe hydronephrosis, multicystic kidneys, or renal agenesis the commonest abnormalities were trisomies 18 and 13, each with their own syndromal defects. Consequently, the patterns of associated malformations were different.

SKELETAL ABNORMALITIES

Malformations of the extremities

Characteristic abnormalities in the extremities are commonly found in a wide range of chromosomal defects and the detection of abnormal hands or feet at the routine ultrasound examination should stimulate the search for other markers of chromosomal defects. Syndactyly is associated with triploidy, clinodactyly with trisomy 21, polydactyly with trisomy 13, overlapping fingers, rocker bottom feet and talipes with trisomy 18^{1,16}.

In three series of antenatally diagnosed talipes equinovarus, chromosomal abnormalities, mainly trisomy 18, were reported in 25%, 31% and 36% of 8, 13 and 106 fetuses, respectively^{16,123,124}. All the chromosomally abnormal fetuses had multiple abnormalities.

Relative shortening of the femur

Benacerraf and colleagues⁶⁹ reported that if the ratio of the actual femur length to the expected length, based on the biparietal diameter, was ≤ 0.91 , the sensitivity and specificity for detecting fetuses with trisomy 21 at 15–21 weeks' gestation were 68% and 98%, respectively. In contrast, Perella and colleagues⁷¹ found that, although relative shortening of the femur had a positive predictive value of 3% for identifying trisomy 21 in women with advanced maternal age, the predictive value decreased to 1% for the general population. Lynch and colleagues⁷⁰, in their study of nine twin pregnancies with discordant fetuses for trisomy 21, suggested that short femur was of no value in identifying the trisomic twin. Similarly, Shah and colleagues⁴¹ found no significant difference in the mean biparietal diameter to femur length ratio in a group of 17 fetuses with Down's syndrome compared to that of normal controls.

In our series of 2086 fetuses that were karyotyped for a variety of malformations or growth retardation, relative shortening of the femur was defined as head cir-

Table 9 Abnormal fetal karyotype in 682 fetuses with bilateral or unilateral renal abnormalities, which were either isolated or associated with additional malformations

Type of renal defect	n	Total (%)	Triploidy	Chromosomal abnormality							
				Autosomal chromosomes						Sex chromosomes	
				Trisomy				Deletions	45,XO	Other	
21	18	13	Other								
<i>Bilateral</i>											
total	510	66 (13)	2	19	15	13	6	6	4	1	
- other defects	342	14 (4)	2	3	—	1	4	3	—	1	
+ other defects	168	52 (31)	—	16	15	12	2	3	4	—	
<i>Mild hydronephrosis</i>											
total	258	35 (14)	—	15	6	8	3	2	1	—	
- other defects	163	5 (3)	—	1	—	—	3	1	—	—	
+ other defects	95	30 (32)	—	14	6	8	—	1	1	—	
<i>Moderate/severe hydronephrosis</i>											
total	119	15 (13)	1	3	3	2	2	1	3	—	
- other defects	81	5 (6)	1	2	—	—	1	1	—	—	
+ other defects	38	10 (26)	—	1	3	2	1	—	3	—	
<i>Multicystic kidneys</i>											
total	109	13 (12)	1	1	6	2	—	3	—	—	
- other defects	79	3 (4)	1	—	—	1	—	1	—	—	
+ other defects	30	10 (33)	—	1	6	1	—	2	—	—	
<i>Renal agenesis</i>											
total	24	3 (13)	—	—	—	1	1	—	—	1	
- other defects	19	1 (5)	—	—	—	—	—	—	—	1	
+ other defects	5	2 (40)	—	—	—	1	1	—	—	—	
<i>Unilateral</i>											
total	172	19 (11)	3	—	5	5	—	3	2	1	
- other defects	134	2 (2)	—	—	—	—	—	1	—	1	
+ other defects	38	17 (45)	3	—	5	5	—	2	2	—	
<i>Mild hydronephrosis</i>											
total	18	2 (11)	—	—	1	—	—	—	1	—	
- other defects	10	0 (0)	—	—	—	—	—	—	—	—	
+ other defects	8	2 (25)	—	—	1	—	—	—	1	—	
<i>Moderate/severe hydronephrosis</i>											
total	87	8 (9)	1	—	1	3	—	3	—	—	
- other defects	76	1 (1)	—	—	—	—	—	1	—	—	
+ other defects	11	7 (64)	1	—	1	3	—	2	—	—	
<i>Multicystic kidneys</i>											
total	64	8 (13)	2	—	2	2	—	—	1	1	
- other defects	48	1 (2)	—	—	—	—	—	—	—	1	
+ other defects	16	7 (44)	2	—	2	2	—	—	1	—	
<i>Renal agenesis</i>											
total	3	1 (33)	—	—	1	—	—	—	—	—	
- other defects	0	0 (0)	—	—	—	—	—	—	—	—	
+ other defects	3	1 (33)	—	—	1	—	—	—	—	—	

cumference to femur length ratio > 97.5th centile¹⁶. Chromosomal defects, mainly trisomies 18 and 21, triploidy and Turner's syndrome, were found in 116 of the 411 (28%) fetuses with short femur (Table 2).

Short humerus

In a postmortem study of Down's syndrome fetuses, FitzSimmons and colleagues¹²⁵ reported that shortening of the long bones of the upper extremity was more pronounced than that of the lower extremity. Two studies, which evaluated the utility of ultrasonographic

measurements of the humerus at 15–22 weeks for detection of trisomy 21, reached different conclusions. Rodis and colleagues¹²⁶ reported that, in five of 11 fetuses with trisomy 21, the humerus length versus biparietal diameter was < 5th centile. In contrast, Rotmensch and colleagues¹²⁷ found shortening of the humerus in only one of 43 fetuses with trisomy 21. Humerus length versus gestational age < 5th percentile yielded a 64% sensitivity and a positive predictive value of 6.8% in the first study, whereas a ratio of 0.90 for observed/expected humeral length yielded a sensitivity of 28% and a positive predictive value of 1.23% in the second study.

INTRAUTERINE GROWTH RETARDATION

Although low birth weight is a common feature of many chromosomal abnormalities, the incidence of chromosomal defects in small-for-gestational-age neonates is less than 1–2%^{128–132}. However, data derived from postnatal studies may underestimate the association between chromosomal abnormalities and growth retardation, since many pregnancies with chromosomally abnormal fetuses result in spontaneous abortion or intrauterine death. Furthermore, since the degree of growth retardation is generally more severe in the more lethal types of chromosomal abnormalities, it is expected that, in antenatally diagnosed, early onset, severe growth retardation, the types of chromosomal abnormalities will be different from those recognized at birth.

Snijders and colleagues¹³³ examined 458 patients with severely growth-retarded singleton pregnancies at 17–40 weeks' gestation, and reported that the incidence of chromosomal defects was 19%. The commonest chromosomal abnormalities were triploidy, trisomies 13, 18 and 21, and deletion of the short arm of chromosome 4. The triploidies were most commonly encountered in the second trimester, while the aneuploidies, deletions and translocations were found in the third-trimester group of fetuses. These findings suggest that triploidy is associated with the most severe form of early onset growth retardation and that the majority of affected fetuses die before the third trimester of pregnancy.

The incidence of chromosomal defects was higher in:

- (1) The group with malformations (40%), than in those with no structural defects (3%);
- (2) The group with normal or increased amniotic fluid volume (40%) than in those with reduced or absent amniotic fluid (7%);
- (3) The group with normal waveforms from both uterine and umbilical arteries (44%), than in those with abnormal waveforms from either or both vessels (40/347).

A substantial proportion of the chromosomally abnormal fetuses demonstrated the asymmetry (high head to abdominal circumference ratio), thought to be typical for fetal starvation; indeed the most severe form of asymmetrical growth retardation is found in fetuses with triploidy.

OVERVIEW

- (1) The incidence of chromosomal abnormalities for ultrasonographically detectable fetal malformations and/or growth retardation is much higher than the incidence reported in screening studies based on advanced maternal age or maternal serum biochemistry. Although there are no prospective studies on the sensitivity of second-trimester ultrasound screening for chromosomal defects in unselected populations, available data indicate that ultrasonography may prove to be the most effective method of screening for fetal chromosomal defects. The most promising marker is nuchal translucency at 10–13 weeks.
- (2) The ultrasound diagnosis of a marker for a specific chromosomal defect should stimulate the search for other associated malformations and, when these additional abnormalities are found, the probability that the fetus is chromosomally abnormal is dramatically increased (Table 10).
- (3) For a given malformation, the risk of a chromosomal defect may be inversely related to the apparent severity of the malformation. For example, the incidence of chromosomal defects is higher for mild than severe ventriculomegaly or exomphalos.
- (4) A sonographically detectable fetal defect is not just a potentially useful marker for a chromosomal abnormality, but it may also lead to the diagnosis of another significant defect, such as nuchal edema unmasking a cardiac abnormality, or talipes leading to the diagnosis of a lethal arthrogryposis syndrome.
- (5) Although there is a rapidly increasing list of subtle deviations from normality in anatomy and measurements in trisomy 21 fetuses, the incidence of these markers is quite high (1–5%) and the positive predictive value is around 1%. The implications in terms of anxiety for the parents and fetal death as well as economic cost from invasive testing remain to be discussed.
- (6) More than 90% of fetuses with trisomy 13 or 18, triploidy, and Turner's syndrome have associated malformations that should be easily detectable by diligent ultrasonographic examination. Trisomy 18

Table 10 Frequency of chromosomal abnormalities and number of ultrasound-detected defects

Number of defects	Number of chromosomal abnormalities/total with defects (%)	Autosomes						
		Trisomy				Sex chromosomes		
		21	18	13	Other	Turner's	Other	Triploidy
Any	301/2086 (14)	69	83	31	33	38	5	42
≥ 2	276/958 (29)	60	83	31	21	36	2	42
≥ 3	223/468 (48)	37	79	28	12	33	—	34
≥ 4	153/248 (62)	19	64	24	10	18	—	18
≥ 5	93/133 (70)	5	50	16	5	8	—	9
≥ 6	58/80 (72)	—	36	12	4	2	—	4
≥ 7	33/40 (82)	—	26	5	1	—	—	1
≥ 8	22/24 (92)	—	17	4	1	—	—	—

is associated with strawberry-shaped head, choroid plexus cysts, facial cleft, micrognathia, heart defects, exomphalos, malformations of hands and feet, and growth retardation. In trisomy 13, defects include holoprosencephaly, facial cleft, cardiac defects, hydronephrosis, polydactyly, overlapping fingers and talipes. Turner's syndrome is associated with nuchal cystic hygromata, generalized edema, brachycephaly and cardiac defects. Triploidy is characterized by early onset, severe asymmetrical growth retardation, ventriculomegaly and syndactyly; a molar placenta is found in the minority of cases. In trisomy 21, the associated defects are often more subtle and include nuchal edema, macroglossia, atrioventricular septal defects, mild hydronephrosis, sandal gap and clinodactyly. Therefore the false-positive rate for each individual feature may be unacceptably high. Nevertheless, it should be emphasized that a single ultrasound marker, such as nuchal edema, as a risk factor for fetal karyotyping can identify 40% of fetuses with trisomy 21, which compares favorably with the potential 25% detection rate, if the risk factor is advanced maternal age, or even the 50% rate, if a combination of maternal age and triple biochemistry are used.

- (7) Fetal karyotyping should be considered even in the third trimester because knowledge of a serious chromosomal abnormality may alter the management of labor and delivery. Karyotyping should also be performed for conditions, such as hydrops fetalis or severe early onset growth retardation, where the risk of intrauterine death is high; autolysis may render postmortem chromosomal studies, and therefore accurate genetic counselling for future pregnancies, impossible.

REFERENCES

- Jones, K. L. (1988). *Smith's Recognizable Patterns of Human Malformation*, 4th edn. (London: W. B. Saunders)
- RCOG Study Group (1990). In Drife, J. O. and Donnai, D. (eds.) *The Antenatal Diagnosis of Fetal Abnormalities*. (London: Springer Verlag)
- Chervenak, F. A., Berkowitz, R. L., Tortora, M. and Hobbins, J. C. (1985). The management of fetal hydrocephalus. *Am. J. Obstet. Gynecol.*, **151**, 933-42
- Cochrane, D. D., Myles, S. T., Nimrod, C., Still, D. K., Sugarman, R. G. and Wittmann, B. K. (1984). Intrauterine hydrocephalus and ventriculomegaly: associated abnormalities and fetal outcome. *Can. J. Neurol. Sci.*, **12**, 51-9
- Pretorius, D. H., Davis, K., Manco-Johnson, M. L., Manchester, D., Meier, P. R. and Clewell, W. H. (1985). Clinical course of fetal hydrocephalus: 40 cases. *Am. J. Radiol.*, **144**, 827-31
- Pilu, G., Rizzo, N., Orsini, L. F. and Bovicelli, L. (1986). Antenatal recognition of cerebral anomalies. *Ultrasound Med. Biol.*, **12**, 319-26
- Serlo, W., Kirkinen, P., Jouppila, P. and Herva, R. (1986). Prognostic signs of fetal hydrocephalus. *Child. Nerv. Syst.*, **2**, 93-7
- Nyberg, D. A., Mack, L. A., Hirsch, J., Pagon, R. and Shepard, T. H. (1987). Fetal hydrocephalus: sonographic detection and clinical significance of associated anomalies. *Radiology*, **163**, 187-91
- Vintzileos, A. M., Campbell, W. A., Weinbaum, P. J. and Nochimson, D. J. (1987). Perinatal management and outcome of fetal ventriculomegaly. *Obstet. Gynecol.*, **69**, 5-11
- Hudgins, R. J., Edwards, M. S. B., Goldstein, R., Callen, P. W., Harrison, M. R., Filly, R. A. and Golbus, M. S. (1988). Natural history of fetal ventriculomegaly. *Pediatrics*, **82**, 692-7
- Drugan, A., Krause, B., Canady, A., Zador, I. E., Sacks, A. J. and Evans, M. I. (1989). The natural history of prenatally diagnosed cerebral ventriculomegaly. *J. Am. Med. Assoc.*, **261**, 1785-8
- Nicolaides, K. H., Berry, S., Sniijders, R. J. M., Thorpe-Beeston, J. G. and Gosden, C. M. (1990). Fetal lateral cerebral ventriculomegaly: associated malformations and chromosomal defects. *Fetal Diagn. Ther.*, **5**, 5-14
- Bromley, B., Frigoletto, F. D. and Benacerraf, B. R. (1991). Mild fetal lateral cerebral ventriculomegaly: clinical course and outcome. *Am. J. Obstet. Gynecol.*, **164**, 863-7
- Anhoury, P., Andre, M., Droulle, P., Czorny, A., Gilgenkrantz, S., Schweitzer, M. and Leheup, B. (1991). Dilatation des ventricules cerebraux decouverte in utero. *J. Gynecol. Obstet. Biol. Reprod.*, **20**, 191-7
- Brumfield, C. G., Davis, R. O., Hauth, J. C., Cosper, P., Colvin, E. V. and Finley, S. C. (1991). Management of prenatally detected non-lethal fetal anomalies: is a karyotype of benefit? *Am. J. Perinatol.*, **8**, 255-8
- Nicolaides, K. H., Sniijders, R. J. M., Gosden, C. M., Berry, C. and Campbell, S. (1992). Ultrasonographically detectable markers of fetal chromosomal abnormalities. *Lancet*, **340**, 704-7
- Filly, R. A., Chin, D. H. and Callen, P. W. (1984). Alobar holoprosencephaly: ultrasonographic prenatal diagnosis. *Radiology*, **151**, 455-9
- Chervenak, F. A., Isaacson, G., Hobbins, J. C., Chitkara, U., Tortora, M. and Berkowitz, R. L. (1985). Diagnosis and management of fetal holoprosencephaly. *Obstet. Gynecol.*, **66**, 322-6
- Nyberg, D. A., Mack, L. A., Bronstein, A., Hirsch, J. and Pagon, R. A. (1987). Holoprosencephaly: prenatal sonographic diagnosis. *Am. J. Radiol.*, **149**, 1051-8
- Berry, S. M., Gosden, C. M., Sniijders, R. J. M. and Nicolaides, K. H. (1990). Fetal holoprosencephaly: associated malformations and chromosomal defects. *Fetal Diagn. Ther.*, **5**, 92-9
- Nicolaides, K. H., Rodeck, C. H. and Gosden, C. M. (1986). Rapid karyotyping in non-lethal fetal malformations. *Lancet*, **1**, 283-6
- Ricketts, N. E. M., Lowe, E. M. and Patel, N. B. (1987). Prenatal diagnosis of choroid plexus cysts. *Lancet*, **1**, 213-14
- Chitkara, U., Cogswell, C., Norton, K., Wilkins, I. A., Mehalek, K. and Berkowitz, R. L. (1989). Choroid plexus cysts in the fetus: a benign anatomic variant or pathologic entity? Report of 41 cases and review of the literature. *Obstet. Gynecol.*, **72**, 185-9
- Gabrielli, S., Reece, A. R., Pilu, G., Perolo, A., Rizzo, N., Bovicelli, L. and Hobbins, J. C. (1989). The significance of prenatally diagnosed choroid plexus cysts. *Am. J. Obstet. Gynecol.*, **160**, 1207-10
- Thorpe-Beeston, J. G., Gosden, C. M. and Nicolaides, K. H. (1990). Choroid plexus cysts and chromosomal defects. *Br. J. Radiol.*, **63**, 783-6
- Achiron, R., Barkai, G., Katznelson, B. M. and Mashich, S. (1991). Fetal lateral ventricle choroid plexus cysts: the dilemma of amniocentesis. *Obstet. Gynecol.*, **78**, 815-18
- Twinning, P., Zucullo, J., Clewes, J. and Swallow, J. (1991). Fetal choroid plexus cysts: a prospective study and review of the literature. *Br. J. Radiol.*, **64**, 98-102

28. Platt, L. D., Carlson, D. E., Medearis, A. L. and Walla, C. A. (1991). Fetal choroid plexus cysts in the second trimester of pregnancy: a cause for concern. *Am. J. Obstet. Gynecol.*, **164**, 1652–6
29. Perpignano, M. C., Cohen, H. L., Klein, V. R., Mandel, F. S., Streltsoff, J., Chervenak, F. A. and Goldman, M. A. (1992). Fetal choroid plexus cysts: beware the smaller cyst. *Radiology*, **182**, 715–17
30. Rotmensch, S., Luo, J. S., Nores, J. A., Schoenfield-Dimaio, M. and Hobbins, J. C. (1992). Bilateral choroid plexus cysts in trisomy 21. *Am. J. Obstet. Gynecol.*, **166**, 591–2
31. Benacerraf, B. R., Harlow, B. and Frigoletto, F. D. (1990). Are choroid plexus cysts an indication for second trimester amniocentesis. *Am. J. Obstet. Gynecol.*, **162**, 1001–6
32. Fitzsimmons, J., Wilson, D., Pascoe-Mason, J., Shaw, M. J., Cyr, C. R. and Mack, L. A. (1989). Choroid plexus cysts in fetuses with trisomy 18. *Obstet. Gynecol.*, **73**, 257–9
33. Comstock, C., Culp, D., Gonzalez, J. and Boal, D. B. (1985). Agenesis of the corpus callosum in the fetus: its evolution and significance. *J. Ultrasound Med.*, **4**, 613–16
34. Amato, M., Howald, H. and von Mural, G. (1986). Fetal ventriculomegaly, agenesis of the corpus callosum and chromosomal translocation – case report. *J. Perinat. Med.*, **14**, 271–4
35. Bertino, R. E., Nyberg, D. A., Cyr, D. R. and Mack, L. A. (1987). Prenatal diagnosis of agenesis of the corpus callosum. *J. Ultrasound Med.*, **7**, 251–60
36. Bahado-Singh, R. O., Wyse, L., Dorr, M. A., Copel, J. A., O'Connor, T. and Hobbins, J. C. (1992). Fetuses with Down syndrome have disproportionately shortened frontal lobe dimensions on ultrasonographic examination. *Am. J. Obstet. Gynecol.*, **167**, 1009–14
37. Nyberg, D. A., Mahony, B. S., Hegge, F. N., Hickok, D., Luthy, D. A. and Kapur, R. (1991). Enlarged cisterna magna and the Dandy-Walker malformation: factors associated with chromosome abnormalities. *Obstet. Gynecol.*, **77**, 436–42
38. Watson, W. J., Katz, V. L., Chescheir, N. C., Miller, R. C., Menard, K. and Hansen, W. F. (1992). The cisterna magna in second trimester fetuses with abnormal karyotypes. *Obstet. Gynecol.*, **79**, 723–5
39. Nicolaidis, K. H., Salvesen, D., Snijders, R. J. M. and Gosden, C. M. (1992). Strawberry-shaped skull in fetal trisomy 18. *Fetal Diagn. Ther.*, **7**, 132–7
40. Perry, T. B., Benzie, R. J., Cassar, N., Hamilton, E. F., Stocker, J., Toftager-Larsen, K. and Lippman, A. (1984). Fetal cephalometry by ultrasound as a screening procedure for the prenatal detection of Down syndrome. *Br. J. Obstet. Gynaecol.*, **91**, 138–43
41. Shah, Y. G., Eckl, C. J., Stinson, S. K. and Woods, J. R. (1990). Biparietal diameter/femur length ratio, cephalic index, and femur length measurements: not reliable screening techniques for Down syndrome. *Obstet. Gynecol.*, **75**, 186–8
42. Pashayan, H. M. (1983). What else to look for in a child born with a cleft of the lip or palate. *Cleft Palate J.*, **20**, 54–82
43. Saltzman, D. H., Benacerraf, B. R. and Frigoletto, F. D. (1986). Diagnosis and management of fetal facial clefts. *Am. J. Obstet. Gynecol.*, **155**, 377–9
44. Nicolaidis, K. H., Salvesen, D., Snijders, R. J. M. and Gosden, C. M. (1993). Facial defects: associated malformations and chromosomal abnormalities. *Fetal Diagn. Ther.*, **8**, 1–9
45. Benacerraf, B. R., Frigoletto, F. D. and Green, M. F. (1986). Abnormal facial features and extremities in human trisomy syndromes: prenatal US appearance. *Radiology*, **159**, 243–6
46. Chervenak, F. A., Isaacson, G., Blakemore, K. J., Breg, R. W., Hobbins, J. C., Berkowitz, R. L., Tortora, M., Mayden, K. and Mahoney, M. J. (1983). Fetal cystic hygroma: cause and natural history. *N. Engl. J. Med.*, **309**, 822–5
47. Newman, D. E. and Cooperberg, P. I. (1984). Genetics of sonographically detected intrauterine fetal cystic hygromas. *Can. Med. Assoc. J.*, **35**, 77–9
48. Redford, D. H. A., Mcnay, M. B., Fergusson-Smith, M. E. and Jamieson, M. E. (1984). Aneuploidy and cystic hygroma detectable by ultrasound. *Prenat. Diagn.*, **4**, 377–82
49. Marchese, C., Savin, E., Dragone, E., Carozzi, F., De Marchi, M., Campogrande, M., Dolfin, G. C., Pagliano, G., Viora, E. and Carbonara, A. (1985). Cystic hygroma: prenatal diagnosis and genetic counselling. *Prenat. Diagn.*, **5**, 221–7
50. Nicolaidis, K. H., Rodeck, C. H., Lange, I., Watson, J., Gosden, C. M., Miller, D., Mibashan, R. S., Moniz, C., Morgan-Capner, P. and Campbell, S. (1985). Fetoscopy in the assessment of unexplained fetal hydrops. *Br. J. Obstet. Gynaecol.*, **92**, 671–9
51. Pearce, M. J., Griffin, D. and Campbell, S. (1985). The differential prenatal diagnosis of cystic hygromata and encephalocele by ultrasound examination. *J. Clin. Ultrasound*, **13**, 317–20
52. Carr, R. F., Ochs, R. H., Ritter, D. A., Kenny, J. D., Friley, J. L. and Ming, P. L. (1986). Fetal cystic hygroma and Turner's syndrome. *Am. J. Dis. Child.*, **140**, 580–3
53. Garden, A. S., Benzie, R. J., Miskin, M. and Gardner, H. A. (1986). Fetal cystic hygroma colli: antenatal diagnosis, significance, and management. *Am. J. Obstet. Gynecol.*, **154**, 221–5
54. Palmer, C. G., Miles, J. H., Howard-Peebles, P. N., Magen, R. E., Patil, S. and Friedman, J. M. (1987). Fetal karyotype following ascertainment of fetal anomalies by ultrasound. *Prenat. Diagn.*, **7**, 551–5
55. Gembruch, U., Hansmann, M., Bald, R., Zerres, K., Schwantz, G. and Fodisch, H. J. (1988). Prenatal diagnosis and management in fetuses with cystic hygroma colli. *Eur. J. Obstet. Gynecol. Reprod. Biol.*, **29**, 241–55
56. Hegge, F. N., Prescott, G. H. and Watson, P. T. (1988). Sonography at the time of genetic amniocentesis to screen for fetal malformations. *Obstet. Gynecol.*, **71**, 522–5
57. Pijpers, L., Reuss, A., Stewart, P. A., Wladimiroff, J. W. and Sachs, E. S. (1988). Fetal cystic hygroma: prenatal diagnosis and management. *Obstet. Gynecol.*, **72**, 223–4
58. Abramowicz, J. S., Warsof, S. L., Doyle, D. L., Smith, D. and Levy, D. L. (1989). Congenital cystic hygroma of the neck diagnosed prenatally: outcome with normal and abnormal karyotype. *Prenat. Diagn.*, **9**, 231–7
59. Cohen, M. M., Schwartz, S., Schwartz, M. F., Blitzer, M. G., Raffel, L. J., Mullins-Keene, C. L., Sun, C. C. J. and Blakemore, K. J. (1990). Antenatal detection of cystic hygroma. *Obstet. Gynecol. Surv.*, **10**, 189–93
60. Eydoux, P., Choiset, A., Le Porrier, N., Thepot, F., Szpiro-tapia, S., Alliet, J., Ramond, S., Viel, J. F., Gautier, E., Morichon, N. and Girard-Orgeolet, S. (1989). Chromosomal prenatal diagnosis: study of 936 cases of intrauterine abnormalities after ultrasound assessment. *Prenat. Diagn.*, **9**, 255–68
61. Miyabara, S., Sugihara, H., Maehara, N., Shouno, H., Tasaki, H., Yoshida, K., Saito, N., Kayama, F., Ibara, S. and Suzumori, K. (1989). Significance of cardiovascular malformations in cystic hygroma: a new interpretation of the pathogenesis. *Am. J. Med. Genet.*, **34**, 489–501
62. Holzgreve, W., Miny, P., Gerlach, B., Westendrop, A., Ahlert, D. and Horst, J. (1990). Benefits of placental biopsies for rapid karyotyping in the second and third trimesters (late chorionic villus sampling) in high-risk pregnancies. *Am. J. Obstet. Gynecol.*, **162**, 1188–92

63. Langer, J. C., Fitzgerald, P. G., Desa, D., Filly, R. A., Golbus, M. S., Adzick, N. S. and Harrison, M. R. (1990). Cervical cystic hygroma in the fetus: clinical spectrum and outcome. *J. Pediatr. Surg.*, **25**, 58–62
64. Rizzo, N., Pitalis, M. C., Pilu, G., Orsini, L. F., Perolo, A. and Bovicelli, L. (1990). Prenatal karyotyping in malformed fetuses. *Prenat. Diagn.*, **10**, 17–23
65. Tannirandorn, Y., Nicolini, U., Nicolaidis, P., Fisk, N. M., Arulkumaran, S. and Rodeck, C. H. (1990). Fetal cystic hygromata: insights gained from fetal blood sampling. *Prenat. Diagn.*, **10**, 189–93
66. Macleod, A. M. and McHugo, J. M. (1991). Prenatal diagnosis of nuchal cystic hygromata. *Br. J. Radiol.*, **64**, 802–7
67. Azar, G., Snijders, R. J. M., Gosden, C. M. and Nicolaidis, K. H. (1991). Fetal nuchal cystic hygromata: associated malformations and chromosomal defects. *Fetal Diagn. Ther.*, **6**, 46–57
68. Benacerraf, B. R., Barss, V. A. and Laboda, L. A. (1985). A sonographic sign for the detection in the second trimester of the fetus with Down's syndrome. *Am. J. Obstet. Gynecol.*, **151**, 1078–9
69. Benacerraf, B. R., Gelman, R. and Frigoletto, F. D. (1987). Sonographic identification of second trimester fetuses with Down's syndrome. *N. Engl. J. Med.*, **317**, 1371–6
70. Lynch, L., Berkowitz, G. S., Chitkara, U., Wilkins, I. A., Mehalek, K. E. and Berkowitz, R. L. (1989). Ultrasound detection of Down's syndrome: is it really possible? *Obstet. Gynecol.*, **73**, 267–70
71. Perella, R., Duerinckx, A. J., Grant, E. G., Tessler, F., Tach, K. and Crandall, B. F. (1988). Second trimester sonographic diagnosis of Down syndrome: role of femur length shortening and nuchal-fold thickening. *Am. J. Radiol.*, **151**, 981–5
72. Nicolaidis, K. H., Azar, G., Snijders, R. J. M. and Gosden, C. M. (1992). Fetal nuchal oedema: associated malformations and chromosomal defects. *Fetal Diagn. Ther.*, **7**, 123–31
73. Gustavii, B. and Edvall, H. (1984). First-trimester diagnosis of cystic nuchal hygroma. *Acta Obstet. Gynecol. Scand.*, **63**, 377–8
74. Dallapiccola, B., Zelante, L., Perla, G. and Villani, G. (1984). Prenatal diagnosis of recurrence of cystic hygroma with normal chromosomes. *Prenat. Diagn.*, **4**, 383–6
75. Reuss, A., Pijpers, L., Schampers, P. T. F. M., Wladimiroff, J. W. and Sachs, E. S. (1987). The importance of chorionic villus sampling after first trimester diagnosis of cystic hygroma. *Prenat. Diagn.*, **7**, 299–301
76. Reuss, A., Pijpers, L., van Swaaij, E., Jahoda, M. G. J. and Wladimiroff, J. W. (1987). First-trimester diagnosis of recurrence of cystic hygroma using a transvaginal ultrasound transducer. Case report. *Eur. J. Obstet. Gynecol. Reprod. Biol.*, **26**, 271–3
77. Pons, J. C., Diallo, A. A., Eydoux, P., Rais, S., Doumerc, S., Frydman, R. and Papiernik, E. (1989). Chorionic villus sampling after first trimester diagnosis of fetal cystic hygroma colli. *Eur. J. Obstet. Gynecol. Reprod. Biol.*, **33**, 141–6
78. Bronshtein, M., Rottem, S., Yoffe, N. and Blumenfeld, Z. (1989). First trimester and early second trimester diagnosis of nuchal cystic hygroma by transvaginal sonography: diverse prognosis of the septated from the non septated lesion. *Am. J. Obstet. Gynecol.*, **161**, 78–82
79. Cullen, M. T., Gabrielli, S., Green, J. J., Rizzo, N., Mahoney, M. J., Salafia, C., Bovicelli, L. and Hobbins, J. C. (1990). Diagnosis and significance of cystic hygroma in the first trimester. *Prenat. Diagn.*, **10**, 643–51
80. Szabo, J. and Gellen, J. (1990). Nuchal fluid accumulation in trisomy-21 detected by vaginosonography in first trimester. *Lancet*, **336**, 1133
81. Hill, L. M., Macpherson, T., Rivello, D. and Peterson, C. (1991). The spontaneous resolution of cystic hygromas and early fetal growth delay in fetuses with trisomy 18. *Prenat. Diagn.*, **11**, 673–7
82. Nicolaidis, K. H., Azar, G., Byrne, D., Mansur, C. and Marks, K. (1992). Fetal nuchal translucency: ultrasound screening for chromosomal defects in first trimester of pregnancy. *Br. Med. J.*, **304**, 867–9
83. Shulman, L. P., Emerson, D., Felker, R., Phillips, O., Simpson, J. and Elias, S. (1992). High frequency of cytogenetic abnormalities with cystic hygroma diagnosed in the first trimester. *Obstet. Gynecol.*, **80**, 80–2
84. van Zalen-Sprock, R. M., van Vugt, J. M. G. and van Geijn, H. P. (1992). First-trimester diagnosis of cystic hygroma – course and outcome. *Am. J. Obstet. Gynecol.*, **167**, 94–8
85. Schulte-Vallentin, M. and Schindler, H. (1992). Non-echogenic nuchal oedema as a marker in trisomy 21 screening. *Lancet*, **339**, 1053
86. Ville, Y., Lalondrelle, C., Doumerc, S., Daffos, F., Frydman, R., Oury, J. F. and Dumez, Y. (1992). First-trimester diagnosis of nuchal anomalies: significance and fetal outcome. *Ultrasound Obstet. Gynecol.*, **2**, 314–16
87. Sepulveda, W. H. and Ciuffardi, I. (1992). Early sonographic diagnosis of fetal cystic hygromata colli. *J. Perinat. Med.*, **20**, 149–52
88. Benacerraf, B. R. and Adzick, N. S. (1987). Fetal diaphragmatic hernia: ultrasound diagnosis and clinical outcome in 19 cases. *Am. J. Obstet. Gynecol.*, **156**, 573–6
89. Thorpe-Becston, G., Gosden, C. M. and Nicolaidis, K. H. (1989). Congenital diaphragmatic hernia: associated malformations and chromosomal defects. *Fetal Ther.*, **4**, 21–8
90. Nora, J. J. and Nora, A. H. (1978). The evolution of specific genetic and environmental counselling in congenital heart disease. *Circulation*, **57**, 205
91. Crawford, D. C., Chita, S. K. and Allan, L. D. (1988). Prenatal detection of congenital heart disease: factors affecting obstetric management and survival. *Am. J. Obstet. Gynecol.*, **159**, 352–6
92. Copel, J. A., Cullen, M., Green, J. J., Mahoney, M. J., Hobbins, J. C. and Kleinman, C. S. (1988). The frequency of aneuploidy in prenatally diagnosed congenital heart disease: an indication for fetal karyotyping. *Am. J. Obstet. Gynecol.*, **158**, 409–13
93. German, J. C., Mahour, G. H. and Wooley, M. M. (1976). Esophageal atresia and associated anomalies. *J. Pediatr. Surg.*, **11**, 299–306
94. Louhimo, I. and Lindahl, H. (1983). Esophageal atresia: primary results of 500 consecutively treated patients. *J. Pediatr. Surg.*, **18**, 217–29
95. Nicolaidis, K. H., Snijders, R. J. M., Cheng, H. and Gosden, C. M. (1992). Fetal abdominal wall and gastrointestinal tract defects: associated malformations and chromosomal defects. *Fetal Diagn. Ther.*, **7**, 102–15
96. Fonkalsrud, E. W., DeLorimier, A. A. and Hays, D. M. (1969). Congenital atresia and stenosis of the duodenum. A review compiled from the members of the Surgical Section of the American Academy of Pediatrics. *Pediatrics*, **43**, 79–83
97. Touloukian, R. J. (1978). Intestinal atresia. *Clin. Perinatol.*, **5**, 3–18
98. DeLorimier, A. A., Fonkalsrud, E. W. and Hays, D. M. (1969). Congenital atresia and stenosis of the jejunum and ileum. *Surgery*, **65**, 819–27
99. Nyberg, D. A., Resta, R. G., Luthy, D. A., Hickok, D. E., Mahony, B. S. and Hirsch, J. H. (1990). Prenatal sonographic findings of Down syndrome: review of 94 cases. *Obstet. Gynecol.*, **76**, 370–7
100. Scioscia, A. L., Pretorius, D. H., Budorick, N. E., Cahill, T. C., Axelrod, F. T. and Leopold, G. R. (1992). Second-trimester echogenic bowel and chromosomal abnormalities. *Am. J. Obstet. Gynecol.*, **167**, 889–94

101. Dicke, J. M. and Crane, J. P. (1992). Sonographically detected hyperechoic fetal bowel: significance and implications for pregnancy management. *Obstet. Gynecol.*, **80**, 778–82
102. Nakayama, D. K., Harrison, M. K., Gross, B. H., Callen, P. W., Filly, R. H., Golbus, M. S., Stephens, J. U. and de-Lorimier, H. H. (1984). Management of the fetus with an abdominal wall defect. *J. Pediatr. Surg.*, **19**, 408–13
103. Nielson, L. B., Bang, J. and Norgaard-Pedersen, B. (1985). Prenatal diagnosis of omphalocele and gastroschisis by ultrasonography. *Prenat. Diagn.*, **5**, 381–92
104. Gilbert, W. M. and Nicolaides, K. H. (1987). Fetal omphalocele: associated malformations and chromosomal defects. *Obstet. Gynecol.*, **70**, 633–5
105. Sermer, M., Benzie, R. J., Pitson, L., Carr, M. and Skidmore, M. (1987). Prenatal diagnosis and management of congenital defects of the anterior abdominal wall. *Am. J. Obstet. Gynecol.*, **156**, 308–12
106. Hughes, M., Nyberg, D. H., Mack, L. H. and Pretorius, D. H. (1989). Fetal omphalocele: prenatal US detection of concurrent anomalies and other predictors of outcome. *Radiology*, **173**, 371–6
107. Nyberg, D. H., Fitzsimmons, J., Mack, L. H., Hughes, M., Pretorius, D. H., Hickok, D. and Shepard, I. H. (1989). Chromosomal abnormalities in fetuses with omphalocele. Significance of omphalocele contents. *J. Ultrasound Med.*, **8**, 299–308
108. Benacerraf, B. R., Saltzman, D. H., Estroff, J. H. and Frigoletto, F. D. Jr. (1990). Abnormal karyotype of fetuses with omphalocele: prediction based on omphalocele contents. *Obstet. Gynecol.*, **75**, 317–19
109. Shah, D. M., Roussis, P., Ulm, J., Jeanty, P. and Boehm, F. H. (1990). Cordocentesis for rapid karyotyping. *Am. J. Obstet. Gynecol.*, **162**, 1548–50
110. Van de Geijn, E. J., van Vugt, J. M. G., Sollic, J. E. and van Geijn, H. P. (1991). Ultrasonographic diagnosis and perinatal management of fetal abdominal wall defects. *Fetal Diagn. Ther.*, **6**, 2–10
111. Getachew, M. M., Goldstein, R. B., Edge, V., Goldberg, J. D. and Filly, R. A. (1991). Correlation between omphalocele contents and karyotypic abnormalities: sonographic study of 37 cases. *Am. J. Radiol.*, **158**, 133–6
112. Rezai, K., Holzgreve, W., Schloo, R., Terclani, S., Horst, J. and Miny, P. (1991). Pränatale Chromosomenbefunde bei sonographisch auffälligen feten. *Geburts. Frauenheilk.*, **51**, 211–16
113. Curry, C. J. R., Jensen, K., Holland, J., Miller, L. and Hall, B. D. (1984). The Potter sequence: a clinical analysis of 80 cases. *Am. J. Med. Genet.*, **19**, 679–702
114. Rizzo, N., Gabrielli, S., Pilu, G., Perolo, A., Cacciari, A., Domini, R. and Bovicelli, L. (1987). Prenatal diagnosis and obstetrical management of multicystic dysplastic kidney disease. *Prenat. Diagn.*, **7**, 109–18
115. Boue, A., Muller, F., Briard, M. L. and Boue, J. (1988). Interest of biology in the management of pregnancies where a fetal malformation has been detected by ultrasonography. *Fetal Ther.*, **3**, 14–23
116. Hegge, F. N., Prescott, G. H. and Watson, P. T. (1988). Sonography at the time of genetic amniocentesis to screen for fetal malformations. *Obstet. Gynecol.*, **71**, 522–5
117. Reuss, A., Wladimiroff, J. W., Stewart, P. A. and Scholtmeijer, R. J. (1988). Non-invasive management of fetal obstructive uropathy. *Lancet*, **2**, 949–51
118. Benacerraf, B. R., Mandell, J., Estroff, J. A., Harlow, B. L. and Frigoletto, F. D. (1990). Fetal pyelectasis: a possible association with Down syndrome. *Obstet. Gynecol.*, **76**, 59–60
119. Stoll, C., Alembik, Y., Roth, M. P., Dott, B. and Sauvage, P. (1990). Risk factors in internal urinary system malformations. *Pediatr. Nephrol.*, **4**, 319–23
120. Brumfield, C. G., Davis, R. O., Joseph, D. B. and Cosper, P. (1991). Fetal obstructive uropathies: importance of chromosomal abnormalities and associated anomalies to perinatal outcome. *J. Reprod. Med.*, **36**, 662–6
121. Nicolaides, K. H., Cheng, H., Snijders, R. J. M. and Gosden, C. M. (1992). Fetal renal defects: associated malformations and chromosomal defects. *Fetal Diagn. Ther.*, **7**, 1–11
122. Corteville, J. E., Dicke, J. M. and Crane, J. P. (1992). Fetal pyelectasis and Down syndrome: is genetic amniocentesis warranted. *Obstet. Gynecol.*, **79**, 770–2
123. Benacerraf, B. R. (1986). Antenatal sonographic diagnosis of congenital clubfoot: a possible indication for amniocentesis. *J. Clin. Ultrasound*, **14**, 703–6
124. Jeanty, P., Romero, R., d'Alton, M., Venus, I. and Hobbins, J. C. (1985). *In utero* sonographic detection of hand and foot deformities. *J. Ultrasound Med.*, **4**, 595–601
125. FitzSimmons, J., Droste, S., Shepard, T. H., Pascoe-Mason, J., Chinn, A. and Mack, L. A. (1989). Long bone growth in fetuses with Down syndrome. *Am. J. Obstet. Gynecol.*, **161**, 1174–7
126. Rodis, J. F., Vintzileos, A. M., Fleming, A. D., Giarleglio, L., Nardi, D. A., Feeney, L., Scorza, W. E., Campbell, W. A. and Ingardia, C. (1991). Comparison of humerus length with femur length in fetuses with Down syndrome. *Am. J. Obstet. Gynecol.*, **165**, 1051–6
127. Rotmensch, S., Luo, J. S., Liberati, M., Belanger, K., Mahoney, M. J. and Hobbins, J. C. (1992). Fetal humeral length to detect Down's syndrome. *Am. J. Obstet. Gynecol.*, **166**, 1330–4
128. Reisman, I. E. (1970). Chromosomal abnormalities and intrauterine growth retardation. *Pediatr. Clin. N. Am.*, **17**, 101–10
129. Chen, A. T. L., Chan, Y. K. and Falek, A. (1972). The effects of chromosomal abnormalities on birth weight in man. *Hum. Heredity*, **22**, 209–24
130. Ounsted, M., Moar, V. and Scott, A. (1981). Perinatal morbidity and mortality in small for dates babies: the relative importance of some maternal factors. *Early Hum. Dev.*, **5**, 367–75
131. Khoury, M. J., Erickson, J. D., Cordero, J. F. and McCarthy, B. J. (1988). Congenital malformations and intrauterine growth retardation: a population study. *Pediatrics*, **82**, 83–90
132. Hook, E. B. (1983). Chromosome abnormalities and spontaneous fetal death following amniocentesis: further data and associations with maternal age. *Am. J. Hum. Genet.*, **35**, 110–16
133. Snijders, R. J. M., Sherrod, C., Gosden, C. M. and Nicolaides, K. H. (1993). Severe fetal growth retardation: associated malformations and chromosomal abnormalities. *Am. J. Obstet. Gynecol.*, in press