

# Patient Satisfaction with Vaginal Erbium Laser Treatment of Stress Urinary Incontinence, Vaginal Relaxation Syndrome and Genito-urinary Syndrome of Menopause

Miguel A. Barber, Idoia Eguiluz

*Clinica ginecologica Baren, Cosmetic gynecology, Federico de Leon 2, Las Palmas, Spain*

## ABSTRACT

**Introduction:** Increasing demand in the field of cosmetic gynecology, together with the trend toward minimally invasive procedures in clinical gynecology and the appearance of new devices designed for these procedures, have led to a change in perspective toward this gynecological subspecialty.

**Objective:** To identify the impact and evaluate the degree of satisfaction among patients, after the introduction of a new 2940 nm erbium laser device in one gynecology center, for the treatment of vaginal relaxation syndrome, genito-urinary syndrome of menopause, and urinary incontinence.

**Materials and methods:** A prospective descriptive study of the first 40 consecutive cases treated in our center with said device and our experience in its use.

**Results:** All subjects completed the treatment without reporting adverse events. Clinical improvements in the pathologies present were noted in 78% of patients receiving the treatment, and the degree of satisfaction was greater than 90%.

**Conclusions:** This procedure is a quick and minimally invasive in-office alternative treatment, without side effects, that is effective and easily tolerated by patients. The patients reported a level of satisfaction greater than 90%, and 98% would recommend the treatment to other patients.

**Key words:** laser; erbium laser; vaginal relaxation syndrome; stress urinary incontinence; genito-urinary syndrome of menopause.

*Article: J. LA&HA, Vol. 2016, No.1; pp.18-23.*

*Received: September 18, 2016; Accepted: December 1, 2016*

© Laser and Health Academy. All rights reserved.  
Printed in Europe. [www.laserandhealth.com](http://www.laserandhealth.com)

## I. INTRODUCTION

A history of obstetric vaginal birth and

chronological ageing result in an increased laxity of the pelvic connective tissue and can lead to vaginal relaxation syndrome [1-3]. This loss of normal vaginal architecture results in a loss of tension that principally manifests with a loss of “friction” during sexual relations and a resulting loss of sexual gratification [4]. The laxity of the pelvic floor and periurethral connective tissue are also related to the appearance of stress incontinence [5]. Likewise, aging precipitates a lower production of female hormones, which is causative of the so-called genito-urinary syndrome of menopause [6] and consistent with the appearance of vulvo-vaginal atrophy [7], which manifests clinically as dryness, burning, irritation, discomfort during sexual intercourse, and urinary symptomatology. The recent appearance of laser photothermal treatments that produce a “shrinking” effect on the vaginal mucosa opens the door to alternatives to existing treatments [8].

## II. MATERIALS AND METHODS

This prospective, descriptive study was conducted in only one center and included a total of 240 “in-office” procedures performed with a 2940 nm Erbium-YAG laser during the period from January 2014 to August 2015. A total of 82 of these cases were vaginal treatments. Of these cases, 40 were patients treated consecutively. All patients were evaluated by the same doctor, who performed anamnesis and gynecological explorations, including vaginal speculscopy, cytology sampling, and ultrasound studies of the internal genital structure. During this consultation, the Sandvik test was performed to evaluate the degree of stress incontinence in patients who reported this symptom, including for patients with a result of less than 6 [9] (Table 1). Table 2 shows a summary of the inclusion/exclusion criteria applied for this study. Subsequently, results regarding vaginal tension, stress incontinence, genito-urinary syndrome, and the patients’ degrees of satisfaction with the treatments performed were graded using a previously designed questionnaire. Patients affected with slight or moderate stress incontinence were included, whereas patients diagnosed with mixed incontinence and severely affected patients were excluded.

**Table 1. Sandvik's severity test for urinary incontinence.**

<b>How often does urine escape?</b>	
Less than once a month	1
A few times a month	2
A few times a week	3
Every day and/or night	4
<b>How much urine escapes each time?</b>	
Drops (very small quantity)	1
A small stream (moderate quantity)	2
A large quantity	3

The severity index is calculated by multiplying the result of the two questions and then categorizing according to the following scale: 1-2 = slight, 3-6 = moderate, 8-9 = severe, 12 = very severe.

**Table 2. Inclusion and exclusion criteria for erbium laser treatment.**

<b>Inclusion criteria</b>
Vaginal relaxation syndrome
Slight-to-moderate stress urinary incontinence
Genito-urinary syndrome
Examination and cytology without pathologic findings
Introitus, vestibule, and vagina free of blood or lesions
<b>Exclusion criteria</b>
Age greater than 70 years
Pregnancy
Taking of medications causing photosensitivity
Menstruation
Active infections
Diabetes mellitus
Morbid obesity

The patients were given appointments for clear explanations of the treatments to be performed and received forms with post-treatment recommendations. Informed consent forms for treatment were signed. All procedures were performed by the same obstetrics & gynecology specialist, who had surgical experience and training specific to this device. A topical anesthetic (EMLA®) was recommended. After situating the patients in the dorsal lithotomy position and proceeding to disinfection, followed by a thorough drying of the area, the minimally invasive non-ablative thermal treatment was performed using a 2940 nm Erbium-YAG (FotonaSmooth™ XS, Fotona, Slovenia) laser device in SMOOTH mode.

The use of the device complied with the protocols recommended by Fotona in each case, including the protocols for IntimaLase®, IncontiLase®, and RenovaLase®.

Two identical treatment sessions separated by a 30-day interval were performed. After each session, the patients were given a one-week follow-up appointment with the goal of early detection of possible complications produced by the treatment with the new laser device. Subsequently, a four-month follow-up evaluation was performed, and patient satisfaction questionnaires (Suppl. 1) were delivered to assess the treatment for vaginal relaxation syndrome, urinary incontinence, or genito-urinary syndrome. These questionnaires were designed specifically for this study and were based on examples published by other authors [10,11].

### III. RESULTS

Since the acquisition of the FotonaSmooth™ XS erbium laser device in 2013, we have performed a total of 240 different outpatient gynecological procedures in office. A total of 40 patients with vaginal relaxation syndrome (27% n=11), slight-to-moderate stress urinary incontinence (52% n=21), or genito-urinary syndrome (20% n=8) were consecutively included in our study. Other indications or combinations of the above treatments were excluded from the study. In all cases, we successfully completed the minimally invasive treatment with the 2940 nm erbium laser. Subsequently, the impacts of this treatment on different patient quality of life measures were evaluated, including general satisfaction, the effect on vaginal tension in sexual relations, improvement of stress incontinence, and other factors in the scope of genito-urinary syndrome, such as vaginal dryness, leucorrhea, and recurrent infections.

The average patient age was 47.6 years (range from 30 to 61 years). Of the patients included in the study, 92% had undergone vaginal births; of these patients, 50% had undergone two or more births. After treatment, 80% of patients whose indication had been a loss of vaginal tension (n=8/11) reported improvement; 70% of these saw their improvement as "important" (Fig. 1). This value increased to 82% when the partner was questioned (Fig. 2). 70% of patients with vaginal laxity experienced improvements in their sex lives, and 20% reported increases in sexual desire (Fig. 2). Urinary incontinence improved in 75% of the patients (n=15/21) suffering from SUI; 86% (n=13/15) of these referred to the improvement as important (Fig. 1). More than 80% of patients presenting with vaginal dryness experienced

improvement after the procedure and 85% of these achieved important improvement (Fig. 1).

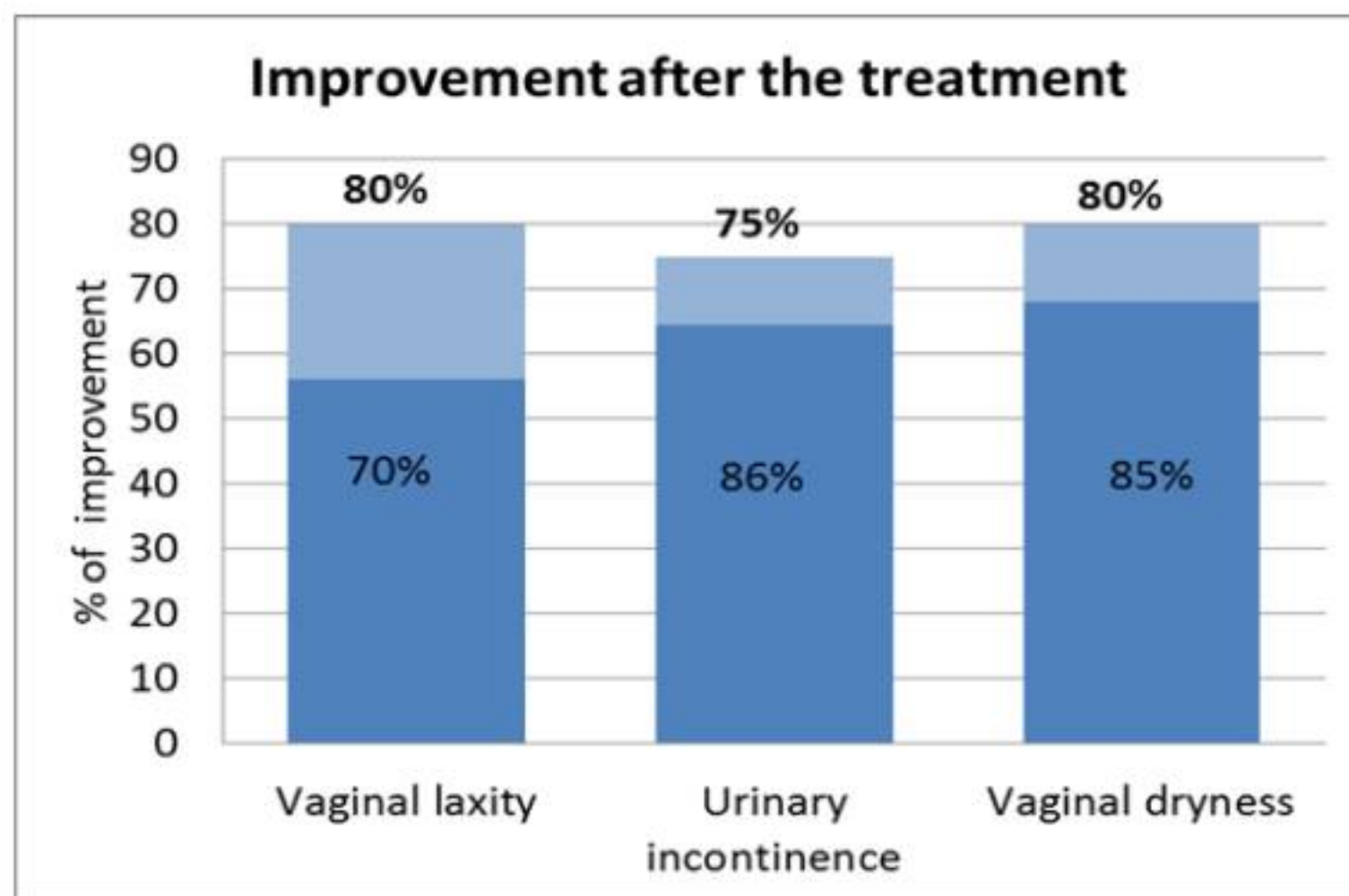


Fig. 1: Improvement Results. Group 1: Vaginal laxity: Group 2: Urinary incontinence: Group 3: Vaginal dryness

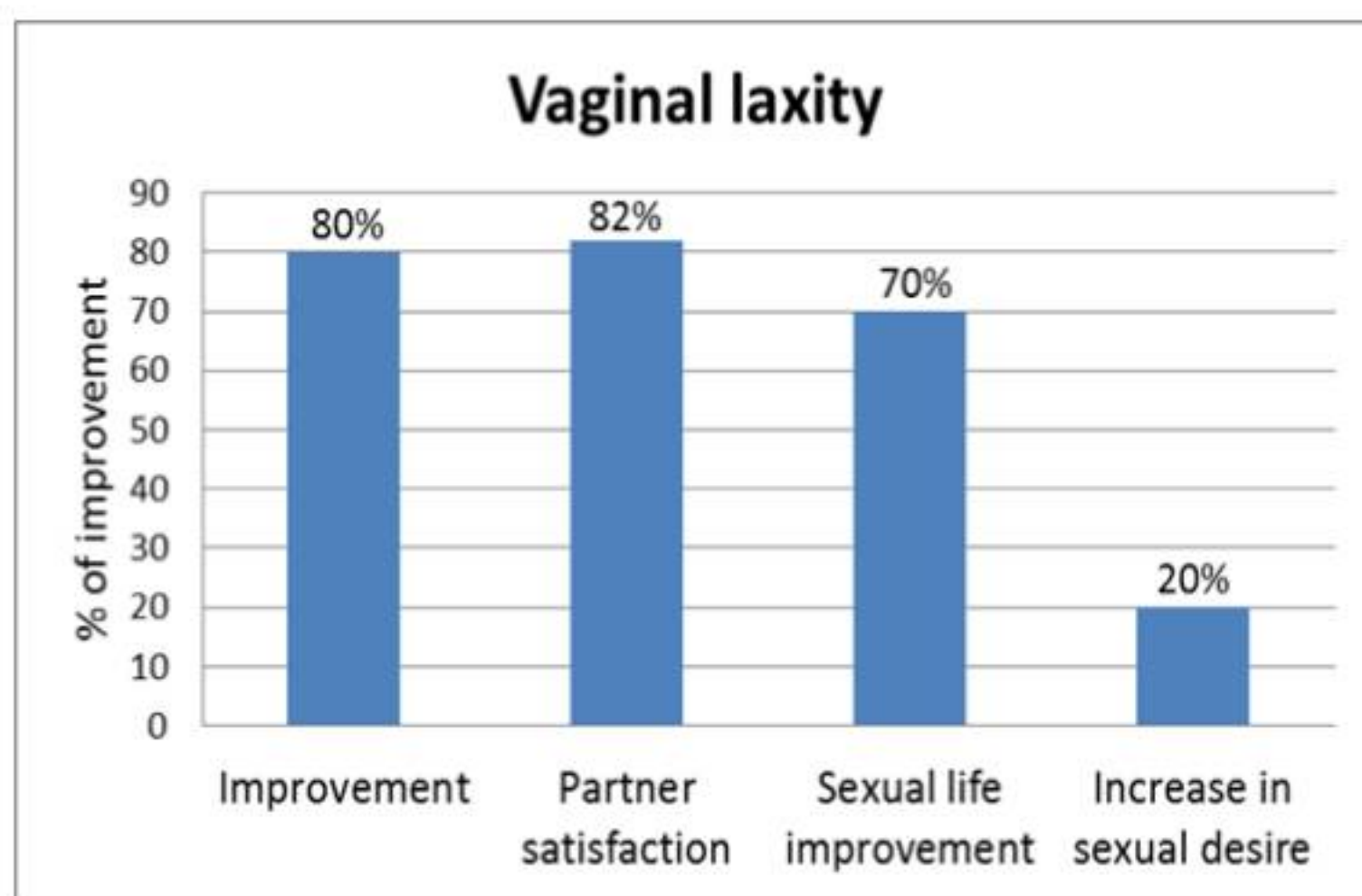


Fig. 2: Vaginal laxity: improvement after the treatment with Er:YAG laser

When evaluating treatment tolerance and patient satisfaction, 90% of the patients reported little or no discomfort. Only 10% of the patients reported the moment of treatment as painful. Only 10% of the patients reported any complaints after treatment, including discomfort or mild pain, which were of very minimal impact in the days following treatment. All patients reported that they were able to proceed with their normal lives the same day, indicating that this treatment was well tolerated, practically painless and without a convalescent period. In reference to overall satisfaction with the treatment, despite an overall improvement reported by 78.3% of patients, 90% of the patients considered the treatment useful, 98% would recommend the treatment to a friend, and the overall degree of satisfaction was 90%.

#### IV. DISCUSSION

The loss of anatomical support of the periurethral structures due to age and damage of these areas is very likely due to alterations in collagen quantity or quality [12-14]. The use of lasers can improve these

alterations in connective tissue [15-17]. The exposure of collagen to a thermal effect produces an immediate contraction of collagen fibers and a shrinkage of the irradiated tissue [18]. Additionally, the long-term effects result in remodeling and collagenogenesis, which entails the generation of new collagen fibers and general improvements in the elasticity and tension of the treated tissues [19-23].

After using the FotonaSmooth™ XS 2940 nm erbium laser device for the treatment of patients with vaginal relaxation syndrome with loss of sexual gratification, García et al. [24] reported improvements not only in sexual relations, but also secondarily with respect to the urinary incontinence with which these patients presented, very possibly due to the existence of a close relationship between the two conditions. Different authors have demonstrated the effectiveness of treatment with erbium laser for a loss of vaginal tension [25], urinary incontinence [26], and genito-urinary syndrome [27-29]. This evidence suggests the utility of incorporating these devices into our daily practice in the field of gynecology. Gaviria et al. [10] described erbium laser treatment for the loss of vaginal tension as a safe modality with minimal discomfort for the patient. We conducted weekly follow-ups with our patients after each of the two sessions and did not encounter any complications following treatment. As a result, this procedure is positioned as a valid alternative to standard treatments. The procedure was performed under topical anesthetic (EMLA® 25 g/g), and very little discomfort was experienced during its performance; furthermore, the results showed high patient satisfaction. Gaviria et al. [10] also reported improvements of 95% in vaginal tension and sexual satisfaction. In our study, sexual improvements were reported for only approximately 75% of the patients and were confirmed by the partner at a similar percentage.

In another report studying 39 patients affected with slight to moderate stress incontinence who were treated using the same system, Fistonc et al. [11] also demonstrated that the procedure was safe. The same author treated 73 women affected with incontinence in another prospective study in only one center and found improvements in 67% of women with a normal body mass index, and in 100% of women when the treated patients were younger than 39 years of age [30]. Ogrinc et al. [31] used an erbium laser to treat 175 consecutive patients affected with incontinence, including 114 women with stress incontinence, and demonstrated that this method was effective with at least one year of positive effects. This report also demonstrated that this method was not suitable for mixed incontinence cases. In our study, only patients

with stress incontinence of the slight or moderate type were included, whereas patients diagnosed with mixed incontinence or severely affected patients were excluded. Generally, we demonstrated improvement in vaginal tension and urinary incontinence (80% and 75%, respectively). These results were comparable to the results described with other surgical techniques without the same possibility for complications [3].

Regarding vaginal dryness, the erbium laser is proposed as a good alternative to other existing medical treatments [32-35]. Gaspar [36] published better results with laser treatment versus local estrogen treatment to improve symptoms such as dyspareunia, vaginal dryness, burning sensation, or irritation. After performing laser treatment on 48 menopausal patients for genito-urinary syndrome, Perino et al. [27] demonstrated that the treatment was reliable and safe. Finally, Salvatore et al. [28] also showed improvement in vulvo-vaginal atrophy and sexual relations in menopausal patients after laser treatment. Although our objective was to evaluate patients with vaginal relaxation syndrome and urinary incontinence, the data gathered included the degrees of improvement in vaginal dryness, vaginal discharge, and recurrent infections. Of the three indications studied for vaginal erbium-laser treatment, genito-urinary syndrome was the most infrequent; only 20% of the patients presented with this clinical indication, very possibly due to the average age of the treated patients. The improvement reported was 80%.

In our center, the introduction of laser treatments has not produced any complications in our daily routine. Moreover, this novel method appeared to be well received by the clientele based on the number of cases seen in the given period and the great satisfaction of the patients who had the treatment (90%). Vizintin et al. [37] was in agreement with this conclusion and suggested that the erbium laser was effective and safe for the treatment of vaginal relaxation, stress urinary incontinence, pelvic-organ prolapse, and vaginal atrophy. These data together with the social changes seen in gynecological consultations where patients increasingly request solutions for the loss of vaginal tension, urinary incontinence, or genital dryness [37,38] indicate that this type of treatment should be included in the alternatives currently offered for the treatment of these conditions. Classically, different treatments are available for vaginal rejuvenation, although these procedures are invasive and have a surgical risk and long periods of convalescence [39]. Based on our results, we found that this method represented an easily performed and easily learned in-office procedure without significant reported complications that offered

good results and yielded great patient satisfaction. Due to these factors, this procedure should be considered as an important treatment alternative.

## V. CONCLUSIONS

We propose offering 2940 nm erbium laser treatment as a minimally invasive and safe treatment for the loss of vaginal tension and deterioration in sexual relations, slight-to-moderate urinary incontinence, and vaginal dryness caused by genito-urinary syndrome. This procedure is associated with a significant degree of patient satisfaction, with 90% overall satisfaction and 98% of the patients reporting that they would recommend the treatment to others. The procedure can be integrated into the daily activities of any obstetrics and gynecology center and can be presented as an alternative to other medical or surgical treatments.

## REFERENCES

1. Bump RC, Norton PA (1998) Epidemiology and natural history of pelvic floor dysfunction. *Obstet Gynecol Clin North Am* 25:723-746
2. Luber KM (2004) The definition, prevalence, and risk factors for stress urinary incontinence. *Rev Urol* 6:S3-S9
3. Rovner ES, Wein AJ (2004) Treatment options for stress urinary incontinence. *Rev Urol* 6:S29-S47
4. Braun V, Kitzinger C (2001) The perfectible vagina: size matters. *Cult Health Sex* 3:263-277
5. Dietz HP, Clarke B (2001) The urethral pressure profile and ultrasound imaging of the lower urinary tract. *Int Urogynecol J Pelvic Floor Dysfunct* 12:38-41
6. Panay N (2015) Genitourinary syndrome of the menopause – dawn of a new era? *Climacteric* 18:13-17
7. Hutchinson-Colas J, Segal S (2015) Genitourinary syndrome of menopause and the use of laser therapy. *Maturitas* 82:342-345
8. Gambacciani M, Torelli MG, Martella L, Bracco GL, Casagrande AG, Albertin E, Tabanelli S, Viglietta M, D'Ambrogio G, Garone G, Cervigni M (2015) Rationale and design for the Vaginal Erbium Laser Academy Study (VELAS): an international multicenter observational study on genitourinary syndrome of menopause and stress urinary incontinence. *Climacteric* 18:43-48
9. Sandvik H, Seim A, Vanvik A, Hunskaar S (2000) A severity index for epidemiological surveys of female urinary incontinence: comparison with 48-hour pad-weighting tests. *Neurourol Urodyn* 19:137-145
10. Gaviria P, Lanz L (2012) Laser vaginal tightening (LVT)–evaluation of a novel non-invasive treatment for vaginal relaxation syndrome. *J Laser Health Acad* 1:59-66
11. Fistonc I, Gustek SF, Fistonc N (2012) Minimally invasive laser procedure for early stages of stress urinary incontinence. *J Laser Health Acad* 1:67-74
12. Falconer C, Ekman G, Malmstrom A, Ulmsten U (1994) Decreased collagen synthesis in stress-incontinent women. *Obstet Gynecol* 84:583-586
13. Wong MY, Harmanli OH, Agar M, Dandolu V, Grody MHT (2003) Collagen content of nonsupport tissue in pelvic organ prolapse and stress urinary incontinence. *Am J Obstet Gynecol* 189:1597-1599
14. Soderberg MW, Falconer C, Bystrom B, Malmstrom A, Ekman G (2004) Young women with genital prolapse have a low collagen concentration. *Acta Obstet Gynecol Scand* 83:1193-1198

15. Appell RA, Juma S, Wells WG, Lenihan JP, Klimberg IW, Kanellos A, Reilley SF (2006) Transurethral radiofrequency energy collagen micro-remodeling for the treatment of female stress urinary incontinence. *Neurourol Urodyn* 25:331-336
16. Juma S, Appell RA (2007) Nonsurgical transurethral radiofrequency treatment of stress urinary incontinence in women. *Women's Health* 3:291-299
17. Gaspar A, Addamo G, Brandi H (2011) Vaginal fractional CO2 laser: a minimally invasive option for vaginal rejuvenation. *American Journal of Cosmetic Surgery* 28:156-162
18. Lukac M, Perhavec T, Nemes K, Ahcan U (2010) Ablation and thermal depths in VSP Er: YAG laser skin resurfacing. *J Laser Health Acad* 1:56-71
19. Beltram M, Drnovsek-Olup B (2005) New collagen synthesis in skin fibroblasts after Er: YAG laser skin resurfacing. *Lasers Surg Med* 17:33
20. Beltram M, Drnovsek B (2008) Quantitative analysis of new collagen synthesis after Er: YAG laser skin resurfacing with biomolecular technique. *Lasers Surg Med* 20:35
21. Beltram M, Zivin M, Drnovsek-Olup B (2010) Collagen synthesis after laser skin resurfacing of the periocular skin. *Zdrav Vestn* 79:i111-i116
22. Utley DS, Koch RJ, Egbert BM (1999) Histologic analysis of the thermal effect on epidermal and dermal structures following treatment with the superpulsed CO2 laser and the Erbium:YAG laser: an in vivo study. *Lasers Surg Med* 24:93-102.
23. Goldberg DJ (2003) Biology of collagen. In: Ablative and non-ablative facial skin rejuvenation. Martin Dunitz, London, New York, pp 1-8
24. García V, Gonzalez A, Herrera S, Lemmo A, Ollarves V, Gonzalez E, et al (2012) Tensado vaginal laser y gratificación sexual [Laser vaginal tightening and sexual gratification]. Poster. *Laser Europe*. London May 2012. *Lasers Med Sci* 27: 849-893.
25. Fistonc I, Manestar M, Perovic D, Sorta-Bilajac Turina I, Fistonc N, Maletic D, Maletic A (2011) Laser vaginal tightening for sexual dysfunction. *Climacteric* 14:85
26. Vizintin Z, Rivera M, Fistonc I, Saraçoğlu F, Guimares P, Gaviria J, Garcia V, Lukac M, Perhavec T, Marini L (2012) Novel minimally invasive VSP Er: YAG laser treatments in gynecology. *J Laser Health Acad* 1:46-58
27. Perino A, Calligaro A, Forlani F, Tiberio C, Cucinella G, Svelato A, Saitta S, Calagna G (2015) Vulvo-vaginal atrophy: a new treatment modality using thermo-ablative fractional CO2 laser. *Maturitas* 80:296-301
28. Salvatore S, Nappi RE, Parma M, Chionna R, Lagona F, Zerbinati N, Ferrero S, Origoni M, Candiani M, Leone Roberti Maggiore U (2015) Sexual function after fractional microablative CO2 laser in women with vulvovaginal atrophy. *Climacteric* 18:219-225
29. Salvatore S, Nappi RE, Zerbinati N, Calligaro A, Ferrero S, Origoni M, Candiani M, Maggiore U (2014) A 12-week treatment with fractional CO2 laser for vulvovaginal atrophy: a pilot study. *Climacteric* 17:363-369
30. Fistonc N, Fistonc I, Lukanovic A, Gustek SF, Turina ISB, Franic D (2015) First assessment of short-term efficacy of Er:YAG laser treatment on stress urinary incontinence in women: prospective cohort study. *Climacteric* 18:37-42
31. Ogrinc UB, Sencar S, Lenasi H (2015) Novel minimally invasive laser treatment of urinary incontinence in women. *Lasers Surg Med* 47:689-697
32. Palacios S, Mejía A, Neyro JL (2015) Treatment of the genitourinary syndrome of menopause. *Climacteric* 18:23-29
33. Bachmann G, Lobo RA, Gut R, Nachtigall L, Notelovitz M (2008) Efficacy of low-dose estradiol vaginal tablets in the treatment of atrophic vaginitis: a randomized controlled trial. *Obstet Gynecol* 111:67-76
34. Suckling JA, Kennedy R, Lethaby A, Roberts H (2006) Local oestrogen for vaginal atrophy in postmenopausal women. *Cochrane Database Syst Rev* doi:10.1002/14651858.CD001500
35. Bojanini B, Mejía A (2014) Laser treatment of vaginal atrophy in post-menopause and post-gynecological cancer patients. *J Laser Health Acad* 2014:65-71
36. Gaspar A (2014) Comparison of new minimally invasive Er:YAG laser treatment and hormonal replacement therapy in the treatment of vaginal atrophy. *Climacteric* 17:124.
37. Vizintin Z, Lukac M, Kazic M, Tettamanti M (2015) Erbium laser in gynecology. *Climacteric* 18:4-8
38. Gambacciani M, Cervigni M (2015) Erbium laser in gynecology: aims, aspirations and action points. *Climacteric* 18:2-3
39. Pardo JS, Solà VD, Ricci PA, Guiloff EF, Freundlich OK (2006) Colpoperineoplasty in women with a sensation of a wide vagina. *Acta Obstet Gynecol Scand* 85:1125-1127

The intent of this Laser and Health Academy publication is to facilitate an exchange of information on the views, research results, and clinical experiences within the medical laser community. The contents of this publication are the sole responsibility of the authors and may not in any circumstances be regarded as official product information by medical equipment manufacturers. When in doubt, please check with the manufacturers about whether a specific product or application has been approved or cleared to be marketed and sold in your country.

**SUPPLEMENT 1:  
SATISFACTION QUESTIONNAIRE**

**A-MEDICAL INDICATION**

What was the reason for the laser vaginal tightening?

- a) Urinary incontinence.
- b) Interest in improving sexual relations
- c) Vaginal dryness
- d) Recurrent vaginal-urinary infections

**B-URINARY INCONTINENCE**

What changes occurred in your urinary incontinence following the laser treatment compared to before the treatment?

- a) No pre-treatment incontinence was presented
- b) No change
- c) Slight
- d) Moderate
- e) Great change

What were the results following the laser treatment in relation to your urinary incontinence?

- a) No pre-treatment incontinence was presented
- b) Still very wet
- c) Slightly wet (sometimes)
- d) Rarely wet (practically dry)
- e) Totally dry

What were the results following the laser treatment in relation to urine loss during sexual activity?

- a) I have never presented urine loss
- b) I continue to lose urine during sexual intercourse
- c) I do not lose urine during sexual intercourse

**C-SEXUAL ACTIVITY**

What changes occurred in your vaginal tension following the laser treatment compared to before the treatment?

- a) No change
- b) Slight
- c) Moderate
- d) Great change

What changes in your vaginal tension were perceived by your partner following the laser treatment compared to before the treatment?

- a) No change
- b) Slight
- c) Moderate
- d) Great change

How has vaginal laser tightening improved your sex life?

- a) It has not improved at all
- b) More vaginal friction during sexual intercourse
- c) Better orgasms
- d) More orgasms
- e) Other (If other, explain the reason).....

Has the vaginal laser tightening improved your sexual interest in some way?

- a) Same sexual interest
- b) Less sexual interest
- c) Greater sexual interest
- d) Much greater sexual interest

**D-VAGINAL DRYNESS**

What changes occurred in your vaginal dryness/lubrication following the laser treatment compared to before the treatment?

- a) No vaginal dryness was presented
- b) No improvement of vaginal dryness-lubrication
- c) Mild-moderate improvement of vaginal dryness-lubrication
- d) Significant improvement of vaginal dryness-lubrication

**E-VAGINAL-URINARY INFECTIONS**

What changes in your flow (leucorrhoea)/repetition of infections were perceived by your partner following the laser treatment?

- a) No recurrent infections were presented
- b) Improvement in the flow-repetition of infections
- c) No improvement in the flow-repetition of infections

**F-TREATMENT**

Did you find the laser treatment annoying/painful?

- a) Nothing annoying
- b) Slightly annoying
- c) Very annoying

Did you present discomfort/pain following the laser treatment?

- a) No discomfort/pain
- b) A little discomfort/pain
- c) Much discomfort/pain

How long did it take for you to consider that you were in a position to continue your normal life?

- a) The same day
- b) In one day
- c) In two days
- d) In more days

**G-SATISFACTION**

Do you think the treatment you received has been useful?

- a) Yes
- b) No

Would you recommend the treatment to a friend?

- a) Yes
- b) No (If no, explain the reason)

.....  
.....

What degree of satisfaction would you express?

- a) None
- b) A little bit
- c) Much