

Modified Wedge Labiaplasty with an Aesthetic Eye: The True Technique

Robert L. True, MD, FACOG, FACS*

5203 Heritage Ave., Colleyville, TX 76034, USA.

***Correspondence:**Robert L. True, 5203 Heritage Ave., Colleyville, TX 76034, USA,
Tel: 817-399-8783; E-mail: rbrtrue@yahoo.com.**Received:** 18 November 2017; **Accepted:** 06 December 2017**Citation:** Robert L. True. Modified Wedge Labiaplasty with an Aesthetic Eye: The True Technique. Anesth Pain Res. 2017; 1(1): 1-6.**ABSTRACT****Statement of the problem:** Many labiaplasty procedures result in unacceptable aesthetic results.**Summary:** Labiaplasty procedures have become very popular but results vary depending on the technique and experience of the surgeon. There are many techniques of performing the procedure and many times women are unhappy about the results due to an unsatisfactory aesthetic result. There are numerous reasons why women desire labiaplasty. These include embarrassment, poor self-esteem functional and emotional enhancement [1-4]. To achieve the best aesthetic result one must consider the specific characteristics of a more aesthetic genital area. I would like to describe a different technique for performing labiaplasty which emphasizes this goal, versus other techniques that may not provide the same type of results. I developed a technique called a modified posterior wedge technique that results in a more aesthetic and natural appearance of the labia. A similar technique has been described in the past [5], but I developed this technique separately and based on what constitutes a more aesthetic labial appearance.**Description of technique:** I discuss my technique of performing labiaplasty from initial evaluation, markings, surgical details, results, potential complications and how to avoid them.**Conclusion:** The rationale, goals and technique for performing a modified posterior wedge labiaplasty is described.**Keywords**

Women, Labiaplasty, Tissue.

aesthetic appearance to give these women a prettier genital area could resolve these concerns.

Introduction

Reduction of excess labial tissue, otherwise called labiaplasty, should be performed in the most aesthetic manner possible. The procedure should be planned out precisely and correctly before any cutting has been done. The goal of labiaplasty is not just to trim the labia to make them shorter, but to improve the beauty, sensitivity, and function of the female external pelvic tissues.

Emotional discomfort regarding self-appearance and social and sexual relationships are the most frequent and the most prominent motivations for considering labial reduction surgery on women's online communities, regardless of age and national background. Functional discomfort and desired emotional enhancement ranked second [8]. Thus the emphasis for performing labiaplasties with the best aesthetic appearance to help them feel good about their appearance should be most importance for better satisfaction of the patient.

Why women want Labiaplasty?

Many women dislike excess labial tissue that falls down excessively and hangs down between her labia majora when she stands. Many are embarrassed by this excess tissue, they don't feel comfortable with its appearance, and may have self-esteem issues due to its presence [6,7]. Changing the anatomy to a more

Some people believe that labiaplasty surgery is a fabricated cosmetic procedure that women don't need. However, just like all other cosmetic procedures, need is not necessarily the concern. Women just want to look more beautiful in their vaginal area.

The importance of genital appearance beauty enhancements is exemplified by the millions of dollars spent on waxing and laser hair reduction treatments that women pay to make their “bikini” areas more beautiful.

Thus, the labiaplasty procedure should be performed with an aesthetic eye to give the patient the best possible beautiful appearance of the pelvic area. Too many times physicians literally just cut the excess labial tissue without regard to the aesthetic goal. Sometimes they excise too much tissue leaving the woman with hardly any labia left intact, giving the area an unnatural look and making many women very unhappy [9]. Many suffer remorse for making the decision to have the labiaplasty done. Forging into the procedure recklessly without adequate planning and foresight into what makes up a beautiful genital area should be discouraged. The surgery should be designed, planned, and executed with beauty in mind not only for the patient, but also to give the procedure a good reputation.

Characteristics of aesthetic labia

Knowing the characteristics of more aesthetic labia is therefore essential before we perform the procedure [10]. Let’s summarize these characteristics so we can create the surgery to fit the desired results. When one first looks at a beautiful female vulva, the labia majora should be slightly full with minimal wrinkles. The clitoris and labia should “peek” from the top medial parts of these mounds in a sensuous manner. The thin labia should peek slightly below the clitoris with a natural fall of the thin delicate frenulum. They should not protrude excessively from the vulvar mounds and the tissue around the clitoris should not bulge excessively nor be excessively wrinkled.

After spreading the vulvar mounds, there should be minimal redundant tissue on either side of the clitoris, i.e. the prepuce. One should see a slight amount of clitoral tissue peeking from below the foreskin without redundancy of the foreskin tissue. The frenulum should drape down naturally from the clitoris without bulges or nodules and intersect with the thin labial edges with a smooth transition. The labial edges should be thin and transition smoothly and sensuously down to the lower perineal tissues. There should be minimal to no excess tissue redundancy in the lower fourth of the vaginal opening and the perineal area.

Knowing these characteristics will allow us to plan the labiaplasty procedure with the goal of a more aesthetically beautiful external pelvic area [11]. This can not only improve the appearance of this area, but also may improve the self-esteem and self-confidence of the patient.

Types of labiaplasties

Over the years there have been several types of labiaplasties developed. Regardless of the technique, the majority of women are satisfied with their results [12]. Most popular have been the wedge resection and linear excision labiaplasty. An inner resection deepithelialization reduction labiaplasty has also been performed [13].

The original wedge resection procedure simply excises a wedge of tissue from the labia to reduce the size of the labia, and then the remaining edges are sewn back together [14]. This procedure, unfortunately, does not adequately address excessive prepuce and perineal tissue. In addition, if performed with excess tension, the wound edges may separate resulting in non-union and a “V” shaped deformity, which may be a difficult repair over time.

Another popular method is a linear excision of the elongated labia, also called a Trim procedure. This linear resection of the labia removes the outer part of the labia with a curved excision. There are many problems with this technique. The thin sensitive edge of the labia is removed with this technique leaving a wide base. Removing the labial edges may leave the labia with decreased sensitivity. The downward natural draping of the frenulum is disrupted by this incision which can leave unnatural nodules at the ends of the cut-off frenulum which can be difficult to hide. This may take away the beautiful natural fall of the frenulum and its sensual transition from the clitoris to the upper labia minora.

Although a Trim procedure may reduce excess pigmentations of the labia, after excision, the remaining labia may appear blunted and widened in appearance with too much wide unnatural pink showing. Moreover, sometimes incorrect sewing of the labia can leave multiple depressions or scalloping of the labial edges [15]. Just like the wedge procedure, the incision line can come open leaving gaps in the labial tissues.

If excised with cautery or even radiofrequency, Trim procedures can sometimes result in excision of too much tissue or a deep burn injury, further reducing the labial tissue and leaving the woman sometimes with hardly any labial tissue present or irregular dents in the edges. Many surgeons sew the edges with sutures in such a manner that it leaves the edges with an unnatural “scalloped” look, about which many women are not happy. All of these problems can thus result in a most unnatural and not aesthetically beautiful look.

A third technique is the deepithelialization technique. This can result in thickening and bunching of the labial tissues, especially if larger labia are reduced [16]. It is accompanied by other potential problems such as non-union of the wound edges resulting in holes inside of the labia. It may result in an unnatural transition of pigment color where the anterior and posterior flaps are brought together [17], and unnatural bunching of the tissues. Moreover, it does not address the excess prepuce or perineal tissue that may also be concerns.

Finally, a posterior wedge resection has also been described [18], similar to my technique, and its results have been proven to be satisfactory with minimal complications. However, the technique does not address all the aspects for achieving more natural labia with a more aesthetic improvement of the genital area.

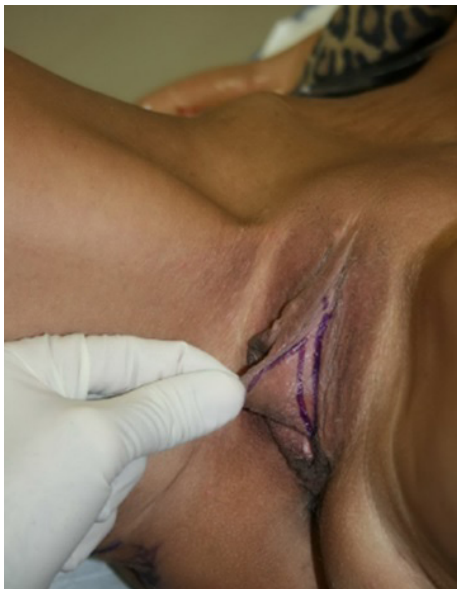
Because of these many shortcomings of prior procedures, I created a different technique I call the True Labiaplasty, which maintains all the goals to achieve a more aesthetically beautiful and natural

labial appearance while maintaining or even enhancing sexual sensation of the genital area.

Method: True Labiaplasty Technique

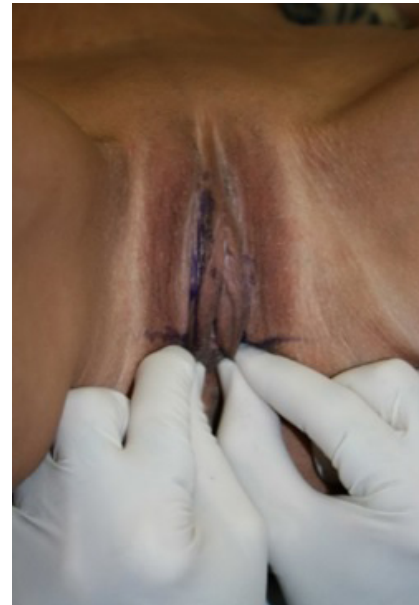
The technique of the True Labiaplasty encompasses not only a modified wedge resection of the labia minora, but also resections of the excess prepuce in a smooth transitional fashion with the labia minora and excess tissue in the perineum to produce a more natural and aesthetically preferred appearance of the labia and its adjacent structures.

The patient is placed in the lithotomy position and photos done. The labia are marked and an assessment of the anatomy is made. The lateral labial crease, the lower incision, and the lower border of the superior pedicle are marked, thus outlining the inferior triangular wedge of tissue to be resected with these marks (Figure 1).



The desired plan should be to make the labial flap thin enough to reduce the size of the elongated labia and to improve the beauty of the labia, but be tall and wide enough to preserve its superior circulation and nerves. The final shape is of a narrow curved pedicle with the proposed incision several millimeters below the natural labial edges, transitioning into the upper wider portion of the pedicle. The amount and shape is variable depending on the patient's present anatomy. Next, any excess prepuce tissue and any extra tissue in the lower fourth of the introitus down to the perineum that is planned to be resected should also be marked.

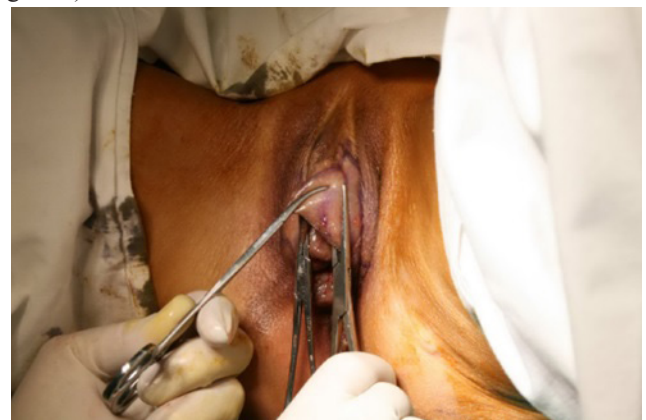
An important anatomic mark to be made is a transverse linear mark made on both sides of the labia majora that will be the end points for where the lower tips of the superior pedicle flaps will end. This creates a guideline to help assure symmetry of the flaps when they are sewn down. With labial surgery, one should always remember that, just like on the face and the body, symmetry is extremely important and the tissues should be tested and reexamined throughout the procedure to make sure the desired result will be achieved (Figure 2).



A mental picture of the marked area is formed since the markings fade and the anatomy becomes distorted after the local anesthetic is applied. It is very important to use tumescent anesthetic in the tissues for this decreases bleeding and thus markedly decreases the need for cautery to coagulate bleeding points. In addition, it may also decrease infections and postop hematomas.

Mild sedation can be administered before the local tumescent anesthetic is administered. General anesthesia is usually not needed for this procedure for once the patient is numb, she feels nothing. Tumescent anesthetic is administered starting inferiorly with one skin stick mid perineum using a small gauge needle, and progressing superiorly within the subcutaneous tissue using a 25G 1" needle. The tumescent fluid is made using 250 cc of normal saline, 1 mg of epinephrine, and 50 cc of 1% lidocaine. Normally, only around 100 to 250 cc are used.

Clamps are then placed within the marked lines to create very symmetrical flaps of labial tissue. Initially these are placed very loosely on the tissue and not clamped until symmetry is achieved of the right and left labia. A straight clamp is placed at the base and a curved one placed along the lower edge of the superior pedicle (Figure 3).



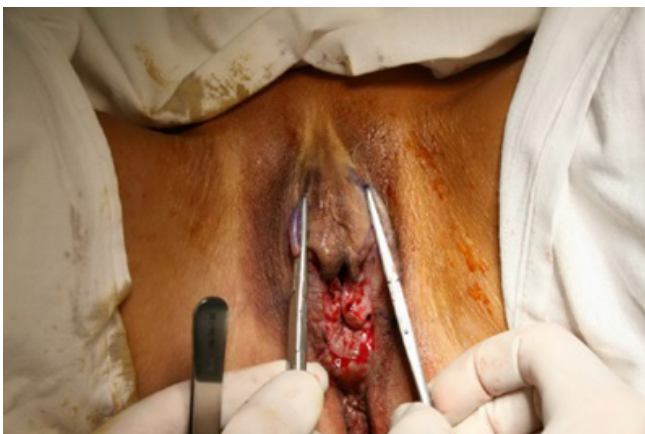These must be placed so that the lower tip of the pedicle will end up at the transverse line and symmetrical on both sides. Once symmetry is assured, the clamps are tightened. Note that once tight, the tissue is crushed and cannot be used for sewing. The incision should be outside the clamp borders and not include any crushed tissue.

Adequate pedicle flap should be assured and there should be no excessive pull of the pedicle tissue superiorly as the flaps should be able to drape down naturally without pulling tension. If sewn under excess tension, the pedicle is more likely to dehisce and pop up, plus an unnatural “pulled down” look may result.

The wedge of tissue is then excised sharply with a knife or scissors and removed from the field, leaving the pedicle and the base tissue. I do not recommend that cutting cautery be used here. The tumescent effect with the clamps usually are sufficiently adequate to produce hemostasis. Any remaining bleeding points are usually minimal and can be cauterized with pin-point cautery at low power. The other side is excised in a similar fashion making sure that the pedicle flaps are of equal size, thickness and length for symmetry. Remember, symmetry is important for beauty.

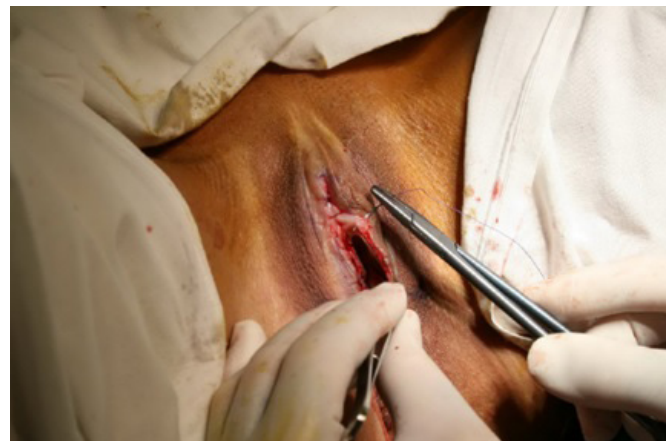Any excess tissue on both sides of the clitoris is then measured and clamped, again making sure they are symmetrically. A key point is to not plan to make this excision too close to the clitoris and to not cut any deep tissue above the clitoris. This is important to help prevent injury to the clitoral nerve that usually descends directly superior to the clitoris. Maintenance of clitoral sensation is very important, therefore only superficial excisions (not deep excisions) and no injury to the clitoral tissues is cautioned.

To help ensure symmetry, loosely placed clamps are used and adjusted gently several times before adequate symmetry of the remaining clitoral and prepuce tissues is achieved (Figure 4). Of note, many times one side may be much larger than the other and this must be adjusted appropriately. After assurance of symmetry, these tissues are excised with sharp excision below the clamped tissues, remembering to never leave any crushed tissue behind. The lateral excision line should be trimmed so that it is a straight line from the top of the prepuce tissue to the lowest point of the excision.

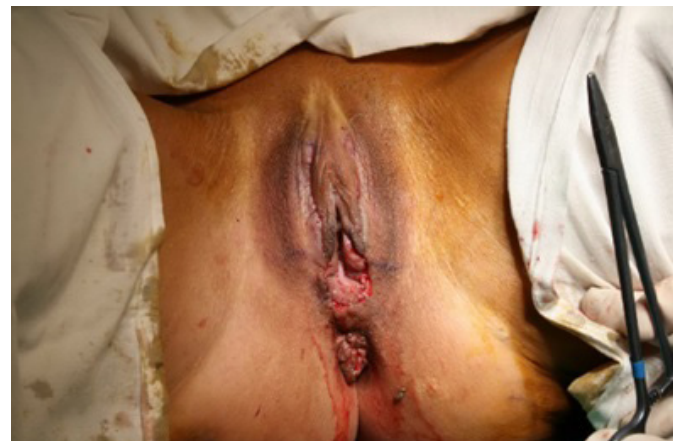

Next, any excess tissue present in the lower 1/4th of the vagina and perineum is excised in a symmetrical fashion to end up with a smooth transition from the thin labia to the lower tissues. Minimal cautery is used again for hemostasis.

The deeper tissues are then sewn together with a running stitch of 3-0 or 4-0 absorbable suture (e.g. PGA or Vicryl) from top to bottom (Figure 5). It is very important to ensure the pedicle flap is connected securely to the base tissue without creating excessive pulling or tension. In so doing, this can decrease the risk of dehiscence and separation of the tissues.



It is also important to note that the tips of the pedicles should be in symmetrical alignment with the transverse vulvar line mark that had been made preoperatively to ensure symmetry (Figure 6). The skin edges and medial edges of the flaps are then sewn with subcuticular stitches of the same suture.



Postoperative care involves daily washings with antibacterial soap and water, peribottle sprays (using diluted antibacterial liquid soap in water) after urination or BMs, ice packs for the first few days, and prophylactic antibiotics started a day before the procedure and continued for a few days. Patients were instructed to avoid intercourse for 4 to 6 weeks.

Discussion

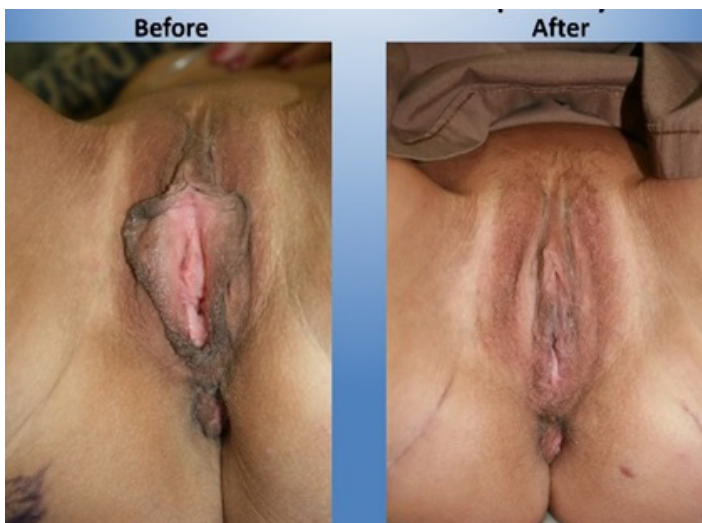There are many types of labiaplasty surgeries, each with its inherent problems. The True Labiaplasty technique attempts to

first set a goal for the characteristics of an aesthetically beautiful genital area. Then, using this concept as the end result creates a procedure that best produces this desired result.

Finding out what the patient desires of course is paramount in deciding on the technique used. There are some women who prefer to have excision of the pigmented edge of the labia, and in these women a linear type of labiaplasty may be the better surgery. Some women have minimal enlargement of the labia and no other problems, thus a deepithelialization procedure may be better for them. I believe that most women seeking labiaplasty surgery desire and prefer a more natural aesthetically beautiful look of their labia, including the surrounding tissues, and want to preserve the outer labial edges. My True Labiaplasty technique accomplishes these goals.

In the majority of cases, I believe the entire genital area should be addressed including excess tissue around the clitoris, excess prepuce tissue, and excess redundant tissue in the lower introital and perineal area. Sometimes, the clitoral hood and the labia majora also need enhancements, which are optional procedures not addressed in this article. A preservation of the natural downward fall of the frenulum and the thin labial tissues with smooth transitions of these can result in a more naturally correct and improved aesthetic appearance of the labia.

The resultant appearance of the external pelvic tissue after the True Labiaplasty thus fulfills all the criteria mentioned for a more aesthetically beautiful external pelvic area. There is less redundant tissue on either side of the clitoris. The labia are no longer excessively long and have preservation of their outer delicate edges. The labial edges maintain their natural width and pigmentations. The frenulum and labial edges drape down with a natural transition from the prepuce down to the lower tissues. Any excess tissue in the lower vaginal and perineal area is excised and heals with a very smooth result. Scars are minimal and mostly hidden in the labial folds (Figure 7).



Critiques of posterior wedge techniques such as mine have described a “pulled down” appearance of the labia with unnatural

sharp transition near the posterior fourchette [19]. In my experience, as long as excess pull-down tension is not placed upon the superior pedicle, this pulled down appearance does not occur. In addition, a more natural look can occur with the transition from pigmented labia to lesser pigmented fourchette area with this technique.

Minimal problems or complications have occurred with this technique as long as it is performed correctly. Dehiscence rarely happens, and is usually only in the lower 1/4th of the incision. I believe dehiscence can be avoided by adequately suturing the deeper tissue to the base tissue, and to make sure that no crushed tissue is left behind that can be sutured. If dehiscence happens, the area must heal first with normal wound care, and a revision may be necessary but not before 3 to 6 months of healing has occurred. Infections and hematomas are also rare and treated the same as with other procedures. I have not seen suture strictures or irritations occur with this procedure, which can cause discomfort while walking, but have been noted to happen with other techniques [20].

Most of my patients have complained of minimal pain after the procedure unlike what I have heard from the linear excision technique using cautery. Moreover, many patients have admitted to increased sensitivity of the labial tissues after the labiaplasty, especially with sensation in the preserved edges of the labia minora from this technique. The satisfaction of patients is very good.

Conclusions

Several types of labiaplasty procedures are discussed, each with their inherent problems. The preferred type per patient depends on many factors and more importantly on the patient’s desires. My modified wedge resection, the True Labiaplasty technique, as described in this article, is an improved technique for labiaplasty preserving the natural draping of the frenulum and labial tissues, ensuring symmetry, maintaining natural pigmentation, preserving the natural thin edges of the labia, enhancing sexual sensations, reducing excess labial tissues adequately and enhancing the aesthetic beauty of the genital area.

References

1. Veale D, Eshkevari E, Ellison N, et al. Psychological characteristics and motivation of women seeking labiaplasty. *Psychol Med.* 2014; 44: 555-565.
2. Miklos JR, Moore RD. Labiaplasty of the labia minora: patients’ indications for pursuing surgery. *J Sex Med.* 2008; 5: 1492-1495.
3. Sorice SC, Li AY, Canales FL, et al. Why Women Request Labiaplasty. *Plast Reconstr Surg.* 2017; 139: 856-863.
4. Zwier S. “What Motivates Her”: Motivations for Considering Labial Reduction Surgery as Recounted on Women’s Online Communities and Surgeons’ Websites. *Sex Med.* 2014; 2: 16-23.
5. Kelishadi SS, Elston JB, Rao AJ, et al. Posterior wedge resection: a more aesthetic labiaplasty. *Aesthet Surg J.* 2013; 32: 847-853.
6. Veale D, Eshkevari E, Ellison N, et al. Psychological characteristics and motivation of women seeking labiaplasty.

-
- Psychol Med. 2014; 44: 555-565.
7. Miklos JR, Moore RD. Labiaplasty of the labia minora: patients' indications for pursuing surgery. *J Sex Med.* 2008; 5: 1492-1495.
 8. Sandra Zwier. "What Motivates Her": Motivations for Considering Labial Reduction Surgery as Recounted on Women's Online Communities and Surgeons' Websites. *Sex Med.* 2014; 2: 16-23.
 9. <http://www.smh.com.au/national/health/labiaplasty-like-female-genital-mutilation-doctors-not-upselling-to-more-invasive-surgery-and-not-informing-patients-of-what-is-normal-20150828-gjacjt.html>
 10. Goodman MP. Female cosmetic genital surgery. *Obstet Gynecol.* 2009; 113: 154-159
 11. Hunter JG, Labia Minora, Labia Majora. and Clitoral Hood Alteration: Experience-Based Recommendations. *Aesthet Surg J.* 2016; 36: 71-79.
 12. Goodman MP, Placik OJ, Benson RH, et al. A large multicenter outcome study of female genital plastic surgery. *J Sex Med.* 2010; 7: 1565-1577.
 13. Cao YJ. A modified method of labia minora reduction: the de-epithelialized reduction of the central and posterior labia minora. *J Plast Reconstr Aesthet Surg.* 2012; 65: 1096-1102.
 14. Benadiba L. Labiaplasty: plastic or cosmetic surgery? Indications, techniques, results and complications. *Ann Chir Plast Esthet.* 2010; 55: 147-152.
 15. Alter GJ. Labia minora reconstruction using clitoral hood flaps, wedge excisions, and YV advancement flaps. *Plast REconstr Surg.* 2011; 127: 2356-2363.
 16. Ellsworth WA, Rizvi M, Lypka M, et al. Techniques for labia minora reduction: an algorithmic approach. *Aesthetic Plast Surg.* 2010; 34: 105-110.
 17. Giraldo F, González C, de Haro F. Central wedge nympectomy with a 90-degree Z-plasty for aesthetic reduction of the labia minora. *Plast Reconstr Surg.* 2004; 113: 1820-1825.
 18. Kelishadi SS, Elston JB, Rao AJ, et al. Posterior wedge resection: a more aesthetic labiaplasty. *Aesthet Surg J.* 2013; 32: 847-853.
 19. Munhoz AM, Filassi JR, Ricci MD, et al. Aesthetic labia minora reduction with inferior wedge resection and superior pedicle flap reconstruction. *Plast Reconstr Surg.* 2006; 118: 1237-1247.
 20. Mass SM, Hage JJ. Functional and aesthetic labia minora reduction. *Plast Reconstr Surg.* 2000; 105: 1453-1456.