

TOTAL REGRESSION OF BILATERAL OVARIAN ENDOMETRIOTIC CYSTS UNDER ULIPRISTAL ACETATE THERAPY DURING 3 MONTH, A CASE REPORT

Vesna Harni^{1}, MD, Damir Babic², MD, PhD*

¹Gynecological Clinic Dr. Vesna Harni, Zagreb

²University Department of Obstetrics and Gynecology, Zagreb

Case Report

Keywords: ulipristal acetate, ovarian endometrioma, endometriotic cyst, endometriosis

ABSTRACT

Rationale for this case report. Following the CARE guidelines for publishing case reports, here is described a successful drug treatment of a symptomatic patient with large endometriotic cysts on both ovaries, which completely disappeared after 3 months of therapy with ulipristal acetate. **Presenting concerns of the patient.** A 21-year old patient scheduled a gynaecological exam due to nausea and vomiting, as well as abdominal pain during ovulation and dyspareunia. She was previously diagnosed with bilateral ovarian endometriotic cysts, almost 7 cm in diameter, which was followed by a recommendation for surgery. The patient wanted second opinion regarding the medical treatment. **Diagnosis.** Bilateral ovarian endometriotic cysts. **Interventions.** Ulipristal acetate (UPA) was recommended, in the same manner as in the treatment of uterine fibroids ("off label use"): two cycles of UPA at a dose of 5 mg daily during 3 months, with a month-long break between two cycles. **Outcomes.** After the first cycle of UPA (3 packs of Esmya® 5 mg tablet) the patient was asymptomatic. Palpatory pelvic exam was normal and transvaginal ultrasound showed total regression of both endometriotic cysts. **Main lessons learned from this case.** The history of this case reveals the necessity of rethinking the approach to therapy every single time when facing endometriosis and the need for the full cooperation of the patient in making treatment decisions.

* Corresponding address: Vesna Harni, MD, Ginekološka poliklinika Dr. Vesna Harni, Bukovacka 1, HR-10000 Zagreb, Croatia. e-mail: vesna.harni@zg.t-com.hr

INTRODUCTION

Endometriosis is a benign gynaecological disease characterised by the presence of functional endometrial tissue fragments growing outside the uterine cavity, most frequently on the peritoneum, the ovaries, and the bowel, which induces a chronic, inflammatory reaction, predominantly in women of reproductive age, from all ethnic and social groups [1]. The exact prevalence of endometriosis is unknown, however, estimates range from 2 to 10% within the general female population, but up to 50% in infertile women [2–3].

The diagnosis of endometriosis is first suspected based on the history, the symptoms and signs, then corroborated by physical examination and imaging techniques and, finally, proven by the histological examination of specimens collected during laparoscopy. The combination of laparoscopy and the histological verification of endometrial glands and/or stroma is considered to be the "gold standard" for the diagnosis of the disease [4]. Based on the recently published ultrasound characteristics of ovarian endometrioma, ESHRE recommends that ovarian endometrioma can be diagnosed and excluded by transvaginal sonography (TVS) [4–5].

Endometriosis is considered a predominantly estrogen-dependent disease. Thus, hormonal suppression might be an attractive medical approach to treat the disease and its symptoms. Currently, hormonal contraceptives, progestogens, anti-progestogens, GnRH agonists and aromatase inhibitors are in clinical use. Data on selective estrogen receptor modulators (SERMs) and selective progesterone receptor modulators (SPRMs) was also retrieved and assessed [4].

SPRMs are associated with an increase in estrogen receptors, progesterone receptors and androgen receptors. The beneficial effects of the treatment with SPRMs are probably related to their antiproliferative effects and suppression of vascular endothelial growth factor (VEGF), which have been well described in the primate endometrium [6]. For all these reasons, SPRMs could represent a new and promising therapeutic option for endometriosis. Ulipristal acetate (UPA) derives from 19-norprogesterone and is an antagonistic, partial agonistic, progesterone receptor modulator, currently registered for emergency contraception and treatment of uterine fibroids. UPA has potential clinical applications for the treatment of endometriosis, cervical ripening for induction of labour and the treatment of breast cancer and gliomas [7–8].

This report, written in line with the CARE guidelines for publishing a case report (9), talks about a successful treatment of a symptomatic patient with endometriotic cysts on both ovaries, which completely disappeared after 3 months of therapy with UPA.

PRESENTING CONCERNS

A 21-year old patient came to Poliklinika Harni on April 29, 2015 for a gynaecological exam due to nausea and vomiting, as well as abdominal pain during ovulation and dyspareunia, which she had suffered from December 2014.

The patient was asymptomatic until a gynaecological examination in a private gynaecological practice on December 19, 2014, which revealed an endometriotic cyst of 49x38 mm on the right ovary and an endometriotic cyst of 59x46 mm on the left ovary. After this, the patient became symptomatic, but no therapy was prescribed.

Gynaecological check-up was done on April 24, 2015 in the same practice. At this point, ultrasound exam showed an endometriotic cyst of 82x75 mm on the right ovary and endometriotic cysts of 53x39 plus 26x23 mm on the left ovary. Thereupon, surgery was recommended.

The patient wanted second opinion regarding the medical treatment.

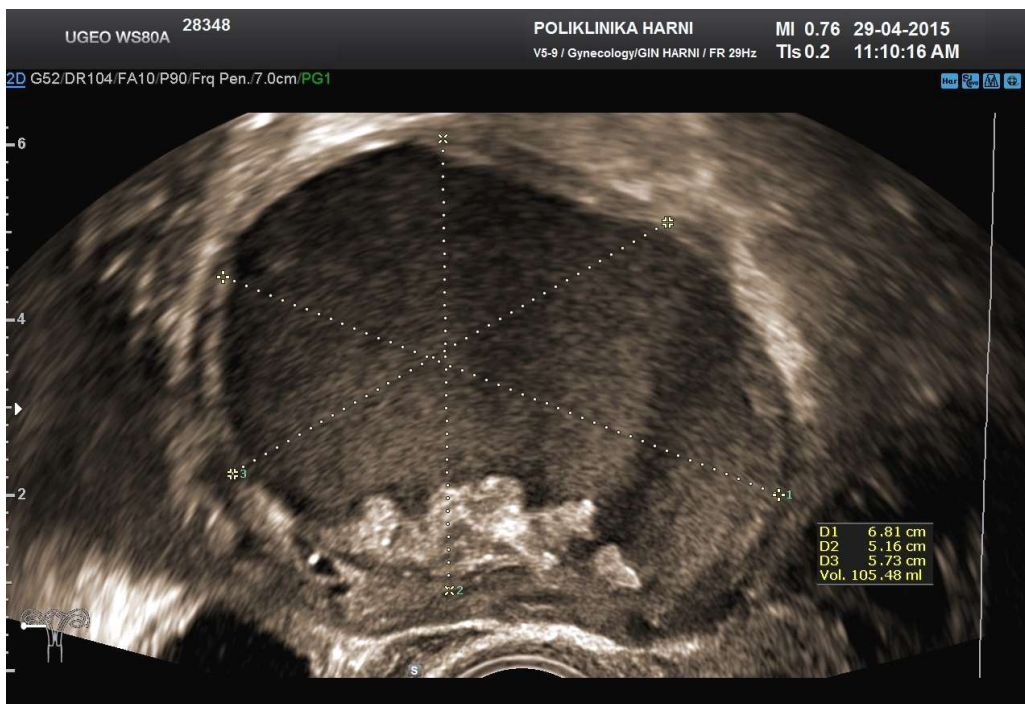


Figure 1. Endometriotic cyst on the right ovary. Almost round hypoechoic, homogeneous formation of 68x57x51 mm (V = 105.4 ml) on the right ovary. Basal hyperechoic echoes without vascular flow.

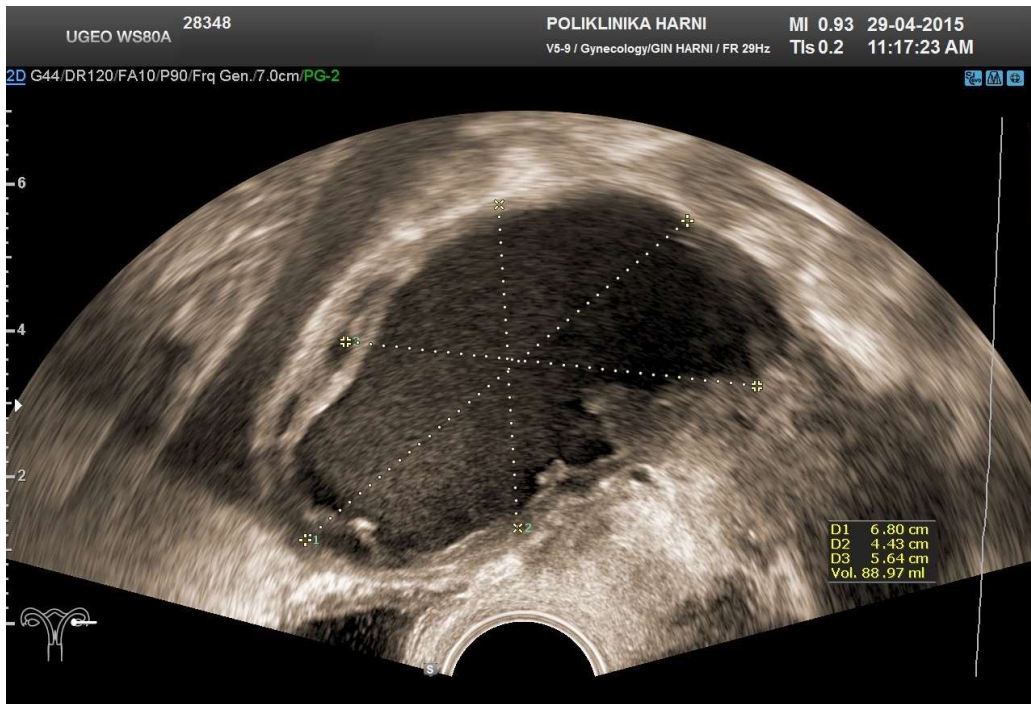


Figure 2. Endometriotic cyst on the left ovary. Oval hypoechoic, homogeneous formation of 68x56x43 mm (V=88.9 ml) on the left ovary. Hyperechoic echoes without vascular flow on the lateral wall.

PATIENT INFORMATION

The patient was born on June 20, 1994, and at the age of three she underwent tonsillectomy. As a child she had chickenpox.

Menarche occurred at the age of 9. Menstrual cycles were regular, between 30 and 31 days with 6–7 days of bleeding. Occasionally, she had less intense dysmenorrhoea on the first day of bleeding.

During 2011, she was treated for infectious mononucleosis.

The first gynaecological exam was performed on August 24, 2011, the results were normal.

Her grandparents have had type II diabetes, her mother had uterine fibroid and thyroid problems.

CLINICAL FINDING

Pelvic exam and transvaginal ultrasound were performed on April 29, 2015 in Poliklinika Harni.

By previously published ultrasound characteristics of ovarian endometrioma, the patient was diagnosed with an endometriotic cyst of 68x57x51 mm ($V = 105.4$ ml) on the right ovary [Figure 1] and an endometriotic cysts of 68x56x43 mm ($V = 88.9$ ml) on the left ovary [Figure 2].

TIMELINE

Based on the history, it was assumed that the disease started at some point between 2011 and 2014 [Figure 3].

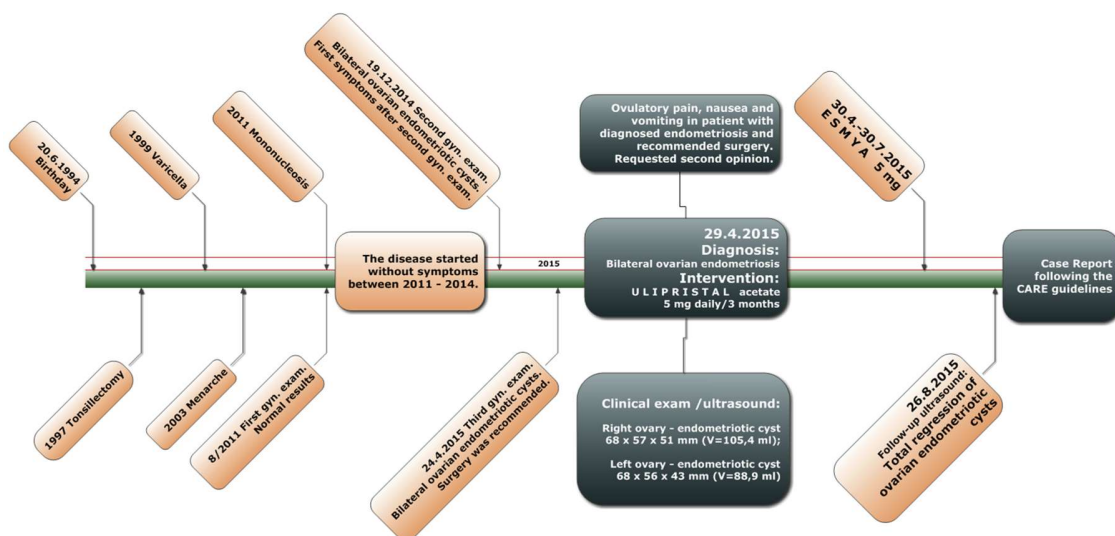


Figure 3. Timeline. Based on the history, it was assumed that the disease started at some point between 2011 – 2014.

DIAGNOSTIC ASSESSMENT

Although laparoscopy is the "gold standard" for the diagnosis of primarily deep pelvic and rectal endometriosis, in this case the characteristic ultrasound finding of large hypoechogenic, homogeneous cystic ovarian tumours was sufficiently reliable to confirm the previous diagnosis of bilateral ovarian endometriosis.

Women with endometriosis are confronted with one or both of two major problems: endometriosis-associated pain and infertility. Surgical treatment has long been an important part of the management of endometriosis in women with ovarian endometriotic cysts (≥ 3 cm) with regard to the recurrence of endometriosis-associated pain and the recurrence of endometrioma [4]. Therefore, and especially because of the possibility of torsion of large endometriotic cysts, surgical treatment was also recommended at our institution, as the best option for the patient's treatment.

THERAPEUTIC INTERVENTION

Ulipristal acetate has proved to be a good alternative treatment of uterine fibroids, which are estrogen-dependent tumours as well as ovarian endometriotic cysts, but a successful treatment of the ovarian endometriosis with UPA was not known to the authors. Since the patient had insisted on conservative treatment, she was informed about the possibilities, limitations and side effects, and realistic expectations from the treatment with UPA, which she fully accepted.

The therapy was planned in the same manner as in the treatment of uterine fibroids with ulipristal acetate: two cycles of UPA at a dose of 5 mg once a day during 3 months, with a month-long break between two cycles (10). In order to control and monitor side effects, the patient was asked to come for a check-up after taking the first three packs of tablets, in between two cycles of taking the pills. Additionally, the patient was recommended a diet free of red meat and a moderate-paced walk, while the exercise was banned because of the size of the cysts and the possibility of complications.

The first treatment cycle was conducted from April 30 to July 30, 2015.

FOLLOW-UP AND OUTCOMES

Gynaecological check-up and ultrasound examination were performed on August 26, 2015, after the first cycle of taking UPA (3 packs of Esmya® 5 mg tablets). The patient stated that she did not have any symptoms. She tolerated the therapy well, without side effects. During the treatment she was amenorrhoeic.

Palpatory finding was normal and transvaginal ultrasound unexpectedly revealed the total regression of both endometriotic cysts [Figure 4 and 5].

After the endometriotic cysts on both ovaries had regressed, further therapy with ulipristal acetate was not necessary. In consultation with the patient, a low-dose oral contraceptive pill was prescribed for the next six months to suppress ovulation.

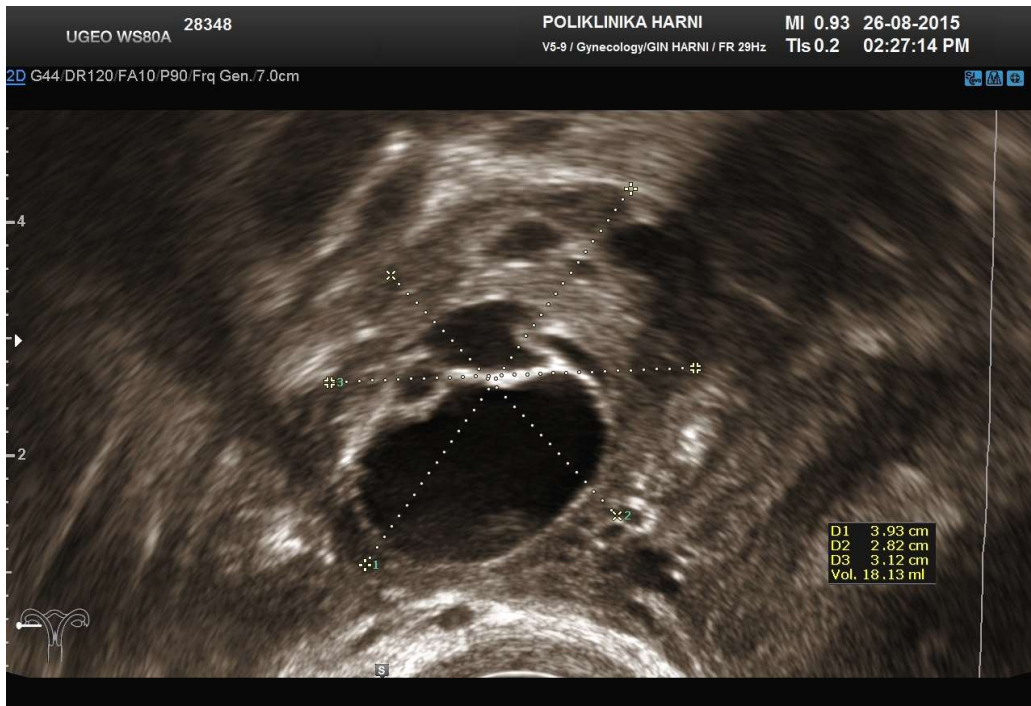


Figure 4. Right ovary after a 3-month therapy with ulipristal acetate. Complete regression of the endometriotic cyst on the right ovary. Ovarian size 39x31x28 mm (V=18,1 ml), with dominant follicle 19x18 mm.

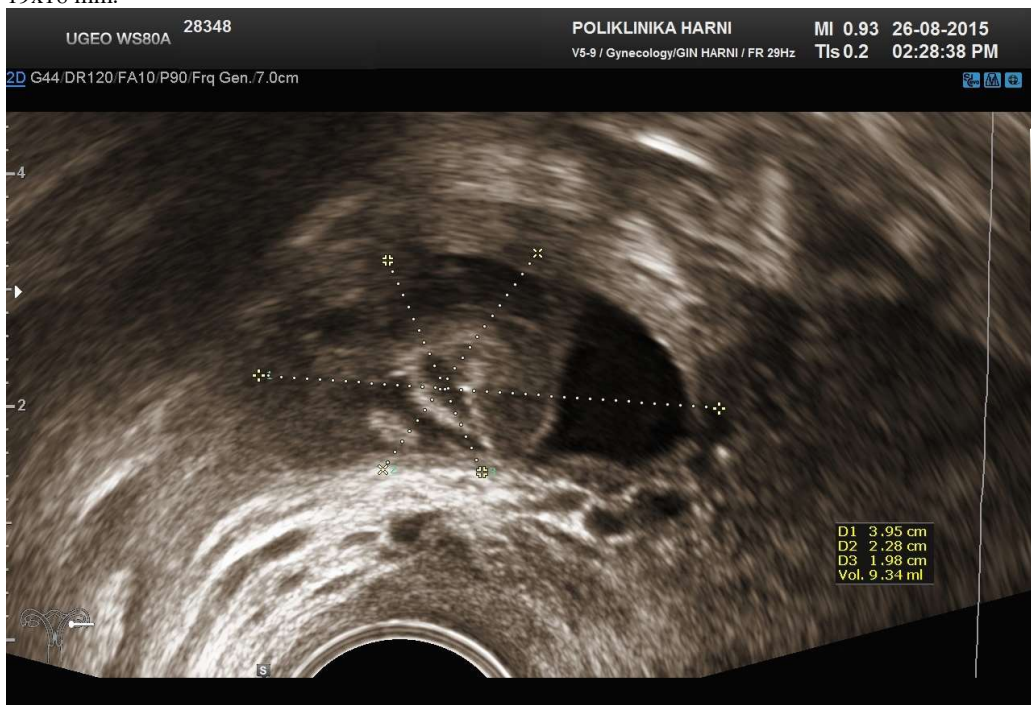

Figure 5. Left ovary after a 3-month therapy with ulipristal acetate. Complete regression of the endometriotic cyst on the left ovary. Ovarian size 39x22x19 mm (V=9,3 ml).

DISCUSSION

This case report describes the unexpected result of the drug treatment of bilateral ovarian endometriosis with ulipristal acetate. Surprisingly, after a 3-month cycle of using the UPA at a dose of 5 mg daily, there was a complete, bilateral regression of two large ovarian endometriotic cysts, of almost 7 cm in diameter.

Endometriosis is a chronic disease, characterised by the proliferation of endometrial glands and stroma outside the uterine cavity. Current treatment modalities, including both surgical removal of endometriotic lesions and hormonal suppression of estrogen, are associated with significant morbidity, side effects and recurrence rates. In addition, the indications for the treatment of endometriosis are related only to symptomatic and infertile patients. Therefore, novel therapeutic approaches are still required.

Asoprisnil is the first SPRM to reach an advanced stage of clinical development for the treatment of symptomatic uterine fibroids and endometriosis [11]. In human subjects with uterine fibroids, asoprisnil suppressed both the duration and intensity of uterine bleeding in a dose-dependent manner and reduced tumour volume in the absence of estrogen deprivation. In subjects with endometriosis, asoprisnil was effective in reducing nonmenstrual pain and dysmenorrhoea. Therefore, asoprisnil was considered as a promising, tissue-selective approach to control endometriosis-related pain, and SPRMs as the potential treatment of uterine fibroids and endometriosis [11-12].

Ulipristal acetate is an orally active SPRM characterised by a tissue-specific, partial progesterone antagonist effect. On April 23, 2015, the European Commission has approved ulipristal acetate (Esmya® 5 mg tablet) for the intermittent use in the long-term management of uterine fibroids, based on the results of the PEARL III study and its extension. The study results showed that one repeated course of UPA delivers continued efficacy for women. Amenorrhoea rates were 79.5% and 88.5% for the women after the first and second treatment courses respectively. Median percentage change from screening in fibroid volume reduction were 49.9% and 63.2% after the first and second treatment courses respectively [10].

"Off label" use of drugs is not popular, and there are hidden dangers. But, the persistence of the young patient, who had not accepted surgery, and her huge desire for drug treatment, forced the author to prescribe a drug designed to treat uterine fibroids, for the treatment of endometriosis. The patient was taking medicine conscientiously with a lot of expectations, not knowing what effects to expect.

The history of this case, when looking at the incidence of endometriosis, especially among young patients, as well as a devastating impact on fertility, reveals the necessity of rethinking the therapy every single time when faced with endometriosis and the need for the full cooperation of the patient in making treatment decisions.

It is important to recognize that a woman is able to make informed choices based on a good understanding of what is happening to her body and that the decisions in any treatment plan should be individual.

PATIENT PERSPECTIVE

"I took Esmya® regularly. It only happened three times that I did not take the medicine on time because I fell asleep or I was not home and had forgotten to bring the tablet with me. In those cases I would follow the instructions about taking the medicine and took it if I did not miss more than 12 hours, as it was stated. I had a light red discharge after intercourse only twice. Except for that, I did not notice any other side effects and I felt great while taking the medicine. I did not have any pain. The current menstrual bleeding is a little lighter, but there is nothing unusual about it. I feel the same as during any other menstrual bleeding, and emotions are a bit more intense. I had slight pain on the second or third day of the period. I eat normally, and that's it. I hope, my experience will help many women and I wish you good luck with that. Thank you once again for your help."

INFORMED CONSENT

The patient provided informed consent for this case report.

DECLARATION OF AUTHORSHIP

VH: participation in study design, execution, analysis, manuscript drafting and critical discussion. DB: participation in study design, analysis and critical discussion.

AUTHOR DISCLOSURE

Nothing to disclose.

PUBLISHABLE CONFLICT OF INTEREST STATEMENT

No conflict of interest.

REFERENCES

- [1] Kennedy S, Bergqvist A, Chapron C, D'Hooghe T, Dunselman G, Greb R et al. ESHRE guideline for the diagnosis and treatment of endometriosis. *Hum Reprod* 2005; 20:2698–2704.
- [2] Eskenazi B and Warner ML. Epidemiology of endometriosis. *Obstet Gynecol Clin North Am* 1997; 24:235–258.
- [3] Meuleman C, Vandenabeele B, Fieuws S, Spiessens C, Timmerman D and D'Hooghe T. High prevalence of endometriosis in infertile women with normal ovulation and normospermic partners. *Fertil Steril* 2009; 92:68–74.
- [4] Dunselman GA, Vermeulen N, Becker C, Calhaz-Jorge C, D'Hooghe T, De Bie B et al. ESHRE guideline: management of women with endometriosis. *Hum Reprod*. 2014; 29(3):400–12. doi: 10.1093/humrep/det457.
- [5] Van Holsbeke C, Van Calster B, Guerriero S, Savelli L, Paladini D, Lissoni AA et al. Endometriomas: their ultrasound characteristics. *Ultrasound Obstet Gynecol* 2010; 35:730–740.
- [6] Greb RR, Heikinheimo O, Williams RF, Hodgen GD, Goodman AL. Vascular endothelial growth factor in primate endometrium is regulated by estrogen-receptor and progesterone receptor ligands in vivo. *Hum Reprod* 1997; 12(6):1280–92.
- [7] Bliithe DL, Nieman LK, Blye RP, Stratton P, Passaro M. Development of the selective progesterone receptor modulator CDB-2914 for clinical indications. *Steroids*. 2003; 68:1013–17.
- [8] Gainer E, Ulmann A. Pharmacologic properties of CDB (VA)–2914. *Steroids*. 2003; 68:1005–11.
- [9] Gagnier JJ, Kienle G, Altman DG, Moher D, Sox H, Riley DS and the CARE group. The CARE guidelines: consensus-based clinical case report guideline development. *J Clin Epidemiol* 2014; 67(1):46–51.
- [10] Donnez J, Hudecek R, Donnez O, Matule D, Arhendt HJ, Zatik J et al. Efficacy and safety of repeated use of ulipristal acetate in uterine fibroids. *Fertil Steril*. 2015;103(2):519–27.e3. doi: 10.1016/j.fertnstert.2014.10.038.
- [11] Chwalisz K, Mattia-Goldberg K, Lee M, Elger W, Edmonds A. Treatment of endometriosis with the novel selective progesterone receptor modulator (SPRM) asoprisnil. *Fertil Steril* 2004; 82:S83 (Abstract O–207)
- [12] Chwalisz K, Perez MC, DeManno D, Winkel C, Schubert G, Elger W. Selective Progesterone Receptor Modulator Development and Use in the Treatment of Leiomyomata and Endometriosis. *Endocrine Reviews* 2005; 26(3):423–438
- [13] *Tract. Dis.* 2012; 16 (2):88-91.

POTPUNA REGRESIJA ENDOMETRIOTIČNIH CISTA OBA JAJNIKA NAKON 3-MJESEČNE TERAPIJE S ULIPRISTAL ACETATOM, PRIKAZ SLUČAJA

VESNA HARNI, DAMIR BABIĆ

Prikaz slučaja

KLJUČNE RIJEČI: ulipristal acetat, endometriom jajnika, endometriotična cista, endometrioza

SAŽETAK. Razlog za prikaz slučaja. Sukladno "CARE" smjernicama za objavljivanje prikaza slučaja, opisali smo uspješno medikamentozno liječenje simptomatske pacijentice s velikim endometriotičnim cistama oba jajnika, koje su se u potpunosti povukle nakon 3-mjesečne terapije s ulipristal acetatom. **Aktualne tegobe pacijenta.** 21-godišnja pacijentica zakazala je ginekološki pregled zbog mučnine i povraćanja te bolova u trbuhu za vrijeme ovulacije, kao i disporeunije. Pacijentica navodi da je ranije postavljena dijagnoza endometrioze te da su na oba jajnika dijagnosticirane endometriotičke ciste promjera gotovo 7 cm, nakon čega joj je preporučen operativni zahvat. Pacijentica dolazi za drugo mišljenje u vezi liječenja. **Dijagnoza.** Bilateralna ovarijska endometrioza. **Intervencija.** Oralna terapija ulipristal acetatom (UPA), na isti način kao u liječenju mioma maternice ("off label use"): dva ciklusa UPA u dozi od 5 mg dnevno tijekom 3 mjeseca, s pauzom od mjesec dana između dva ciklusa. **Ishod.** Nakon prvog ciklusa UPA (3 pakiranja tableta Esmya® 5 mg) pacijentica nije imala tegobe. Palpacijski pregled zdjelice bio je normalan, a transvaginalni ultrazvuk je pokazao potpunu regresiju obje endometriotičke ciste. **Glavne pouke iz ovog slučaja.** Tijek opisanog slučaja otkriva nužnost promišljanja liječenja endometrioze kod svake pojedinačne pacijentice, kao i potrebu pune suradnje pacijenta u donošenju odluke o liječenju.