

¹ Poliklinika Harni, Bukovacka 1, HR-10000 Zagreb,

² University Department of Obstetrics and Gynecology, Petrova 13, HR-10000 Zagreb,

³ Department of Obstetrics and Gynecology Villach, Nikolaigasse 43, A-9500 Villach

”THREE RINGS VULVOSCOPY” – A NEW APPROACH TO THE VULVA

Vesna Harni¹, Damir Babic², Dubravko Barisic³

Professional paper

Keywords: vulvoscopy; three vulvar rings; vulvar diseases; vulvar dermatosis; vulvodynia; impaired vulvar skin

SUMMARY. Objective. To test a new approach to vulvar discomfort adapted to vulvar anatomy and specificity of vulvar lesions. **Methods.** In a retrospective observational study, we analyzed the results of the original vulvoscopy technique called ”Three Rings Vulvoscopy”, in a total of 216 gynecological patients with or without vulvar discomfort, in which colposcopic changes of the vulva were documented according to their specificity and localization using ISSVD Vulvodynia Pattern Questionnaire. **Results.** Analysis of vulvoscopy results revealed four groups of respondents: asymptomatic patients without vulvoscopy findings and asymptomatic patients with non-specific lesions; symptomatic patients with non-specific lesions and symptomatic patients with specific vulvoscopy findings. Absence of any vulvar complaints and vulvoscopy findings in all three vulvar rings were found in the patients with a ”normal vulva”. Vulvar discomfort with a significantly frequent presence of both, specific and non-specific lesions, in all three vulvar rings were found in the patients with ”vulvar dermatosis”. Absence of specific lesions in any of the vulvar rings and a significantly higher incidence of non-specific lesions in the inner vulvar ring (non-relevant to the diagnosis of vulvodynia), were common characteristics of patients with vulvodynia and impaired vulvar skin. The fundamental difference between these subjects was the presence of vulvar complaints in patients with vulvodynia. There weren’t diagnosed symptomatic patients without any vulvoscopy lesion in all three vulvar rings or asymptomatic patients with specific lesion in any of the vulvar rings. **Conclusion.** ”Three Rings Vulvoscopy”, with the assessment of the specificity of vulvar lesions, seems to be promising in the differential diagnosis of vulvar discomfort. The new vulvoscopy technique is being proposed in order to encourage others to adopt it and prove it in clinical practice.

Introduction

The definition of vulvology as a new multidisciplinary competence has led to developing a new philosophy in approaching vulvar diseases, considering the vulva as a complex organ, both histologically and embryologically.

The mons pubis, labia majora and the perineum are composed of hair-bearing, keratinised skin containing sebaceous, apocrine and eccrine glands, subcutaneous fat and blood vessels. The epidermis of the vulvar skin is developed from ectoderm.¹

The anterior commissure, prepuce and frenulum of the clitoris, interlabial sulci, labia minora and the fourchette are covered with non-hair-bearing skin, but the only appendages found are sebaceous glands, without subcutaneous fat. The epithelium of these structures is of ectodermal origin. The underlying tissue is developed from mesoderm.

The vestibule is squamous mucosa composed of non-keratinised, non-pigmented stratified squamous epithelium, with a complete absence of skin appendages. It is of endodermal origin, except for a small area immediately anterior to the urethra, which is of ectodermal origin.^{2,3} The junction of the epithelium derived from endoderm and the one derived from ectoderm is seen in adults on the inner aspects of the labia minora, marked

by the junction of keratinised with non-keratinised epithelium. This line of demarcation is referred to as the vestibular line of Hart.

The abnormal findings in accordance with the vulvar terminology defined by the International Society for Study of Vulvovaginal Disease (ISSVD) and the International Federation for Cervical Pathology and Colposcopy (IFCPC) from 2011, include various variables that characterize each lesion by its size, location, type, color and secondary morphology according to dermatological criteria.^{4,5} Implementation of these recommendations in daily practice results in further efforts to assess and plan the treatment of vulvar lesions.

Vulvodynia remains a separate problem, defined as vulvar discomfort, most often described as burning pain, occurring in the absence of relevant visible finding or a specific neurological disorder, which is diagnosed using Friedrich’s criteria and ”per exclusion”.⁶⁻⁹

In the attempt to colposcopically examine the vulva, it is essential to know the histology of vulvar skin since the general appearance of lesions largely depends on the underlying tissue structure. Given the complex histology and embryology of the vulva, a question was asked whether using a new concept of vulvoscopy, adapted to the vulvar anatomy, may play a role in a better understanding and differential diagnosis of vulvar discomfort.

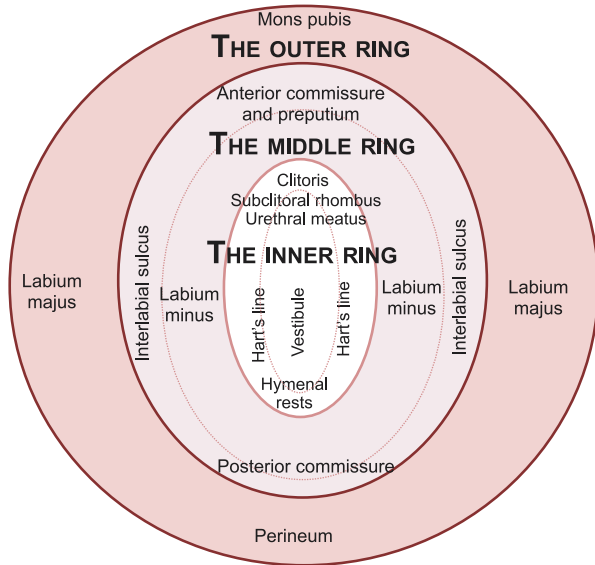


Figure 1. The three vulvar rings: outer, middle and inner vulvar ring

The three vulvar rings were described according to histological and embryonic nature of the vulva. "The outer vulvar ring" includes vulvar skin: the mons pubis, labia majora and the perineum. "The middle vulvar ring" encompasses the modified mucosa: the anterior commissure, prepuce and frenulum of the clitoris, interlabial sulci, labia minora and the posterior commissure (fourchette). "The inner vulvar ring" is presented with glycogenated squamous mucosa of the non-keratinised type: the clitoris, subclitoral rhombus, urethral meatus, hymenal remains, Bartholin's gland opening, Hart's line and the vestibule.

Methods and patients

In order to ensure a more accurate and systematic mapping of vulvar lesions, a new vulvoscopy technique was proposed, taking into account three different skin types and zones that are almost ring-shaped. Instead of a random or linear vulvoscopy, this is a circular purposeful observation of the vulva, hereinafter called "Three Rings Vulvoscopy" (Figure 1). The three vulvar rings – outer, middle and inner vulvar ring were described according to the histology and embryology of the vulva.

"The outer vulvar ring" includes the vulvar skin developed from the ectoderm, and it is composed of hair-bearing, keratinised skin containing sebaceous, apocrine and eccrine glands, subcutaneous fat and blood vessels, which make a natural outer boundary of the vulva. This includes the mons pubis, labia majora and the perineum.

"The middle vulvar ring" encompasses the modified mucosa of ectodermal origin, which makes an intermediate circuit between the labia majora and vestibule. It is covered with non-hair-bearing skin, but the only appendages found are sebaceous glands, without subcutaneous fat. This includes the anterior commissure, prepuce and frenulum of the clitoris, interlabial sulci, labia minora and the fourchette.

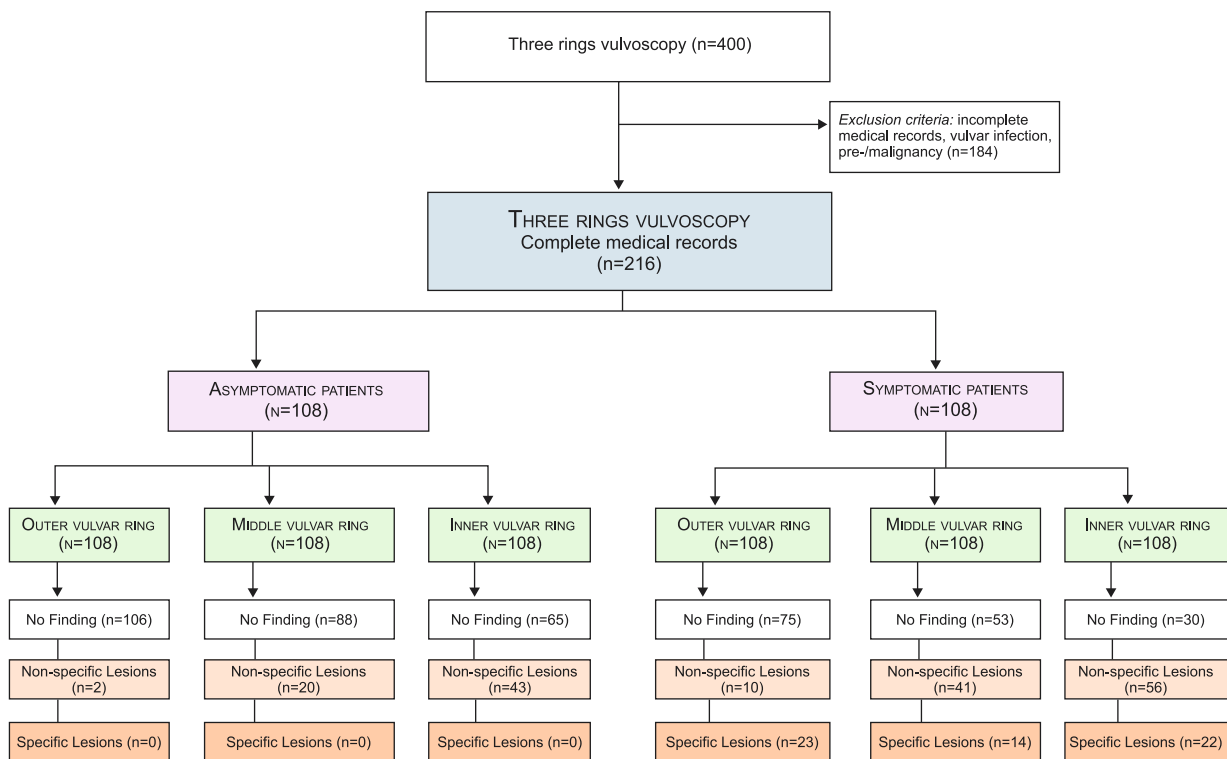


Figure 2. Flow diagram

"Three Rings Vulvoscopy" was performed in 400 consecutive patients, after exclusion of 184 patients with incomplete medical records, vulvar infection, benign tumors and pre-/malignancy; we analyzed the symptoms, specificity and localization of the vulvoscopy lesions related to the three vulvar rings in a total of 108 patients with vulvar discomfort and 108 asymptomatic patients.

"The inner vulvar ring" is glycogenated squamous mucosa of non-keratinised type, non-pigmented stratified squamous epithelium with a complete absence of skin appendages, which is of endodermal origin. This includes the clitoris, sub-clitoral rhombus (sulcus urethralis), urethral meatus, hymenal remains, Bartholin's gland opening, Hart's line and the vestibule. The demarcation line between the inner and middle ring is represented by the junction of keratinised with non-keratinised epithelium on the inner aspects of the labia minora, which is known as Hart's line.

The lower genital tract, in addition to the vulva, includes groins, perianal region and the anus. The skin of the groin and perianal region is composed of the same tissue as the skin of the outer ring of the vulva and the lesions may be examined together with the lesion of the outer ring of the vulva. Endoscopy or colposcopy of the anus is commonly known as "anoscopy".

In a retrospective observational study we investigated the results of the "Three Rings Vulvoscopy", which was performed in Poliklinika Harni, Zagreb (Croatia), in 400 consecutive patients, during the period between January 1, 2012, and June 30, 2014. Vulvar discomfort and vulvoscopy results were mapped according to the ISSVD Vulvodinia Pattern Questionnaire.¹⁰ In addition to the vulvoscopy, cotton-swab test, inspection of the vagina, vaginal pH measurement and microscopy of vaginal discharge were done in all patients.

After exclusion of 184 patients with incomplete medical records, vulvar infection, benign tumors and pre-/malignancy; we retrospectively analyzed the data from the ISSVD Vulvodinia Pattern Questionnaire – symptoms, specificity and localization of the vulvoscopy lesions related to the three vulvar rings in a total of 108 patients with vulvar discomfort and 108 asymptomatic patients, as shown in flow diagram (Figure 2).

Symptoms that indicated the disease of the vulva included burning, stinging, soreness, irritation, feeling as if being cut with a knife or paper, stabbing, sticking, itching, inflammation and pain.¹⁰ Diagnosis of vulvar dermatosis was confirmed by the Keyes punch biopsy and histopathological diagnosis. Diagnosis of vulvodinia was based on medical history data with the determination of the index of dyspareunia, and clinical examination where signs of vulvar specific disease ("diagnosis per exclusion") were absent, in combination with positive cotton swab test according to the actual guidelines.^{6–9}

Based on the specificity of vulvoscopy findings, patients were divided into the group with specific lesions and patients with non-specific vulvoscopy findings.

"Specific lesions" were defined as the finding of eczematous inflammation with thickened, excoriated skin in lichen simplex chronicus; hypopigmented or white lesions, fusion or resorption of the labia minora and clitoral hood, loss of vulvar architecture and sclerotic changes in lichen sclerosis; white reticular pattern to extensive erosion with agglutination or resorption of the labia in lichen planus and psoriatic erythematous pap-

ules with silver, scaly plaques.¹¹ The diagnosis of vulvar dermatosis was confirmed histopathologically in all patient with specific lesions (n=33).

"Non-specific findings" included non-specific erythema in the absence of infection in any part of the vulva; punctuations and papillae in the area of labia minora, Hart's line and the vestibule; the paleness and smoothness of the sub-clitoral rhombus and the vestibule and excoriations in the absence of vulvar dermatosis.^{11–12} A Keyes punch biopsy was done in 21 patients with non-specific vulvoscopy findings.

Asymptomatic patients without visible vulvoscopy changes were labeled as patients with a "normal vulva". As the previous data suggest the importance of maintaining the integrity of the barrier function of the skin to prevent the activation of inflammatory mediators on exogenous or endogenous path and psychological stress,¹³ we assumed that these mechanisms may play a role in the occurrence of non-specific lesions in asymptomatic patients and named this group "impaired vulvar skin".

Table 1. Distribution of patients depending on the symptoms and vulvoscopy findings.

		Specificity of vulvoscopy lesions	
		A/ Specific findings (n=33)	B/ Non-specific findings (n=75)
Vulvar symptoms	Symptomatic patients (n=108)	Vulvar dermatosis: 5 Lichen simplex chronicus, 23 Lichen sclerosis, 3 Lichen planus, 1 Dermatitis psoriasisiformis 1 Pemphigus familiaris	Vulvodinia*
	Asymptomatic patients (n=108)	A/ Normal findings (n=54)	B/ Non-specific findings (n=54)
		Normal vulva	Impaired vulvar skin

* = Non-specific findings in these patients were not relevant for the diagnosis of vulvodinia.

Table 2. Demographic data.

	Asymptomatic patients (n=108)		Symptomatic patients (n=108)	
	Control group	Impaired vulvar skin	Vulvodinia	Vulvar dermatosis
Age ± SD	34.1 ± 9.1	35.7 ± 8.3	35.7 ± 7.4	44.0 ± 16.5
Reproductive age	94.4%	98.2%	96.0%	72.7%
Country of birth Croatia	75.9%	72.2%	82.7%	75.8%
High education	44.4%	53.7%	54.7%	36.36%
Married	23.2%	22.3%	33.0%	21.43%
Parity ± SD	0.85 ± 1.17	0.70 ± 1.00	0.80 ± 0.97	1.24 ± 0.96
Nuliparity	53.8%	62.9%	53.3%	21.88%
Abortion ± SD	0.16 ± 0.46	0.12 ± 0.43	0.17 ± 0.52	0.51 ± 0.83

Table 3. Vulvoscopy findings in the outer vulvar ring.

	Control group	Impaired vulvar skin	Vulvodynia	Vulvar dermatosis
THE OUTER RING				
All findings	0%	3.7%	13.3%	93.9%**
mons pubis				
All findings	0%	0%	1.3%	39.4%**
Erythema	0%	0%	1.3%	6.0%
Excoriations and sores	0%	0%	0%	12.1%**
Other lesions (specific to dermatosis)	0%	0%	0%	21.2%**
Labia majora				
All findings	0%	0%	4.0%	69.7%**
Erythema	0%	0%	4.0%	33.3%**
Excoriations and sores	0%	0%	0%	33.3%**
Other lesions (specific to dermatosis)	0%	0%	0%	48.5%**
perineum				
All findings	0%	3.7%	13.3%	69.2%**
Erythema	0%	3.7%	13.3%	69.2%**
Excoriations and sores	0%	0%	2.7%	33.3%**
Other lesions (specific to dermatosis)	0%	0%	1.3%	48.5%**

* p<0.05 and ** p<0.001

Non-specific vulvoscopy findings in patients, diagnosed as "vulvodynia", were not relevant for the diagnosis of vulvodynia.

Diagnostic biopsy was not performed in any asymptomatic patient, or in patients with vulvodynia and discrete skin changes, following the ethical principles in the Declaration of Helsinki.

Statistical analysis was performed using software packages StatSoft, Statistica 12 and SPSS 20. Basic statistics, which involves calculating the mean (the arithmetic mean, quartiles, mode) and measures of dispersion (variance, standard deviation), was performed. Continuous outcome variables were analyzed using the Student's *t*-test as a parametric test or Mann-Whitney test as a nonparametric test. When the data were measured on a nominal or ordinal scale, the Chi-square test and Fisher's exact test were used. The hypothesis of the existence of differences between the distributions of random variables was investigated using the appropriate parametric or non-parametric tests with multivariate logistic regression, which is often used for the analysis of multivariate binary data. Logistic regression was used to test the significance of test-variables on the dependent variable (the existence of the disease). The likelihood that a person will suffer from a vulvar disease was described in this way, using non-linear links:

$$P = \frac{e^{\sum_{i=1}^n \alpha_i X_i}}{1 + e^{\sum_{i=1}^n \alpha_i X_i}}$$

whereas α_i ($i = 1, \dots, n$) were coefficients, X_i ($i = 1, \dots, n$) – values of corresponding independent variables, and n – number of variables.

Logistic regression was done on the basis of the data which consisted of 216 subjects, of which 54 were healthy and 162 suffered from vulvar dermatosis, vulvodynia or impaired vulvar skin. Any demographic variables were individually placed in logistic regression to determine the significance of each variable in estimating the probability of disease.

Results

The analysis of the results of the "Three Rings Vulvoscopy" revealed four groups of patients, as shown in Table 1.

All symptomatic patients with specific vulvoscopy lesions (n=33) were histopathologically diagnosed as suffering from "vulvar dermatosis".

Non-specific vulvoscopy lesions were found in 129 patients, of which 75 patients were anamnestic and clinically diagnosed with "vulvodynia" and 54 patients

Table 4. Vulvoscopy findings in the middle vulvar ring.

	Control group	Impaired vulvar skin	Vulvodynia	Vulvar dermatosis
THE MIDDLE RING				
All findings	0%	55.6%	72.0%	96.9%**
anterior commissure				
All findings	0%	9.3%	14.7%	60.6%**
Erythema	0%	5.6%	5.3%	24.2%*
Excoriations and fissures	0%	0%	0%	9.1%*
Smoothness	0%	0%	0%	6.0%*
Other lesions (specific to dermatosis)	0%	0%	1.3%	30.3%**
Interlabial sulci				
All findings	0%	29.2%	41.3%	93.9%**
Erythema	0%**	29.6%	38.7%	39.4%
Excoriations and fissures	0%	1.8%	1.3%	18.2%**
Other lesions (specific to dermatosis)	0%	0%	1.3%	45.4%**
Labia minora				
All findings	0%	12.9%	28.0%	78.8%**
Erythema	0%	9.3%	26.7%	33.4%*
Excoriations and fissures	0%	1.8%	1.3%	0%
Other lesions (specific to dermatosis)	0%	0%	0%	45.4%**
posterior commissure				
All findings	0%	38.9%	58.7%	84.8%*
Erythema	0%**	37.0%	54.7%	42.4%
Excoriations and fissures	0%	0%	1.3%	21.2%**
Other lesions (specific to dermatosis)	0%	1.8%	1.3%	30.3%**

* p<0.05 and ** p<0.001

Finding of any vulvoscopy lesion, both specific and non-specific, in the outer ring of the vulva was significantly more frequent in the patients with vulvar dermatosis in relation to the patients from the other groups ($p < 0.001$). Non-specific lesions in the patients with vulvodynia were not relevant for the diagnosis of vulvodynia.

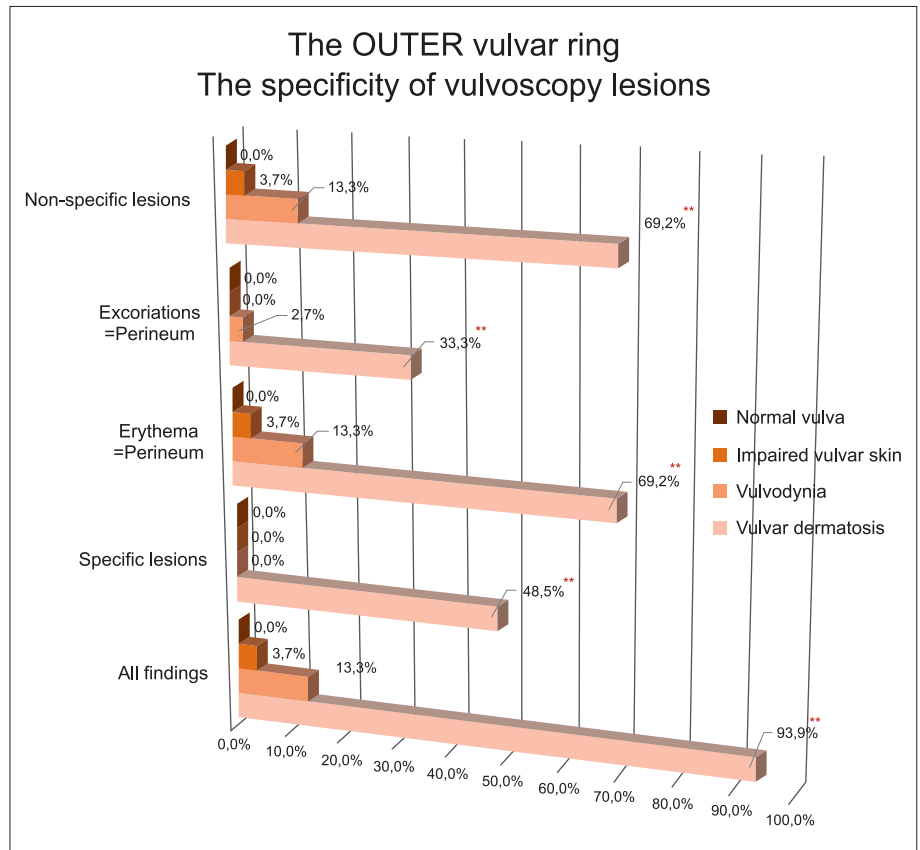


Figure 3. The specificity of vulvoscopy lesions in the outer ring of the vulva, $p < 0.001$ **

Diagnosis of any vulvoscopy findings, primarily specific lesions in the middle vulvar ring was significantly more frequent in the patients with vulvar dermatosis compared to the other groups. The incidence of excoriations in the fourchette was significantly higher in the patients with vulvar dermatosis. Non-specific lesions in the patients with vulvodynia were not relevant for the diagnosis of vulvodynia.

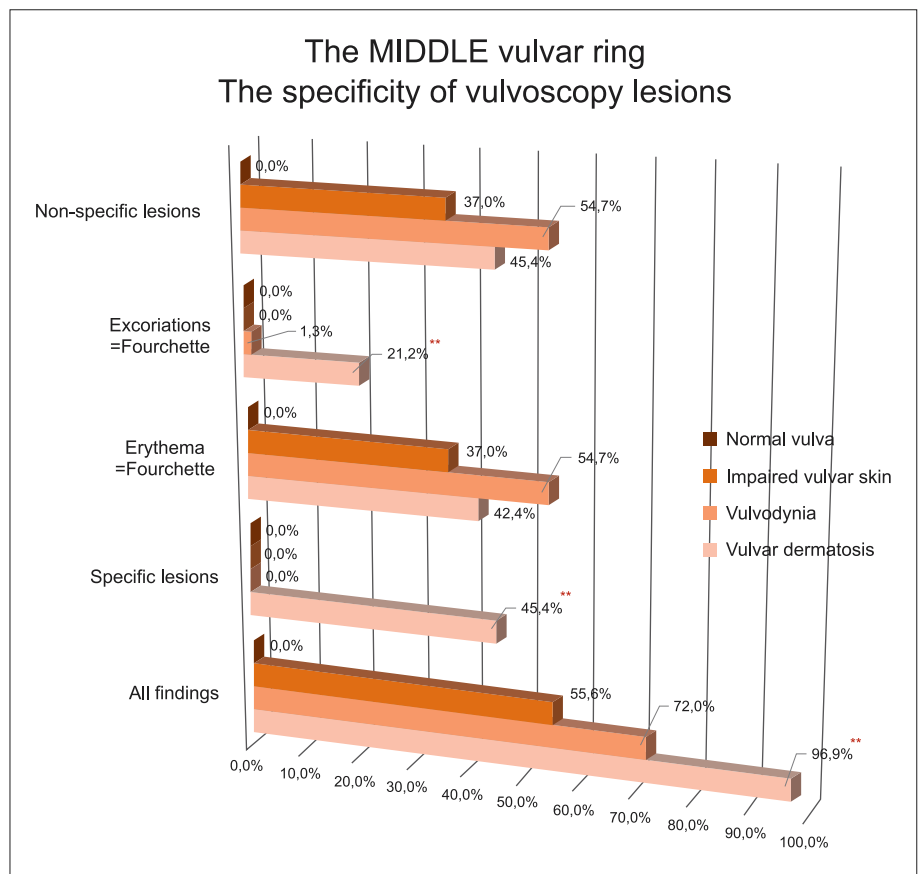


Figure 4. The specificity of vulvoscopy lesions in the middle ring of the vulva, $p < 0.05$ * and $p < 0.001$ **

were diagnosed with "impaired vulvar skin". "Normal vulva" was diagnosed in 54 asymptomatic patients.

There weren't diagnosed symptomatic patients without any vulvoscopy finding in all three vulvar rings or asymptomatic patients with specific lesion in any of the vulvar rings.

Demographic data

Although it was originally planned to have four groups with approximately same characteristics (same age, education and parity), the selection of symptomatic patients and a random selection of asymptomatic patients created differences, as shown in *Table 2*.

Logistic regression showed an increased probability of vulvar disease with increasing age (regression coefficient= 0.034; p-value=0.045). Additionally, a person with a higher level of education had a higher risk of vulvar disease compared to a person with low education (regression coefficient=0.517; p-value=0.105).

The analysis of the data other than vulvoscopy findings, given their magnitude, goes beyond the issues raised in this study, and therefore will be reported separately.

Vulvoscopy results

Vulvoscopy findings in the outer vulvar ring

Finding of both specific and non-specific lesions in the outer ring of the vulva, which were present in 93.9% of patients, was significantly more frequent ($p < 0.001$) in the group with vulvar dermatosis in relation to the patients from the other groups (*Table 3; Figure 3*).

Non-specific findings were found in 13.3% of patients with vulvodinia and 3.7% of patients with impaired vulvar skin. Non-specific findings in patients, diagnosed as vulvodinia, were not relevant for the diagnosis of vulvodinia.

Vulvoscopy findings in the middle vulvar ring

Diagnosis of any vulvoscopy findings, primarily specific lesions in the middle vulvar ring, was significantly more frequent ($p < 0.001$) in patients with vulvar dermatosis compared to the other groups.

The presence of non-specific lesions, specifically the erythema of interlabial sulci and fourchette, did not differ between the groups, but the incidence of erythema ($p=0.039$) and smoothness ($p=0.019$) of the anterior commissure and prepuce, and the incidence of excoriations in the fourchette ($p < 0.001$), were significantly higher in the patients with vulvar dermatosis (*Table 4; Figure 4*).

Vulvoscopy findings in the inner vulvar ring

There was a significant difference ($p = 0.046$) in the presence of any vulvoscopy findings, primarily non-specific lesions in the inner ring of the vulva in patients with vulvodinia and impaired vulvar skin compared to "vulvar dermatosis", and in all groups compared to a

"normal vulva" (*Table 5; Figure 5*). Non-specific findings in patients, diagnosed as vulvodinia, were not relevant for the diagnosis of vulvodinia.

The smoothness of the sub-clitoral rhombus was significantly more frequent ($p=0.003$) in the group with vulvodinia, whereas the paleness of urethral meatus ($p=0.030$), as well as Hart's line punctuations ($p < 0.001$) and Hart's line papillae ($p=0.006$) were significantly higher in the groups with vulvodinia and impaired vulvar skin in relation to "vulvar dermatosis" and "normal vulva".

There were no differences in the appearance of non-specific lesions of the clitoris, hymenal rests, Bartho-

Table 5. Vulvoscopy findings in the inner vulvar ring.

	Control group	Impaired vulvar skin	Vulvodinia	Vulvar dermatosis
THE INNER RING				
All findings	0%	98.1%*	97.3%*	87.9%
clitoris				
All findings	0%	38.9%	56.0%*	63.6%*
Erythema	0%**	20.4%	32.0%	18.1%
Loss of architecture	0%*	1.8%	1.3%	9.0%
Paleness	0%**	16.7%	22.7%	15.1%
Other lesions (specific to dermatosis)	0%	0%	0%	24.2%**
subclitoral rhombus				
All findings	0%**	87.0%	88.0%	78.8%
Erythema	0%**	46.3%	44.0%	33.3%
Paleness	0%**	38.9%	36.0%	27.3%
Smoothness	0%	18.5%	45.3%*	24.2%
Other lesions (specific to dermatosis)	0%	14.3%	4.0%	27.3%**
Hart's line				
All findings	0%**	87.0%	90.7%	75.8%
Erythema	0%**	79.6%	74.7%	66.7%
Punctuations	0%	46.3%**	49.3%**	15.1%
Papillae	11.1%	24.1%*	32.0%*	6.1%
Other lesions (specific to dermatosis)	0%	1.8%	2.7%	15.1%**
Bartholin's gland opening				
All findings	0%**	48.1%	60.0%	48.5%
Erythema	0%**	29.9%	56.0%	36.4%
Punctuations	0%	0%	0%	3.0%
Other lesions (specific to dermatosis)	0%	5.6%	4.0%	9.1%
vestibule				
All findings	0%**	61.1%	74.7%	69.7%
Erythema	0%**	48.1%	49.3%	48.5%
Punctuations	0%*	11.1%	6.7%	0%
Papillae	0%	9.3%	17.3%	18.5%
Paleness	0%**	9.3%	18.7%	15.1%
Other lesions (specific to dermatosis)	0%	0%	0%	21.2%**

* $p < 0.05$ and ** $p < 0.001$

There was a significant difference in the presence of any vulvoscopy findings, primarily non-specific lesions in the inner ring of the vulva in the patients with vulvodynia and impaired vulvar skin compared to vulvar dermatosis, and in all groups compared to a normal vulva. The smoothness of the sub-clitoral rhombus, the paleness of urethral meatus as well as Hart's line punctuations and Hart's line papillae were significantly more frequent in the patients with vulvodynia and impaired vulvar skin in relation to "vulvar dermatosis" and "normal vulva". Non-specific lesions in the patients with vulvodynia were not relevant for the diagnosis of vulvodynia.

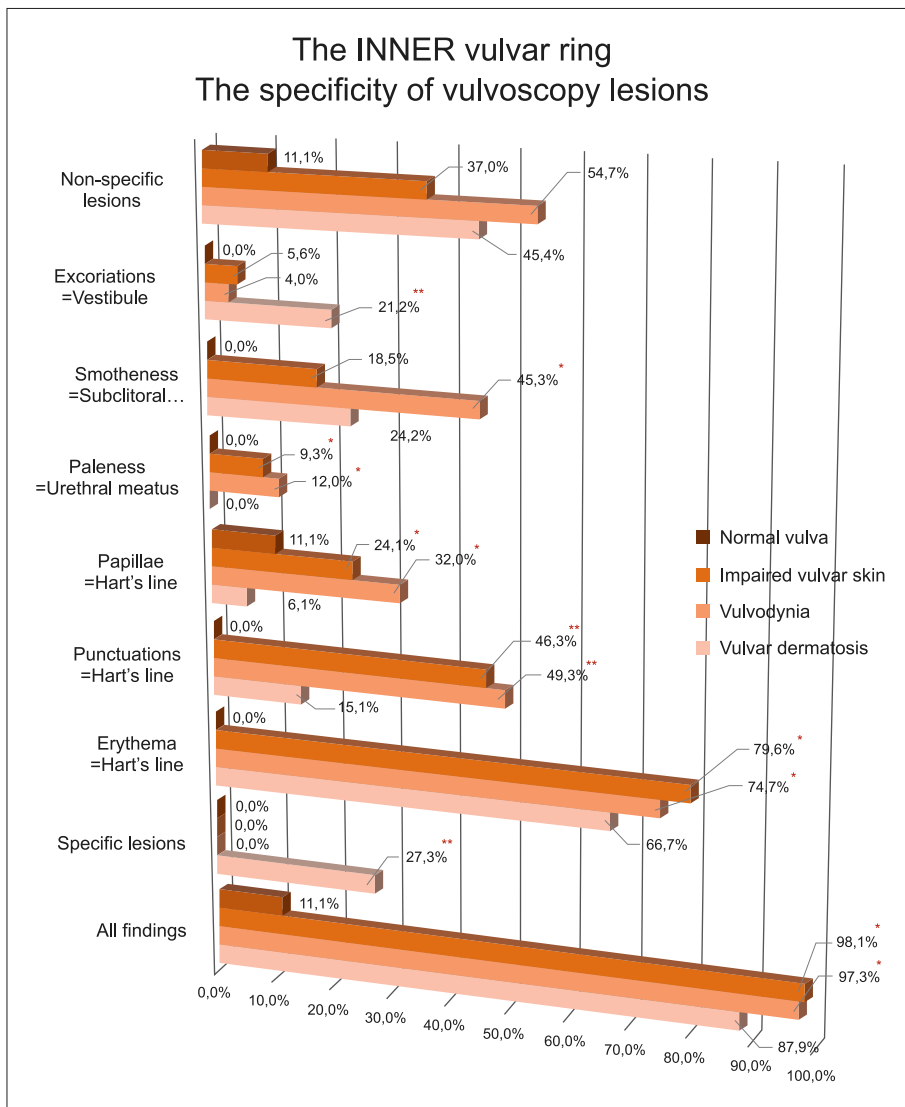


Figure 5. The specificity of vulvoscopy lesions in the inner ring of the vulva, p<0.05* and p<0.001**

lin's gland opening and in the vestibular area between the two groups, except in relation to a "normal vulva" (p<0.001).

Specific lesions of the clitoris, sub-clitoral rhombus, Hart's line and in the vestibular area were significantly more likely (p <0.001) in the group with vulvar dermatosis.

Discussion

The complexity of the anatomy of the vulva, which is based on embryological and histological differences, requires a different assessment of the seemingly same types of lesions in this area. Thickness of the vulvar skin affects the opacity; the vascular patterns are less marked and less reliable than with colposcopy of the cervix. Vascular aberrations, such as punctuations and mosaic, can be practically seen only on the inner portions of the labia minora where the keratin layer is thinner and vestibular epithelium does not contain a keratin layer. This is why the main principles of vulvoscopy

underline that histologically identical lesions may have different vulvoscopy appearance when present on different parts of the vulva.¹⁴ This was the reason for testing a new concept of vulvoscopy, adapted to the anatomy of vulva and for defining the three vulvar rings according to the differences in histological structure and embryological origin of the vulvar structures.

The introduction of a circular observation of the vulva and mapping of lesions depending on the histological structure of the vulvar rings as well as morphological evaluation of lesions according to their specificity (non-specific and specific) seems to be promising in the differential diagnosis of vulvar discomfort.

The actual study of vulvar colposcopic lesions has shown that vulvar dermatosis is characterized by the presence of specific and non-specific lesions in all three vulvar rings. A common characteristic of patients with vulvodynia and patients with impaired vulvar skin is a significantly higher incidence of non-specific lesions in the inner ring of the vulva. Given that the fundamental difference between the patients with vulvodynia and

impaired vulvar skin is the presence of vulvar symptoms, this study could open the debate on whether the patients with impaired vulvar skin without vulvar discomfort are a possible target population for the prevention of vulvodynia.

These data suggest the importance of maintaining the integrity of the skin of the vulva. Vulvar care guidelines are successful for the management of vulvar complaints, and previous research has shown a decrease in the mean score for dyspareunia, burning after intercourse, vulvar burning, vulvar itching and vulvar pain.^{7,15} This study raised the question whether the vulvar care measures should also be recommended to asymptomatic women with impaired vulvar skin.

Study limitations include the lack of histopathological diagnosis in patients with normal vulva, and impaired vulvar skin and in more than half of patients with vulvodynia. Diagnostic biopsy was not performed in these patients, following the ethical principles in the Declaration of Helsinki. In addition, it is difficult to determine the significance of any changes observed in patients experiencing vulvodynia, as previous studies have demonstrated histological variance in the asymptomatic population. The histopathology of vulvodynia remains an area of controversy, with findings which support both an inflammatory and a non-inflammatory disease state in the literature.¹⁶

We described an original technique for performing colposcopy of the vulva called "Three Rings Vulvoscopy", taking into account three different skin types and zones, which are approximately ring-shaped, as well as morphological evaluation of lesions according to their specificity (non-specific and specific lesions). The new vulvoscopy technique seems to be promising in the differential diagnosis of vulvar discomfort.

"Three Rings Vulvoscopy" is being proposed in order to encourage others to adopt it and prove it in clinical practice.

Acknowledgements

I would like to express my deep gratitude to Olaf Reich and Sigrid Regauer from the University of Graz, Austria, who have, year after year, unselfishly shared not only their extensive knowledge and experience, but also their immense enthusiasm, with all participants of their Workshops on Colposcopy and Vulva. My sincerest appreciation for their support. Vesna Harni.

Ethical approval. The study was approved by the Poliklinika Harni Institutional Review Board, Ethical Approval Number 20111201001 from December 1, 2011.

Declaration of authorship. VH performed "Three Rings Vulvoscopy" and DBab performed histopathological examination. All three authors contributed to the design of the study and discussed the results. VH performed the literature search and wrote the manuscript. With the submission of the manuscript we hereby declare that all the authors have approved its contents and submission to the journal.

The contents of this manuscript have not been previously published, or submitted for consideration for publication to any other journal.

Competing interests: No conflict of interest.

Author disclosure: Nothing to disclose.

References

- Ridley's The Vulva, Third Edition. Edited by Sallie M. Neill and Fiona M. Lewis. 2009 Blackwell Publishing. ISBN: 078–1–4051–6813–7.
- Friedrich EG. The vulvar vestibule. *J Reprod Med* 1983; 28:7373–7.
- Woodruff JD, Friedrich EG. The vestibule. *Clin Obstet Gynecol* 1985;28:134–41.
- Lynch PJ, Moyal-Barracco M, Scurry J, Stockdale C. 2011 ISSVD Terminology and Classification of Vulvar Dermatological Disorders: An Approach to Clinical Diagnosis. *J Low Genit Tract Dis* 2012;16(4):339–44.
- Bornstein J, Sideri M, Tatti S, et al. 2011 Terminology of the Vulva of the International Federation for Cervical Pathology and Colposcopy. *J Low Genit Tract Dis* 2012;16(3):1–6.
- Moyal-Barracco M, Lynch PJ. 2003 ISSVD Terminology and Classification of Vulvodynia: A historical perspective. *J Reprod Med* 2004;49:772–7.
- Haefner HK, Collins ME, Davis GD, Edwards L, Foster DC, Hartman ED, et al. The vulvodynia guideline. *J Lower Gen Tract Dis* 2005;9:40–51.
- ACOG Committee Opinion Number 345. Vulvodynia. *Obstet Gynecol* 2006;108:1049–52.
- Stockdale CK, Lawson HW. 2013 Vulvodynia Guideline Update. *J Low Genit Tract Dis*. 2014;18(2):93–100.
- ISSVD Vulvodynia Pattern Questionnaire. Available at: <https://netforum.avecra.com/temp/ClientImages/ISSVD/3ef9c6ea-aac7-4d2b-a37f-058ef9f11a67.pdf> / Last accessed May 23, 2015.
- Julian TM. Vulvar Pain: Diagnoses, Evaluation, and Management. *J Low Genit Tract Dis* 1997;1(3):185–94.
- Bohm–Starke N. Medical and physical predictors of localized provoked vulvodynia. *Acta Obstet Gynecol* 2010;89:1504–10.
- Slominski A. A nervous breakdown in the skin: stress and the epidermal barrier. *J Clin Invest* 2007;117(11):3166–9. doi: 10.1172/JCI33508.
- Kesic V. Colposcopy of the vulva, perineum and anal canal. IN Bösze P, Luesley D eds. EAGC Course book of colposcopy, Chapter 14; 2004; 126–63. available at: <http://www.yalaphc.net/readbook/colposcopy-of-the-vulva-perineum-and-anal-canal-kntf.html> / Last accessed May 23, 2015.
- Lifits-Podorozhansky YM, Podorozhansky Y, Hofstetter S, Gavard JA. Role of Vulvar Care Guidelines in the Initial Management of Vulvar Complaints. *J Low Genit Tract Dis* 2012;16(2):88–91.
- Brokenshire C, Ross Pagano, Scurry J. The Value of Histology in Predicting the Effectiveness of Vulvar Vestibulectomy in Provoked Vestibulodynia. *J Low Genit Tract Dis* 2014;18(2):109–114.

Corresponding address: Vesna Harni, MD, Poliklinika Harni, Bukovacka 1, HR-10000 Zagreb, Croatia; *e-mail:* vesnaharni@gmail.com

Paper received: June 1st 2014. *Paper accepted:* December 12th 2014.

„VULVOSKOPIJA TRI PRSTENA” – NOVI PRISTUP VULVI

Vesna Harni, Damir Babic, Dubravko Barisic

Stručni članak

Ključne riječi: vulvoskopija, tri vulvarna prstena, bolesti vulve, vulvodinija, oštećenje kože vulve

SAŽETAK. *Cilj.* Testirati novi pristup vulvarnim tegobama prilagođen anatomiji vulve i specifičnostima vulvarnih lezija. *Metode.* U retrospektivnom opservacijskom istraživanju analizirali smo rezultate izvorne vulvoskopske tehnike nazvane „Vulvoskopija tri prstena”, kod sveukupno 216 ginekoloških pacijentica bez ili s vulvarnim tegobama, kod kojih su kolposkopske promjene vulve dokumentirane prema specifičnosti i lokalizaciji uz pomoć ISSVD upitnika za vulvodiniju. *Rezultati.* Analiza rezultata je otkrila četiri skupine ispitanice: asimptomatske pacijentice bez vulvoskopskog nalaza i asimptomatske pacijentice s nespecifičnim lezijama, simptomatske pacijentice s nespecifičnim lezijama i simptomatske pacijentice sa specifičnim vulvoskopskim nalazom. Vulvoskopski nalaz kod asimptomatskih pacijentica u odsutnosti lezija u bilo kojem od vulvarnih prstenova označen je kao „normalna vulva”. Simptomatske pacijentice sa statistički značajno češćim nalazom i specifičnih i nespecifičnih lezija u sva tri vulvarna prstena, u usporedbi s drugim pacijenticama, imale su dijagnozu „vulvarne dermatoze”. Odsutnost specifičnih lezija u bilo kojem od vulvarnih prstenova i značajno veća učestalost nespecifičnih nalaza u unutarnjem prstenu vulve bile su uobičajene karakteristike pacijentica s „vulvodinijom” i „oštećenom vulvarnom kožom” (vulvoskopske promjene bile su irelevantne u postavljanju dijagnoze vulvodinije). Temeljna razlika između tih ispitanica bila je prisutnost vulvarnih tegoba u bolesnica s vulvodinijom. Analizom nije pronađena niti jedna simptomatska pacijentica bez vulvoskopskih lezija, kao niti jedna asimptomatska pacijentica sa specifičnim lezijama u bilo kojem od vulvarnih prstenova. *Zaključak.* „Vulvoskopija tri prstena” s procjenom specifičnosti vulvarnih lezija čini se obećavajućom u diferencijalnoj dijagnostici vulvarnih tegoba. Predložena je nova vulvoskopska tehnika u cilju poticanja drugih na usvajanje i dokazivanje u kliničkoj praksi.